

We are IntechOpen, the world's leading publisher of Open Access books Built by scientists, for scientists

4,800

Open access books available

122,000

International authors and editors

135M

Downloads

Our authors are among the

154

Countries delivered to

TOP 1%

most cited scientists

12.2%

Contributors from top 500 universities



WEB OF SCIENCE™

Selection of our books indexed in the Book Citation Index
in Web of Science™ Core Collection (BKCI)

Interested in publishing with us?
Contact book.department@intechopen.com

Numbers displayed above are based on latest data collected.
For more information visit www.intechopen.com



Differential Diagnosis of Hepatocellular Carcinoma on Computed Tomography

Kristina Zviniene
*Lithuanian University of Health Sciences
Lithuania*

1. Introduction

Focal liver lesions (FLL) are common pathological findings in patients investigated for different gastrointestinal and other diseases. After detecting FLL radiologically, their clinical differential diagnosis is very important.

The precise identity and description of blood circulation of FLL is essential for differential diagnosis by computer tomography (CT). This is why the evaluation of the effectiveness of CT diagnostic criteria in diagnosing FLL is a relevant problem of theoretical and practical radiology, gastroenterology, surgery and oncology.

Multislice spiral CT is a perfect imaging modality to evaluate large area in a short time and visualize lesion optimally with an injection of contrast media (c/m). Scanning may include unenhanced images (without c/m), arterial, portal venous and delayed phases. The speed of contrast injection and optimal scanning protocol are crucial to separate all phases, what is very important in differential diagnostics of FLL.

It is important to optimize scanning time delay in order to achieve qualitative liver CT images. This can be achieved in few ways, including fixed time delay, "bolus" test and automatic scanning technology. In most hospitals and clinics contrast enhanced CT is performed simultaneously with the same scan delay .

To evaluate focal liver lesions Foley and Mallisee suggested triphasic multislice CT. When the whole liver is scanned in 10 sec. or even less, it's possible to achieve different liver CT images in particular time. In arterial phase (25-30 sec. after c/m injection) you can see the ramification of arteries without portal blood addition, contrary in portal venous phase c/m flows into portal vein. This phase is in 45-50 sec. after the c/m injection starts.

In daily practice additional venous phase images are not necessary, however it could help in doubtful cases. This phase starts in about 70-120 sec. after IV "bolus" injection. As concentration of non-ionic c/m, including iodine, inside and outside the artery is probably the same, some FLL have tendency to "disappear" in this phase. Despite that, this phase is very useful in differentiating cholangiocarcinoma (I-CCC) from other FLL. Delayed phase is important in differential diagnosis of cholangiocarcinoma and hemangioma.

Murakami et al. described double CT scanning in arterial phase. Analyzing early and delayed arterial phase CT images, the so called pseudo-tumours can be found that is a great

problem for the patients with liver cirrhosis. But the importance of this method is controversial nowadays, so it is not included into the CT scanning protocols.

In contrast enhanced CT, faster injection (4-5 ml/sec.) is recommended, which guarantees earlier and brighter peak of enhancement in the arteries, and also improves temporal separation of arterial, portal venous and venous phases.

Concentration of c/m is also very important in contrast enhanced CT. Data from few sources confirms the hypothesis that the concentration of c/m improves greater enhancement and hypervascular liver lesions diagnostics.

Multislice spiral CT has a few advantages in abdominal imaging: gradual and minor inspiration and breath hold decrease body movements and ensure higher quality of the images. With improvement of CT scanners optimization of scanning is necessary to maximize the ability of getting new CT images.

Few studies suggest that multiple-phase CT scans are useful in differentiation and blood supply evaluation of solitary liver lesions. This is why CT scans should be evaluated separately in all phases.

There are multiple FLL types. Even such condition as fatty liver degeneration which is not considered as tumour should be differentiated. This is the reason why all FLL must be classified to make their diagnosis as objective and precise as possible.

Based on the literature, incidentally found <2.0 cm liver lesions of unknown origin, are benign in 75% of all cases, but USA scientists say, it is only about 50%. Scientists from Italy state that <1.5 cm FLL, diagnosed in people with extra-hepatic malignant process are benign in 80% of all cases.

From radiological point of view FLL are classified to hyper- and hypovascular, and also cystic and solid.

The aim is to describe the most important contrast enhanced CT diagnostic criteria for differentiating solid FLL.

2. Most common benign focal liver lesions

Liver cysts are the most common FLL, and they are usually detected incidentally during common follow-up. Liver cysts have specific US, CT and MRI features, so the radiological diagnosis is always clear, usually not complicated and it is not a medicine practice problem. This is why the diagnostics of liver cysts is not discussed in this paper. The diagnostics of non-cystic lesions is much more important and topical.

2.1 Liver hemangioma

Liver hemangioma is the most common (after liver cysts) benign liver lesion presenting 0.4-20% of all liver tumours. Normally it is solitary, well-defined vascularized lesion that can reach 20.0 cm in size. Hemangioma is composed of multiple vascular channels surrounded by endothelium cells with thin fibrotic stroma. Large hemangiomas are usually detected in older patients, with an average age of 54 years. Giant hemangiomas have non-homogenous structure because of fibrosis, necrosis, and cystic zones.

On unenhanced CT scans hemangiomas are hypodense with well-defined borders. Calcification is rare (10-20%) and usually detected occasionally. Calcifications have rarely been reported in sclerosed or hyalinized and giant hemangiomas. The calcifications can be marginal or central; large and coarse; or multiple, small, and punctuate (e.g. phleboliths). Massive calcification of hemangiomas is extremely rare. The finding of a non-enhancing liver tumour with calcification should not preclude the diagnosis of hemangioma.

Performing contrast enhanced CT (in 2-15 min. after the injection of contrast media) peripheral nodular enhancement with centripetal fill in is observed. An early enhancement of FLL even before contrast media appears in the aorta is typical for hemangioma. According to several authors, globular enhancement in hemangiomas is seen with 88% of sensibility and 84-100% specificity. The lesion is filled-in with c/m depending on the size of hemangioma (fig.1).

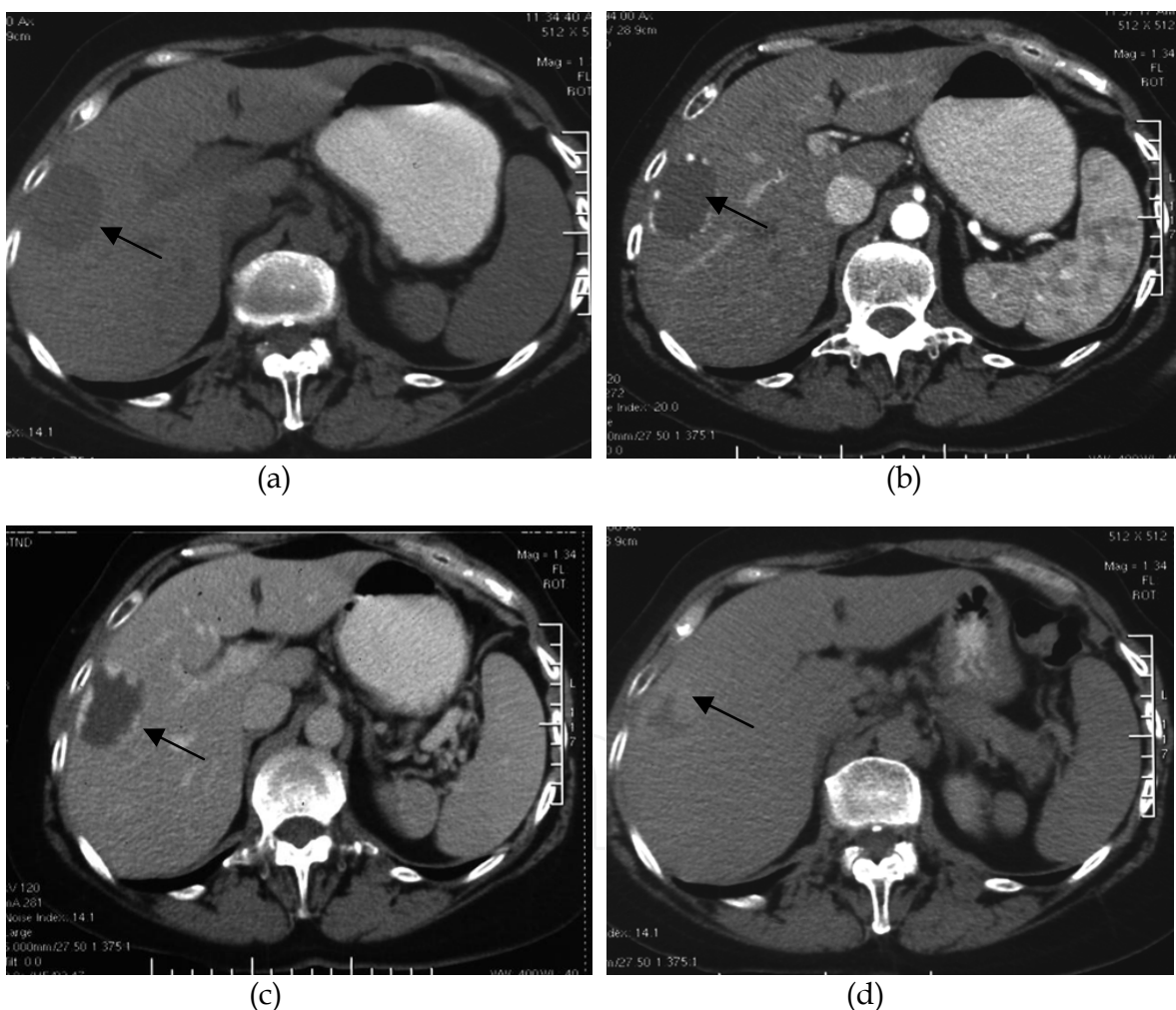


Fig. 1. Typical hemangioma. (a) Precontrast axial CT images demonstrate a hypodense lesion in the right hepatic lobe. (black arrow) (b,c) Arterial-phase and venous-phase images show progressive, peripheral nodular enhancement of the lesion with centripetal fill in. (arrow) (d) Delayed-phase images show that the lesion is isodense compared to the surrounding liver parenchyma an appearance that suggest persistence of contrast material within the lesion. (arrow)

Small hemangiomas (42% of hemangiomas are <1 cm) enhance rapidly and intensively in an early arterial phase (about 16% of all hemangiomas). The smaller the lesion, the faster it fills in with c/m.

This sign makes it more difficult to differentiate hemangiomas from other hypervascular tumours: islet cell metastases, small HCC, etc. Small hypodense hemangiomas are particularly problematic in patients with underlying malignancy. Some metastases can also have peripheral globular enhancement. Leslie et al. noticed that up to 8% of all cases metastases can show the same enhancement pattern. Another important differential diagnostic sign of hemangioma is attenuation equivalent to that of the aorta during all CT phases. Another valuable sign in differential diagnosis of hemangioma and malignant liver lesion is peripheral hypodense rim at the periphery of the mass. It indicates malignant neoplasm and is never seen in hemangiomas.

Large hemangiomas usually look like heterogenic lesions that enhance normally, however large hemangiomas with scar tissue do not enhance gradually, thus, there are non-enhanced areas.

In the late phase (10 min. after injection of contrast media) hemangiomas become isodense to surrounding liver parenchyma. This is one of the most important signs in differential diagnostics of hemangioma (fig.2)

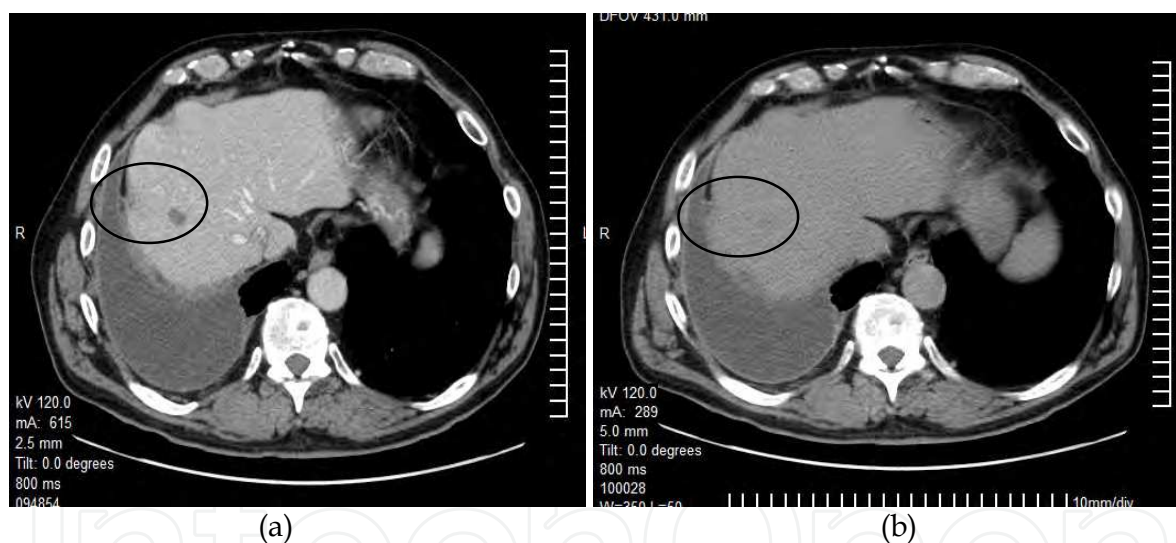


Fig. 2. Atypical hemangioma. (a) Portal venous- phase; there is no visible enhancement in the lesion (b) Delayed-phase CT image shows that the lesion is isodense compared to the liver (circle).

Sometimes in the late phase slight peripheral enhancement may be seen. This way of contrast uptake is typical of hyalinized hemangioma that, according to some authors, is the last stage of the development of hemangioma. These hemangiomas must be differentiated from malignant tumours of the liver. Percutaneous biopsy is indicated in these cases. In the late phase small hemangiomas (<1 cm) are still slightly hypodense, but hypervascular metastases become contrast-free.

In case of liver steatosis hemangiomas are usually iso- or hyperdense. On unenhanced CT images hemangiomas are isodense to hepatic vessels. Thrombosed, fibrosed or

degenerated areas are specific to large hemangiomas and are hypodense compared to hepatic vessels.

Though centripetal fill in is specific to hemangiomas, this finding is not pathognomonic; sometimes hepatocellular carcinoma (HCC), cholangiocarcinoma or even liver metastases may have the same features. What is more, early peripheral nodular enhancement can be found in some focal nodular hyperplasia or vascular abnormalities.

Liver hemangiomas are differentiated from focal nodular hyperplasia (FNH) in up to 23% of all cases, however two or more different lesions may be found in the same liver. 33% of multiple FNH should be differentiated with hemangioma. When the tumours have typical CT features, the diagnosis can be made with confidence.

Large heterogeneous hemangiomas must be differentiated from all liver lesions that have scars: FNH, hepatocellular adenoma (HCA), hepatocellular carcinoma (HCC), intrahepatic cholangiocarcinoma. Large hemangiomas usually demonstrate cleft-like central or eccentric areas of scarring that constitute areas of fibrosis, sclerosis (i. e. hyalinization), cystic degeneration, or thrombosis. These areas have variable shape and size and usually do not demonstrate delayed contrast enhancement (fig.3).

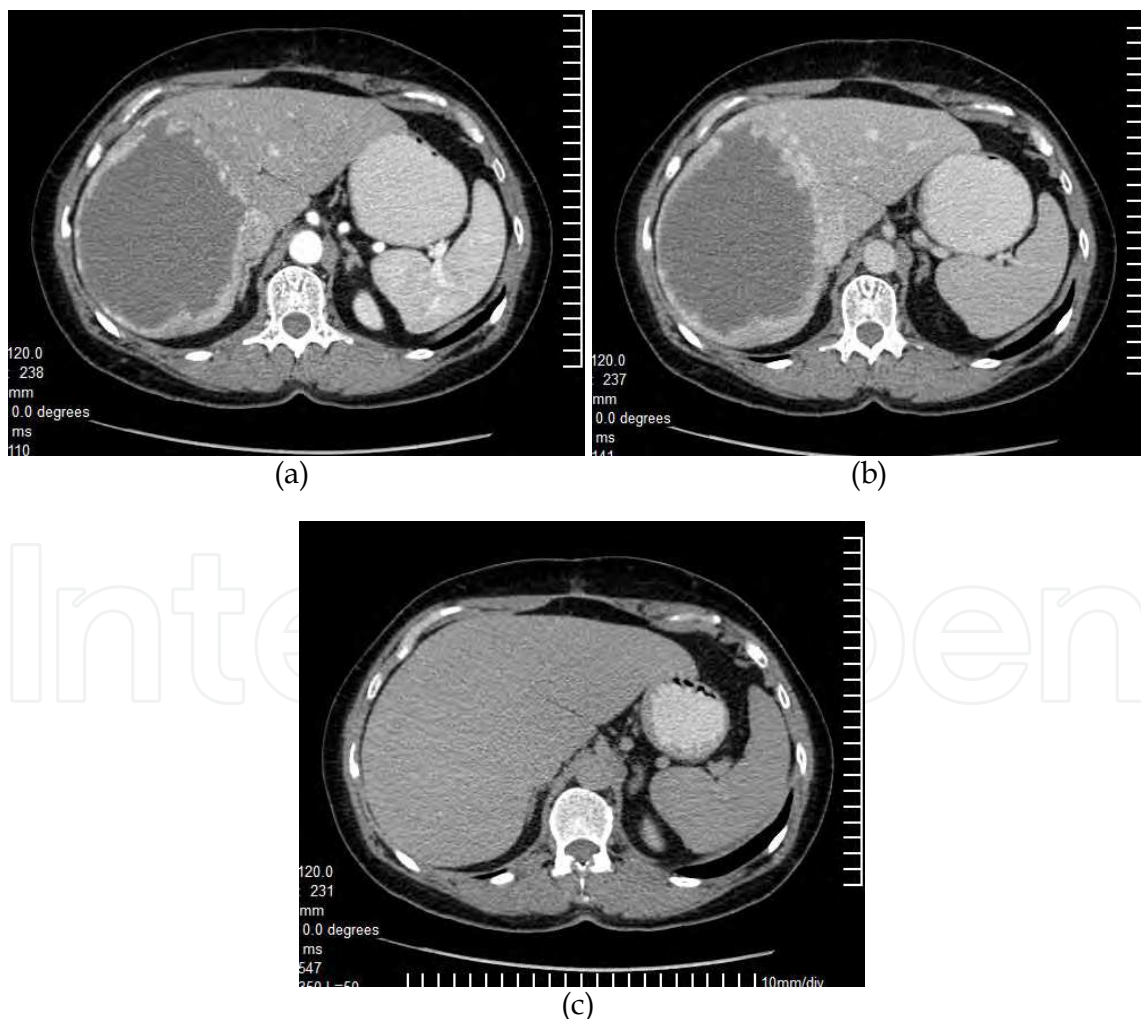

Fig. 3. Large hemangioma. Contrast-enhanced CT images show the typical enhancement pattern of hemangioma.

The essential criteria of evaluation of liver hemangiomas CT images are as follows: hypodense or isodense lesion on precontrast CT images; early peripheral nodular ring enhancement in arterial phase with centripetal fill-in in portal venous phase; and isodense lesion in the delayed phase. Based on these criteria our study shows that CT scanning is 91 % sensitive and 93 % specific.

2.2 Focal nodular hyperplasia

Focal nodular hyperplasia (FNH) is the hyperplastic process of liver, characterized by normal histological view of liver structure, but abnormal arrangement of it. FNH accounts for 1-8% of all primary liver tumours and it is the second most common benign liver neoplasm (after hemangiomas). FNH is diagnosed mostly in women (80-90%) in their twenties-fifties. Oral contraceptives are very important for the development of FNH, particularly the growth of it, but not formation de novo. In men FNH can be diagnosed in those taking anabolic steroids or having testicular tumour.

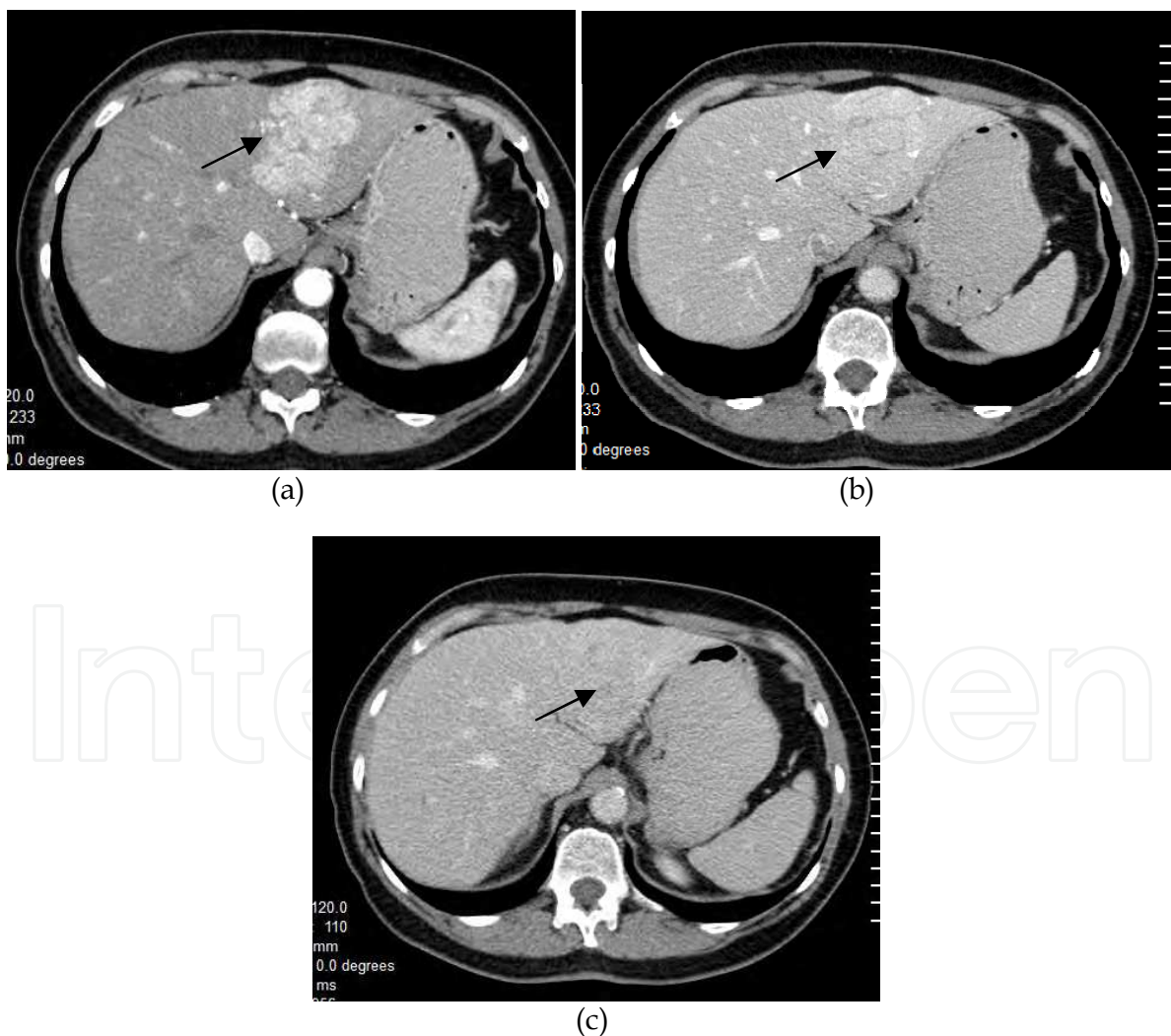


Fig. 4. Focal nodular hyperplasia with deformation of the liver margin . (a) In the arterial phase the hypervascular lesion with a hypodense central scar appears. (b,c) In the portal venous phase CT image FNH is iso- or hypodense to the liver. (arrow)

Etiology and pathogenesis of FNH are unclear. Histologically it is characterized as neoplasm with star-shaped central scar, surrounded with nodules of hyperplastic liver cells and minor bile ducts. In 95% of cases FNH is well-defined solid tumour with clear margins and central scar with blood vessels coming from it. Normally FNH is less than 5.0 cm in diameter and they are usually diagnosed not smaller than 3.0 cm.

On non-enhanced CT images FNH appears as hypodense (42-57%) or isodense (40-48%) lesion without well-defined borders and sometimes with more intensive hypodense central zone. If the lesion is isodense, the 'mass' effect may be the only criteria for detecting FNH. In 15-33% of patients, unenhanced CT images show the hypoattenuating stellate central scar with a central core and radiating fibrous septa. FNH is often subcapsular and that can complicate the course of adjacent vessels.

One third of FNH grows exophytically and deforms contours of the liver (fig.4).

In arterial phase FNH enhances rapidly and becomes hyperdense (89-100%) because of vascularization of hepatic arteries (entering the FLL). In this situation hypodense central scar is seen clearly.

In portal venous phase the difference between FNH and normal liver parenchyma decreases, and later lesion becomes hypodense except for the central scar which is hyperdense in this phase (usually this scar is formed of afferent central vein) (fig.5).

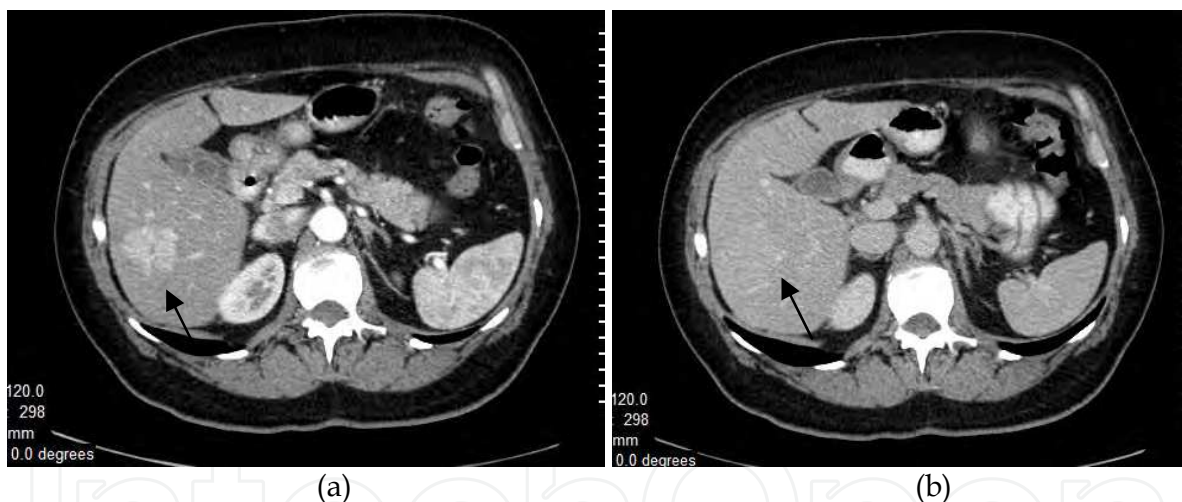


Fig. 5. Focal nodular hyperplasia. (a) Arterial phase CT image shows homogeneous enhancement of the lesion, except for the central scar. (arrow) (b) Contrast-enhanced CT image on the portal venous phase shows isoattenuating enhancement of the lesion compared to the liver. (arrow).

Although the typical CT features of FNH are characteristic, atypical features may be seen in more than half of cases. Multiple focal nodular hyperplasias occur in about 20% of patients. Atypical FNH may show less intense enhancement, unusual appearance on non-enhanced central scar and pseudocapsular enhancement on delayed images. In these cases it is very difficult to differentiate FNH from other benign and malignant lesions, such as HCA, HCC, hypervascular liver metastases of FLC.

A central scar is histologically present in almost all patients with FNH. However, it may be subtle and extremely small and is identified with the use of CT in 30%-50% of cases.

Presence of a central scar is clearly related to the size of the lesion. 35% of small FNH (<3 cm) and 65% of large FNH (>3 cm) demonstrated central scar. FNH lesions smaller than 3 cm in size may be more difficult to distinguish from other hypervascular lesions. The scar is typically thin and small and is hypodense compared with the rest of the FNH on unenhanced images, hepatic arterial and portal venous phase images. On delayed phase images, the scar often becomes hyperdense because of retention of contrast media (fig.6).

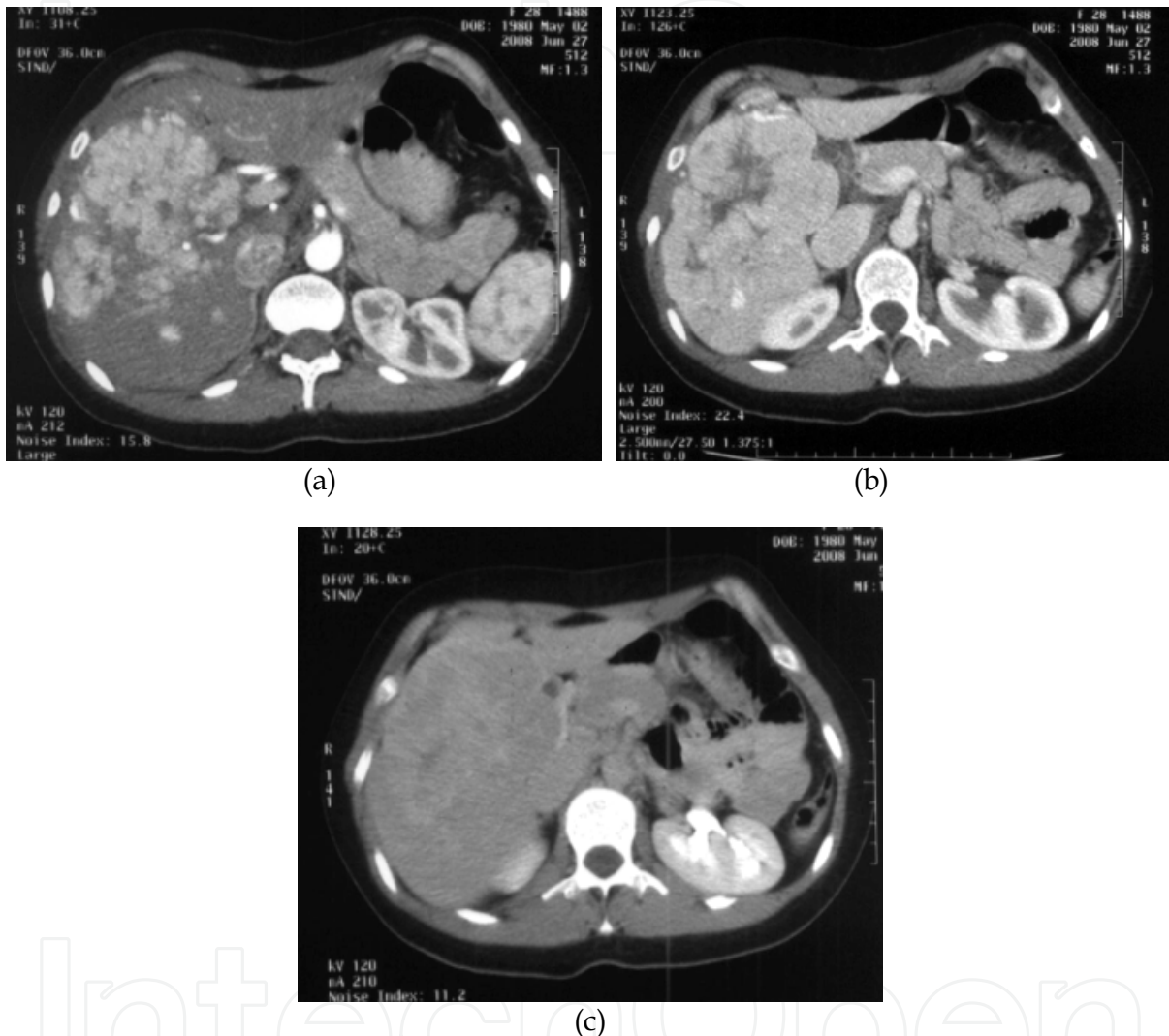


Fig. 6. Large atypical focal nodular hyperplasia. (a) Arterial phase CT image shows lobulated enhancement with a thick irregular scar of the lesion. (b,c) In the portal venous phase, FNH is slightly hypodense to the liver. The central scar shows contrast enhancement. Pseudocapsule is evident.

Although central scar is very specific for FNH, it can also be seen in other atypical malignant liver lesions, such as gigantic liver hemangioma.

Pseudocapsule is one of atypical FNH signs (8% of cases), which is usually seen in liver steatosis because of the peripheral fibrosis of liver under pressure. Pseudocapsule may be more dense than the liver or FNH. Pseudocapsule should not be regarded as a sign of malignancy.

Internal haemorrhage or necrosis is seen in less than 6% of all cases. Calcification, fatty or necrotic zones are not common findings in FNH.

In some patients with hepatic steatosis, FNH is still isodense or hypodense on non-enhanced CT images; in rare cases, this may be due to fatty infiltration of FNH. Hypothetically, intralesional steatosis in focal nodular hyperplasia can be expected in several types of hepatic injury associated with steatosis, such as alcoholic toxicity, obesity, diabetes, malnutrition, and protein malabsorption.

FNH-like nodules in the cirrhotic liver are usually hypervascular, and they can mimic HCC. Although CT images give you precise diagnosis of FNH in most cases, rarely, a false-positive diagnosis of FNH occurs in cases of fibrolamellar hepatocellular carcinoma, as well as in cases involving other well-differentiated variants of hepatocellular carcinoma. The essential FNH criteria of evaluation are as follows: slightly hypodense lesion with brighter low density zone in the centre on unenhanced CT images; strongly homogenous enhancement with hypodense central zone in the arterial phase; and isodense zone with central hyperdense zone in the venous phase. CT scanning is 78% sensitive and 89% specific.

2.3 Hepatocellular adenoma

Hepatocellular adenoma (HCA) is a rare benign liver lesion, which in 80% of cases is a solitary well defined tumour with a capsule. Oral contraceptives and steroids are one of the reasons of HCA development. HCA are more common in women in their twenties-forties. The difficulty of differential diagnosis of FNH and HCA is further compounded by the fact that both types of lesion typically occur in fertile women with a history of oral contraceptive use, who may be asymptomatic. People with glycogen metabolism disorders and haemosiderosis, as well as anabolic steroids taking males, are at a greater risk of HCA development. By the way pregnancy is one of the HCA risk factors. Normally HCA are 8-10 cm sized; in 70-80% of cases they are solitary tumours, however multiple adenomas can occur (sometimes >10 cm). HCA are difficult to differentiate from other hypervascular liver tumours.

Adenomas are more likely to contain areas of heterogeneity, fat, necrosis, hemorrhage and calcification rather than FNH. Adenomas are well defined (85% of cases), non-lobulated (95%), sometimes encapsulated (30%) and rarely calcified (10%).

While adenomas are also benign, they have a low-grade-malignancy potential, may bleed spontaneously, and are usually resected if they are large or if the diagnosis is doubtful. The diagnosis of this benign tumour is important as there is a possibility of rupture. Approximately 50% of tumours demonstrate intratumoural haemorrhage and can present with haemoperitoneum followed by hypotension and shock.

HCA can transform into hepatocellular carcinoma.

Adenomas consist almost entirely of uniform hepatocytes and a variable number of Kupffer cells, most of the adenomas in our experience are nearly isodense compared to normal liver on unenhanced images, portal venous, and delayed-phase images.

Diagnosis of HCA based only on CT scans is complicated, although a few specific HCA signs can be described. On precontrast CT images fatty HCA inserts may look like

hypodense areas, and acute subcapsular haemorrhage looks like hyperdense areas. Necrosis and haemorrhage are detected in nearly 25% of HCA.

On contrast enhanced CT images in arterial phase you can see intensive peripheral contrast enhancement, which is caused by subcapsular vessels of the lesion. Central part of the lesion is filled with contrast media (cm) pretty fast as well. The lesion becomes hyperdense, however we can see washout and in portal-venous and late phases HCA becomes isodense. HCA showed more wash-out in the portal phase and 22% of the HCA may be hypodense (fig. 7).

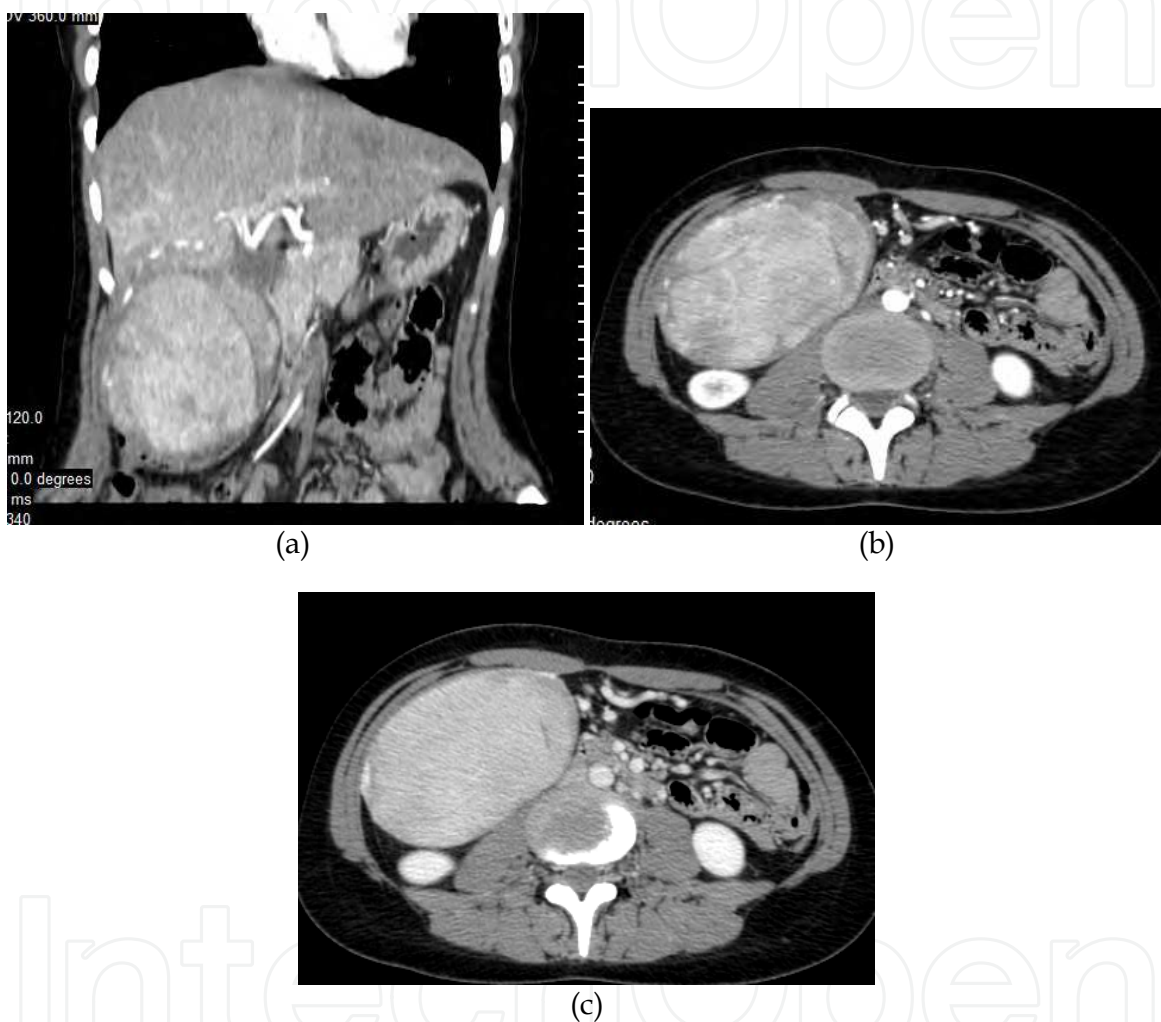


Fig. 7. CT images of large hepatocellular adenoma. A big lesion is seen in S6, deforms hepatic inferior border and goes down up to the level of the right kidney (a) Coronal image. (b,c) Axial images. Hepatic CT arterial phase (a,b) shows slightly heterogeneous enhancement of the tumor. (c) Portal venous CT phase: tumor becomes isointense and homogenous.

These features are typical to the lesions that are smaller than 3.0 cm in size. In some cases a thin capsule can be identified. Small adenomas enhance faster than normal liver tissue. In about 80% of cases HCA demonstrated homogeneous or nearly homogeneous enhancement, except for the acute or previous haemorrhage or fatty tissue in it.

In patients with liver steatosis HCA is hyperdense in all phases.

The differentiation of adenoma from hypervascular metastases may be difficult or even impossible. Most hypervascular metastases are multiple and will manifest as lesions or portions of lesions that are hypoattenuating or hypodense compared to normal liver parenchyma on unenhanced images, portal venous, and late-phases. It is crucial to identify if there is a primary tumour, for example, pancreatic or kidney carcinoma. In the age group of women, who are usually diagnosed with HCA, breast or thyroid carcinomas are the most likely to be the primary tumours.

The essential HCA diagnostic criteria are as follows: isodense lesion on unenhanced CT images; diffuse homogenous enhancement in arterial phase; isodense lesion in venous phase. Contrast enhanced CT shows 71% sensitivity and 93% specificity.

2.4 Rare benign focal liver lesions

2.4.1 Angiomyolipoma

Angiomyolipoma is a benign mesenchymal tumour that usually involves the kidney and rarely the liver. Lipomas or angiomyolipomas have been found in 10% of patients with tuberous sclerosis but can occur in patients without the disease. Angiomyolipomas can be diagnosed in patients of different age and sex, but are more common in women. The lesion can be of different size and may be solitary or multiple. Extremely rare cases of hepatic angiomyolipomas with spontaneous rupture, tumor recurrence, and vascular invasion were reported.

Hepatic angiomyolipomas are composed of varying portions of fat, epithelioid and spindled smooth muscle cells, and thick-walled blood vessels. The imaging features of hepatic angiomyolipomas depend on the relative proportions of the tumour components. It is difficult to diagnose hepatic AMLs with low fat content. Occasionally, it is difficult to distinguish hepatic AMLs from other fat-containing hepatic tumours, such as HCC with fatty metamorphosis, lipoma, and liposarcoma. The feeding blood vessels can be seen in other hypervascular lesions such as HCC and FNH, but the vessels in those cases usually are located in the periphery of the lesion.

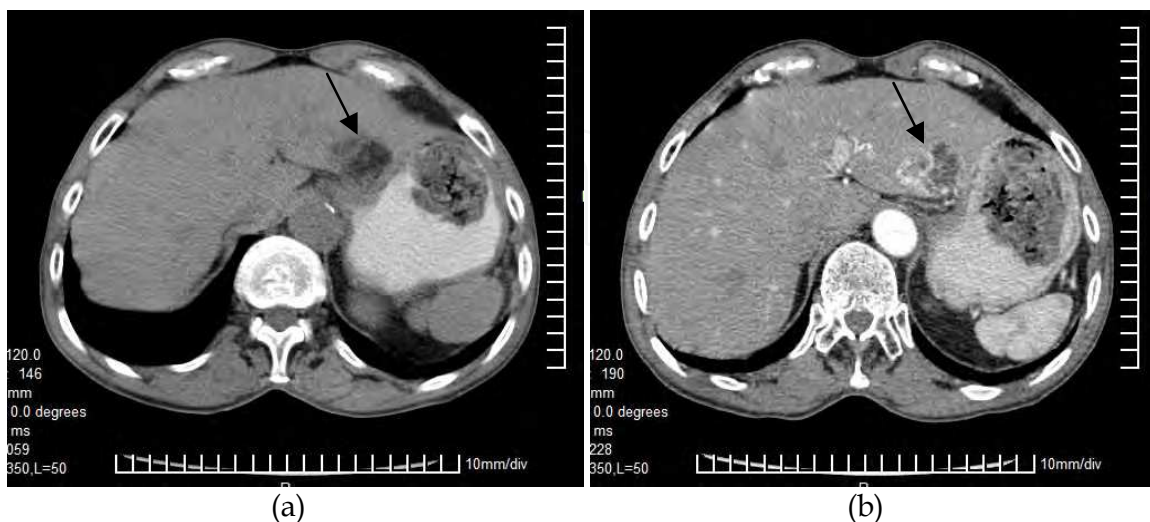


Fig. 8. Angiomyolipoma in S2 of the liver. (a) Nonenhanced CT scan shows a hypoattenuating fat-containing lesion in the left liver lobe. (arrow) (b) Arterial phase CT image shows slightly heterogeneous hyperenhancement in the vascular area of the lesion. (arrow)

On contrast enhanced CT images, hepatic angiomyolipomas strongly enhance in the arterial phase and enhancement persists in the venous phase, depending on the vascularisation of the tumour. Such hepatic angiomyolipomas should be differentiated from HCCs and cavernous hemangiomas (fig. 8).

2.4.2 Liver hamartoma

Liver hamartoma is a benign mesenchymal cystic tumour, consisting of gelatinous mesenchymal tissue with cyst formation and remnants of normal hepatic parenchyma. The tumour may have either mesenchymal predominance (a solid appearance) or cystic predominance (multiloculated cystic masses). On CT images mesenchymal hamartoma is a well defined lesion with hypodense central part and septa. Both solid and cystic areas are seen (fig.9).

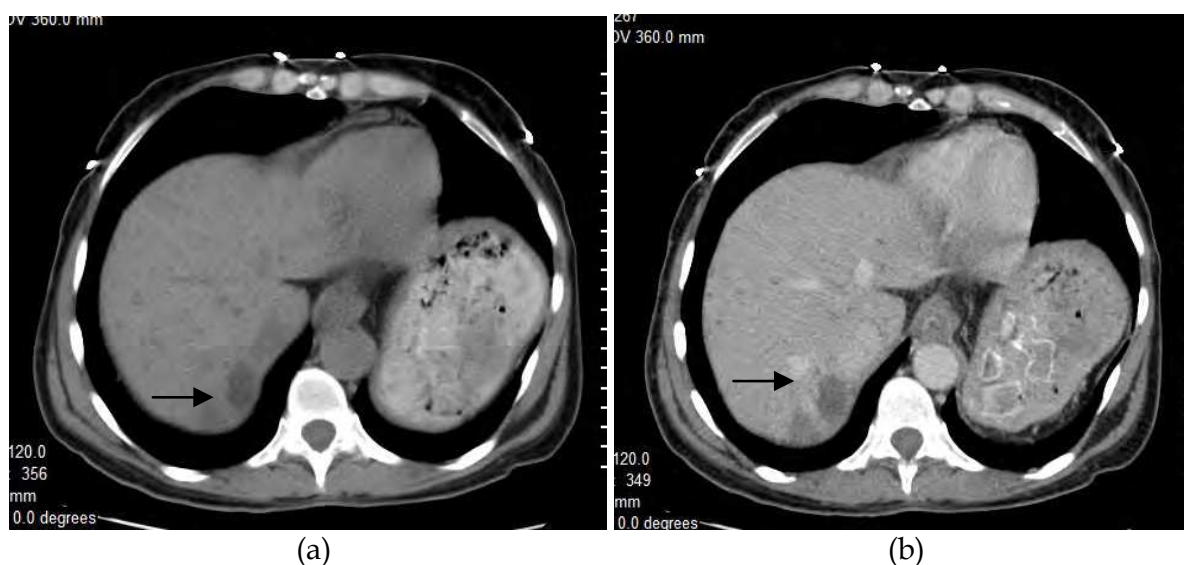


Fig. 9. Mesenchymal hamartoma of the liver. (a) unenhanced CT images: we see cystic lesions in S7 (b) enhancement of the septa in portal venous phase. (arrow)

2.4.3 Liver TB granuloma

Liver TB granuloma is the most common manifestation of upper abdominal parenchymatous organ tuberculosis and its incidence has also been increasing. There are three morphological types of liver TB: miliary tuberculosis of the liver associated with generalized miliary tuberculosis, primary miliary tuberculosis of the liver and primary tuberculoma or abscess of the liver. More than half of the patients present with hepatomegaly.

Radiological findings of hepatic tuberculosis are not specific. On CT images liver tuberculoma appears as an unenhancing, central, low density lesion due to cessation necrosis with a slightly enhancing peripheral rim corresponding to surrounding granulation tissue. Calcification can also be observed. TB granuloma should be differentiated from necrotic tumours, such as metastatic carcinoma and hepatocellular carcinoma (fig. 10).

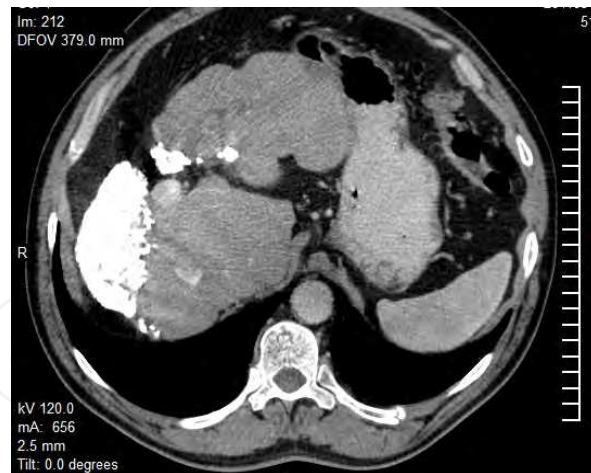


Fig. 10. Liver tuberculosis. Contrast enhanced CT image shows a large irregular miliary confluent calcification. The liver is decreased in size with irregular margins.

3. Most common malignant focal lesions

Malignant liver tumours are one of the most common oncological diseases all over the world.

It is still unknown why some of the liver cells become malignant; however it is well-known that people with differently damaged liver are at a greater risk of developing liver cancer. The highest risk of liver damage is for those infected with hepatitis B and C viruses. These and other diseases can cause liver cirrhosis, which induces scarring of liver tissue. When the tumour develops in cirrhotic liver, patient's survival and recovery rates are tragically low; and the only treatment option in this situation is liver transplantation.

Malignant liver tumours are more common in men than women (2.7:1) (based on USA data).

According to American Cancer Association (ACA) in 2007 liver tumours were diagnosed de novo in 13650 males and 5510 females.

ACA says liver tumours are among 20 most common oncological diseases in the USA. Though World Health Organization (WHO) states that liver cancer is the third most common mortality reason.

In Japan since 1995 the incidence of liver tumours has also been rising, and mortality from liver tumours is up to 30/100000. About 30000 Japanese people die from liver cancer annually .

In some African and Eastern Asian countries liver cancer is the most common type of malignancy.

According to Lithuanian Cancer Registration Department the rate of liver cancer was 132/100000 in 2001 and 162/100000 in 2005. Primary data on liver cancer in 2010 shows general morbidity of 142/100000: among them 94/100000 – males, 48/100000 – females.

In 2005 liver cancer caused 174/100000 deaths, 89/100000 of them – males and 85/100000 – females.

3.1 Hepatocellular carcinoma

Hepatocellular carcinoma (HCC) is the most common malignant liver lesion caused by hepatocytes damage. Very often HCC is diagnosed in patients who already have some underlying liver disease, such as chronic viral hepatitis, alcoholic cirrhosis, haemochromatosis, etc. With growing population of people with hepatitis C and the disease's tendency to become chronic or cause liver cirrhosis, there is no doubt hepatitis C will become the most important HCC risk factor.

HCC is more common in males than females (4:1) in their fifties-seventies. In some African and Asian countries HCC rate reaches its maximum at 40 yrs.

When the fibrosis is concentrated focally, a finding, often referred to as a focal confluent fibrosis, can create mass lesions that simulate tumours on cross sectional images. These lesions often radiate from the porta hepatis and are wedge-shaped and widest at the capsular surface. The most common sites for confluent fibrosis are the anterior and medial segments of the liver, but it can be present anywhere else. The reliable finding in differentiation of confluent fibrosis from HCC is associated atrophy of hepatic parenchyma with capsular retraction (fig.11).

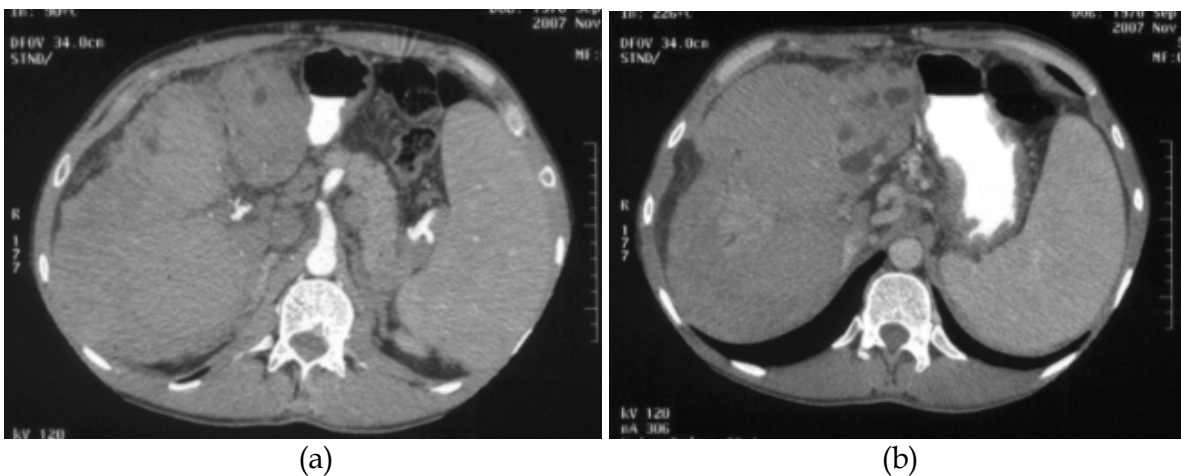


Fig. 11. Liver fibrosis. (a) Arterial phase CT image shows heterogeneous area in the right liver lobe, liver capsule retraction. (b) The portal venous phase CT image shows a hyperenhancement of the fibrotic area. Dilated bile ducts in the left liver lobe.

HCC can be solitary, multifocal or diffusely infiltrating, what is least common. Multifocal HCC may look like multiple small foci or one dominant large tumour with multiple satellite nodules. HCC classification can also be based on its growth characteristics. Highly differentiated tumour grows slowly, meanwhile tumour with low grade of differentiation demonstrate aggressive growth patterns.

HCC has a tendency to spread locally involving portal (30-60%) and other hepatic veins (15%). Portal vein is usually involved when the tumour is infiltrative. Intravenously growing tumour must be differentiated from thrombi, based on HCC arterial or venous signal depending on recanalization.

Serum AFP levels are often elevated in patients with large tumours, and the serum AFP level is frequently normal in patients with small tumours.

CT is highly accurate in the staging of HCC, as the number of lesions, segmental anatomy, regional adenopathy, vascular tumour invasion and metastases can be detected easily.

On unenhanced CT images HCC looks like a hypodense lesion. It often happens that small HCCs are not detected on precontrast CT. In HCC, however, there may be metamorphosis, necrosis, periodic changes or haemorrhage; therefore, it is usually heterogeneous attenuation, especially in large HCCs. Fatty metamorphosis usually occurs in high grade differentiated HCC and on unenhanced images it looks as a hypodense lesion. In some instances, increased attenuation within the HCC may be due to haemorrhage or calcifications.

Focal hyperdense fragments (calcification areas) or diffuse hyperdense changes (iron accumulations) inside the neoplasm are extremely rare (5-10%).

Optimal liver CT scanning protocol is based on accumulation of contrast substance in arterial, portal vein and venous phases during spiral CT.

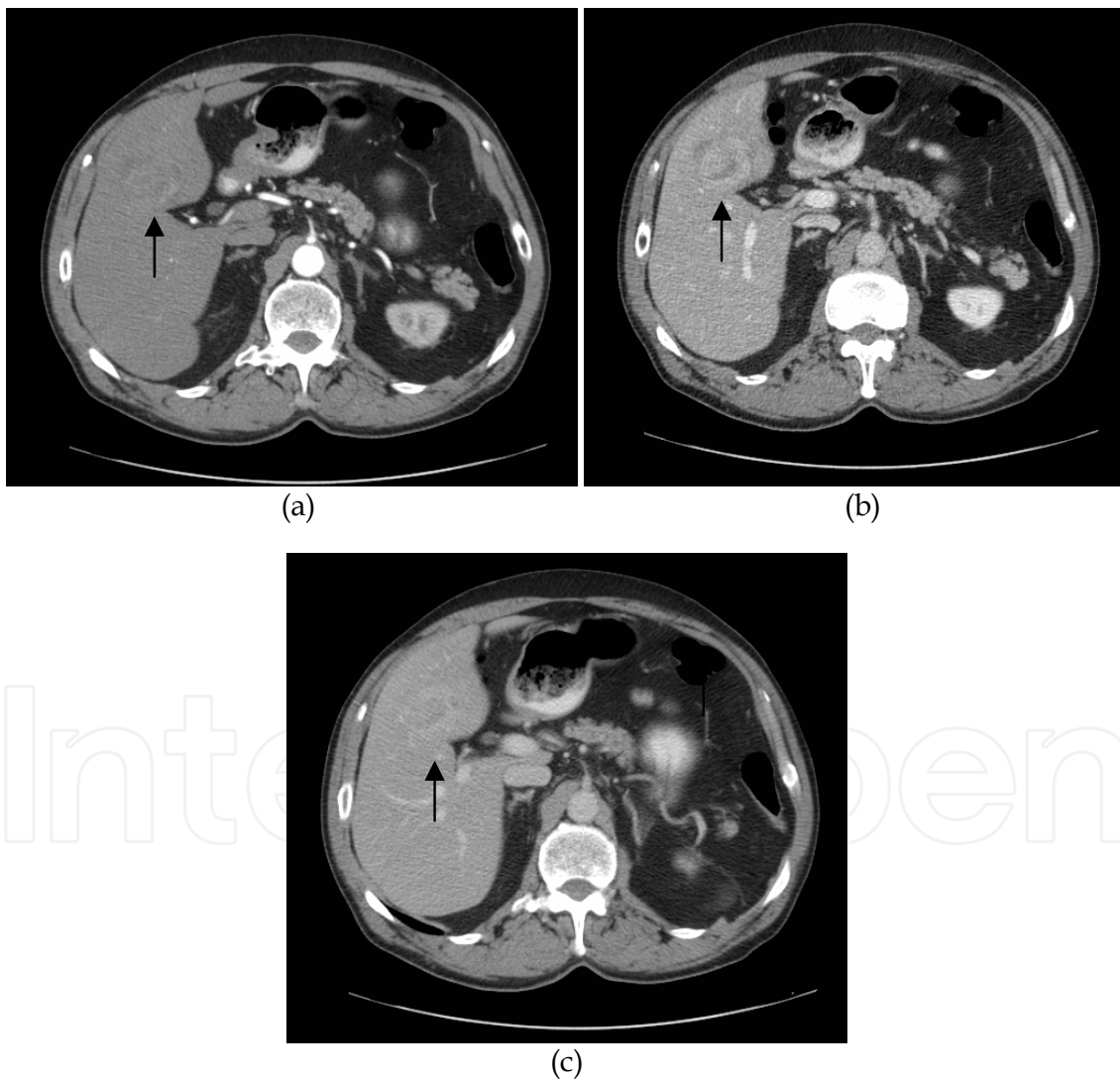


Fig. 12. Hepatocellular carcinoma. (a) Arterial phase CT image shows a typical hyperenhancement of the lesion. (arrow) (b,c) HCC shows washout in portal venous phase. Pathologic diagnosis of this tumor was moderately differentiated hepatocellular carcinoma. (arrow)

The most common HCC sign in arterial phase is enhancement or persistent enhancement and wash-out in portal venous and venous phases on CT or MRI (fig.12).

Intensive enhancement in HCC is caused by a good vascularization of the tumour. In early arterial phase, the lesions enhance homogeneously or heterogeneously, while most of the small HCC lesions enhance homogeneously. Areas of internal necrosis or fat may remain hypodense.

In the portal venous and equilibrium phases, the contrast media is moving from the intravascular to the intercellular space. The wash-out is rapid because HCC contains less intercellular space than the surrounding liver parenchyma.

The imaging characteristics of HCC vary greatly with the size of the lesion.

Diffusely infiltrating HCCs may be difficult to detect on CT during any enhancement phase (fig.13).

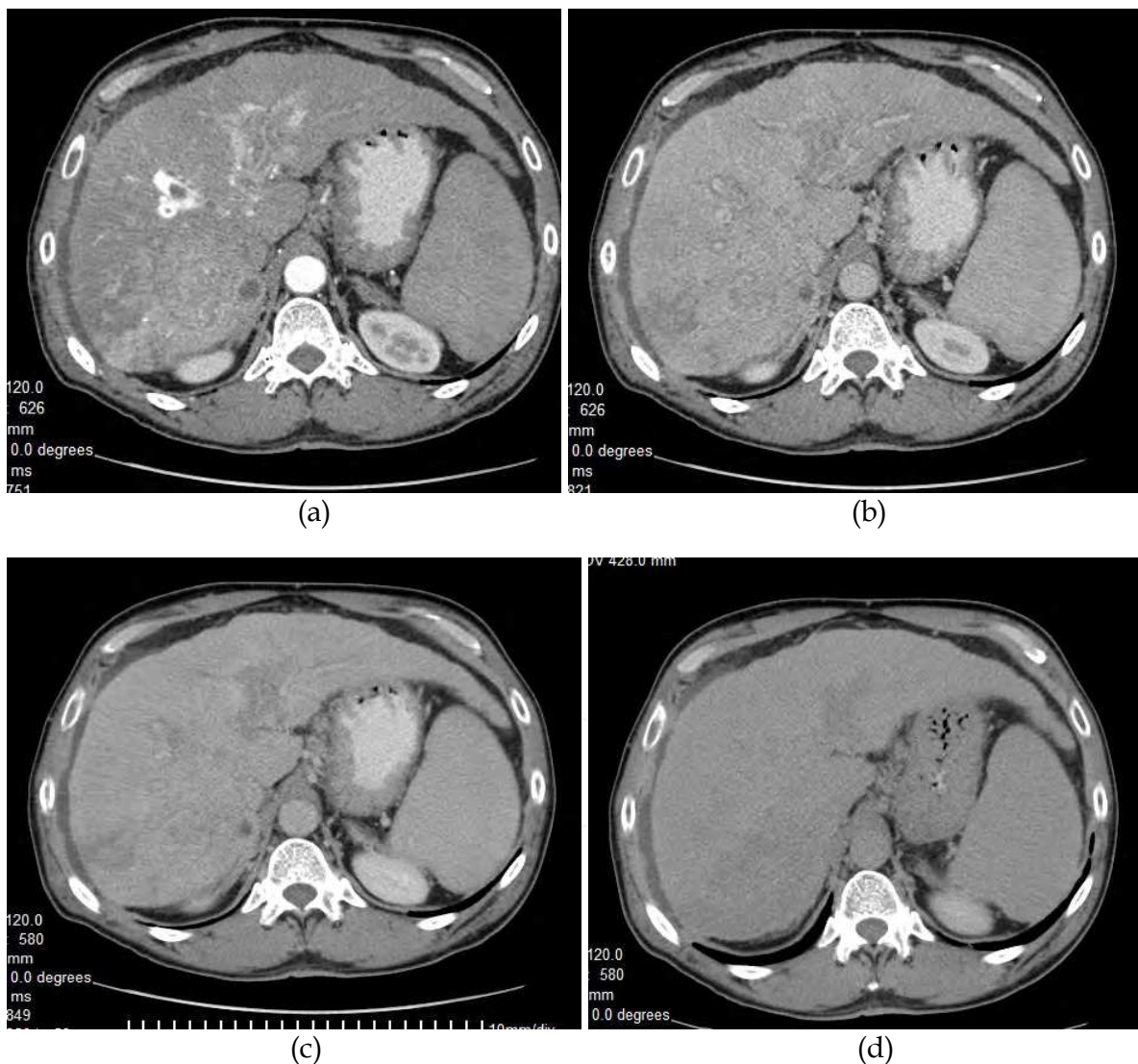


Fig. 13. Diffusely infiltrating hepatocellular carcinoma. (a) Hepatic arterial phase CT image shows slightly heterogeneous mass in the right lobe of the liver and hyperattenuating enhancement of the hepatic parenchyma. (b,c) In the portal venous phase and delayed phase CT images, the tumor shows washout.

Pathologic diagnosis of the tumor was diffusely infiltrating hepatocellular carcinoma.

Well-differentiated and small HCCs more often had atypical enhancement features.

Small HCC (<3 cm) can be hypovascular, do not enhance intensively or show no enhancement at all in arterial phase. In 10% of all cases enhancement is not intensive due to high differentiation degree of HCC. In this situation HCC is easier to identify in portal venous and venous phases, when hypodense HCC foci are seen due to contrast wash-out (fig. 14).

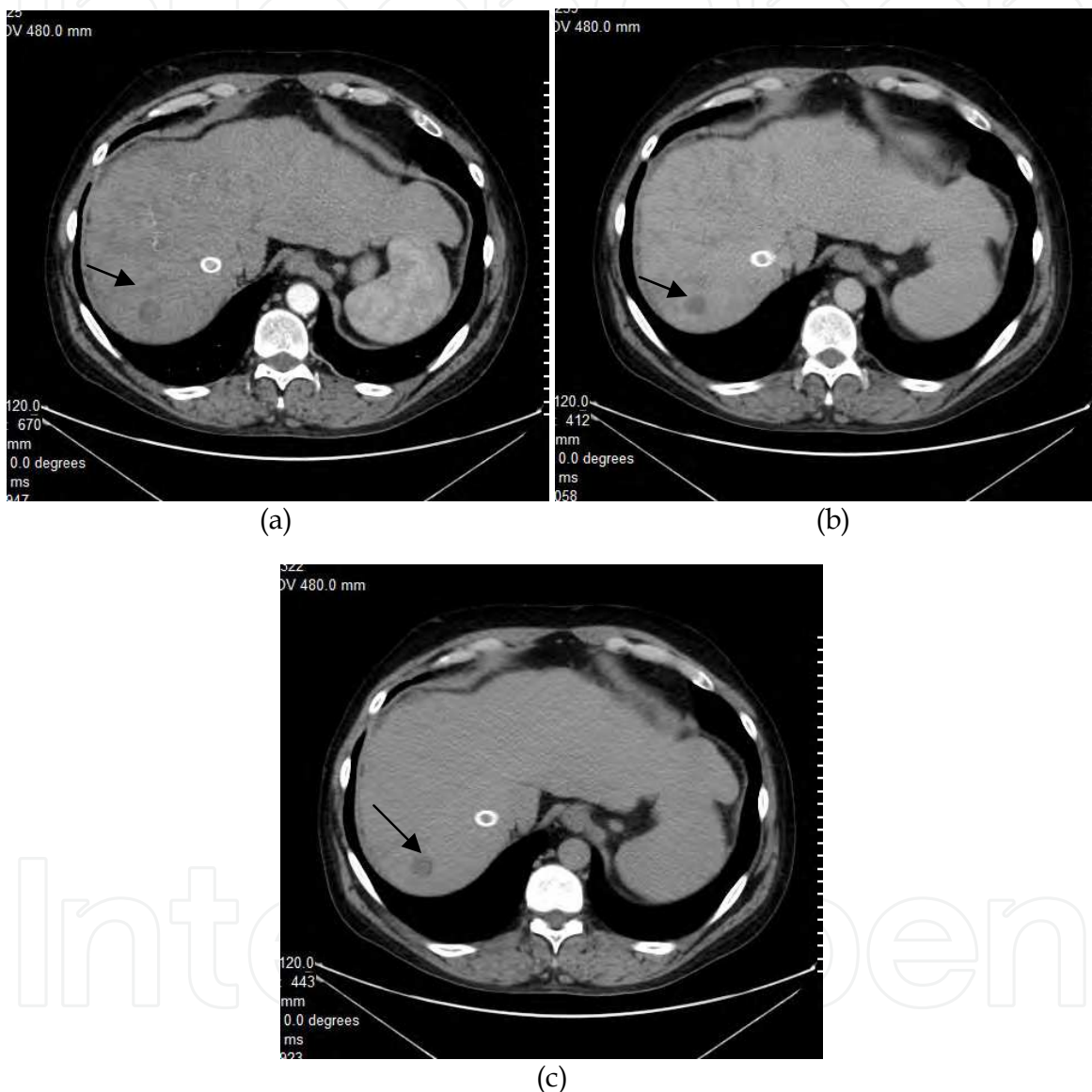


Fig. 14. Atypical hepatocellular carcinoma. (a,b) Arterial and portal venous phase show an atypical finding with no enhancement in the lesion. (arrow) (c) Delayed phase image shows no visible enhancement of the tumor. (arrow)

If HCC is big (> 5 cm), it is identified as a heterogeneous tumour in arterial phase. In these cases additional diagnostic criteria can be identified, it helps to diagnose HCC: in 40-60% of HCC cases a picture of mosaic tumour is seen; lesions of portal or hepatic veins, characterized by defects of vascular lumen filling, are seen in 33-48% of all cases; central scar

consisting of collagen, fibrotic and sclerotic tissue and internal fatty components are seen in 2-21% of all cases (fig. 15).

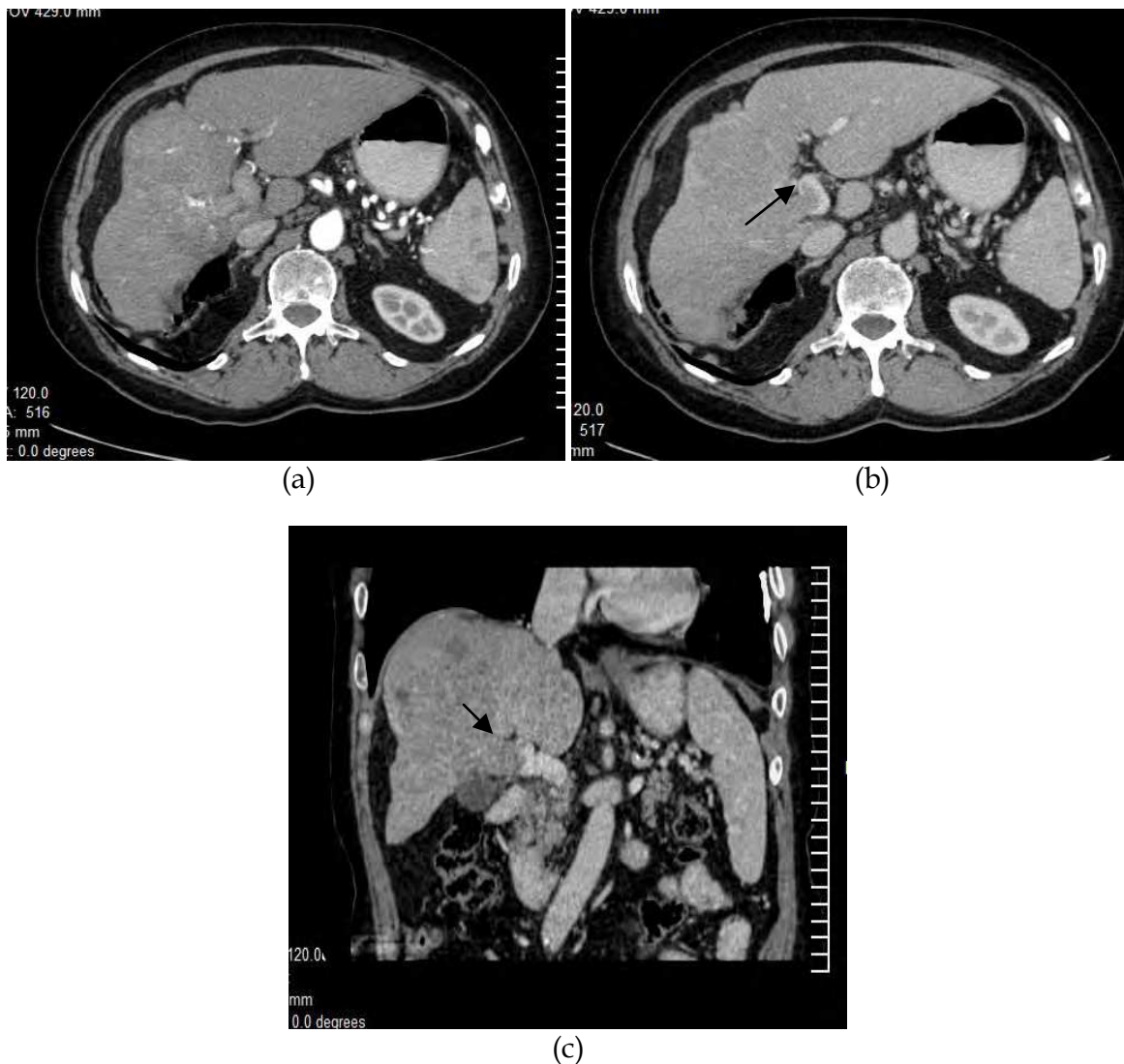


Fig. 15. Hepatocellular carcinoma with portal vein invasion. (a, b) Contrast-enhanced CT image shows the typical enhancement pattern of hepatocellular carcinoma. Invasion of the right portal vein is confirmed. (arrow) (c) On the coronal CT reconstruction, the portal vein is filled with hypodense tumor thrombus, which demonstrates a small amount of enhancement. (arrow)

The capsule, limiting all of the tumour or a part of it, is identified in 30-67% of HCC cases. The capsule is seen as hypodense rim in arterial phase, it enhances in late venous phase. Capsule is more common for the tumours with lower differentiation than those highly differentiated; it is also more common for medium sized (3-10 cm) tumours. Peripheral enhancement in solitary hepatocellular carcinoma (>3.0 cm in diameter) is also uncommon in images obtained by helical CT. Firstly, encapsulated carcinoma pseudocapsule usually shows an enhanced rim, arterioportal shunting around the lesion usually shows very dense, wedge shaped or triangular, peripheral enhancement in hepatic arterial phase and less enhancement in portal venous phase. This sort of enhancement should be differentiated

from other focal liver lesions, such as hepatic metastases, hepatic abscess, hepatic inflammatory pseudotumour and hepatic cavernous hemangioma (fig.16).

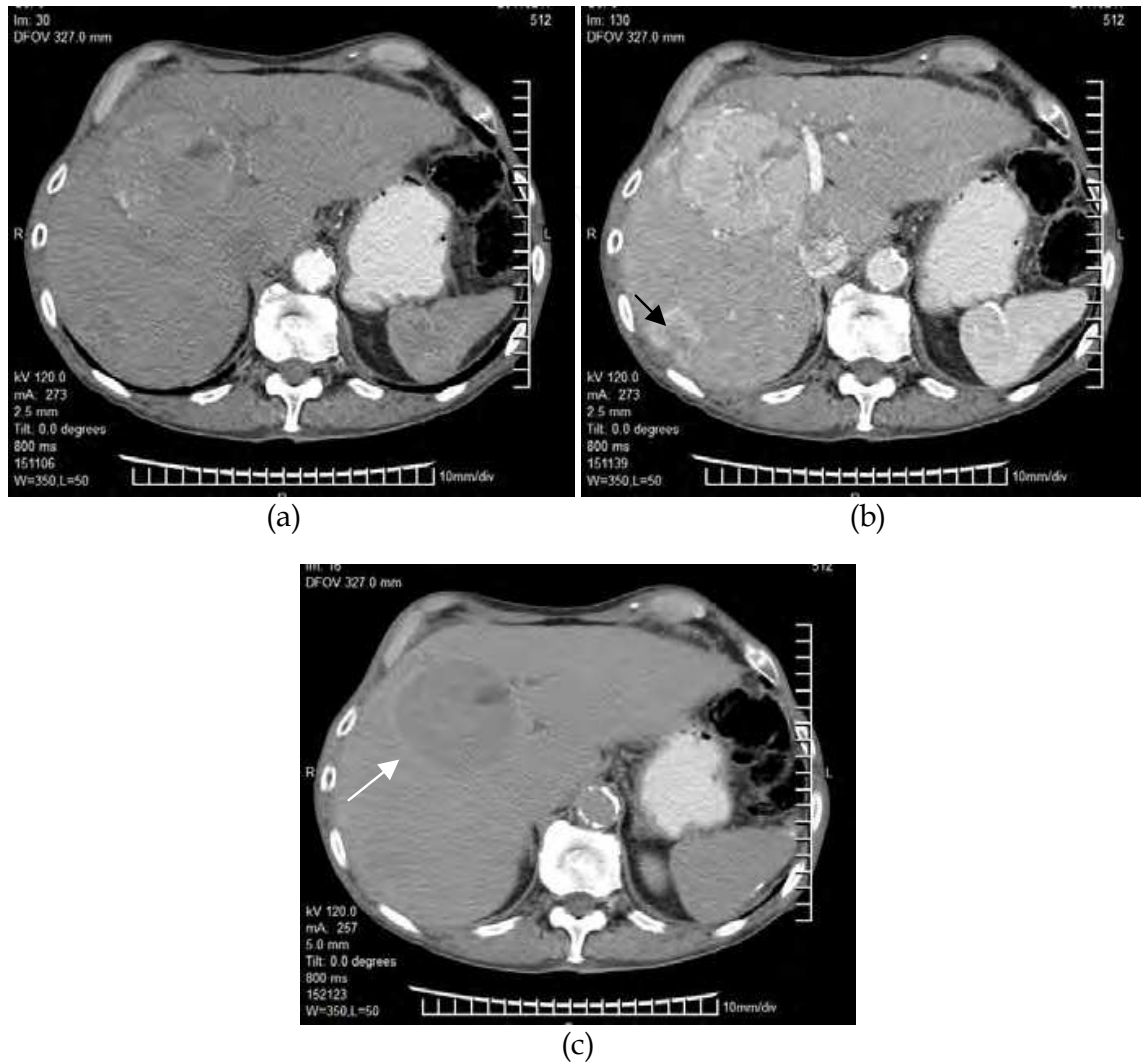


Fig. 16. Hepatocellular carcinoma with satellite nodule. The large tumor is defined on the right liver lobe and small satellite nodule in S7, with capsule retraction. (arrow) (a,b) Contrast enhanced CT images show the typical enhancement pattern of hepatocellular carcinoma. (c) Delayed phase image shows washout of contrast media. A hyperdense rim (white arrow) is present at the periphery of the tumor.

Quick contrast wash out from HCC increases the specificity of CT and allows distinguishing HCC from hemangiomas, hypervascular dysplastic nodules, small arterial portal shunts, which mimics HCC because of contrast uptake in arterial phase. Small hemangiomas can appear with flash filling during the arterial phase and thus simulate HCC. These lesions always show enhancement on delayed-phase images, whereas HCC exhibits a washout of the contrast material, becoming either isoattenuating or hypoattenuating relative to liver tissue.

CT has some lack of specificity in distinguishing HCC from tumours such as metastases, focal nodular hyperplasia, and hepatic adenomas. In general the clinical and radiographic setting indicates which of these is likely in a given patient, as these tumours are rare in cirrhotic liver and HCC is uncommon in the healthy liver.

The essential HCC diagnostic criteria on CT images are as follows: hypodense area on unenhanced CT images; homogenous or heterogeneous enhancement in arterial phase; rapid wash-out in venous phase. Based on these criteria CT is 84% sensitive and 93% specific.

3.2 Intrahepatic cholangiocarcinoma

Intrahepatic cholangiocarcinoma (I-CCC) is a malignant tumour of bile ducts' epithelium, which affects minor branches of intrahepatic bile ducts.

Usually I-CCC is a disease of young people that can be caused by primary sclerosing cholangitis, secondary cholangitis, congenital liver cirrhosis, Caroli disease etc. There is no

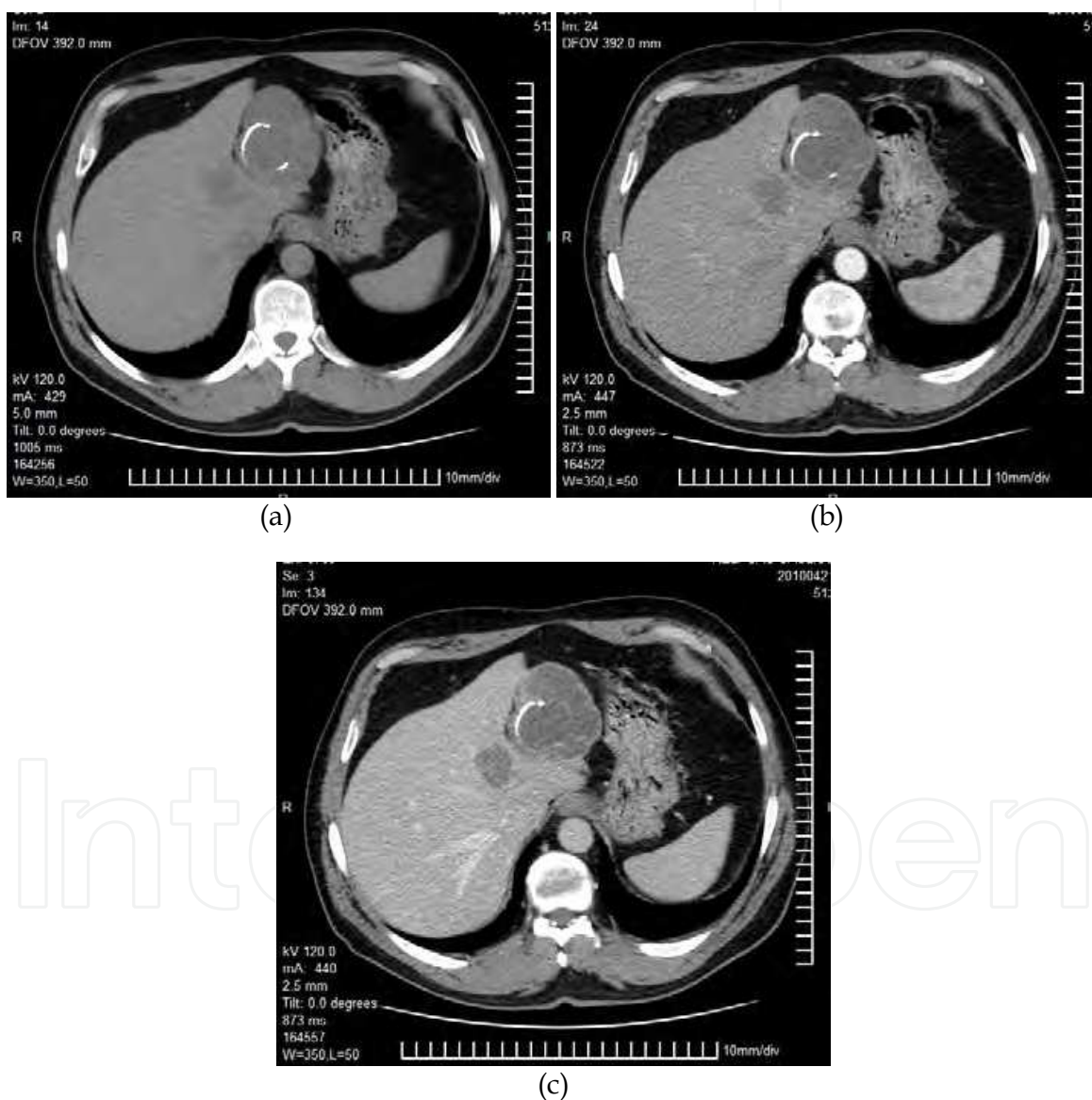


Fig. 17. Intrahepatic cholangiocarcinoma. (a) Unenhanced CT image shows well defined hypodense lesion with calcification. Sattelite nodule is also seen. Atrophy of the left liver lobe. (b) Arterial phase CT image shows poorly enhancement of the lesion; tiny septations show enhancement. (c) Portal venous phase shows increased and persistent enhancement of the lesion.

strong evidence that intrahepatic stones can or cannot cause I-CCC, however this disease can be caused by recurrent cholangitis that leads to mucosal hyperplasia, adenomatous changes or carcinoma. I-CCC represents about 15% of all primary liver tumours. By growth types cholangiocarcinoma is classified into mass-forming, periductal infiltrating and intraductal.

On unenhanced CT images I-CCC is seen as solitary not encapsulated hypodense lesion with irregular margins. Hyperdense areas inside the lesion look like calcification (fig.17).

In both arterial and portal venous phases the most important sign is the enhancement of the capsule limiting jagged edges of the tumour. The tumour itself enhances very slowly. This is why CT imaging in arterial and venous phases shows no difference. Tumour tissue enhances only in delayed phase. Deformation of tumour capsule can be seen in 20% of all cases, dilatation of intrahepatic bile ducts is seen in 20-60% of cases (fig.18).

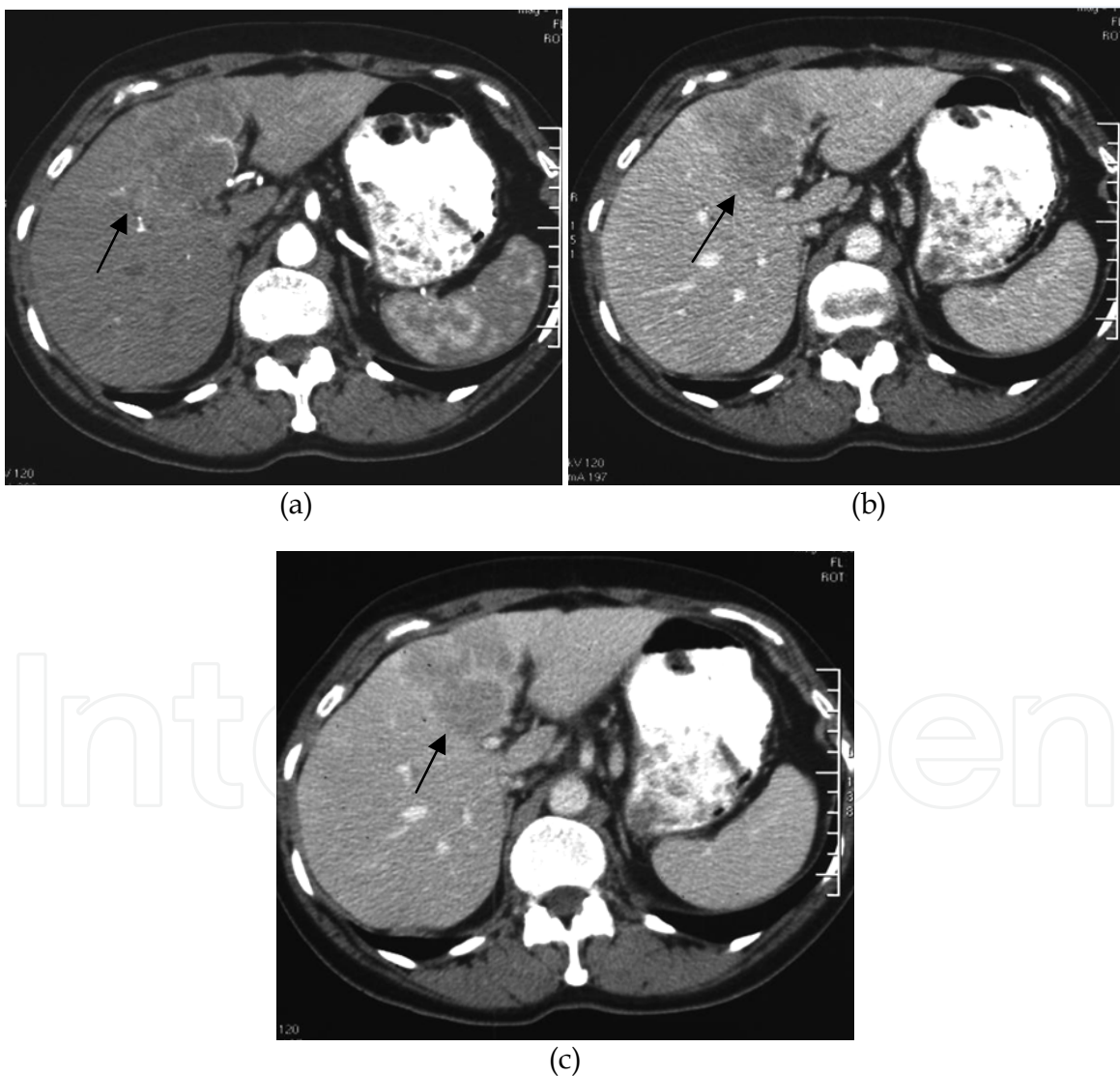


Fig. 18. Mass forming intrahepatic cholangiocarcinoma. (a) the lesion enhances heterogeneously in arterial phase;(b,c) persistent enhancement is seen in portal venous phase. (arrow)

Mass-forming cholangiocarcinoma is characterized by a homogeneous sclerotic mass with an irregular lobulated margin, typically in the absence of haemorrhage or central necrosis. Uptake of c/m in the late phase is closely related to the amount of interstitial space in the fibrous stroma. Peripheral masses are sometimes associated with capsular retraction. About 80% of all lesions enhance in the late phase.

Diffuse periductal thickening and increased enhancement due to tumour infiltration, with an abnormally dilated or irregularly narrowed duct and peripheral ductal dilatation is typical for periductal infiltrative type. This is one of the least common types of cholangiocarcinoma. Most of hilar cholangiocarcinomas are of this type. Periductal cholangiocarcinoma tends to be localized to one segment or lobe and manifests with ductal dilatation, a finding that is indicative of biliary disease. This is a very important sign differentiating this type of cholangiocarcinoma from periportal lymphangitic metastasis or from the extrahepatic tumour. Metastases are usually localised in a few liver lobes and do not cause ductal dilatation (fig.19).

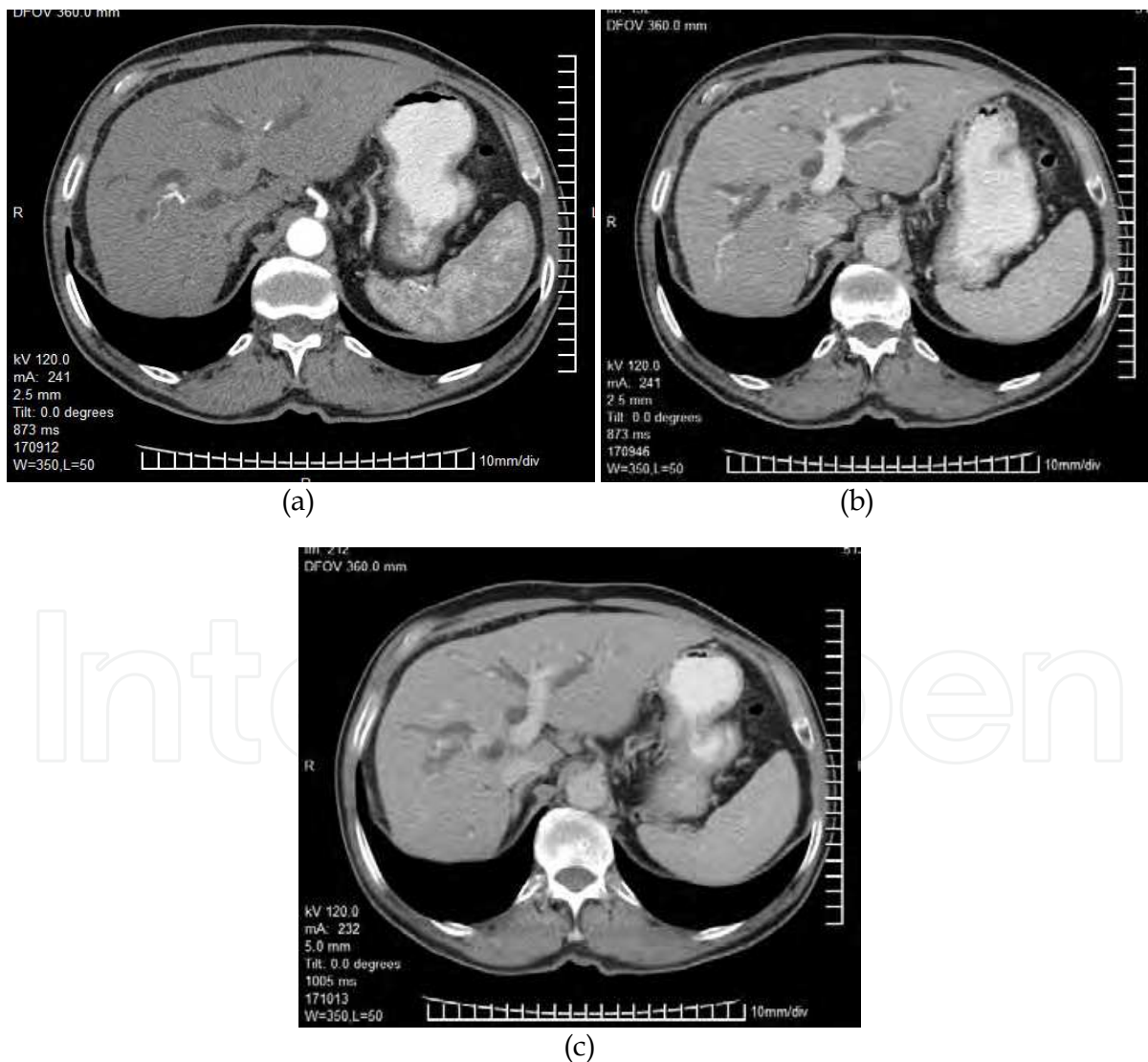


Fig. 19. Intraductal infiltrating cholangiocarcinoma. CT scan images show diffuse ductal dilatation in the both hepatic lobes with no visible intraductal mass.

On precontrast CT images intraductal cholangiocarcinomas appear as a lesion within the dilated bile duct that is hypo- and isodense compared to surrounding liver tissue. After administration of contrast media, the intraductal tumour shows enhancement. This type of tumour can be distinguished from HCC invading the bile duct on the basis of identification of the mass outside the ductal system, hypervascularity at dynamic imaging, the presence of a prominent fibrous capsule or pseudocapsule, and other imaging features favouring HCC. This type of intraductal tumour may also be confused with an intraductal mass-like stone. The absence of enhancement and the high attenuation on unenhanced CT images are useful in making the diagnosis of an intraductal mass-like stone, whereas an enhancing polypoid mass with asymmetric adjacent bile duct wall thickening is suggestive of an intraductal tumour (fig.20).

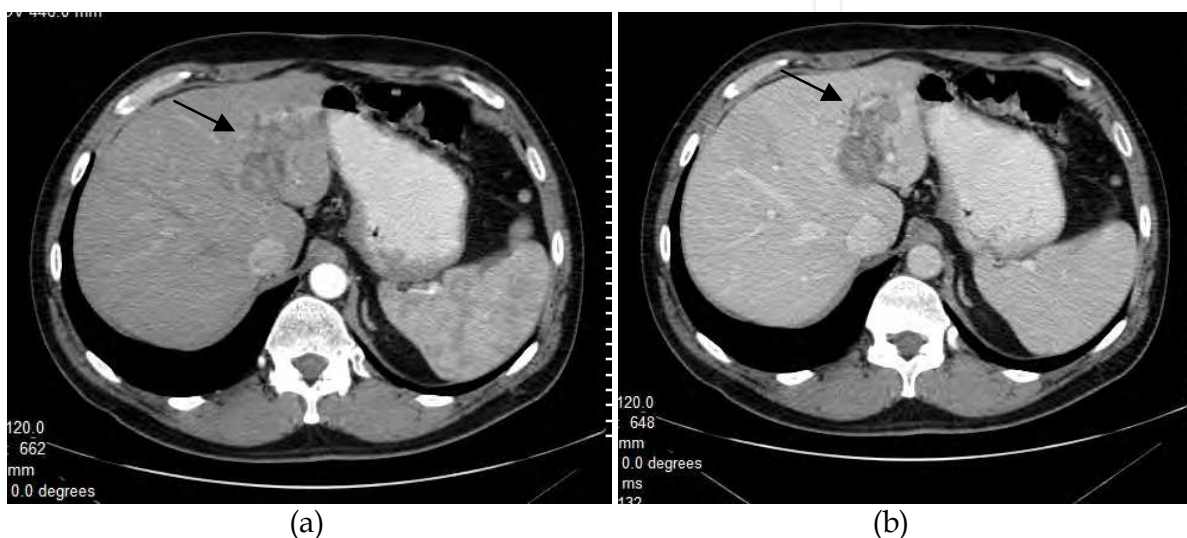


Fig. 20. Intrahepatic stone disease. (a,b) Arterial and portal venous phase CT images show dilated intrahepatic bile ducts in the left liver lobe with hepatolithiasis (arrow).

The diagnostic criteria of I-CCC on CT images are as follows: hypodense or isodense lesion on unenhanced CT images; slight peripheral enhancement in arterial phase; that emerges in venous phase. Based on these criteria CT imaging is 78% sensitive and 89% specific.

3.3 Metastases

Liver is the second most common (after lymph nodes) organ, where different malignant tumours metastasize. 80% patients with extrahepatic tumour are expected to have liver metastases. Multiple hepatic metastases are way more common (>90%) than solitary ones (<10%). Both liver lobes are more likely to be affected (77%) than the right one (20%) or the left one (31%) alone. Lesions may be infiltrative, expansive or miliary. Liver metastases may be hypovascular or hypervascular (fig. 21).

Few lesions may look completely different in one patient due to variations in cellular differentiation, fibrosis, necrosis, haemorrhage, and blood supply. This is typical for metastases from renal cell carcinoma, carcinoid, choriocarcinoma and some types of lung cancer. Majority of authors differentiate hypervascular liver metastases from FNH and HCC. Primary tumours that are the most likely to metastasise to the liver are ophthalmic and pancreatic (70-75%), breast, gall-bladder and extrahepatic bile ducts, colon and rectal (about 60%), and stomach (about 50%).

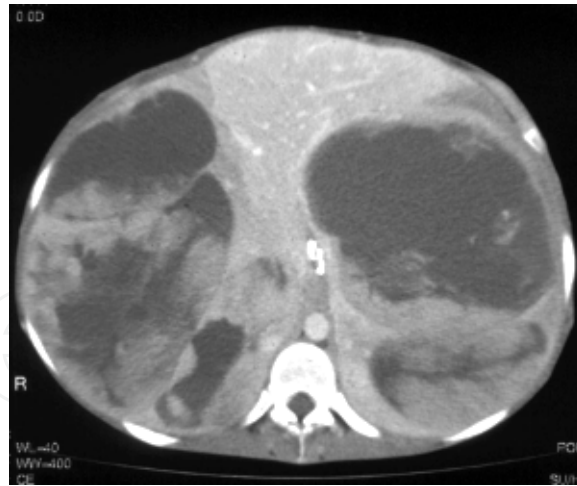

Fig. 21. Hepatic metastases from GIST. Multiple large masses show heterogeneous enhancement, intralesional irregular necrotic areas are seen.

On contrast enhanced CT images characteristic of enhancement of liver metastases is determined by the primary tumor. Most liver metastases are hypovascular. This is why they look hypodense on CT images, especially in portal venous phase compared to normal liver parenchyma. Central hypodense area caused by tissue necrosis may be seen on CT images (fig.22).

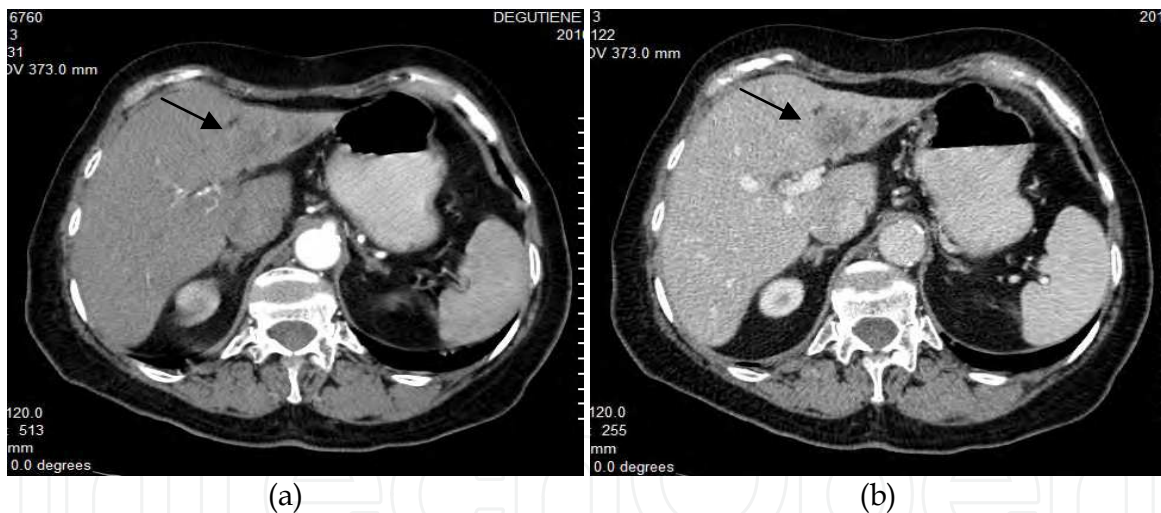


Fig. 22. Hepatic metastasis from colon carcinoma. (a) Arterial phase CT image shows a hypodense lesion with biliary duct dilatation in the left liver lobe (arrow). (b) Portal venous phase image: the lesion is hypodense to the surrounding liver parenchyma (arrow).

Peripheral hyperdense border rim can be visualized due to peripheral afferent blood vessels or hyperemia of liver tissue. The borders of metastases may be sharply defined, ill-defined, or nodular, and their shape may be ovoid, round, or irregular.

Hipervascular metastases (RCC, pancreatic carcinoma, sarcoma or melanoma) enhance more or less homogeneously intensively in arterial phase. Normally arterial phase is crucial in evaluation of metastases as hyperenhancement is caused by hepatic artery supplying blood to the tumor (fig. 23).

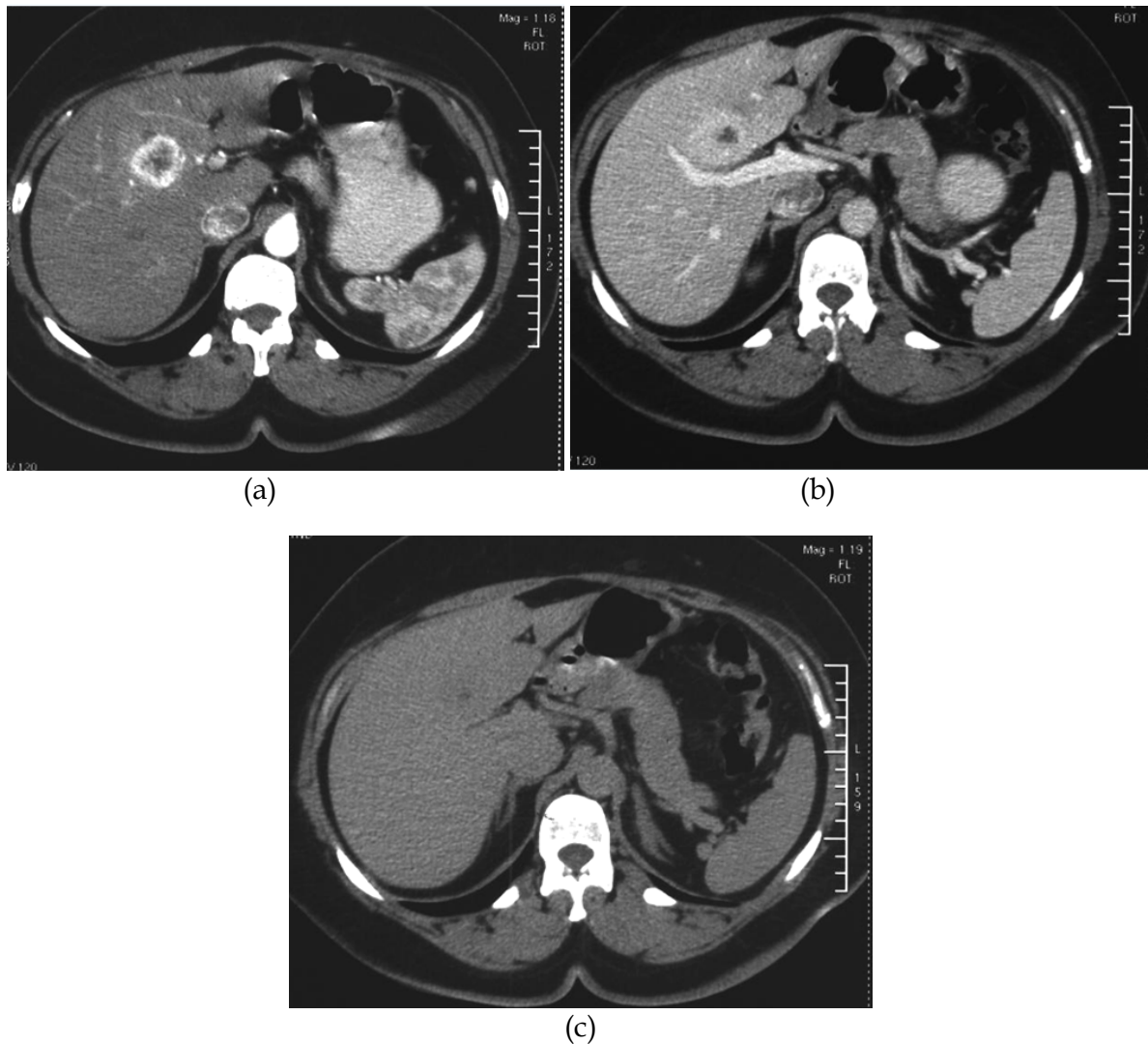


Fig. 23. Hepatic metastasis from renal cell carcinoma. a) Arterial phase CT image shows peripheral contrast enhancement, with hypodense centre of the lesion. (b) Portal venous phase CT image shows a slightly hyperenhancement of the lesion. (c) Delayed phase image - metastatic lesion is hypodense. Central part of the lesion shows necrosis.

However, sometimes metastases can enhance atypically.

In Van Leeuwen study, 11% of colorectal metastases enhanced heterogeneously, and about 60% of metastases from hypervascular tumours did not enhance at all. Metastases may develop calcification that is detectable by CT in the presence of mucin, necrosis, and phosphatase activity (fig.24).

This is typical for metastases from mucin adenocarcinoma, such as colon, pancreatic, and stomach cancer. Sometimes in case of mucin producing tumour cystic metastases may be found in the liver. On CT images they look like foci with peripheral ring enhancement. In all unclear cases differentiation from common liver cysts is required (fig. 25).

It is very important to differentiate peripheral enhancement in FLL, especially metastases, from nodular peripheral enhancement in first few seconds of arterial phase that gradually

becomes more intensive in portal venous, venous and delayed phases. This character of enhancement is typical for liver hemangiomas. It is a reliable sign of non-malignant lesion.

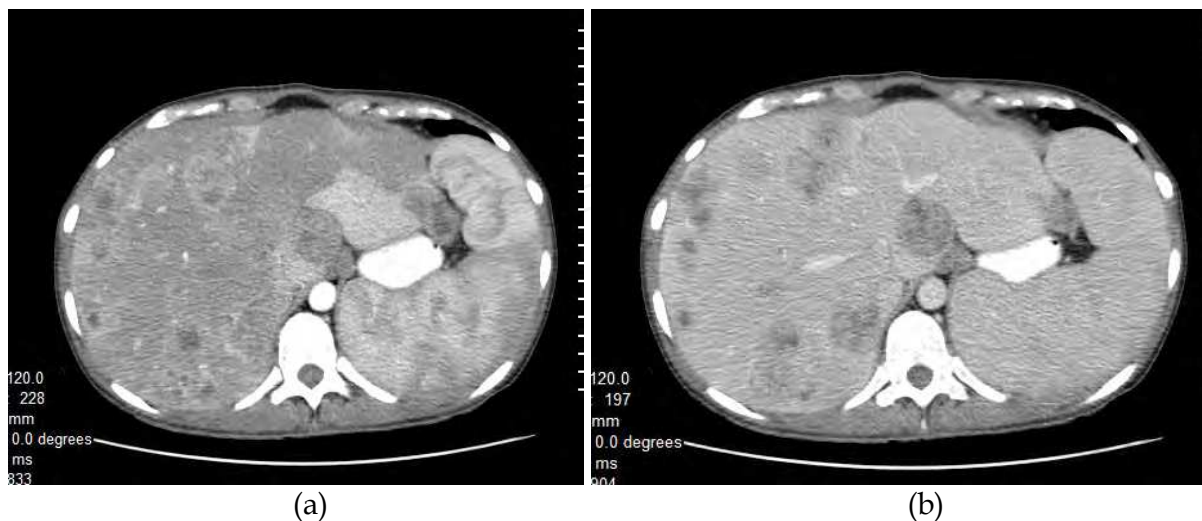


Fig. 24. Metastatic melanoma. (a) Contrast-enhanced CT image during hepatic arterial phase shows a multiple hyperattenuating hepatic metastases. (b) On portal venous phase we see washout of contrast media.

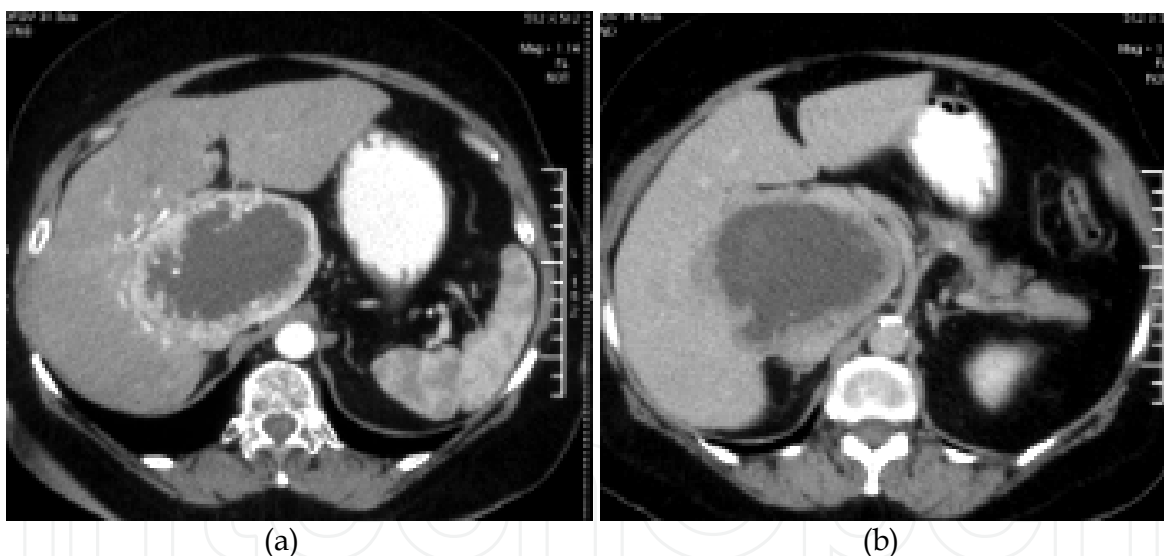


Fig. 25. Hepatic metastasis of neuroendocrine tumor. (a) On arterial CT phase, a large hypervascular tumor is seen as hyperattenuating mass with central necrosis. (b) In the portal venous phase tumor becomes isodense to surrounding liver parenchyma; necrosis remains hypodense.

Arterial-venous shunts, liver perfusion abnormalities and focal or diffuse fatty degeneration can also mimic metastases, so radiological differential diagnostic with these lesions is necessary.

In differential diagnostics of HCC and metastases it is very important to identify the following CT diagnostic criteria of hypervascular areas: hypodense lesion on unenhanced

CT images; intensive enhancement in arterial phase and rapid wash-out (hypodense lesion) in venous phase. Based on these criteria CT scanning is 85% sensitive and 86 % specific.

3.4 Rare malignant tumours

Even though these tumours are relatively rare FLL, they also should be differentiated radiologically. These are fibrolamellar carcinoma (FLC), epithelioid haemangioendothelioma (EHE), primary liver lymphoma and biliary cystadenocarcinoma.

3.4.1 Fibrolamellar carcinoma

Fibrolamellar carcinoma (FLC) presents only 2% of all liver tumours and is mostly diagnosed in young women without chronic liver disease. According to available sources, FLC should be differentiated from benign FNL, such as FNH, large haemangioma, and sometimes - HCA. It is challenging to differentiate FLC from HCC when the lesion enhances heterogeneously. This is why the late phase is so important: it visualises hypodense homogenous FLC.

Fibrolamellar carcinoma is another hypervascular tumour occurring in young adults and it usually contains a fibrotic scar. However it is not difficult to differentiate it from FNH. FLC is usually a large (>10-cm), heterogeneous, lobulated mass with broad central or eccentric scars and radiating septa. Calcifications are found in 68% of FLC, and obvious signs of malignancy such as lymphadenopathy (65%), metastases, and biliary and vascular invasion are found in the majority of cases. Calcification is typical of FLC, with a reported incidence of 35–68%. Calcifications may be punctate, nodular, or stellate and are usually small (<5 mm), few (one to three in number), and almost always located near the centre of the tumour. FLC demonstrates a central scar in up to 20–71% of cases. It is typically large and may be broad or stellate, eccentric or central. Invasion of the hepatic vessels or bile ducts was also found to be an important differentiating feature, but it may be seen in less than 5% of cases of FLC.

3.4.2 Epithelioid haemangioendothelioma

Epithelioid hemangioendothelioma (EHE) is a rare and highly malignant tumour with vascular component that develops from epithelioid endothelium cells. On unenhanced CT images epithelioid hemangioendothelioma is hypodense compared to normal hepatic parenchyma. EHE usually localises in lateral liver parts and is formed of fibrotic hypovascular central nucleus and peripheral hypervascular rim that is still seen in the late phase. Capsular retraction is frequently present, and calcification is occasionally seen.

3.4.3 Lymphoma

Primary hepatic lymphoma is an exceptionally rare disease, representing less than 1.0 % of all extranodal lymphomas. Lymphoma of the liver is considered primary in the absence of extra-hepatic involvement or in cases of predominant hepatic presentation. Hepatic lymphoma is more commonly encountered in patients with cirrhosis, mostly secondary to hepatitis C, AIDS, systemic lupus erythematosus and in transplant recipients being treated with immunosuppressive drugs. The prognosis appears to be favourable in patients diagnosed and treated early, unless there is an underlying disease. In 57% of all cases primary liver lymphoma is solitary tumour. On CT images it is seen as hypodense

homogenous lesion of variable size and enhancement. Secondary lymphoma tends to present as multiple lesions in most cases, but can also show a single lesion or diffusely infiltrate the liver. CT features of hepatic lymphoma are non-specific and do not allow differentiation from other solitary or multicentric hepatic tumours (fig.26).

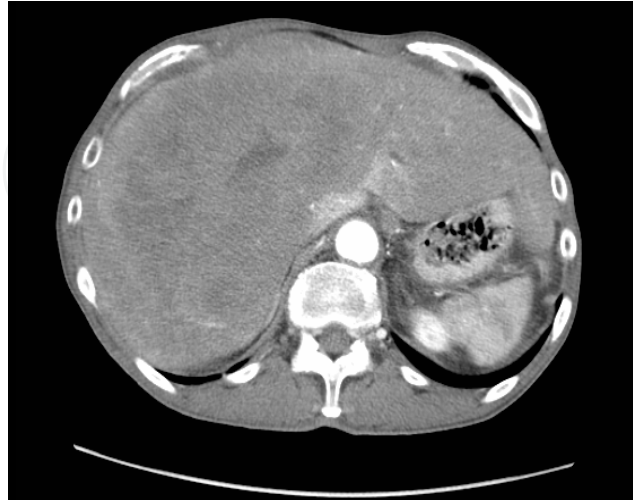


Fig. 26. B cell lymphoma. Arterial phase CT image shows a large heterogeneous tumor in the right lobe with hypodense central necrosis.

3.4.4 Biliary cystadenocarcinoma

Biliary cystadenocarcinoma is a malignant tumour, developed from biliary cystadenoma (fig. 27).

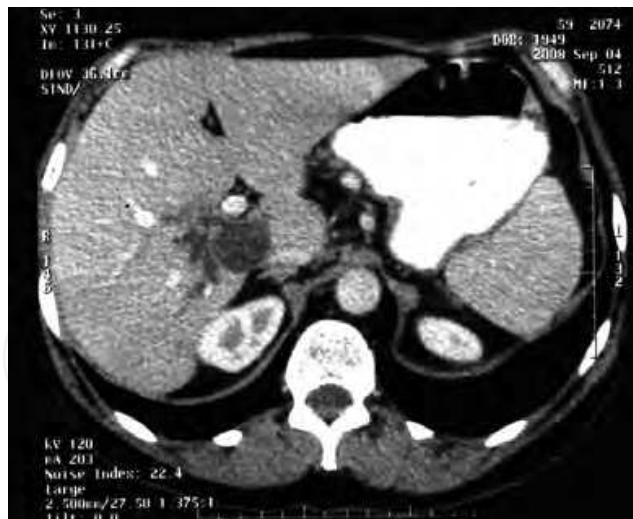

Fig. 27. Biliary cystadenoma in S1 with biliary ductal dilatation. Contrast-enhanced CT image shows a hypodense lesion in the liver without contrast enhancement. A partial septation of the lesion is present.

It is a large cystic tumour that is usually septated, but may be unilocular. The cystic spaces contain mucinous or serous fluid. On CT images both cystadenoma or cystadenocarcinoma are well defined cystic lesions that do not enhance. We can see an enhancement of the wall and septa of the tumour. Calcifications and soft tissue components are possible.

4. Conclusion

Contrast enhanced CT is a powerful imaging technique for the accurate diagnostics of HCC. Arterial and portal venous phases are important in evaluation of FLL. Delayed phase is essential in differential diagnosis of benign and malignant lesions. These imaging techniques should be optimized for the evaluation of suspected HCC. Typical CT features may help in differentiating HCC from other liver lesions.

Contrast enhanced CT is important technique for the accurate diagnosis of HCC. Optimal scanning protocol is essential. Delayed phase should be always included in scanning protocol.

5. Acknowledgment

I am particularly indebted to all the radiologist of our department of Radiology in Lithuanian University of Health Sciences Kaunas Clinics for their help in gathering CT images of interesting and extremely rare cases.

6. References

- Albrecht T., Hohmann J., Oldenburg A., Skrok J., & Wolf KJ. (2004). Detection and characterisation of liver metastases. *European Radiology*, Vol.14,suppl 8, pp. 25-33, ISSN 0938-7994.
- Albrecht T., Thorelius L., Solbiati L., Cova L., & Frauscher F. (2005). Contrast-enhanced ultrasound in clinical practice. Springer-Verlag Italia, Milan, ISBN 88-470-0304.
- Anderson SW., Kruskal JB., & Kane RA. (2009). Benign hepatic tumors and iatrogenic pseudotumors. *Radiographic*, Vol. 29, pp. 211-229, ISSN 0271-5333.
- Appelbaum L., Lederman R., Agid R., & Libson E. (2005). Hepatic lymphoma: an imaging approach with emphasis on image-guided Needle biopsy. *IMAJ*, Vol. 7, pp. 19-22, ISSN 1565-1088.
- Arab M., Mansoori D., Abbasidezfouli A., Shadmehr M. & Afsari M. (2002). Splenic tuberculosis: a case report. *Acta Medica Iranica*, Vol. 40, No.1, pp. 26-28, ISSN 1560-8239.
- B. E. Van Beers. (2008). Diagnosis of cholangiocarcinoma. Review article. *HPB*, Vol. 10, pp. 87-93, ISSN 1365-182X print/ISSN 1477-2574 (online).
- Banshodani M., Ishiyama K., Amano H., Tashiro H., Arihiro K., Itamoto T., & Ohdan H. (2009). Hepatic angiomyolipoma with minimal intratumoral fat content. Case reports in *Gastroenterology*, Vol. 3, pp. 324-331, ISSN 1662-0631.
- Basaran C., Karcaaltincaba M., Akata D., Karabulut N., Akinci D., Ozmen M., & Akhan O. (2005). Fat-containing lesions of the liver: cross-sectional imaging findings with emphasis on MRI. *AJR*, Vol.184, pp.1103-1110, ISSN 1844-1103.
- Blachar AB., Federle MP., Ferris JV., Lacomis JM., Waltz JS., Armfield DR., Chu G., Almusa O., Grazioli L., Balzano E., & Li W. (2002). Radiologists' performance in the diagnosis of liver tumors with central scars by using specific CT criteria. *Radiology*, Vol. 223, pp. 532-539, ISSN.0033-8419.
- Brancatelli G., Federle MP., Blachar A., & Grazioli L. (2001). Hemangioma in the cirrhotic liver: diagnosis and natural history. *Radiology*, Vol. 219, pp. 69-74, ISSN. 0033-8419.


- Brancatelli G., Federle MP., Grazioli L., Blachar A., Peterson MS., & Thaete L. (2001 b). Focal nodular hyperplasia: CT findings with emphasis on multiphasic helical CT in 78 patients. *Radiology*, Vol. 219, pp. 61-68, ISSN 0033-8419.
- Carlson SK., Johnson C.D., Bender C.E., & Welch TJ. (2000). CT of focal nodular hyperplasia of the liver. Pictorial essay. *AJR*, Vol. 174, pp. 705-712, ISSN 1743-705.
- Caturelli E., Pompili M., Bartolucci F., Siena DA., Sperandeo M., Andriulli A., & Bisceglia M. (2001). Hemangioma-like lesions in chronic liver disease: diagnostic evaluation in patients. *Radiology*, Vol. 220, pp. 337-342, ISSN 0033-8419
- Cha E-Y., Kim KW., Choi YJ., Song JS., Cho KJ., & Lee M-G. (2008). Multicystic cavernous hemangioma of the liver: ultrasonography, CT, MR appearances and pathological correlation. *The British Journal of Radiology*, Vol. 81, pp. 37-39, ISSN 0007-1285.
- Chuan-Miao XIE., Lie Zheng., Yun-Xian MO., Li Li., Chao-Mei Ruan Yan-Chun LU., & Pei - Hong WU. (2007). Helical double-phase CT scan imaging features of hepatocellular carcinoma and pathology of false-positive lesions. *Chinese Journal of Cancer*, Vol. 26, No. 1, pp.1-6, ISSN 16735269.
- Chung YE., Kim M-F., Park YN., Choi F-Y., Pyo FY., Kim YC., Cho HF., KimK A., & Choi SY. (2009). Varying appearances of cholangiocarcinoma: radiologic-pathologic correlation. *Radiographics*, Vol. 29, pp. 683-700, ISSN 0271-5333.
- Eldad S.Bialecki & Adrian M. Di Bisceglie. (2005). Diagnosis of hepatocellular carcinoma. *HPB*, Vol. 7, pp. 26-34, ISSN 1365-182X print/ ISSN 1477-2574 (online).
- Foley WD., Mallisee TA., Hohenwarter MD., Wilson CR., Quiroz FA. & Taylor AJ. (2000). Multiphase hepatic CT with a multidetector CT scanner. *Am J Roentgenol*, Vol. 175, pp. 679-685, ISSN 1753-679.
- Goshima S., Kanematsu M., Kondo H., Yokoyama R., Miyoshi T., Kato H., Hoshi H., Onozuka M., & Moriyama N. (2006). MDCT of the liver and hypervascular hepatocellular carcinomas: optimizing scan delays for bolus-tracking techniques of hepatic arterial and portal venous phases. *AJR*, Vol. 187, pp. W25-W32, ISSN 1871-W25.
- Grazioli L., Federle MP., Brancatelli G., Ichikawa T., Olivetti L., & Blachar A. (2001). Hepatic adenomas: imaging and pathologic findings. *Radiographics*, Vol. 21, pp. 877-894, ISSN 0271-5333.
- Grazioli L., Morana G., Kirchin MA., & Schneider G. (2005). Accurate differentiation of focal nodular hyperplasia from hepatic adenoma at Gadobenate Dimeglumine-enhanced MR imaging: prospective study. *Radiology*, Vol. 236, pp.166-177, ISSN 0033-8419.
- Hussain SM., Terkivatan T., Zondervan PE., Lanjouw E., Sjoerd de Rave, IJzermans Jan N.M., & Rob A. de Man. (2004). Focal nodular hyperplasia: findings at state of the art MR imaging, US, CT, and pathologic analysis. *Radiographics*, Vol. 24, pp. 3-19, ISSN 0271-5333.
- Iannaccone R., Piacentini F., Murakami T., Paradis V., Belghiti J., Hori M., Kim T., Durand F., Wakasa K., Monden M., Nakamura H., Passariello R., & Vilgrain V. (2007). Hepatocellular carcinoma in patients with nonalcoholic fatty liver disease: helical CT and MR imaging findings with clinical-pathologic comparison. *Radiology*, Vol. 243, No. 2, pp.422-430, ISSN 0033-8419.
- Ichikawa T., Federle MP., Grazioli L., & Nalesnik M. (2000). Hepatocellular adenoma: multiphasic CT and histopathologic findings in 25 patients. *Radiology*, Vol. 214, pp. 861-868, ISSN 0033-8419.

- Yoon SH., Lee JM., So YH., Hong SH., KimS J., Han JK., & Choi BI. (2009). Multiphasic MDCT enhancement pattern of hepatocellular carcinoma smaller than 3 cm in diameter: tumor size and cellular differentiation. *AJR*, Vol. 193, pp.W482-W489, ISSN 1936-W482.
- Jacomina W. Van den Esschert, Thomas M. van Gulik, & Phoa S.S.K.S. (2010). Imaging modalities for focal nodular hyperplasia and hepatocellular adenoma. *Digestive Surgery*, Vol. 27, pp.46-55, ISSN 0271-0046.
- Jang H-J., KimT K., Lim HK., Park SJ., Sim JS., Kim HY., & Lee J-H. (2003). Hepatic hemangioma: atypical appearances on CT, MR imaging, and sonography. Pictorial essay. *AJR*, Vol. 180, pp.135-141, ISSN 0361-803X.
- Jeong YY., Yim NY., & Kang HK. (2005). Hepatocellular carcinoma in the cirrhotic liver with helical CT and MRI: imaging spectrum and pitfalls of cirrhosis-related nodules. *AJR*, Vol. 185, pp. 1024-1032, ISSN 1854-1024.
- Jeong MG., Yu JS., & Kim KW. (2000). Hepatic cavernous hemangioma: temporal peritumoral enhancement during multiphase dynamic MR imaging. *Radiology*, Vol. 213, pp. 692-697, ISSN 0033-8419.
- Karcaaltincaba M., & Sirlin CB. (2010). CT and MRI of diffuse lobar involvement pattern in liver pathology. *Diagnostic and interventional radiology*, Vol.5, pp. 1-8, ISSN 21053176.
- Ke-guo ZHENG, Jing-xian SHEN, Gen-shu WANG & Da-sheng XU. (2007). Small hepatocellular carcinoma with peripheral enhancement: pathological correlation with dual phase images by helical CT. *Chinese medical Journal*, Vol. 120, No.18, pp.1583-1586, ISSN: 0366-6999.
- Kim HG. (2006). Biliary cystic neoplasm: biliary cistadenoma and biliary cystadenocarcinoma. *Korean Journal of Gastroenterology*, Vol. 47, No. 1, pp. 5-14, ISSN 1598-9992.
- Kim KW, Kim AY., KimT K., Kim SY., Park M-S., Park SH., Lee KH., Kim JK., Kim P-N., Ha HK., Lee M-G. (2006). Hepatic hemangiomas with arteriportal shunt: sonographic appearances with CT and MRI correlation. *AJR*, Vol.187, pp. 406-414, ISSN 0361-803X print/ISSN 1874-W406 (online).
- Kim KW., Kim MJ., Lee SS., Kim HJ., Shin YM., Kim P-N., & Lee M-G. (2008). Sparing of fatty infiltration around focal hepatic lesions in patients with hepatic steatosis: sonographic appearance with CT and MRI correlation. *AJR*, Vol. 190, pp. 1018-1027, ISSN 1904-1018.
- Kim S J., Lee JM., Han JK., KimK H., Lee JY., & Choi BI. (2007). Peripheral mass-forming cholangiocarcinoma in cirrhotic liver. *AJR*, Vol. 189, pp. 1428-1434, ISSN 0361-803X print/ISSN 1896-1428 (online).
- Kim T., Federle MP., Baron RL., Peterson MS., & Kawamori Y. (2001). Discrimination of small hepatic hemangiomas from hypervascular malignant tumors smaller than 3 cm with three-phase helical CT. *Radiology*, Vol. 219, pp 699-706, ISSN 0033-8419.
- Kumar V. & Pandey D. (2008). Isolated hepatosplenic tuberculosis. *Hepatobiliary and pancreatic diseases International*, Vol. 7, No. 3, pp. 328-330, ISSN 1499-3872.
- Lee YH., Kim SH., Cho M-Y., Shim KY., & Kim MS. (2007). Focal nodular hyperplasia - like nodules in alcoholic liver cirrhosis: radiologic - pathologic correlation. *AJR*, Vol. 188, pp. 459-463, ISSN 1885-W459.

- Lee J., Lee WJ., Lim HK., Lim JH., Choi N., Park M., Kim S W., & Park CK. (2008). Early hepatocellular carcinoma: three-phase helical CT features of 16 patients. *Korean J Radiology*, Vol. 9, pp. 325-332, ISSN 1229-6929.
- Lim A KP., Patel N., Gedroyc WMW., Blomley MJK., Hamilton G., & Taylor-Robinson SD. (2002). Hepatocellular adenoma: diagnostic difficulties and novel imaging techniques. Case report. *The British Journal of Radiology*, Vol. 75, pp. 695-699, ISSN 0007-1285 print/ ISSN 1748-880X(online).
- M.A. Hayat. (2009). *Methods of Cancer Diagnosis, Therapy and Prognosis - liver Cancer*. Volume 5, Part IV, Part 6. Springer-Science + Business Media B.V., ISBN 978-1-4020-9803-1-P, USA.
- Manouras A., Markogiannakis H., Lagoudianakis E., & Katergiannakis V. (2006). Biliary cistadenoma with mesenchymal stroma: Report of a case and review of the literature. *World J Gastroenterol*, Vol.12, No. 37, pp. 6062-6069, ISSN 1007-9327.
- Marchal G., Vogl T.J., Heiken J.P., Rubin G.D. (2005). *Multidetector - Row Computed Tomography. (Scanning and contrast protocols)*. Springer-Verlag, ISBN 88-470-0305-9, Milan, Italy.
- Masood A., Kairouz S., Hudhud K.H. Hegazi A.Z., Banu A., & Gupta N.C. (2009). Primary non-Hodgkin lymphoma of liver. *Current Oncology*, Vol. 16, No. 4, pp.74-77, ISSN 1718-7729.
- Mita K., Kim S R., Kudo M., Imoto S., Nakajima T., Ando K., Fukuda K., Matsuoka T., Maekawa Y., & Hayashi Y. (2010). Diagnostic sensitivity of imaging modalities for hepatocellular carcinoma smaller than 2 cm. *World J Gastroenterology*, Vol. 16, No. 33, pp. 4187-4192, ISSN 1007-9327 (print), ISSN 2219-2840 (online).
- Monzawa S., Ischikawa T, Nakajima H., Kitanaka Y., Omata K., & Araki T. (2007). Dynamic CT for detecting small hepatocellular carcinoma: usefulness of delayed phase imaging. *AJR*, Vol. 188, pp.147-153, ISSN 1881-147.
- Mortele KJ., Praet M., Van Vlierberghe, Kunnen., & Ros P.R. (2000). CT and MR imaging findings in focal nodular hyperplasia of the liver: radiologic - pathologic correlation. *AJR*, Vol.175, pp.687-692, ISSN 1753-687.
- Murakami T., Kim T., Takamura M., Hori M., Takahashi S., Federle MP., Tsuda K., Osuga K., Kawata S., Nakamura H. & Kudo M. (2001). Hypervascular hepatocellular carcinoma: detection with double arterial phase multi-detector row helical CT. *Radiology*, No.218, pp. 763-767, ISSN.0033-8419
- Nakanuma Y., Sato Y., Harada K., Sasaki M., Xu J., & Ikeda H. (2010). Pathological classification of intrahepatic cholangiocarcinoma based on a new concept. *World J of Hepatology*, Vol. 2, No. 12, pp. 419-427, ISSN 1948-5182.
- Natsuizaka M., Kudo M., Suzuki M., Takano M., Tsuyuguchi M., Kawamura N., Noguchi S., Wada A., Nakata M., Ogasawara M., Kiyama Y., Asaka M., & Kasai M. (2009). Diffuse large B-cell lymphoma with massive portal vein tumor thrombosis in a patient with alcoholic cirrhosis: a case report and literature review. *Internal medicine*, Vol. 48, pp.805-808, ISSN 0918-2918.
- Nino-Murcia M., Olcott EW., Jeffrey RB., Lamm RL., Beaulieu CF., & Jain KA. (2000) Focal liver lesions: pattern - based classification scheme for enhancement at arterial phase. *Radiology*, Vol. 215, pp. 746-751, ISSN 1527-1315.
- Nouira K., Allani R., Bougamra I., Bouzaidi K., Azaiez O., Mizouni H., Messaoud MB., & Menif E. (2007). Atypical small hemangiomas of the liver: hypervascular

- hemangiomas. *International journal of biomedical science*, Vol.3, No.4, pp. 302-304, ISSN 15509702
- Numminen K., Isoniemi H., Halavaara J., Tervahartiala P., Makisalo H., Laasonen L., & Hockerstedt K. (2005). Preoperative assessment of focal liver lesions: multidetector computed tomography challenges magnetic resonance imaging. *Acta Radiol*, Vol. 46, pp. 9-15, ISSN 0284-1851.
- Oliva MR., & Saini S. (2004). Liver cancer imaging: role of CT, MRI, US and PET. *Cancer imaging*, Vol. 4, pp. S42-S46, ISSN 1740-5025.
- Outwater EK. (2010). Imaging of the liver for hepatocellular Cancer. *Cancer control*, Vol. 17, No. 2, pp. 72-82, ISSN 20404790.
- Pitton MB., Kloeckner R., Herber S., Otto G., Kreitner KF., & Dueber C. (2009). MRI versus 64-row MDCT for diagnosis of hepatocellular carcinoma. *World J Gastroenterology*, Vol. 15, No. 48, pp. 6044-6051, ISSN 1007-9327.
- Purl A.S., Nayyar A.K. & Vij J.C. (1994). Hepatic tuberculosis. *Indian Journal of tuberculosis*, Vol.41, pp. 131-134, ISSN 0971-5916.
- Quiroga S., Sebastia C., Pallisa E., Castella E., Perez-Lafuente M., & Alvarez-Castells. (2001). Improved diagnosis of hepatic perfusion disorders: value of hepatic arterial phase imaging during helical CT. *Radiographics*, Vol. 21, pp. 65-81, ISSN 0271-5333.
- Raptopoulos VD., Blake SP., Weisinger K., Atkins MB., Keogan MT., & Kruskal JB. (2001). Multiphase contrast-enhanced helical CT of liver metastases from renal cell carcinoma. *European Radiology*, Vol.11, No. 12, pp. 2504-2509, ISSN 0938-7994.
- Ri-Sheng Y., Zhang S-Z., Wu J-J & Li R-F. (2004). Imaging diagnosis of 12 patients with hepatic tuberculosis. *World Journal of Gastroenterology*, Vol. 10, No. 11, pp. 1639-1642, ISSN 1007-9327.
- Robinson PH. (2008). Hepatocellular carcinoma: development and early detection. *Cancer imaging*, Vol. 8, pp. S128-S131, ISSN 1740-5025.
- Ronzoni A., Artioli D., Scardina R., Battistig L., Minola E., Sironi S., & Vanzulli A. (2007). Role of MDCT in the diagnosis of hepatocellular carcinoma in patients with cirrhosis undergoing orthotopic liver transplantation. *AJR*, Vol. 189, pp. 792-798., ISSN 1894-792.
- Ruppert-Kohlmayr AJ., Uggowitz MM., Kugler C., Zebedin D., Schaffler G., & Ruppert GS. (2001). Focal nodular hyperplasia and hepatocellular adenoma of the liver: differentiation with multiphasic helical CT. *AJR*, Vol. 176, pp.1493-1498, ISSN 1766-1493.
- Saluja SS., Ray S., Pal S., Kukeraja M., Srivastava DN., Sahni P., & Chattopadhyay T. (2007). Hepatobiliary and pancreatic tuberculosis: a two decade experience. *Research article. BMC Surgery*, pp. 7-10, ISSN 1471-2482.
- Sanders LM., Botet JF., Straus DJ., Ryan J., Filippa DA., & Newhouse JH. (1989). CT of primary lymphoma of the liver. *AJR*, Vol. 152, pp.973-976, ISSN 1525-0973.
- Schwarz LH., Gandras EJ., Colangelo SM., Ercolani MC., & Panicek DM. (1999). Prevalence and importance of small hepatic lesions found at CT in patients with cancer. *Radiology*, Vol. 210, pp. 71-74, ISSN.0033-8419.
- Scott DJ., Guthrie JA., Arnold P., Ward J., Atchley J., Wilson D., & Robinson PJ. (2001). Dual-phase helical CT versus portal venous phase CT for the detection of colorectal liver metastases: correlation with intra-operative sonography, surgical and pathological findings. *Clinical Radiology*, Vol.56, pp. 235-242, ISSN 0009-9260.

- Sharma S.K., Smith-Rohrberg D., Tahir M., Mohan A. & Seith A. (2007). Radiological manifestations of splenic tuberculosis: a 23-patient case series from India. *Indian J Med Res*, Vol. 125, pp. 669-678, ISSN 17642503.
- Soyer P, Pocard M, Boudiaf M, Abitbol M., Hamzi L., Panis Y., Valleur P., & Rymer R. (2004). Detection of hypovascular hepatic metastases at triple-phase helical CT: sensitivity of phases and comparison with surgical and histopathologic findings. *Radiology*, Vol. 231, pp. 413-420, ISSN 0033-8419.
- Sood D., Kumaran V., Buxi TBS., Nundy S., & Soin AS. (2009). Liver hemangioma mimicking cholangiocarcinoma - a diagnostic dilemma. *Tropical gastroenterology*, Vol. 30, No.1, pp. 44-46, ISSN 0250-636X.
- Szklaruk J., & Bhosale P. (2007). Hepatocellular carcinoma: MRI and CT examination. *Reviews. IMAJ*, Vol. 9, pp.153-155, ISSN 1565-1088.
- Takayasu K., Muramatsu Y., Mizuguchi Y., Okusaka T., Shimada K., Takayama T., & Sakamoto M. (2006). CT evaluation of the progression of hypoattenuating nodular lesions in virus-related chronic liver disease. *AJR*, Vol. 187, pp. 454-463, ISSN 1872-454.
- Toriyama E., Nasashima A., Hayashi H., Abe K., Kinoshita N., Yuge S., Nagayasu T., Uetani M., & Hayashi T. (2010). A case of intrahepatic clear cell cholangiocarcinoma. *World J of Gastroenterology*, Vol. 16, pp. 2571-2576, ISSN 1007-9327.
- Tranquart F., Bleuzen A., & Kissel A. (2004). Value of combined conventional and contrast enhanced sonography in the evaluation of hepatic disorders. *J Radol.*, Vol. 85, No.1, pp. 755-762, ISSN 0221-0363.
- Vilgrain V., Boulos L., Vullierme M-P., Denys A., Terris B., & Menu Y. (2000). Imaging of atypical hemangiomas of the liver with pathologic correlation. *Radiographics*, Vol.20, No. 2, pp. 379-397, ISSN 0271-5333
- Xu A-M., Cheng H-Y., Chen D., Jis Y-C., & Wu M-C. (2002). Plane and weighted tri-phase helical CT findings in the diagnosis of liver focal nodular hyperplasia. *Hepatobiliary & Pancreatic Diseases International*, Vol. 1, No. 2, pp. 219-223, ISSN 1499-3872.
- Zhao H., Yao J-L., Wang Y., & Zhou K-R. (2007). Detection of small hepatocellular carcinoma: comparison of dynamic enhancement magnetic resonance imaging and multiphase multirow-detector helical CT scanning. *World J Gastroenterology*, Vol.13, No.8, pp.1252-1256, ISSN 1007-9327.
- Zviniene K., Zaboriene I., Basevicius A., Jurkiene N., Barauskas G., & Pundzius J. (2010). Comparative diagnostic value of contrast-enhanced ultrasonography, computed tomography, and magnetic resonance imaging in diagnosis of hepatic hemangiomas. *Medicina (Kaunas)*, Vol. 46, No.5, pp. 329-335, ISSN 1010-660X [pint/1648-9144](http://www.pint/1648-9144) (online)
- [<http://emedicine.medscape.com/article/368377>].
[www.loc.lt].



Hepatocellular Carcinoma - Clinical Research

Edited by Dr. Joseph W.Y. Lau

ISBN 978-953-51-0112-3

Hard cover, 330 pages

Publisher InTech

Published online 02, March, 2012

Published in print edition March, 2012

This book covers the clinical aspects of hepatocellular carcinoma. This book is a compendium of papers written by experts from different parts of the world to present the most up-to-date knowledge on the clinical aspects of hepatocellular carcinoma. This book is divided into three sections: (I) Diagnosis / Differential Diagnosis; (II) Surgical Treatment; (III) Non-surgical Treatment. There are 19 chapters covering topics from novel diagnostic methods to hepatic lesions mimicking hepatocellular carcinoma, from laparoscopic liver resection to major hepatectomy without allogeneic blood transfusion, from molecular targeted therapy to transarterial radioembolization, and from local ablative therapy to regional therapy. This volume is an important contribution to the clinical management of patients with hepatocellular carcinoma. The intended readers of this book are clinicians who are interested in hepatocellular carcinoma, including hepatologists, liver surgeons, interventional and diagnostic radiologists, pathologists and epidemiologists. General surgeons, general physicians, trainees, hospital administrators, and instruments and drug manufacturers will also find this book useful as a reference.

How to reference

In order to correctly reference this scholarly work, feel free to copy and paste the following:

Kristina Zviniene (2012). Differential Diagnosis of Hepatocellular Carcinoma on Computed Tomography, Hepatocellular Carcinoma - Clinical Research, Dr. Joseph W.Y. Lau (Ed.), ISBN: 978-953-51-0112-3, InTech, Available from: <http://www.intechopen.com/books/hepatocellular-carcinoma-clinical-research/differential-ct-diagnostics-of-hepatocellular-carcinoma>

INTECH
open science | open minds

InTech Europe

University Campus STeP Ri
Slavka Krautzeka 83/A
51000 Rijeka, Croatia
Phone: +385 (51) 770 447
Fax: +385 (51) 686 166
www.intechopen.com

InTech China

Unit 405, Office Block, Hotel Equatorial Shanghai
No.65, Yan An Road (West), Shanghai, 200040, China
中国上海市延安西路65号上海国际贵都大饭店办公楼405单元
Phone: +86-21-62489820
Fax: +86-21-62489821

© 2012 The Author(s). Licensee IntechOpen. This is an open access article distributed under the terms of the [Creative Commons Attribution 3.0 License](#), which permits unrestricted use, distribution, and reproduction in any medium, provided the original work is properly cited.

IntechOpen

IntechOpen