

# We are IntechOpen, the world's leading publisher of Open Access books Built by scientists, for scientists

4,800

Open access books available

122,000

International authors and editors

135M

Downloads

Our authors are among the

154

Countries delivered to

TOP 1%

most cited scientists

12.2%

Contributors from top 500 universities



WEB OF SCIENCE™

Selection of our books indexed in the Book Citation Index  
in Web of Science™ Core Collection (BKCI)

Interested in publishing with us?  
Contact [book.department@intechopen.com](mailto:book.department@intechopen.com)

Numbers displayed above are based on latest data collected.  
For more information visit [www.intechopen.com](http://www.intechopen.com)



# Surgical Treatment of Erectile Dysfunction

Faruk Kucukdurmaz and Ates Kadioglu  
*Istanbul University, Istanbul Medical Faculty, Urology Department, Istanbul  
Turkey*

## 1. Introduction

Erectile dysfunction (ED) is defined as the consistent or recurrent inability of a man to attain and/or maintain penile erection sufficient for sexual activity. According to current guidelines, a 3-month symptom duration is accepted to establish the diagnosis except for some cases of trauma or surgically induced ED (Lewis R 2010). ED affects physical and psychosocial health and has a significant impact on the quality of life (QoL) of sufferers and their partners and families. Epidemiologic studies for ED estimate the prevalence of ED ranging between 20-30 % among men aged between 40-80 years (Laumann et al 2005, Lewis R 2010). These differences in reported incidences are probably due to variations in the methodology and the age and socioeconomic status of the study populations.

ED is a disorder in which subjective perception of patients is very important, therefore, the aim of the treatment should not only be organ focused but also be patient-outcome oriented. Patient satisfaction with sexual intercourse, their overall sex lives and ED treatments may represent reliable predictors of key patient-related treatment outcomes, in addition to pharmacological efficacy and safety (Carson C, et al. 2004)

The basic diagnostic work-up for patients who presented with ED should include a thorough medical and psychosexual history to identify common causes and risk factors of ED and assess psychological status of patients by using validated instruments (Hatzimouratidis K, et al. 2010). A focused physical examination should be the next step to evaluate possible penile deformities, prostatic diseases, signs of hypogonadism, cardiovascular and neurological status of the patients. Evaluation of serum glucose, lipid and testosterone levels is also an essential part of the initial evaluation of ED patients.

Patients suffering from ED should be treated with a structured strategy which may be influenced by efficacy, safety, invasiveness, cost effectivity and satisfaction of both the patient and his partner. These parameters should also be considered for the selection of the treatment option for each particular patient and his partner.

Although newer medical treatment alternatives such as PDE-5 inhibitors, vacuum erection devices and intracavernosal applications are considered first and second lines of ED therapy, respectively; surgical treatment, especially penile prosthesis implantation, is the standard of care in cases of medication-resistant ED. Surgical treatment options in order to correct ED are divided into three categories. These categories are:

1. Penile prosthesis implantation
2. Penile revascularization
3. Surgery for corporal veno-occlusive dysfunction

## 2. Penile prosthesis implantation

From the historical point of view, the wooden sticks that were either placed under the skin of the penis or into the urethra are known as the earliest implanted materials designed to improve erectile function (Henry GD, 2009). With increased knowledge of human anatomy, autologous materials were started to be implanted. The first real attempt to create an internal penile support and provide penile rigidity was described in 1936 by Bogoras who used a piece of cartilage as a penile stiffener in a total phallic reconstruction (Bogoras 1936). This is followed by Beheri who first documented successful intracavernosal placement of polyethylene rods in 700 patients in 1966 (Beheri 1966). The successful implantation of a new semirigid silicone cylinder that fulfills the whole corpora was described in 1973 which lead to the development of new implants that are currently used (Scott 1973).

### 2.1 Indications of surgery

There are many types of penile prosthesis designs that are currently available for implantation, but it should be kept in mind that not all patients with ED are candidates for penile prosthesis implantation. Implantation of penile prosthesis is indicated for the treatment of organic ED in men who fail or reject more conservative measures, such as oral PDE5 inhibitors, vacuum erection devices (VED), urethral alprostadil suppositories, and intracavernosal injection therapy. Additionally, implants are appropriate when medical therapy is contraindicated, cause severe side effects, vacuum erection therapy has proven unsatisfactory or unacceptable, and/or in men with end organ failure (e.g. diabetes mellitus), severe structural abnormalities (e.g. Peyronie's disease), cavernosal fibrosis (e.g. after prolonged priapism or infection). Patients who experience ED after radical prostatectomy or pelvic organ transplantation may also serve as the candidates for penile prosthesis implantation. Careful counseling before penile implant procedures will reduce the probability of problems that may result in postoperative dissatisfaction. The type of the prosthesis for each particular patient should be selected according to the patients' needs and expectations (Carson CC 2005). Patients at younger age with normal manual dexterity or who wear firm clothing often choose a three-piece inflatable penile prosthesis because appearance in the flaccid position is better than other designs (Hellstrom WG, et al. 2010). In addition, inflatable penile prosthesis should be the preferred option in patients with Peyronie's disease, history of previous implantation procedures or neurological disorders where considering interior tissue pressures are declined between uses and the risk of extrusion is diminished (Zermann DH, 2006). For some patients such as paraplegics, malleable prostheses can be chosen since inflatable ones have much higher malfunction rates. Malleable penile prosthesis can be better served in those patients who lack adequate manual dexterity, or those with significant obesity (Hellstrom WG, et al. 2010).

### 2.2 Types of implants

There are three classes of penile implants including hydraulic, semi-rigid and soft silicone. The hydraulic implants consist of two types, the three-piece inflatable and the two-piece

inflatable. The only two-piece device currently available is AMS Ambicor(Fig.1). When this nondistensible device is deflated, the cylinders collapse and the penis, unlike that with a malleable prosthesis, is not rigid. When the scrotal pump is cycled, a small volume of fluid is transferred from the rear tips of the cylinders into the distal nondistensible chambers filling and then pressurizing them. Different from 3-piece inflatable prosthesis, Ambicor does not increase in size with inflation. Flaccidity and erection are more compromised with this model when compared with 3-piece device due to low, restricted reservoir volume. Also the device is not available with antibiotic impregnated forms as of yet, but has an acceptable short-term mechanical reliability (Levine LA 2001).



Fig. 1. AMS Ambicor two-piece inflatable penile prosthesis

The ideal penile prosthesis would produce flaccidity and erection that mimics natural condition. Three-piece inflatable prostheses provide these conditions by transferring fluid into and out of cylinders. These devices consist of a pair of cylinders, reservoir and a pump. AMS and Coloplast are the two main companies that manufacture 3-piece inflatable prostheses. Coloplast manufactures the Titan Inflatable Penile Prosthesis (Fig. 2) and the Titan Narrowbase Inflatable Penile Prosthesis. The Narrowbase implant is developed for patients with small penises or for cases in which dilation is limited because of scarring from corporal fibrosis or previous surgery. All of these cylinders expand in girth, but not in length. AMS manufactures the AMS 700 CX Inflatable Penile Prosthesis (Fig. 3), the AMS 700 LGX Inflatable Penile Prosthesis, and the AMS 700 CXR Inflatable Penile Prosthesis. The CXR device, like the Titan Narrow-base prosthesis, has smaller diameter cylinders and is used in revision cases and less commonly in men with small penises.

Apart from other devices, AMS LGX cylinder has a unique property that it expands both in girth and length (Fig 4). The CX and CXR have a unidirectional weave that allows only girth expansion, whereas the LGX has a bidirectional weave permitting expansion both in length and girth. In patients with organic ED and penile deformity or curvature, girth only expanding devices may provide better cosmetic outcome. In men with small penises or men with scarring due to ischemic priapism or previous penile surgery where corporeal dilation is limited, smaller diameter CXR cylinders often serve as a better alternative.

Infections are known to be the most significant and unwanted complications in IPP surgery, especially for revision/replacement, which may develop due to decreased host resistance,

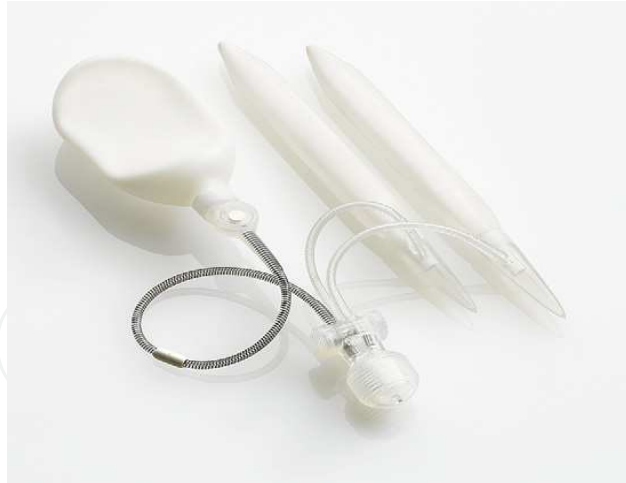

Fig. 2. Hydrophilic-coated Coloplast Titan™ threepiece prosthesis with reservoir lock-out valve to minimize autoinflation

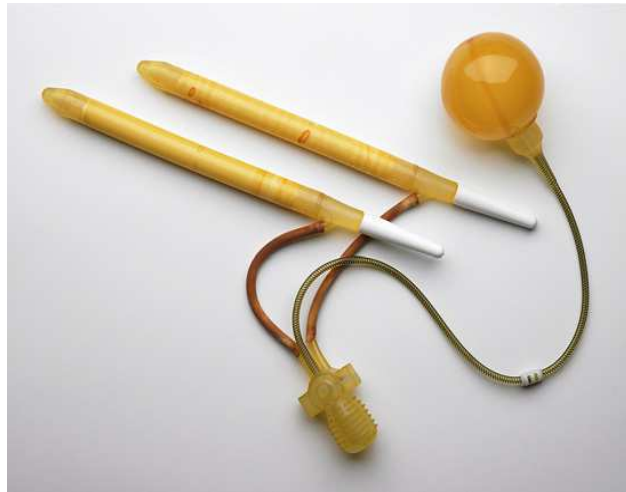

Fig. 3. AMS 700 CX inflatable penile prosthesis

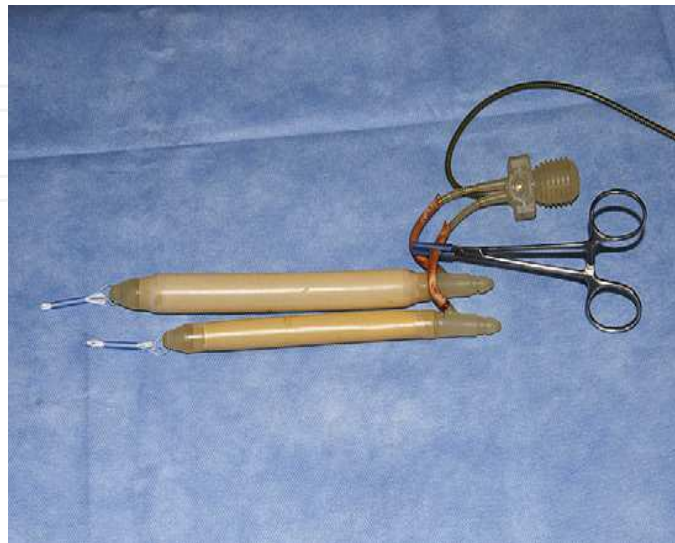


Fig. 4. AMS LGX inflatable penile prosthesis



impaired antibiotic penetration due to capsule formation, and decreased wound healing related to scarring. Most bacteria produce a mucin coat or biofilm that is the bacterial colonisation over the device and resistant to systemic antibiotic treatment due to decreased metabolic needs (Silverstein A, et al 2003). Antibiotics or the body's defense mechanisms can not eradicate the bacteria inside the biofilm without removing all prosthetic components and irrigation of the implant spaces (Stewart et al 2001). Both manufacturers developed advances in the designs of prosthesis in order to decrease the incidence of infections by applying coatings to the prosthesis designed to retard bacterial growth. In 2001, AMS introduced InhibiZone™ (Fig. 5) which is a patented antibiotic surface treatment that impregnates minocycline and rifampin into the external silicone surfaces of all the components, except the RTE, giving the orange-like color.



Fig. 5. AMS 700 MS™ series cylinder with InhibiZone® antibiotic surface treatment. AMS = American Medical Systems.

The antibiotics reach into the implant space within 10 days. They seem effective in the prevention of bacterial colonization and development of biofilm layer (Nickel JC, et al.1998). Minocycline and rifampin may help decrease the probability of developing bacterial resistance by inhibition of protein synthesis and inhibition of DNA-dependent RNA polymerase, respectively (Darouiche RO, et al 1999). In-vitro and in-vivo studies have demonstrated the effectiveness of minocycline in retarding the emergence of staphylococcal strains that are resistant to rifampin (Raad et al 1995). Short-term follow-up for this prosthesis enhancement shows statistical improvement in infection reduction for first time implant patients by a single surgeon (Wilson SK, et al 2002). Coloplast also produced antibiotic-coated devices named as Titan and Titan NB. The hydrophilic coating absorbs much more water and the idea is the adherence of antibiotics to the surface of prosthesis when soaked into antibiotic solutions.

It should be remembered that pumping systems of inflatable devices require some manual dexterity and patients who lack this ability may experience difficulties in order to make these devices work. AMS developed Momentary Squeeze Pump (MSP) that contains a much smaller pump with the inflation part in the most dependent site and deflation part in the upper portion of pump. It delivers more volume per squeeze and is easier to find deflation button. The main difference with the previous pump is that the MSP deflates completely after pressing the deflation button for a few moments. It also has a lock-out valve precluding

auto-inflation of the implant. Early clinical studies reported significant reduction in time spent instructing the patient in use of this device (Henry GD, et al 2004).

Semi-rigid rod prostheses are constructed of two solid prostheses that are independently placed in each corpus cavernosum (Sadeghi-Nejad H 2007). They are divided into two types as the malleable and the mechanical. Coloplast's Genesis is a malleable device that consists of a braided silver wire surrounded by a silicone hydrophilic coat. The AMS 650 and 600 implants have similar construction of silicone surrounding a stainless steel woven core. Soft silicone rods were originally manufactured in France by Subrini (Subrini L 1982). They are ideal for patients in whom the cosmetic advantages of the inflatable devices are not as important as the ease of use and the lower chances of mechanical failure in semirigid implants. Pelvic organ transplant recipients may be well served by the semirigid devices rather than a three-piece inflatable device due to the results of a study addressing the higher incidence of reservoir complications in the retroperitoneal space (Cuellar DC, 2001). The narrow cylinders are appropriate for thin penises and for the penises with scar tissue where dilation to a large caliber corporal body is not easily performed.

Implantation of three-piece inflatable prostheses is a complex issue since they require a reservoir which has a large volume to be placed in the abdominal cavity. Since reservoir has a high capacity, complications such as stretching of pliant tunica and compression of erectile tissue that cause deterioration of the erectile tissue with time which are observed with the use of self-contained or two-piece devices with no reserve fluid volume are not seen in three-piece inflatable implants (Wilson SK, et al 1996). The three-piece inflatable also gives the best flaccidity, as all fluid can be drained out of the cylinders into the reservoir when the non-erect state is desired. Satisfaction rates of 70–87% are reported from patients after appropriate consultation.

### 2.3 Patient selection

The surgeon has three choices when selecting a prosthesis for a particular patient which include semirigid, two-piece inflatable, and three-piece inflatable prosthesis. Generally, the decision of the type of the prosthesis to be used depends on the physician's comfort with the surgical approach, assessment of body habitus, penile size, previous abdominal surgery and manual dexterity of the patient. Recently, the 3-piece inflatable prosthesis is accepted as the gold standard option in industrialized countries.

The semi-rigid rods are easy to implant and manipulate since they are bendable and can easily be maneuvered (Hellstrom WG et al, 2010). This kind of implants may have tendency to be eroded through glans because of cylinder pressure and loss of sensation in patients with spinal cord injury. Implantation of inflatable prostheses in this patient population can be recommended even if the implant is used only to make condom catheter urinary drainage easier (Rossier 1984).

Two-piece inflatable devices have the advantage of avoiding intra-abdominal reservoir placement. They provide better functional outcomes than rod implants in terms of rigidity and flaccidity.

Although three-piece inflatable devices provide the best rigidity, it should be beneficial to use these devices in patients with a larger penis. Similarly, patients with shorter penises

mostly prefer three-piece devices because of the difficulty to hide semi-rigid rods and two-piece implants. Semi-rigid rods are generally selected in patients with limited manual dexterity or those who experience problems with the use of hydraulic devices. A motivated partner who may manipulate the device will be an exception to this issue.

Penile prosthesis implantation restores penetrative ability, however, it has no effect on recovery of sexual drive, glandular sensitivity and ejaculatory functions. If the removal of implants occurs at a later date, the capsule remains and the empty space will partially fill with proliferating scar tissue which makes it difficult for the patient to respond sufficiently to other medical treatment alternatives. Therefore, it is important that the patient should be aware of his expectations about the penile prosthesis. Also, a detailed discussion between surgeon and patient about the outcomes and potential complications of the procedure such as infection which may necessitate reoperation with a rate of 1-4% and mechanical dysfunction should be performed (Govier et al 1998, Wilson et al 1999).

#### **2.4 Preoperative preparation and postoperative care**

Preoperative preparation of patient aims to reduce the risk of infection (AUA Guidelines 2005). Lower urinary tract should be investigated before prosthetic surgery to find out some abnormalities such as urinary tract infection and urethral stricture. A urinalysis, determination of post-void residual urine, and cystoscopy in indicated cases should be performed in order to rule out these abnormalities. If infection is detected, it should be treated or the patient should be placed on prophylactic antibiotic treatment before the surgery. Any obstruction that may be due to prostatic hypertrophy or bladder neck contracture should be treated prior to prosthetic surgery. Simultaneous insertion of penile prosthesis and artificial urinary sphincter may be recommended in patients who suffer from urinary incontinence after radical prostatectomy. Although there are some studies which reported that a better control of blood sugar in patients with diabetes mellitus is associated with a lower risk of infection, larger studies detected no difference in infection rates in normal or elevated blood glucose level (Wilson SK, et al 1998). More recently, Mulcahy et al reported the results of 6071 diabetic patients who underwent penile prosthesis implantation with antibiotic (minocycline and rifampin) impregnated and 624 patients implanted with non-antibiotic impregnated implants with initial revision rates of 1.47% and 4.17%, respectively (Mulcahy et al 2011). At the end of 7 year-follow-up, authors found out the rate of infection related revisions significantly lower for antibiotic impregnated implant (1.62%) than for nonimpregnated implants (4.24%). It is also determined that diabetic men had a significantly higher rate of revisions due to infection at 7 yr (1.88%) than men without diabetes (1.53%). Finally, authors concluded that this long-term evidence obtained from the largest patient population establishes that the use of an antibiotic-impregnated IPP can decrease revisions due to infection and this decline may represent a significant medical advance in erectile restoration for diabetic patient population. There are a few measures to decrease the risk of infection such as showering with antibacterial soap, shaving operation area and use of broad-spectrum antibiotics one hour prior to surgery. Insertion of a catheter may facilitate urethral dissection and provide space for reservoir placement by emptying the bladder if a scrotal incision is carried out. The catheter may remain until the following morning. Some surgeons have tendency to use drains at the end of the surgery to reduce



edema and provide an exit for bleeding. Such a drain is removed the following morning and has not demonstrated an increased incidence of prosthesis infection (Wilson SK, et al 1996).

Most patients need oral pain medication following the surgery. Heavy exercise and other activities which may cause displacement of the reservoir into the inguinal canal are proscribed for 4 weeks. Patients are instructed to use the device and return the sexual activity at the postoperative period of 4 to 6 weeks (Montague DK. 2011). Since initial inflation of the prosthesis may be difficult to perform; it will be beneficial to instruct the patients to inflate and deflate the device twice daily for the first month after surgery.

## **2.5 Operative technique**

There are a variety of approaches for the implantation of penile prostheses described in the literature. These are distal penile, infrapubic and penoscrotal approaches. The distal penile approach is generally preferred for insertion of a semirigid or malleable penile prosthesis. Better visualization for the reservoir placement is the advantage of infrapubic approach. However, neurovascular injury which may result in decreased distal penile sensation is more likely due to close relationship with neurovascular bundle. Two-piece devices, due to the absence of a separate reservoir, are best implanted through a penoscrotal incision. Infrapubic approach may be preferred in patients with the history of previous abdominal surgeries where reservoir placement is complicated, however, penoscrotal approach provides ease in massive obese patients. In conclusion, the approach chosen for each particular patient should be based upon the type of prosthesis available, anatomy and surgical history of patient and preference of the surgeon.

### **2.5.1 Distal penile approach**

This approach is generally accepted as the best approach for insertion of a semirigid or malleable penile prosthesis. It provides some advantages such as well incision healing, allowing corporeal dilation, and facilitation of rod placement.

After placement of a foley catheter, a circumcoronal incision is carried out and dissection is performed down to the layer of Buck's fascia with special consideration to prevent harm to dorsal penile nerves, which course within Buck's fascia. After identification of Buck's fascia, stay sutures are placed in the two corpora through the tunica albuginea lateral to the penile nerves. Dilation of corpora is performed by large scissors to establish a track in the corporal tissue. Dilation then follows with Hegar or Brooks dilators from 9 to 14 depending upon required cylinder girth. Once the corpora are measured by using a Furlow or other dilator, the cylinders can be placed. The corporotomy is then closed with 2-0 absorbable, synthetic sutures. With noninflatable cylinders, a penile block can be performed and a noncompression dressing is applied.

### **2.5.2 Infrapubic approach**

The infrapubic approach is carried out by a horizontal or vertical incision approximately one finger below the symphysis pubis. After performing incision, subcutaneous tissue is dissected down to the rectus fascia. The rectus fascia is then incised and dissected for approximately 2 to 3 cm. A midline separation of the rectus muscles is achieved by sharp

and blunt dissection to create a pouch beneath the rectus muscles in order to insert the reservoir without any discomfort. Dissection is then carried out over the corpora cavernosa. Sharp and blunt dissection is performed on either side of the fundiform ligament, identifying the dorsal neurovascular bundle. At this point, it should be remembered that the dorsal nerves of the penis lie approximately 2 to 3 mm lateral to the deep dorsal vein. Once Buck's fascia has been dissected free from the tunica albuginea, the shiny white tunica albuginea is fixed with longitudinal traction sutures. Then, a corporotomy incision is performed between the traction sutures. Following corporotomy, scissors are used to initiate the tunneling of the corpora cavernosa. Hegar dilators from size 9 to 14 can also be used. If corporeal fibrosis is encountered, Rossillo cavernotomes can be used to dilate to size 12. After performing dilation bilaterally, Furlow introducer can be used to measure corporal length by using the traction suture as the reference point.

Proximal and distal measurements are added to give total corporal length and choose appropriately sized inflatable cylinders. A length slightly less than the total measurement is usually used to permit comfortable positioning of the cylinders. Rear tip extenders of size 0.5, 1, 2, 3 cm, or combinations thereof are placed on the proximal cylinder end to adjust length.

Following measurement, interrupted sutures can be placed for subsequent corporotomy closure. When the corporotomy sutures are placed, cylinders are positioned in the dilated corpora cavernosa using the Furlow inserting tool with distal needle to pull the cylinders into position. It is important to ensure that adequate positioning of proximal and distal ends of cylinders has been performed. The corporal incision should be placed proximal enough to allow easy exit of the input tube and minimize cylinder/input tube contact. Closure of the corpora cavernosa is carried out with traction on the cylinder placement suture to maintain it in a flat, nonkinking position and ensure adequate seating. Following placement of cylinders and closure of the corporotomy incision, cylinder inflation can be tested by pumping fluid to identify any abnormalities in position, curvature, or related problems. A finger is placed beneath Scarpa's fascia down into the scrotum on one side to develop a subdartos pouch for the pump. The pump is then positioned in the most dependent portion of the scrotum. The reservoir is then placed into the previously prepared area and filled with saline. Before connection, it is important to release pressure on the filling syringe and determine if any backfilling is observed. This backfilling or backpressure may predict an autoinflation problem in the future. Tubing connection is then carried out using quick connectors or suture tie plastic connectors. The tubing is tailored to eliminate excessive length but to allow for adequate pump positioning. Shodded clamps are used to compress the ends of tubes. Following tailoring, tubes are irrigated to eliminate small particles or blood clots. After the tubing is connected, the adequacy of the connection is tested by gently pulling on the connectors. All shodded clamps are removed and the device is inflated and deflated on multiple occasions to ensure adequate location, placement, and erection.

After that, thorough irrigation with antibiotic solution and then closure of rectus fascia with interrupted sutures are carried out. The wound then is closed in the standard fashion with two layers of subcutaneous tissue and a subcuticular skin suture leaving the cylinders partially inflated for 24 hours to improve haemostasis. A dry, sterile dressing is applied and a foley catheter is placed at the end of the procedure. Suction drains may be used according to surgeon's preference. The catheter is usually removed in the first postoperative day. The

cylinders are deflated and patient discharged after the removal of drain. At discharge, patients are prescribed with a one-week antibiotic regimen and instructed to start cycling the device. Sexual activity can usually be resumed 6 weeks postoperatively (Garaffa G, et al 2010).

### **2.5.3 Penoscrotal approach**

Three-piece inflatable penile prostheses, as well as semirigid and two-piece prostheses can be implanted by a transverse or vertical penoscrotal incision. This approach has distinct advantages in obese patients and is the most common approach for routine penile prosthesis implantation. Since differentiation of corpus spongiosum and corpus cavernosum is mandatory during dissection in this approach, initial insertion of a foley catheter is generally recommended. The incision is placed in the upper portion of the scrotum one finger below the penoscrotal junction. Once the skin incision has been carried out, dissection is continued lateral to the corpus spongiosum and urethra to expose the corpora cavernosa. Incision, dilation, and closure of the corpora cavernosa are similar to that described previously for the infrapubic incision, but synthetic absorbable sutures should be used with this approach because the suture line may be palpable postoperatively. Cylinder sizing and placement are as described above. Pump placement is likewise in the most dependent portion of the scrotum just below the dartos fascia. Dissection for reservoir placements can be carried out with a second separate infrapubic incision, but is more commonly performed through the penoscrotal incision. The scrotal skin incision is retracted to the area of the external inguinal ring and dissection is carried out medial to the spermatic cord. It is important to drain the bladder completely at this point. The transversalis fascia is then identified and incised sharply using large scissors pushed firmly through the medial aspect of the external inguinal ring. Dilation is carried out with the index finger after incision of the transversalis fascia. The reservoir balloon is then positioned over the index finger and placed in the perivesical space. Inflation of the reservoir is carried out with care that no backpressure is observed. Pocket enlargement should be performed to prevent autoinflation in case of syringe refilling. Once the reservoir is placed, inflated, and tubing connected as previously described, the device is tested in inflation and deflation modes. Closure is carried out with a subcuticular suture in the standard fashion.

### **2.6 Complications of penile prosthesis implantation**

Complications of penile prosthesis can be divided into two categories as intraoperative and postoperative complications. Intraoperative complications include corporal cross-over and corporal/urethral perforation. Corporal cross-over can be subdivided into proximal and distal and might be encountered during corporal dilatation or cylinder placement (Garaffa et al 2010). This complication may be easily detected and corrected during the procedure. Testing for cross over is performed by side by side placement of dilators in each corpus cavernosum with special consideration to symmetry and proper positioning. If a crossover is detected, the dilator may be simply redirected with the contralateral dilator left in situ to prevent repeat crossover. Corporal perforation may also be recognized and easily repaired during the procedure, however, if urethral perforation is suspected, the procedure should be abandoned to allow for spontaneous recovery of the tear or a direct repair through a separate incision should be performed while the cylinder is in place.

Postoperative complications include infection, mechanical failure, auto-inflation, glans tumescence or coolness, reservoir displacement, cylinder erosion or extrusion and cavernosal fibrosis.

The two main complications of penile prosthesis implantation are mechanical failure and infection. Mechanical failure of penile prosthesis can include leakage from the cylinders, tubing fracture, reservoir malfunction, connector disruption, tube kinking and cylinder aneurysm. Historically, mechanical failure rates have been known to be low with many studies reporting rates of failure between 5-15% (Milbank et al 2002, Deuk et al 2001, Daitch et al 2001). Although, mechanical failure rates are low, manufacturers provided some improvements in the design of prostheses to achieve more successful outcomes. Five year freedom from mechanical failure rates reached over 90% after these improvements. More recently, Dhar et al. reported the long-term results of 455 patients who underwent penile prosthesis implantation with AMS 700 CX and found out that the overall freedom from reoperation was 74.9% and from mechanical failure was 81.3% after ten years (Dhar NB, et al 2006). A large-scale study performed with 2384 patients who had undergone penile prosthesis implantation with four different implant types reported revision-free survivals for all reasons to be 68.5% at 10 years and 59.7% at 15 years. For freedom from mechanical failure, the results were 79.4% at 10 years and 71.2% at 15 years (Wilson SK, et al. 2007). In another recently published, long-term study, Kim et al. reported the mechanical reliability results of AMS 700CX/CXM in 397 men with mean age of 63.1 years and follow-up duration of 113 months (Kim et al 2010). Mechanical survival rates of the prostheses were 97.6%, 93.2% and 78.2% at 3, 5, and 10 years after implantation, respectively. It is also reported that the overall survival of implants were significantly lower in patients with neurogenic ED when compared to non-neurogenic ones which may be due to decreased glandular sensation and difficulty in having natural position during sexual intercourse.

Infection is the bane of penile prosthesis surgery because, if it occurs in the space around the implant, total removal of all prosthetic material will be needed. Penile prosthesis reimplantation is more difficult due to corporal fibrosis in these patients.

A number of measures have been taken to decrease the risk of infection in prosthesis implanted patients. The most popular approach to reduce the rate of infection is the impregnation of antibiotics to the surface of prosthetic devices. Initial research suggests these newer interventions decrease the rate of prosthetic infection. With antibiotic prophylaxis, the infection rate is 2-3% and may be further reduced by using an antibiotic impregnated or hydrophilic-coated implant. Recently, Carson et al. reported the results of the retrospective comparison of the initial revision events due to infection in patients who underwent antibiotic impregnated or non-impregnated implantation with a follow-up of 7.7 years. At the end of follow-up, it is determined that initial revision rates due to infection were significantly lower in the impregnated group (Carson CC 2011). In another study, the antimicrobial activity of InhibiZone-coated IPPs produced by AMS was compared with the Titan hydrophilic-coated implants (produced by Coloplast) dipped in vancomycin, in both in-vivo and in-vitro animal models (Mansouri MD, et al 2009). The antimicrobial activity of the two implants was also compared against a control. In-vivo zones of inhibition were compared for each group against methicillin-resistant *Staphylococcus aureus* (MRSA), methicillin-resistant *S. epidermidis* (MRSE), vancomycin-resistant *Enterococcus* (VRE), and *Escherichia coli*. It is found that the InhibiZone-treated implants produced a larger zone of inhibition



against MRSA, VRE, and E. Coli when compared with the vancomycin-dipped Titan implant and control and zones of inhibition were equivalent for MRSE in both implants. Similar results were obtained in animal models. Authors concluded that InhibiZone prostheses have a broader spectrum in vitro and a more durable antimicrobial activity in vitro and in an animal model than implants dipped in vancomycin. Therefore, the use of InhibiZone implants may help reduce the incidence of penile implant infection.

The use of prophylactic broad spectrum antibiotics is widespread in penile prosthetic surgery; however, the timing of the administration of these antibiotics varies among different studies. According to the guidelines “infusion of the first antimicrobial dose should begin within 60 minutes before surgical incision and that prophylactic antimicrobials should be discontinued within 24 hours after the end of surgery”. It is well-known that infection rates in revision penile prosthetic surgery have been higher than primary implant surgery. During the revision surgery, the entire device is removed and the implant spaces are lavaged with multiple antiseptic solutions before implantation of a new device, the infection rate is similar to that with first time (primary) penile prosthesis implantation (Henry GD, et al 2005). Mulcahy et al. reported an 82% success rate achieved by using salvage therapy which involves removal and reimplantation immediately following thorough irrigation of the corpora with a multiantibiotic solution (Mulcahy et al 1996). More recently, the success rate increased to 84% in 101 patients who had infected implants (Mulcahy et al 2003). The salvage protocol described by Mulcahy should be performed in a stepwise fashion which consists of the removal of all prosthetic parts and foreign material, irrigation of wound and all compartments with 7 antiseptic solutions, changing operative equipment such as gloves, drapes and implantation of new prosthesis, closing the wound primarily without any drain and prescribe oral antibiotics according to culture for one month. The 7 antiseptic solution contains kanamycin and bacitracin, half strength hydrogen peroxide, half strength povidone iodine, water pic pressure irrigation with 1 gm vancomycin and 80 mg gentamicin in 5 liters, half strength povidone iodine, half strength hydrogen peroxide, kanamycin and bacitracin.

Autoinflation of a three-piece device may cause discomfort for the patient. In a study, the rate of autoinflation was reported between 3-5% (Hollenbeck BK et al 2002).

In order to prevent auto-inflation, Mentor developed a lockout valve mechanism that is added to prosthetic reservoir stem. This mechanism decreased the risk of autoinflation by transferring the fluid from reservoir in response to negative pressure from the pump (Wilson SK, et al 2002). Autoinflation risk decreased to the rate of 1.3% after this modification.

Coloplast developed Coloplast Titan One-Touch Release (OTR) pump to make device deflation easier for the patient. The new OTR pump allows cylinder deflation with one firm squeeze to the release pads. One firm squeeze of these pads causes the deflate valve to shift into the open position, providing a new pathway for fluid flow from the cylinders to the reservoir. In a recent study, Shaw et al assessed the functionality and surgeon experience with 100 consecutive patients implanted with a Titan OTR pump, compared with 100 prior consecutive patients implanted with a Titan Genesis pump (Shaw et al.2011). At the end of a mean length of follow-up of 20.8 months in the Genesis group and 8.4 months in the OTR group, the average number of postoperative teaching sessions needed to teach the patient how to operate the device was significantly lower in the OTR group (1.87 vs. 1.19). It is also reported that no pump malfunctions were seen in either group and the OTR pump was



subjectively easier for the surgeon and the patient to deflate when compared with the Genesis pump.

Reservoir complications are not commonly encountered, however, they include herniation into inguinal canal and upper scrotum or erosion into adjacent viscera. Reservoir herniation is a rare complication that occurs in approximately 0.7% of three-piece inflatable prosthesis surgery cases (Sadeghi-Nejad et al. 2001). This complication is exclusively limited to cases when the penoscrotal approach is used. It may be caused by vigorous postoperative coughing or failure of proper initial reservoir placement under the transversalis fascia. Reservoir protrusion through an unrecognized existing hernia or a large transversalis defect created intraoperatively are other possible contributory factors. Decreased spontaneous autoinflation of the cylinders in the immediate postoperative period may result in a lower incidence of this adverse event. Correction of this complication is by revision through an inguinal incision with placement of the reservoir in its proper position and repairing the defect (Hellstrom WG, et al.2010).

Some patients may suffer from poor support of the glans by the tips of the prosthesis. This angulation of the glans penis is called as the supersonic transport (SST) deformity because of the similarity of its appearance to the supersonic transport of aircraft. This deformity may develop secondary to small-size prosthesis or incomplete distal dilation of the corpora. If the problem occurs during the operation, following the achievement of adequate distal dilation, a larger rear-tip extender may be placed to lengthen the cylinder and see whether the defect is corrected. If the problem is noted in the immediate postoperative period, it is wise to wait a few weeks and allow for complete healing and scar formation, which may result in glans fixation and resolution of the SST deformity (Carson C. 1999)

Device extrusion may develop as an isolated finding or may be a sign of the device infection. Semirigid prosthesis are more prone to erosion, as the rate was reported as 18.1% for semirigid prostheses, 2.4% for self contained inflatable and 0% for 3-piece inflatable ones (Zermann et al 2006). Distal cylinder extrusion can be corrected by preparing a new cavity for the distal cylinder behind the back wall of the fibrotic sheath containing it (Mulcahy JJ. 1999). An alternative technique is to perform distal corporoplasty using synthetic material. Proximal perforation of the crura during the implant procedure can be repaired by the constructing wind sock of vascular prosthetic material and anchoring this to the prosthesis. More recently, Shindel et al described a novel technique of transglanular repair of the impending distal erosion of penile prostheses and reported successful outcomes in 4 of 6 patients during the follow-up (Shindel et al. 2010).

## 2.7 Outcomes of penile prosthesis surgery

Different from other treatments of ED, inflatable prostheses allow men to achieve a rigid erection on demand and as often as desired and also allow them to maintain the erection for a long period of time. Men with ED may develop performance anxiety and loss of confidence in their sexual capabilities, however, implantation of penile prosthesis may restore both erectile capacity and men's sexual confidence and provides the best results among all ED treatment modalities in terms of satisfaction.

In a study performed with 138 ED patients, the satisfaction rates were found to be significantly higher in patients treated with penile prosthesis implantation when compared

with patients treated with sildenafil and intracavernous prostoglandin E1(Rajpurkar et al 2003). There are various studies that reported high satisfaction rates for both patients and partners after penile prosthesis implantation for the treatment of ED. Montorsi et al reported the results of 200 consecutive patients who underwent prosthetic surgery with 3-piece inflatable implants and reported a 98% patient and 96% partner satisfaction rate. Authors noted that the major factors that contribute to these high satisfaction rates are the rapid ability of the implants to produce an erection and consistent excellent rigidity (Montorsi et al 2000). However, loss of penile length which is likely to occur in revision surgeries after infection or penile shortening in Peyronie's disease may result in much lower satisfaction rates (Montorsi et al 1996).

There are many factors that may influence the patient satisfaction, such as postoperative pain and edema, occurrence of postoperative complications, cosmetic outcome, functional integrity of the device, ability to use and partner acceptance. Apart from these factors, reduced sensitivity, diminished sexual drive, unnatural feeling and perception of having a diminished role in initiating erection by the partner may be accepted as the other reasons of dissatisfaction. In a study performed by Akin-Olugbade et al over 114 penile prosthesis recipients, all patients showed significant improvement in IIEF and EDITS scores, however, patients with Peyronie's disease, body mass index over 30 and who underwent radical prostatectomy had lower satisfaction rates than the overall group. It should be kept in mind that these men have shorter penile length and failure of the implants to restore this length loss may contribute to increased rate of dissatisfaction (Akin-Olugbade et al 2008). High complication rates and unrealistic expectations are the other reasons of this low satisfaction rate.

More recently, Natali et al reported the results of 200 patients who underwent penile prosthesis implantation with AMS 700 CX, AMS Ambicor and AMS 600-650 with a mean follow-up of 5 years and found out a patient satisfaction rate of 97%, 81% and 75%, respectively (Natali et al 2008). In the same study, partner satisfaction rate was reported as 92%,91% and 75%, respectively. In another case series, 41 of 42(97.6%) patients reported successful intercourse after penile prosthesis implantation (Xuan XJ et al 2007). Paranhos et al reported the outcomes of 139 patients who underwent penile prosthesis implantation with a mean follow-up of 40 months (Paranhos et al 2010). The overall satisfaction rate was 86.3% for patients and 83.4% for partners at the end of the follow-up. In a recently performed study, Bettocchi et al evaluated 80 patients who underwent prosthesis surgery and reported that seventy-six patients (97%) affirmed to use penile prostheses frequently. Fifty-four patients (69%) and 70 partners (90%) affirmed that they never had problems with the use of the prosthesis and they considered themselves satisfied. Outcomes of these studies of penile prosthesis implantation concerning patient and partner satisfaction are summarized in table-1.

### **3. Penile arterial revascularization**

Penile microarterial bypass surgery which was first described by Michal, is considered as a milestone in the treatment of ED because it is accepted as the only treatment option that is capable of restoring normal erectile function without the need of using any external mechanical (vacuum erection) devices, vasoactive medications or surgical placement of

Author	Year of publication	No of pts	Patient satisfaction rate	Partner satisfaction rate	Implant type/Comment
Montorsi et al	2000	200	98%	91%	AMS 3-piece implant
Xuan et al	2007	42	97.6%	NA	Patients who achieve coitus
Natali et al	2008	62/98/40	97%/81%/75%	92%/91%/75%	AMS 700CX/Ambicor/600-650
Knoll et al	2009	69	86%	NA	AMS 700 Momentary squeeze
Paranhos et al	2010	139	86.3%	83.4%	RP and DM as negative predictors of satisfaction
Bettocchi et al	2010	80	97%	90%	AMS 700 CX

Table 1. Outcomes of the penile prosthesis procedures

penile prosthesis (Michal 1973). The objective of the surgery is to bypass arterial lesions that cause obstruction in the hypogastric-cavernous arterial bed (Hellstrom WJ, et al. 2010). Specifically, this surgery aims to increase the cavernosal arterial perfusion pressure and blood inflow in patients with vasculogenic ED that is developed due to pure arterial insufficiency. Lack of standardization in patient selection, hemodynamic evaluation and surgical technique as well as limited long-term outcome data using validated instruments have resulted in this surgery being considered by many surgeons as an experimental procedure. However, guidelines recommended that this type of surgery is proposed only to men with recently acquired ED secondary to focal arterial lesions and with the evidence of no existing generalized vascular disease. Additionally long operation time and the requirement for microsurgical expertise resulted in less frequent use of penile revascularization procedures. The efficacy of this surgery is still controversial and not evidence-based, largely because the selection criteria, outcome measurements, and microsurgical techniques have not been objective or standardized. The patients who are candidates for MABS (microarterial by-pass surgery) should fulfill some criteria such as age younger than 55 years with recently acquired ED due to focal occlusive disease of the common penile or cavernosal arteries detected by penile Doppler ultrasound, cavernosometry and selective internal pudendal arteriography. The patients who have vascular risk factors (diabetes, hypertension, tobacco use, hypercholesterolemia), evidence of neurological ED (eg multiple sclerosis, pelvic surgery, lumbosacral radiculopathies etc), nontreated hormonal abnormalities, psychiatric disorders (severe depression, bipolar disease, schizophrenia), Peyronie's disease, premature ejaculation and any evidence of corporo-occlusive dysfunction should not be considered as a candidate for this type of surgery. Young men who have sustained traumatic arterial lesions appear to have better outcomes compared to elderly patients.

Historically, Michal et al who reported the first MABS, performed a direct anastomosis between the inferior epigastric artery (IEA) and the corpus cavernosum (Michal I) which provided a sufficient flow rate and intraoperative erection. However, this procedure resulted in anastomotic stenosis in all patients and unsatisfactory success rates. Consequently, they performed the anastomosis between the IEA (end-to-side) and the dorsal penile artery (DPA) and achieved a success rate of 56% (Michal II)( Michal et al 1980).

Virag et al. performed the anastomosis between the IEA to the deep dorsal vein in order to increase penile perfusion in a retrograde fashion and reported a 49% success rate and an additional 20% improvement (Virag et al 1981). Furlow et al. also performed arterialization procedures of the dorsal vein with ligation of the circumflex branches to avoid glanular hyperemia, with success rates of 62% (Furlow et al 1988). Hauri reported a complicated side-to-side anastomosis between the dorsal artery and vein covered by a spatulated IEA that resulted in success rates of 80% (Hauri 1984)

MABS techniques that are currently defined include an anastomosis between the IEA to the dorsal vein (arterialization) or artery (revascularization). Artery-to-vein procedures are easier to perform than artery-to-artery, however, the failure rates are higher due to some reasons such as that the dorsal vein has valves that most likely impair penile reperfusion and may be associated with anastomotic thrombosis. Also, the use of a valvulotome may improve retrograde reperfusion to the corpora, but may also cause endothelial injury, which may activate the intrinsic pathway of the clotting system, leading to early thrombosis and failures. Finally, artery-to-artery MABS eliminates the possibility of penile hyperemia. Munarriz et al reported the long-term results of the patients who underwent MABS and although not supported by their data, they favor a MABS with the anastomosis between IEA- and the dorsal artery(Munarriz et al 2009).

MABS has three steps which include dorsal artery dissection, IEA harvesting, and microsurgical anastomosis (Munarriz et al 2004).

1. Dorsal artery dissection is performed via a 5-cm semilunar incision 2 cm below the penoscrotal junction. While the penis is stretched, blunt dissection is carried out along Buck's fascia towards the glans to invert the penis. The fundiform ligament is identified and preserved to minimize penile shortening. The selected dorsal artery is isolated and mobilized proximally, avoiding injury of the dorsal nerves. Temporary scrotal closure is performed.

2. Harvesting of IEA begins with a 5-cm transverse incision between umbilicus and pubis. Dissection is carried down through Scarpa's fascia, the rectus fascia is divided vertically, and the rectus muscle mobilized medially. The IEA is identified and mobilized from its origin at the level of the common external iliac artery to the umbilicus. If arterial branches are found, they are controlled with bipolar cautery and divided. During the mobilization of the IEA, papaverine is utilized to prevent vasospasm. The distal end of the IEA is clipped near the umbilicus and divided. Subsequently, the scrotal staples are removed and a clamp is utilized to transfer the IEA to the dorsal aspect of the penis through the external inguinal ring. The abdomen is closed in a multilayer fashion using a running technique with 0 polyglycolic acid suture for the rectus fascia, 2-0 for Scarpa's, and a 4-0 monocril for the skin.

3. *Microvascular Anastomosis:* The dorsal artery is mobilized and divided in a proximal location on the penile shaft. The proximal end is cauterized using the bipolar cautery.

Aneurismal clips are placed on the dorsal artery and IEA. The adventitia of the distal end of the IEA and proximal dorsal artery is sharply excised with microscissors to prevent thrombosis of the anastomosis. A microsurgical anastomosis is performed using a simple interrupted technique with 10-0 Nylon stitches. The dorsal aneurismal clip is removed and back blood flow is observed, documenting anastomotic patency. The IEA aneurismal clip is removed and if there is no anastomotic leak, the penis is placed back on its normal anatomical position, the Dartos closed with a running 2-0 polyglycolic acid suture, and the skin with a 4-0 polyglycolic acid suture. Patency of the anastomosis is further confirmed by Doppler ultrasound.

### 3.1 Complications of the penile revascularization surgery

Penile shortening and decreased penile sensitivity may be observed in up to 25% of the patients after the procedure (Munarriz 2010). It is thought that penile shortening is the result of fibrosis/scarring of the fundiform ligament and its incidence may be minimized by the preservation of this ligament during the procedure. Decreased penile sensation is mostly seen due to a denervation injury during surgery, however, patients who underwent this operation may still report improvement in their orgasmic function. Glans hyperemia is another commonly observed complication with a rate of 13% in some series (Manning M, et al 1998). Other less common complications are wound infection and inguinal hernia.

### 3.2 Outcomes of penile revascularization surgery

Generally, the studies reporting the results of penile revascularization surgery are retrospective, had small numbers of patients, short term follow-up, variable patient selection criteria and type of surgery. To make a standardization and proper evaluation of these studies published, however, AUA guidelines recommend some inclusion criteria such as presence of a normal serum testosterone level, failure of pharmacologic erection test, abnormal nocturnal penile tumescence or penile duplex Doppler ultrasonography, abnormal penile arteriogram, artery to artery or artery to dorsal vein anastomosis employed in surgical technique, objective follow-up data reported by either duplex Doppler ultrasonography, penile arteriogram, or validated outcome questionnaire in the absence of diabetes mellitus and history of smoking. Also the follow-up period of studies to be included should at least have a period of 12 months. There are only four studies fulfilling these criteria which report variable success rates with different surgical techniques (Table-2).

Author	Type of surgery	No of pts	Months of follow-up: overall (mean)	Success Rate% (N) Success	Criteria
Ang (1997)	Dorsal vein	6	8-37(20)	66 (4)	NPT,Doppler
De Palma (1995)	Dorsal artery	11	12 to 48	60% (7)	Doppler
Grasso (1992)	Dorsal artery	22	12 months for all	68 (15) 36 (8)	NPT, Doppler
Jarow (1996)	Mixed	11	12 to 84 (50)	91 (10)	Doppler
Munarriz (2010)	Dorsal artery	71	NA(34.5)	88.7% (63)	IIEF

Table 2. Outcomes of the penile revascularization procedures



Apart from these studies, Kawanishi et al. reported the results of 51 men with arteriogenic ED who had objective outcome data reported by color Doppler duplex studies and a longer follow up period (Kawanishi et al 2004). The patency of the neoarterial blood flow either by the Hauri or Furlow-Fischer procedure was assessed objectively by color flow duplex Doppler. The authors reported the objective estimated efficacy rate as 84.9 % at 3 and 65.5% after 5 years of follow-up.

Although guidelines do not recommend this kind of procedures in elderly people, Kayigil et al reported the results of deep dorsal vein arterialization (DDVA) in 43 carefully selected healthy elderly patients with a mean follow-up of 22 months (Kayigil et al 2008). All patients underwent DDVA using the Furlow-Fisher technique. Surgical outcome was tested postoperatively by IIEF score. The success rate of the operation was 60.5% at the end of follow-up. More recently, Kayigil et al reported the long-term results (73.2 months) of 110 men who underwent revascularization surgery and reported an overall success rate of 72% (Kayigil et al 2011). The success rates were 81.8% at 3 months, 77.2% at 1 year, 70% at 2 years, 66.3% at 3 years, and 63.6% at 5-year after surgery in the patients who achieved a no-ED threshold score of more than 26 in the IIEF-15. Authors concluded that this procedure may serve as a better alternative to prosthesis surgery by using a physiological restoration mechanism further studies are needed to compare the outcomes of different treatment modalities.

Recently, Babei reported a systematic review and metaanalysis to determine the results of patients with arteriogenic ED who underwent penile revascularization surgery. Characteristics of participants, study qualities, types of interventions, cure rates and adverse events were analyzed. Outcomes of procedures were found to be better in men younger than 30 years old and in men with the absence of venous leakage and history of smoking. In conclusion, the authors noted that inconsistent measurements of outcomes limited the findings, and none of the studies were randomized controlled trials. Authors also concluded that this kind of procedures may be beneficial in highly selected patients, however, randomized-controlled trials examining penile revascularization techniques are needed to recommend one technique over another (Babei et al 2009).

Robot-assisted vessel harvesting for penile revascularization is a new surgical approach in patients who suffered pelvic crush injuries resulting in post-traumatic ED. Raynor et al. reported five patients that underwent penile revascularization using a modified Virag-V technique (Raynor et al. 2010). The epigastric artery was harvested robotically and transposed through a 3 cm incision at the base of the penis. Microscopic revascularization was performed by anastomosing the epigastric artery to the deep dorsal vein. Distal dorsal vein ligation of the subcoronal plexus was performed to prevent glans hyperemia. The procedure was successful in 4 patients. Authors concluded that this procedure is an ideal minimally invasive complement to penile revascularization which may shorten operation time and offer a novel option for the use of minimally-invasive technology.

#### **4. Surgical treatment of Corporal Venous Occlusive Dysfunction (CVOD)**

Cavernous venous occlusive dysfunction is another type of ED which may result from congenital reasons or trauma in young men, and acquired factors such as Peyronie's disease, diabetes mellitus and late onset hypogonadism in older men.

Pathophysiology of venogenic ED (VED) consists of formation of large venous channels draining the corpora cavernosa, degenerative changes to the tunica albuginea, structural alterations of the cavernous smooth muscle and endothelium (Ghanem et al 2008). Whatever the cause is, the objective of the treatment is to obstruct this leakage. It is found out that the deep dorsal vein is the major site of venous leakage in more than 75% of cases (Fuchs et al.1989).

Surgical treatment for VED should be considered when medical treatment fails to provide sufficient erection. Selection criteria for surgery include the patients with erections of short duration or tumescence only with sexual stimulation; younger than 50 years; normal cavernous arterial inflow in response to an intracavernous injection agent; and who are more likely to have venous leakage after performing Doppler ultrasound or penile cavernosography in the absence of chronic systemic diseases (Manning M et al 1998).

Surgery for penile venous leakage is not recommended in older men because penile venous leakage often results from atrophy of the intracorporeal muscles or the tunica albuginea (Lue TF 1999, Montague DK, et al 1996). However, when venous leakage is congenital, the deficiency is usually in the large, ectopic, superficial and deep dorsal veins or the large crural veins (Lue TF, 1999, Ebbehøj et al. 1979). Currently, there is no evidence from randomized controlled trials to recommend a standardized approach for the diagnosis and effective treatment of veno-occlusive ED. Since it is generally accepted that venous leakage is an effect rather than a cause, and newer pathophysiologic mechanisms that cause CVOD and therapeutic possibilities that might address these causes, are being examined. Research continues to detect an effective surgical treatment alternative.

Although there is no standard evidence-based surgical option, ligation of superficial dorsal vein, deep dorsal vein, crural vein, crural plication/ ligation, arterialization of deep dorsal or cavernosal veins or extraperitoneal laparoscopic penile vein ligation are some of the intervention types used in CVOD surgery.

Recently, Cayan et al reported the results of a study including 26 men with a mean age of 34, who underwent penile venous surgery for primary venous leakage with a mean follow-up of 42 months (Cayan 2008). Surgical procedure consists of resection of the superficial and deep dorsal veins, ligation of the cavernous vein and 2 crura proximal to the entrance of the cavernous artery with umbilical tapes, and preservation of the dorsal artery and nerve on each side. In the follow-up, erectile function improved in 19 men and remained unchanged in 7 men. Patient satisfaction with no additional treatment or with phosphodiesterase-5 inhibitors was 88.4% and only 3 patients were unsatisfied with the surgery. It is concluded that penile venous surgery with crural ligation for venous leakage has excellent long-term results, high patient satisfaction rate and should be offered to young men with primary cavernous ED. Additionally, young patients who have normal penile arterial system and no risk factors such as diabetes are the best candidates for the improved postoperative outcome. Since the surgery of ligation or resection for venous leakage has not been very successful and unsatisfactory long-term results have reduced the indications for venous surgery, a new technique which is the embedding of dorsal vein for dorsal venous leakage is reported to improve the long-term outcomes (Zhang et al 2009). The procedure is performed through a curved incision made over the root of the penis. Following the dissection of deep dorsal vein, a whole thickness tunica albuginea excision of about 0.8 cm was performed and the dissected vein is embedded to this newly formed groove. At the end of 42 months of

average follow-up, 14 of 17 patients reported satisfactory intercourse and three had sufficient erection after oral treatment. Besides, it was also noted that there were significant improvements in terms of IIEF-5 scores and some Doppler USG parameters in all patients. According to these results, authors concluded that this new surgical technique is a simple operation which seems to provide promising results with the need of future studies in the treatment of penile deep dorsal venous leakage of ED.

Possible complications that may be encountered in the post-operative period include wound infection, skin necrosis, glandular hyperemia or hypoesthesia, inguinal hernia, penile curvature, shortening or edema.

If CVOD surgery is going to be performed, a long-term follow-up of at least 48 months is recommended with the use of pre and postoperative validated scales (e.g. IIEF). Post-operative follow-up should include objective evaluation of the penile vascular and erectile status. Penile color duplex ultrasound after complete cavernosal smooth muscle relaxation is the gold standard investigation of choice for both pre-op and post-op objective assessment.

The type of operation offered to the patient should be determined depending on the experience and preference of the surgeon and the basis of the site, nature, and size of the leak.

## 5. Conclusion

Penile prosthesis implantation is currently the most effective treatment option in terms of both patient and partner satisfaction in the management of ED. Satisfaction rates and prosthesis survival significantly increased with the improvements in both prosthesis design and surgical techniques. Among prosthesis types, inflatable 3-piece prosthesis have the best outcomes and recommended for younger patients with normal manual dexterity, patients with Peyronie's disease, neurological disorders, patients who underwent radical prostatectomy and in revision procedures. Preoperative preparation and use of antibiotic impregnated devices during surgery are the essential points to reduce the risk of prosthesis infection. The ideal prosthesis aims to mimic natural erection and flaccidity as well as possible and research to find the ideal prosthesis still continues. Further technological improvements may provide additional significant increases in satisfaction and survival rates and decrease the number of infected implants. Penile revascularization is not a commonly performed procedure and its use is limited only to selected cases because of the variabilities in inclusion and exclusion criteria, short length of follow-up, and lack of objective follow-up data. However, patients who are younger than the age of 55, non-smoker, non-diabetic with the absence of venous leakage may have a better outcome after the procedure. Penile venous surgery is not a recommended surgical treatment modality due to absence of a standardized surgical technique and follow-up data. This operation may only be recommended for young patients with site-specific congenital, posttraumatic or post-inflammatory venous leaks with informed consent. The type of the operation for each particular patient should be decided according to experience of surgeon, site, size and nature of the venous leak.

## 6. References

Akin-Olugbade O, Parker M, Guhring P, Mulhall J.(2006) Determinants of patient satisfaction following penile prosthesis surgery. *J Sex Med Jul*: 3:743-8

- Ang LP, Lim PH. Penile revascularisation for vascular impotence. (1997) *Singapore Med J.* Jul: 38:285-8
- AUA Guidelines. Management of Erectile Dysfunction (2005)
- Babei AR, Safarinejad MR, Kolahi AA. (2009) Penile revascularization for erectile dysfunction: a systematic review and meta-analysis of effectiveness and complications. *Urol J.* Winter: 6:1-7
- Bettocchi C, Palumbo F, Spilotros M, Lucarelli G, Palazzo S, Battaglia M, Selvaggi FP, Ditunno P. (2010) Patient and partner satisfaction after AMS inflatable penile prosthesis implant. *J Sex Med.* Jan;7(1 Pt 1):304-9.
- Bogoraz. (1936) On complete Plastic reconstruction of a penis sufficient for Coitus (in Russian). *Soviet Surgery (Sovetskaya).* 8:303-9
- Carson C, Giuliano F, Goldstein I, Hatzichristou D, Hellstrom W, Lue T et al. (2004) The 'effectiveness' scale – therapeutic outcome of pharmacologic therapies for ED: an international consensus panel report. *Int J Impot Res* 16: 207–213.
- Carson C. (1999) Complications of penile prostheses and complex implantations. In: Carson C, Kirby R, Goldstein I, eds. *Textbook of male erectile dysfunction.* Oxford, UK: Isis Medical Media. 435–50.
- Carson CC, Mulcahy JJ (2011) *J Urol.* Long-term infection outcomes after original antibiotic impregnated inflatable penile prosthesis implants: up to 7.7 years of followup.
- Carson CC, Noh CH. (2002) Distal penile prosthesis extrusion: treatment with distal corporoplasty or Gortex windsock reinforcement. *Int J Impot Res.* Apr: 14:81-4
- Carson CC. (2005) Penile prosthesis implantation: surgical implants in the era of oral medication. *Urol Clin North Am.* Nov: 32:503-9, vii
- Cayan S. (2008) Primary Penile Venous Leakage Surgery With Crural Ligation in Men With Erectile Dysfunction. *J Urol.* 180, 1056-1059.
- Cuellar DC, Sklar GN. (2001) Penile prosthesis in the organ transplant recipient. *Urology* 57:138–41.
- Daitch JA, Angermeier KW, Lakin MM, Ingleright BJ, Montague DK. (1997) Long-term mechanical reliability of AMS 700 series inflatable penile prostheses: comparison of CX/CXM and Ultrex cylinders. *J Urol.* Oct: 158:1400-2
- Darouiche RO, Smith JA, Jr., Hanna H, et al. (1999) Efficacy of antimicrobial-impregnated bladder catheters in reducing catheter-associated bacteriuria: a prospective, randomized, multicenter clinical trial. *Urology.* Dec: 54:976-81
- DePalma RG, Olding M, Yu GW, et al. (1995) Vascular interventions for impotence: lessons learned. *J Vasc Surg.* Apr: 21:576-84; discussion 84-5
- Deuk Choi Y, Jin Choi Y, Hwan Kim J, Ki Choi H. (2001) Mechanical reliability of the AMS 700CXM inflatable penile prosthesis for the treatment of male erectile dysfunction. *J Urol.* Mar: 165:822-4
- Dhar NB, Angermeier KW, Montague DK. (2006) Long-term mechanical reliability of AMS 700CX/CXM inflatable penile prosthesis. *J Urol.* Dec: 176:2599-601; discussion 601
- Ebbehoj J and Wagner G. (1979) Insufficient penile erection due to abnormal drainage of cavernous bodies. *Urology* 13:507.
- Fuchs AM, Mehringer CM, Rajfer J. (1989) Anatomy of penile venous drainage in potent and impotent men during cavernosography. *J Urol* 141:1353–6.
- Furlow, W.L. and Fisher, J. (1988) Deep dorsal vein arterialization: clinical experience with a new technique for penile revascularization. *J. Urol.* 139, 298A, Abstr. 543




- Garaffa G, Moncada I, Ralph DJ. (2010) Surgical management of erectile dysfunction. *Arch Esp Urol*.63;8: 728-738.
- GE B. (1964) Surgical Treatment of Impotence. *Plast Reconst Surg*. 34:71-3
- Ghanem H, Shamloul R. (2008) An evidence-based perspective to commonly performed erectile dysfunction investigations. *J Sex Med*. 5:1582-9.
- Govier FE, Gibbons RP, Correa RJ, Pritchett TR, Kramer-Levien D.(1998) Mechanical reliability, surgical complications, and patient and partner satisfaction of the modern three-piece inflatable penile prosthesis. *Urology*. Aug; 52:282-6
- Grasso M, Lania C, Castelli M, Deiana G, Francesca F, Rigatti P. (1992) Deep dorsal vein arterialization in vasculogenic impotence: our experience. *Arch Ital Urol Nefrol Androl*. Dec: 64:309-12
- Hatzimouratidis K, et al. (2010) Guidelines on Male Sexual Dysfunction: Erectile Dysfunction and Premature Ejaculation. *Eur Urol* 57:804-814.
- Hauri, D. (1984) Therapiemoglichkeiten bei der vascular bedingten erectilein impotenz. *Akt. Urol*. 15, 350
- Hellstrom WJ, Montague DK, Moncada I, Carson C, Minhas S, Faria G, Krishnamurti S. (2010) *J Sex Med*. Jan;7(1 Pt 2):501-23.
- Henry GD WS, Delk JR. (2004) Early results with new ribs and pads AMS 700 pump: Device instruction easier. *J Sex Med*. 1:81
- Henry GD, Wilson SK, Delk JR, 2nd, et al. (2005) Revision washout decreases penile prosthesis infection in revision surgery: a multicenter study. *J Urol*. Jan: 173:89-92
- Hollenbeck BK, Miller DC, Ohl DA. (2002)The utility of lockout valve reservoirs in preventing autoinflation in penile prostheses. *Int Urol Nephrol*.34:379-83
- Jarow JP, Defranzo AJ. (1996) Long-term results of arterial bypass surgery for impotence secondary to segmental vascular disease. *J Urol*. 156:982-5.
- Kawanishi Y, Kimura K, Nakanishi R, Kojima K, Numata A. (2004) Penile revascularization surgery for arteriogenic erectile dysfunction: the long-term efficacy rate calculated by survival analysis. *BJU Int*. Aug; 94:361-8.
- Kayigil O, Agras K, Okulu E. (2008)Is deep dorsal vein arterialization effective in elderly patients? *Int Urol Nephrol*. 40:125-31
- Kayigil O, Okulu E, Aldemir M, Onen F. (2011)Penile revascularization in vasculogenic erectile dysfunction (ED): long-term follow-up. *BJU Int*.
- Kim DS, Yang KM, Chung HJ, Choi HM, Choi YD, and Choi HK. (2010) AMS 700CX/CXM inflatable penile prosthesis has high mechanical reliability at long-term follow-up. *J Sex Med* 7:2602-2607
- Laumann EO, Nicolosi A, Glasser DB, Paik A, Gingell C, Moreira E et al. (2005) Sexual problems among women and men aged 40-80 y: prevalence and correlates identified in the Global Study of Sexual Attitudes and Behaviors. *Int J Impot Res*;17: 39-57.
- Levine LA, Estrada CR, Morgentaler A. (2001) Mechanical reliability and safety of, and patient satisfaction with the Ambicor inflatable penile prosthesis: results of a 2 center study. *J Urol*. Sep: 166:932-7
- Lewis RW, Fugl-Meyer KS, Corona G, Hayes RD, Laumann EO, Moreira ED Jr, Rellini AH, Segraves T. (2010) Definitions/Epidemiology/Risk factors for sexual dysfunction. *J Sex Med*. Apr;7(4 Pt 2):1598-607
- Lue TF: Surgery for crural venous leakage. *Urology* 1999; 54: 739.



- Manning M, Junemann KP, Scheepe JR, Braun P, Krautschick A, Alken P. (1998) Long-term followup and selection criteria for penile revascularization in erectile failure. *J Urol.* Nov; 160:1680-4
- Mansouri MD, Boone TB, Darouiche RO.(2009) Comparative assessment of antimicrobial activities of antibiotic-treated penile prostheses. *Eur Urol Dec;56(6):1039-45.*
- Michal V, Kramar R, Pospichal J et al. (1973) Direct arterial anastomosis on corpora cavernosa penis in the therapy of erectile impotence. *Rozhl Chir* 52: 587.
- Michal, V., Kramer, R., and Hejhal, L. (1980) Revascularization procedures of the cavernous bodies. In *Vasculogenic Impotence: Proceedings of the First International Conference on Corpus Cavernosum Revascularization*. Zornio, A.W. and Ross, G., Eds. Charles C Thomas, Springfield, IL. pp. 239-255
- Milbank AJ, Montague DK, Angermeier KW, Lakin MM, Worley SE. (2002) Mechanical failure of the American Medical Systems Ultrex inflatable penile prosthesis: before and after 1993 structural modification. *J Urol.* Jun: 167:2502-6
- Montague DK, Barada JH, Belker AM, Levine LA, Nadig PW, Roehrborn CG et al (1996) Clinical guidelines panel on erectile dysfunction: summary report on the treatment of organic erectile dysfunction. *J Urol* 1996; 156: 2007.
- Montorsi F, Guazzoni G, Barbieri L, et al. (1996) AMS 700 CX inflatable penile implants for Peyronie's disease: functional results, morbidity and patient-partner satisfaction. *Int J Impot Res.* Jun: 8:81-5; discussion 5-6
- Montorsi F, Rigatti P, Carmignani G, et al.(2000) AMS three-piece inflatable implants for erectile dysfunction: a long-term multi-institutional study in 200 consecutive patients. *Eur Urol.* Jan: 37:50-5
- Mulcahy JJ. (1999) Distal corporoplasty for lateral extrusion of penile prosthesis cylinders. *J Urol.* Jan: 161:193-5
- Mulcahy JJ. (2003) Treatment alternatives for the infected penile implant. *Int J Impot Res.* Oct: 15 Suppl 5:S147-9
- Munarriz R, Uberoi J, Fantini G, Martinez D, Lee C. (2009) *J Urol.* Microvascular Arterial Bypass Surgery: Long-Term Outcomes Using Validated Instruments Vol. 182, 643-648
- Munarriz, R., Mulhall, J., and Goldstein, I. (2004) Penile arterial reconstruction. In *Glenn's Urologic Surgery*. 6th ed. Lippincott Williams & Wilkins, Philadelphia. pp. 573-581.
- Natali A, Olanas R, Fisch M.(2008) Penile implantation in Europe: successes and complications with 253 implants in Italy and Germany. *J Sex Med.* Jun: 5:1503-12
- Nickel JC, Heaton J, Morales A, Costerton JW. (1986) Bacterial biofilm in persistent penile prosthesis-associated infection. *J Urol.* Mar: 135:586-8
- Paranhos M, Andrade E, Antunes AA, Barbieri ALN, Claro JA, Srougi M.(2010) Penile Prosthesis Implantation in an Academic Institution in Latin America. *Int Braz J Urol* 36 (5): 591-601
- Raad I, Darouiche R, Hachem R, Sacilowski M, Bodey GP. (1995) Antibiotics and prevention of microbial colonization of catheters. *Antimicrob Agents Chemother.* Nov:39:2397-400
- Rajpurkar A, Dhabuwala CB. (2003) Comparison of satisfaction rates and erectile function in patients treated with sildenafil, intracavernous prostoglandin E1 and penile implant surgery for erectile dysfunction in urology practice. *J Urol* 170(1):159-163.

- Rossier AB, Fam BA. (1984) Indication and results of semirigid penile prostheses in spinal cord injury patients: long-term followup. *J Urol*. Jan: 131:59-62
- Sadeghi-Nejad H, Sharma A, Irwin RJ, Wilson SK, Delk JR.(2001) Reservoir herniation as a complication of three-piece penile prosthesis insertion. *Urology*. Jan: 57:142-5
- Sadeghi-Nejad H. (2007)Penile prosthesis surgery: A review of prosthetic devices and associated complications. *J Sex Med* 4:296–309
- Scott FB BW, Timm GW. (1973) Management of erectile impotence. Use of implantable inflatable prosthesis. *Urology*. 2:80-2
- Shaw T and Garber BB. (2011) Coloplast Titan inflatable penile prosthesis with one-touch release pump: Review of 100 cases and comparison with genesis pump. *J Sex Med* 8:310–314.
- Shindel AW, Brant WO, Mwamukonda K, Bella AJ, Lue TF. (2010) Transglanular repair of impending penile prosthetic cylinder extrusion. *J Sex Med*. Aug;7(8):2884-90
- Stewart PS, Costerton JW. (2001)Antibiotic resistance of bacteria in biofilms. *Lancet*;358:135–8.
- Subrini L. (1982) Subrini penile implants: surgical, sexual and psychological results. *Eur Urol*. 8:222-6
- Virag, R., Zwang, G., Dermange, H., and Legman, M. (1981) Vasculogenic impotence: a review of 92 cases with 54 surgical operations. *Vasc. Surg.* 15, 9–16.
- Wilson SK DJ, Henry GO. (2002) Short-term Follow-up for Enhanced American Medical Systems CX Prosthesis. *J Urol*. 169:1333A
- Wilson SK DJ. (1996) Scrotal hematoma prevention following penile prosthesis implantation; to drain or not to drain. *J Urol*. 155:634A
- Wilson SK, Cleves M, Delk JR, 2nd.(1996) Long-term results with Hydroflex and Dynaflex penile prostheses: device survival comparison to multicomponent inflatables. *J Urol*. May: 155:1621-3
- Wilson SK, Cleves MA, Delk JR, 2nd.(1999) Comparison of mechanical reliability of original and enhanced Mentor Alpha I penile prosthesis. *J Urol*. Sep: 162:715-8
- Wilson SK, Delk JR, Salem EA, et al. (2007)Long-term survival of inflatable penile prostheses: single surgical group experience with 2,384 first-time implants spanning two decades. *J Sex Med* 4:1074–9
- Wilson SK, Henry GD, Delk JR, Cleves MA. (2002)The Mentor Alpha I penile prosthesis with reservoir lock-out valve: effective prevention of auto-inflation with improved capability for ectopic reservoir placement. *J Urol*.168:1475-8.
- Xuan XJ, Wang DH, Sun P, Mei H.(2007) Outcome of implanting penile prosthesis for treating erectile dysfunction: experience with 42 cases. *Asian J Androl*. Sep: 9:716-9
- Zermann DH, Kutzenberger J, Sauerwein D, Schubert J, Loeffler U. (2006) Penile prosthetic surgery in neurologically impaired patients: long-term followup. *J Urol*. Mar: 175:1041-4; discussion 4



## **Erectile Dysfunction - Disease-Associated Mechanisms and Novel Insights into Therapy**

Edited by Dr. Kenia Nunes

ISBN 978-953-51-0199-4

Hard cover, 214 pages

**Publisher** InTech

**Published online** 29, February, 2012

**Published in print edition** February, 2012

Erectile dysfunction is a widespread problem, affecting many men across all age groups and it is more than a serious quality of life problem for sexually active men. This book contains chapters written by widely acknowledged experts, each of which provides a unique synthesis of information on emergent aspects of ED. All chapters take into account not only the new perspectives on ED but also recent extensions of basic knowledge that presage directions for further research. The approach in this book has been to not only describe recent popular aspects of ED, such as basic mechanism updates, etiologic factors and pharmacotherapy, but also disease-associated ED and some future perspectives in this field.

### **How to reference**

In order to correctly reference this scholarly work, feel free to copy and paste the following:

Faruk Kucukdurmaz and Ates Kadioglu (2012). Surgical Treatment of Erectile Dysfunction, *Erectile Dysfunction - Disease-Associated Mechanisms and Novel Insights into Therapy*, Dr. Kenia Nunes (Ed.), ISBN: 978-953-51-0199-4, InTech, Available from: <http://www.intechopen.com/books/erectile-dysfunction-disease-associated-mechanisms-and-novel-insights-into-therapy/surgical-treatment-of-erectile-dysfunction>

**INTECH**  
open science | open minds

### **InTech Europe**

University Campus STeP Ri  
Slavka Krautzeka 83/A  
51000 Rijeka, Croatia  
Phone: +385 (51) 770 447  
Fax: +385 (51) 686 166  
[www.intechopen.com](http://www.intechopen.com)

### **InTech China**

Unit 405, Office Block, Hotel Equatorial Shanghai  
No.65, Yan An Road (West), Shanghai, 200040, China  
中国上海市延安西路65号上海国际贵都大饭店办公楼405单元  
Phone: +86-21-62489820  
Fax: +86-21-62489821

© 2012 The Author(s). Licensee IntechOpen. This is an open access article distributed under the terms of the [Creative Commons Attribution 3.0 License](#), which permits unrestricted use, distribution, and reproduction in any medium, provided the original work is properly cited.

IntechOpen

IntechOpen