

We are IntechOpen, the world's leading publisher of Open Access books Built by scientists, for scientists

4,800

Open access books available

122,000

International authors and editors

135M

Downloads

Our authors are among the

154

Countries delivered to

TOP 1%

most cited scientists

12.2%

Contributors from top 500 universities



WEB OF SCIENCE™

Selection of our books indexed in the Book Citation Index
in Web of Science™ Core Collection (BKCI)

Interested in publishing with us?
Contact book.department@intechopen.com

Numbers displayed above are based on latest data collected.

For more information visit www.intechopen.com



Diagnostic Value of Dynamic Contrast-Enhanced MRI in Endometrial Cancer

Ting Zhang, Ai-Lian Liu, Mei-Yu Sun, Ping Pan,
Jin-Zi Xing and Qing-Wei Song
*Radiology Department of the First Affiliated Hospital
of Dalian Medical University
China*

1. Introduction

Endometrial cancer is the second most common cancer of the female reproductive organs after cervical cancer in China. The depth of myometrial invasion is the most important factor for treatment selection and prognosis prediction^[1]. Magnetic resonance imaging (MRI) provides high spatial resolution and excellent soft tissue contrast. The contrast of tumors to uterine cavity and myometrium can be further improved with the use of contrast agents and the enhancement features of tumors at different stages can be analyzed quantitatively and dynamically^[5]. However, the relationship between the clinical stages and differentiation degrees of endometrial cancer and the time-intensity curve (TIC) types or the enhancement rates is still not clear on the dynamic contrast-enhanced MRI (DCE-MRI). This study aimed to explore the relationship between the quantitative data of DCE-MRI and the staging of endometrial cancer by investigating the DCE-MRI characteristics of endometrial cancer at different stages, and thus to evaluate the usefulness of the quantitative data and the TIC types of MRI in the diagnosis of endometrial cancer and identification of their degrees of differentiation.

2. Methods

2.1 Cases

A retrospective analysis of 24 patients with endometrial cancer from April 2007 to July 2009 was performed. The diagnosis was confirmed with diagnostic curettage in all patients. The 24 patients received MRI examination in our hospital and of them, 15 patients underwent MRI within 1 week after surgery. The mean age of the patients was 55.8 years, ranging from 28 to 77. Eight patients were pre-menopausal and 16 were post-menopausal. The clinical symptoms included postmenopausal vaginal bleeding in 19 cases, increased vaginal discharge in 2 cases, increased menstrual flow and extended menstrual period in 1 case, and contact bleeding in 2 cases. Informed written consent was obtained from all patients.

2.2 MRI techniques

MRI was performed using GE 1.5T Signa HD Echospeed Superconducting Scanner with body phased-array. Intrauterine device was removed from each patient who had it and all patients were asked to drink about 500 ml water to make the bladder moderate full 1 h before the scanning. Conventional MRI was first performed with the sequences of SE T1-weighted imaging (T1WI) and fat-suppressed FSE T2-weighted imaging (T2WI). DCE-MRI was then performed in 9 patients with horizontal surface fast spoiled gradient echo (FSPGR) sequence and in 15 patients with sagittal liver volume T1-weighted ultra-fast three-dimensional imaging (liver acquisition with volume acceleration, LAVA). MR scanning ranged from the upper edge of the iliac wing to the level of bilateral femoral neck with patients in the supine position. For DCE-MRI, Gd-DTPA contrast agent (0.1 mmol/kg) was given to each patient through antecubital vein using a high-pressure syringe with a flow rate of 2.5 ml/s. Scanning was taken at 16, 32, 48, 64, and 300 seconds (s), respectively, after injection. The scanning parameters were summarized in Table 1.

2.3 Image analysis

2.3.1 Analysis of the tumor characteristics

2.3.1.1 General types

Two types were classified: diffuse type and focal type. Diffuse type was defined as extensive thickening of the uterine endometrium (>3 mm for menopause and >10 mm for premenopausal patients). The focal type was defined as the formation of soft-tissue mass.

2.3.1.2 Invasion depth

Two groups were divided. One group referred to the tumors with no myometrial invasion (intact junctional zone and homogeneous low signal on T2WI) or with superficial myometrial invasion (depth of the myometrial invasion, $\leq 1/2$). Another group referred to the tumors with deep myometrial invasion (myometrial invasion, $>1/2$).

sequence	position	TR (ms)	TE (ms)	thickness (mm)	spacing (mm)	FOV (cm x cm)	matrix	NEX
SE T1WI	axial	400	8	6.0	1.0	32 × 32	320×192	2
fat-suppressed	axial	4000	125	6.0	1.0	32 × 32	320×192	4
FSE T2WI	sagittal	3500	110	5.0	0.5	40 × 40	288×256	4
	coronal	3500	110	5.0	0.5	40 × 40	288×256	4
FSPGR	axial	155	1.4	6.0	1.0	32 × 32	320×192	1
	sagittal	155	1.4	5.0	0.5	40 × 40	288×256	1
	coronal	155	1.4	5.0	0.5	40 × 40	288×256	1
LAVA	sagittal	6.1	1.1	3.0	-3.0	40 × 40	288×256	1

Note: FSPGR: fast spoiled gradient echo sequence; LAVA: liver volume three-dimensional ultra-fast T1WI sequence.

Table 1. The sequence parameters of MRI.

2.3.1.3 Cervical invasion

All tumors were divided into two groups: without cervical invasion and with cervical invasion.

2.3.1.4 Infiltration width

Tumors were classified into two groups. One group was the lesions limited within the uterus, and another group was those with invasion into the parametrium or adjacent organs, or with metastasis.

2.3.2 Region Of Interest (ROI)

The ROI of the tumors or ROI1 was selected from the scanning section with the maximum tumor diameter and the contrast-enhanced area of the solid part ($> 0.1 \text{ cm}^2$). The control or ROI2 was selected from the adjacent unaffected myometrial tissue, and its size and shape were kept same to those of ROI1. Necrosis, hemorrhage, and other areas with heterogeneous signal were avoided on the basis of the characteristics of conventional MRI.

2.3.3 Quantitative measurements

The DCE TIC was obtained directly from the GE functool 4.3 workstation. The signal intensity in the different DCE phases was measured in the ROI1 and ROI2, respectively. The enhanced rate in each phase was calculated as enhanced rate = $(SI_{\text{post}} - SI_{\text{pre}}) / SI_{\text{pre}} \times 100\%$. SI_{post} was the enhanced signal intensity in the ROI and SI_{pre} was the corresponding signal intensity before the enhancement. The enhanced rate at 16 s was recorded as the arterial phase relative signal increase (ARSI%) and the enhanced rate at the curve peak was recorded as the maximal relative signal increase (MRSI%). The signal enhancement ratio (SER%) was calculated as $SER\% = (SI_{\text{max}} - SI_{\text{prior}}) / (SI_{\text{e}} - SI_{\text{prior}}) \times 100\%$. SI_{max} was the maximum signal intensity from the DCE TIC, and SI_{e} was the signal intensity during the delayed period.

2.3.4 TIC types

The time period of enhancement to 32 s after injection of contrast agent was set to the early phase; the time period from 32 s to 64 s was set to the middle phase; the time period from 64 s to 300 s was set to the late phase; and the time period from 300 s to 300 s was set to the delayed phase. Thus the TIC of endometrial cancer could be divided into four types^[6]: type I: early and rapid enhancement to the peak in the early phase with the $ARSI\% \geq 60\%$; type II: similar enhancement pattern in the early phase to type I, but with the $ARSI\% < 60\%$; type III: significant enhancement in the early phase with the $ARSI\% \geq 60\%$, but showing continued enhancement in the middle and late phases; and type IV: lack of rapid enhancement in the early phase with $ARSI\% < 60\%$, but showing continued enhancement.

2.3.5 Endometrial cancer staging based on pathology

The pathological information of 15 postoperative cases was collected by two physicians. The general type, differentiation degree, and invasion depth on MRI were compared with the corresponding findings in pathology which was used as the gold standard. The other 9 cases

without operative treatment were staged comprehensively based on the clinical information, mainly the gynecological specialized examination, B-mode ultrasound, cystoscopy, and colonoscopy^[7].

2.4 Statistical analysis

Statistical analysis was performed with the SPSS 11.5 statistical software package. Paired t-test was used to compare the signal intensity in different DCE phases between cancer lesions and adjacent myometrial tissues. Two independent samples t-test was used to compare the differences of ARSI%, MRSI%, and SER% among groups. $P < 0.05$ was considered to be significant.

3. Results

3.1 Pathological findings and MRI features

3.1.1 Pathological findings

Pathologically, 16 tumors were adenocarcinoma, 5 were adenosquamous cell carcinoma, 1 was serous adenocarcinoma, 1 was papillary adenocarcinoma, and 1 was clear cell carcinoma. In addition, 12 of the 24 tumors were well differentiated and the other 12 were poorly differentiated.

3.1.2 Features of MRI

3.1.2.1 General types

Nineteen tumors exhibited diffuse type with the endometrial thickness of 1.12 ~ 10.35 cm (4.68 ± 0.33 cm in average). Five tumors exhibited focal type with the maximum diameter of 0.94 ~ 6.17 cm (3.27 ± 0.42 cm in average).

3.1.2.2 Depth of invasion

Fifteen tumors showed no invasion or superficial myometrial invasion, and the other 9 tumors showed deep myometrial invasion.

3.1.2.3 Cervical involvement

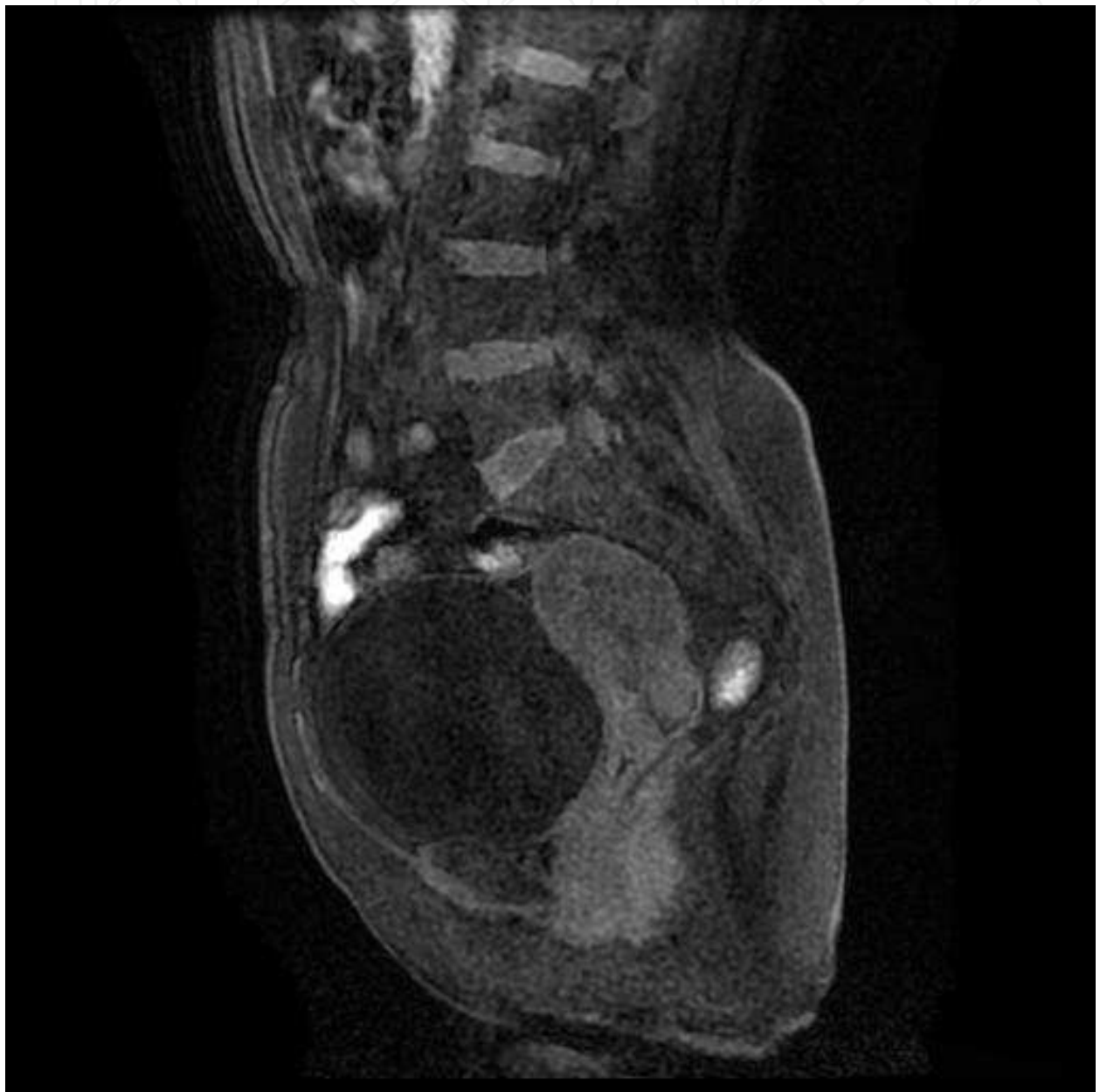Nine tumors had no involvement of the cervix and 15 tumors invaded the cervix.

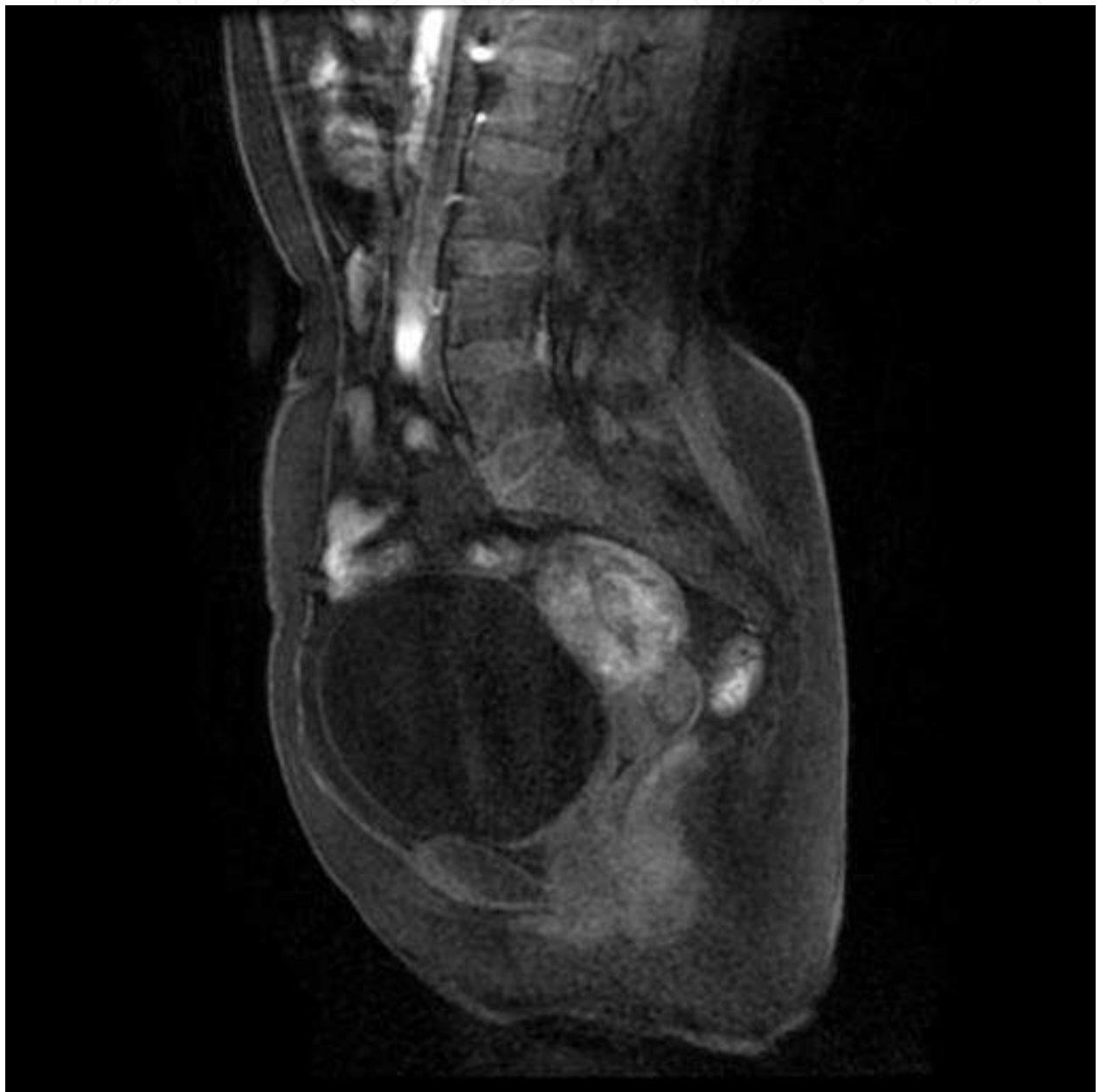3.1.2.4 Infiltration width

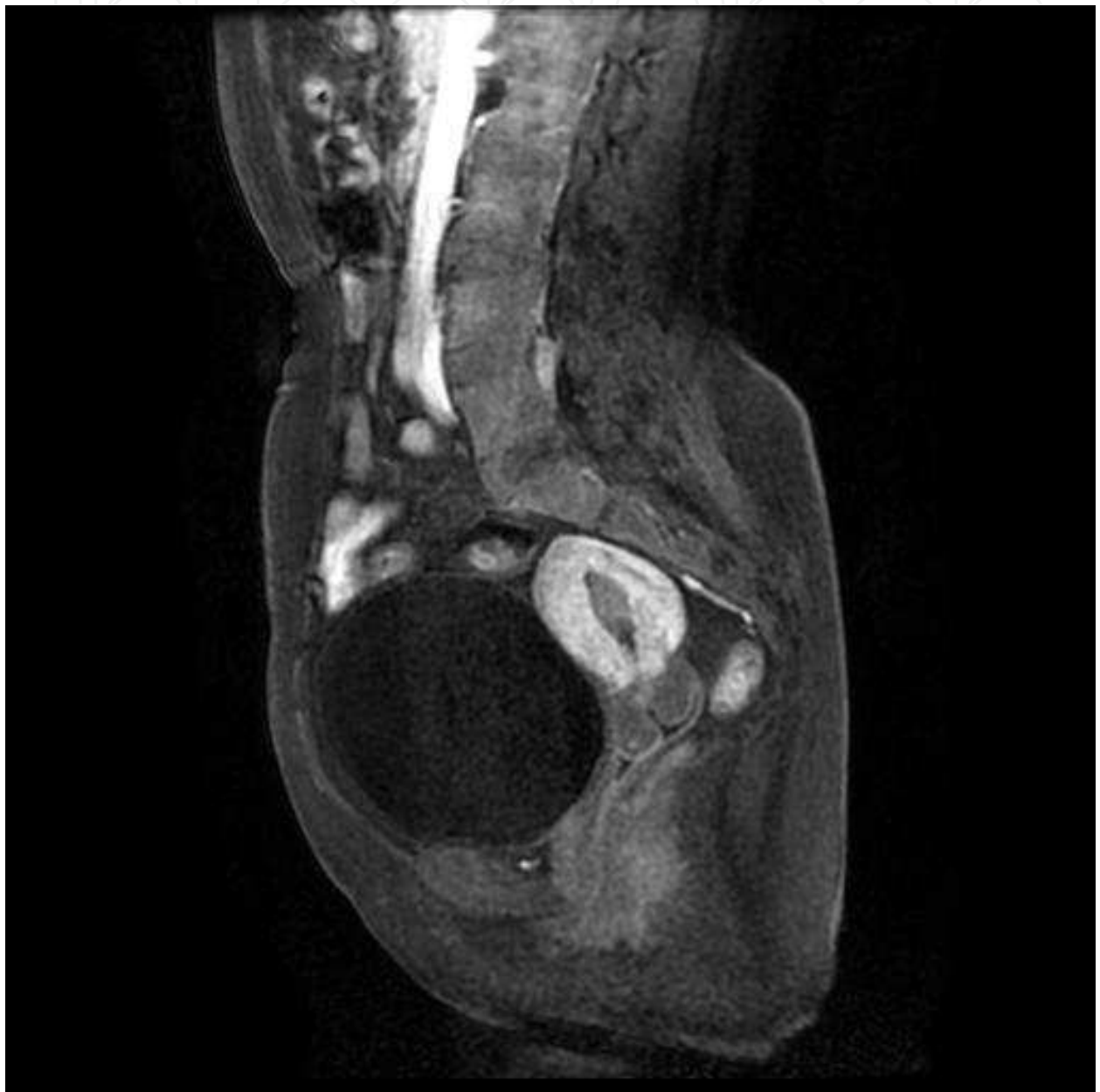There were 20 tumors without peripheral invasion, 1 tumor with parametrial invasion, 1 tumor with right sacral metastasis, and 2 tumors with lymph node metastasis.

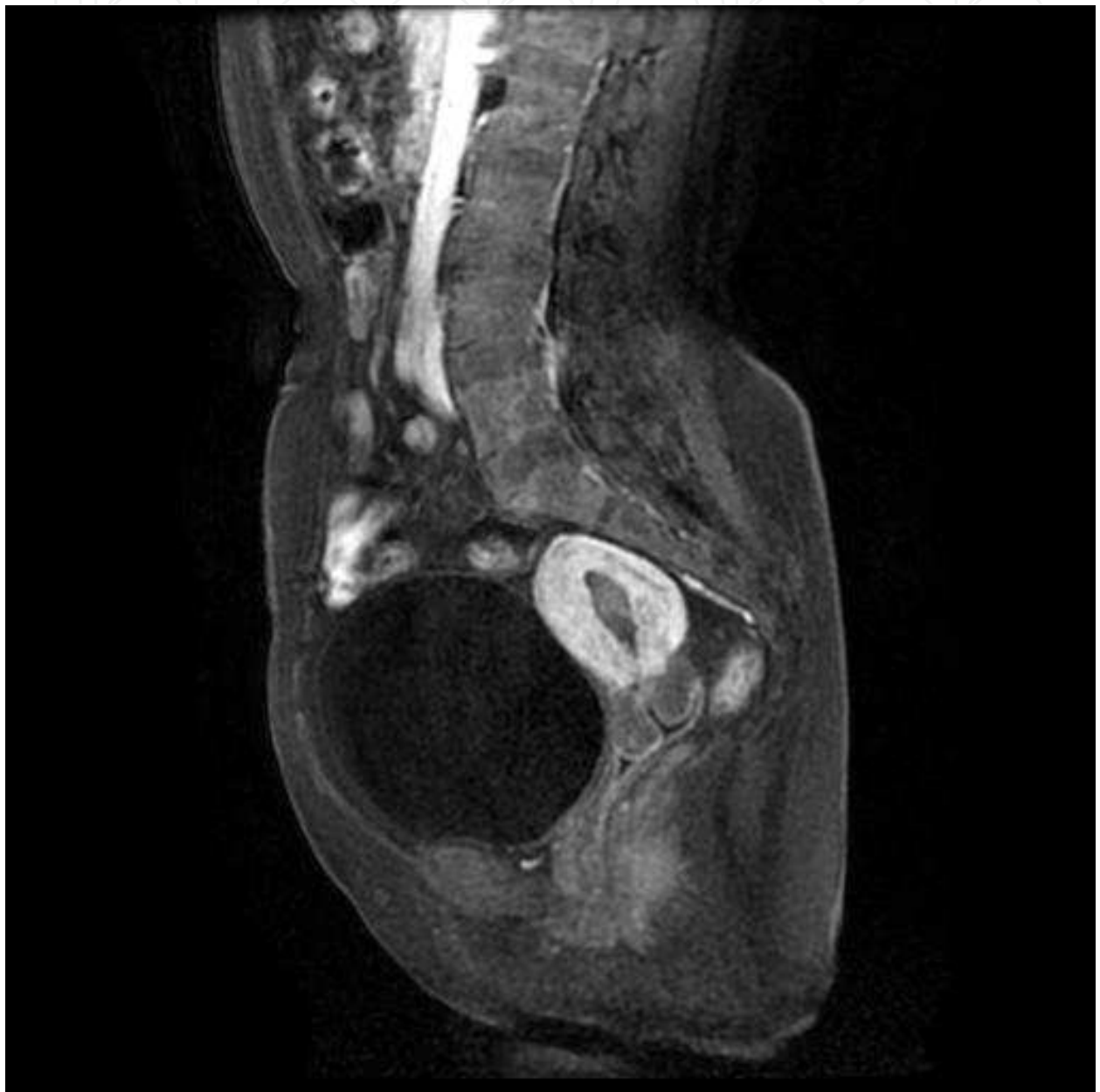3.2 DCE TIC types

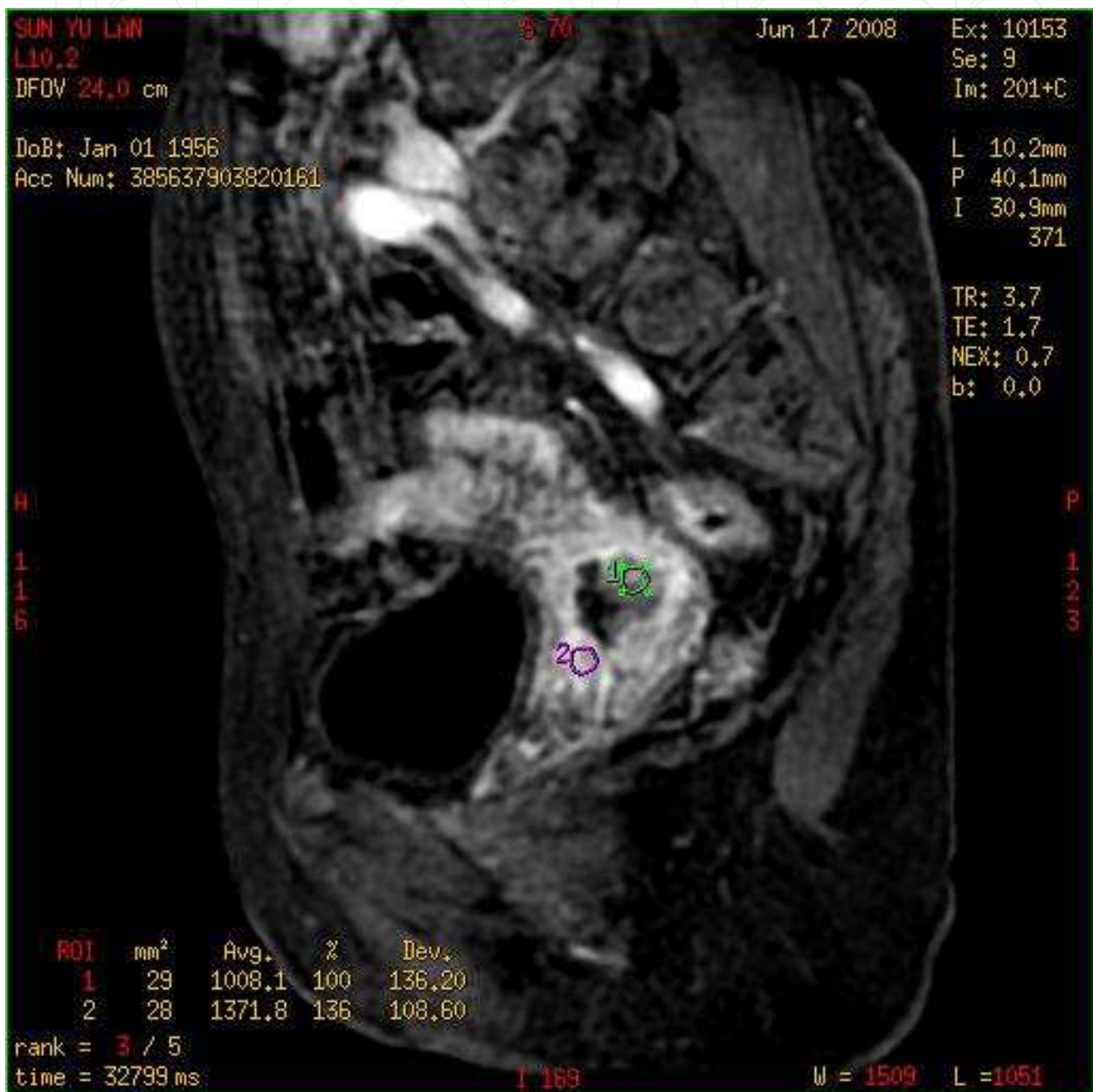All 24 tumors were enhanced at 16 s after contrast agent injection. Of them, 17 tumors showed lower or similar enhancement and the other 7 tumors showed significantly higher enhancement compared with the adjacent normal myometrium tissues. On TIC, 23 tumors exhibited continued enhancement in the late phase, and only 1 tumor exhibited decreased enhancement (Figures 1-4). Based on the TIC types, we found type I in 12 tumors (12/24), type II in 6 tumors (6 / 24), type III in 3 tumors (3 / 24), and type IV in 3 tumors (3 / 24). Types I and II curves with an early peak were observed in 18 tumors (18/24). ARSI% $\geq 60\%$ in types I and III curves was observed in 15 tumors (15/24) (Figures 5-8).

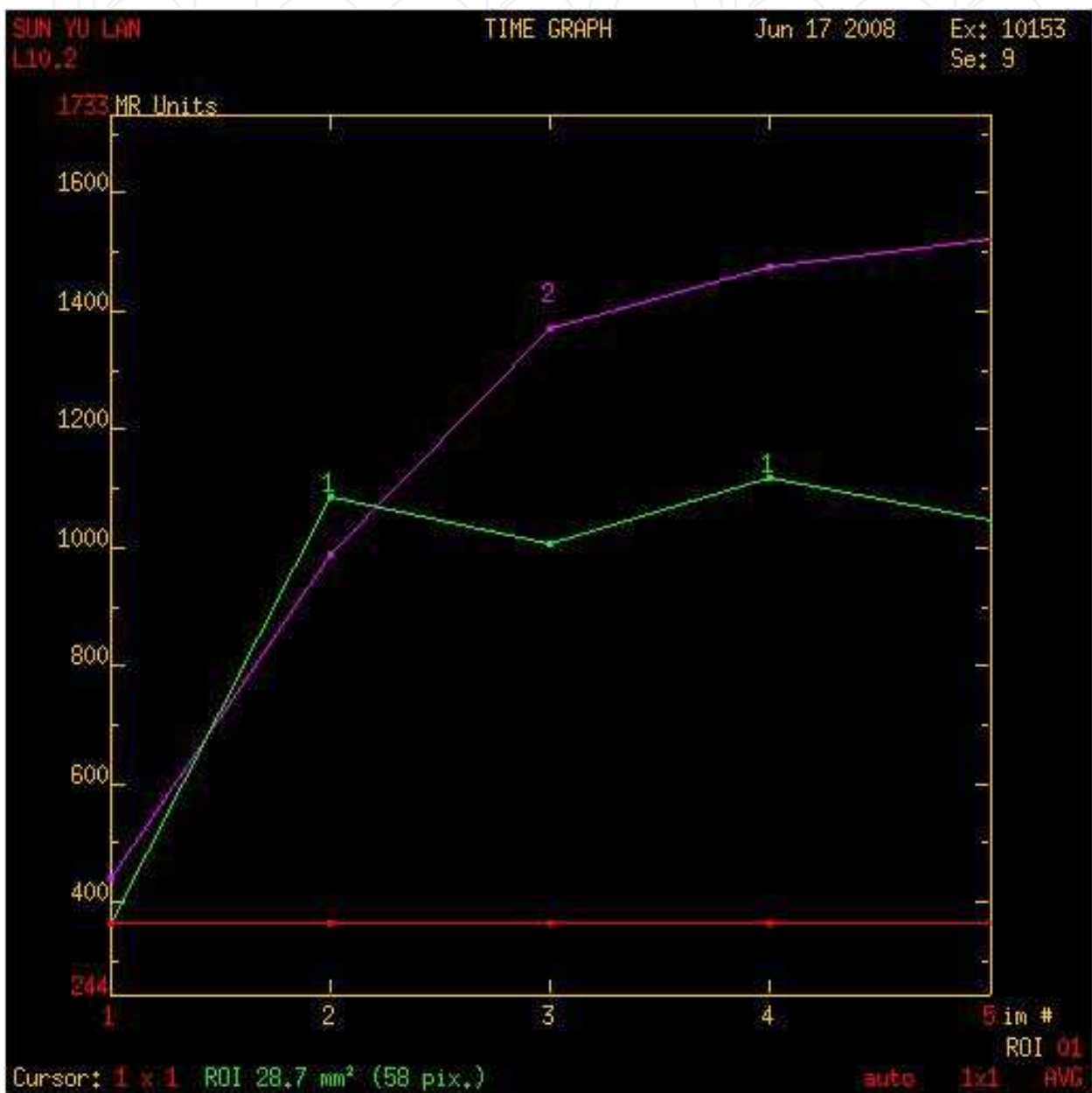


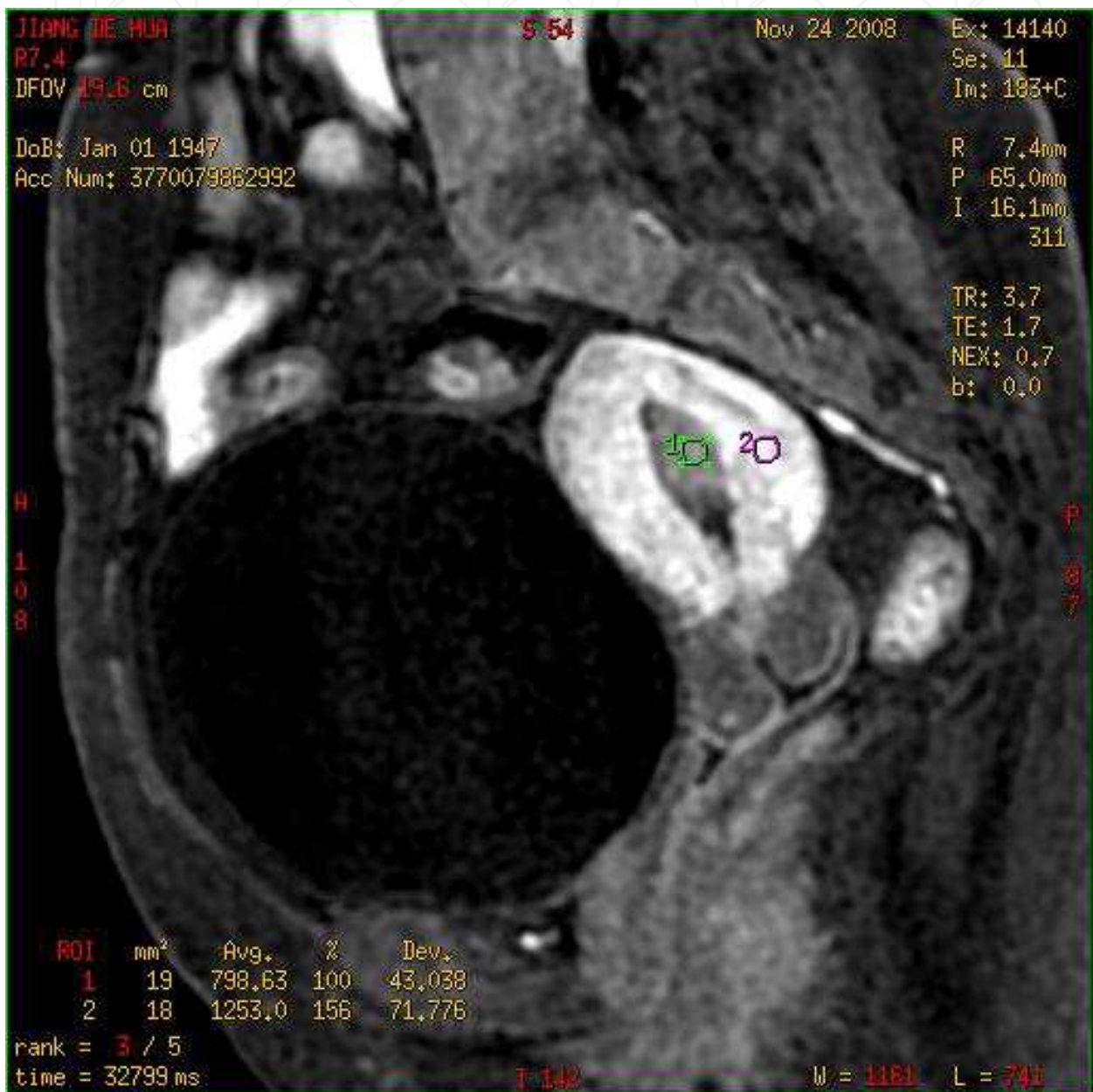

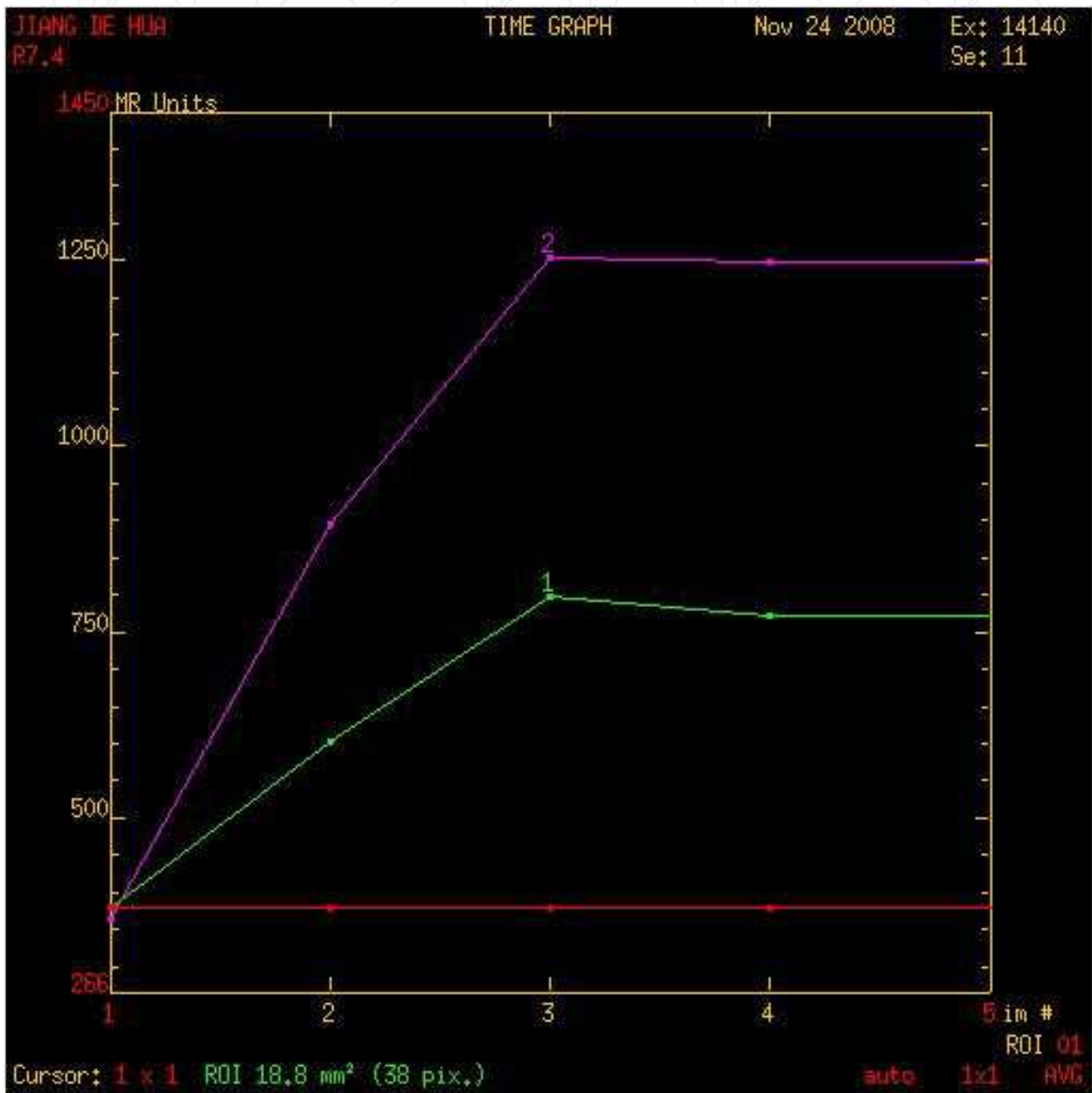


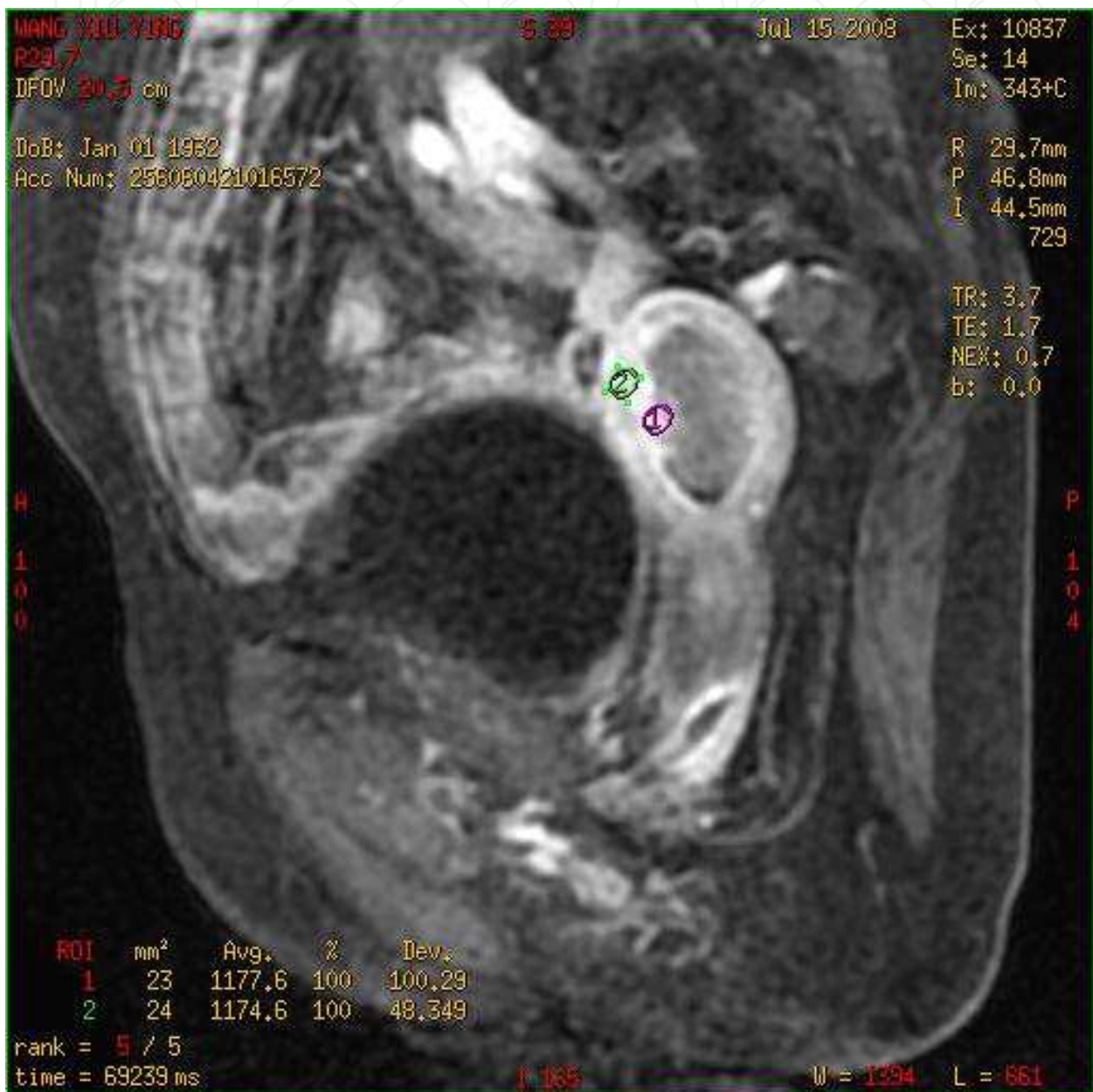


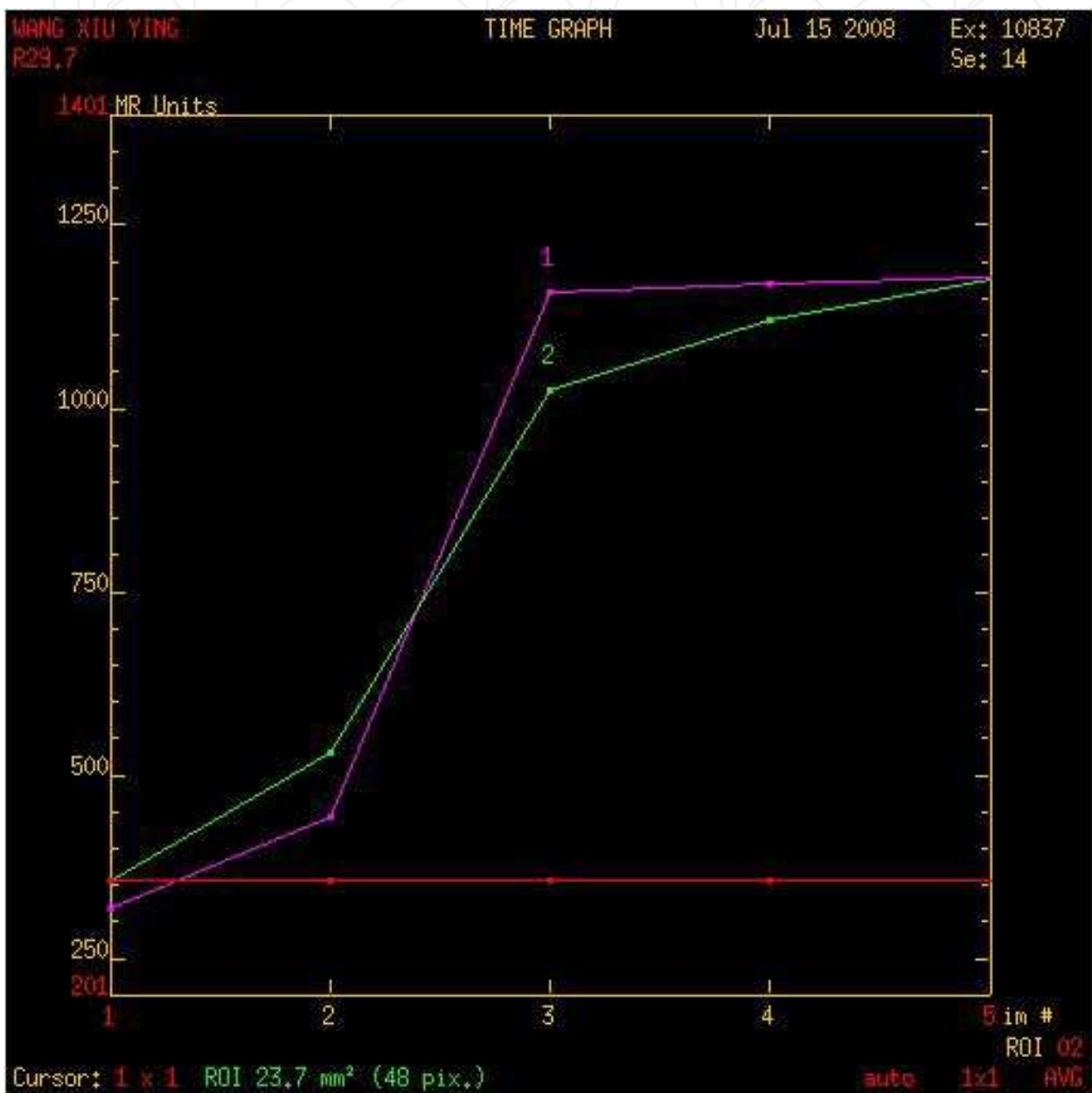



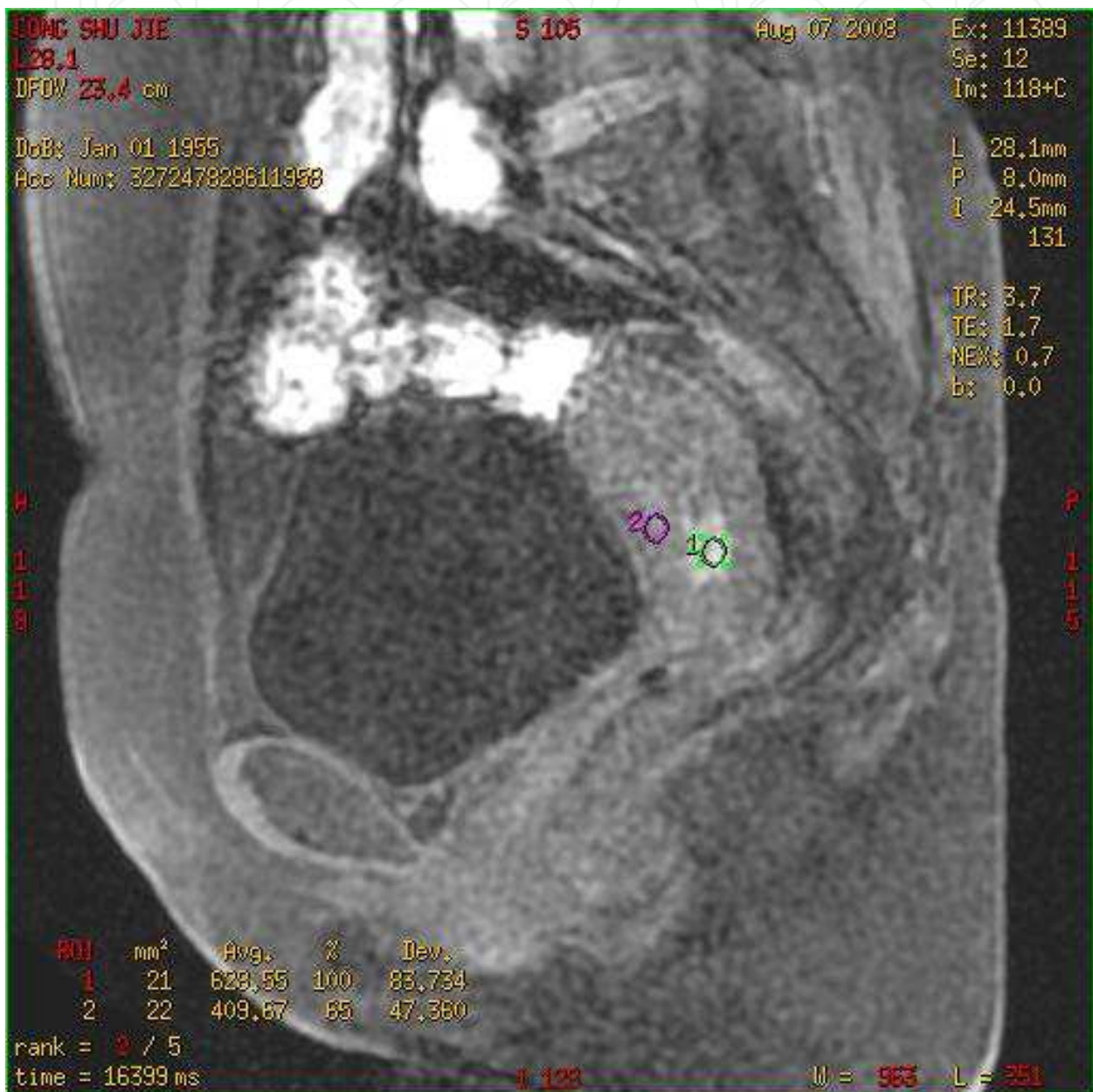










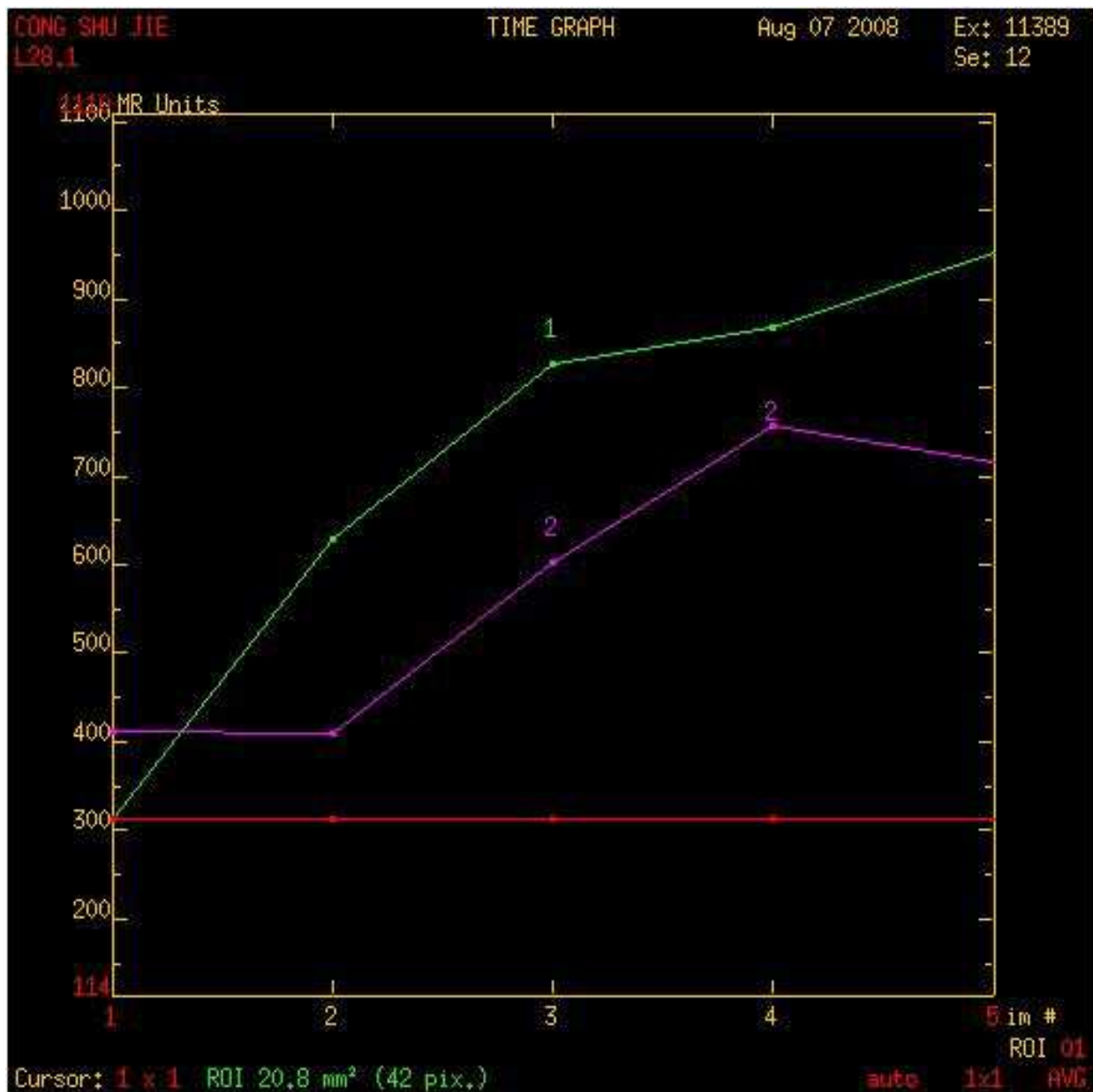


Fig. 1 to 4 female, 61 years old, endometrial adenocarcinoma. Figure 1 showed 0 s after the contrast agent injection, endometrial cancer lesions showed slightly lower signal, such as uterine tissue showed equal signal; Figure 2-4 16 s, 32 s and 64 s after the contrast agent injection, endometrial cancer lesions showed moderate enhancement, and normal uterine tissue was significantly enhanced, contrast between them was clear. Figure 5-12 Dynamic enhancement curves (TIC) type. Figure 5 endometrial cancer lesions (curve 1) was type I, ARSI% $\geq 60\%$, reached peak in early dynamic contrast-enhanced; normal tissue (curve 2) showed type III, ARSI% $\geq 60\%$, continuing to strengthen and enhance level higher than lesion; Figure 6 endometrial cancer lesions (curve 1) showed type II, ARSI% $< 60\%$, also reached its peak in the early dynamics; normal tissue (curve 2) showed type I, strengthening was higher than the lesion; Figure 7 endometrial cancer lesions (curve 1) showed type II curve, normal tissue (curve 2) showed type IV, ARSI% $< 60\%$, degree of enhancement was similar with lesions; Figure 8 endometrial cancer lesions (curve 1) showed type III, normal tissue (curve 2) showed type IV, the degree of enhancement below the lesion.

The signal intensities of the tumors in the early phase (16 s), delayed phase (300 s), or the curve peak were significantly lower than those of the adjacent normal tissue. The signal intensity in tumors was significantly higher in the delayed phase than in the early phase (Table 2). Also, the mean values were all significantly higher for SER% in the menopausal group than in the non-menopausal group, for ARSI% in the poorly differentiated group than in well differentiated group, and for ARSI% in the deep myometrial invasion group than in the superficial or no myometrial invasion group (all $P < 0.05$) (Table 3).

tissue	16 s	300 s	peak
endometrial carcinoma	716.48±215.10	802.71±289.34	879.33±280.96
normal	893.94±354.52	1110.83±288.83	1183.18±318.13
t	-2.911	-4.926	-4.7
P	$P < 0.01$	$P < 0.01$	$P < 0.01$

Table 2. Comparison of the signal intensity in the early and delayed phases between normal tissues and endometrial carcinoma (% \pm s).

enhanced rate	menopause		t	P	general types		t	P
	yes	no			diffuse	localized		
ARSI%	1.06±0.50	1.03±0.48	0.132	0.896	1.07±0.45	0.95±0.61	0.492	0.628
MRSI%	1.56±0.75	1.92±0.72	-1.139	0.267	1.69±0.78	1.68±0.67	0.016	0.988
SER%	1.27±0.23	1.07±0.19	2.095	0.048	1.22±0.24	1.12±0.22	0.87	0.394
enhanced rate	differentiation degree		t	P	infiltration depth		t	P
	well	poorly			no / superficial	deep		
ARSI%	0.80±0.38	1.20±0.48	2.142	0.044	0.86±0.34	1.37±0.52	2.917	0.008
MRSI%	1.86±0.88	1.58±0.67	-0.862	0.398	1.66±0.75	1.73±0.78	0.231	0.819
SER%	1.13±0.22	1.25±0.24	1.17	0.254	1.17±0.23	1.25±0.24	0.762	0.454
enhanced rate	cervical involvement		t	P	Infiltration breadth		t	P
	yes	no			yes	no		
ARSI%	1.19±0.53	0.82±0.28	1.955	0.063	1.34±0.70	0.99±0.42	1.364	0.186
MRSI%	1.73±0.81	1.61±0.66	0.388	0.702	1.90±0.80	1.64±0.75	0.63	0.535
SER%	1.17±0.23	1.26±0.24	-0.848	0.406	1.27±0.31	1.19±0.22	0.643	0.527

Note: ARSI%: arterial phase relative signal increase; MRSI%: maximal relative signal increase; SER%: signal enhancement ratio.

Table 3. Comparison of the ARSI%, MRSI%, and SER% between designated groups (%).

4. Discussion

4.1 Endometrial cancer characteristics of DCE-MRI

Currently, staging of uterine lesions is often determined based on the findings of multi-phase enhanced MRI in clinic, however, the selection of the enhanced phases is controversial^[8]. DCE-MRI is a dynamic MR technology, focusing on the enhancement behaviors at different time points and reflecting the characteristics of tumor blood supply^[9]. Therefore, the tumor blood vessels can be quantified to a certain extent, which makes it possible to study the microvascular characteristics non-invasively.

It has been reported^[5] that a mild thin-like enhancement can be observed in the thin layer of tissue between endometrium and myometrium in the early phase of DCE-MRI, which is called subendometrial enhancement (SEE). Similarly, because of the difference in blood supply between tumor and myometrial tissue, the signal enhancement in tumors is significantly lower than that in normal tissue, which leads to increased contrast between tumor and myometrium. Until to the delayed phase, the tumor enhancement is increasing, but the intensity in tumor is still lower than that in myometrium. The maximum signal difference between tumor and myometrium can be observed at certain time, at which the tumor size and margin can be seen clearly and accurate estimation of the invasion depth to myometrium can be made. In the present study, all 24 endometrial tumors were enhanced on DCE-MRI. The enhancement degree in 17 tumors was lower than that in the normal tissue in the early phase, which was consistent with the literature. The remaining 7 tumors showed significantly stronger enhancement than the normal tissues, and of the tumors, 3 were poorly differentiated adenocarcinoma, 1 was clear cell carcinoma, and 1 was serous carcinoma. These results suggest that the enhancement degree may be associated with the degree of malignancy as more abundant blood supply in higher malignant tumors. Only 1 tumor showed decreased contrast enhancement in the delayed phase, which was inconsistent with the report in the literature. The maximum signal intensity in the delayed phase was lower in the tumors than in the adjacent normal tissue, but the signal intensity difference between tumors and normal tissues was higher in the delayed phase than in the early phase, consistent with the previous reports^[10-11], indicating that the delayed phase (300 s) was more favorable to delineate the lesions on DCE-MRI.

4.2 Quantitative evaluation of enhancement and TIC curves

Enhanced patterns of tumors reflect the trend of enhancement, however there is no quantitative criterion for the enhancement evaluation. In recent years, many investigators measured the degree of the lesion enhancement with ARSI%, MRSI%, SER%, and other indicators, in addition to the detection sensitivity, noise, etc. These indicators reflect the degree of tumor angiogenesis and the status of blood supply. ARSI% reflects the relative degree of enhancement in the early phase, MRSI% reflects the maximum degree of enhancement, and SER% reflects the relative degree of enhancement in the delayed phase.

Our study showed that the mean value of ARSI% was significantly higher in poorly differentiated tumors than in well differentiated tumors, which was consistent with the findings by Yamashit et al.^[12] who showed that the poorer the tumor differentiation was, the richer blood supply in the early phase there was. They also showed that ARSI% could be used to evaluate the prognosis to a certain extent. Bronow et al. found^[1] that the metastasis probabilities in the pelvic and para-aortic lymph nodes were 2.5% and 1.2%, respectively, if

the tumor limited in the endometrium, while those probabilities were 46.4% and 28.5%, respectively, if tumors had deep myometrial invasion. Therefore, precise evaluation of the depth of myometrial invasion is critical for the clinical treatment selection and prognosis prediction. In our study, the ARSI% in deep myometrial invasion group was higher than in the no/superficial myometrial invasion group. The mean value of SER% in postmenopausal group was higher than in non-menopausal group, which may be due to the reasons of uterine atrophy, increased fiber content, and a larger extracellular space in postmenopausal women. Patients diagnosed with cervical involvement should expand the scope of operation, or take surgery after the radiotherapy. Seki et al.^[5] used DCE sequences in the detection of cervical involvement and they showed diagnostic accuracy of 95%, higher than 85% obtained on T2WI. Our study showed that the mean value of ARSI% in cervical involvement group was higher than in the unaffected group, but the difference was not significant. Further study is necessary in a large sample of tumors.

Regarding the TIC curves of the 24 endometrial cancers, 18 (18/24) were types I and II with an early peak and 16 (16/24) were types I and III with ARSI% $\geq 60\%$ and an early enhancement. All these endometrial cancers were those with rich blood supply.

In short, the signal enhancement of endometrial cancers in different phases of DCE-MRI can be quantitatively measured, which reflects the status of the tumor's blood supply, and indirectly provides information on their biology. The data in the early and delayed phases of DCE-MRI could provide more relevant information for prognosis prediction and tumor stage determination.

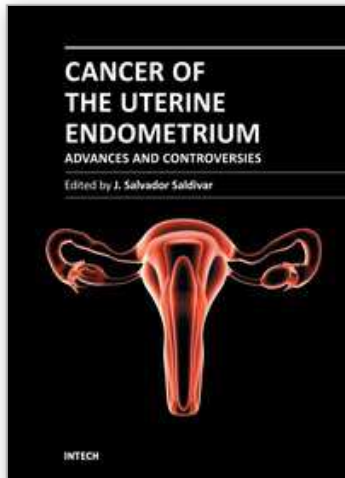
5. References

- [1] Bronow RC. Surgical staging in endometrial cancer: clinical pathologic findings of preoperative study. *David Manual of Gynecologic Oncology*, 1999, 87:99
- [2] Janus CL, Wlczky HP, Laufer N. Magnetic resonance imaging of the menstrual cycle. *Magn Reson Image*. 1998;6:669-674
- [3] Lee EJ, Byun JY, Kim BS, et al. Staging of early endometrial carcinoma: assessment with T2-weighted and Gadolinium-enhanced T1-weighted MR imaging. *Radiographics*, 1999, 19:937
- [4] Hardesty LA, Sumkin JH, Nath ME, et al. Use of preoperative MR imaging in the management of endometrial carcinoma: a retrospective analysis. *Radiology*, 2000, 115(1): 45-49
- [5] Seki H, Takano T, Sakai K. Value of Dynamic MR Imaging in Assessing Endometrial Carcinoma Involvement of the Cervix [J]. *AJR*, 2000, 175(1): 171-176.
- [6] Jun Shan, Jian-Min Xu, Jing-Shan Gong, etc. The value of differential diagnosis to Ovarian benign and malignant tumor on enhanced MRI. *Chinese Journal of Radiology*, 2003, 11:1001-1006
- [7] Van Vierzen PB, Massuger LF, et al. Fast dynamic contrast enhanced MR imaging of cervical carcinoma. *Clin Radiol*, 1998, 53:183-192
- [8] Seki H, Azumi R, Kimura M, et al. Stromal invasion by carcinoma of the cervix: assessment with dynamic MR imaging. *AJR*, 1997, 168:1579-1585.
- [9] Aberle DR, Chiles C, Gatsonis C, et al. Imaging and cancer: research strategy of the American College of Radiology Imaging Network. *Radiology*, 2005, 235:741-751.
- [10] Seki H, Kimura M, Sakai K. Myometrial invasion of endometrial carcinoma; assessment with dynamic MR and contrast-enhanced T1-weighted images. *Clin Radiol*. 1997, 52(18):18-23

- [11] Chaudhry S, Reinhold C, Guermazi A , et al. Benign and Malignant Disease of the Endometrium[J]. *Top Magn Reson Imaging*, 2003, 14(4) :339-357
- [12] Yamashita Y, Fan ZM, Yamamoto H, et al. Spin echo and dynamic gadolinium enhanced FLASH MR imaging of hepatocellular carcinoma: correlation with histopathologic findings[J]. *J Magn Reson Imaging*, 1994, 4 (1) :83 - 90.

IntechOpen

IntechOpen



Cancer of the Uterine Endometrium - Advances and Controversies

Edited by Dr J.S. Saldivar

ISBN 978-953-51-0142-0

Hard cover, 182 pages

Publisher InTech

Published online 29, February, 2012

Published in print edition February, 2012

The book *Cancer of the Uterine Endometrium - Advances and Controversies* brings together an international collaboration of authors who share their contributions for the management of endometrial carcinoma. The scope of the text is not basic, but rather aims to provide a comprehensive and updated source of advances in the diagnosis and therapeutic strategies in this field of gynecologic cancer. Each section in the book attempts to provide the most relevant evidence-based information in the biology and genetics, modern imaging, surgery and staging, and therapies for endometrial cancer. It is hoped that future editions will bring additional authors to contribute to this endeavor. To this end, it is our patients who will benefit from this work.

How to reference

In order to correctly reference this scholarly work, feel free to copy and paste the following:

Ting Zhang, Ai-Lian Liu, Mei-Yu Sun, Ping Pan, Jin-Zi Xing and Qing-Wei Song (2012). Diagnostic Value of Dynamic Contrast-Enhanced MRI in Endometrial Cancer, *Cancer of the Uterine Endometrium - Advances and Controversies*, Dr J.S. Saldivar (Ed.), ISBN: 978-953-51-0142-0, InTech, Available from: <http://www.intechopen.com/books/cancer-of-the-uterine-endometrium-advances-and-controversies/dynamic-enhanced-mri-scan-diagnosis-of-endometrial-cancer-with-staging>

INTECH
open science | open minds

InTech Europe

University Campus STeP Ri
Slavka Krautzeka 83/A
51000 Rijeka, Croatia
Phone: +385 (51) 770 447
Fax: +385 (51) 686 166
www.intechopen.com

InTech China

Unit 405, Office Block, Hotel Equatorial Shanghai
No.65, Yan An Road (West), Shanghai, 200040, China
中国上海市延安西路65号上海国际贵都大饭店办公楼405单元
Phone: +86-21-62489820
Fax: +86-21-62489821

© 2012 The Author(s). Licensee IntechOpen. This is an open access article distributed under the terms of the [Creative Commons Attribution 3.0 License](#), which permits unrestricted use, distribution, and reproduction in any medium, provided the original work is properly cited.

IntechOpen

IntechOpen