

# We are IntechOpen, the world's leading publisher of Open Access books Built by scientists, for scientists

4,800

Open access books available

122,000

International authors and editors

135M

Downloads

Our authors are among the

154

Countries delivered to

TOP 1%

most cited scientists

12.2%

Contributors from top 500 universities



WEB OF SCIENCE™

Selection of our books indexed in the Book Citation Index  
in Web of Science™ Core Collection (BKCI)

Interested in publishing with us?  
Contact [book.department@intechopen.com](mailto:book.department@intechopen.com)

Numbers displayed above are based on latest data collected.  
For more information visit [www.intechopen.com](http://www.intechopen.com)



## Robotic-Assisted Bariatric Surgery

Ulises Garza, Angela Echeverria and Carlos Galvani  
*Section of Minimally Invasive & Robotic Surgery, Department of Surgery,  
College of Medicine, University of Arizona, Tucson,  
USA*

### 1. Introduction

Obesity is a serious public health problem in the United States. The prevalence of obesity is growing every year, not only in adults but also in the pediatric population (Ogden et al., 2002). Obesity is now the second leading cause of death in the United States after tobacco-related disease, and 400,000 Americans died of obesity-related causes in 2000 (Mokdad et al., 2004). It is well known that obesity contributes to such comorbidities as noninsulin-dependent diabetes mellitus, hypertension, and hypertri-glyceridemia or hypercholesterolemia. Surgical treatment of morbid obesity is recognized as long-term effective therapy, and its goal is to limit or eliminate these comorbidities (Dixon & O'Brien, 2002; Giusti et al., 2004).

Robotically-assisted surgery's most notable contributions are reflected in its ability to extend the already well-established benefits of minimally invasive surgery to procedures not routinely performed using minimal access techniques (i.e., total esophagectomies, coronary artery bypass grafting, and radical prostatectomies). This technology may ultimately increase the number of physicians who are able to provide the benefits of minimal access surgery to their patients without the increased risks of complications associated with initial learning curves. We believe that the progress and development of robotic surgery will eventually provide all bariatric surgeons with the option of a minimally invasive approach. As more patients become aware of the clinical outcomes from minimally invasive surgical treatment for morbid obesity, they will actively seek a bariatric surgeon skilled in these techniques. The additional advantages afforded by the use of minimally invasive surgical techniques, coupled with the desire to retain the natural ergonomics and visual advantages of open surgery, have propelled the development and progression of robot-assisted surgery. Current robotics systems have already begun to return the "natural feel" of open access afforded by laparotomy to minimally invasive surgeons.

A survey of surgeons in 2003 revealed that only few surgeons in the United States were currently using a robotic surgical system for bariatric surgery (Jacobsen et al., 2003). This statistic can be explained by the small number of bariatric cases performed laparoscopically and by the limited number of institutions with a robotics system available for use. The first robot-assisted adjustable gastric banding was reported in 1999 (Cadiere et al., 1999), and Horgan and collaborators performed the first robot-assisted gastric bypass in September 2000 (Horgan et al., 2001). Since that time there have been numerous publications detailing the use of robotic assistance in bariatric surgery.

Herein, we examine the current use of robotics in bariatric surgery as well as its potential advantages and disadvantages.

### 1.1 The da Vinci robotic system

Using robots to perform surgery once seemed a futuristic fantasy. Nonetheless, since the FDA approval in the year 2000, robotic surgery and the use of the da Vinci Surgical System™ (DVSS Intuitive Surgical Corporation, Sunnyvale, Calif) has widely extended. The DVSS became the first robotic surgical system cleared by the FDA for general laparoscopic surgery. In the following years, the FDA cleared the da Vinci Surgical System™ for thoracoscopic surgery, for cardiac procedures, urologic, and gynecologic procedures.

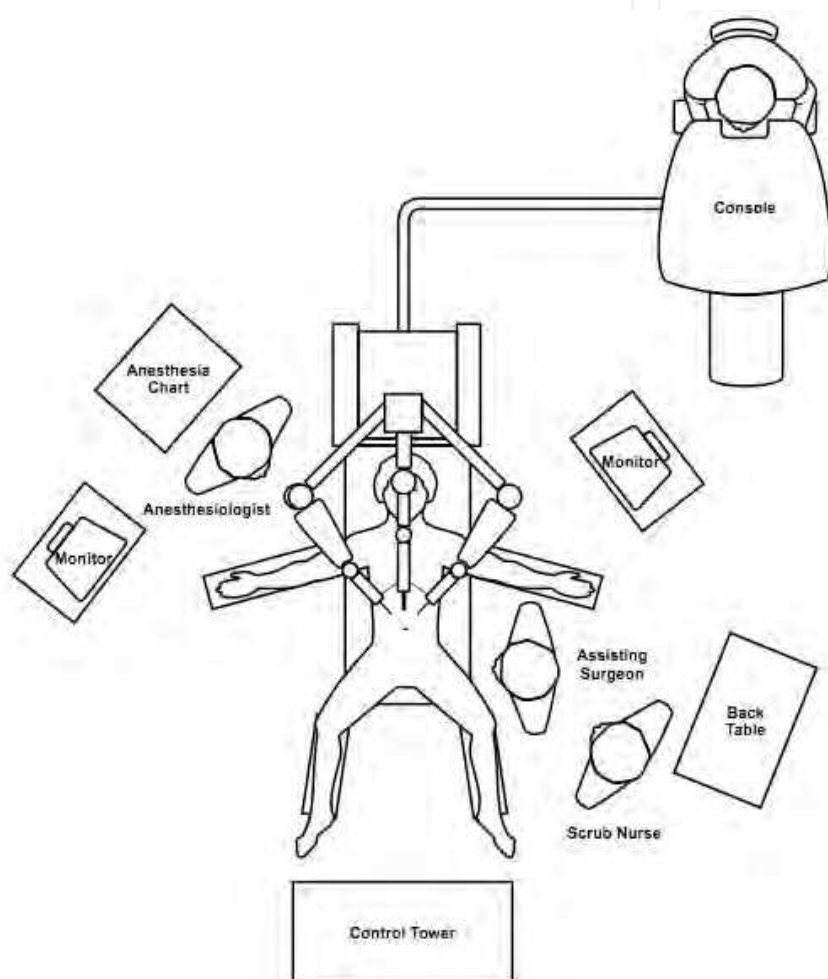


Fig. 1. Operating room setup for Robotic-Assisted Gastric Banding.

In the US, approximately 1,950 units are actually working, 347 in Europe, and 182 distributed throughout the rest of the world.

The equipment has three different components (1).

- **Surgeon Console:** At which the surgeon operates while comfortably seated, using four pedals, a set of console switches, and two master controls. The movements of the surgeon's fingers are transmitted by the master controls, to the tip of the

instruments located inside the patient. A high-resolution three-dimensional view of the surgical field is obtained using a 12 mm scope, which contains two 5 mm three-chip video cameras that integrate images.

- **Control Tower:** monitor, light sources, and cord attachments for the cameras.
- **Patient side cart:** consisting of four robotic arms, one arm positions the laparoscope and the other three arms allow placement and manipulation of a variety of da Vinci-specific instruments.

The bariatric procedures performed vary from a simple laparoscopic adjustable gastric band up to the most complex biliopancreatic diversion/duodenal switch (BPD/DS).

## 2. Robotic gastric adjustable band placement

Laparoscopic adjustable gastric banding (LAGB) is one of the preferred methods for surgical treatment of morbid obesity (Muhlman et al., 2003). Excellent long-term results and postoperative improvement in quality of life have been reported (Cadiere et al., 2002; Dargent, 1999; Nehoda et al., 2001). The expanding use of the LAGB is probably driven by the encouraging data on its safety and effectiveness. LAGB is associated with a shorter learning curve and decreased perioperative complications compared to gastric bypass. For that reason, adoption of robotic technology for this procedure is scarce. Nevertheless, Cadiere et al., described the first robotic gastric band placement in 1999 (Cadiere et al., 1999). Later, several studies in the literature have reported the use of robotics for LAGB (Edelson et al., 2011; Moser & Horgan, 2004).

### 2.1 Surgical technique

The surgical technique was previously described Moser et al (Moser & Horgan, 2004). In brief, the patient is placed in the low lithotomy position with the legs and arms open. The surgeon operates between the patient's legs, with the assistant at the patient's left side (1).

Pneumoperitoneum can be achieved with the Veress needle technique or with the optiview assistance trocar up to 15 or 20 mm Hg. The first trocar used is a 10- to 12-mm trocar, which is inserted under direct vision or with an optiview trocar, 15 to 20 cm from the xyphoid process using a 10-mm, 0 or 30-degree scope, the rest of the trocars are introduced under direct vision. An 8-mm trocar (robotic arm) is placed immediately below the left rib cage in the mid clavicular line; also a 12-mm trocar is then placed on the left flank at the same level as the camera. Then, the patient is placed in the reverse Trendelenburg position, to allow a better visualization of the His Angle. A Nathanson liver retractor is inserted through a 5-mm incision placed below the xyphoid process. The last 8-mm trocar (robotic arm) is placed approximately 8 cm below the right rib cage. A Cadiere forceps or robotic grasper is used attached to the right arm and the harmonic scalpel to the left arm. The operation begins with detaching the phrenogastric ligament to expose the left crura. Then, the gastrohepatic ligament is opened to expose the caudate lobe of the liver, the inferior vena cava and the right crura. A retrogastric tunnel is created between the edge of the right crura and the posterior wall of the stomach until the articulated tip of the robotic instrument is visualized at the angle of His. The band is placed inside the abdomen, through the 12-mm trocar and the tip of the tubing is placed between the jaws of the Cadiere forceps, attached to the left arm, and the band is threaded around the stomach [2].

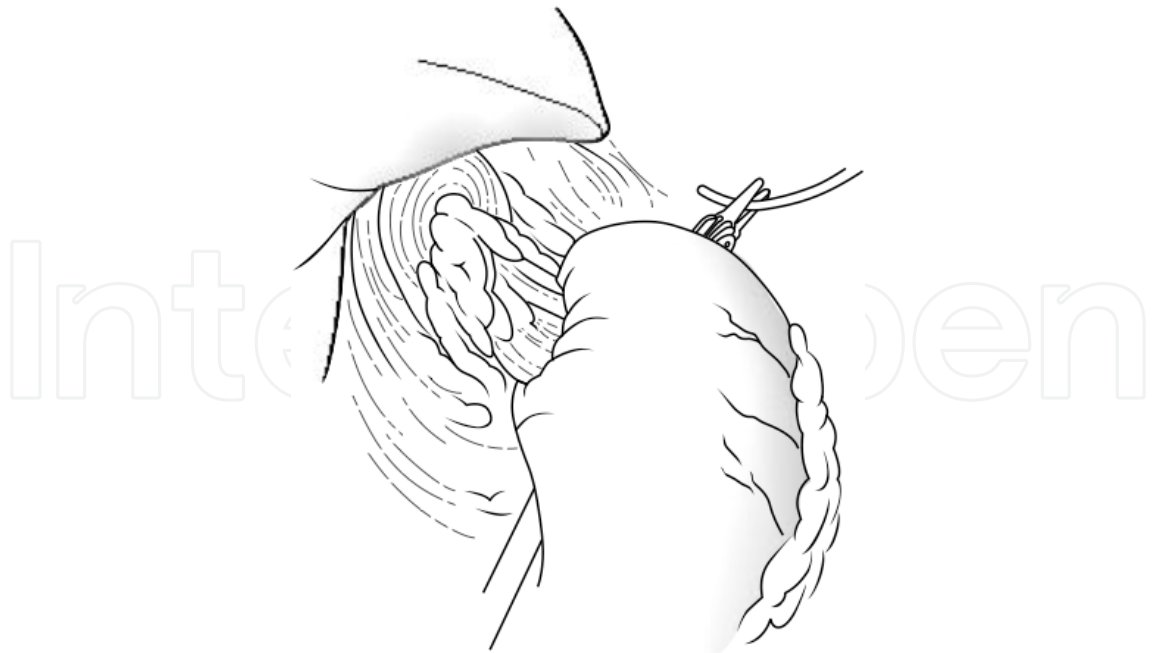

Fig. 2. The band is threaded around the stomach with Cadiere forceps.

The tip of the tubing is inserted into the band buckle and locked. After the band is in place, a wrap is fashioned out of the stomach to secure it using several nonabsorbable seromuscular sutures [3]. Finally, the port is then secured with nonabsorbable sutures or using built-in hooks.

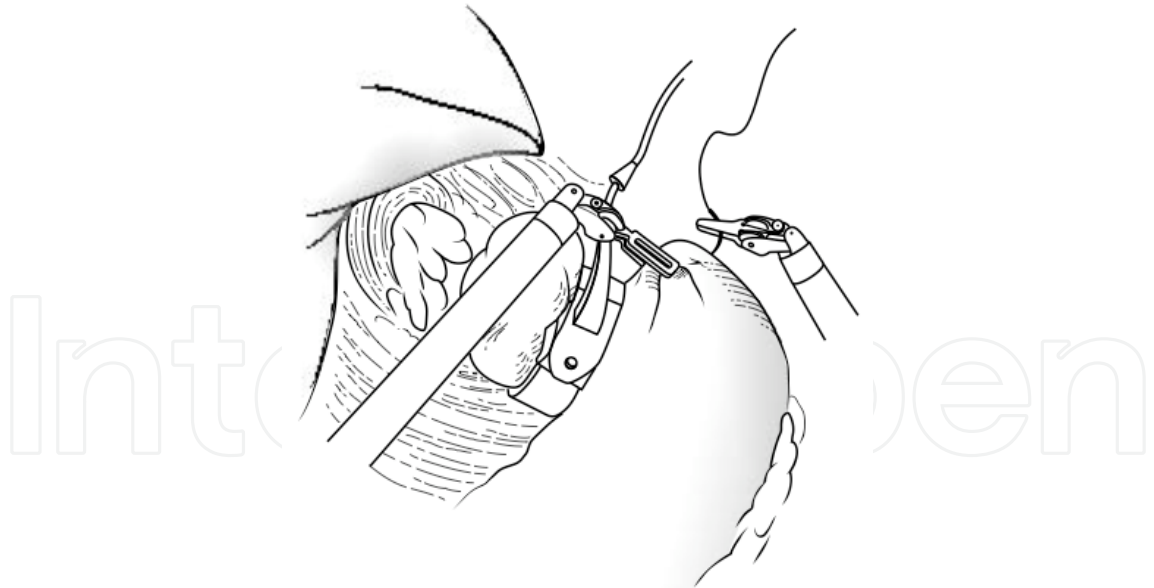


Fig. 3. A wrap is fashioned out of the stomach to secure the band in place.

### 3. Robotic-assisted Roux-en-Y gastric bypass

During the past 40 to 50 years, Roux-en-Y gastric bypass (RYGB) has been the preferred surgical procedure performed by bariatric surgeons in the United States. However, due to its complexity, this operation has always been challenged by alternative surgical

procedures. Although gastric bypass has been shown to be safe and effective in maintaining long-lasting weight loss, it is associated with a steep learning curve and is not free from complications (Podnos et al., 2003; Schauer et al., 2003).

Robotic surgery is potentially ideal for the Roux-en-Y gastric bypass (RYGB), for a variety of reasons including: the shorter learning curve to perform advanced maneuvers such as suturing, precise dissection, and the ability to be used in patients with a high BMI (Kim & Buffington, 2011). For these reasons, currently gastric bypass is the fastest growing robotic-assisted bariatric procedure with a 50% growth in 2009.

### 3.1 Surgical technique

#### 3.1.1 Robotic-assisted gastric bypass (Hybrid approach)

The patient is placed in the low lithotomy position with the legs and arms open; a beanbag is placed under the patient to support the steep reverse Trendelenburg position during the operation. Initially, the pneumoperitoneum is achieved by inserting a 12-mm trocar placed in the supraumbilical position using the Optiview system. Additional 12-mm trocars are placed in the left lower quadrant, right upper quadrant and left mid abdomen. Later, a 5-mm incision will be made below the xyphoid process to introduce a Nathanson liver retractor. Final configuration is shown in Figure 4.

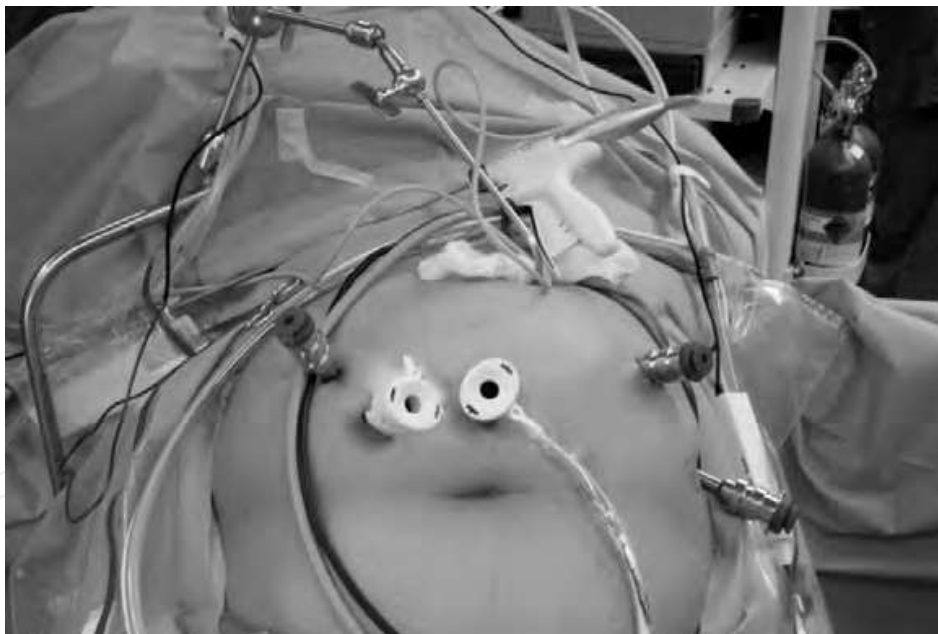


Fig. 4. Ports placement for Robotic-Assisted Gastric Bypass.

The next step consists in identifying the ligament of Treitz (LT) to run the small bowel distally 50 cm and dividing it using a vascular stapler; the mesentery of the bowel is divided using a vascular stapler or the harmonic scalpel. After creating a 100-cm jejunal limb (some authors used 150 cm [Moser & Horgan 2004]), a side-to-side jejunojejunal anastomosis is performed using a vascular stapler. The bowel opening can be closed using a needle holder with interrupted stitches of 3-0 silk or stapler. The defect between the mesentery is closed using a 2-0 Ethibond suture. The patient is then placed in a reverse Trendelenburg position (5).

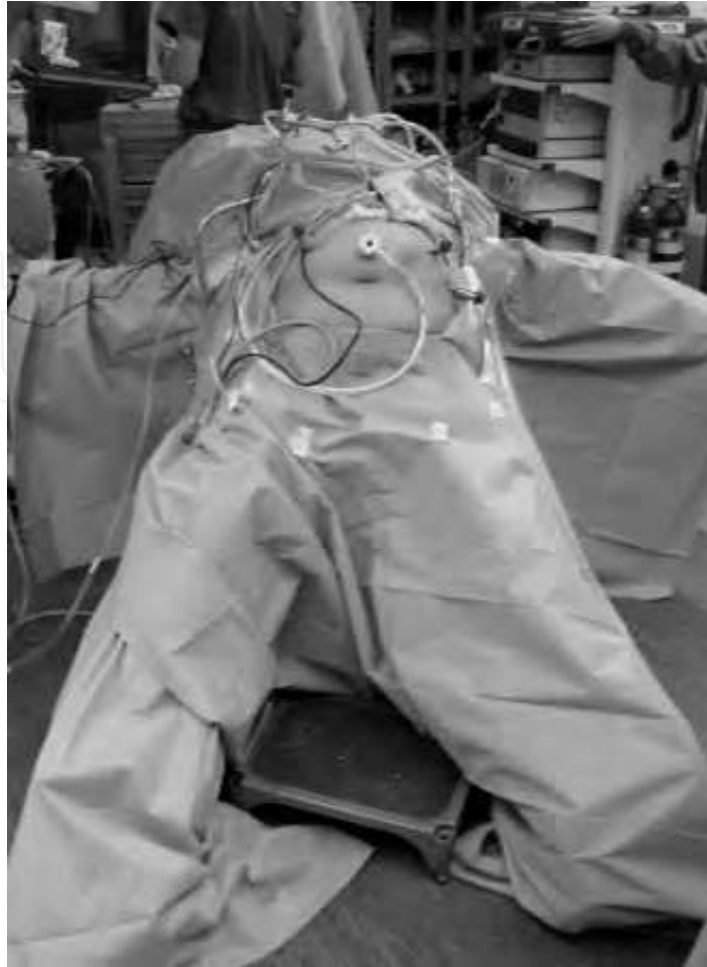

Fig. 5. Patient placed in reverse trendelenburg for Robotic-Assisted Gastric Bypass.

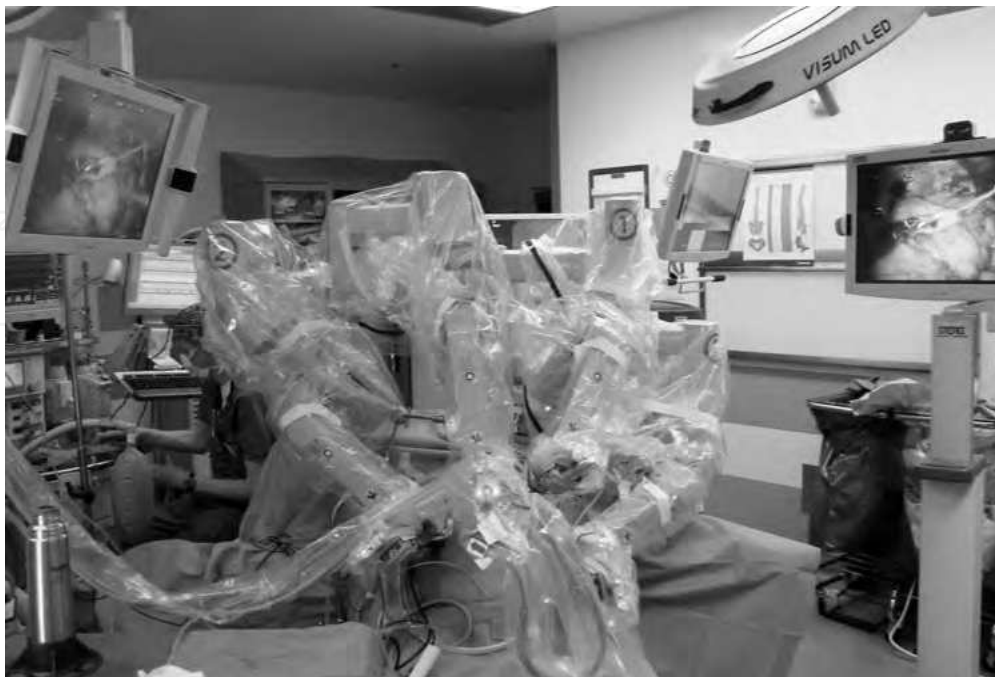

Fig. 6. da Vinci Surgical System™ positioned over the head of the patient.

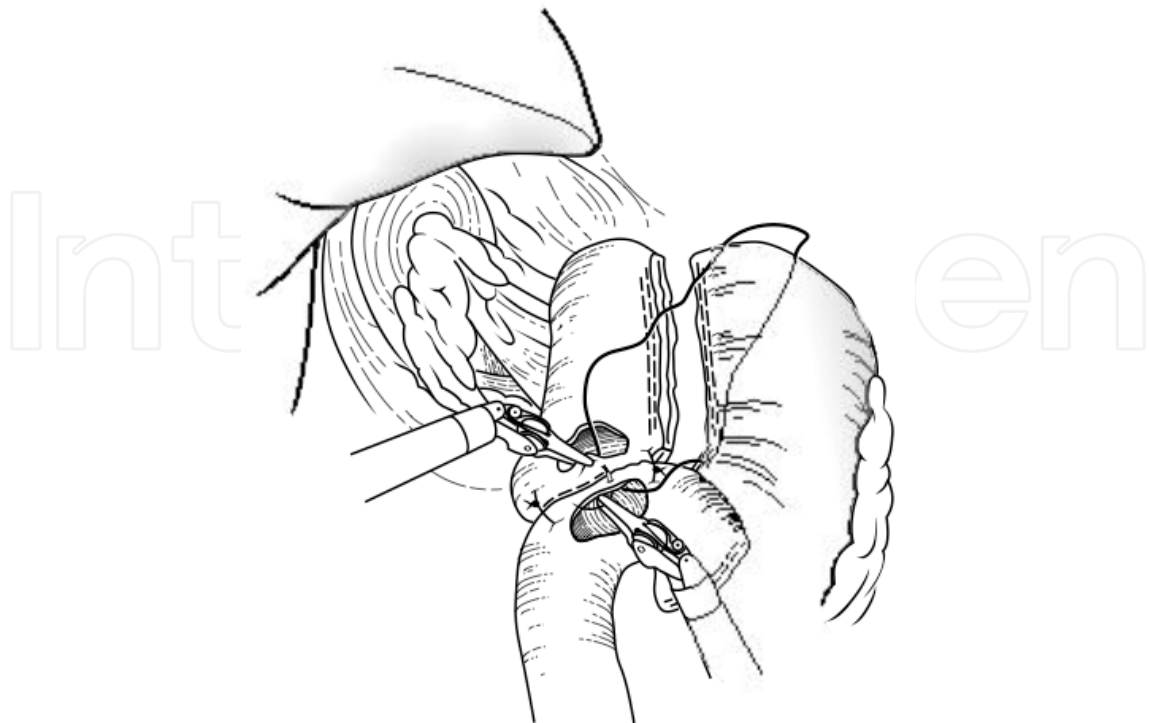


Fig. 7. Creation of the gastrojejunostomy.

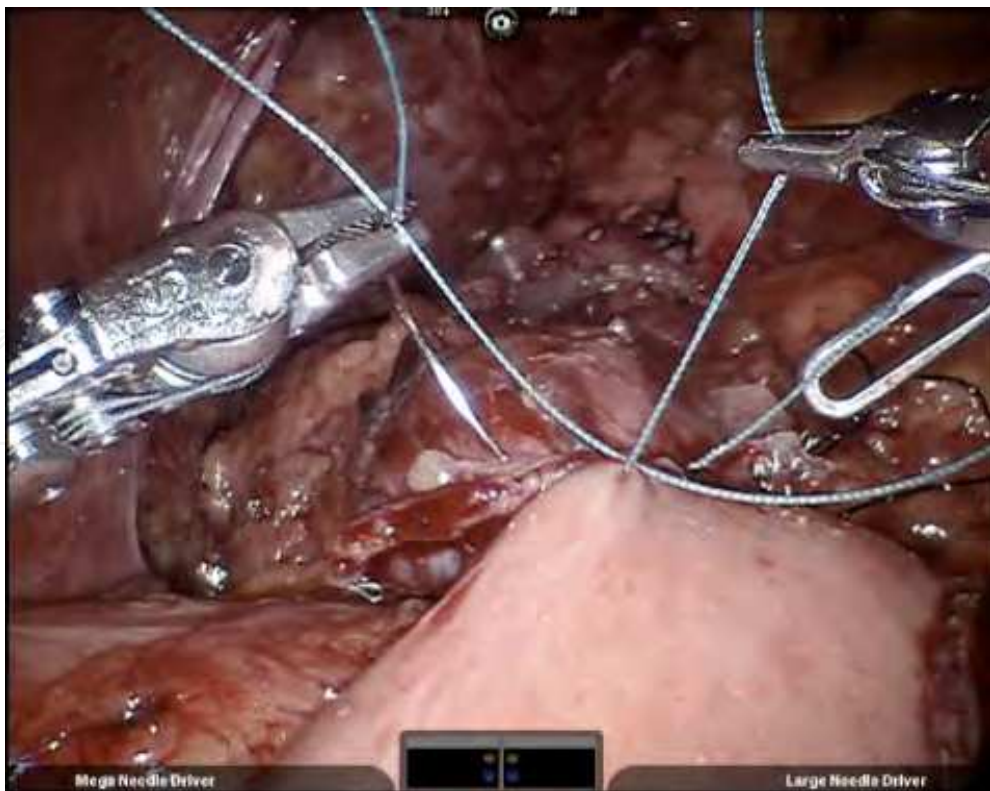


Fig. 8. Gastrojejunal anastomosis posterior running suture created.



As previously described, a 5-mm incision is made in the subxiphoid area to insert the Nathanson retractor for the anterior mobilization of the left liver lobe. The omentum is mobilized and sectioned using the harmonic scalpel. The retrogastric tunnel is created using the harmonic scalpel starting at the lesser curve approximately 5 cm from the gastroesophageal junction. Two or three fires (one perpendicular and one/two parallels) to the lesser curvature of the stomach are used to create the gastric pouch. The Roux limb is brought up antecolic for creation of the gastrojejunostomy. Horgan et al. (Horgan & Vanuno, 2001) first described the technique for the creation of the gastrojejunostomy in 2001.

The surgical arm cart of the da Vinci Surgical System™ (Intuitive Surgical, Inc., Sunnyvale, CA) is positioned over the head of the patient with the arms going through right upper quadrant and left upper quadrant ports (6).

The da Vinci ports are introduced into the 12-mm trocars. A Cadiere forceps is attached to the right arm and a needle holder to the left arm. The gastrojejunal (GJ) anastomosis (7, 8) is performed hand sewn in two layers using running 3-0 Ethibond for the posterior layer and 3-0 Vycril of the anterior layer [1].

Then, using a harmonic scalpel, a 1.5-cm opening is created in both the jejunum and the stomach (9, 10).

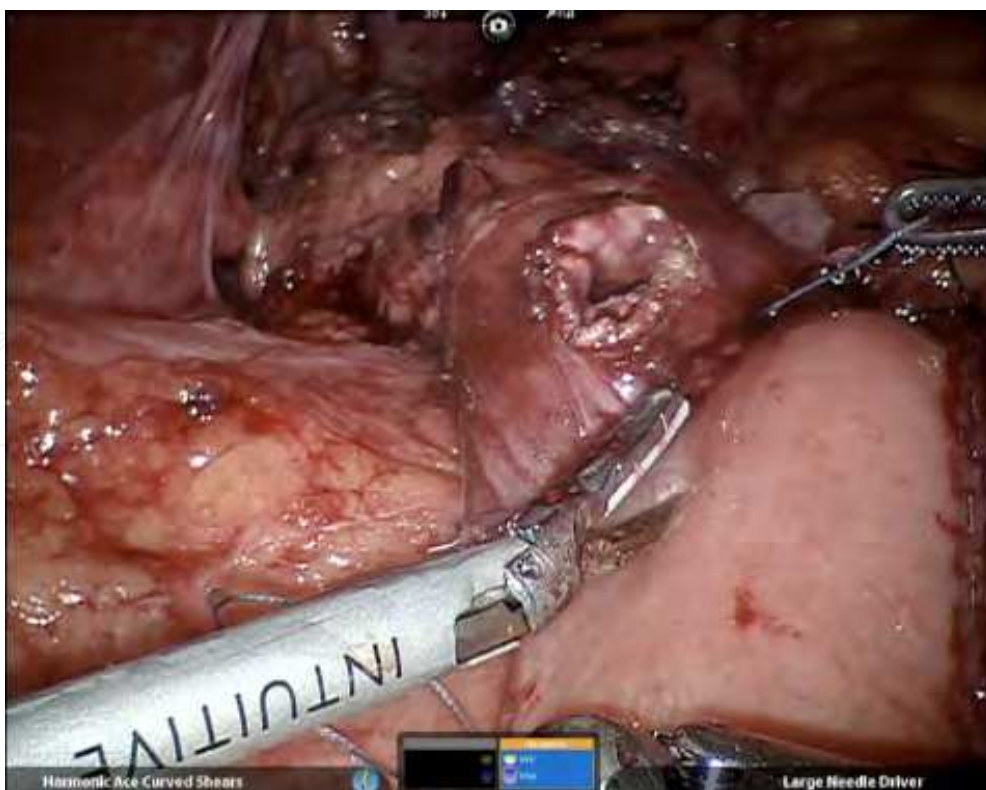


Fig 9. An opening is created in the jejunum limb with the harmonic scalpel.

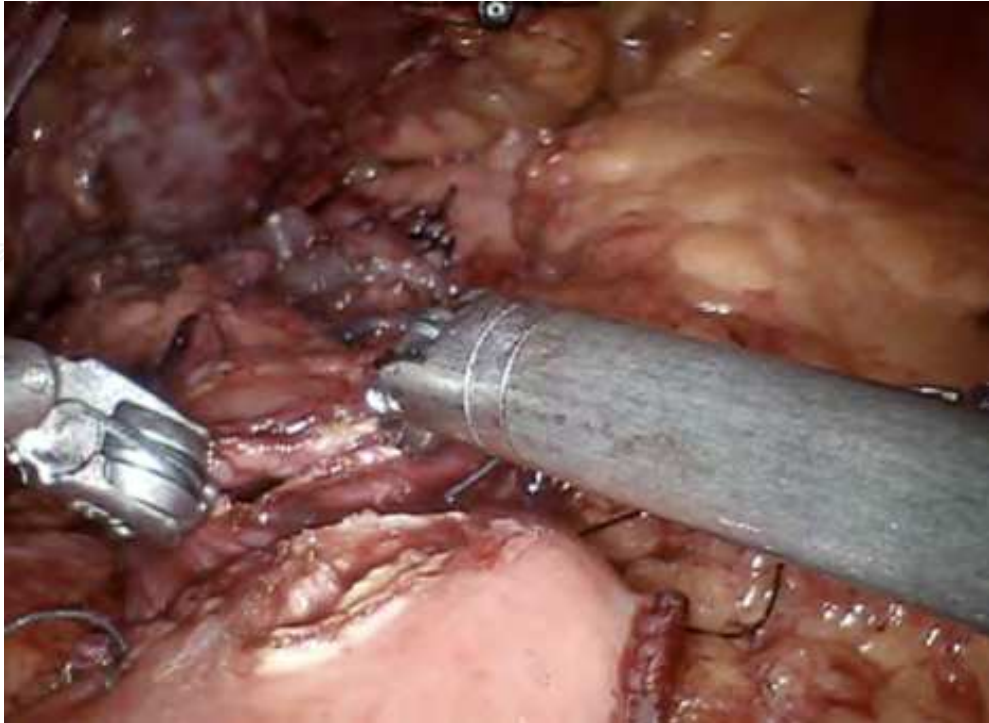

Fig. 10. An opening is created in both the jejunum and the stomach.

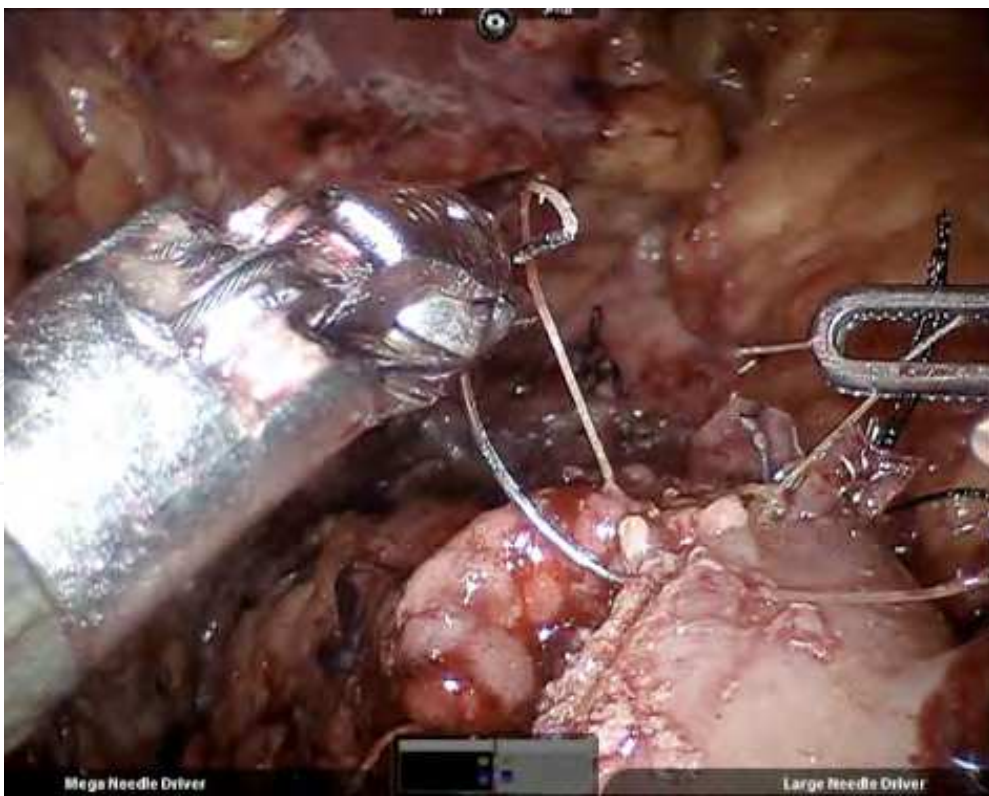


Fig. 11. Creation of the anterior layer of the GJ anastomosis using 3-0 Vycril on a running fashion.

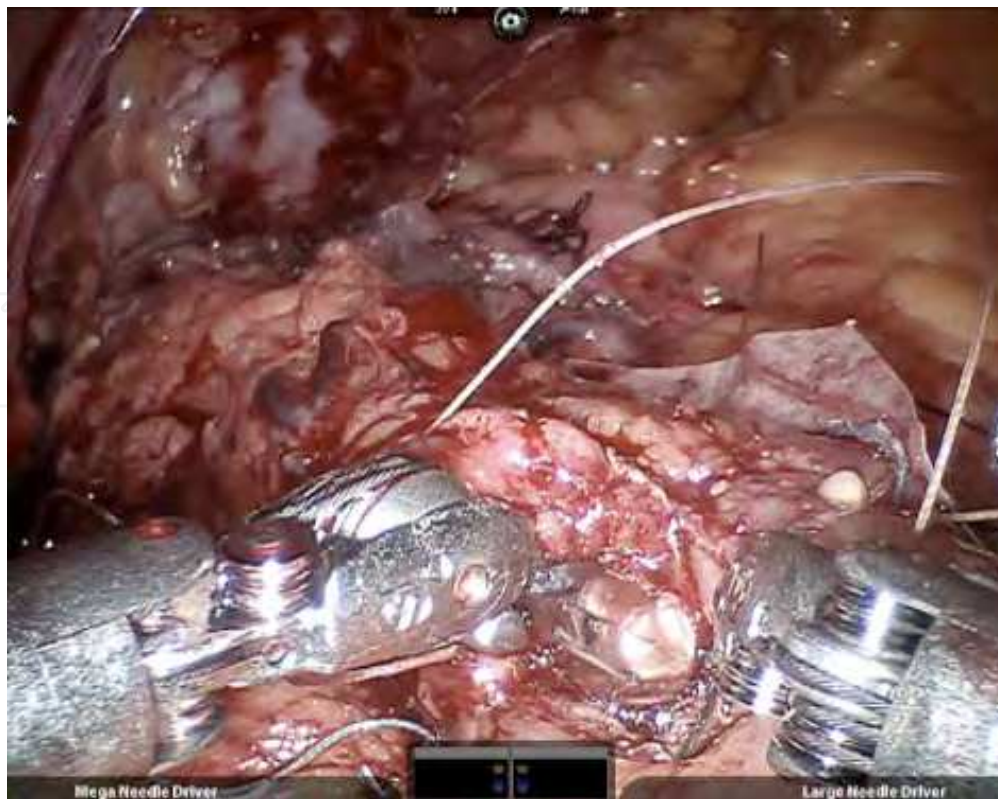

Fig. 12. An NGT is passed down to the gastric pouch and into the jejunum limb to maintain patency of the anastomosis.

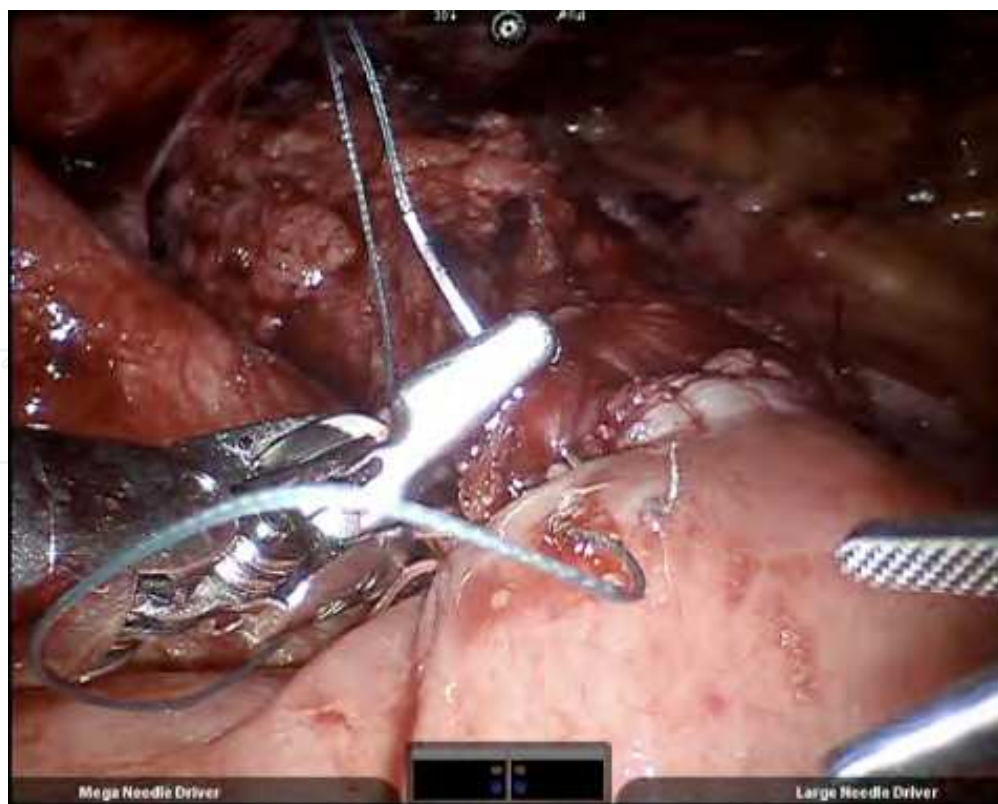


Fig. 13. Posterior layer of the GJ anastomosis using 3-0 Ethibond running suture.

Once gastrotomy and enterotomy are created the anterior layer of the anastomosis is started using 3-0 Vycril on a running fashion (11). A nasogastric tube (NGT) is passed down the gastric pouch and into the Roux limb to maintain the patency of the anastomosis (12). The posterior layer is then completed with running 3-0 Ethibon (13). Once the anastomosis is finished, using the NGT, the jejunum is clamped distally, and 60 mL of methylene blue is introduced to rule out the presence of leak. Peterson space is closed in a running fashion with non-reabsorbable suture.

### 3.1.2 Totally robotic gastric bypass

The orientation of the left and right robot arms reflects the console surgeon's and assistant's left and right (14).

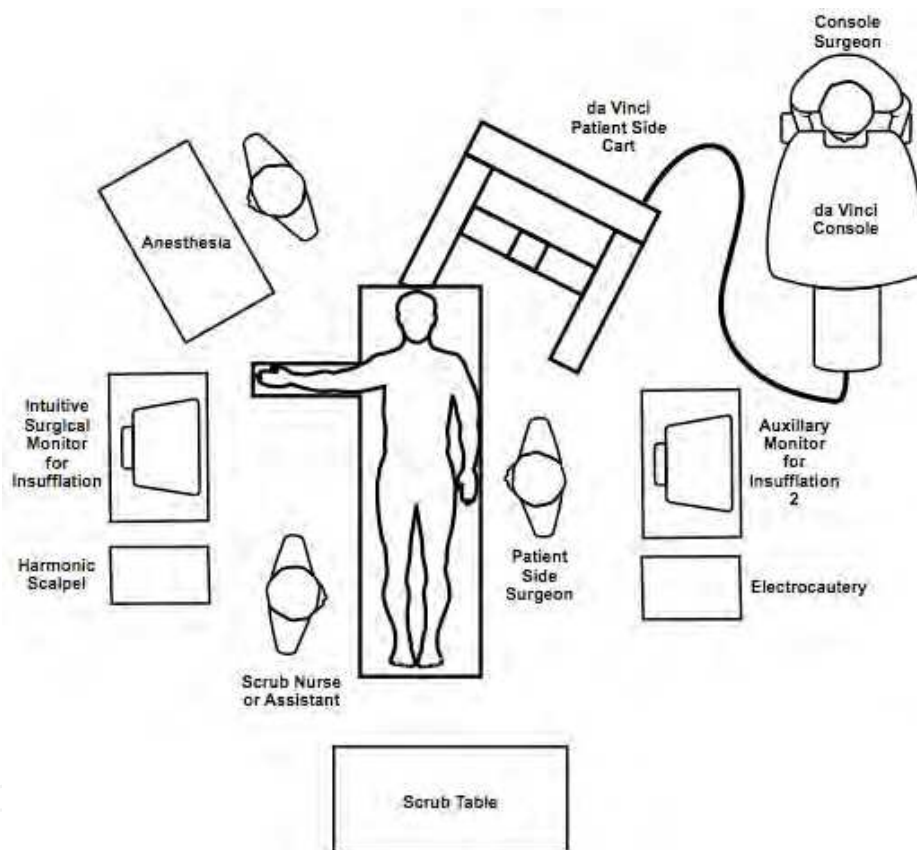


Fig. 14. Operating room setup. Totally robotic gastric bypass.

Mohr et al. (Mohr et al., 2005) describes the technique with six ports using a double cannulation of the Intuitive Surgical cannulas of 8 mm, which fitted inside a 10/12 mm port, this allows the robot arm to be removed from the port with the cannula still attached for a stapling tool and also, for the quick replacement of the robotic arm. Laparoscopy is started first placing the camera port using an Optiview nonbladed trocar and a 0° scope. Pneumoperitoneum is achieved. A total of 5 ports [a left subcostal port, two right trocars (one at the subcostal margin and one at the right flank), two trocars for the assistant (one at the left flank and one to the right of the supraumbilical midline)] are placed under direct visualization (15). The transverse mesocolon is retracted superiorly with a laparoscopic grasper allowing visualization of the ligament of Treitz.

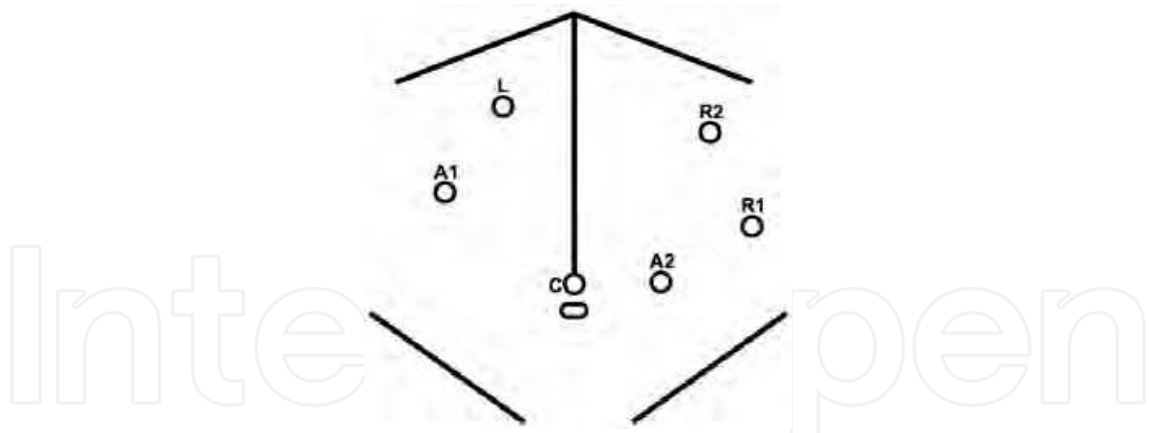


Fig. 15. Operative port placement. A, Port positions in a patient. B, Diagram of port placement. L indicates left; C, camera; A1, assistant1; A2, assistant2; R1, right 1; R2, right 2.

The robot is then docked in and it is positioned at the patient's left shoulder at a steep angle ( $15^\circ - 30^\circ$  off patient midline) and as close to the table as the base permits (16).

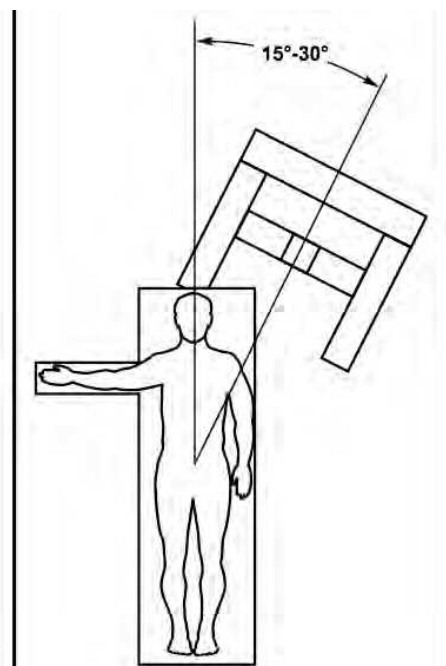


Fig. 16. Base position with respect to the operating room table.

The left arm is positioned such that the external yaw axis is as close to vertical as possible. The right arm should be brought in relatively low, and the setup joints tucked close to the base so that the tool holder is in the middle of its range of motion in the pitch axis (17).

The jejunojejunostomy is made first, but some authors prefer to make the gastric pouch first (Kim & Buffington, 2011). The surgeon manipulates the bowel with Cadiere graspers or bowel graspers at the robotic console, aided by the surgeon's assistant who also transects the bowel 20 to 40 cm from the LT using a white stapler through the left flank assistant's port (15). The jejunal mesentery is further divided by the surgeon's assistant using a LigaSure Atlas, da Vinci ultrasonic shears or stapler (Galvani et al., 2006; Horgan & Vanuno, 2001; Moser & Horgan, 2004).

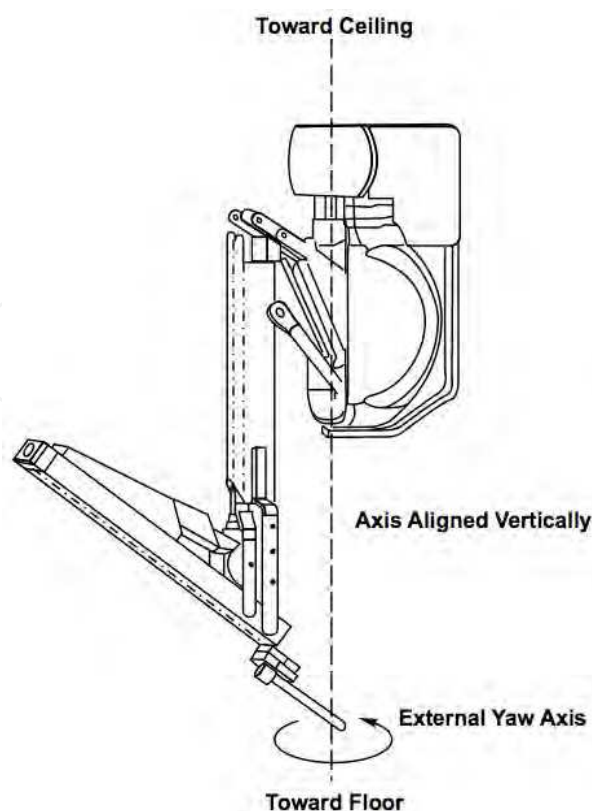


Fig. 17. The external yaw axis.

The assistant and the console surgeon then measure 100 to 150 cm of bowel for the Roux limb and align the Roux and biliopancreatic limbs joined by a 7-inch 3-0 Ethibond stay stitch placed by the console surgeon, aligning the bowel for the jejunojunctionostomy using a needle driver and DeBakey forceps and also creates the enterotomies with the Endowrist Permanent Hook below the stay stitch.

The stay stitch is used to provide counter traction for the assistant to complete the internal portion of the jejunojunctionostomy with the linear stapler. The console surgeon closes the enterotomy with a running 3-0 Ethibond single-layer suture. The mesenteric defect is then closed with interrupted or running non-absorbable sutures. The surgeon's assistant with a Ligasure Atlas divides the omentum and the Roux limb is brought up antecolic. The next step is to work at the gastroesophageal (GE) area that involves removing the right robot arm from the right flank double cannulated port, inserting the Intuitive Surgical port at the right subcostal port position (15), and redocking the arm.

The liver is retracted using a 5-mm liver retractor through the assistant's right supraumbilical port and held in place with a laparoscopic instrument holder. The console surgeon is then ready to work at the GE junction after repositioning the surgical instruments and camera visualizing the angle of His which is dissected with the electrocautery hook.

When completed, dissection of the gastric pouch begins. Dissection initiates 5 cm along the lesser curve and with the electrocautery hook into the retrogastric space. The assistant removes the left robotic arm from the double cannulated left subcostal margin port, introduces the stapler, and creates the lower border of the gastric pouch with a blue cartridge (3.5 mm).

The left robot arm is replaced, and the console surgeon provides traction for the surgeon's assistant to staple the lateral border of the pouch, which is sized using a transoral 36F tube, aided by an esophageal retractor.

The console surgeon then creates the enterotomies and a 2-layer sutured anastomosis. The outer and inner layers are sutured with running 7-in and 6-in 3-0 Ethibond sutures, respectively, with the 36F tube used to stent the anastomosis open while completing the anastomosis. A leak test is then performed insufflating it underwater; or using the methylene blue leak test (Galvani et al., 2006; Kim & Buffington, 2011; Moser & Horgan, 2004). The robot and all ports are removed and the skin incisions closed.

#### **4. Robotic sleeve gastrectomy**

The laparoscopic sleeve gastrectomy was initially reported by Ren et al. (Ren et al., 2000) in 2000 as part of the duodenal switch for super-super morbidly obese patients and later described by Regan (Regan et al., 2003) as a staged operation for morbid obesity in 2003. The rationale for sleeve gastrectomy was initially to lower the morbidity of this complex surgical procedure by offering a less challenging operation, decreasing operative time, and allowing patients to lose weight before proceeding with the second stage. Because of the excellent results in these patients, several studies (Lee et al., 2007) have supported the use of the sleeve gastrectomy as a primary bariatric operation. The main advantages of this operation are that it is not as technically challenging as gastric bypass or biliopancreatic diversion-duodenal switch (BPD-DS), thereby decreasing operative times and morbidity. As a result, robotic technology for sleeve gastrectomy has not been widely adopted amongst bariatric surgeons. The use of the robot for this procedure is still debated. However, few series have been reported in the literature (Ayloo et al., 2011; Diamantis et al., 2011).

##### **4.1 Surgical technique**

The surgical technique is described by Diamantis et al. in their first clinical experience series (Ayloo et al., 2011; Diamantis et al., 2011), which is similar to a Standard Laparoscopic Sleeve Gastrectomy (LSG). The first step is achieving pneumoperitoneum. Then, a 12-mm port 8 cm above the umbilicus for the camera, a right 12-mm trocar is positioned at the epigastrium, 5 cm towards the left of the midline, and a left 12-mm trocar placed at least 8 cm far away from the camera port, in order to avoid collision of the robotic arms that would hamper the advancement of the procedure. A double cannulation technique is used inserting the 8-mm metallic robotic ports through the standard 12-mm trocars. Two further 12-mm trocars are inserted, one at the right anterior axillary line, 2 cm below the subcostal arch for liver retraction and one at the symmetrical site on the left side to retract the gastrosplenic ligament (18).

All the trocars and robotic cannulas are inserted under the guidance of the standard laparoscopic camera and the robotic system approached the patient and is installed ("docked") afterwards. The robotic camera is docked last, and the robotic cart is positioned over the patient's left shoulder.

Only three arms of the da Vinci S Surgical System™ are used (camera and two working arms). Once the general setup is ready, the procedure begins with the console surgeon grasping with a Cadiere forceps, the greater curvature of the stomach at its lowest part and

the gastrocolic ligament is cut with the da Vinci harmonic scalpel. The division of the gastrocolic and gastrosplenic ligament continues exactly like in a standard LSG. Once the angle of His is clearly visible and mobilized from the left crus, division of the gastrocolic ligament ends 4-6 cm proximally from the pylorus. At this point instead of a bougie preferred by some surgeons, an intra-operative endoscopy can be used for the calibration of the gastric sleeve. Once the endoscope lies across the lesser gastric curvature will tailor the gastrectomy. The console surgeon holds and abducts the mobilized greater gastric curvature with a Cadieere forceps through the right working trocar and the left robotic arm is undocked. The table surgeon inserts the stapler, loaded with a green cartridge, through the working port at the right site of the patient and divides the stomach in a direction from the lowest tip of the greater gastric curvature, 4 cm proximally to the pylorus, towards the lateral edge of the endoscope.

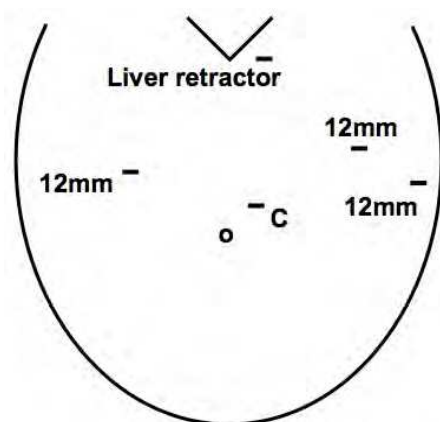


Fig. 18. Port Placement. C = camera.

All staple lines are regularly reinforced with prosthetic material (GORE SEAMGUARD bioabsorbable staple line reinforcement, W. L. GORE and Associates Inc.). The left robotic arm is docked once again after the first two fires. The stapling continues in a cephalad direction with the traction of the gastric sleeve using the Cadieere forceps, while the right arm is undocked for the insertion of the stapler, and division of the stomach; also the laparoscopic could be used to mobilize the greater gastric curvature. The stomach is divided till the angle of His, then the endoscope is smoothly withdrawn. Ayloo et al. (Ayloo, et al., 2011) also describes the assistance of the robot to invert the stapling line by placing sero-serosal sutures of 2-0 PDS (Ethicon) beginning at the angle of His. The staple line is then inspected from inside bleeding and air leak. A leak test is also performed filled with diluted Povidone 10% solution or methylene blue by some other authors (Galvani et al., 2006; Moser & Horgan, 2004). Finally, the transected, redundant part of the stomach is removed through the left lateral port site mainly through a fascial digital dilation.

## 5. Robotic-assisted biliopancreatic diversion and duodenal switch

The duodenal switch (DS) operation for bariatric surgery was initially described by Hess as a modification of the Scopinaro biliary pancreatic diversion (BPD). Today, it is accepted as the most effective weight reduction procedure (Anthone et al., 2003). In spite of this, the operation represents only about 0.89% of the bariatric procedures performed in the US (DeMaria et al., 2010). This is probably due to the technical challenges that surgeons are



faced with BPD-DS. Consequently, the vast majority of procedures are done primarily open. However, the introduction of laparoscopy has decreased its morbidity (Kim et al., 2003). The addition of robotics could potentially increase the number of minimally invasive BPD-DS procedures performed. Conversely, there are only two reports in the literature describing the use of robotic technology for BPD-DS (Sudan et al., 2007).

### 5.1 Surgical technique

Sudan et al. (Sudan et al., 2007) describes the surgical technique placing the patient in a supine position. After achieving pneumoperitoneum, a 12-mm port with a 0° camera is used to enter the abdominal cavity. Four additional 12-mm ports are placed, and the Nathanson liver retractor is placed intraoperatively through an epigastric 5-mm incision (19).

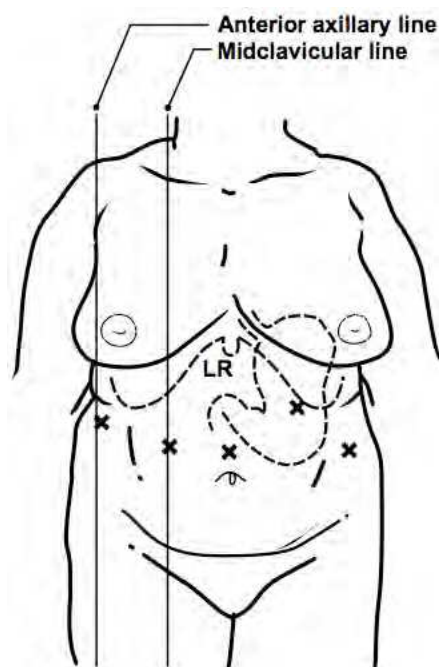


Fig. 19. Port sites. The midclavicular line ports are used for robotic arms. LR, site for Nathanson liver retractor placement.

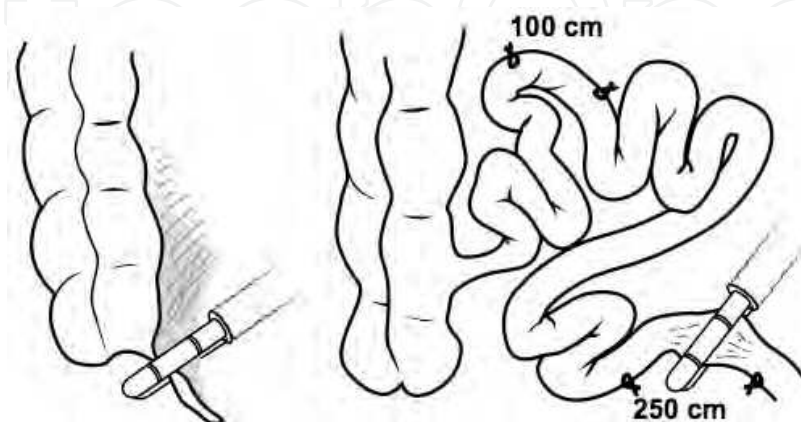


Fig. 20. Appendectomy followed by placement of marking stitches at points 100 and 250 cm proximal to the ileocecal valve. Bowel is transected 250 cm proximal to the ileocecal valve.

Midclavicular ports are used for the da Vinci arms when the duodeno-ileal (proximal alimentary limb) anastomosis is performed. Standard laparoscopic procedure is made first by positioning the patient in the Trendelenberg position and tilted to the left and an appendectomy is performed, as practiced by open BPD/DS surgeons. Marking sutures are placed 100 and 250 cm from the ileocecal junction, and the bowel is divided at the 250-cm mark using an endoliner cutter stapler (20).

The mesentery of the alimentary limb of small bowel is divided using the Harmonic Scalpel for a tension-free anastomosis to the duodenum. The biliary limb then is anastomosed to the common channel at the 100-cm mark using two applications of the 45-mm vascular endoliner cutter staplers (21).

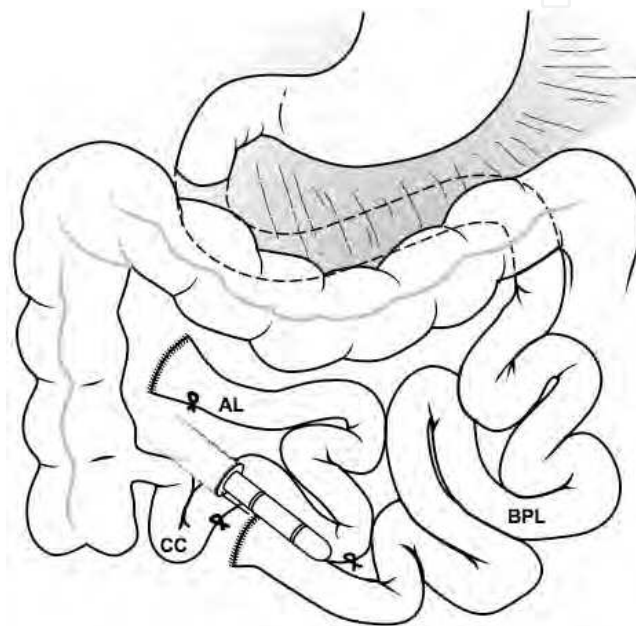


Fig. 21. The distal enteroenteric anastomosis is performed using a 45-mm vascular load endoscopic stapler. The 100-cm-long common channel (CC) is shown. AL, eventual alimentary limb; BPL, eventual biliopancreatic limb.

The enterotomy for the staplers is closed transversely using hand sewn intracorporeal suturing. The mesenteric defect between the biliary limb and the common channel is closed with running nonabsorbable suture, and the distal anastomosis is marked with three large radio-opaque hemoclips for future identification purposes. After performance of a cholecystectomy, the greater curvature of the stomach is mobilized using the Harmonic Scalpel, beginning 4 cm distal to the pylorus and working proximally to the angle of His. The duodenum is divided using the endoliner cutter stapler, and a sleeve gastrectomy is performed to reduce the capacity of the stomach to 150 ml (22). Methylene blue is used to ensure absence of leaks in the gastric staple line. The stapled edge of the alimentary limb is next positioned in a retrocolic fashion, and the da Vinci system is docked by bringing it over the patient's right shoulder.

After setting up the robot, a two-layer sutured anastomosis is then created using 2-0 Surgilon and 2-0 Vicryl in a running fashion (23).

The mesenteric defect between the alimentary limb and the retroperitoneum and transverse mesocolon is closed. The duodenoileal anastomosis then is checked with methylene blue to exclude a leak. All the specimens that had been resected (i.e., gallbladder, resected stomach, appendix) are placed in endobags and retrieved through the umbilical port site. After removal of the ports, the incisions are closed with skin staples. Final configuration is shown in Figure 24.

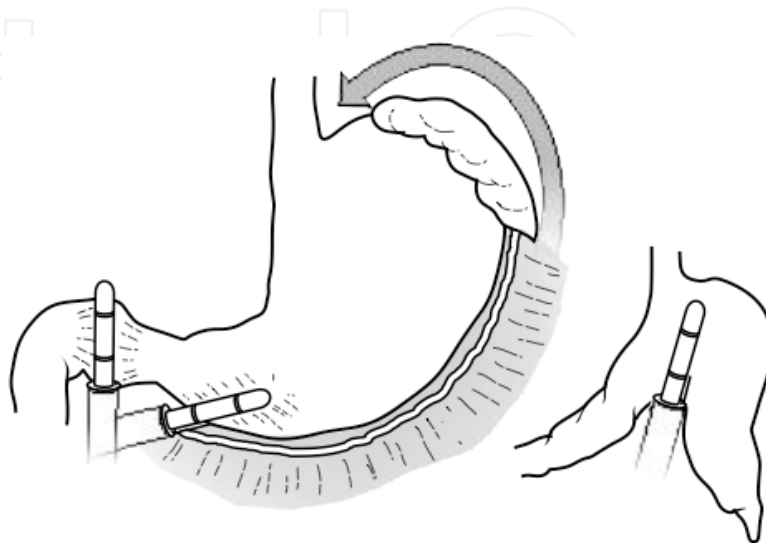


Fig. 22. Mobilization of the proximal 4 cm of the duodenum and the greater curvature of stomach is followed by transection of the duodenum and resection of the greater curvature of the stomach to result in a gastric remnant with a capacity of 150 ml.

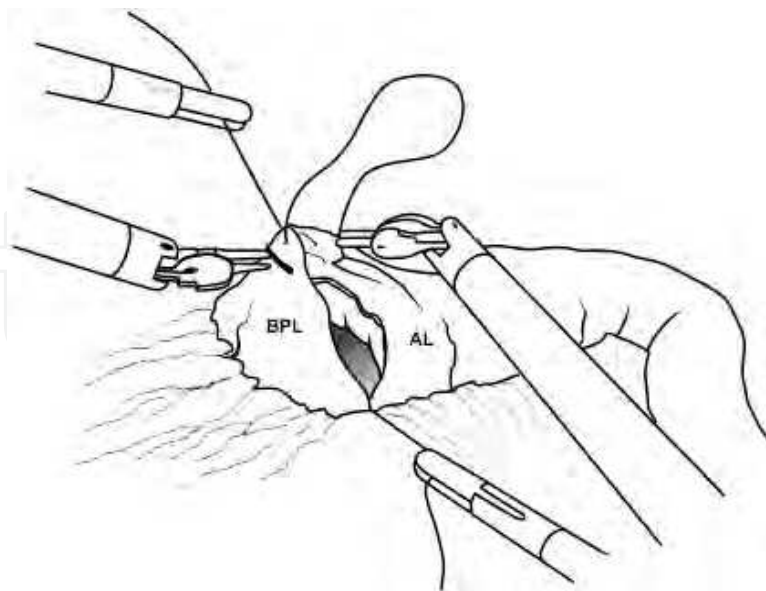


Fig. 23. A two-layered anastomosis is performed between the duodenum (Duo) and the alimentary limb (AL), which is brought up in retrocolic fashion. The robotic arms are used for suturing. The laparoscopic instruments handled by the bedside surgeon provide exposure and traction with stay sutures.

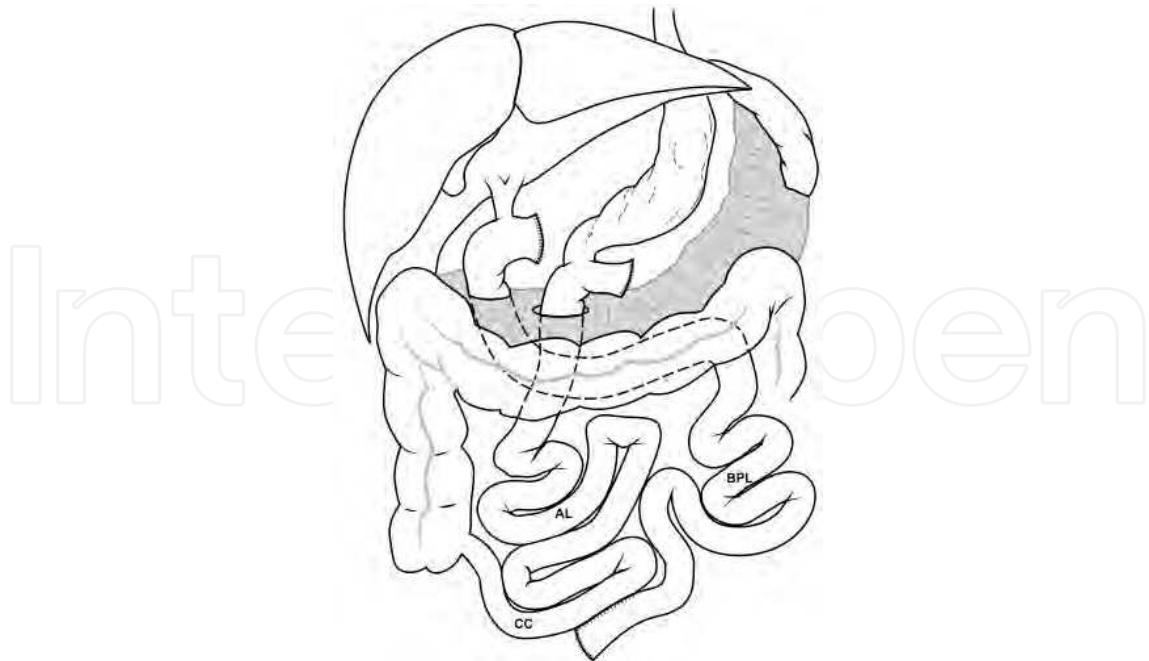


Fig. 24. The final configuration results in a 100-cm-long common channel (CC). The alimentary limb (AL) and the biliopancreatic limb (BPL) are demonstrated. The length of the AL is 250 cm.

## 6. Discussion

### 6.1 Laparoscopic adjustable gastric band vs. robotic adjustable gastric band (RAGB)

There are two series that compared LAGB vs. RAGB in the literature. Both of them demonstrated no advantages in using robotic surgery in terms of hospital stay, complications and postoperative weight loss (Edelson et al., 2011; Moser & Horgan, 2004). However, both series noticed benefits in the super obese patients such as those BMI  $\geq 50$  kg/m<sup>2</sup>. In this particular group of patients the thickness of the abdominal wall increases the torque of standard bariatric instruments. The authors attributed these findings to the characteristics of the robotic system such as longer and stiffer instrumentation, and mechanical power (Edelson et al., 2011; Jacobsen et al., 2003). Specifically, operative time in these patients is reported to be shorter than the LAGB counterparts (Edelson et al., 2011). In addition, gastric banding seems to be an acceptable training platform for the novice robotic surgeon. The increased procedural cost is another mayor disadvantage for the widespread implementation of robotics (Gill et al., 2011).

### 6.2 Laparoscopic gastric bypass vs. robotic assisted gastric bypass (RYGB) and totally robotic gastric bypass (TRYGB)

Robotic RYGB is increasingly accepted as a safe alternative to laparoscopic RYGB (Gill et al., 2011; Jacobsen et al., 2003; Moser & Horgan 2004). Evidence shows that both offer the same long-term postoperative benefits like excess weight loss and resolution of comorbidities (Snyder et al., 2008). Several authors have described a decreased gastrojejunostomy leak rate while using the robotic system (Galvani et al, 2006; Gill et al., 2011; Moser & Horgan, 2004; Snyder et al., 2008; Wilson et al., 2008). Therefore, lowering the overall complications rate of

the procedure and potentially decreasing costs (Snyder et al, 2008). An additional advantage is the shortening of the learning curve, since it has been suggested that the learning curve for laparoscopic RYGB is about a 100 cases (Schauer et al., 2003). Our experience suggested that the learning curve for achieving optimal outcomes and low complication rate plateau after the first 20 cases, indicating a shorter learning curve than conventional laparoscopy. These advantages of the robotic RYGB include the limited possibility to access different areas of the abdomen after the system is docked (Jacobsen et al., 2003; Moser & Horgan, 2004; Snyder et al., 2008). For that reason, surgeons have opted to go either the hybrid or the totally robotic approach. It is worth mentioning, that in the so-called "Totally robotic gastric bypass" a qualified bedside assistant is necessary to perform stapling of the stomach and small bowel. Making obvious also the need of further instrumentation. For these reasons, in spite of a shorter learning curve, the totally robotic gastric bypass is not widely accepted.

### **6.3 Laparoscopic sleeve gastrectomy (LSG) vs. robotic sleeve gastrectomy (RSG)**

The reported experience in RSG is scarce (Ayloo et al., 2011; Diamantis et al., 2011). Available evidence demonstrates that the procedure is safe and feasible. No clinical advantages have been shown when using RSG in terms of hospitalization, morbidity, mortality and 1-year weight loss. The use of the robot can be of benefit in the super obese with the mechanical force needed to overcome the torque of a thick abdominal wall. Obviously the precision of the system is a key advantage for surgeons that routinely oversaw the staple line. Additionally, it is also helpful as a training model for fellows and residents.

An important point to keep in mind at the time of making the decision to perform a RSG is to consider the added cost of the procedure. The routine use of the Robot for Sleeve Gastrectomy has yet to be defined.

### **6.4 Robotic assisted biliopancreatic diversion and duodenal switch (RABPD)**

The operation represents only about 0.89% of the bariatric procedures performed in the US (DeMaria et al., 2010). Since most of the BPD/DS are done open, the introduction of the robotics could potentially increase the number of minimally invasive cases performed. Conversely, the experience with RABPD is very limited. Today, there are only two studies in the literature about the use of the RABPD (Sudan et al., 2007; Wilson et al., 2008). The authors described that the main advantages include accurate suturing, better control over the size of the anastomosis, elimination of the potential for oropharyngeal and esophageal trauma while inserting the anvil of the circular stapler. The impossibility to work in different areas of the abdomen after setup it is also a disadvantage. The precision of the robot has shown low complication rates.

## **7. Conclusion**

The advantages of the robotic surgery are more obvious in more technically demanding procedures that require the creation of gastrointestinal anastomosis. The mechanical power offered by the robotic system makes this approach the attractive alternative for super obese patients.

The learning curve of the robotic system is shorter than for the standard laparoscopic approach, allowing more surgeons to offer patients the same safety and successful outcomes currently available through open surgical techniques but without the significant morbidities of large surgical wounds.


The limitation of the robotic system still remains the high operational and acquisitional cost of the system. Moreover, for certain bariatric procedures like RAGB, RSG, and the RABPD its benefits have yet to be defined.

The development of new robotic instruments, minimization of the robotic systems and cost reduction will potentially encourage bariatric surgeons to adopt this technology.

## 8. References

- Anthone, G.J., et al., *The duodenal switch operation for the treatment of morbid obesity*. *Ann Surg*, 2003. 238(4): p. 618-27; discussion 627-8.
- Ayloo, S., et al., *Robot-assisted sleeve gastrectomy for super-morbidly obese patients*. *J Laparoendosc Adv Surg Tech A*, 2011. 21(4): p. 295-9.
- Cadiere, G.B., et al., *The world's first obesity surgery performed by a surgeon at a distance*. *Obes Surg*, 1999. 9(2): p. 206-9.
- Cadiere, G.B., et al., *Laparoscopic adjustable gastric banding*. *Semin Laparosc Surg*, 2002. 9(2): p. 105-14.
- Dargent, J., *Laparoscopic adjustable gastric banding: lessons from the first 500 patients in a single institution*. *Obes Surg*, 1999. 9(5): p. 446-52.
- DeMaria, E.J., et al., *Baseline data from American Society for Metabolic and Bariatric Surgery-designated Bariatric Surgery Centers of Excellence using the Bariatric Outcomes Longitudinal Database*. *Surg Obes Relat Dis*, 2010. 6(4): p. 347-55.
- Diamantis, T., et al., *Initial experience with robotic sleeve gastrectomy for morbid obesity*. *Obes Surg*, 2011. 21(8): p. 1172-9.
- Dixon, J.B. and P.E. O'Brien, *Changes in comorbidities and improvements in quality of life after LAP-BAND placement*. *Am J Surg*, 2002. 184(6B): p. 51S-54S.
- Edelson, P.K., et al., *Robotic vs. conventional laparoscopic gastric banding: a comparison of 407 cases*. *Surg Endosc*, 2011. 25(5): p. 1402-8.
- Galvani, C. and S. Horgan, *[Robots in general surgery: present and future]*. *Cir Esp*, 2005. 78(3): p. 138-47.
- Galvani, C., et al., *Laparoscopic adjustable gastric band versus laparoscopic Roux-en-Y gastric bypass: ends justify the means?* *Surg Endosc*, 2006. 20(6): p. 934-41.
- Gill, R.S., et al., *Robotic-assisted bariatric surgery: a systematic review*. *Int J Med Robot*, 2011.
- Giusti, V., et al., *Effects of laparoscopic gastric banding on body composition, metabolic profile and nutritional status of obese women: 12-months follow-up*. *Obes Surg*, 2004. 14(2): p. 239-45.
- Horgan, A.F., et al., *Atypical diverticular disease: surgical results*. *Dis Colon Rectum*, 2001. 44(9): p. 1315-8.
- Horgan, S. and D. Vanuno, *Robots in laparoscopic surgery*. *J Laparoendosc Adv Surg Tech A*, 2001. 11(6): p. 415-9.
- Jacobsen, G., R. Berger, and S. Horgan, *The role of robotic surgery in morbid obesity*. *J Laparoendosc Adv Surg Tech A*, 2003. 13(4): p. 279-83.

- Kim, W.W., et al., *Laparoscopic vs. open biliopancreatic diversion with duodenal switch: a comparative study*. J Gastrointest Surg, 2003. 7(4): p. 552-7.
- Kim, K. and C. Buffington, *Totally robotic gastric bypass: approach and technique*. J Robotic Surg, 2011. 5(1): p. 47-50.
- Lee, C.M., P.T. Cirangle, and G.H. Jossart, *Vertical gastrectomy for morbid obesity in 216 patients: report of two-year results*. Surg Endosc, 2007. 21(10): p. 1810-6.
- Mohr, C.J., G.S. Nadzam, and M.J. Curet, *Totally robotic Roux-en-Y gastric bypass*. Arch Surg, 2005. 140(8): p. 779-86.
- Mokdad, A.H., et al., *Actual causes of death in the United States, 2000*. JAMA, 2004. 291(10): p. 1238-45.
- Moser, F. and S. Horgan, *Robotically assisted bariatric surgery*. Am J Surg, 2004. 188(4A Suppl): p. 38S-44S.
- Muhlmann, G., et al., *DaVinci robotic-assisted laparoscopic bariatric surgery: is it justified in a routine setting?* Obes Surg, 2003. 13(6): p. 848-54.
- Nehoda, H., et al., *Results and complications after adjustable gastric banding in a series of 250 patients*. Am J Surg, 2001. 181(1): p. 12-5.
- Ogden, C.L., et al., *Prevalence and trends in overweight among US children and adolescents, 1999-2000*. JAMA, 2002. 288(14): p. 1728-32.
- Podnos, Y.D., et al., *Complications after laparoscopic gastric bypass: a review of 3464 cases*. Arch Surg, 2003. 138(9): p. 957-61.
- Regan, J.P., et al., *Early experience with two-stage laparoscopic Roux-en-Y gastric bypass as an alternative in the super-super obese patient*. Obes Surg, 2003. 13(6): p. 861-4.
- Ren, C.J., E. Patterson, and M. Gagner, *Early results of laparoscopic biliopancreatic diversion with duodenal switch: a case series of 40 consecutive patients*. Obes Surg, 2000. 10(6): p. 514-23; discussion 524.
- Schauer, P., et al., *The learning curve for laparoscopic Roux-en-Y gastric bypass is 100 cases*. Surg Endosc, 2003. 17(2): p. 212-5.
- Snyder, B. and e. al., *Lowering gastrointestinal leak rates: a comparative analysis of robotic and laparoscopic gastric bypass*. J Robotic Surg, 2008. 2: p. 159-163.
- Snyder, B.E., et al., *Robotic-assisted Roux-en-Y Gastric bypass: minimizing morbidity and mortality*. Obes Surg, 2010. 20(3): p. 265-70.
- Sudan, R., V. Puri, and D. Sudan, *Robotically assisted biliary pancreatic diversion with a duodenal switch: a new technique*. Surg Endosc, 2007. 21(5): p. 729-33.
- Wilson, E.B., et al., *Robotic Bariatric Surgery: Outcomes of Laparoscopic Biliopancreatic Diversion and Gastric Bypass*. Surg Obes Relat Dis, 2008. 4: p. 312-357.



## **Advanced Bariatric and Metabolic Surgery**

Edited by Dr. Chih-Kun Huang

ISBN 978-953-307-926-4

Hard cover, 326 pages

**Publisher** InTech

**Published online** 29, February, 2012

**Published in print edition** February, 2012

Bariatric surgery has gained importance in the last 20 years because of the high prevalence of global obesity, and the vast understating of the physiological and pathological aspects of obesity and associated metabolic syndromes. This book has been written by a number of highly outstanding authors and pioneering bariatric surgeons from all over the world. The intended audience for this book includes all medical professionals involved in caring for bariatric patients. The chapters cover the choice of operation, preoperative preparation including psychological aspect, postoperative care and management of complication. It also extends to concept and result of metabolic surgery and scarless bariatric surgery.

### **How to reference**

In order to correctly reference this scholarly work, feel free to copy and paste the following:

Ulises Garza, Angela Echeverria and Carlos Galvani (2012). Robotic-Assisted Bariatric Surgery, *Advanced Bariatric and Metabolic Surgery*, Dr. Chih-Kun Huang (Ed.), ISBN: 978-953-307-926-4, InTech, Available from: <http://www.intechopen.com/books/advanced-bariatric-and-metabolic-surgery/robotic-assisted-bariatric-surgery>

**INTECH**  
open science | open minds

#### **InTech Europe**

University Campus STeP Ri  
Slavka Krautzeka 83/A  
51000 Rijeka, Croatia  
Phone: +385 (51) 770 447  
Fax: +385 (51) 686 166  
[www.intechopen.com](http://www.intechopen.com)

#### **InTech China**

Unit 405, Office Block, Hotel Equatorial Shanghai  
No.65, Yan An Road (West), Shanghai, 200040, China  
中国上海市延安西路65号上海国际贵都大饭店办公楼405单元  
Phone: +86-21-62489820  
Fax: +86-21-62489821



© 2012 The Author(s). Licensee IntechOpen. This is an open access article distributed under the terms of the [Creative Commons Attribution 3.0 License](#), which permits unrestricted use, distribution, and reproduction in any medium, provided the original work is properly cited.

IntechOpen

IntechOpen