

We are IntechOpen, the world's leading publisher of Open Access books Built by scientists, for scientists

4,800

Open access books available

122,000

International authors and editors

135M

Downloads

Our authors are among the

154

Countries delivered to

TOP 1%

most cited scientists

12.2%

Contributors from top 500 universities



WEB OF SCIENCE™

Selection of our books indexed in the Book Citation Index
in Web of Science™ Core Collection (BKCI)

Interested in publishing with us?
Contact book.department@intechopen.com

Numbers displayed above are based on latest data collected.

For more information visit www.intechopen.com



Research and Clinical Applications of Facial Analysis in Dentistry

Barbara de Lima Lucas¹, Roberto Bernardino Júnior²,
Luiz Carlos Gonçalves³, Maria Beatriz Duarte Gavião¹
and Vanderlei Luiz Gomes³

¹*Piracicaba Dental School, University of Campinas, Piracicaba, Sao Paulo,*

²*Biomedical Sciences Institute,*

³*Faculty of Dentistry, Federal University of Uberlandia, Uberlandia, Minas Gerais
Brazil*

1. Introduction

Anthropometry is the study of human body measurement for use in anthropological classification and comparison in living subjects (Farkas et.al., 2005). It has been applied in medical areas such as plastic surgery, craniofacial development, forensic science and bioengineering as well as in diverse industries such as clothing, glasses and shoes manufacturing (Farkas et.al., 2005; Germec-Cakan et.al., 2010; Fourie et.al., 2011). This traditional method of finding required body dimensions by manual measurements has many sociological, logistical and technical drawbacks such as prolonged time, skilled researcher for consistency and accuracy of measurements, undesirable physical contact between the subject and the researcher, required presence of people from different demographic categories or travel of researcher with equipment. If these dimensions are extracted from the stored digital human models, above drawbacks can be eliminated (Nechala et.al., 1999; Lucas et.al., 2009; Fourie et.al., 2011).

Current literature presents a range of techniques and methods to measure human body parts for both research and clinical purposes. Photogrammetry, which is a method that encloses the image acquisition to obtain such measurements, is one of these techniques (Nechala et.al., 1999; Germec-Cakan et.al., 2010; Fourie et.al., 2011). It has been adopted by medicine in the middle of the 19th century, though, without exhibiting any useful applications. Nowadays, due to its recent technical advances this noninvasive procedure is related to particular relevant advantages as follows: the absence of soft tissue compression, usefulness with low cost and easy transportation. In addition, the image registration is an important source of documentation enabling to compare results among studies and their reproducibility (Nechala et.al., 1999; Gomes et.al., 2006; Lucas et.al., 2009; Germec-Cakan et.al., 2010; Maal et.al., 2010; Fourie et.al., 2011). For all these reasons, photogrammetry has reacquired enormous popularity in research and clinical practice.

Facial anatomy is a primary characteristic by which individuals present themselves to the external world. This influences the subjective perception of a given person by another person, for instance in terms such as 'attractive' or 'notable' (Frush and Fisher, 1958;

Ackerman et.al., 1998; Gomes et.al., 2006; Gomes, et.al. 2008; Gomes et.al., 2009; Lucas et.al., 2009). In Dentistry, particularly during rehabilitation treatments of the dentofacial dimensions, limited accepted protocols are available to provide the esthetic quality desired by the patient. Usually, a natural appearance is pursued (Frush and Fisher, 1958). The facial analysis performed during the first dental clinical exam has been used successfully to offer essential evidences for treatment planning mainly when associated to photogrammetry (Gomes et.al., 2006; Gomes et.al., 2008; Lucas et.al., 2009; Germec-Cakan et.al., 2010; Fourie et.al., 2011). The issue of increased productivity in a dental practice is of great interest to dentists, not only because of its economic implication but also because the demand by the public for more dental services is ever increasing. The armamentarium of facial cosmetic, orthognatic and maxillofacial surgery allows correction of greater portion of facial abnormalities. However, surgical correction reaches far beyond the scope of this chapter. The following discussion is limited strictly to methods of recognition and diagnosis of faults in the balance of the face.

2. Esthetic diagnoses

Many professionals in both medical and dental literature have expressed interest in facial balance, harmony, and unity. The diagnosis and the careful acquisition of complementary exams are the basis of the suitable treatment planning (Frush and Fisher, 1958; Germec-Cakan et.al., 2010). However, successful esthetic outcomes of dentofacial restorations comprise of existing skills that are associated to much more than the ability of diagnosing and correcting functional and pathological irregularities. Esthetic restorations are not only associated with pathology and function but also with patient's attitudes related to his/her appearance, personality, career fields and social life. It is, therefore, influenced by culture and self-image (Frush and Fisher, 1958).

Any scientific analysis of a physically beautiful face of a patient ultimately must be approached on a mathematical basis. Proportion is the certain ratio between parts, and proportional means a proper correlation of parts among themselves. Efforts in the past were made to find principles of esthetic and functional equilibrium for use as guides in clinical practice. It is reputed, that knowledge about "Gold Proportion" Pythagor has got from products of the Egyptian and Babylon scientists (Mack, 1991; Preston, 1993). The Golden Section is also known as the Golden Ratio, the Golden Mean, the Golden Cut or the Divine proportion. It has been considered for a long period to present proportions that is most appealing, soothing, or attractive to the human psyche, but its implications extend to encompassing space or time and the very foundations of physics and abstract science. The proportions of pyramids in Giza, home appliances and ornaments from Tutanhamon tomb testify, that under their creation the Egyptian masters were guided by a principle of "Gold Proportion". The facade of ancient Greek temple Parthenon was also built by the same principle. During archeological digs of this temple the compasses which sculptors and architects of an ancient world used has been found. The "Gold Proportion" is mentioned in the work which has reached us "Beginning" the author is the scientist of antique epoch Euclid (Ricketts, 1981; Mack, 1991; Preston, 1993).

According to Vadachkoriia et. al. (2007), Luka Pacholi published the book of the "Divine Proportion" illustrated by Leonardo de Vinci, in 1509, Italy. This work has been recognized as a "Hymn of a Gold Proportion". In 1885, the German researcher professor Zeising published his work "Aesthetic researches". When Zeising has received numerical values of

piece length, he saw that they coincided with figures of some numerical sequence, which was offered by the great Italian mathematician of Middle Ages Fibonacci (or Leonardo Pisano). In his composition the "Abacus Book" Leonardo Fibonacci showed aforesaid sequence of numbers, by means of which he has explained the formula of duplication of rabbits. In sequence of Fibonacci, in some division of its term on previous, it is received irrational number $1,61803398875\dots$, known as Fibonacci. It is used in the reduced, approximated kind as $F = 1,618$ or $\phi = 0,618$ (Ricketts, 1981; Mack, 1991; Preston, 1993). In the past, dental professionals used these concepts as a guide in the facial analysis of patients, and approximate conformity with these principles was considered one of the objectives of treatment (Ricketts, 1981; Nanda and Ghosh, 1995). Classic studies produced aesthetic canons in which the dimensions of nose, lips, and chin were stated to follow to mathematical ratios (Ricketts, 1981; Mack, 1991). In his works Ricketts has specified, that mentioned data is necessary to be considered in aesthetic stomatology during teeth reconstruction. For example, Ricketts (1982) stated that the distance between the base of the nose to the rima oris is in Golden Proportion to the distance between the rima oris to the chin. Also, the interalar width is supposed to be in golden proportion with the lip commissure distance. Marquardt (2002), an oral and maxillofacial surgeon from California, analyzed human face from ancient times to modern day and discovered that beauty is not only related to phi but can be defined for both genders and for all races and cultures, with a method and apparatus for analyzing facial configurations and components named the "Beauty Mask". This method patented from 1997 to 1999 (number 5867588) analyzes the form and proportion of faces and components of those faces (e.g., eyes, nose, mouth, etc.) and establishes a reference system to analyze human faces for surgical, cosmetic, and identification purposes.

Nowadays, some studies have suggested that, in general, there are no concrete evidences to consider the Golden Proportion as the ideal aesthetic standard to rehabilitate neither human face or in the anterior dental segment (Nikgoo et al., 2011; Condon et al., 2011; Al-Johany et al., 2011). Recent observations of 81 Brazilian undergraduate students (37 females and 44 males), with mean age of 21 years old, showed that facial architecture was not significantly dimensioned according to Divine Proportion. Table 1 and 2 present, respectively, the horizontal and vertical measurements of the face (mean and standard deviation) obtained through photogrammetry for the total sample and when divided to gender. For the total sample and when it was divided to gender, table 3, 4 and 5 present the mean ratios and standard deviation found to each facial relationship compared, as well as the percentage of golden ratio found in each comparison with the highest percentages highlighted.

The lack of Divine Proportion among dental and facial structures are also stated in recent literature (Bukhary et al., 2007; Murthy and Ramani, 2008; Mizumoto et al., 2009; Nikgoo et al., 2011; Condon et al., 2011; Al-Johany et al., 2011) attesting this proportion as an unsuitable method to relate dentofacial dimensions with natural or even 'attractive' appearance during rehabilitation treatments.

According to the values presented on table 3, the lip commissure distance was in Golden Proportion to the interalar distance only in 1,3% of the total sample (LCD-IAD), and the mean ratio found was 1,395 instead of 1,618 as stated by Ricketts (1981). Another relationship tested was the upper lip length (distance from the base of the nose to the lips) and the lower third of the face (UL-LT). As shown on table 4, no significant percentage for Golden Proportion (0,0%) was found and the mean ratio corresponded to 0,334 instead of 0,618 (see table 3).

	Total		Female		Male	
	Mean	SD	Mean	SD	Mean	SD
Horizontal						
RE	3.185	0.212	3.128	0.212	3.258	0.191
LE	3.205	0.213	3.135	0.172	3.296	0.229
MCE	3.438	0.312	3.391	0.295	3.498	0.328
MPD	6.846	0.434	6.690	0.405	7.049	0.388
RE+MCE	6.622	0.400	6.520	0.404	6.756	0.358
LE+MCE	6.643	0.410	6.527	0.382	6.795	0.401
LCE	9.828	0.545	9.655	0.518	10.052	0.501
IAD	4.081	0.350	3.911	0.314	4.302	0.260
LCD	5.670	0.439	5.469	0.321	5.931	0.438
BZG	14.178	0.808	13.787	0.716	14.686	0.621

Table 1. Mean, in centimeters, and standard deviation (SD) of the horizontal facial measurements for the total sample and when divided to gender: RE (right eye width), LE (left eye width), MCE (distance between the medialis canthus of the eyes), MPD (mid-pupillary distance), RE-MCE and LE-MCE (distance between the lateral canthi of one eye - right or left - to the medial canthi of the other eye), LCE (distance between the lateral canthus of the eyes), IAD (interalar distance), LCD (lip commissure distance), BZG (bizigomatic width)

	Total		Female		Male	
	Mean	SD	Mean	SD	Mean	SD
Vertical						
UT	6.318	0.792	6.025	0.696	6.699	0.755
MT	6.685	0.494	6.632	0.513	6.754	0.468
LT	7.393	0.643	7.083	0.511	7.797	0.574
UT-LT	20.396	1.310	19.740	1.065	21.250	1.096
UL	2.471	0.268	2.404	0.230	2.556	0.293
LL-C	4.818	0.463	4.567	0.345	5.144	0.390
LE-C	12.191	0.998	11.694	0.633	12.838	1.022
RE-C	12.284	0.865	11.765	0.583	12.960	0.689
LE-LC	7.477	0.567	7.205	0.455	7.831	0.503
RE-LC	7.518	0.567	7.245	0.449	7.872	0.508

Table 2. Mean, in centimeters, and standard deviation (SD) of the vertical facial measurements for the total sample and when divided to gender: UT (upper third), MT (middle third), LT (lower third), UL (upper lip length), LL-C (distance between the lower lip to the chin), LE-C and RE-C (distance between the eyes - left or right - to the chin), LE-LC and RE-LC (distance between the eyes - lefts or right - to the lip commissure)

Horizontal	Total			Female			Male		
	MR	SD	GR	MR	SD	GR	MR	SD	GR
MCE:IAD	0.846	0.083	0.0%	0.870	0.079	0.0%	0.815	0.080	0.0%
LCD:IAD	1.395	0.112	1.3%	1.406	0.126	2.3%	1.380	0.091	0.0%
IAD:MPD	0.597	0.044	27.6%	0.585	0.045	27.9%	0.611	0.040	27.3%
BZG:IAD	3.488	0.221	0.0%	3.541	0.256	0.0%	3.419	0.141	0.0%
LCE:IAD	2.420	0.183	0.0%	2.480	0.192	0.0%	2.342	0.136	0.0%
LCD: LCE	0.578	0.043	19.7%	0.567	0.037	18.6%	0.591	0.046	21.2%
LCD:MCE	1.660	0.173	11.8%	1.622	0.143	14.0%	1.709	0.198	9.1%
LCD:MPD	0.830	0.062	0.0%	0.819	0.057	0.0%	0.843	0.068	0.0%
LCD:BZG	0.400	0.028	0.0%	0.398	0.030	0.0%	0.404	0.026	0.0%
MCE-LCE	2.071	0.127	0.0%	2.082	0.118	0.0%	2.056	0.138	0.0%

Table 3. Mean ratio (MR), standard deviation (SD) and the percentage of the Golden Ratio (GR) found after comparing all horizontal facial measurements for the total sample and when divided to gender. See footnotes table 1

Verticais	Total			Female			Male		
	MR	SD	GR	MR	SD	GR	MR	SD	GR
(UT+ MT):LT	1.769	0.170	1.3%	1.769	0.170	1.3%	1.769	0.170	1.3%
LT:UT-LT	0.923	0.007	0.0%	0.923	0.007	0.0%	0.923	0.007	0.0%
LT:LE-C	0.608	0.047	42.1%	0.608	0.047	42.1%	0.608	0.047	42.1%
LT:RE-C	0.602	0.030	43.4%	0.602	0.030	43.4%	0.602	0.030	43.4%
LE-LC:LE-C	0.614	0.031	63.2%	0.614	0.031	63.2%	0.614	0.031	63.2%
RE-LC:RE-C	0.612	0.022	60.5%	0.612	0.022	60.5%	0.612	0.022	60.5%
UL:LE-LC	0.331	0.028	0.0%	0.331	0.028	0.0%	0.331	0.028	0.0%
UL:RE-LC	0.329	0.027	0.0%	0.329	0.027	0.0%	0.329	0.027	0.0%
LL-C:LE-LC	0.646	0.058	21.1%	0.646	0.058	21.1%	0.646	0.058	21.1%
LL-C:RE-LC	0.642	0.059	23.7%	0.642	0.059	23.7%	0.642	0.059	23.7%
LL-C:LT	0.652	0.027	28.9%	0.652	0.027	28.9%	0.652	0.027	28.9%
UL:LT	0.334	0.024	0.0%	0.334	0.024	0.0%	0.334	0.024	0.0%

Table 4. Mean ratio (MR), standard deviation (SD) and the percentage of the Golden Ratio (GR) found after comparing all vertical facial measurements for the total sample and when divided to gender. See footnotes table 2

The dentist and health professionals that work with esthetics overemphasize attractive dentofacial architecture not only from form and functions with stereotyped orientated dimensions but also from organic expressions of the patient’s personality, lifestyle, and

other features that differentiate one individual from another. Accordingly, the evaluation of facial beauty is subjective, since the balance and harmony of its components are not indicative that the face is attractive. In fact, asymmetric and disproportionate dentofacial dimensions contribute significantly with esthetic problems, but fortunately they can be recognized and diagnosed objectively (Ras et.al., 1995; Aksu et.al., 2010; Germec-Cakan et.al., 2010).

Horizontal and Vertical	Total			Female			Male		
	MR	SD	GR	MR	SD	GR	MR	SD	GR
UL:LCD	0.437	0.051	0.0%	0.441	0.049	0.0%	0.433	0.055	0.0%
LCD:LL-C	1.185	0.118	0.0%	1.205	0.121	0.0%	1.158	0.110	0.0%

Table 5. Mean ratio (MR), standard deviation (SD) and the percentage of the Golden Ratio (GR) found after comparing vertical and horizontal facial measurements for the total sample and when divided to gender. See footnotes table 1 and 2

3. Facial analysis protocol

Photographs of a patient's face provide an enormous amount of information for to guide diagnosis and treatment planning, as well as to document preoperative and postoperative conditions. It can be said that, for the ideal diagnosis of dentofacial imbalances, the evaluation begins with the face of the patient being visualized in frontal and lateral view followed by the dental clinical exam. Facial analysis was underestimated for a long time due to the lack of clinical parameters such as those used in radiographic images. However, radiography produces inaccurate soft tissues registration, and consequently, avoids their esthetic evaluation (Nechala et.al., 1999; Edler et.al., 2003; Good et.al., 2006; Fourie et.al., 2001). Additionally, traditional anthropometry produces inaccurate values due to the soft tissue compression. Though, to perform photogrammetry accurately a standardized protocol must be followed during the image registrations, to guarantee a mathematical relationship between the real and the image dimensions. The following section of this chapter discusses reliable approach to obtaining frontal and profile photographs of the face. Careful use of the equipment and techniques described in this part will enable clinicians and researchers to make useful full-face and profile records of patients when needed.

3.1 Materials and equipment

A single-lens reflex (SLR) camera system with a 90 mm or longer focal length is needed. Shorter focal lengths tend to distort the subject's face in the center of the image. This distortion is known in general photography as "barrel distortion." Barrel distortion is a lens effect resulting in images that are "spherized" at their center (Vargas, 2003). The camera should be held in a tripod, in front of the object to avoid having blurry edges because of unsteady hands or other instable support. The background makes the image stand out properly and for this reason is important to improve the visualization of the object. A

nonreflective background of black, light-gray or light-blue is commonly used (Vargas, 2003). The subject must be positioned about 120 centimeters in front of the background to avoid shadows from the subject on the background. A piece of black or blue velvet is ideal due to the absorption of the light by the fabric (Vargas et.al., 2003; Lucas et.al, 2009). A white background does not provide sufficient distinction with the subject. Shiny or hard surfaces will detour the absorption of light rays, and for this reason neutral gray backgrounds are preferred. The light also plays an important part in the photographic process. The light rays that are emitted from sunlight and artificial light (tungsten light bulbs or fluorescent light) are different. Also, the angle of the light rays reflecting or being absorbed by the object will produce different effects (Laws, 2001). The illumination of the subject can be obtained with two studio flashes attached to the camera or activated by a remote-control unit. The flashes must be positioned 45 degree angle each side in relation to the sagittal plane of the face (facial median line). Flash units used in intraoral photography can be used, but these may not illuminate the subject properly, resulting in the appearance of undesirable shadows in the background (Vargas, 2003). When a studio flash is not accessible and an intraoral flash must be used, some restrictions on quality should be expected. The intraoral flash does not have the power to evenly illuminate the subject, necessitating the use of large apertures and resulting in a shallow depth of field, teeth frontal aspects for example. If a nonblack background is used, remove the flash from the lens and hold it above the camera to eliminate "red eye" as well as undesirable shadows over the background. The natural light source is recommended instead of a single flash close to the camera, such as is obtained with an intraoral unit.

3.2 Facial positioning

The patient's posture is essential to assure standardized digital image. The head must be positioned at the center of the image. Also, the head during the image registration must be positioned according to the three reference section planes: transverse, coronal and sagittal (Gomes et.al. 2006, Gomes et.al., 2008; Gomes et.al., 2009; Lucas et.al., 2009). Including the patient's ears in the image may be important. The ears (porion, the superior aspect of the external auditory meatus) and the eyes (orbitale, the inferior point of the orbital rim) define the Frankfort horizontal plane. The horizontal plane of Frankfort is the reference for transverse plane and it may be parallel to the floor plane. The mid-pupillary line must also be parallel to the floor plane, with the patient looking forward (horizon line). Regarding the sagittal plane, facial median line must be perpendicular to the floor. Figure 1 A and B illustrates facial positioning for anterior and lateral analysis, respectively.

The lower third of the face can have far reaching effects on facial aesthetics, not just on the peri-oral areas but on the whole face (Mohindra and Bulman, 2002; Gomes et.al, 2008). Mandibular posture greatly depends on head posture. Thus, it is compulsory to state if the subject is in rest vertical dimension (RVD)¹ or in occlusal vertical dimension (OVD) with the teeth in contact. The seated or supine position may also influence since it is the habitual mandibular position is determined by the stiffness that results from the postural muscle tone acting on the mandible (Woda et.al., 2001).

¹Craniofacial muscles are in tonic balance, with labial and mental muscles relaxed.

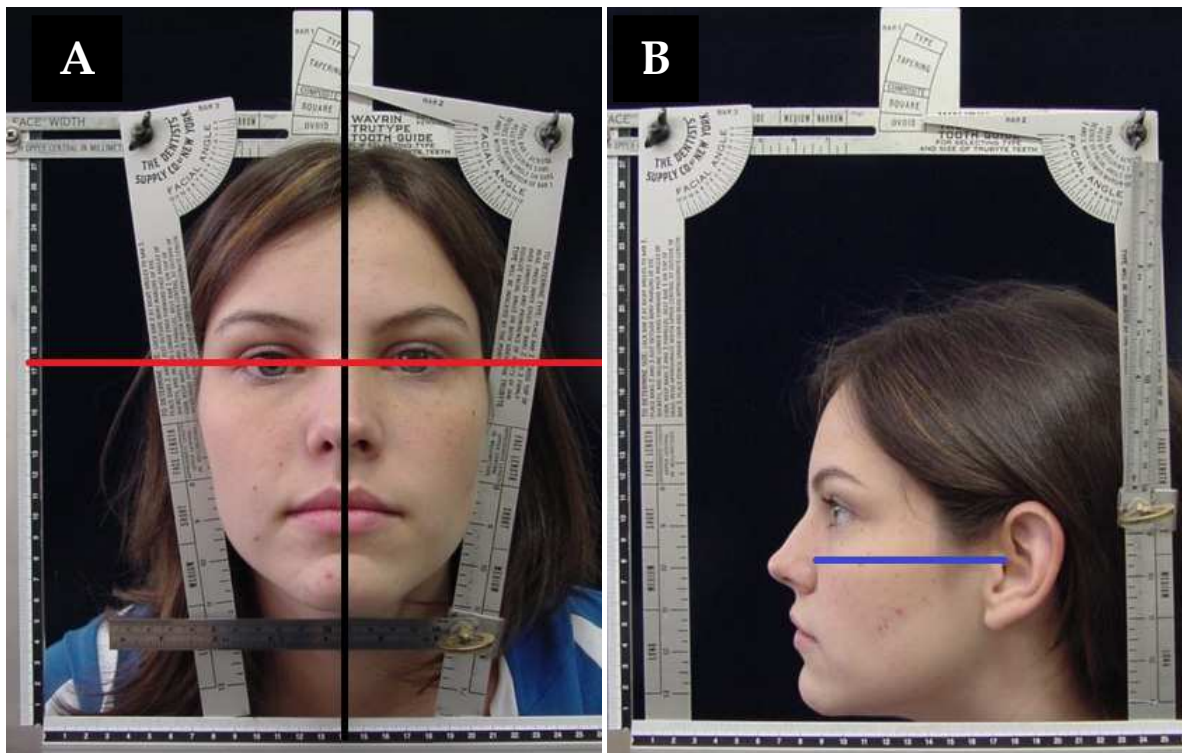


Fig. 1. Reference lines for facial positioning: A- Frontal view: mid-pupillary line (red) and facial median line (black); and B- Frankfort plane (blue)

3.3 Anatomical parameters

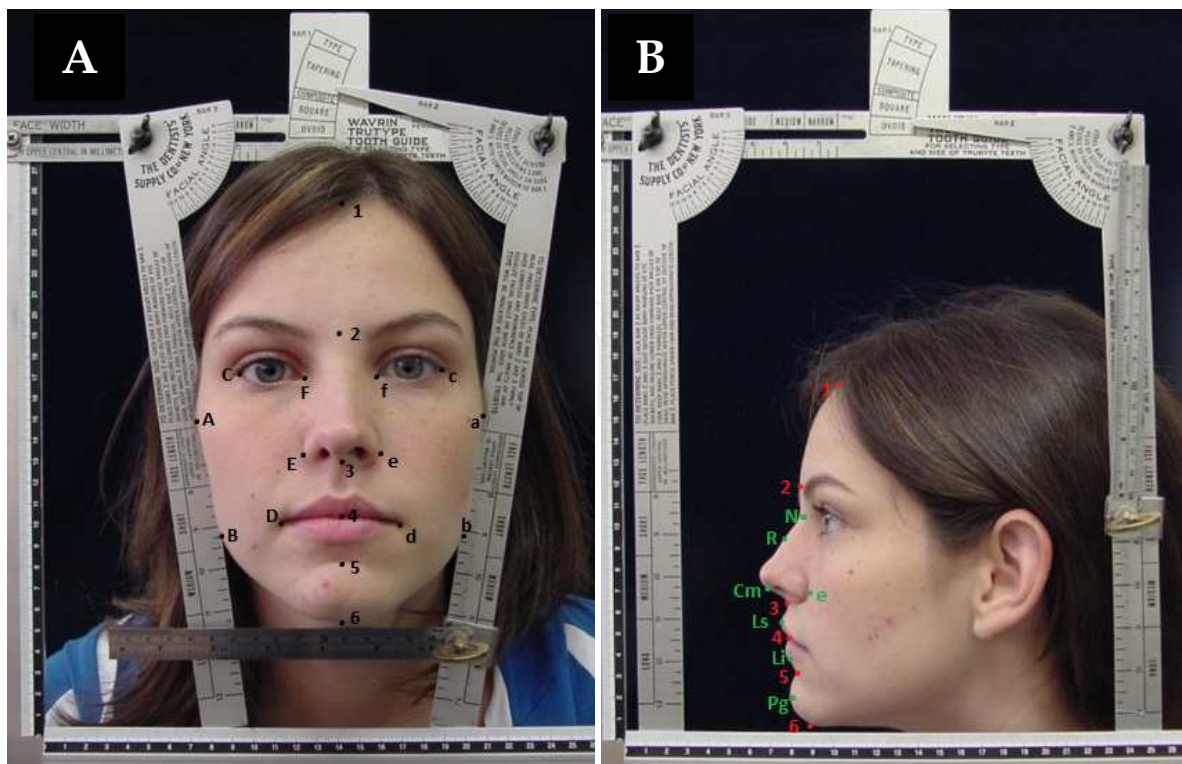


Fig. 2. Biometric Points for facial analysis: A- Frontal view; C- Lateral view

3.3.1 Frontal view

Considering the facial median line (Figure 1A), the face must be examined in a frontal view to evaluate bilateral symmetry and horizontal proportions among facial structure's sizes: nasal width, width of the eyes and the masseter muscles conditions. The vertical proportions of the face must be evaluated in the same facial position, however, with the pupil lines as the reference (Figure 1A). The vertical proportion enables to classify the facial pattern as well as the division of the face in three thirds. Figure 2A illustrates biometric points for dividing the face in three thirds: (1) upper third, between points 1 and 2; (2) middle third, between points 2 and 3; and (3) lower third, between points 3 and 6. Also, the lower third can be divided in upper lip length (between points 3 and 4), lower lip length (between points 4 and 5) and the chin corresponding to the mental region (between points 5 and 6). Thus, the frontal view is important to calculate facial asymmetry and disproportions considering the laterolateral and longitudinal axis.

3.3.2 Lateral view

In the lateral view, not only the vertical thirds but also the maxillomandibular relationship can be assessed allowing both the anatomic evaluation of the lips and the classification of the facial profile. As seen on figure 2B, biometric points are used to measure vertical dimensions. In this view, angular measurements can also be assessed: nasofacial angle, nasolabial angle and mentolabial angles. So, the lateral view enables the estimation of the vertical disproportions on the longitudinal axis and the horizontal discrepancies on the anteroposterior axis.

4. Relationship between dentofacial structures

It is questionable if the Golden Proportion can really reproduce the natural appearance during the restoration of dentofacial proportions. Baker and Woods (2001) concluded that there is no correlation between esthetic rating and divine proportion in various facial and cephalometric ratios, either before or after orthodontic/orthognathic surgical treatment. However, it is a consensus that facial architecture is correlated (Powell and Humphreys, 1984; Gomes et. al. 2006; Gomes at. al, 2008; Gomes et. al., 2009). The mathematical relationship between dentofacial structures can improve mainly the rehabilitation of the dental dimensions of the maxillary anterior segment for patients with tooth agenesis from craniofacial anomalies or those who lost their teeth from oral pathology or craniofacial traumas (Gomes et.al., 2009; Lucas et.al., 2009; Germec-Cakan et.al., 2010).

When anthropometric methods were introduced into clinical practice, features differentiating various races/ethnic groups were revealed. Farkas et. al. (2005) published anthropometric values found after evaluating in a preliminary study, 1470 healthy subjects (18 to 30 years), 750 males and 720 females. The largest group (780 subjects, 53.1%) came from Europe, all of them Caucasians. Three groups were from the Middle-East (180 subjects, 12.2%), five groups from Asia (300 subjects, 20.4%) and four groups from peoples of African origin (210 subjects, 14.3%). From all facial measurements, the orbital regions exhibited the greatest variations in identical and contrasting measurements in comparison to North American White (NAW) subjects. Nose heights and widths contrasted sharply: in relation to NAW the nose was very or extremely significantly wide in both sexes of Asian and Black ethnic groups. Among Caucasians, nose height significantly differed from NAW in three

ethnic groups, with one shorter and two greater. In the Middle Eastern groups nose width was identical to those of NAW but the height was significantly greater.

Normative data of facial measurements are indispensable to precise determination of the degree of deviations from the normal. Surgeons require access to craniofacial databases based on accurate anthropometric measurements in order to study and to treat successfully congenital or post-traumatic facial disfigurements in members of different groups. Comparison among the ethnic groups' databases offered the most suitable way to select a method for successful treatment. The following section of this chapter discusses reliable mathematical relationships obtained from photogrammetry to guide oral rehabilitation treatments. Concepts and techniques described in this part will enable clinicians and researchers to understand dentofacial architecture.

4.1 Frontal view

Three different conditions can be registered in frontal aspect: smiling, in RVD or in OVD. In addition to displaying anterior tooth dimensions, the image of the patient's smile is suggested when the lip-tooth relationship is the aim of the observer.

According to Johnson and Moore (1997) the lips are fleshy folds consisting of skin superficially and mucous membrane internally, with muscle, loose connective tissue, nerves and blood vessels contained between them. The sphincter of the lips is the orbicularis oris. It consists of circular fibres surrounding the orifice of the mouth. Some of its fibres are contained entirely within the lips while others are contributed from the dilator muscles and especially from buccinator. The central fibres of buccinator decussate at the corner of the mouth so that those from above pass to the lower lip and vice versa. Many of the fibres that are contained entirely within orbicularis oris pass obliquely through the thickness of the lips from the dermis of the skin on the outer labial surface to the mucous membrane on the inner aspect. Lee (1988) stated that the muscle fibres decussate in the midline and vertical as well as oblique muscle fibre extensions insert into the dermis in the region of the midline philtral groove and the philtral ridges. A dynamic role is postulated of the role of orbicularis oris muscle in giving rise to the unique configuration of the philtrum. Contraction of orbicularis oris compresses the lips against the teeth as well as closing the oral orifice. Due to its instability, the measurement of this facial part is a complex procedure. Ackerman and Ackerman (2002) used photogrammetry to measure the patient's dynamic lip-tooth relationship. Through this method the clinician can incorporate smile analysis into routine treatment planning. Esthetic smile design is a multifactorial decision-making process that allows the clinician to treat patients with an individualized, interdisciplinary approach.

The upper and lower lips frame the display zone of the smile. Within this framework, the components of the smile are the teeth and the gingival scaffold (Fig. 3). The soft-tissue determinants of the display zone are lip thickness, intercommissure width, interlabial gap, smile index (width/height), and gingival architecture. Although the commissures of the lips form lateral borders of the smile, the eye can perceive inner and outer commissures, as delineated by the innermost and outermost confluences, respectively, of the vermilion of the lips at the corners of the mouth (Fig.3). The curve formed by the incisal edges of the maxillary anterior teeth was named by Ackerman and Ackerman (1998) of "smile arc" (Figure 4). The smile arc is described as consonant when there is a parallelism between the smile arc and the curvature of the lower lip, and as less esthetic if the smile arc is flat.

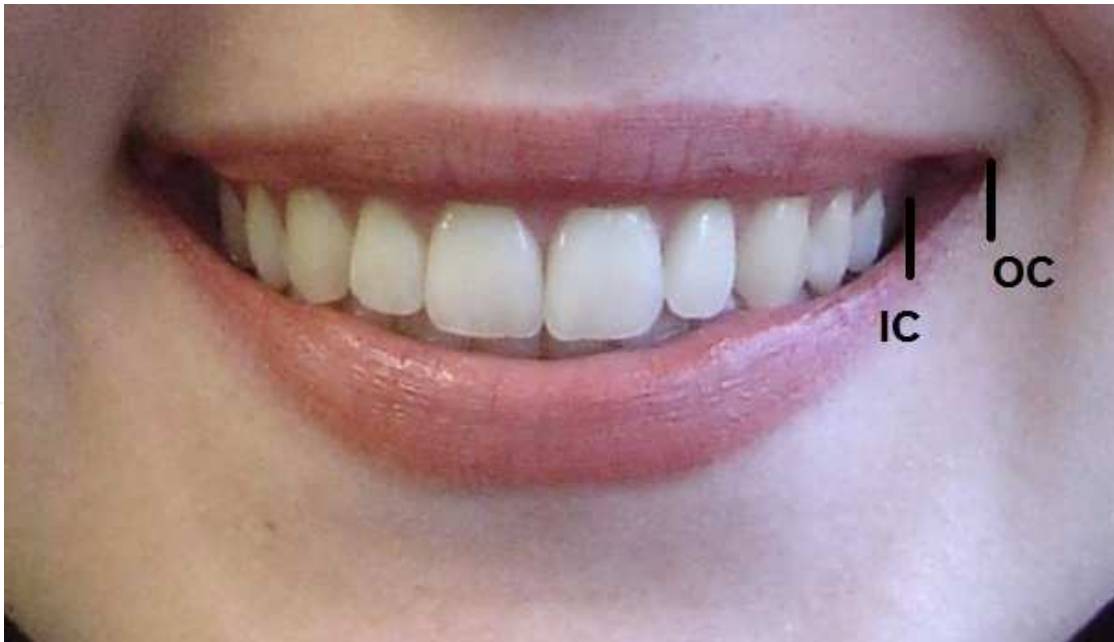

Fig. 3. Anatomy of the lips: (IC) inner commissure, (OC) outer commissure

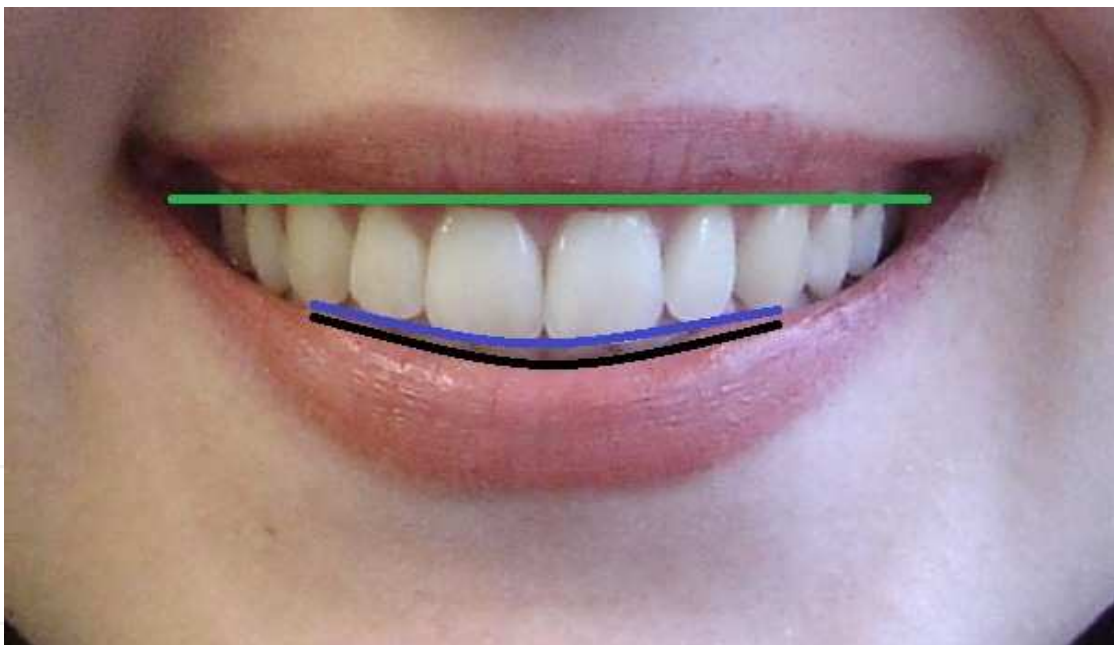

Fig. 4. Anatomy of the lips: in green, the inter-commissure line; in blue, the smile arc; and in black, the curvature of the lower lip

Conventionally, the length of the maxillary anterior teeth is established by the length of the upper lip. However, there is a lack of consensus regarding the suitable anatomical parameter for the estimation of the width of these teeth. Berry (1905), House and Loop (1939) found the width of the maxillary central incisor as 1/16 of the facial width, measured between the zygomatic bone. Cesario and Latta (1984) and Latta et.al. (1991) published that the mid-pupillary distance was supposed to be the width of the maxillary central incisor multiplied by the factor of 6.6.

A recent research developed at the Department of Prosthodontics and Dental Materials at the Faculty of Dentistry of the Federal University of Uberlandia (Brazil) evaluated 70 facial photographs of undergraduated students. The following facial measurements were compared to the width of the maxillary central incisors: mid-pupillary distance and bizigomatic width of the face. Table 6 presents the ANOVA and Tucky test's results after to apply the techniques mentioned above. Only the bizigomatic width technique (BZG) showed values similar to the real width of the maxillary anterior teeth.

Comparisons for tooth width	Mean	Results
Maxillary central incisor	8.745	A1
BZG/16	8.808	A1
MPD/6.6	10.278	A2

Table 6. Tucky test's results for the techniques to select the width of the central incisors. Footnotes see table 1

The length of the maxillary central incisor is usually said to be the facial length also divided by a factor of 16 (Berry, 1905; House and Loop, 1939). In the same study, facial length was measured both from glabella to mental region and from hair line to mental region, corresponding to the sum of the three facial thirds. Regarding the length of this tooth, the facial length measured in both ways, cannot be used safely to estimate the real length of the maxillary central incisor (Table 7).

Comparisons for tooth length	Mean	Results
Maxillary central incisor	9.574	A1
(MT+LT)/16	8.747	A2
(UT+MT+LT)/16	12.688	A3

Table 7. Tucky test's results for the techniques to select the length of the central incisors. Footnotes see table 2

Usually, when it is necessary to observe facial pattern, maxillomandibular relations and facial muscle conditions, the vertical dimension of rest position is recommended. In this situation, photogrammetry can also allow identifying associations between the width of facial structures, such as the nasal width (Gomes et.al., 2009) or the distance between the medialis angles of the eyes (Lucas et.al 2009), and the width of the six maxillary anterior teeth.

The measurement of the vertical dimension of the face can also be evaluated through photogrammetry, compulsory for those patients with posterior tooth loss or reduced teeth size by oral parafunction. Significant correlations were found between the distance from the outer canthus of the eyes to the labial commissure and the lower third of the face while the patient is in vertical dimension of rest position (Gomes et al., 2008).

Another research developed at the Department of Prosthodontics and Dental Materials at the Faculty of Dentistry of the Federal University of Uberlandia (Brazil) evaluated 82 facial photographs of undergraduated students to evaluate the lower third of the face (figure 5). The length of the upper lip was measured from the base of the nose to the rima oris (UL).

The distance between the rima oris and the mental region was also measured (LL-C), corresponding to the length of the lower lip and the chin (figure 5). The distances were compared to the lower third (LT) of the face registered while the subject was in rest vertical dimension. Table 8 presents mean values, standard deviations (SD) and student t test's results for differences according to gender for these measurements. As shown on table 9, all measurements are correlated. Values for the relationship between the lower lip length to the lower third (LLC-LT) are the most significant ($r=0.903$; $p=.000$). Figures 6-8 illustrate mathematical equation from linear regression for these mathematical relationships.

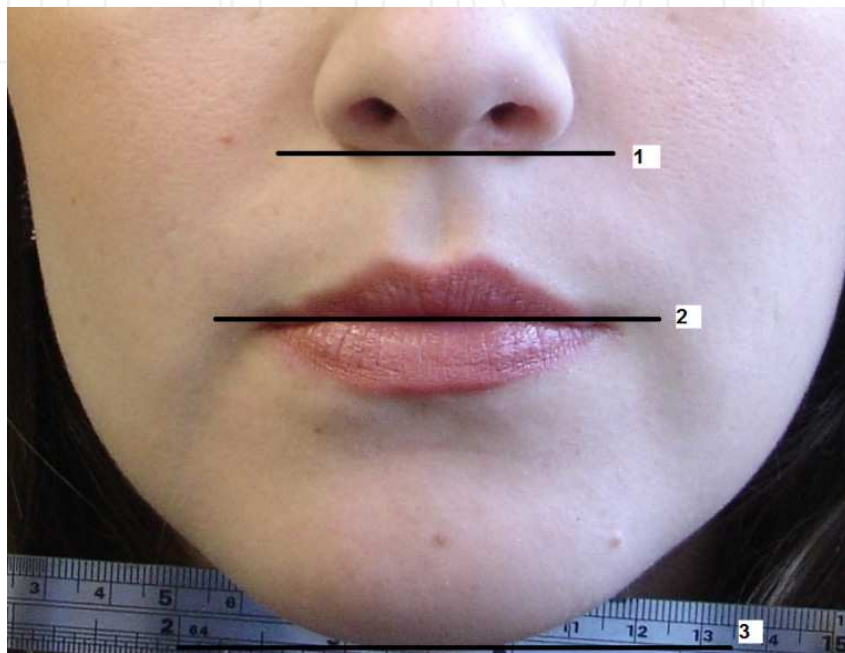


Fig. 5. Frontal view of the lower one-third of the face and landmarks used to guide measurements in digital image

Variables	Total (SD)	Male (SD)	Female (SD)	p
UL	24,71 (2,68)	25,57 (2,93)	24,04 (2,30)	0,008
LL-C	48,18 (4,63)	51,44 (3,90)	45,67 (3,45)	0,000
LT	73,93 (6,43)	77,97 (5,74)	70,83 (5,11)	0,000

Table 8. Mean values and standard deviation (SD) for the total sample and when it was divided according to gender. Footnotes see table 2. Results of Student's *t* Test for differences according to gender ($p<.05$)

Variables	r	P-value
LL-C x UL	0.439	0.000*
UL x LT	0.745	0.000*
LL-C x LT	0.903	0.000*

Table 9. Pearson's correlation coefficient (r) and their probabilities (P) in a bilateral test

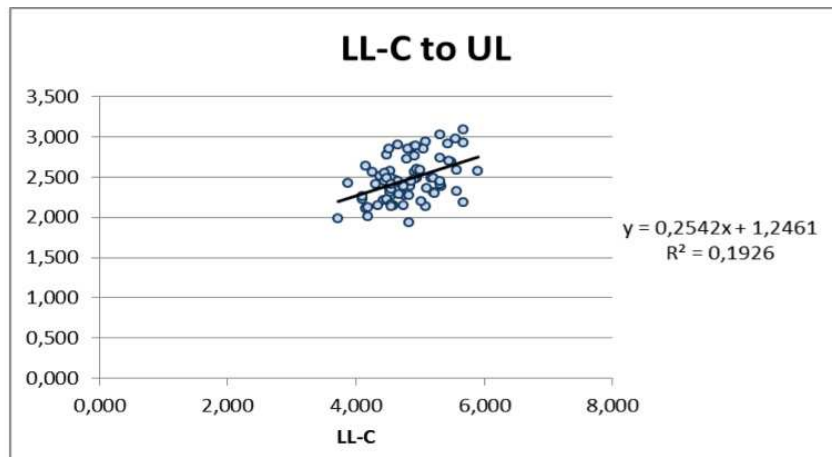


Fig. 6. Scatter plot to show correlation between the values of UL (y) and LL-C (x), and mathematical equation from linear regression

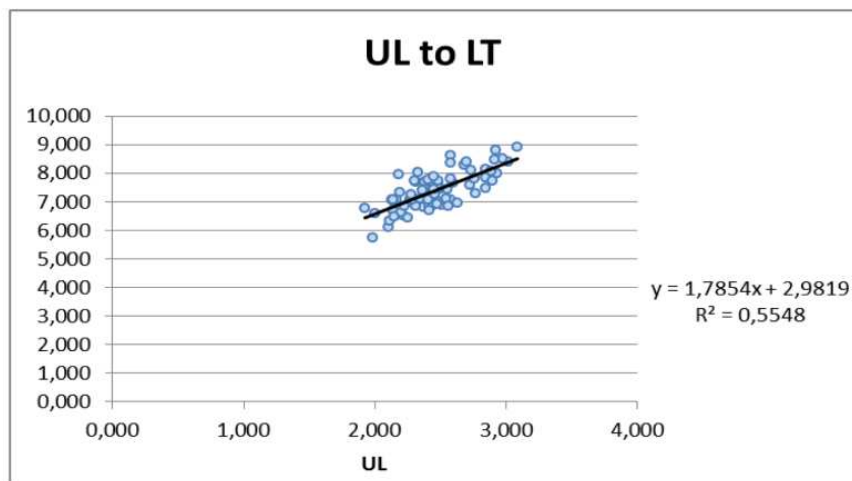


Fig. 7. Scatter plot to show correlation between the values of LT (y) and UL (x), and mathematical equation from linear regression

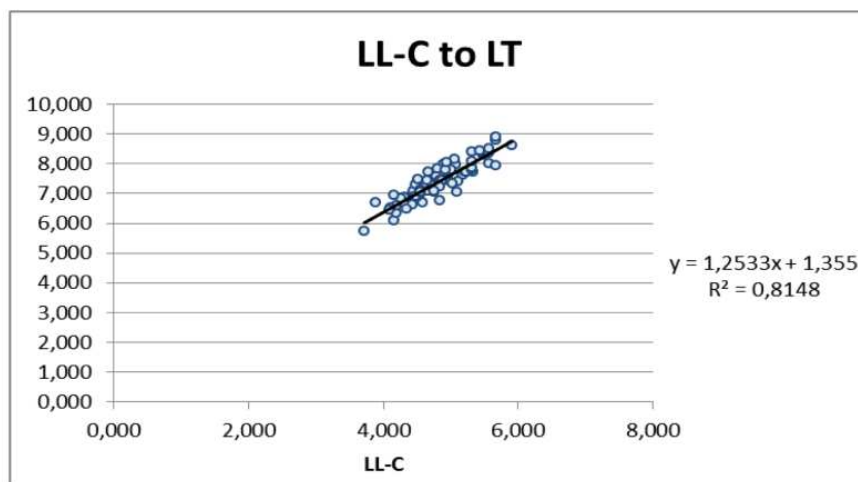


Fig. 8. Scatter plot to show correlation between the values of LT (y) and LL-C (x), and mathematical equation from linear regression

4.2 Lateral view

The success of an oral rehabilitation treatment is frequently related to the improvement in the patient’s facial appearance, which includes the soft tissue profile. Unfortunately, during the orthodontic treatment, for instance, traditional cephalometric measurements do not provide all the answers to the aesthetic considerations of the face and dentition, particularly in relation to the soft tissues (Powell and Humphreys, 1984; Gomes et. al. 2006; Gomes at. al, 2008; Gomes et. al., 2009; Aksu et.al, 2010).

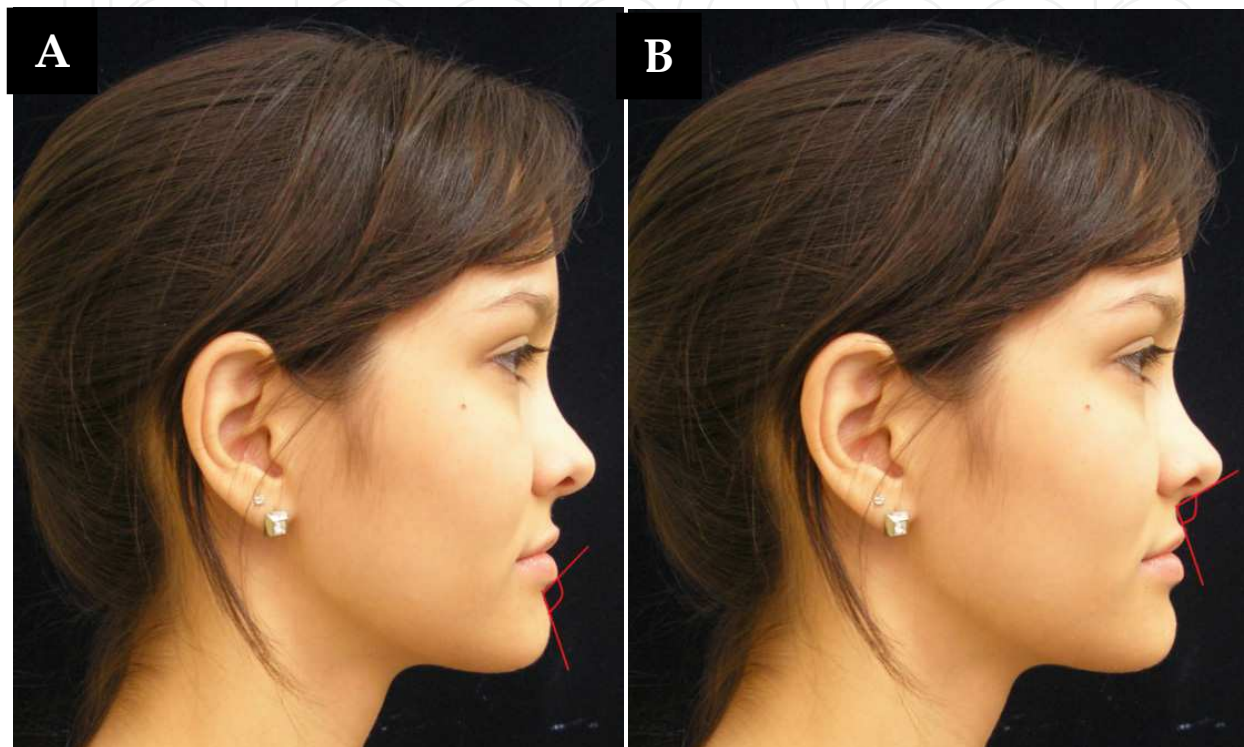


Fig. 9. Mentolabial and Nasolabial angles

Lateral photographs of the subject’s face allow the aesthetic analysis to be rapidly carried out, providing the determinants for the horizontal positions of the soft tissue chin, upper lip, lower lip, upper incisors, and lower incisors in relation to the profile (see biometric points on figure 2B). Also, angular measurements can be observed improving the esthetic treatment planning. Table 10 presents mean values for nasolabial and mentolabial angles measured on 18 Brazilian undergraduated students (aged between 18- 25 years old). Figure 7A and B illustrates how those angles were measured.

	Nasolabial angles	Mentolabial angle
Mean (SD)	107.3 (8.2)	128.3 (15.4)

Table 10. Mean values and standard deviation (SD) of the nasolabial and mentolabial angles for total sample

5. Future research

Anthropometry techniques have gained large interest in the last decades to study and to identify human body parts. Two types of approaches are distinguished: direct

measurements with simple instruments and indirect measurements through digital images. While direct approach generates inaccurate results, due to differences in soft tissues compression among observers, indirect measurements requires a standardize image registration of body parts. In this chapter, the use of photogrammetry in dentistry were introduced and discussed. It consists of a steady measurement technique to perform facial analysis offering anatomical parameters for surgical, orthodontic, prosthetic treatments and for researches. Several dentofacial associations to guide oral rehabilitation treatments were shown to implement the diagnosis and restoration of dentofacial irregularities, of craniofacial development, and of facial reconstruction in forensic medicine. Future studies are recommended to define normative data for different ethnic groups as well as other reliable mathematical associations among dentofacial structures to guarantee esthetic quality and natural appearance after oral rehabilitation treatments.

6. Acknowledgments

The authors gratefully acknowledge the Coordination for the Improvement of Higher Level Personnel (CAPES, Brazil) and the State of Sao Paulo Research Foundation (FAPESP, SP, Brazil, n. 2010/02020-0).

7. References

- Ackerman, JL. Ackerman, MB. Brensinger, CM. & Landis, JR. (1998) A morphometric analysis of the posed smile, *Clin. Orth. Res.* 1;1:2-11. ISSN: 0009-921X
- Ackerman, JL. Ackerman, MB. (2002). Smile Analysis and Design in the Digital Era. *J Clin. Orthodon.* 36;4:221-36. ISSN 0022-3875.
- Aksu, M. Kaya, D. & Kocadereli, I. (2010) Reliability of reference distances used in photogrammetry. *Angle Orthod.*80;4:670-677. ISSN: 0003-3219.
- Al-Johany, SS. Alqahtani, AS., Alqahtani, FY. & Alzahrani, AH. (2011) Evaluation of different esthetic smile criteria. *Int J Prosthodont.* 24;1:64-70. ISSN: 0893-2174.
- Baker, WB. & Woods, MG. (2001) The role of the divine proportion in the esthetic improvement of patients undergoing combined orthodontic/orthognathic surgical treatment *Int J Adult Orthod Orthognath Surg* 16;2:108-120 ISSN: 0742-1931.
- Berry, FH. (1905) Is the theory of temperaments the foundation of the study of the prosthetic art? *Dentist Mag.* 1:405-13.
- Bukhary, SM. Gill, DS., Tredwin, CJ. & Moles, DR. (2007) The influence of varying maxillary lateral incisor dimensions on perceived smile aesthetics. *Br Dent J.* 22;203:687-93. ISSN: 0007-0610.
- Cesario, VAJr. & Latta GHJr. (1984) Relationship between the mesiodistal width of the maxillary central incisor and interpupillary distance. *J Prosthet Dent.* 53;5:641-2 ISSN: 0022-3913.
- Condon, M. Bready, M. Quinn, F. O'Connell, BC. Houston, FJ. & O'Sullivan, M. (2011) Maxillary anterior tooth dimensions and proportions in an Irish young adult population. *J Oral Rehabil.* 38;7:501-8. ISSN: 0305-182X.
- Edler, R. Wertheim, D. & Greenhill, D. (2003) Comparison of radiographic and photographic measurement of mandibular asymmetry. *Am J Orthod Dentofacial Orthop.* 123;2:167-174. ISSN: 0889-5406.

- Fariaby, J. Hossini, A. & Saffari, E. (2005). Photographic analysis of faces of 20-year-old students in Iran. *Br J Oral Maxillofac Surg.* 44;5:393-6. ISSN: 0266-4356.
- Farkas, LG. Katic, MJ. Forrest, CR. Alt, KW. Bagic, I. Baltadjiev, G. Cunha, E. Cvicelová, M. Davies, S. Erasmus, I. Gillett-Netting, R. Hajnis, K. Kemkes-Grotenthaler, A. Khomyakova, I. Kumi, A. Kgamphe, JS. Kayo-Daigo, N. Le, T. Malinowski, A. Negasheva, M. Manolis, S. Ogetürk, M. Parvizrad, R. Rösing, F. Sahu, P. Sforza, C. Sivkov, S. Sultanova, N. Tomazo-Ravnik, T. Tóth, G. Uzun, A. & Yahia, E. (2005) International anthropometric study of facial morphology in various ethnic groups/races. *J Craniofac Surg.* 16;4:615-46. ISSN: 1049-2275.
- Fourie, Z. Damstra, J. Gerrits, PO.& Ren, Y. (2011) Evaluation of anthropometric accuracy and reliability using different three-dimensional scanning systems *Forensic Science International.* 15; 207:127-134. ISSN: 0379-0738.
- Frush, JO. & Fisher, RD. (1958) The dynesthetic interpretation of the dentogenic concept. *J. Prosth. Dent.* 8:558-581. ISSN: 0022-3913.
- Germec-Cakan, D. Canter, DI. Nur, B. & Arun, T. (2010) Comparison of Facial Soft Tissue Measurements on Three-Dimensional Images and Models Obtained With Different Methods. *J Craniofac Surg* 21;5: 1393-1399. ISSN: 1049-2275.
- Goldstein, RE. (1976). *Esthetics in Dentistry*, JB Lippincott Company, ISBN: 100397503490, Philadelphia, USA.
- Gomes, VL. Gonçalves, LC, Correia, CLM. Lucas, BL. & Carvalho, PM. (2008) Vertical dimension of the face analyzed in digital photographs. *Eur J Esthet Dent.* 3;4:14-24. ISSN: 1862-0612.
- Gomes, VL. Gonçalves, LC. Costa, MM. & Lucas, BL. (2009). Interalar distance to estimate the combined width of the six maxillary anterior teeth in oral rehabilitation treatment. *J Esthet Restor Dent.*21;1:26-35. ISSN: 1496-4155.
- Gomes, VL. Gonçalves, LC. do Prado, CJ. Lopes-Junior, I. & de Lima Lucas, B. (2006) Correlation between facial measurements and the mesiodistal width of the maxillary anterior teeth. *J Esthet Restor Dent.*18;4:196-205. ISSN: 1496-4155.
- Good, S. Edler, R. Wertheim, & D. Greenhill, D. (2006) A computerized photographic assessment of the relationship between skeletal discrepancy and mandibular outline asymmetry. *Eur J Orthod.* 28;2:97-102. ISSN 0141-5387.
- House, MM. & Loop, JL. (1939) *Form and color in dental art* (monograph). California: Whittier 1939: p.3-33.
- Johnson DR, & Moore WJ. (1997). *Anatomy for dental students.* ISBN 9780192626738 3rd edition. Oxford University Press. New York.140p.
- Latta, GHJr. Weaver, JR. & Conkin, JE. (1991) The relationship between the width of the mouth, interalar width, bizygomatic width, and interpupillary distance in edentulous patients. *J Prosthet Dent.* 65;2:250-4. ISSN: 0022-3913.
- Laws, R. (2001) The author's guide to controlling the photograph. *J Prosthet Dent.* 85;3:213-218. ISSN: 0022-3913.
- Lee, ST. (1988) A histological study of the philtrum. *Ann Acad Med Singapore.* 17;3:328-34. ISSN: 0304-4602
- Lucas, BL. Bernardino-Júnior, R. Gonçalves, LC & Gomes, VL. (2009). Distance between the medialis angles of the eyes as an anatomical parameter for tooth selection. *J Oral Rehabil.* 36;11:840-847. ISSN: 0305-182X

- Maal, TJJ. Van-Loon, B. Plooi, JM. Rangel, F. Ettema, AM. Borstlap, WA.& Bergé, SJ. (2010) Registration of 3-Dimensional Facial Photographs for Clinical Use. *J Oral Maxillofac Surg* 68;10:2391-2401. ISSN: 0278-2391.
- Mack MR. (1991) Vertical dimension: a dynamic concept based on facial form and oropharyngeal function. *J Prosthet Dent*. 66;4:478-85. ISSN: 0022-3913.
- Marquardt SR. (2002) Dr. Stephen R. Marquardt on the Golden Decagon and human facial beauty. Interview by Dr. Gottlieb. *J Clin Orthod*. 36;6:339-47. ISSN:0022-3875.
- Mizumoto, Y. Deguchi, TSr & Fong, KW. (2009) Assessment of facial golden proportions among young Japanese women. *Am J Orthod Dentofacial Orthop*. 136;2:168-74. ISSN: 0889-5406.
- Mohindra, NK & Bulman, J S. (2002) The effect of increasing vertical dimension of occlusion on facial aesthetics. *Br Dent J*. 192;3:164-68. ISSN: 0007-0610.
- Mondelli, J. (2006). *Estética e Cosmética em clínica integrada*, ISBN 85-8742-552-8, Quintessence, Sao Paulo, Brazil.
- Murthy, BV. & Ramani, N. (2008) Evaluation of natural smile: Golden proportion, RED or Golden percentage. *J Conserv Dent*. 11;1:16-21. ISSN, 0972-0707
- Nanda, RS. & Ghosh J. (1995) Facial soft tissue harmony and growth in orthodontic treatment. *Semin Orthod*. 1;2:67-81. ISSN: 1073-8746.
- Nechala, P. Mahoney, J. & Farkas, LG. (1999) Digital two-dimensional photogrammetry: a comparison of three techniques of obtaining digital photographs. *Plast Reconstr Surg*.103;7:1819-1825. ISSN, 1225-4207.
- Nikgoo, A. Alavi, K. Alavi, K. & Mirfazaelian, A. (2009) Assessment of the golden ratio in pleasing smiles. *World J Orthod*. 10;3:224-8. ISSN: 1530-5678.
- Powell, N. & Humphreys, B. (1984) *Proportions of the aesthetic face*. The American Academy of Facial Plastic and Reconstructive Surgery. New York, Thieme-Stratton. 1-72.
- Preston, JD. (1993) The golden proportion revisited. *J Esthet Dent*. 5;6:247-51. ISSN: 1496-4155.
- Ras, F. Habets, LL. Van Ginkel, FC. & Prah-Andersen, B. (1995) Method for quantifying facial asymmetry in three dimensions using stereophotogrammetry. *Angle Orthod*. 65;3:233-239. ISSN: 0003-3219.
- Ricketts RM. (1981) The golden divider. *J Clin Orthod*. 15;11:752-9. ISSN:0022-3875.
- Ricketts RM. (1982) Divine proportion in facial esthetics. *Clin Plast Surg*.9;4:401-22. ISSN: 0094-1298.
- Ricketts RM. (1982) The biologic significance of the divine proportion and Fibonacci series. *Am J Orthod*. 81;5:351-70. ISSN, 0889-5406.
- Vadachkoria, NR. Gumberidze, NSh. & Mandzhavidze, NA. (2007) "Golden proportion" and its application to calculate dentition. *Georgian Med News*. Jan;142:87-94. ISSN 1512-0112.
- Vargas, MA. (2003) Photographs of the Face for Publication and Presentations. *J Prosthodont*, 12;1:47-50. ISSN: 1678-1899.
- Woda, A. Pionchon, P. & Palla, S. (2001) Regulation of mandibular postures: mechanisms and clinical implications. *Crit Rev Oral Biol Med*. 12;2:166-178 ISSN:1045-4411.



**Oral Health Care - Prosthodontics, Periodontology, Biology,
Research and Systemic Conditions**

Edited by Prof. Mandeep Virdi

ISBN 978-953-51-0040-9

Hard cover, 372 pages

Publisher InTech

Published online 29, February, 2012

Published in print edition February, 2012

Geriatric dentistry, or gerodontics, is the branch of dental care dealing with older adults involving the diagnosis, prevention, and treatment of problems associated with normal aging and age-related diseases as part of an interdisciplinary team with other healthcare professionals. Prosthodontics is the dental specialty pertaining to the diagnosis, treatment planning, rehabilitation, and maintenance of the oral function, comfort, appearance, and health of patients with clinical conditions associated with missing or deficient teeth and/or oral and maxillofacial tissues using biocompatible materials. Periodontology, or Periodontics, is the specialty of oral healthcare that concerns supporting structures of teeth, diseases, and conditions that affect them. The supporting tissues are known as the periodontium, which includes the gingiva (gums), alveolar bone, cementum, and the periodontal ligament. Oral biology deals with the microbiota and their interaction within the oral region. Research in oral health and systemic conditions concerns the effect of various systemic conditions on the oral cavity and conversely helps to diagnose various systemic conditions.

How to reference

In order to correctly reference this scholarly work, feel free to copy and paste the following:

Barbara de Lima Lucas, Roberto Bernardino Júnior, Luiz Carlos Gonçalves, Maria Beatriz Duarte Gavião and Vanderlei Luiz Gomes (2012). Research and Clinical Applications of Facial Analysis in Dentistry, Oral Health Care - Prosthodontics, Periodontology, Biology, Research and Systemic Conditions, Prof. Mandeep Virdi (Ed.), ISBN: 978-953-51-0040-9, InTech, Available from: <http://www.intechopen.com/books/oral-health-care-prosthodontics-periodontology-biology-research-and-systemic-conditions/research-and-clinical-applications-of-facial-analysis-in-dentistry>

INTECH
open science | open minds

InTech Europe

University Campus STeP Ri
Slavka Krautzeka 83/A
51000 Rijeka, Croatia
Phone: +385 (51) 770 447
Fax: +385 (51) 686 166
www.intechopen.com

InTech China

Unit 405, Office Block, Hotel Equatorial Shanghai
No.65, Yan An Road (West), Shanghai, 200040, China
中国上海市延安西路65号上海国际贵都大饭店办公楼405单元
Phone: +86-21-62489820
Fax: +86-21-62489821

© 2012 The Author(s). Licensee IntechOpen. This is an open access article distributed under the terms of the [Creative Commons Attribution 3.0 License](#), which permits unrestricted use, distribution, and reproduction in any medium, provided the original work is properly cited.

IntechOpen

IntechOpen