

We are IntechOpen, the world's leading publisher of Open Access books Built by scientists, for scientists

4,800

Open access books available

122,000

International authors and editors

135M

Downloads

Our authors are among the

154

Countries delivered to

TOP 1%

most cited scientists

12.2%

Contributors from top 500 universities



WEB OF SCIENCE™

Selection of our books indexed in the Book Citation Index
in Web of Science™ Core Collection (BKCI)

Interested in publishing with us?
Contact book.department@intechopen.com

Numbers displayed above are based on latest data collected.

For more information visit www.intechopen.com



Gingivitis in Children and Adolescents

Folakemi Oredugba and Patricia Ayanbadejo
*Faculty of Dental Sciences, College of Medicine, University of Lagos
Nigeria*

1. Introduction

Gingivitis or inflammation of the gingiva, is the commonest oral disease in children and adolescents. It is characterized by the presence of gingival inflammation without detectable bone loss or clinical attachment loss. The causes and risks are as varied in children as in adults and range from local to systemic causes. The most important local predisposing factor in children is poor oral hygiene which stems from children's dependence on adults for assistance with routine oral hygiene. It also stems from age limitation in perception of the need for regular and efficient tooth brushing.

When plaque and food debris accumulate in poor oral hygiene, micro-organisms also accumulate and the process of inflammation starts. This leads to gingivitis, which, if not taken care of can progress to gradual destruction of supporting soft and hard tissues of the teeth. This is evident in the very young and those with disabilities, where manual dexterity is not well developed.

Gingivitis in children is also commonly seen during eruption and exfoliation of both primary and permanent teeth and exfoliation of primary teeth. This process, although physiological, if not managed carefully, may contribute to discomfort during tooth brushing, mastication and also cause restlessness in the affected children. During puberty, it may be a response to hormonal changes in the developing adolescent, though more pronounced when there is plaque accumulation.

In children with compromised immunity, chronic malnutrition, exanthematous fevers such as malaria, measles or chicken pox, the gingivitis may be acute and necrotic. The systemic effect and local destruction of soft and hard tissues may contribute to increased morbidity and poor aesthetics in affected children.

Habitually leaving the mouth open, either spontaneously or due to pathology in the oropharynx, may also contribute to gingivitis. During childhood and adolescence, appliances, either habit breakers or removable and fixed appliances may be required. Most children at this age present with gingivitis. This is a result of non compliance with routine tooth brushing which is further made difficult by orthodontic wires and elastics. One of the pre-conditions for appliance therapy is a commitment to efficient routine tooth brushing because the use of an appliance in the presence of plaque and debris accumulations is deleterious to the periodontal structures.

Gingivitis may also be a complication of chronic use of certain medications whose side effects include dryness of the mouth. It predisposes to gingival inflammation which is due to a low output of saliva. This type of gingivitis is frequently encountered in children and

adolescents on antidepressants and other medications, which if used on long term basis and in the presence of plaque and debris, predispose to gingivitis.

Several studies on the oral health of the young population in developing countries show that poor gingival health is rampant, especially in those residing in the rural and remote areas and in those of the lower socioeconomic strata. This condition is even more significant in those who are institutionalized, those with intellectual disabilities, for example, Down syndrome, Autism Spectrum Disorders; those with multiple disabilities and generally those who have musculo-skeletal disorders who may not be able to carry out effective tooth brushing. The main problem with these individuals is neglect on the part of parents and care givers who are supposed to be responsible for their daily hygiene. When compared with children and adolescents without disabilities, their oral health has been found to be poorer.

The situation can however be controlled with regular dental visits, which is still alien to the population at large, where oral health education will be re-inforced. The school health programme has also been recommended as an important means by which oral health education can be provided and established for children and adolescents. The programme is being supported by Faculty and corporate bodies across the globe and it is believed that this will gradually expose the population to good oral health practices and improve gingival health. This Chapter aims to discuss the various forms of gingivitis encountered in children and adolescents including those with special health care needs and provide a summary of recommendations given from the different studies carried out.

2. Plaque induced gingivitis

Gingivitis is also regarded as the most common periodontal disease in children, with the primary aetiology as plaque (Oh et al, 2002). In poor oral hygiene, food debris, plaque and micro-organisms also accumulate and the process of inflammation starts. This leads to gingivitis, which, if not taken care of can progress to gradual destruction of supporting soft and hard tissues of the teeth (Fig 1).

2.1 Histopathology

Inflammation represents the body's protective response to injury and tissue destruction. This response consists of a spectrum of highly coordinated events that occur at cellular and tissue level. Its purpose is to destroy, dilute or sequester the injurious agent and the injured tissue in order to permit healing.

Inflammation is a defensive mechanism intended to protect the host, but can also be potentially harmful. Clinical signs of inflammation are redness (due to open blood vessels), heat (due to warmth of blood), swelling (due to oedema), pain (due to stimulation of pain receptors) and loss of function due to oedema (Ramzi et al, 2002).

Gingival inflammation is the result of plaque or bacterial biofilm. This biofilm develops and matures over a period of several weeks, initially developing supragingivally with mainly aerobic bacteria (Serio et al, 2009). Over time, the flora changes from predominantly gram positive to gram negative, from facultative aerobes to strictly anaerobic species, with more motile forms present. Mature subgingival biofilm takes up to twelve weeks to develop (Lovegrove et al, 2004) and contains gram negative bacteria such as *P. gingivalis*, *B. forsythus*, and *P. intermedia*, among many others (Fleming, 1999).

These bacteria possess complex carbohydrate and proteins on their cell walls called endotoxins or lipopolysaccharides (LPS). When these molecules are detected by the host, a

protective response ensues, resulting in inflammation, recruitment of white blood cells (WBCs) and release of cytokines and chemical mediators.

As the biofilm accumulates, gingivitis develops over a period of several days in the presence of periodontal bacteria (Loe et al, 1965). Gingivitis may be a non-specific bacterial infection dependent on the level of plaque present (Goodson et al, 2004).

Nevertheless, the prevalence and severity of inflammation of the oral tissues (gingivitis and periodontitis) is low in healthy young children and gradually increases with increasing age (Matsson, 1993; Papaioannou et al, 2009). With increasing age, the proportions of periodontal pathogens also increase (Papaioannou, 2009; Kimura et al, 2002).

Page and Shroeder (1976), reported the sequence of changes during the development of gingivitis and periodontitis under four stages, according to prominent histopathological signs. They termed the stages, Initial, Early, Established and Advanced lesions.

In health, hallmark features of gingival connective tissue are an even collagen density throughout the gingiva and absence of clusters of inflammatory cells.

In the initial lesion, which occurs within 2 to 4 days after allowing plaque to accumulate, an increased volume of junctional epithelium (JE) is occupied by polymorphonuclear leucocytes (PMNL). Blood vessels subjacent to the JE become dilated and exhibit increased permeability. A small cellular infiltrate of PMNL and mononuclear cells forms and collagen content in the infiltrated areas markedly decreases.

In the Early stage, which is about 4 to 7 days of plaque accumulation, gingivitis in humans evolves at this stage, the differentiating sign being accumulation of large numbers of lymphocytes as an enlarged infiltrate in the connective tissue. There are altered fibroblasts and earlier changes are quantitatively increased.

In the Established stage, which is about 2 to 3 weeks of plaque accumulation, there is preponderance of plasma cells in an expanded inflammatory lesion with continuance of earlier changes. The Established lesion may persist for a long time before becoming 'aggressive' and progressing to the advanced lesion.

In the Advanced lesion, the infiltrate is dominated by plasma cells. Collagen destruction continues with loss of alveolar bone and apical migration of JE, with "pocket" formation now being apparent. Throughout the sequence, viable bacteria remain outside the gingiva, on the surface of the tooth and in the periodontal pocket against, but not invading the soft tissue.

However, a notable finding by Longhurst (1980) is that the histopathology of chronic gingivitis in children corresponds to the plasma cell-dominated established lesion of the adult, but has an inflammatory infiltration with a great majority of lymphocytes. This is analogous to the Early lesion as described by Page and Shroeder (1976) for the adult. Other reports on the nature of cellular infiltrates in various stages of periodontal disease had indicated that in mild gingivitis, the predominant lymphocyte was the T-cell while in more severe gingivitis and periodontitis the B-cell line predominates. This implies that gingivitis in children is T-cell dominated, although the degree of delineation is not quite established. It also indicates an age-related difference in immunologic response (Koch & Poulsen, 2009).

In a study assessing the prevalence of three microorganisms, *Porphyromonas gingivalis*, *Actinobacillus actinomycetemcomitans* and *Tannerella forsythensis*, in the bacterial plaque of children with and without gingivitis, it was found that the organisms causing gingivitis were endogenous in healthy mouths. They start to cause disease when their numbers increase significantly (Gafan et al, 2004)

In Nigeria, gingivitis has been reported to be more prevalent in children from lower socioeconomic background (Oredugba, 2006). This was attributed to low educational level

which causes low perception of need for adequate oral hygiene. In a recent study among Finnish school children, those whose mothers had a college or university education had a smaller chance of presenting with visible plaque accumulation than those from mothers with a lower educational level (Leroy et al, 2011). The study also found an association between bacterial plaque accumulation and the presence of gingivitis.

Poor oral hygiene and gingivitis have been reported to be more prevalent in children with cognitive and developmental disabilities. The Oral Hygiene Index (OHI) scores have been found to be higher in children and adolescents with disabilities than in control groups in studies carried out in some developing countries (Oredugba, 2006; Oredugba & Akindayomi, 2008; Nahar et al, 2010). In the study carried out in Bangladesh, as many as 64% of those with disabilities had gingivitis compared with 27.5% of controls. The prevalence of gingivitis has also been found to be influenced by other demographic factors such as place of residence, age and severity of disability and cognition.

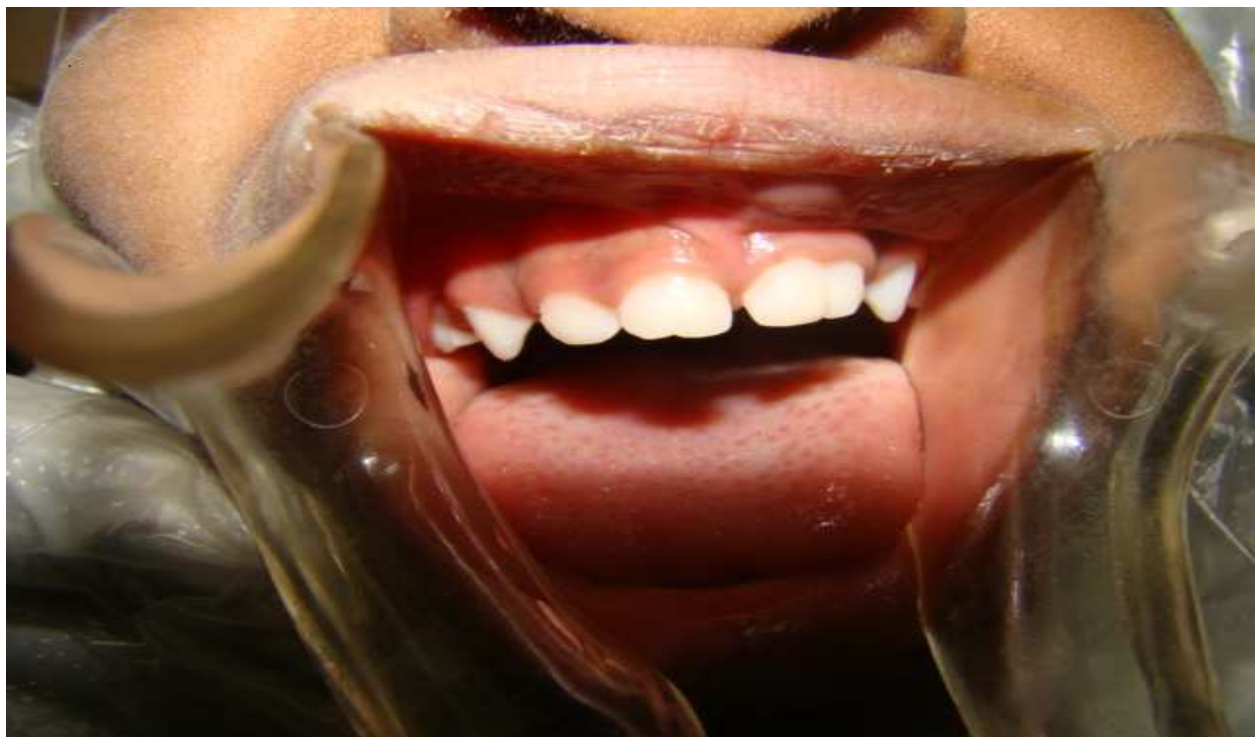

Fig. 1. Gingivitis of the anterior maxillary teeth in a four year old boy

Since most of the affected children do not brush their teeth, or brush only once a day or occasionally, mouth washes containing chemical anti-plaque agents which reduce bacterial plaque accumulation and therefore the incidence of gingival and periodontal diseases are important in such individuals. Chlorhexidine is currently the most effective chemical anti-plaque agent used in dentistry (Twetman, 2004). It causes an immediate reduction in the number of salivary bacteria and possesses a broad spectrum against gram positive and negative bacteria, fungi and lipophilic viruses (Jones, 2000). Its effect is both bactericidal and bacteriostatic and clinical efficacy results from its interaction with bacterial cell membrane causing cell lysis and prevention of adhesion of new bacteria in the oral cavity. These findings point to the need for motivation of parents and caregivers to commence and encourage effective tooth brushing which will lay a foundation for good oral health in their

children and wards (Meyer et al, 2010). This is especially so in those with intellectual disabilities and the very young children.

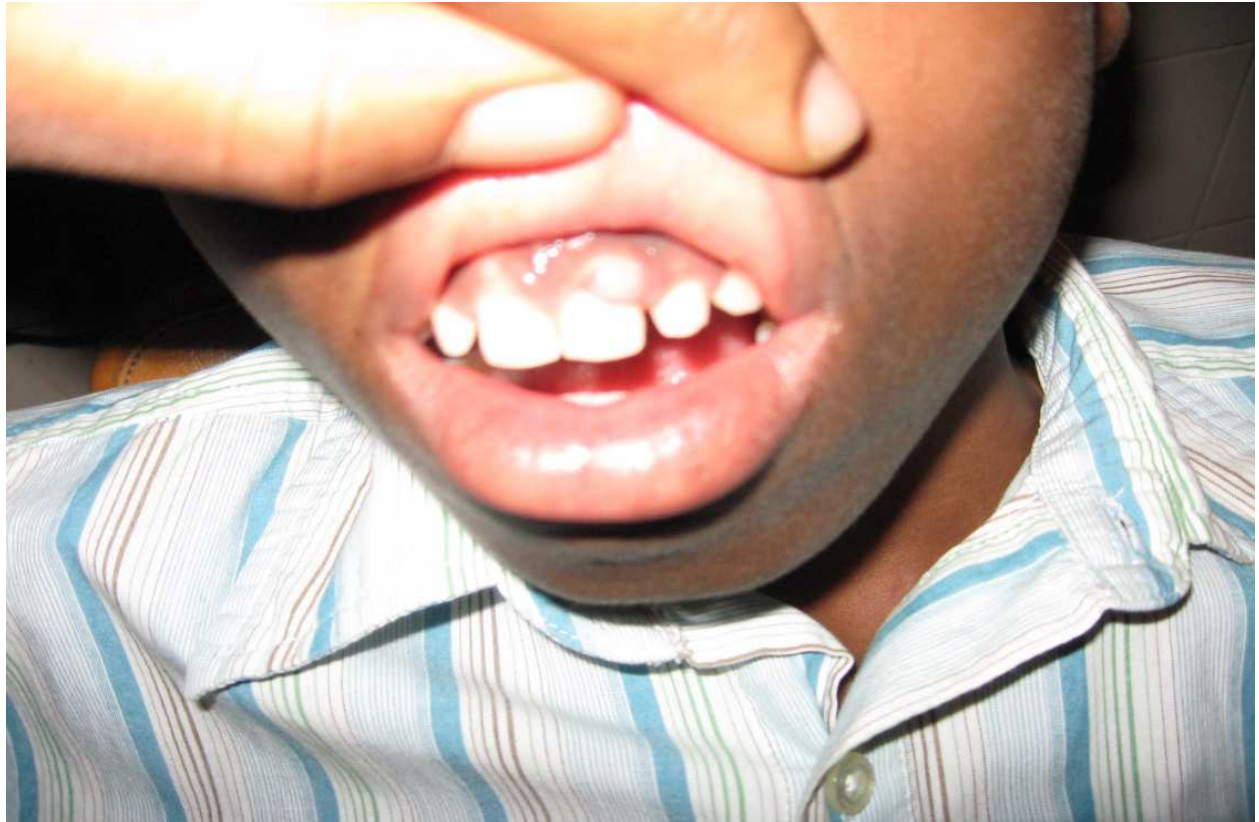

Fig. 2. Gingivitis in a nine year old boy due to mouth breathing

Gingivitis in the maxillary anterior region is also a common finding in mouth breathers (Fig 2). This habit is common among young children and it predisposes to dryness of the gingiva when the lubricating effect of saliva is absent. This habit can be corrected with the use of a removable appliance. Children who use orthodontic appliances for correction of malocclusion are predisposed to gingivitis. However effective tooth brushing and use of chlorhexidine mouthwash will reduce plaque accumulation and gingivitis.

3. Eruption gingivitis

This is gingival inflammation occurring around an erupting permanent tooth. The child may be experiencing discomfort which will therefore make tooth brushing difficult. Sometimes, the child refuses tooth brushing completely. This will lead to plaque accumulation and inflammation. Also during the eruptive phase, the epithelium displays degenerative changes at the site of fusion between dental and oral epithelia. These areas are vulnerable to plaque accumulation and sets up a bacterial reaction (Koch & Poulsen, 2009).

4. Infective gingivitis

These are of viral or bacterial origin and caused by viruses or bacteria which are normal commensals of the oral cavity becoming virulent when present in high proportions.

4.1 Herpetic gingivo-stomatitis

Also known as acute herpetic gingivo-stomatitis and affects both the gingivae and other parts of the oral mucus membrane. It is commonly seen in children less than three years of age. It is caused by the herpes simplex virus type 1. Infection usually follows bouts of childhood fevers such as malaria, measles and chicken pox and it may assume epidemic proportions among children attending same pre-school or crèche centres. The onset of generalized gingivitis is preceded by a prodromal period with symptoms such as irritability, malaise, vomiting and fever and the appearance of small vesicles which rupture to reveal small yellowish painful ulcers with erythematous margins. The condition is associated with drooling of saliva, inability to chew and swallow and the child may become increasingly uncooperative during tooth brushing (Fig 3).

The condition is self limiting and the management is to encourage bed rest, plenty of fluid and maintenance of good oral hygiene through gentle debridement. Analgesics are prescribed to relieve the pain and antibiotics are useful in preventing superimposed bacterial infection. The application of a mild topical anaesthetic gel has been found useful in young children and reduces irritability.

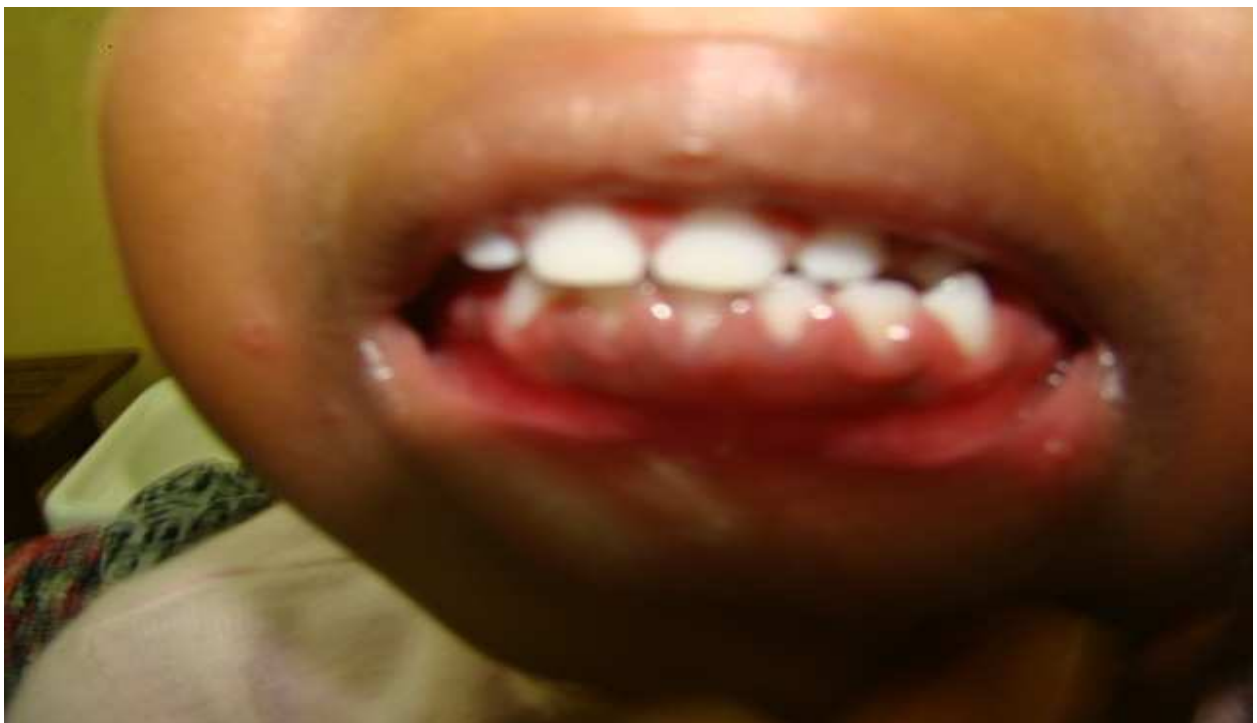

Fig. 3. Acute herpetic gingivostomatitis in a 2 1/2 year old girl

4.2 HIV-associated gingivitis

Oral manifestations of human immunodeficiency virus (HIV) disease are an important part of the natural history of HIV disease (Lamster et al, 1998). Many studies have reported that hairy leukoplakia, pseudomembranous candidiasis, Kaposi sarcoma, non-Hodgkin's lymphoma, linear gingival erythema, necrotizing ulcerative gingivitis and periodontitis were common lesions seen in patients with HIV infection and AIDS. It was also reported that the higher prevalence and incidence rates of these conditions correlated with the falling CD4 counts and higher viral load of the patients (Han & Liu, 2010). However the use of

highly active antiretroviral therapy (HAART) was associated with decreases in the prevalence of oral diseases.

In a study comparing the oral microbiology of HIV-positive children with that of controls, the prevalence of gingivitis was significantly higher in the HIV-positive group (89.4%) than in the healthy group (40.5%) (Portela et al, 2004). It was also found that the frequency of yeast isolation correlated positively with the severity of the gingival condition in the HIV-infected group, because 95% of infants who presented with *Candida* had inflammation of the gingivae. In the study, multiple candida species were isolated from the subgingival crevices of children with positive HIV infection. These include *C. albicans*, *C. dubliniensis*, *C. glabrata* and *C. tropicalis*. Apart from yeast infection, fusobacterial and spirochaetal infections have been found in HIV positive children, with a high proportion of those who manifested the AIDS disease having necrotizing gingivitis. These findings confirm the multiple microbial colonization of the gingival lesions in HIV infection.

4.3 Acute necrotizing ulcerative gingivitis (ANUG)

This is an acute multiple bacterial infection of the gingivae. The lesion starts at the interdental papillae, spreading along the gingival margins and if untreated, starts to destroy the underlying connective tissue and bone. There is a characteristic necrotic odour associated with this condition and the mouth becomes progressively painful with sloughing off of the necrotic ulcers on the gingivae. The ulcers become erythematous and bleed following minimal trauma, especially tooth brushing. Systemic upset may not be associated, but the regional lymph nodes are enlarged and tender. If untreated, destruction of the soft tissues of the mouth and cheek and facial bones result, a condition referred to as Cancrum oris or Noma (Figs 4-6).

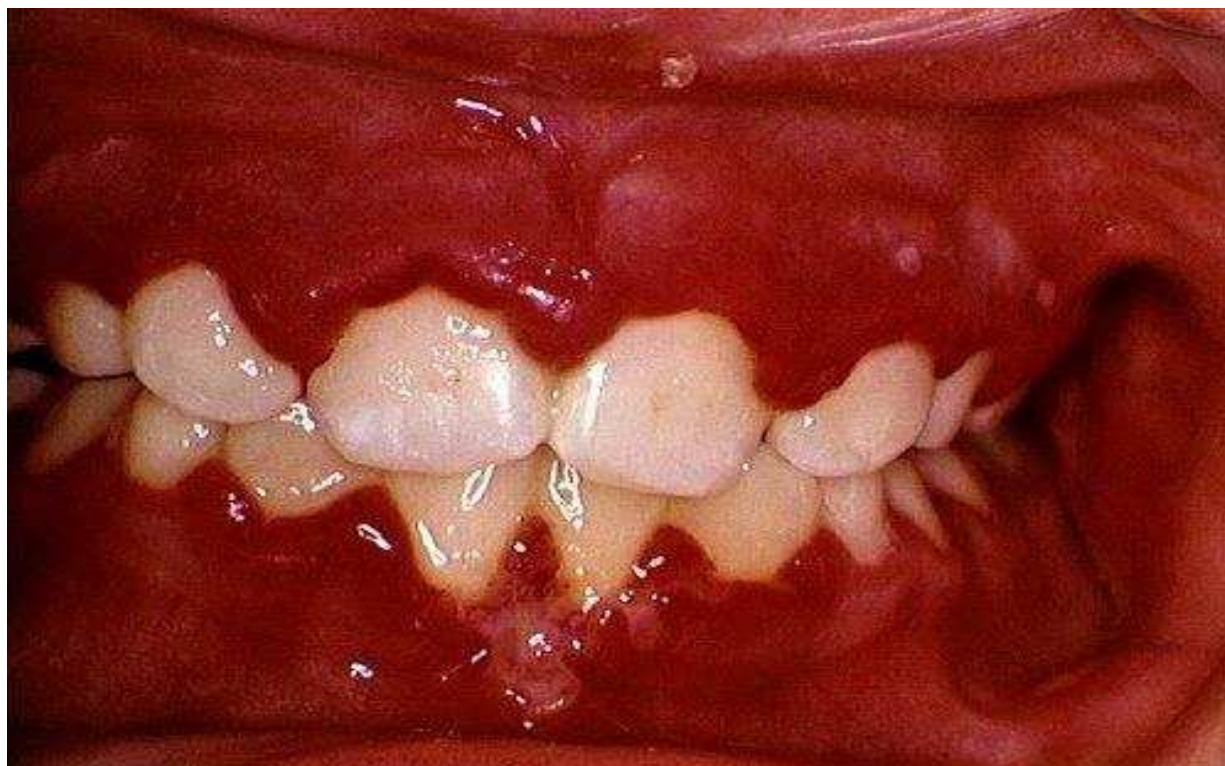


Fig. 4. Early stage of acute necrotizing ulcerative gingivitis (ANUG)

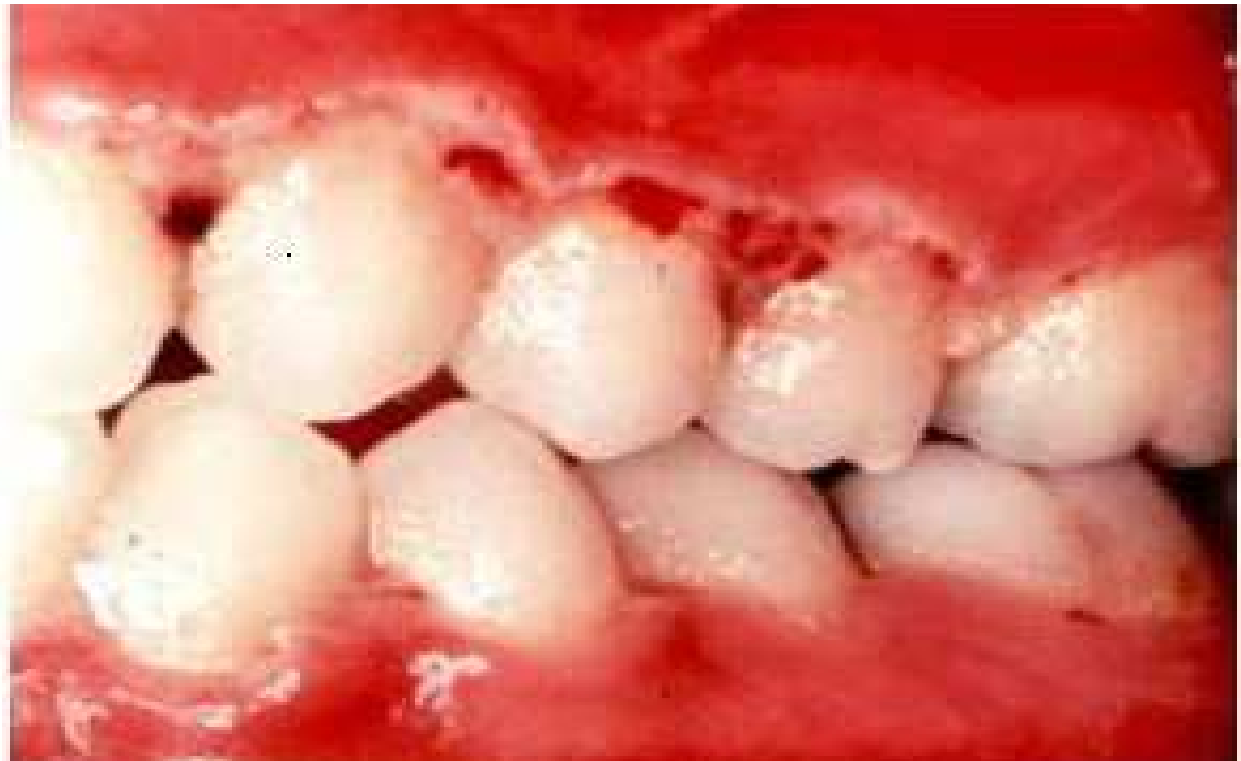

Fig. 5. Advanced stage of acute necrotizing ulcerative gingivitis

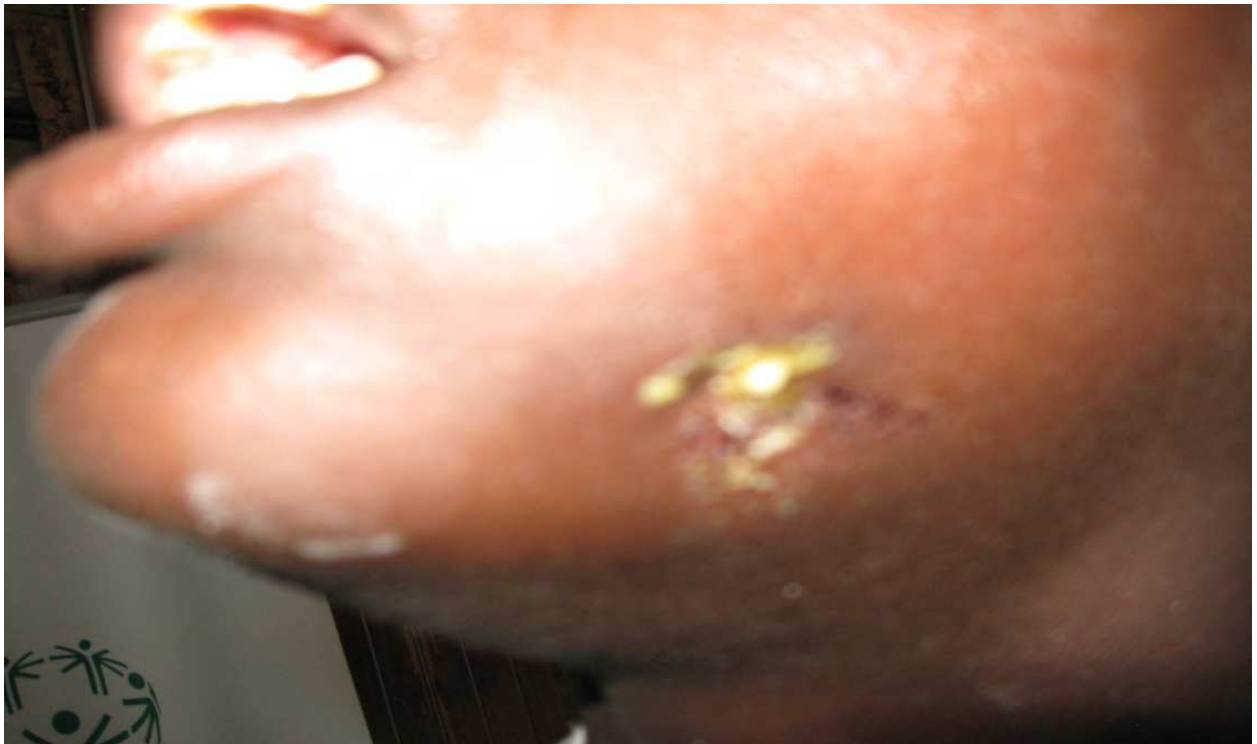

Fig. 6. Cancrum oris in a 14 year old boy

It occurs with low frequency (<1%) in children in developed countries but still seen in higher proportions (2-5%) in children and adolescents in developing countries in Africa, Asia and South America. It is also frequently seen in children and adolescents with

intellectual disabilities and some other medically compromising conditions who may not be able to comply with routine oral hygiene practices.

Predisposing factors include poor oral hygiene, malnutrition, depressed immunity and long term hospitalization. It used to be known as “trench mouth” because it was seen frequently in soldiers occupying trenches during the World War I. It was also called “Vincent’s angina”, after the French physician Henri Vincent (1862- 1950). Later, it was seen in children from low socio-economic families who were malnourished and with poor oral hygiene.

The bacteria implicated earlier were *Fusobacteria fusiformis* and *Borrelia vincentii*. However, modern electron microscope studies have shown the lesion to be colonized by various species of gram negative anaerobes and spirochaetes such as *Treponema species*, *Bacteroides*, *Veilonella*, *Fusobacteria* and *Actinomyces*.

The treatment of choice is regular gentle debridement of the gingivae and irrigation with an oxidising antiseptic such as hydrogen peroxide, until the infection clears. Diet and oral hygiene counseling is also useful and this should be followed up to ensure speedy healing. Metronidazole is used because it is effective against obligate anaerobes which are found in large numbers in the lesion. To prevent secondary infection, penicillin is prescribed.

5. Malnutrition-induced gingivitis

Adolescence is a time of rapid growth, independent food choices and food fads. (Bello & Al-Hammad, 2006). It is also a period of heightened caries activity as a result of increased intake of cariogenic substances and inattentiveness to oral hygiene procedures (Majewski, 2001).

Biological antioxidants form an important part of our diet and together with intracellular antioxidants and antioxidant enzyme systems may prevent various pathological diseases (O’Brien, 1994; Battino et al, 2002). Saliva, which bathes the oral tissues, contains pure salivary secretions, crevicular fluid, proteins, carbohydrates, enzymes, ions, antioxidants and microorganism, and is usually a reflection of plasma. One of the most important functions of salivary enzymes such as peroxidase is the control of oral bacteria that form dental plaque and imbalance in oral ecology which lead to dental caries and chronic inflammatory periodontal diseases (Tulunoglu et al, 2006).

There is evidence that different foods, such as dietary proteins and carbohydrates can affect the buffering capacity of saliva (Mundorff-Shrestha et al, 1994) and protein deficiency influences markedly the composition of whole saliva in man (Johansson et al, 1984; Agarwal et al, 1984). Chronic deficiencies of iron, the B group vitamins and folic acid also predispose to glossitis and gingivitis, especially in young children.

6. Gingivitis associated with hormonal changes

Hormones have been found to have strong effects on mucosal, connective tissue and bones. For an individual, birth is a borderline between the sterile intrauterine life and the extra-uterine existence with a continuous exposure to microorganisms (Kononen, 1999). The microbial community is further shaped by diet, personal oral hygiene (Crielaard et al, 2011) and other parameters such as hormones and various systemic conditions. The microbiome analysis by Crielaard et al (2011) showed that the salivary microbiome of children is already complex by the age of three years matures with increasing age, but at the age of puberty, still differs from the adult microbiome. A higher amount of plaque has also been found in the primary dentition compared with the mixed and permanent dentitions, but the prevalence and

severity of inflammation of the oral tissues (gingivitis and periodontitis) is low in healthy young children and gradually increases with increasing age (Papaioannou et al, 2009).

Pubertal gingivitis has been seen with increasing frequency in young teenagers and has been ascribed to the “rush” of sex hormones which also affects the reaction of tissues to corticosteroids. The same pattern has been described in pregnant women who are more predisposed to gingivitis during pregnancy. The condition ranges from localized inflammation of one or two papillary gingivae, also called ‘pregnancy epulis’, to generalized marginal gingivitis. This condition is not severe if plaque is well controlled. Most cases resolve as soon as debridement is commenced.

7. Drug-induced gingivitis

Drug-induced gingival enlargement (DIGE) and gingivitis are side effects and unwanted outcomes of antiepileptic therapy with phenytoin, or immunosuppressive therapy with systemic cyclosporine. Patients on these medications develop varying degrees of gingival overgrowth (Trackman & Kantaki, 2004; Cury et al, 2009). Gingival enlargement is the most significant oral finding (Robbins, 2009) and can occur in up to 50% of patients taking Phenytoin (Thomason et al, 1992). Valproic acid and Carbamazepine have also been demonstrated to cause gingival enlargement, especially on the labial surfaces of the anterior maxillary and mandibular teeth (Figs 7a & 7b). It is strongly correlated to poor plaque control. Where the oral hygiene is good and food debris and plaque are not allowed to accumulate, this side effect of anticonvulsive therapy is not observed or not so significant. Treatment includes meticulous oral hygiene and in severe cases where the enlarged tissue interferes with function and aesthetics, surgical resection is advised. (Robbins, 2009). A more frequent recall and oral hygiene interval has also been suggested for such patients on antiepileptic drug therapy to reduce the risk of gingival hyperplasia.

7.1 Plasma Cell Gingivitis (PCG)

Plasma cell gingivitis is characterized by diffuse and massive infiltration of plasma cells into the subepithelial gingival tissue (Macleod & Ellis, 1989). It is a rare benign inflammatory condition with no clear aetiology, but an exaggerated response to bacterial plaque, immunological reaction to allergens in food such as strong spices, chilli pepper, medications, toothpaste or herbs such as khat has been reported (Halbach, 1972; Kalix, 1988; Macleod & Ellis, 1989; Serio et al, 1991; Marker & Krogdahl, 2001). The diagnosis requires haematological screening in addition to clinical and histopathological examination in order to exclude leukemia. Further, serological examination is needed to exclude connective tissue disease – first and foremost lupus erythematosus (Al-Meshal, 1988; Neville et al, 1995). In affected children, standard professional oral hygiene procedures and non- surgical periodontal therapy including antimicrobials are associated with marked improvement of clinical and patient related outcomes (Arduino et al, 2011).

8. Gingivitis as a manifestation of systemic disease

Subjects with developmental disabilities, mental retardation, cerebral palsy and autism have been shown to require special care for maintaining oral hygiene and receiving dental treatment (Surabian, 2001 A & B; Oredugba & Akindayomi, 2008). A considerably higher frequency of inflamed gingival surfaces and pathological gingival pockets are present in

children with severe mental retardation as compared with healthy children, in spite of similar frequencies of dental care (Forsberg, 1985). This has been attributed to their lack of cooperation during tooth brushing at home and during treatment. A lot of patience is required by parents and care givers in order to provide effective home oral hygiene care for this group of individuals. Oral health education is also desirable to create awareness of need for good oral health for all individuals, irrespective of age and mental status.

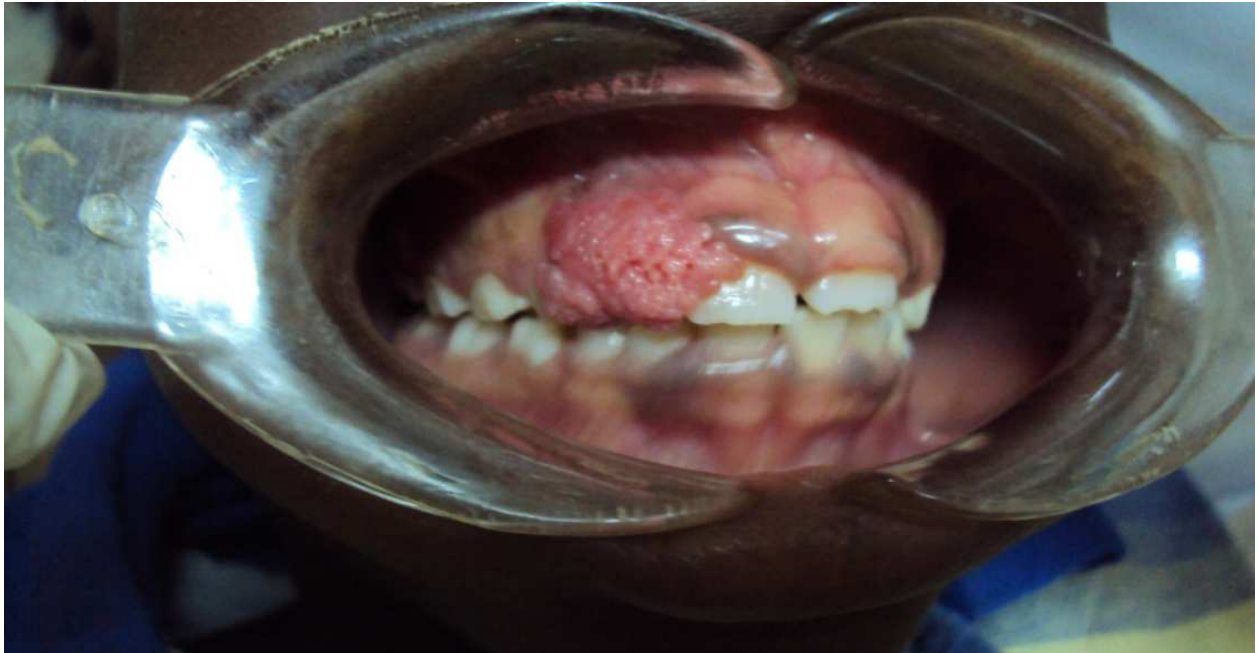

Fig. 7a. Hyperplastic gingivae and generalized gingivitis in a 7 year old boy on carbamazepine for epilepsy

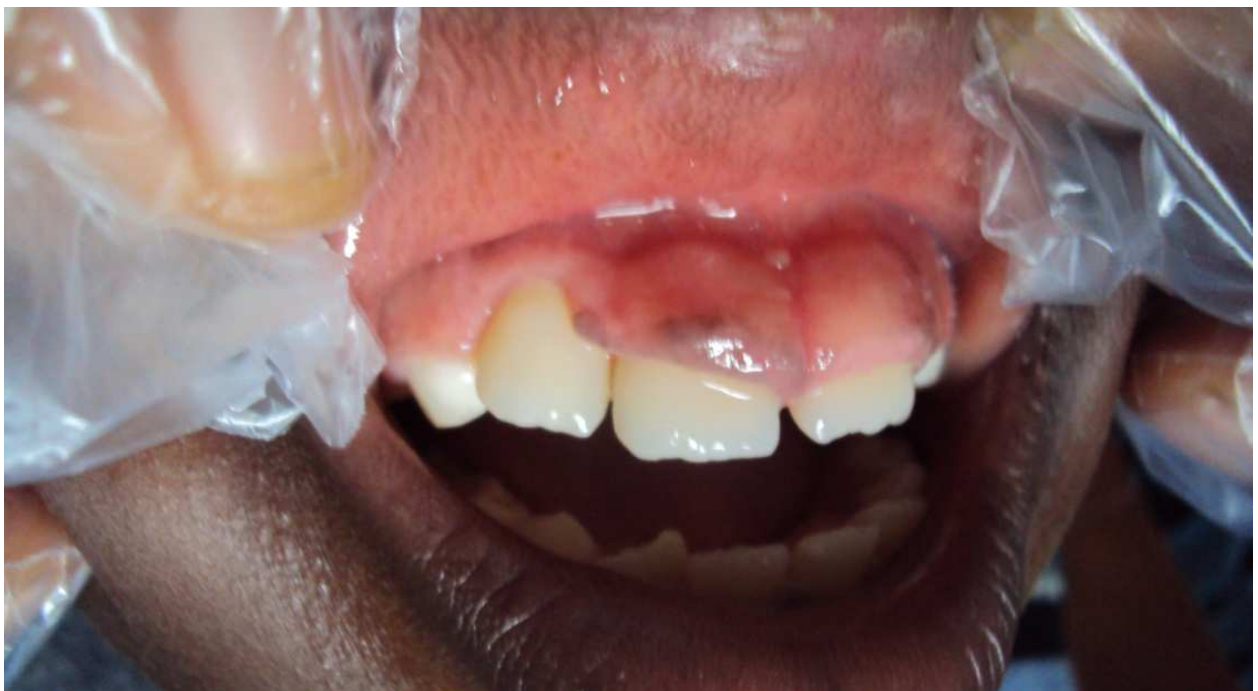

Fig. 7b. Post-operative appearance after excision of hyperplastic mass and removal of plaque

8.1 Gingivitis and orofacial clefts

Children with clefts have been found to show an increase in gingival inflammation when compared with control subjects (Lucas et al, 2000; Perdikogianni et al, 2009)). The cleft deformity, the soft tissue folds, the shallow vestibule, the dental arch irregularities, the long term orthodontic treatment and scar tissue observed in the region, after surgical closure of the cleft defect hinder optimal oral hygiene control (Stec et al, 2007). Parents and care givers should be educated on the method of plaque control as early as possible after presentation in the dental clinic to control plaque, thereby reducing inflammatory gingival and periodontal diseases. For the very young patients, chlorhexidine wipe after careful toothbrushing will reduce bacterial load and recurrent respiratory tract infections which follow aspiration of oral contents.

8.2 Gingivitis and neuromuscular disorders

Reduced muscle strength and motor function characterize conditions such as cerebral palsy (CP), poliomyelitis, myotonic dystrophy and Duchenne muscular dystrophy. Individuals affected by these conditions also have oral motor dysfunction, impairment of lip and tongue motility, lip force and chewing capacity which contribute to poor oral self cleansing ability and plaque and calculus accumulation. Several studies have shown poor oral hygiene and a higher prevalence of gingivitis and periodontal disease in these groups of individuals (Balasubramaniam et al, 2008; Symons et al, 2002; Engvall et al, 2009). According to findings from a recent study of a group of Nigerian individuals with CP and controls, gingivitis was more prevalent among those with CP (Oredugba, 2011). Mouth breathing and food pouching contribute to gingivitis especially in the anterior region in individuals with CP (Scully & Cawson, 2005). Gingival and periodontal diseases have been reported to be common, especially in older children with CP due to poor oral hygiene and complications of oral habits, physical disabilities, malocclusion and gingival hyperplasia caused by medications (National Institute of Dental and Craniofacial Research, 2004). Mouth breathing worsens the periodontal state and papillary hyperplastic gingivitis may be seen even in the absence of phenytoin (Scully & Cawson, 2005). Early routine oral care and close supervision will prevent the untoward consequence of periodontal disease.

8.3 Gingivitis and metabolic conditions

Diabetes mellitus (DM) is one of the most common chronic metabolic diseases of glucose metabolism which affects almost all the organs of the body. The Type 1 DM is the juvenile onset type which affects young people. Diabetes-related abnormalities include impaired hepatic glucose uptake, alterations in immune function, early cellular senescence and premature apoptosis (Crofford, 1995; Acikgoz et al, 2004). The oral environment is characterized by the presence of moisture, warmth and a constant reservoir of micro organisms and so, individuals with diabetes are at increased risk for oral diseases such as gingivitis and periodontal disease. Good and sustained glycaemic control will however reduce this risk considerably.

8.4 Gingivitis and haematological conditions

Gingivitis may be seen in patients affected by haematological conditions such as haemophilia, aplastic anaemia and leukaemia. Oral hygiene maintenance may be impaired because of their reluctance to brush their teeth for fear of increased gingival bleeding (Oyaizu et al, 2005). In very young children, the gingival bleeding may be experienced for

the first time during exfoliation of primary teeth and eruption of the first set of permanent teeth (Figs 8a & 8b).

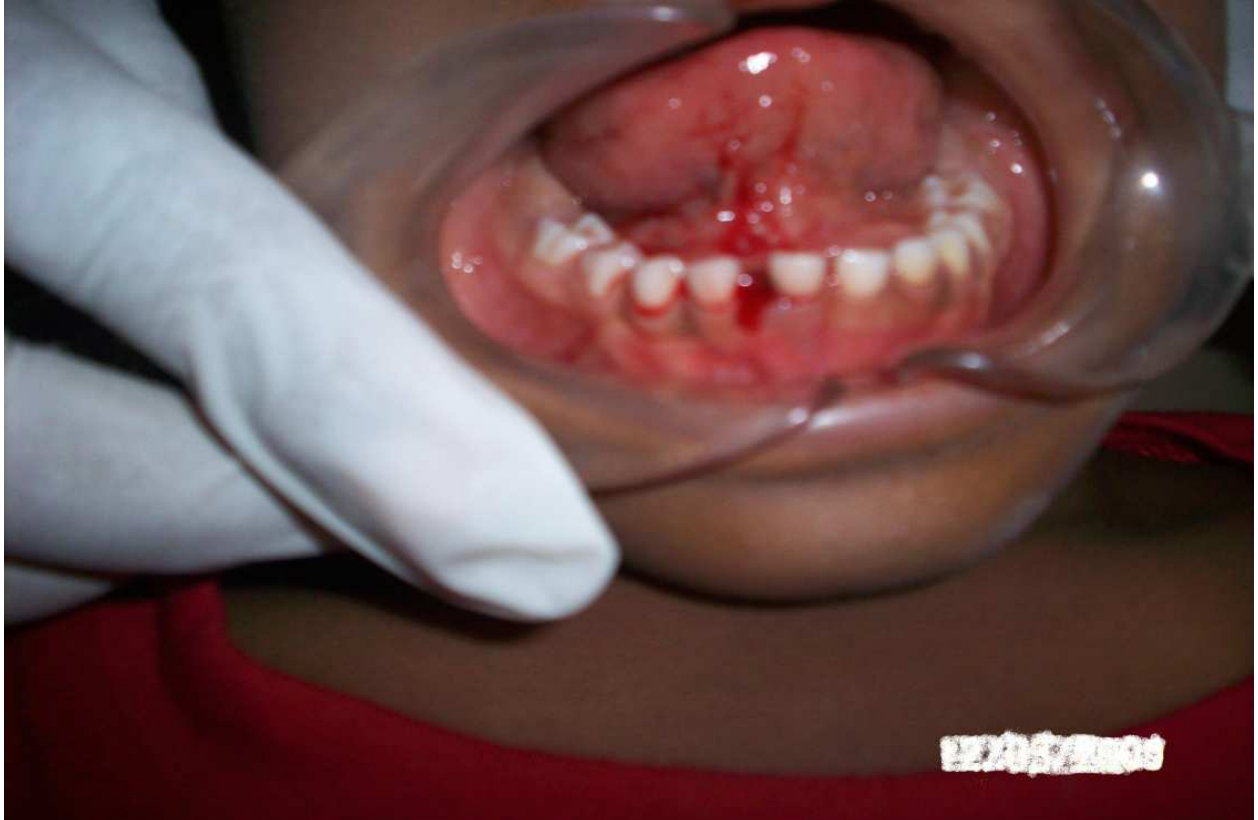

Fig. 8a. Gingival bleeding and gingivitis associated with plaque accumulation in a 3 year old haemophiliac (*Reproduced with permission from Nigerian Dental Journal, 2010, Vol.18,1*)

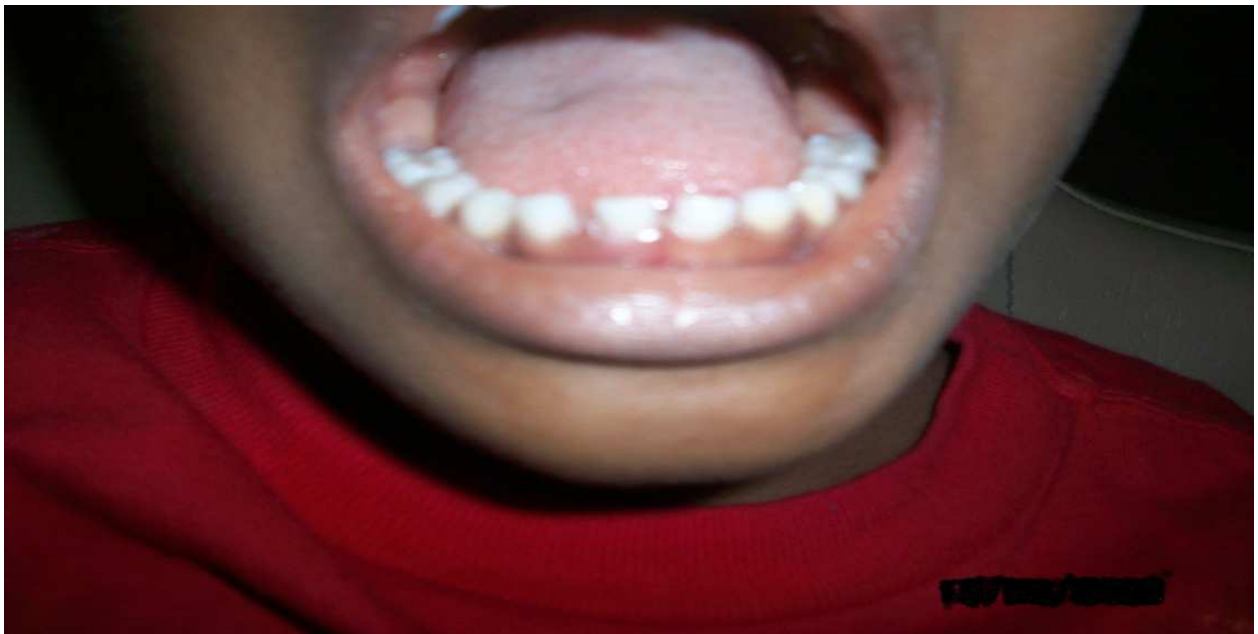

Fig. 8b. Clinical appearance after administration of Factor VIII and removal of plaque (*Reproduced with permission from Nigerian Dental Journal, 2010, Vol.18,1*)

Patients with aplastic anaemia have a weak immune response due to the concurrent immuno suppressive therapy and neutropenia (Agnihotri et al, 2009). Opportunistic infections from normal oral bacteria, periodontal pathogens or mixed odontogenic pathogens may also develop.

Oral findings in aplastic anaemia include gingival haemorrhage, mucosal petechiae, purpura and ecchymoses due to thrombocytopenia (Neville et al, 2004). Ulcerative lesions with erythematous margins, especially of the gingiva, may develop in association with secondary infection (Oyaizu et al, 2005). Gingival hyperplasia, swelling and submucosal haemorrhage may also be present (Luker et al, 1991; Brennan et al, 2001). Patients with leukaemia present with bleeding diathesis, petechiae, oral ecchymosis, gingival haemorrhage and progressive gingival enlargement (Weckx et al, 1990; Genc et al, 1998). The change in gingival morphology and its cyanotic appearance may result from reactive hyperplasia, dense leukaemic infiltration of connective tissue and compression of local vasculature, causing ischaemia (Abdullah et al, 2002; Cooper et al, 2000). Caries, calculus and poor oral hygiene, place the patient at risk for oral pain, bleeding, super infection and tissue necrosis, exacerbating gingival signs and symptoms (Cooper et al, 2000).

Severe persistent gingival inflammation and stomatitis are some of the features of severe congenital neutropenia heightened by susceptibility to bacterial infections due to impaired bone marrow myelopoiesis and an absolute neutrophil count (ANC) in the peripheral blood of $< 0.2 \times 10^9/L$ (Okada et al, 2001; Zeidler et al, 2009). Periodontal manifestations may range from marginal gingivitis to rapidly progressive periodontal disease with advancing bone loss, which may affect both primary and permanent dentitions, but primarily the permanent dentition (Zeidler et al, 2000). Although an individual's susceptibility to gingivitis and periodontal disease is influenced by many factors such as systemic diseases and genetics, evidence indicates that prevention of gingival inflammation by dental plaque control reduces the severity of disease in this group of individuals (Antonio et al, 2010). Such individuals should be motivated to maintain good oral hygiene. In most haematologic conditions, the most important part of patient management is making the patients and their relatives aware of the importance of preventive measures and the need for medical as well as dental appointments at appropriate intervals (Ranjith et al, 2008).

While it is difficult to determine the relative importance of each aetiological or facilitating factor for gingival and periodontal diseases, there is increasing data that indicates that environmental, dietary, behavioural and systemic factors, (including the genetic complement of the host) have an important role in gingival and periodontal disease initiation, progression and response to treatment (Hart, 2001; Shenkein, 2001)

9. Conclusion

Several factors such as genetics, systemic conditions, medications, diet and individual host response to infection have been identified in the aetiology of gingivitis in children. However, the most significant facilitating factor is dental plaque which could be controlled by mechanical means and use of topical chemical agents. Parents, relatives and care givers should be educated on the need for effective plaque control to prevent the condition.


10. References

- Abdullah, BH; Yahyah, HI; Kumoona, RK; Hilmi, FA. & Mirza, KB. (2002). Gingival fine needle aspiration cytology in acute leukaemia. *Journal of Oral Pathology and Medicine*, Vol.31, pp. 55-58
- Acikgoz, G; Devrim, I. & Ozdamar, S. (2004). Comparison of keratinocyte proliferation in diabetic and non- diabetic inflamed gingiva. *Journal of Periodontology*, Vol. 75, pp. 989-994
- Agarwal, PK; Agarwal, KN. & Agarwal, DK. (1984). Biochemical changes in saliva of malnourished children. *American Journal of Clinical Nutrition*, Vol. 39, pp. 181-184
- Agnihotri, R; Bhat, KM; Bhat, GS. & Pandurang, P. (2009). Periodontal management of a patient with severe aplastic anaemia: a case report. *Special Care Dentistry*, Vol. 29, pp. 141-144
- Al-Meshal, IA. (1988). Effect of (alpha) chationone, an active principle of *Catha edulis* Forssk (khat) on plasma amino acid levels and other biochemical parameters in male wistar rats. *Phytotherapy Research*, Vol. 2, pp. 63-66
- Antonio, AC; Alcantara, PC; Ramos, MEB. & de Souza, PR. (2010). The importance of dental care for a child with severe congenital neutropaenia: a case report. *Special Care Dentistry*, Vol. 30, pp. 261-265
- Arduino, PG; D' Aiuto, F; Cavallito, C; Carcieri, P; Carbone, M; Conrotto, D; Defabianis, P. & Broccoletti, R. (2011). Professional oral hygiene as a therapeutic option for pediatric patients with plasma cell gingivitis: preliminary results of a prospective case series. *Journal of Periodontology*, May 12, (doi:10.1902/jop.2011.100663
- Balasubramaniam, R; Sollecito, TP. & Stoopler, ET. (2008). Oral health considerations in muscular dystrophies. *Special Care Dentistry*, Vol. 28, pp. 243-253
- Battino, M; Ferreira, MS; Garrlado, I; Newman, HN. & Bullon, P. (2002). The antioxidant capacity of saliva. *Journal of Clinical Periodontology*, Vol. 29, pp. 189-194
- Bello, LL. & Al-Hammad, N. (2006). Pattern of fluid consumption in a sample of Saudi Arabian adolescents aged 12-13 years. *International Journal of Paediatric Dentistry*, Vol. 16, pp. 168-173
- Brennan, MT; Sankar, V. & Baccaglini, L. (2001). Oral manifestations in patients with aplastic anaemia. *Oral Surgery Oral Medicine Oral Pathology Oral Radiology and Endodontics*, Vol. 92, pp. 503-508
- Cooper, CL; Loewen, R. & Shore, T. (2000). Gingival hyperplasia complicating acute myelomonocytic leukaemia. *Journal of Canadian Dental Association*, Vol. 66, pp. 78-79
- Crielaard, W; Zaura, E; Schuller, AA; Huse, SM; Montijn, RC. & Keijser, BJJ. (2011). Exploring the oral microbiota of children at various developmental stages of their dentition in relation to their oral health. *BioMedCentral Medical Genomics* Vol. 4, 22
- Crofford, OB. (1995). Diabetic control and complications. *Annual Review of Medicine*, Vol. 46, pp. 267-279
- Cury, PR; Arsati, F; de Magalhaes, MH; de Araujo, VC; de Araujo, NS. & Barbuto, JA. (2009). Antigen-presenting cells in human immuno-suppressive drug-induced gingival enlargement. *Special Care Dentistry*, Vol. 29, pp. 80-84
- Fleming, T. (1999). Periodontitis. *Annals of Periodontology. International Workshop for Classification of Periodontal Diseases and Conditions*, Vol. 4, pp. 32-35
- Forsberg, H; Quick-Nilsson, I; Gustavson, KH. & Jagell, S. (1985). Dental health and dental care in severely mentally retarded children. *Swedish Dental Journal*, Vol. 9, pp. 15-28

- Gafan, GP; Lucas, VF; Roberts, GJ; Petrie, A; Wilson, M. & Spratt, DA. (2004). Prevalence of periodontal pathogens in dental plaque of children. *Journal of Clinical Microbiology*, Vol. 42, pp. 4141-4146
- Genc, A; Atalay, T; Gedikoglu, G; Zulfikar, B. & Kullu, S. (1998). Leukemic children: clinical and histopathological gingival lesions. *Journal of Clinical Pediatric Dentistry*, Vol. 22, pp. 253-256
- Goodson, JM; Palys, MD; Carpino, E et al (2004). Microbiological changes associated with dental prophylaxis. *Journal of American Dental Association*, Vol. 35, pp. 1559-1564
- Halbach, H. (1972). Medical aspects of the chewing of khat leaves. *Bulletin of the World Health Organization* Vol. 47, pp. 21-29
- Han, Y. & Liu, HW. (2010). Progress on study on oral lesions in patients with AIDS. *Beijing Da Xue Xue Bao*, Vol. 42, pp. 117-121
- Hart, TC. (2001). Genetic aspects of periodontal diseases. In: Bimstein, E; Needleman, HL; Karinbux, N. & Van Dyke, TE. *Periodontal and Gingival Health and Diseases. Children, Adolescents and Young Adults*. London, England:Martin Dunitz Ltd, pp. 189-204
- Johansson, I; Ericsson, T. & Steen, L. (1984). Studies of the effect of diet on saliva secretion and caries development: the effect of fasting on saliva composition of female subjects. *Journal of Nutrition*, Vol. 114, pp. 2010-2020
- Jones, CG. (2000). Chlorhexidine: is it still the good standard? *Periodontology*, Vol 15, pp. 55-62
- Kalix, P. (1988). Khat: A plant with amphetamine effects. *Journal of Substance Abuse and Treatment*, Vol. 5, pp. 163-169
- Kimura, S; Ooshima, T; Takiguchi, M; Sasaki, Y; Amano, A; Morisaki, I. & Hamada, S. (2002). Periodontopathic bacterial infection in childhood. *Journal of Periodontology*, Vol. 73, pp. 20-26
- Kononen, E. (1999). Oral colonization by anaerobic bacteria during childhood: role in health and disease. *Oral Diseases*, Vol. 5, pp. 278-285
- Lamster, IB; Grbic, JT; Mitchell-Lewis, DA; Begg, MD. & Mitchell, A. (1998). New concepts regarding the pathogenesis of periodontal disease in HIV infection. *Annals of Periodontology*, Vol. 3, pp. 62-75
- Leroy, R; Jara, A; Martens, L. & Declerck, D. (2011). Oral hygiene and gingival health in Flemish pre-school children. *Community Dental Health*, Vol. 28, pp. 75-81
- Loe, H; Theilade, E. & Jensen, SB. (1965). Experimental gingivitis in man. *Journal of Periodontology*, Vol. 36, pp. 177-187
- Lovegrove, JM. (2004). Dental plaque revisited: bacteria associated with periodontal disease. *Journal of New Zealand Society of Periodontology*, Vol. 87, pp. 7-21
- Lucas, VS; Gupta, R; Ololade, O; Gelbier, M. & Roberts, GJ. (2000). Dental health indices and caries associated microflora in children with unilateral cleft lip and palate. *Cleft Palate and Craniofacial Journal*, Vol. 37, pp. 447-452
- Luker, J; Scully, C. & Oakhill, A. (1991). Gingival swelling as a manifestation of aplastic anaemia. *Oral Surgery Oral Medicine Oral Pathology*, Vol. 71, pp. 55-56
- Macleod, RI. & Ellis, JE. (1989). Plasma cell gingivitis related to the use of herbal toothpaste. *British Dental Journal*, Vol. 166, pp. 375-376
- Majewsky, R. (2001). Dental caries in adolescents associated with caffeinated carbonated beverages. *Pediatric Dentistry* Vol. 23, pp. 198-203
- Marker, P. & Krogdahl, A. (2002). Plasma cell gingivitis apparently related to the use of khat: report of a case. *British Dental Journal*, Vol. 192, pp. 311-313

- Matsson, L. (1993). Factors influencing the susceptibility to gingivitis during childhood - a review. *International Journal of Paediatric Dentistry*, Vol. 3, pp. 119-127
- Meyer, AC; Tera T; da Rocha, AC. & Jardini MAN. (2010). Clinical and microbiological evaluation of the use of toothpaste containing 1% chlorhexidine and the influence of motivation on oral hygiene in patients with motor deficiency. *Special Care Dentistry*, Vol. 30, pp. 140-145
- Mundorff-Shrestha, SA; Featherstone, JDB. & Eisenberg, AD. et al (1994). Cariogenic potential of foods. *Caries Research*, Vol. 28, pp. 106-115
- Nahar, SG; Hossain, MA; Howlader, MB. & Ahmed, A. (2010). Oral health status of disabled children. *Bangladesh Medical Research Council Bulletin*, Vol. 36, pp. 61-63
- National Institute of Dental and Craniofacial Research. (2004). Practical oral care for people with cerebral palsy. *National Oral Health Information Clearinghouse, Bethesda, MD*.
- Nejat, R; Nejat, D. & Nejat, M. (2007). Periodontal inflammation: the oral-body connection. *The Academy of Dental Therapeutics and Stomatology*. September, PennWell Publications
- Neville, BW; Damm, DD; Allen, CM. & Bouquot, JE. (1995). *Oral and Maxillofacial Pathology*. Philadelphia: WB Saunders Company, pp. 126-127
- Neville, BW; Damm, DD; Allen, CM. & Bouquot, JE. (2004). Hematological disorders. In: Neville BW, Damm DD, Allen CM, Bouquot JE (eds). *Oral and Maxillofacial Pathology*. Philadelphia, PA. WB Saunders Company, pp. 497-531
- O'Brien, PJ. (1994). Antioxidants and cancer: molecular mechanisms. In: Armstrong D (ed). *Free Radicals in Diagnostic Medicine*. 2nd edition, New York. Plenum Press. Pp. 215-232
- Oh, TJ; Eber, R. & Wang, HL. (2002). Periodontal disease in the child and adolescent. *Journal of Clinical Periodontology*, Vol. 29, pp. 400-410
- Okada, M; Kobayashi, M; Hino, T; Kurihara, H. & Miura, K. (2001). Clinical periodontal findings and microflora profiles in children with chronic neutropenia under supervised oral hygiene. *Journal of Periodontology*, Vol. pp. 72, 945-952
- Oredugba, FA. & Akindayomi, Y. (2008). Oral health status and treatment needs of children and young adults attending a day centre for individuals with special needs. *BioMedCentral Oral Health*, Vol. 8, 30
- Oredugba, FA. (2006). Use of oral health care services and oral findings in children with special needs in Lagos, Nigeria. *Special Care Dentistry*, Vol. 26, pp. 59-65
- Oredugba, FA. (2011). Comparative oral health of children and adolescents with cerebral palsy and controls. *Journal of Disability and Oral Health*, Vol. 12, pp. 81-87
- Page, RC. & Shroeder, HE. (1976). Pathogenesis of inflammatory periodontal disease. *Laboratory Investigations*, Vol. 33, pp. 235-249
- Papaoiannou, W; Gizani, S; Haffajee, AD; Quirynen, M; Mama-Homata, E. & Papagiannoulis, L. (2009). The microbiota on different oral surfaces in healthy children. *Oral Microbiology and Immunology*, Vol. 24, pp. 183-189
- Perdikogianni, H; Papaoiannou, W; Nakou, M; Oulis, C. & Papagianoulis, L. (2009). Periodontal and microbiological parameters in children and adolescents with cleft lip and/palate. *International Journal of Paediatric Dentistry*, Vol. 19, pp. 455-467
- Portela, MB; Souza, IPR; Costa, EMMB; Hagler, AN; Soares, RMA. & Santos, ALS. (2004). Differential recovery of *Candida* species from subgingival sites in human immunodeficiency virus-positive and healthy children from Rio de Janeiro, Brazil. *Journal of Clinical Microbiology*, Vol. 42, pp. 5925-5927

- Ramzi, S; Conran, SL; Robins, V; Kumar, V; Robbins J. & Perkins A. (2002) *Basic Pathology*, 7th Edition. Harcourt Publishers Limited.
- Ranjith, A; Nandakumar, K. & Glanzmann, A. (2008). Thrombasthenia; a rare hematological disorder with oral manifestations: a case report. *Journal of Contemporary Dental Practice*, Vol. 9, pp. 107-113
- Robbins, MR. (2009). Dental management of special needs patients who have epilepsy. *Dental Clinics of North America*, Vol. 53, pp.295-309
- Schenkein, HA. (2001). Pathogenesis of aggressive periodontitis. In: Bimstein, E; Needleman, HL; Karinbux, N. & Van Dyke, TE. *Periodontal and Gingival Health and Diseases. Children, Adolescents and Young Adults*. London, England: Martin Dunitz Ltd, pp. 147-197
- Scully, C. & Cawson, RA. (2005). Neurological disorders I: Epilepsy, stroke and craniofacial neuropathies. In: *Medical Problems in Dentistry*. 5th Edition, Elsevier, Churchill Livingstone, pp. 297-298
- Serio, FG. & Duncan, TB. (2009). The pathogenesis and treatment of periodontal disease. *Academy of Dental Therapeutics and Stomatology*. PennWell Publications, pp. 1-12
- Serio, FG; Siegel, MA. & Slade, BF. (1991). Plasma cell gingivitis of unusual origin. *Journal of Periodontology*, Vol. 62, pp. 390-393
- Stec, M; Szczepanska, J; Pypec, J. & Hirschfelder, U. (2007). Periodontal status and oral hygiene in two populations of cleft patients. *Cleft Palate and Craniofacial Journal*, Vol. 44, pp. 73-78
- Surabian, SR. (2001). Developmental disabilities and understanding the needs of patients with mental retardation and Down syndrome. *Journal of Californian Dental Association*, Vol. 29, pp. 415-423
- Surabian, SR. (2001). Developmental disabilities: epilepsy, cerebral palsy and autism. *Journal of Californian Dental Association*, Vol. 29, pp. 424-432
- Symons, AI; Townsend, GC. & Hughes, TE. (2002). Dental characteristics of children with Duchenne muscular dystrophy. *Journal of Dentistry for Children*, Vol. 69, pp. 277-283, 234
- Thomason, JM; Seymour, RA. & Rawlins, MD. (1992). Incidence and severity of phenytoin-induced gingival overgrowth in epileptic patients in general medical practice. *Community Dentistry and Oral Epidemiology*, Vol. 20, pp. 288-291
- Trackman, PC. & Kantaki, A. (2004). Connective tissue metabolism and gingival overgrowth. *Critical Review of Oral Biology and Medicine* Vol. 15, pp. 165-175
- Tulunoglu, O; Demirtas, S. & Tulunoglu, I. (2006). Total antioxidant levels of saliva in children related to caries, age and gender. *International Journal of Paediatric Dentistry* Vol. 16, pp. 186-191
- Twetman, S. (2004). Antimicrobials in future caries control? A review with special reference to chlorhexidine treatment. *Caries Research*, Vol. 38, pp. 223-229
- Weckx, LL; Hidal, LB. & Marcucci, G. (1990). Oral manifestations of leukaemia. *Ear Nose and Throat Journal*, Vol. 69, pp. 341-342, 345-346
- Zeidler, C; Boxer, L; Dale, DC; Freedman, MH; Kinsey, S. & Welte, K. (2000). Management of Kostmann syndrome in the G-CSF era. *British Journal of Haematology*, Vol. 109, pp. 490-495
- Zeidler, C; Germeshausen, M; Klein, C. & Welte, K. (2009). Clinical implications of ELA 2-, HAX 1-, and G-CSF receptor (CSF3R) mutations in severe congenital neutropenia. *British Journal of Haematology*, Vol. 144, pp. 459-467



Oral Health Care - Pediatric, Research, Epidemiology and Clinical Practices

Edited by Prof. Mandeep Viridi

ISBN 978-953-51-0133-8

Hard cover, 302 pages

Publisher InTech

Published online 29, February, 2012

Published in print edition February, 2012

Oral health care in pediatric dentistry deals with complete oral health, including preventive aspects for children right from their conception to adolescence, encompassing all the spheres of dentistry including various specialties. It also includes planning a preventive program at individual and community levels. The current research interests in oral health care include studies regarding the role of stem cells, tissue culture, and other ground-breaking technologies available to the scientific community in addition to traditional fields such as anatomy, physiology, and pharmaceuticals etc of the oral cavity. Public health and epidemiology in oral health care is about the monitoring of the general oral health of a community, general afflictions they are suffering from, and an overall approach for care and correction of the same. The oral health care-giver undertakes evaluation of conditions affecting individuals for infections, developmental anomalies, habits, etc. and provides corrective action in clinical conditions. The present work is a compendium of articles by internationally renowned and reputed specialists about the current developments in various fields of oral health care.

How to reference

In order to correctly reference this scholarly work, feel free to copy and paste the following:

Folakemi Oredugba and Patricia Ayanbadejo (2012). Gingivitis in Children and Adolescents, Oral Health Care - Pediatric, Research, Epidemiology and Clinical Practices, Prof. Mandeep Viridi (Ed.), ISBN: 978-953-51-0133-8, InTech, Available from: <http://www.intechopen.com/books/oral-health-care-pediatric-research-epidemiology-and-clinical-practices/gingivitis-in-children-and-adolescents>

INTECH
open science | open minds

InTech Europe

University Campus STeP Ri
Slavka Krautzeka 83/A
51000 Rijeka, Croatia
Phone: +385 (51) 770 447
Fax: +385 (51) 686 166
www.intechopen.com

InTech China

Unit 405, Office Block, Hotel Equatorial Shanghai
No.65, Yan An Road (West), Shanghai, 200040, China
中国上海市延安西路65号上海国际贵都大饭店办公楼405单元
Phone: +86-21-62489820
Fax: +86-21-62489821

© 2012 The Author(s). Licensee IntechOpen. This is an open access article distributed under the terms of the [Creative Commons Attribution 3.0 License](#), which permits unrestricted use, distribution, and reproduction in any medium, provided the original work is properly cited.

IntechOpen

IntechOpen