

We are IntechOpen, the world's leading publisher of Open Access books Built by scientists, for scientists

4,800

Open access books available

122,000

International authors and editors

135M

Downloads

Our authors are among the

154

Countries delivered to

TOP 1%

most cited scientists

12.2%

Contributors from top 500 universities

**WEB OF SCIENCE™**Selection of our books indexed in the Book Citation Index
in Web of Science™ Core Collection (BKCI)

Interested in publishing with us?
Contact book.department@intechopen.com

Numbers displayed above are based on latest data collected.
For more information visit www.intechopen.com



Treatment of Diabetic Macular Edema – Latest Therapeutic Developments

Yeon Sung Moon and Na Rae Kim*
Inha University School of Medicine
Korea

1. Introduction

Macular edema is a frequent manifestation of diabetic retinopathy and an important cause of impaired vision in individuals with diabetes (Klein et al., 1984; Moss et al., 1998). The Wisconsin Epidemiologic Study of Diabetic Retinopathy (WESDR), a population-based study in southern Wisconsin, estimated that after 20 years of known diabetes, the prevalence of diabetic macular edema (DME) was approximately 28% in both type 1 and type 2 diabetes (Klein, et al., 1984)

Despite recent attempts at strict glycemic control and optimization of other important systemic parameters such as hypertension and hyperlipidemia, diabetic retinopathy continues to be a leading cause of new onset vision loss worldwide in the working age population (DCCT Group, 1995). Although severe vision loss can occur from proliferative diabetic retinopathy (PDR), DME accounts for the majority of vision loss (Moss, et al., 1998).

Treatment for DME is continuously evolving. While focal laser photocoagulation remains the standard of care, a new wave of studies is emerging that shows the benefits of adjunctive therapy for DME. The goal of this chapter is to briefly summarize recent strategies for the treatment of DME.

2. Treatment of diabetic macular edema

DME has been an area of particular interest for clinical investigators. Although PDR is the cause of severe vision loss, DME is more prevalent and is the leading cause of moderate vision loss in patients with diabetic retinopathy. By disruption of the inner blood-retinal barrier, retinal vessels become permeable, leading to the exudation of fluid and lipids into the macula, which ultimately leads to a decline in vision (Bhagat et al., 2009).

The Early Treatment for Diabetic Retinopathy Study (ETDRS) was the first randomized and controlled trial to examine therapy for DME, and it demonstrated that focal (direct/grid) laser photocoagulation reduces moderate vision loss caused by DME by 50% or more (ETDRS group, 1987a). The ETDRS also indicated that focal laser treatment is not an ideal therapy. Focal laser treatment failed to prevent vision loss in a large number of patients, and it did not improve vision in the majority of patients (ETDRS group, 1985).

*Yeon Sung Moon and Na Rae Kim have contributed equally to this chapter.

2.1 Laser treatment

Laser photocoagulation remains the standard of care and the only treatment with proven efficacy in a large-scale clinical trial for this condition. The ETDRS demonstrated the efficacy of focal/grid photocoagulation in reducing the risk of moderate vision loss from DME (ETDRS group, 1991). The beneficial outcomes of focal/grid laser in an era of improved glycemic control were confirmed and expanded in recent clinical trials conducted by the Diabetic Retinopathy Clinical Research Network (DRCR.net) (Aiello et al., 2010; Beck et al., 2009; DRCR net, 2008).

Focal/grid photocoagulation has potential side effects, including laser scar expansion, paracentral scotomata, elevation of central visual field thresholds, and secondary choroidal neovascularization and subretinal fibrosis (Guyer et al., 1992; Han et al., 1992; Schatz et al., 1991). Modifications to the focal/grid photocoagulation technique have been made in response to these potential side effects. A comparison across studies suggests that outcomes with current modified techniques may be similar to those obtained with the original ETDRS technique (DRCR net, 2009).

2.1.1 Focal / grid laser photocoagulation

To characterize the severity of macular edema and for treatment guidelines, the term clinically significant macular edema (CSME) is defined: retinal thickening at or within 500 μ m of the foveal center, hard exudates at or within 500 μ m of the foveal center with adjacent retinal thickening, or retinal thickening greater than 1 disc diameter in size, within 1 disc diameter of the foveal center (ETDRS group, 1985, 1987a).

There is good evidence that focal laser treatment preserves vision in eyes with DME. The ETDRS randomized 1490 eyes with DME to receive focal laser treatment or observation (ETDRS group, 1985). Retreatment was applied at 4-month intervals if CSME persisted, one or more treatable lesions were identified, and the investigator believed these lesions were responsible for the edema (ETDRS group, 1987b). At 3 years, treatment significantly reduced moderate visual loss as compared with observations, with the greatest benefits in eyes with CSME (ETDRS group, 1987b).

Although focal laser photocoagulation reduces the risk of moderate visual loss by approximately 50%, approximately 12% of treated eyes still lose vision, many because of persistent DME (ETDRS group, 1985). Kim et al. assessed macular optical coherence tomography (OCT) findings of DME patients to determine whether specific OCT patterns are predictive of visual outcome after focal laser photocoagulation (Kim et al., 2009). DME was classified into four different OCT patterns, which are: diffuse retinal thickening, cystoids macular edema, serous retinal detachment, and vitreomacular interface abnormalities (Figure 1). In this study, eyes with diffuse retinal thickening achieved a greater visual acuity increase than eyes with other patterns.

It is unclear how focal retinal laser exerts its effects. One theory is that it improves oxygenation to the inner retina by eliminating highly oxygen-dependent photoreceptors (Gottfredsdottir et al., 1993; Stefansson, 2001). Another theory is that the laser reduces the retinal capillary area and thereby reduces leakage (Wilson et al., 1988). Other authors postulate that photocoagulation restores the outer blood-retinal barrier (Bresnick, 1983).

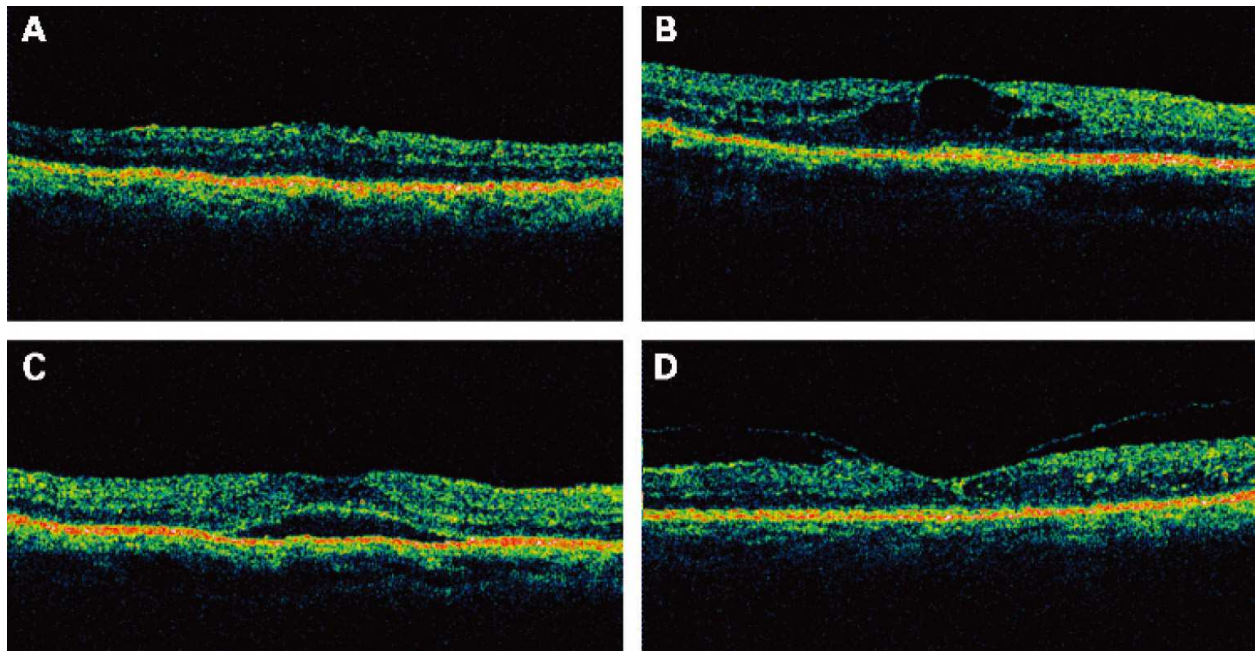


Fig. 1. Different patterns of diabetic macular edema by optical coherence tomography. (A) Diffuse retinal thickening appears as a sponge-like retinal swelling with areas of reduced intraretinal reflectivity. (B) Cystoid macular edema showing intraretinal cystoid spaces. (C) Serous retinal detachment showing shallow elevation of the retina, with an optically clear space between the retina and the retinal pigment epithelium. (D) Vitreomacular interface abnormalities showing a highly reflective band over the inner retinal surface and extending towards the optic nerve or peripherally.

2.1.2 Modified ETDRS direct/grid photocoagulation

Although effective, ETDRS protocol for photocoagulation may require placement of burns close to the center of the macula. Over time, laser burns may develop into areas of progressive retinal pigment epithelium and retinal atrophy that become larger than the original laser spot size and this may encroach upon fixation (Schatz, et al., 1991). In an attempt to reduce these adverse effects, many retinal specialists now treat patients using burns that are lighter and less intense than what was originally specified in the ETDRS, although no clinical trials have been performed to show improved outcomes with this approach (Akduman & Olk, 1999).

These include specifications with maximal spot sizes of 50 μ m, allowing the use of yellow and green wavelengths, not requiring blanching of large microaneurysms as long as the subjacent retinal pigment epithelium is lightly blanched, and removing the requirement for fluorescein angiography to guide treatment (Abu el Asrar & Morse, 1991; Fong et al., 2007). A modified ETDRS focal/grid photocoagulation protocol including all these changes has been adopted as the standard laser technique for DME used in DRCR Network studies.

2.1.3 Mild Macular Grid (MMG) laser photocoagulation

An alternative approach is the mild macular grid (MMG) technique, the application of mild, widely spaced burns throughout the macula (avoiding the foveal region). By design, some burns could be placed in clinically normal appearing retina if the entire retina was not

abnormally thickened, including areas within the macula that are relatively distant from the area of thickening. The lighter burns applied to the macula are theoretically less likely to result in thermal injury to the overlying retina and less likely to break the Bruch membrane. The widespread application also might lead to improved oxygenation, development of healthier retinal pigment epithelium, and overall physiologic improvement of the entire macula.

The DRCR Network trial was designed to compare 2 laser techniques for previously untreated DME. One technique was the most commonly used approach in current clinical practice, the modified ETDRS technique, and the other approach was the MMG technique. At 12 months after treatment, the MMG technique was less effective at reducing OCT-measured retinal thickening than the current modified ETDRS laser photocoagulation approach. The visual acuity outcomes with both approaches were not substantially different. (Fong, et al., 2007).

2.1.4 Subthreshold Micropulse Diode Laser Photocoagulation (SMDLP)

Many laser modalities such as argon blue-green, argon green, krypton and diode have been used to achieve a clinically visible burn (threshold burn) according to the conventional photocoagulation protocol (Akduman & Olk, 1997; Olk, 1990). Subthreshold micropulse diode laser photocoagulation (SMDLP) is designed to target the retinal pigment epithelium while minimizing the negative thermal effects on the neural retina and deeper structures. A micropulse diode laser allows subthreshold therapy without a visible burn end point, and has been shown to be as effective as standard argon laser photocoagulation in reducing DME, while potentially allowing for more frequent re-dosing (Jain et al., 2010).

A study comparing the efficacy and side effects of conventional green laser photocoagulation and SMDLP treatment for diabetic CSME was conducted with prospective, randomized, double-masked manner. There were no statistically significant differences in best-corrected visual acuity (BCVA), contrast sensitivity and retinal thickness between the two laser modalities at 0, 4 and 12 months. It is found that laser scarring was much more apparent with conventional green laser than with the SMDLP (Figueira et al., 2009).

Recently, Lavinsky et al. conducted a prospective, randomized, controlled, double-masked clinical trial comparing modified ETDRS focal/grid laser photocoagulation with normal-density or high-density SMDLP for the treatment DME. In this study, the subthreshold micropulse 810-nm diode laser technique delivered in a high-density manner was superior to the standard mETDRS photocoagulation over at least 1 year of follow-up, with significantly more eyes gaining substantial vision and significantly fewer eyes losing substantial vision. (Lavinsky et al., 2011).

2.2 Steroid treatment

Corticosteroids are potent anti-inflammatory agents that can counteract many of the pathological processes thought to play a role in the development of macular edema. Corticosteroids prevent leukocyte migration, reduce fibrin deposition, stabilize endothelial cell tight junctions, and inhibit synthesis of vascular endothelial growth factor (VEGF), prostaglandins, and proinflammatory cytokines (Joussen et al., 2007; Kern, 2007; Leopold, 1985; Nauck et al., 1998).

The rationale for the use of corticosteroids to treat DME follows from the observation that the increase in retinal capillary permeability that results in edema may be caused by a breakdown of the blood retina barrier mediated in part by VEGF (Aiello et al., 1997; Antonetti et al., 1999; Senger et al., 1983). Corticosteroids have been demonstrated to inhibit the expression of VEGF and the VEGF gene (Nauck, et al., 1998; Nauck et al., 1997).

2.2.1 Intravitreal triamcinolone

In 2001-2002, the first reports were published of the use of intravitreal injection of triamcinolone acetonide for DME (Jonas & Sofker, 2001; Martidis et al., 2002), suggesting that intravitreal triamcinolone was potentially an efficacious treatment for DME. This treatment gained widespread use, most commonly as a dose of 4 mg of Kenalog® (Bristol-Myers Squibb, Princeton NJ), despite the lack of data from a controlled study demonstrating efficacy that exceeded risks.

In light of the short-term results from early reports of intravitreal triamcinolone for DME, the DRCR Network conducted a randomized clinical trial to evaluate the efficacy and safety of two doses of preservative-free intravitreal triamcinolone (1 mg and 4 mg) in comparison with standard focal/grid photocoagulation. At 4 months, both triamcinolone groups had greater improvement in visual acuity and macular thickness than the focal laser; however, by year one, there was no difference between the groups, and by the second year, the laser group demonstrated better visual acuity and more reduced macular thickness results over the corticosteroid groups (DRCR net, 2008). Another study in a subset of randomized subjects who completed the 3-year follow-up do not indicate a long-term benefit of intravitreal triamcinolone relative to focal/grid photocoagulation in patients with DME similar to those studied in this clinical trial (Beck, et al., 2009).

More recently, Gillies et al. reported that treatment with intravitreal triamcinolone acetonide plus laser resulted in a doubling of improvement in vision by 10 letters or more compared with a laser only over 2 years in eyes with DME. However, this treatment was associated with cataracts and a raised intraocular pressure (Gillies et al., 2011)

2.2.2 Peribulbar triamcinolone

Peribulbar injections have been performed using anterior combined sub-Tenon and subconjunctival, posterior sub-Tenon, and retrobulbar approaches. Theoretically, adverse effects may be presumed to be lower than those of intravitreal triamcinolone acetonide. A peribulbar corticosteroid injection is of particular interest for eyes with DME that have good visual acuity where the risks of an intravitreal injection of corticosteroid may not be justified (E. Chew et al., 2007).

The DRCR Network conducted a pilot study evaluating the effects of both anterior and posterior sub-Tenon delivery of peribulbar corticosteroids, with or without focal photocoagulation, in eyes with DME and good visual acuity. In cases of DME with good visual acuity, peribulbar triamcinolone, with or without focal photocoagulation, is unlikely to be of substantial benefit (E. Chew, et al., 2007). The group further reported long-term effects of anterior and posterior peribulbar injections of triamcinolone acetonide. The results suggested that the risk of intraocular pressure elevation and cataract development is increased with anterior peribulbar triamcinolone acetonide injections while ptosis development is increased with the posterior peribulbar injections (E. Y. Chew et al., 2011).

2.2.3 Dexamethasone implant

The treatment of macular edema is considerably limited by the difficulty in delivering effective doses of therapeutic agents into the vitreous cavity. In recent years, the development of a sustained-release intravitreal dexamethasone implant (Ozurdex® , Allergan Inc, Irvine, CA) enabled more controlled delivery of the drug, with a potentially lower rate of adverse events (Herrero-Vanrell et al., 2011).

In a previous study to evaluate the safety and efficacy of dexamethasone implant vs. observation in eyes with persistent DME, treatment with a 700µg intravitreal dexamethasone drug delivery system is well tolerated and produces significant improvements in BCVA, central retinal thickness, and fluorescein leakage, compared with observation (Haller, Kuppermann, et al., 2010).

2.2.4 Fluocinolone acetonide

Extended release intravitreal inserts of fluocinolone acetonide have also been evaluated for the treatment of DME. As fluocinolone acetonide has been in use for many years as a dermal product, its pharmacology, systemic metabolism and elimination are well established.

A nonbiodegradable fluocinolone acetonide, Retisert® (Bausch & Lomb, Rochester, NY) is FDA-approved for the treatment of uveitis. Surgical implantation of this polymer device initially showed evidence of benefit in reducing macular thickness in DME; however 20% of patients required filtering surgery for high intraocular pressures within 24 months (Pearson et al., 2005).

Iluvien® (Alimera Sciences, Alpharetta, GA) is another reservoir implant currently being studied in phase III trials for the treatment of DME. It was hypothesized that fluocinolone acetonide inserts may cause fewer problems with glaucoma than the surgically implanted device because of lower in vitro release rates of fluocinolone acetonide (0.2 and 0.5µg/day) and also because of a more posterior location in the eye, which may decrease exposure to the trabecular meshwork in the anterior chamber while still delivering adequate levels of fluocinolone acetonide to the retina. In a small phase II trial in patients with persistent DME despite focal laser, both 0.2- and 0.5-µg/day fluocinolone acetonide inserts significantly improved visual acuity in patients with DME over 2 years. Significantly fewer incisional glaucoma procedures were needed in the low-dose insert group (Campochiaro et al., 2010).

2.3 Anti-Vascular Endothelial Growth Factor (Anti-VEGF) injection

An alternative treatment approach, and to now, available for less than a decade, is the use of intravitreal therapies targeting VEGF (Nicholson & Schachat, 2010), the most potent known promoter of vascular permeability (Senger et al., 1990). Clinical studies have established that VEGF concentrations are elevated in eyes with DME (Funatsu et al., 2003; Funatsu et al., 2005), and preclinical studies have demonstrated that VEGF levels increased after its onset in a manner temporally correlated with the breakdown of the blood-retinal barrier (Qaum et al., 2001). Several mechanisms are believed to underlie these actions; in addition to the direct action of VEGF on the permeability of intact blood vessels, it also promotes an influx of inflammatory cells that produces endothelial cell apoptosis in the retinal vasculature (Adamis & Berman, 2008).

2.3.1 Pegaptanib

Pegaptanib (Macugen®; Eyetech Pharmaceuticals, Inc. and Pfizer Inc, New York) is a ribonucleic acid aptamer that targets the VEGF165 isoform that is currently approved in a number of countries worldwide for the treatment of neovascular age-related macular degeneration.

Cunningham et al. assessed the efficacy of pegaptanib for the treatment of DME. In a phase II trial, subjects treated with pegaptanib had better visual acuity outcomes, were more likely to show a reduction in central retinal thickness, and were deemed less likely to need additional therapy with photocoagulation at follow-up than those assigned to sham injection (Cunningham et al., 2005).

A phase 2/3, randomized, double-masked, 2-year trial has been performed to assess the safety and efficacy of intravitreal pegaptanib sodium 0.3 mg compared with sham injections in subjects with DME, with focal/grid photocoagulation being permitted as needed after week 18. In this study, intravitreal pegaptanib sodium 0.3 mg was well tolerated and demonstrated superior efficacy over the sham in the treatment of patients with DME. The proportion of patients with ≥ 10 letters (or 2 lines) of visual acuity improvement at week 54 was statistically significantly greater in the pegaptanib group versus those in the sham treatment arm ($P = 0.0047$; primary efficacy endpoint) (Sultan et al., 2011).

2.3.2 Ranibizumab

Ranibizumab (Lucentis®; Genentech, South San Francisco, California) is a humanized antibody fragment directed at all isoforms of VEGF-A and is fabricated specifically for intravitreal use. Ranibizumab is now FDA-approved for the treatment of age-related macular degeneration as well as macular edema associated with retinal vein occlusion.

For diabetic macular edema, an initial small pilot study showed efficacy of intravitreal injections of ranibizumab in reducing macular thickness and improving visual acuity (Nguyen et al., 2006).

Acting upon the favorable results of their pilot study, a 6-month, phase II, multicenter, randomized controlled trial, the Ranibizumab for Edema of the mAcula in Diabetes-2 (READ-2) study was designed. Patients with DME were randomized to three groups. Group 1 received four injections of ranibizumab, group 2 received focal laser at baseline and again at 3 months if needed; and group 3 had combination of laser treatment and injections of ranibizumab. The ranibizumab only group gained a mean of 7.24 ETDRS letters, the laser-only group lost 0.43 letters, and the combination group had gained 3.80 letters (Nguyen et al., 2009).

Data at twenty-four-months were also reported for the READ-2 study. After the initial 6 months, all patients were followed up every 2 months. Patients in group 1 could be re-injected if they had persistent or recurrent DME, patients in group 2 could receive ranibizumab alone or laser only, and patients in group 3 could receive ranibizumab alone or in combination with laser. After 24 months, patients gained 7.7, 5.1, and 6.8 letters in the three groups, respectively, and the percentage of patients who gained three or more lines of visual acuity was 24, 18 and 26%, respectively (Nguyen et al., 2010).

One-year safety and efficacy results from the Ranibizumab in Diabetic Macular Edema Study (RESOLVE) have also been reported. This was a phase II, randomized clinical trial

comparing 0.3 and 0.5mg ranibizumab with sham injections for the treatment of DME in 151 eyes. Patients received three monthly injections initially, followed by continuation of monthly injections on an as-needed basis with the opportunity for rescue focal laser treatment. In addition, after the first month, dose doubling (0.05 to 0.10 ml) was allowed based on pre-specified criteria. At the end of the 12-month assessment period, ranibizumab led to a mean gain of 10.3 letters from the baseline compared with a decline of 1.4 letters in the sham patients. Macular thickness reduction was also greater in the ranibizumab group vs. the sham group (Massin et al., 2010).

The DRCR Network group has reported 1-year results of a phase III, randomized controlled trial comparing four groups: sham injection plus prompt laser, ranibizumab plus prompt laser, ranibizumab plus deferred laser, and triamcinolone plus prompt laser. A total of 854 eyes of 691 patients were enrolled. In the ranibizumab groups, patients received at least four initial injections, after which retreatment was based on specific retreatment criteria. Change in mean visual acuity was greater in both ranibizumab groups (both +9 letters) vs. the laser only (+3 letters) and the triamcinolone group (+4 letters). Reduction in macular thickness was similar in all three injection groups and was greater than that in the laser only group (Elman et al., 2010).

The expanded 2-year results reported are similar to the results published previously and reinforce the conclusions originally reported. At the 2-year visit, compared with the sham plus prompt laser group, the mean change in the visual acuity letter score from the baseline was 3.7 letters greater in the ranibizumab plus prompt laser group, 5.8 letters greater in the ranibizumab plus deferred laser group, and 1.5 letters worse in the triamcinolone plus prompt laser group (Elman et al., 2011).

The 12-month, phase III, randomized, double-masked, multicenter, laser-controlled RESTORE study was designed to assess whether ranibizumab monotherapy or combined with laser was superior to laser alone in patients with visual impairment due to DME. The results from the RESTORE study demonstrated that treatment with ranibizumab as a monotherapy and combined with laser treatment is superior to laser treatment in rapidly improving and sustaining visual acuity in patients with visual impairment due to DME. There were no efficacy differences detected between the ranibizumab and ranibizumab combined with laser treatment arms (Mitchell et al., 2011).

2.3.3 Bevacizumab

Bevacizumab (Avastin®; Genentech, South San Francisco, California) inactivates all VEGF isoforms and is indicated for systemic use as an adjunct cancer chemotherapeutic agent (Van Meter & Kim, 2010). Bevacizumab, which is a full-length humanized monoclonal G1 antibody, has emerged as a therapeutic agent for retinal diseases (Arevalo et al., 2009), and has been used as an off-label agent in a number of ocular diseases, including diabetic retinopathy (Gunther & Altaweel, 2009).

The DRCR Network group conducted a phase II study over 3 months in 121 eyes, comparing five treatment arms: focal photocoagulation, two intravitreal injections of 1.25mg bevacizumab, two intravitreal injections of 2.5mg bevacizumab, one 1.25mg bevacizumab followed by a sham injection at week 6, and two 1.25mg bevacizumab injections combined with focal photocoagulation. Compared with laser alone, eyes in groups 2 and 3 had an

improvement in visual acuity after 3 months (-1 letter vs. +5 and +7 letters, respectively). There was a greater initial reduction in macular thickness after 3 weeks in groups 2 (-35 μ m) and 3 (-86 μ m) compared with laser (+21 μ m); however, this difference did not persist by week 12 (Scott et al., 2007).

A subsequent 3-arm randomized clinical trial demonstrated the superiority of intravitreal bevacizumab injection either alone or in combination with triamcinolone acetonide over macular laser photocoagulation in visual acuity improvement up to 24 weeks in primary treatment of DME. This improving effect persisted longer in the intravitreal bevacizumab group (up to 36 weeks) than in the intravitreal bevacizumab/intravitreal triamcinolone acetonide group (up to 12 weeks). In the macular laser photocoagulation group, no improvement in visual acuity was observed at all follow-up visits. In regard to central macular thickness reduction, there was no meaningful superiority of the intravitreal bevacizumab and intravitreal bevacizumab/intravitreal triamcinolone groups over the macular laser photocoagulation group (Soheilian et al., 2009).

The intravitreal Bevacizumab or Laser Therapy in the management of diabetic macular edema study (BOLT) was designed to compare bevacizumab therapy to laser for DME. This study was a randomized controlled trial comparing intravitreal bevacizumab 1.25mg with laser therapy in 80 patients who had previously received focal laser for DME. Patients in the bevacizumab arm received injections every 6 weeks for the first 3 months and every 6 weeks as needed thereafter, while those in the laser group received as needed laser every 4 months. The bevacizumab arm had superior visual acuity results at 12 months (+8 vs. -0.5 letters), a 5.1 times greater odds of gaining at least 10 letters, and a trend toward greater decrease in macular thickness (130 vs. 68 μ m) (Michaelides et al., 2010).

2.3.4 VEGF-Trap

VEGF Trap-Eye® (Regeneron Pharmaceuticals, Tarrytown, New York, NY, and Bayer Healthcare Pharmaceuticals, Berlin, Germany) is a 115-kDA recombinant fusion protein consisting of the VEGF binding domains of human VEGF receptors 1 and 2 fused to the Fc domain of human immunoglobulin-G1 (Holash et al., 2002). Animal studies have demonstrated that intravitreal VEGF Trap-Eye has theoretic advantages over ranibizumab and bevacizumab, including a longer half life in the eye and a higher binding affinity to VEGF-A (Gaudreault et al., 2005). In addition, the fusion protein binds placental growth factors 1 and 2, which have been shown to contribute to excessive vascular permeability and retinal neovascularization (Rakic et al., 2003).

A phase I study showed that a single intravitreal injection of VEGF Trap-Eye effected biological activity by improving visual acuity and reducing excess retinal thickness in 5 eyes with DME (Do et al., 2009).

On the basis of a sound biological rationale and encouraging phase I results, a phase II multicenter, randomized clinical trial, the DME and VEGF Trap-Eye: INvestigation of Clinical Impact (DA VINCI) study was designed to compare intravitreal VEGF Trap-Eye with standard macular laser treatment after the modified ETDRS protocol. In this phase II randomized clinical trial, intravitreal VEGF Trap-Eye was superior to macular laser treatment by the modified ETDRS protocol for the treatment of DME over a 24-week period. VEGF Trap-Eye resulted in significantly better mean visual acuity outcomes (+8.5 to +11.4

vs. +2.5 letters gained) and greater mean reductions in retinal thickness (-127.3 to -194.5 μ m vs. -67.9 μ m) compared with laser alone (Do et al., 2011).

2.4 Vitrectomy

The vitreous has been implicated as a cause of macular edema in people with diabetes via several mechanical and physiologic mechanisms, all of which are postulated to lead to increased vascular permeability. Widespread or diffuse DME that is unresponsive to focal laser treatment may benefit from a vitrectomy. The presence of vitreous traction and macular edema, now readily documented with OCT, in association with visual impairment is also a common indication for the need of a vitrectomy. Complications of vitrectomy include recurrent vitreous hemorrhage, retinal tears and detachment, cataract formation and glaucoma (Figueroa et al., 2008; Harbour et al., 1996; Hartley et al., 2008; Ikeda et al., 1999; Lewis et al., 1992; Pendergast et al., 2000; Tachi & Ogino, 1996; Yamamoto et al., 2001).

In a prospective study of 87 eyes undergoing vitrectomy for DME associated with at least moderate visual loss and vitreomacular traction, the median change in visual acuity at 6 months was an improvement of 3 letters, with visual acuity improving by ≥ 10 letters from the baseline to 6 months in 38% and worsening by ≥ 10 letters in 22%. Reduction in OCT central subfield thickness to $< 250\mu$ m occurred in almost half, and most eyes had a reduction of thickening of $\geq 50\%$ (Haller, Qin, et al., 2010).

2.5 Protein kinase C inhibitor

An increased understanding of the pathophysiology of diabetic microangiopathy and the mechanisms of glycaemic vascular damage might facilitate the development of new therapeutic agents that ameliorate microvascular complications, even or especially when tight glycaemic control is unattainable. Hyperglycaemia-induced *de novo* synthesis of diacylglycerol in vascular cells leads to preferential activation of the PKC- β isoform, which is strongly implicated in the pathogenic processes involved in diabetic microangiopathy such as ischemia, leakage, neovascularization and abnormal vasodilator function (Idris & Donnelly, 2006).

2.5.1 Protein kinase C β inhibitor (Ruboxistaurin)

The Protein Kinase C β inhibitor Diabetic Retinopathy Study (PKC-DRS) was designed to test the primary hypothesis that ruboxistaurin, a β -isoform-selective protein kinase C inhibitor, would delay the progression of diabetic retinopathy. Ruboxistaurin was well tolerated without significant adverse effects. Compared with a placebo, 32 mg/day ruboxistaurin was associated with a delayed occurrence of moderate visual loss. However, in patients with moderately severe to very severe nonproliferative diabetic retinopathy at the baseline, ruboxistaurin did not prevent retinopathy progression to the proliferative disease state (PKC-DRS group, 2005).

2.5.2 PKC412

Orally administered PKC412 at doses of 100mg/day or higher may significantly reduce macular edema and improve visual acuity in diabetic subjects. However, concern regarding

liver toxicity with systemic therapy makes local delivery an appealing approach (Campochiaro, 2004).

2.6 Others

2.6.1 HMG-CoA reductase inhibitor (Atorvastin)

Lipids have a definite role in the pathogenesis of diabetic retinopathy. Because of the increased permeability and leakage of the retinal capillaries, extravascular deposition of less soluble plasma lipoprotein occurs. The mass of lipid-filled macrophages is visible on funduscopy as hard exudates (Watanabe et al., 1988).

Statins act by competitively inhibiting 3-hydroxy-3-methylglutaryl-coenzyme A (HMG-CoA) reductase, the first committed enzyme of the HMG-CoA reductase pathway. Sen et al. found that statins retard the progression of retinopathy in patients with diabetes mellitus and hypercholesterolemia (Sen et al., 2002), whereas other studies have reported that statins limit the severity of hard exudates and subfoveal lipid migration in CSME (Gordon et al., 1991; Gupta et al., 2004).

A recent study evaluated the efficacy and safety of atorvastatin and described its effect on hard exudates and macular edema in patients with diabetes mellitus and dyslipidemia. In this study, aggressive treatment of hyperlipidemia resulted in significant improvement in hard exudates and fluorescein leakage. The lipid-lowering drug atorvastatin was safe when administered to patients with diabetes mellitus and useful in the management of DME in patients with an abnormal lipid profile (Panagiotoglou et al., 2010).

3. Conclusion

Although, focal laser photocoagulation is the standard-of-care treatment for DME, it is not a cure. During the last decade, a number of additional treatments for DME have been proposed. Such treatments include intravitreal injection of corticosteroids such as triamcinolone acetonide, intravitreal injection of aptamers or antibodies targeted at VEGF, vitrectomy, and pharmacologic therapy with oral protein kinase C beta inhibitors.

In particular, anti-VEGF therapies, in conjunction with laser or as standalone treatments, have shown promise in not only maintaining but also improving visual acuity. Intravitreal triamcinolone also has a role in treating patients with DME refractory to laser and anti-VEGF therapy, and it remains to be seen whether extended-release corticosteroid devices might play a role in the management of DME. Diabetic patients with macular edema who have a taut posterior hyaloid membrane may benefit from pars plana vitrectomy and removal of the posterior hyaloids

The pathogenesis of DME is complex, and a variety of factors and biochemical pathways are involved, which provides an opportunity for the development of a number of therapeutic modalities to treat the condition.

4. Acknowledgements

This work was supported by Inha university Research grant.

5. References

- Abu el Asrar, A. M., & Morse, P. H. (1991). Laser photocoagulation control of diabetic macular oedema without fluorescein angiography. *Br J Ophthalmol*, 75(2), 97-99, ISSN 0007-1161 (Print)
- Adamis, A. P., & Berman, A. J. (2008). Immunological mechanisms in the pathogenesis of diabetic retinopathy. *Semin Immunopathol*, 30(2), 65-84, ISSN 1863-2297 (Print)
- Aiello, L. P., Bursell, S. E., Clermont, A., Duh, E., Ishii, H., Takagi, C., Mori, F., Ciulla, T. A., Wachs, K., Jirousek, M., Smith, L. E., & King, G. L. (1997). Vascular endothelial growth factor-induced retinal permeability is mediated by protein kinase C in vivo and suppressed by an orally effective beta-isoform-selective inhibitor. *Diabetes*, 46(9), 1473-1480, ISSN 0012-1797 (Print)
- Aiello, L. P., Edwards, A. R., Beck, R. W., Bressler, N. M., Davis, M. D., Ferris, F., Glassman, A. R., Ip, M. S., & Miller, K. M. (2010). Factors associated with improvement and worsening of visual acuity 2 years after focal/grid photocoagulation for diabetic macular edema. *Ophthalmology*, 117(5), 946-953, ISSN 1549-4713 (Electronic)
- Akduman, L., & Olk, R. J. (1997). Diode laser (810 nm) versus argon green (514 nm) modified grid photocoagulation for diffuse diabetic macular edema. *Ophthalmology*, 104(9), 1433-1441, ISSN 0161-6420 (Print)
- Akduman, L., & Olk, R. J. (1999). Subthreshold (invisible) modified grid diode laser photocoagulation in diffuse diabetic macular edema (DDME). *Ophthalmic Surg Lasers*, 30(9), 706-714, ISSN 1082-3069 (Print)
- Antonetti, D. A., Barber, A. J., Hollinger, L. A., Wolpert, E. B., & Gardner, T. W. (1999). Vascular endothelial growth factor induces rapid phosphorylation of tight junction proteins occludin and zonula occluden 1. A potential mechanism for vascular permeability in diabetic retinopathy and tumors. *J Biol Chem*, 274(33), 23463-23467, ISSN 0021-9258 (Print)
- Arevalo, J. F., Sanchez, J. G., Wu, L., Maia, M., Alezzandrini, A. A., Brito, M., Bonafonte, S., Lujan, S., Diaz-Llopis, M., Restrepo, N., Rodriguez, F. J., & Udaondo-Mirete, P. (2009). Primary intravitreal bevacizumab for diffuse diabetic macular edema: the Pan-American Collaborative Retina Study Group at 24 months. *Ophthalmology*, 116(8), 1488-1497, 1497 e1481, ISSN 1549-4713 (Electronic)
- Beck, R. W., Edwards, A. R., Aiello, L. P., Bressler, N. M., Ferris, F., Glassman, A. R., Hartnett, E., Ip, M. S., Kim, J. E., & Kollman, C. (2009). Three-year follow-up of a randomized trial comparing focal/grid photocoagulation and intravitreal triamcinolone for diabetic macular edema. *Arch Ophthalmol*, 127(3), 245-251, ISSN 1538-3601 (Electronic)
- Bhagat, N., Grigorian, R. A., Tutela, A., & Zarbin, M. A. (2009). Diabetic macular edema: pathogenesis and treatment. *Surv Ophthalmol*, 54(1), 1-32, ISSN 0039-6257 (Print)
- Bresnick, G. H. (1983). Diabetic maculopathy. A critical review highlighting diffuse macular edema. *Ophthalmology*, 90(11), 1301-1317, ISSN 0161-6420 (Print)
- Campochiaro, P. A. (2004). Reduction of diabetic macular edema by oral administration of the kinase inhibitor PKC412. *Invest Ophthalmol Vis Sci*, 45(3), 922-931, ISSN 0146-0404 (Print)
- Campochiaro, P. A., Hafiz, G., Shah, S. M., Bloom, S., Brown, D. M., Busquets, M., Ciulla, T., Feiner, L., Sabates, N., Billman, K., Kapik, B., Green, K., & Kane, F. (2010).

- Sustained ocular delivery of fluocinolone acetonide by an intravitreal insert. *Ophthalmology*, 117(7), 1393-1399 e1393, ISSN 1549-4713 (Electronic)
- Chew, E., Strauber, S., Beck, R., Aiello, L. P., Antoszyk, A., Bressler, N., Browning, D., Danis, R., Fan, J., Flaxel, C., Friedman, S., Glassman, A., Kollman, C., & Lazarus, H. (2007). Randomized trial of peribulbar triamcinolone acetonide with and without focal photocoagulation for mild diabetic macular edema: a pilot study. *Ophthalmology*, 114(6), 1190-1196, ISSN 1549-4713 (Electronic)
- Chew, E. Y., Glassman, A. R., Beck, R. W., Bressler, N. M., Fish, G. E., Ferris, F. L., & Kinyoun, J. L. (2011). Ocular side effects associated with peribulbar injections of triamcinolone acetonide for diabetic macular edema. *Retina*, 31(2), 284-289, ISSN 1539-2864 (Electronic)
- Cunningham, E. T., Jr., Adamis, A. P., Altaweel, M., Aiello, L. P., Bressler, N. M., D'Amico, D. J., Goldbaum, M., Guyer, D. R., Katz, B., Patel, M., & Schwartz, S. D. (2005). A phase II randomized double-masked trial of pegaptanib, an anti-vascular endothelial growth factor aptamer, for diabetic macular edema. *Ophthalmology*, 112(10), 1747-1757, ISSN 1549-4713 (Electronic)
- DCCT Group. (1995). The effect of intensive diabetes treatment on the progression of diabetic retinopathy in insulin-dependent diabetes mellitus. The Diabetes Control and Complications Trial. *Arch Ophthalmol*, 113(1), 36-51, ISSN 0003-9950 (Print)
- Do, D. V., Nguyen, Q. D., Shah, S. M., Browning, D. J., Haller, J. A., Chu, K., Yang, K., Cedarbaum, J. M., Vitti, R. L., Ingerman, A., & Campochiaro, P. A. (2009). An exploratory study of the safety, tolerability and bioactivity of a single intravitreal injection of vascular endothelial growth factor Trap-Eye in patients with diabetic macular oedema. *Br J Ophthalmol*, 93(2), 144-149, ISSN 1468-2079 (Electronic)
- Do, D. V., Schmidt-Erfurth, U., Gonzalez, V. H., Gordon, C. M., Tolentino, M., Berliner, A. J., Vitti, R., Ruckert, R., Sandbrink, R., Stein, D., Yang, K., Beckmann, K., & Heier, J. S. (2011). The DA VINCI Study: Phase 2 Primary Results of VEGF Trap-Eye in Patients with Diabetic Macular Edema. *Ophthalmology*, ISSN 1549-4713 (Electronic)
- DRCR net. (2008). A randomized trial comparing intravitreal triamcinolone acetonide and focal/grid photocoagulation for diabetic macular edema. *Ophthalmology*, 115(9), 1447-1449, 1449 e1441-1410, ISSN 1549-4713 (Electronic)
- DRCR net. (2009). The course of response to focal/grid photocoagulation for diabetic macular edema. *Retina*, 29(10), 1436-1443, ISSN 1539-2864 (Electronic)
- Elman, M. J., Aiello, L. P., Beck, R. W., Bressler, N. M., Bressler, S. B., Edwards, A. R., Ferris, F. L., 3rd, Friedman, S. M., Glassman, A. R., Miller, K. M., Scott, I. U., Stockdale, C. R., & Sun, J. K. (2010). Randomized trial evaluating ranibizumab plus prompt or deferred laser or triamcinolone plus prompt laser for diabetic macular edema. *Ophthalmology*, 117(6), 1064-1077 e1035, ISSN 1549-4713 (Electronic)
- Elman, M. J., Bressler, N. M., Qin, H., Beck, R. W., Ferris, F. L., 3rd, Friedman, S. M., Glassman, A. R., Scott, I. U., Stockdale, C. R., & Sun, J. K. (2011). Expanded 2-year follow-up of ranibizumab plus prompt or deferred laser or triamcinolone plus prompt laser for diabetic macular edema. *Ophthalmology*, 118(4), 609-614, ISSN 1549-4713 (Electronic)
- ETDRS group. (1985). Photocoagulation for diabetic macular edema. Early Treatment Diabetic Retinopathy Study report number 1. Early Treatment Diabetic

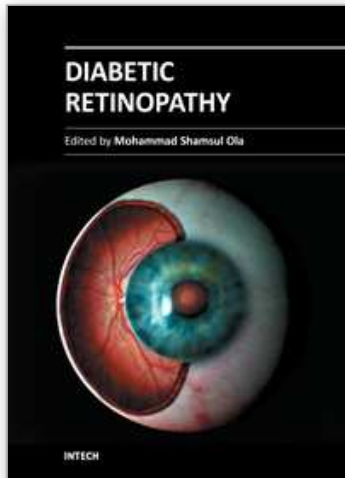
- Retinopathy Study research group. *Arch Ophthalmol*, 103(12), 1796-1806, ISSN 0003-9950 (Print)
- ETDRS group. (1987a). Photocoagulation for diabetic macular edema: Early Treatment Diabetic Retinopathy Study Report no. 4. The Early Treatment Diabetic Retinopathy Study Research Group. *Int Ophthalmol Clin*, 27(4), 265-272, ISSN 0020-8167 (Print)
- ETDRS group. (1987b). Treatment techniques and clinical guidelines for photocoagulation of diabetic macular edema. Early Treatment Diabetic Retinopathy Study Report Number 2. Early Treatment Diabetic Retinopathy Study Research Group. *Ophthalmology*, 94(7), 761-774, ISSN 0161-6420 (Print)
- ETDRS group. (1991). Early photocoagulation for diabetic retinopathy. ETDRS report number 9. Early Treatment Diabetic Retinopathy Study Research Group. *Ophthalmology*, 98(5 Suppl), 766-785, ISSN 0161-6420 (Print)
- Figueira, J., Khan, J., Nunes, S., Sivaprasad, S., Rosa, A., de Abreu, J. F., Cunha-Vaz, J. G., & Chong, N. V. (2009). Prospective randomised controlled trial comparing sub-threshold micropulse diode laser photocoagulation and conventional green laser for clinically significant diabetic macular oedema. *Br J Ophthalmol*, 93(10), 1341-1344, ISSN 1468-2079 (Electronic)
- Figueroa, M. S., Contreras, I., & Noval, S. (2008). Surgical and anatomical outcomes of pars plana vitrectomy for diffuse nontractional diabetic macular edema. *Retina*, 28(3), 420-426, ISSN 0275-004X (Print)
- Fong, D. S., Strauber, S. F., Aiello, L. P., Beck, R. W., Callanan, D. G., Danis, R. P., Davis, M. D., Feman, S. S., Ferris, F., Friedman, S. M., Garcia, C. A., Glassman, A. R., Han, D. P., Le, D., Kollman, C., Lauer, A. K., Recchia, F. M., & Solomon, S. D. (2007). Comparison of the modified Early Treatment Diabetic Retinopathy Study and mild macular grid laser photocoagulation strategies for diabetic macular edema. *Arch Ophthalmol*, 125(4), 469-480, ISSN 0003-9950 (Print)
- Funatsu, H., Yamashita, H., Ikeda, T., Mimura, T., Eguchi, S., & Hori, S. (2003). Vitreous levels of interleukin-6 and vascular endothelial growth factor are related to diabetic macular edema. *Ophthalmology*, 110(9), 1690-1696, ISSN 0161-6420 (Print)
- Funatsu, H., Yamashita, H., Sakata, K., Noma, H., Mimura, T., Suzuki, M., Eguchi, S., & Hori, S. (2005). Vitreous levels of vascular endothelial growth factor and intercellular adhesion molecule 1 are related to diabetic macular edema. *Ophthalmology*, 112(5), 806-816, ISSN 1549-4713 (Electronic)
- Gaudreault, J., Fei, D., Rusit, J., Suboc, P., & Shiu, V. (2005). Preclinical pharmacokinetics of Ranibizumab (rhuFabV2) after a single intravitreal administration. *Invest Ophthalmol Vis Sci*, 46(2), 726-733, ISSN 0146-0404 (Print)
- Gillies, M. C., McAllister, I. L., Zhu, M., Wong, W., Louis, D., Arnold, J. J., & Wong, T. Y. (2011). Intravitreal triamcinolone prior to laser treatment of diabetic macular edema: 24-month results of a randomized controlled trial. *Ophthalmology*, 118(5), 866-872, ISSN 1549-4713 (Electronic)
- Gordon, B., Chang, S., Kavanagh, M., Berrocal, M., Yannuzzi, L., Robertson, C., & Drexler, A. (1991). The effects of lipid lowering on diabetic retinopathy. *Am J Ophthalmol*, 112(4), 385-391, ISSN 0002-9394 (Print)

- Gottfredsdottir, M. S., Stefansson, E., Jonasson, F., & Gislason, I. (1993). Retinal vasoconstriction after laser treatment for diabetic macular edema. *Am J Ophthalmol*, 115(1), 64-67, ISSN 0002-9394 (Print)
- Gunther, J. B., & Altaweel, M. M. (2009). Bevacizumab (Avastin) for the treatment of ocular disease. *Surv Ophthalmol*, 54(3), 372-400, ISSN 0039-6257 (Print)
- Gupta, A., Gupta, V., Thapar, S., & Bhansali, A. (2004). Lipid-lowering drug atorvastatin as an adjunct in the management of diabetic macular edema. *Am J Ophthalmol*, 137(4), 675-682, ISSN 0002-9394 (Print)
- Guyer, D. R., D'Amico, D. J., & Smith, C. W. (1992). Subretinal fibrosis after laser photocoagulation for diabetic macular edema. *Am J Ophthalmol*, 113(6), 652-656, ISSN 0002-9394 (Print)
- Haller, J. A., Kuppermann, B. D., Blumenkranz, M. S., Williams, G. A., Weinberg, D. V., Chou, C., & Whitcup, S. M. (2010). Randomized controlled trial of an intravitreal dexamethasone drug delivery system in patients with diabetic macular edema. *Arch Ophthalmol*, 128(3), 289-296, ISSN 1538-3601 (Electronic)
- Haller, J. A., Qin, H., Apte, R. S., Beck, R. R., Bressler, N. M., Browning, D. J., Danis, R. P., Glassman, A. R., Googe, J. M., Kollman, C., Lauer, A. K., Peters, M. A., & Stockman, M. E. (2010). Vitrectomy outcomes in eyes with diabetic macular edema and vitreomacular traction. *Ophthalmology*, 117(6), 1087-1093 e1083, ISSN 1549-4713 (Electronic)
- Han, D. P., Mieler, W. F., & Burton, T. C. (1992). Submacular fibrosis after photocoagulation for diabetic macular edema. *Am J Ophthalmol*, 113(5), 513-521, ISSN 0002-9394 (Print)
- Harbour, J. W., Smiddy, W. E., Flynn, H. W., Jr., & Rubsamen, P. E. (1996). Vitrectomy for diabetic macular edema associated with a thickened and taut posterior hyaloid membrane. *Am J Ophthalmol*, 121(4), 405-413, ISSN 0002-9394 (Print)
- Hartley, K. L., Smiddy, W. E., Flynn, H. W., Jr., & Murray, T. G. (2008). Pars plana vitrectomy with internal limiting membrane peeling for diabetic macular edema. *Retina*, 28(3), 410-419, ISSN 0275-004X (Print)
- Herrero-Vanrell, R., Cardillo, J. A., & Kuppermann, B. D. (2011). Clinical applications of the sustained-release dexamethasone implant for treatment of macular edema. *Clin Ophthalmol*, 5, 139-146, ISSN 1177-5483 (Electronic)
- Holash, J., Davis, S., Papadopoulos, N., Croll, S. D., Ho, L., Russell, M., Boland, P., Leidich, R., Hylton, D., Burova, E., Ioffe, E., Huang, T., Radziejewski, C., Bailey, K., Fandl, J. P., Daly, T., Wiegand, S. J., Yancopoulos, G. D., & Rudge, J. S. (2002). VEGF-Trap: a VEGF blocker with potent antitumor effects. *Proc Natl Acad Sci U S A*, 99(17), 11393-11398, ISSN 0027-8424 (Print)
- Idris, I., & Donnelly, R. (2006). Protein kinase C beta inhibition: A novel therapeutic strategy for diabetic microangiopathy. *Diab Vasc Dis Res*, 3(3), 172-178, ISSN 1479-1641 (Print)
- Ikeda, T., Sato, K., Katano, T., & Hayashi, Y. (1999). Vitrectomy for cystoid macular oedema with attached posterior hyaloid membrane in patients with diabetes. *Br J Ophthalmol*, 83(1), 12-14, ISSN 0007-1161 (Print)
- Jain, A., Collen, J., Kaines, A., Hubschman, J. P., & Schwartz, S. (2010). Short-duration focal pattern grid macular photocoagulation for diabetic macular edema: four-month outcomes. *Retina*, 30(10), 1622-1626, ISSN 1539-2864 (Electronic)

- Jonas, J. B., & Sofker, A. (2001). Intraocular injection of crystalline cortisone as adjunctive treatment of diabetic macular edema. *Am J Ophthalmol*, 132(3), 425-427, ISSN 0002-9394 (Print)
- Joussen, A. M., Smyth, N., & Niessen, C. (2007). Pathophysiology of diabetic macular edema. *Dev Ophthalmol*, 39, 1-12, ISSN 0250-3751 (Print)
- Kern, T. S. (2007). Contributions of inflammatory processes to the development of the early stages of diabetic retinopathy. *Exp Diabetes Res*, 2007, 95103, ISSN 1687-5303 (Electronic)
- Kim, N. R., Kim, Y. J., Chin, H. S., & Moon, Y. S. (2009). Optical coherence tomographic patterns in diabetic macular oedema: prediction of visual outcome after focal laser photocoagulation. *Br J Ophthalmol*, 93(7), 901-905, ISSN 1468-2079 (Electronic)
- Klein, R., Klein, B. E., Moss, S. E., Davis, M. D., & DeMets, D. L. (1984). The Wisconsin epidemiologic study of diabetic retinopathy. IV. Diabetic macular edema. *Ophthalmology*, 91(12), 1464-1474, ISSN 0161-6420 (Print)
- Lavinsky, D., Cardillo, J. A., Melo, L. A., Jr., Dare, A., Farah, M. E., & Belfort, R., Jr. (2011). Randomized Clinical Trial Evaluating mETDRS versus Normal or High-Density Micropulse Photocoagulation for Diabetic Macular Edema. *Invest Ophthalmol Vis Sci*, 52(7), 4314-4323, ISSN 1552-5783 (Electronic)
- Leopold, I. H. (1985). Nonsteroidal and steroidal anti-inflammatory agents. In M. L. Sears & A. Tarkkanen (Eds.), *Surgical Pharmacology of the Eye*. ISBN 0881670472 9780881670479, New York: Raven Press.
- Lewis, H., Abrams, G. W., Blumenkranz, M. S., & Campo, R. V. (1992). Vitrectomy for diabetic macular traction and edema associated with posterior hyaloidal traction. *Ophthalmology*, 99(5), 753-759, ISSN 0161-6420 (Print)
- Martidis, A., Duker, J. S., Greenberg, P. B., Rogers, A. H., Puliafito, C. A., Reichel, E., & Bauman, C. (2002). Intravitreal triamcinolone for refractory diabetic macular edema. *Ophthalmology*, 109(5), 920-927, ISSN 0161-6420 (Print)
- Massin, P., Bandello, F., Garweg, J. G., Hansen, L. L., Harding, S. P., Larsen, M., Mitchell, P., Sharp, D., Wolf-Schnurrbusch, U. E., Gekkieva, M., Weichselberger, A., & Wolf, S. (2010). Safety and efficacy of ranibizumab in diabetic macular edema (RESOLVE Study): a 12-month, randomized, controlled, double-masked, multicenter phase II study. *Diabetes Care*, 33(11), 2399-2405, ISSN 1935-5548 (Electronic)
- Michaelides, M., Kaines, A., Hamilton, R. D., Fraser-Bell, S., Rajendram, R., Quhill, F., Boos, C. J., Xing, W., Egan, C., Peto, T., Bunce, C., Leslie, R. D., & Hykin, P. G. (2010). A prospective randomized trial of intravitreal bevacizumab or laser therapy in the management of diabetic macular edema (BOLT study) 12-month data: report 2. *Ophthalmology*, 117(6), 1078-1086 e1072, ISSN 1549-4713 (Electronic)
- Mitchell, P., Bandello, F., Schmidt-Erfurth, U., Lang, G. E., Massin, P., Schlingemann, R. O., Sutter, F., Simader, C., Burian, G., Gerstner, O., & Weichselberger, A. (2011). The RESTORE study: ranibizumab monotherapy or combined with laser versus laser monotherapy for diabetic macular edema. *Ophthalmology*, 118(4), 615-625, ISSN 1549-4713 (Electronic)
- Moss, S. E., Klein, R., & Klein, B. E. (1998). The 14-year incidence of visual loss in a diabetic population. *Ophthalmology*, 105(6), 998-1003, ISSN 0161-6420 (Print)
- Nauck, M., Karakiulakis, G., Perruchoud, A. P., Papakonstantinou, E., & Roth, M. (1998). Corticosteroids inhibit the expression of the vascular endothelial growth factor

- gene in human vascular smooth muscle cells. *Eur J Pharmacol*, 341(2-3), 309-315, ISSN 0014-2999 (Print)
- Nauck, M., Roth, M., Tamm, M., Eickelberg, O., Wieland, H., Stulz, P., & Perruchoud, A. P. (1997). Induction of vascular endothelial growth factor by platelet-activating factor and platelet-derived growth factor is downregulated by corticosteroids. *Am J Respir Cell Mol Biol*, 16(4), 398-406, ISSN 1044-1549 (Print)
- Nguyen, Q. D., Shah, S. M., Heier, J. S., Do, D. V., Lim, J., Boyer, D., Abraham, P., & Campochiaro, P. A. (2009). Primary End Point (Six Months) Results of the Ranibizumab for Edema of the mAcula in diabetes (READ-2) study. *Ophthalmology*, 116(11), 2175-2181 e2171, ISSN 1549-4713 (Electronic)
- Nguyen, Q. D., Shah, S. M., Khwaja, A. A., Channa, R., Hatef, E., Do, D. V., Boyer, D., Heier, J. S., Abraham, P., Thach, A. B., Lit, E. S., Foster, B. S., Kruger, E., Dugel, P., Chang, T., Das, A., Ciulla, T. A., Pollack, J. S., Lim, J. I., Eliot, D., & Campochiaro, P. A. (2010). Two-year outcomes of the ranibizumab for edema of the mAcula in diabetes (READ-2) study. *Ophthalmology*, 117(11), 2146-2151, ISSN 1549-4713 (Electronic)
- Nguyen, Q. D., Tatlipinar, S., Shah, S. M., Haller, J. A., Quinlan, E., Sung, J., Zimmer-Galler, I., Do, D. V., & Campochiaro, P. A. (2006). Vascular endothelial growth factor is a critical stimulus for diabetic macular edema. *Am J Ophthalmol*, 142(6), 961-969, ISSN 0002-9394 (Print)
- Nicholson, B. P., & Schachat, A. P. (2010). A review of clinical trials of anti-VEGF agents for diabetic retinopathy. *Graefes Arch Clin Exp Ophthalmol*, 248(7), 915-930, ISSN 1435-702X (Electronic)
- Olk, R. J. (1990). Argon green (514 nm) versus krypton red (647 nm) modified grid laser photocoagulation for diffuse diabetic macular edema. *Ophthalmology*, 97(9), 1101-1112; discussion 1112-1103, ISSN 0161-6420 (Print)
- Panagiotoglou, T. D., Ganotakis, E. S., Kymionis, G. D., Moschandreas, J. A., Fanti, G. N., Charisis, S. K., Malliaraki, N. E., & Tsilimbaris, M. K. (2010). Atorvastatin for diabetic macular edema in patients with diabetes mellitus and elevated serum cholesterol. *Ophthalmic Surg Lasers Imaging*, 41(3), 316-322, ISSN 1542-8877 (Print)
- Pearson, A., Levy, B., & Group., F. A. I. S. (2005). Fluocinolone Acetonide Intravitreal Implant to Treat Diabetic Macular Edema: 2-year Results of a Multi-Center Clinical Trial. *Invest Ophthalmol Vis Sci*, 46, E-Abstract P4673.
- Pendergast, S. D., Hassan, T. S., Williams, G. A., Cox, M. S., Margherio, R. R., Ferrone, P. J., Garretson, B. R., & Trese, M. T. (2000). Vitrectomy for diffuse diabetic macular edema associated with a taut premacular posterior hyaloid. *Am J Ophthalmol*, 130(2), 178-186, ISSN 0002-9394 (Print)
- PKC-DRS group. (2005). The effect of ruboxistaurin on visual loss in patients with moderately severe to very severe nonproliferative diabetic retinopathy: initial results of the Protein Kinase C beta Inhibitor Diabetic Retinopathy Study (PKC-DRS) multicenter randomized clinical trial. *Diabetes*, 54(7), 2188-2197, ISSN 0012-1797 (Print)
- Qaum, T., Xu, Q., Jousen, A. M., Clemens, M. W., Qin, W., Miyamoto, K., Hassessian, H., Wiegand, S. J., Rudge, J., Yancopoulos, G. D., & Adamis, A. P. (2001). VEGF-initiated blood-retinal barrier breakdown in early diabetes. *Invest Ophthalmol Vis Sci*, 42(10), 2408-2413, ISSN 0146-0404 (Print)

- Rakic, J. M., Lambert, V., Devy, L., Luttun, A., Carmeliet, P., Claes, C., Nguyen, L., Foidart, J. M., Noel, A., & Munaut, C. (2003). Placental growth factor, a member of the VEGF family, contributes to the development of choroidal neovascularization. *Invest Ophthalmol Vis Sci*, 44(7), 3186-3193, ISSN 0146-0404 (Print)
- Schatz, H., Madeira, D., McDonald, H. R., & Johnson, R. N. (1991). Progressive enlargement of laser scars following grid laser photocoagulation for diffuse diabetic macular edema. *Arch Ophthalmol*, 109(11), 1549-1551, ISSN 0003-9950 (Print)
- Scott, I. U., Edwards, A. R., Beck, R. W., Bressler, N. M., Chan, C. K., Elman, M. J., Friedman, S. M., Greven, C. M., Maturi, R. K., Pieramici, D. J., Shami, M., Singerman, L. J., & Stockdale, C. R. (2007). A phase II randomized clinical trial of intravitreal bevacizumab for diabetic macular edema. *Ophthalmology*, 114(10), 1860-1867, ISSN 1549-4713 (Electronic)
- Sen, K., Misra, A., Kumar, A., & Pandey, R. M. (2002). Simvastatin retards progression of retinopathy in diabetic patients with hypercholesterolemia. *Diabetes Res Clin Pract*, 56(1), 1-11, ISSN 0168-8227 (Print)
- Senger, D. R., Connolly, D. T., Van de Water, L., Feder, J., & Dvorak, H. F. (1990). Purification and NH₂-terminal amino acid sequence of guinea pig tumor-secreted vascular permeability factor. *Cancer Res*, 50(6), 1774-1778, ISSN 0008-5472 (Print)
- Senger, D. R., Galli, S. J., Dvorak, A. M., Perruzzi, C. A., Harvey, V. S., & Dvorak, H. F. (1983). Tumor cells secrete a vascular permeability factor that promotes accumulation of ascites fluid. *Science*, 219(4587), 983-985, ISSN 0036-8075 (Print)
- Soheilian, M., Ramezani, A., Obudi, A., Bijanzadeh, B., Salehipour, M., Yaseri, M., Ahmadi, H., Dehghan, M. H., Azarmina, M., Moradian, S., & Peyman, G. A. (2009). Randomized trial of intravitreal bevacizumab alone or combined with triamcinolone versus macular photocoagulation in diabetic macular edema. *Ophthalmology*, 116(6), 1142-1150, ISSN 1549-4713 (Electronic)
- Stefansson, E. (2001). The therapeutic effects of retinal laser treatment and vitrectomy. A theory based on oxygen and vascular physiology. *Acta Ophthalmol Scand*, 79(5), 435-440, ISSN 1395-3907 (Print)
- Sultan, M. B., Zhou, D., Loftus, J., Dombi, T., & Ice, K. S. (2011). A phase 2/3, multicenter, randomized, double-masked, 2-year trial of pegaptanib sodium for the treatment of diabetic macular edema. *Ophthalmology*, 118(6), 1107-1118, ISSN 1549-4713 (Electronic)
- Tachi, N., & Ogino, N. (1996). Vitrectomy for diffuse macular edema in cases of diabetic retinopathy. *Am J Ophthalmol*, 122(2), 258-260, ISSN 0002-9394 (Print)
- Van Meter, M. E., & Kim, E. S. (2010). Bevacizumab: current updates in treatment. *Curr Opin Oncol*, 22(6), 586-591, ISSN 1531-703X (Electronic)
- Watanabe, J., Wohltmann, H. J., Klein, R. L., Colwell, J. A., & Lopes-Virella, M. F. (1988). Enhancement of platelet aggregation by low-density lipoproteins from IDDM patients. *Diabetes*, 37(12), 1652-1657, ISSN 0012-1797 (Print)
- Wilson, D. J., Finkelstein, D., Quigley, H. A., & Green, W. R. (1988). Macular grid photocoagulation. An experimental study on the primate retina. *Arch Ophthalmol*, 106(1), 100-105, ISSN 0003-9950 (Print)
- Yamamoto, T., Akabane, N., & Takeuchi, S. (2001). Vitrectomy for diabetic macular edema: the role of posterior vitreous detachment and epimacular membrane. *Am J Ophthalmol*, 132(3), 369-377, ISSN 0002-9394 (Print)



Diabetic Retinopathy

Edited by Dr. Mohammad Shamsul Ola

ISBN 978-953-51-0044-7

Hard cover, 356 pages

Publisher InTech

Published online 24, February, 2012

Published in print edition February, 2012

The aim of this book is to provide a comprehensive overview of current concepts in pathogenesis, diagnosis and treatments of diabetic retinopathy. It provides a collection of topics written by excellent authors, covering discussions on advances in understanding of pathophysiology, immunological factors and emerging concepts, relating to clinical aspects and treatment strategies. The contents of the book will not only provide a resource for our knowledge but also improve diagnosis and treatment options for those patients who suffer vision loss due to diabetic retinopathy.

How to reference

In order to correctly reference this scholarly work, feel free to copy and paste the following:

Yeon Sung Moon and Na Rae Kim (2012). Treatment of Diabetic Macular Edema – Latest Therapeutic Developments, Diabetic Retinopathy, Dr. Mohammad Shamsul Ola (Ed.), ISBN: 978-953-51-0044-7, InTech, Available from: <http://www.intechopen.com/books/diabetic-retinopathy/treatment-of-diabetic-macular-edema-latest-therapeutic-developments>

INTECH
open science | open minds

InTech Europe

University Campus STeP Ri
Slavka Krautzeka 83/A
51000 Rijeka, Croatia
Phone: +385 (51) 770 447
Fax: +385 (51) 686 166
www.intechopen.com

InTech China

Unit 405, Office Block, Hotel Equatorial Shanghai
No.65, Yan An Road (West), Shanghai, 200040, China
中国上海市延安西路65号上海国际贵都大饭店办公楼405单元
Phone: +86-21-62489820
Fax: +86-21-62489821

© 2012 The Author(s). Licensee IntechOpen. This is an open access article distributed under the terms of the [Creative Commons Attribution 3.0 License](#), which permits unrestricted use, distribution, and reproduction in any medium, provided the original work is properly cited.

IntechOpen

IntechOpen