

We are IntechOpen, the world's leading publisher of Open Access books Built by scientists, for scientists

4,800

Open access books available

122,000

International authors and editors

135M

Downloads

Our authors are among the

154

Countries delivered to

TOP 1%

most cited scientists

12.2%

Contributors from top 500 universities



WEB OF SCIENCE™

Selection of our books indexed in the Book Citation Index
in Web of Science™ Core Collection (BKCI)

Interested in publishing with us?
Contact book.department@intechopen.com

Numbers displayed above are based on latest data collected.
For more information visit www.intechopen.com



The Effect of Diabetes Mellitus on Retinal Function

Zvia Burgansky-Eliash

*Department of Ophthalmology, The Edith Wolfson Medical Center,
Holon, Sackler Faculty of Medicine, Tel-Aviv University,
Israel*

1. Introduction

Diabetic retinopathy (DR) is the leading cause of blindness in adults less than 70 years of age in the western world (Kempner, et al., 2004). It is estimated that 1 in 29 Americans 40 years and older has diabetic retinopathy (4.1 million persons) and 1 in 132 persons has vision-threatening DR (Kempner et al., 2004). Diabetic retinopathy is characterized by microvascular changes. Despite the fact that DR is a common complication of diabetes, many cases are detected only at a late phase where visual acuity is impaired and some irreversible retinal damage has occurred (Aiello, 2003).

Structural changes in the microvasculature during the progression of diabetic retinopathy are well characterized. The earliest detectable changes in diabetic retinopathy are the morphological appearance of microaneurysms and capillary occlusions (Apple DJ, 1985). At an early stage the diabetic eye loses pericytes and undergoes structural alteration in smooth muscle cells, as well as proliferation of endothelial cells (Ansari, et al., 1998, Paget, et al., 1998). The loss of pericytes causes microaneurysm formation, while basement membrane thickening and endothelial cell proliferation lead to vascular occlusion (Dodge & D'Amore, 1992). The challenge in ophthalmologic management of diabetic patients is to detect abnormalities in microvascular hemodynamics before gross morphological changes appear, allowing the physician to intervene in the progress of disease before the damage becomes irreversible

Abnormalities detected in the retina can also provide an indication of the effect of systemic diseases. Standard ophthalmoscopy, however, is observer dependent, and too imprecise to use as a risk indicator of increased cardiovascular morbidity and mortality, either in diabetic (van Hecke, et al., 2006) or in hypertensive patients (van den Born, et al., 2005). A device that automatically assesses functional changes in the retinal microvasculature by detecting and quantifying subtle alterations in flow velocity might serve to overcome the limits of standard morphological evaluation. The functional results obtained by such a method can also help to differentiate between diseases whose structural effects, albeit pronounced, may be open to ambivalent interpretation. Therefore, it appears that development of additional devices based on new principles to measure blood flow and or flow velocity is warranted.

Functional optical imaging of the eye represents a novel non-invasive diagnostic approach for the measurement of retinal blood flow-velocities, mapping of vascular network structure, and for obtaining information about the oximetric (Abramoff, et al., 2006, Grinvald, et al., 2004, Hanazono, et al., 2007) and metabolic status of the retina (Grinvald, et al., 1986, Nelson, et al., 2005).

2. Blood flow velocity measurement in patients with diabetes mellitus

The diabetic pathological processes, which initially are subtle, affect retinal hemodynamics. In the normal retina, autoregulated vascular responses keep the blood flow constant over a range of systemic blood pressures and intraocular pressures (Riva, et al., 1981, Robinson, et al., 1986). Vessels are controlled through local factors, (Haefliger & Anderson, 1997, Matsugi, et al., 1997a, atsugi, et al., 1997b, Riva et al., 1981, Shepro & Morel, 1993) which primarily target smooth muscle cells in arterioles and capillary pericytes (Shepro & Morel, 1993, Sims, 1986). In patients with diabetes, however, there are changes in local vasoactive factors as well as in the response of pericytes to these factors (Bursell, et al., 1997, de la Rubia, et al., 1992, Gillies & Su, 1993, Joussem, et al., 2002, King, et al., 1994, Riva et al., 1981).

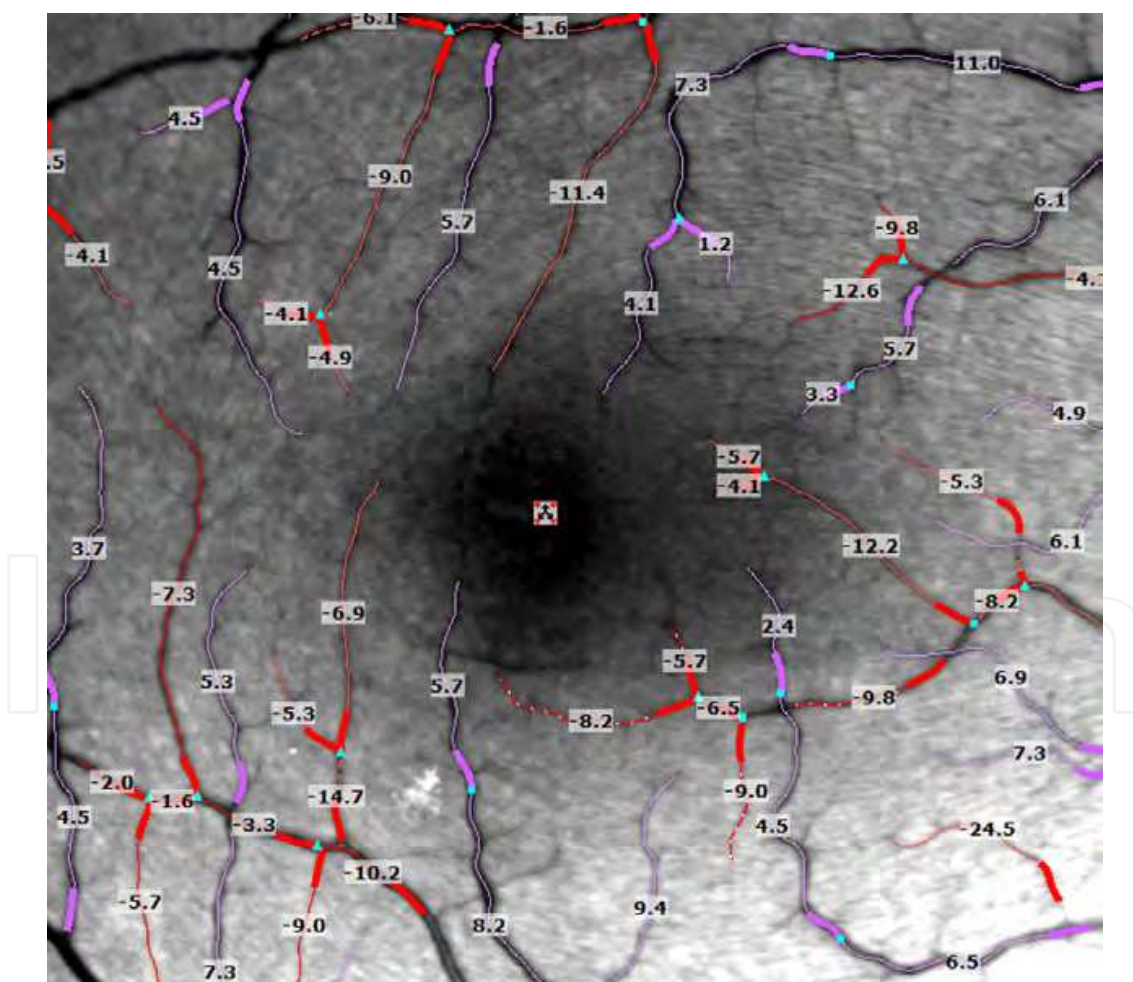


Fig. 1. Blood-flow velocity imaged by Retinal Function Imager in a healthy subject, the velocity (mm/sec) in secondary and tertiary branches of arteries (red) and veins (purple) is shown.

The flow-velocity modality of the Retinal Function Imager (RFI) identifies the motion of red blood cells in retinal vessels by comparing images in a short movie (8- 24 frames) of the retina taken under green light. Each series of 8 frames is acquired within a single short interval of less than 200 msec. To avoid heart-beat pulsation bias of the measured velocities, the timing of a series capture is always triggered on the ECG. The distance traveled by red blood cells in a known time is calculated for each of several retinal blood vessel segments, using a cross-correlation algorithm (Grinvald et al., 2004) and thus directly measuring their average simultaneous velocities. The measured velocity in secondary and tertiary branches of arterioles and venules is recorded by superimposing it on the fundus image (mm/sec; Figure 1).

2.1 Blood flow velocity in patients with Diabetic retinopathy (DR)

To study the effect of DR on the retinal blood flow velocity 42 diabetic patients (58 eyes) and 32 healthy subjects (51 eyes) were recruited (Burgansky-Eliash, et al., 2010). All of the patients in that study group were suffering from adult-onset diabetic mellitus with moderate to severe NPDR in the study eye(s) (ETDRS categories D or E). All subjects were scanned using the RFI resulting in simultaneous measurement of blood-flow velocities in multiple macular vascular segments. In addition, information about medical history and smoking habits were recorded, systemic blood pressure and intraocular pressure were measured and heart rate recording from the RFI was obtained.

The retinal blood flow velocity in the DR patients was significantly slower than in the healthy subjects. The average flow velocities (in mm/sec) of all arterial segments in an eye was 3.74 ± 1.09 for the diabetic patients and 4.19 ± 0.99 for the controls. The difference was significant ($p < 0.001$) using model considering parameters variable between the groups (gender, age, systolic blood pressure, heart rate, hypertension and smoking status). The average velocity of all venous segments in an eye was lower than the average arterial velocities: 2.61 ± 0.65 in the diabetic group and 3.03 ± 0.59 in the healthy group. This difference was statistically different ($p = 0.004$, table 1).

	NPDR Patients <i>N</i> = 58 (eyes)	Healthy Subjects <i>N</i> = 51 (eyes)	<i>P</i> *
Arteries (mm/sec, mean \pm SD)	3.74 ± 1.09	4.19 ± 0.99	<0.001
Veins (mm/sec, mean \pm SD)	2.61 ± 0.65	3.03 ± 0.59	0.004

* Mixed effect model adjusted for gender, age, systolic blood pressure, heart rate, hypertension and smoking status, NPDR= nonproliferative diabetic retinopathy.

Table 1. Blood-Flow Velocity in Arteries and Veins of Diabetic Patients and Healthy Subjects

The retinal blood-flow velocity and volume in patients with NPDR was compared to controls using multiple measuring devices indicating that blood-flow velocity in general is decreased in patients with NPDR (Arend, et al., 1995, Grunwald, et al., 1986, Hudson, et al., 2005), whereas blood-flow volume measured at or near the level of the whole retina is not decreased (Grunwald et al., 1986, Hudson et al., 2005) and may even be increased (Yoshida, et al., 1983). With the progression of retinopathy, there is evidence showing further

reduction in blood flow velocity (Arend, et al., 1991, Blair, et al., 1982, Grunwald et al., 1986, Yoshida et al., 1983) though conflicting data exist (Hudson et al., 2005).

Of the 58 diabetic eyes, 33 (57%) had clinically significant macular edema according to the ETDRS criteria (1991), and 36 (62%) had previously undergone focal laser treatment of the macula. When the diabetic patients were sub grouped according to the presence or absence of macular edema and prior macular laser treatment, differences between subgroups were not significant ($P = 0.22$ in venules 0.52 in arterioles; in the mixed-effect model, blood-flow velocity is compared between the subgroups taking into account the repeated measures of velocities in the two eyes, gender and age; table 2). These results are consistent with previous findings from examination of arteriole diameters (Jeppesen & Bek, 2006), from laser Doppler flowmetry (Guan, et al., 2006), and from SLO FA videos (Arend et al., 1995) but not in a more recent SLO FA study (Sakata, et al., 2006). Landa et al. found a correlation between RFI average blood flow velocity in retinal veins and the degree of retinal edema represent by OCT central retinal volume(Landa, et al., 2009).

		Diabetic Macular Edema	
		No (n = 25)	Yes (n = 33)
Macular laser treatment	No (n = 22)	(n = 13) A*: 4.16 ± 1.22 V**: 2.73 ± 0.42	(n = 9) A: 3.27 ± 1.0 V: 2.3 ± 0.49
	Yes (n = 36)	(n = 12) A: 3.8 ± 0.8 V: 2.8 ± 0.71	(n = 24) A: 3.65 ± 1.1 V: 2.56 ± 0.71

*A = arteries; **V = veins

Table 2. Effects of Macular Edema and Prior Laser Treatment on Retinal Blood Flow Velocity

2.2 Blood flow velocity in patients with pre-retinopathy diabetes mellitus

After confirming blood flow velocity alternation in the patients with existing DR, a study was performed utilizing the RFI in order to discover hemodynamic changes in patients with diabetes mellitus before morphological changes occur in the retina. This study compared the blood-flow velocity in the retinal vasculature of adult-onset diabetic mellitus patients with no evidence of diabetic retinopathy (23 eyes of DM patients) to that of aged-matched healthy controls (51 eyes of 31). Retinal blood flow velocity was measured using the RFI. Measurement of systemic blood pressure, intraocular pressure, blood glucose level, glycosylated haemoglobin (HbA1C) and body mass index (BMI) were recorded, and heart rate recording from the RFI was obtained.

The average blood-flow velocity in the arteries was 4.7 ± 1.7 mm/sec in the DM group. This was significantly higher than in the healthy subjects (4.1 ± 0.9 mm/sec, $p=0.03$, table 2). As expected, in both groups venous velocity was slower than in the arteries. The DM group had significantly increased venous velocity compared to healthy controls (3.8 ± 1.2 mm/sec vs. 2.9 ± 0.5 mm/sec, respectively; $p < 0.0001$). In the DM group, the velocity values of either arteries or veins were not correlated to the duration of diabetes or the levels of glucose, HbA1C or BMI.

	Early DM (N=23)	Healthy (N=51)	<i>P</i> *
Arteries (mm/sec, mean ± SD)	4.7 ± 1.7	4.1 ± 0.9	0.03
Veins (mm/sec, mean ± SD)	3.8 ± 1.2	2.9 ± 0.5	< 0.001

* Mixed effect model adjusted for gender, age and repeated measures of velocity for both eyes of some patients, DM=diabetes mellitus

Table 3. Blood-Flow Velocity in Arteries and Veins of Diabetic Patients and Healthy Subjects

The increased velocity found in pre-retinopathy patients compared to healthy has the opposite direction to the findings in NPDR patients (Burgansky-Eliash et al., 2010). Thus, the patient/healthy blood-flow velocity relationship reverses during the development of morphological alterations in the retina, as arteries reach the end of their compensating range, or capillary resistance assumes dominance in determining flow volume. In longitudinal studies (Konno, et al., 1996, Rimmer, et al., 1989) decreasing blood-flow velocity over time was found in some but not all diabetic patients.

Considering other causes, the increased velocity found in the DM group might reflect counteracted perfusion abnormalities in diabetic patient retina, stimulated, for example, by changes in blood rheological properties or increased vascular resistance. In diabetic patients there is increased aggregation and reduced deformability of red blood cells, with increased plasma viscosity (Burgansky-Eliash et al., 2010, McMillan, 1975, McMillan, 1978), translating to increased capillary resistance. Vascular resistance can result also from multiple molecular changes associated with long term hyperglycemia as well as endothelial dysfunction. Many of these pathways are interrelated and may be simultaneously activated in retinal cells (Schmetterer & Wolzt, 1999). Some known vasoconstrictor effectors are related to diabetic changes like increased expression of endothelin-1 (ET-1) (Takagi, et al., 1996), and over activation of protein kinase C (PKC) (Grunwald, 1996). Other vasodilatory mechanisms were identified as well, like ET-1 resistance, inhibition of calcium-influx channel in smooth muscle cells, tissue hypoxia (Gardiner, et al., 2007), and increased activity of Nitric oxide syntase (do Carmo, et al., 1998). In addition, in diabetes there is increased leukocytes adhesion to endothelium which is caused by increased expression of adhesion molecules (Miyamoto, et al., 1998) and is associated with endothelial dysfunction (Abiko, et al., 2003). Indeed, in vivo studies found elevated levels of markers of endothelial dysfunction in patients with diabetic retinopathy (soluble intercellular adhesion molecule-1 (sICAM-1) and soluble vascular cell adhesion molecule-1 (sVCAM) (van Hecke, et al., 2005). However, studies mimicking retinal capillary obstruction by leukocytes did not detect an effect on retinal blood flow (Abiko et al., 2003). The most physiologically plausible scenario consistent with the findings reported here is that arteries widen in response to impaired capillary perfusion, while venous diameter remains relatively constant. An increase in the arterial/venous diameter ratio is implied by the finding of a greater relative increase in venous velocity (31%) compared to arterial velocity (15%). Excluding an increase in blood pressure, this also implies increased flow volume. Either excessive vasodilatation as a feedback to local ischemia or inhomogeneity in capillary resistance where some capillaries close while other dilate, could produce this over-compensation and increased flow volume. These changes could join a vicious cycle, according to the hemodynamic

hypothesis (Parving, et al., 1983, Zatz & Brenner, 1986) that increased blood flow in diabetes patients induces further endothelial damage due to increased shear stress (Kohner, et al., 1995). The decreased vessel density in early diabetes that was found here, was reported previously (Arend et al., 1991).

2.3 The correlation of blood flow velocity to physiological parameters

2.3.1 Correlation to blood pressure

In the healthy group the flow velocity in the arterioles, but not in the venules, was found to be positively correlated with the mean arterial pressure ($r = 0.29$, $p = 0.006$; Figure 2, systolic BP: $r=0.3$, $p=0.04$, diastolic BP: $r=0.4$, $p=0.009$).

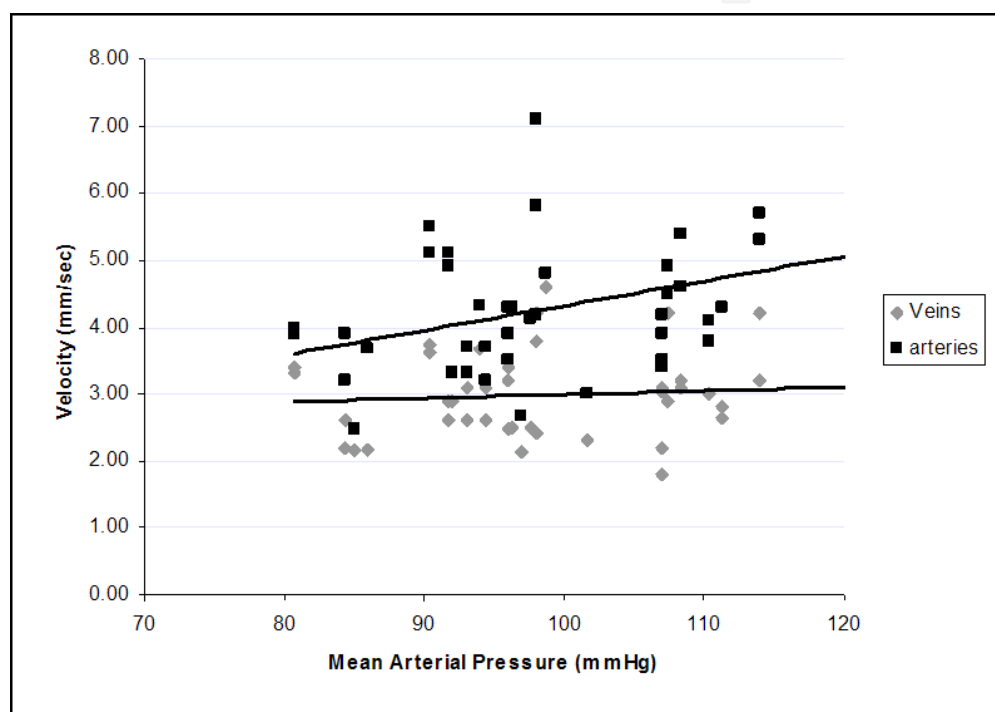


Fig. 2. Correlation between the blood-flow velocity imaged by the Retinal Function Imager and the mean arterial pressure in healthy subjects.

However, there was no significant correlation between flow velocity and mean arterial pressure in the diabetic retinopathy or the pre-retinopathy cohorts. This reduced correlation in the diabetic group compared to the healthy group does not necessarily imply that a fundamental dependency is lost. One possibility is that the dependency relationship itself changes as diabetes develops, so that statistical significance is obscured by uncontrolled factors between patients, such as the progress of the disease.

2.3.2 Correlation to heart rate

The average heart rate did not correlate with average velocity of either the healthy, the DM or DR groups. The relationship between retinal blood-flow-velocity and heart rate in individual participants was assessed by correlating the heart rate recorded by the instrument in parallel with each velocity measurement. For each participant we obtained a

series of three separate paired measurements of heart rate and flow-velocity. Each value was normalized by the corresponding subject's average. In healthy subjects there is a positive correlation between the heart rate and both arterial and venous velocity ($r=0.4$, $p<0.0001$ for both arteries and veins, figure 3A). In the DM patients a small correlation exists only with the arterial velocity and not with the venous velocity ($r=0.4$, $p=0.0008$ for arteries, $r=0.06$, $p=0.6$ for veins, figure 3B). In the diabetic group, points showed a tendency to cluster around a normalized heart-rate value of 1, because in some members of this group the heart rate over the series was relatively stable. These patients apparently did not differ clinically from the rest of the diabetic retinopathy population. Overall, our diabetic patients demonstrated a correlation between blood-flow velocity and heart rate, although the relationship was less pronounced than in the healthy subjects, possibly because normalized heart rates in the latter group were distributed more widely.

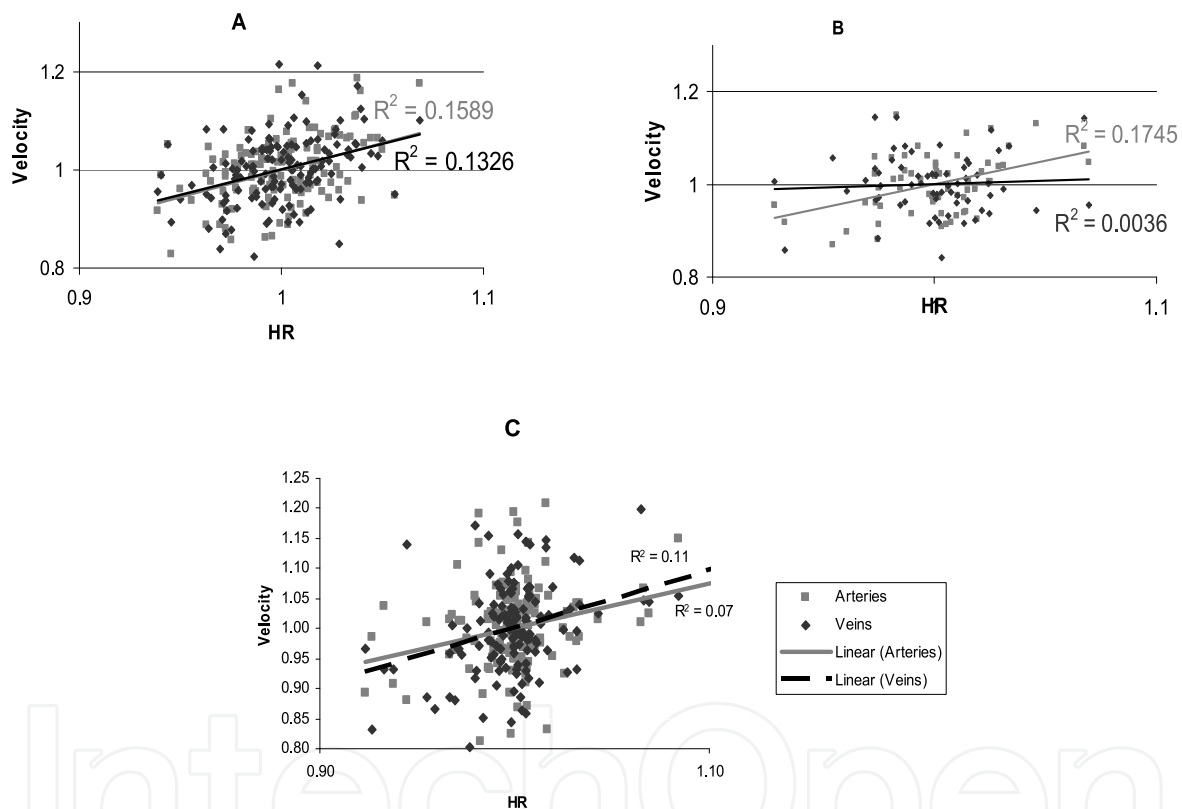


Fig. 3. Correlation between retinal blood flow-velocity and heart rate of all individual series data normalized by the corresponding subject average. A. Healthy group, B. Diabetes mellitus group, C. Diabetic retinopathy group

These findings are consistent with derangement of autoregulatory control mechanisms in diabetic patients (Frederiksen, et al., 2006, Sinclair, et al., 1982), and might be an important characteristic of diabetic retinopathy that warrants future research.

3. Non-invasive Capillary-Perfusion Maps (nCPM)

The retinal function imager (RFI) incorporates a noninvasive method of imaging and mapping the capillaries using the intrinsic contrast chromophore, hemoglobin. Fast

acquisition of images at a wavelength strongly absorbed by hemoglobin enables the motion of RBCs to be detected, and by tracing the paths of this perfusing motion, the capillaries can be visualized to create non-invasive capillary-perfusion maps (nCPMs, figure 4). Fifty-eight eyes of 47 patients with diabetes were scanned (average age, 60.3 ± 11.5); 38 had non-proliferative DR (NPDR) and 20 had proliferative diabetic retinopathy (PDR).

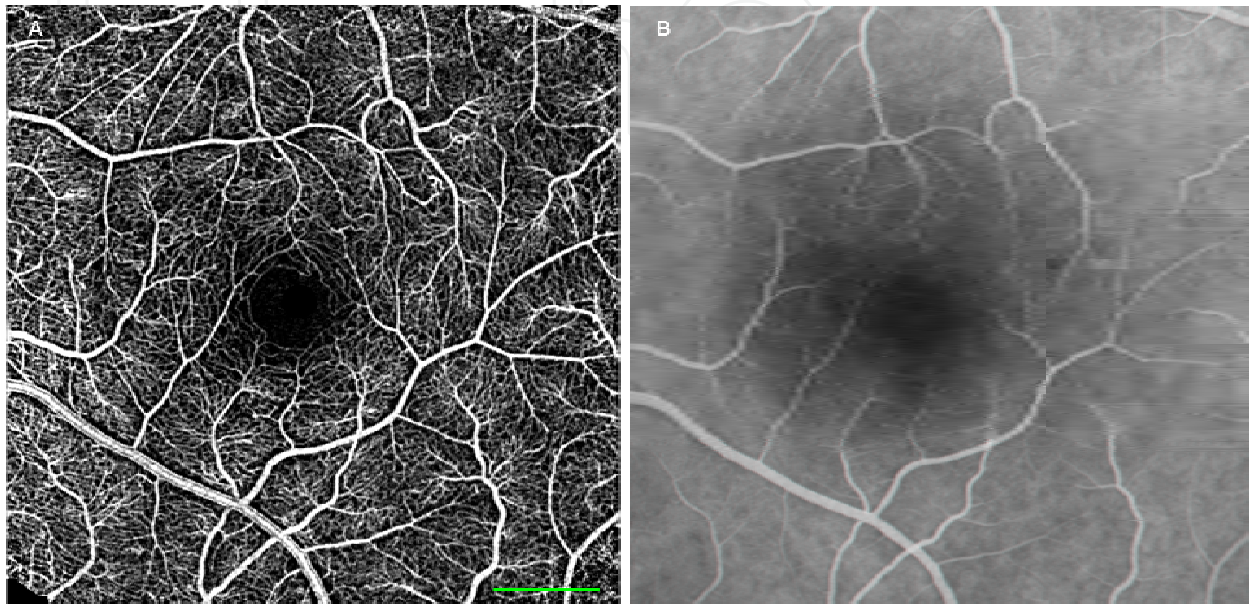


Fig. 4. A. Non-invasive capillary perfusion map in a healthy subject B. corresponding fluorescein angiography (FA) image Scale bar, 500 μm .

Vascular abnormalities seen in the nCPMs of patients with NPDR demonstrate details such as vascular loops and arteriovenous shunts (Figures 5A, 5B). Images of patients with NPDR also demonstrate areas of capillary non-perfusion (Figures. 5C, 5D).

The nCPM images obtained by RFI scanning from eyes with PDR display neovascularization at the optic disc and elsewhere (Figure 6). These coarse, tortuous vessels can be seen protruding from the retina or optic disc surface.

The nCPM provided good capillary perfusion maps that were comparable to the images acquired with an extrinsic contrast agent. Acquisition of nCPM images is non-invasive, comfortable and fast and can be repeated as often as clinically required.

In 14 eyes with DR, a clear image of the fovea was available (in 2 with PDR and in 12 with NPDR). The mean foveal avascular zone (FAZ) diameter and area in these patients were $641.5 \pm 82.3 \mu\text{m}$ and $0.201 \pm 0.07 \text{ mm}^2$, respectively (Figure 7b). This was significantly larger than the corresponding values recorded above for healthy subjects ($n = 37$, Figure 7a; $P < 0.001$ for both diameter and area). Patients with DR were older (average age, 59.2 ± 10.6) than the healthy subjects (average age, 34.8 ± 10.1 ; $P < 0.001$). However, the correlation between age and FAZ size was not significant. Good correlation was found between FAZ diameter and visual acuity in these patients ($R^2 = 0.34$, $P < 0.05$); thus, poorer visual acuity was associated with larger FAZ diameter.

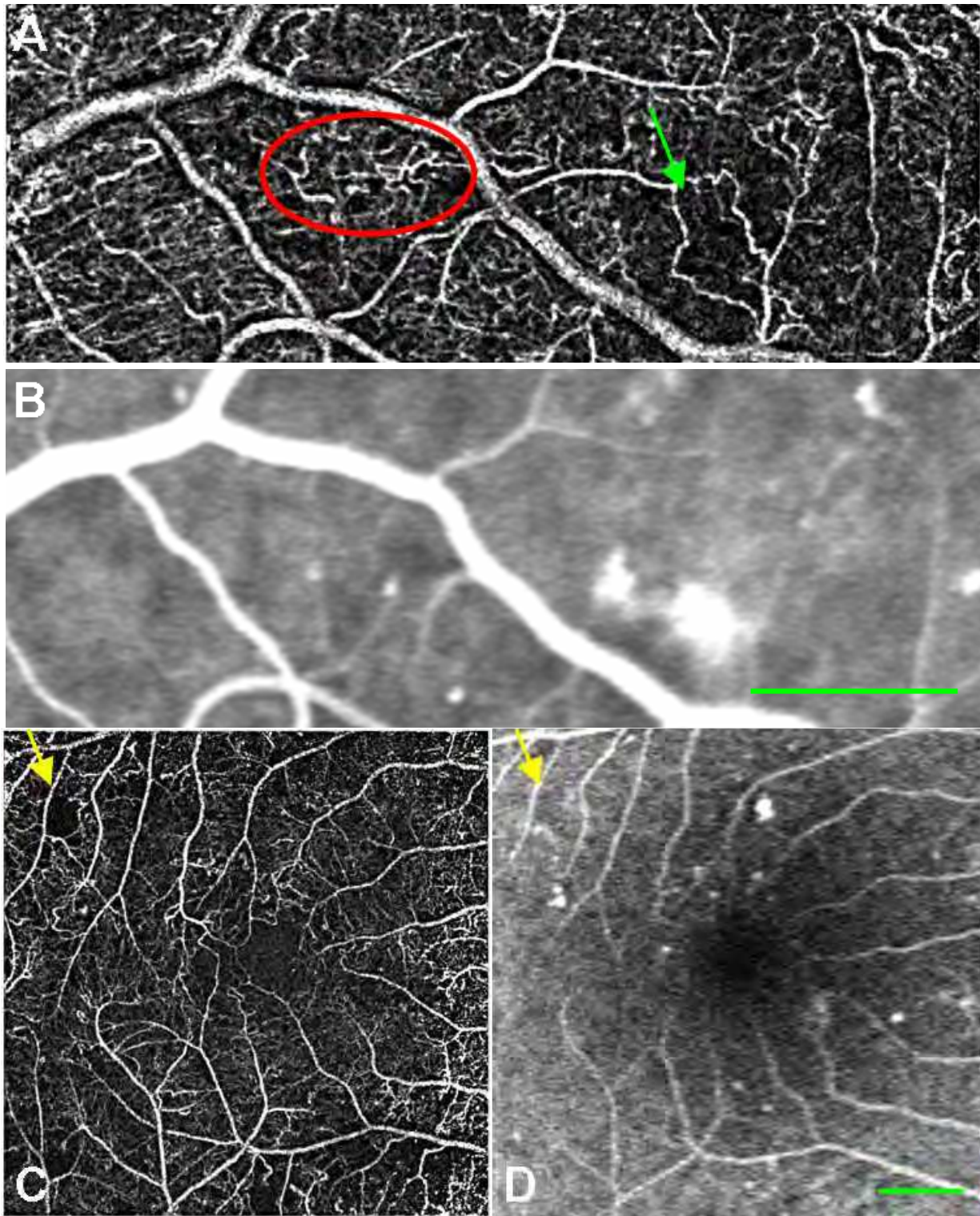


Fig. 5. Non-invasive capillary perfusion map and fluorescein angiographic (FA) images from patients with non-proliferative diabetic retinopathy. A. nCPM of a patient with NPDR. B. Corresponding FA scanning. The nCPM demonstrates vascular loops (red ellipse) and vascular shunts (green arrow). C. nCPM a patient with NPDR. D. Corresponding FA image; yellow arrows demonstrate non-perfusion.

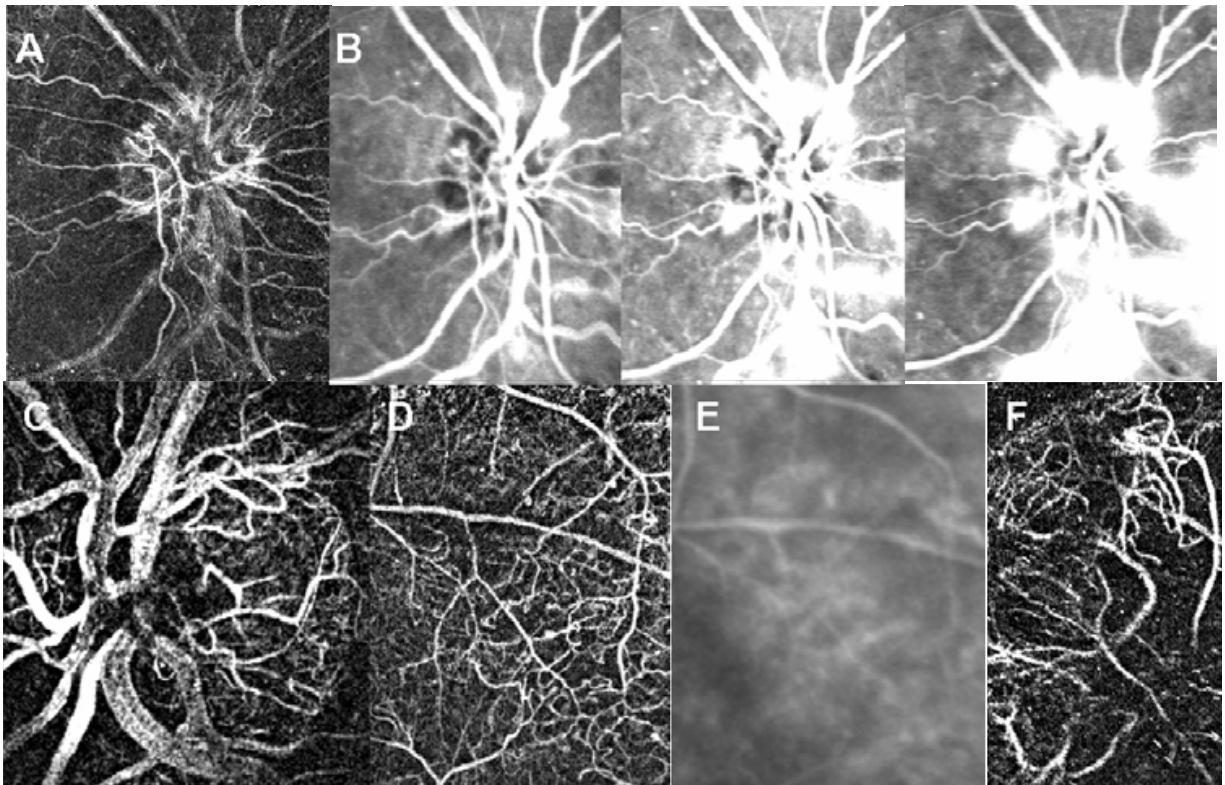


Fig. 6. Non-invasive capillary perfusion imaging of patients with proliferative diabetic retinopathy (PDR). A. nCPM image demonstrating neovascularization of the optic disc (NVD), and B. equivalent fluorescein angiography (FA) images at different stages after fluorescein injection. C. Another example of an nCPM image demonstrating NVD. D. nCPM images showing abnormal vasculature E. Corresponding FA and. F. nCPM image of neovascularization elsewhere (NVE).

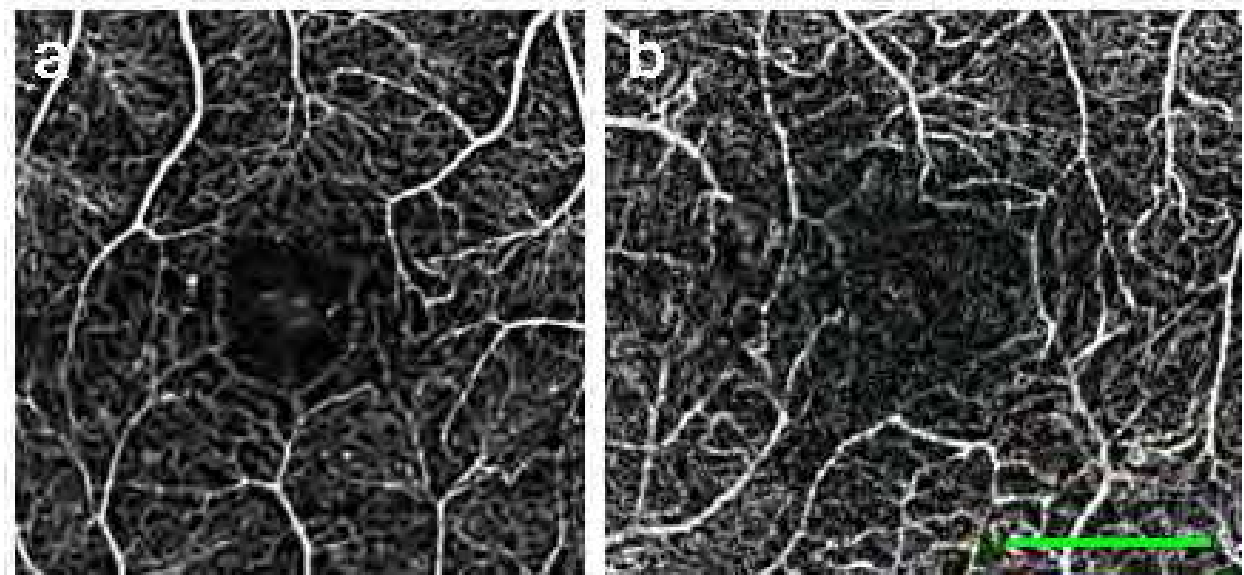


Fig. 7. Foveal avascular zone (FAZ) measurements. A) healthy subject, B) DR patient. Area and diameter, respectively, of FAZ: a) 0.114 mm², 464 μ m; b) 0.225 mm², 672 μ m. The green dotted line encircles the FAZ. Scale bar, 500 μ m.

The size of the FAZ reflects the condition of the capillary circulation surrounding the foveal area, and can be a valuable staging tool as it increases under pathological conditions (Conrath, et al., 2005, Yap, et al., 1987). FAZ was measured noninvasively as long as 20 years ago by the entoptic method (Bradley, et al., 1992), revealing an increase in FAZ size in DR patients (Applegate, et al., 1997). That method, however, is subjective and depends on patient training and compliance. Our measurements revealed a significant increase in FAZ size in patients with DR relative to the healthy group. The FAZ measurement obtained by nCPMs in healthy subjects was within the documented range of the FAZ diameter (350–750 μm) (Tyrberg, et al., 2008). Loss of capillaries in the fovea is common in patients with ischemic retinopathies, and FAZ size has been shown to correlate with the visual prognosis in these cases (Mintz-Hittner, et al., 1999, Tyrberg et al., 2008). As previously reported (Applegate et al., 1997), we found a correlation between poorer visual acuity and larger FAZ diameter. Thus, the use of nCPM images should make it possible to measure FAZ easily, and provide a convenient and safe way to monitor this zone for an increase in size and other related changes during follow-up. Measurement of FAZ size can also help to assess suitability for treatment, given that different treatments are needed for a highly ischemic fovea and one that is well perfused (Chung, et al., 2008).

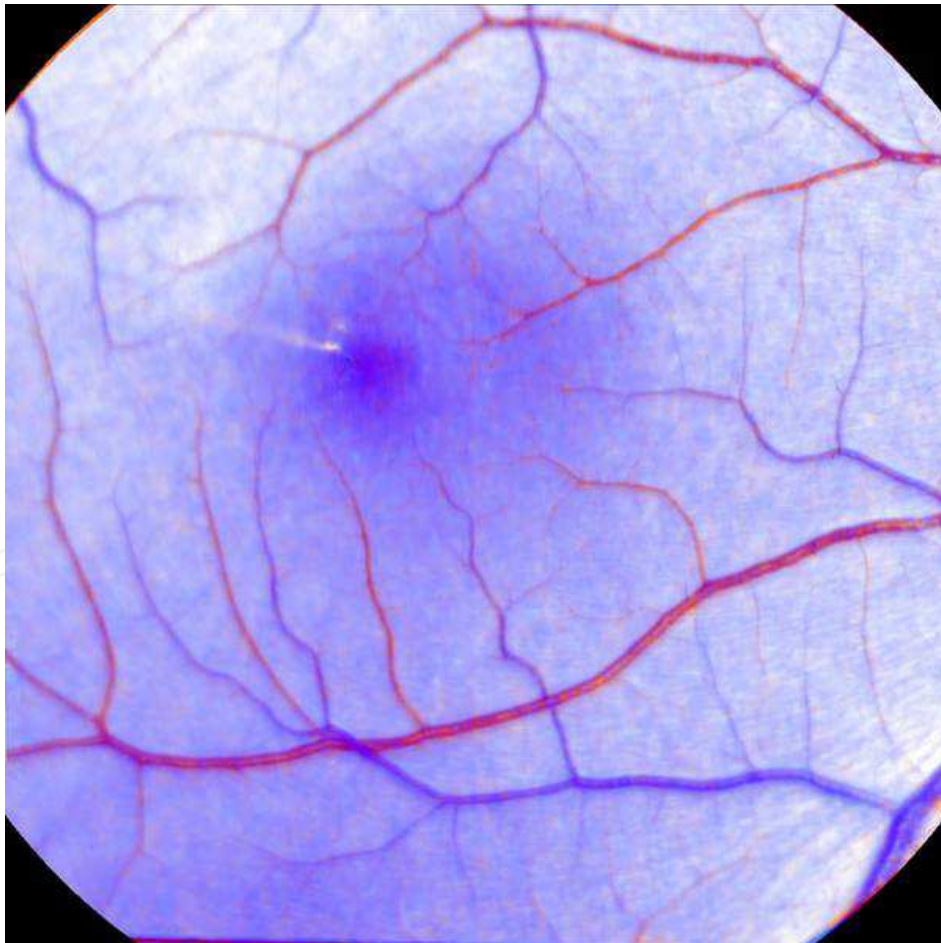


Fig. 8. Qualitative oximetric image obtained with the RFI from the retina of a healthy volunteer. Arteries, veins, and capillaries appear in different colors because of the different oxygen saturation levels of blood.

3. Oxymetry

The balance of oxygen supply and demand in the retina is closely regulated to maintain the processes of visual perception. Alterations in either oxygen supply or consumption might directly indicate the early onset of retinal abnormalities. The difference between the absorption spectra of oxyhemoglobin and deoxyhemoglobin can be used to determine the oxygenation of blood with multispectral imaging methods. Evaluation of retinal oxygen utilization may provide essential information about metabolic state of the retina, and assist in early detection of retinovascular diseases.

In multispectral imaging mode, the RFI can perform spectroscopic decomposition to qualitatively assess the oximetric state of the retina (Izhaky, et al., 2009). A qualitative oximetry map of a healthy volunteer was obtained by acquiring retinal images at two wavelengths (oximetric, 575 ± 5 nm, and isosbestic, 569 ± 5 nm). Differential decomposition analysis was used to generate the oximetry image (Figure 8).

Quantitative retinal oximetry was studied previously in healthy subjects revealing reproducible results that were sensitive to changes in oxygen concentration (Hardarson, et al., 2006). In patients with central retinal vein occlusion, oxygen saturation in veins of the affected eye was lower than in the fellow eye (Hardarson & Stefansson, 2010). Retinal oximetric evaluation using imaging oximeter (oxygen module by Imedos, GmbH, Jena) of diabetic patients revealed an increase in venous oxygen saturation in patients with diabetic retinopathy, which was in correlation with the severity of the retinopathy (Hammer, et al., 2009). This implies reduced oxygen release to the tissue and tissue hypoxia which was attributed to either capillary closure and formation of arterio-venous shunt vessels or disturbance of vascular auto-regulation.

4. Functional assessment of visual tests and ERG

Retinal reflectance changes in response to photic stimulation carry information about metabolic processes underlying light responses in the retina. High-resolution, contrast agent-free optical imaging based on intrinsic signals in vivo has significantly contributed to understanding of the functional architecture of the neocortex (Grinvald et al., 1986). It reveals activity dependent changes in light reflectance, recorded using a digital camera with high spatial and temporal resolution. Such functional signals are usually small, originating from activity-dependent metabolic, hemodynamic, and fast and slow light-scattering changes (Frostig, et al., 1990, Malonek & Grinvald, 1996).

The RFI is capable of imaging outside the absorption range of photoreceptors under near-infrared light (750–840 nm), and can be used to optically monitor retinal activity in response to a well-defined visual stimulus (562 ± 20 nm). The difference between the poststimulated and prestimulated images is used to determine the metabolic state of the retinal compartments. Change in light reflectance in response to a visual stimulus flashing were recorded in the cat retina (Izhaky et al., 2009). Similar experiments conducted on cats, monkeys, and humans have provided functional maps resulting from photic pattern activation (Abramoff et al., 2006, Hanazono, et al., 2008, Hanazono et al., 2007, Srinivasan, et al., 2009).

Electrophysiological studies of visual function in patients with diabetes mellitus demonstrate that functional alterations in the middle and inner retinal layers are present even prior to the development of clinical retinopathy (Bresnick & Palta, 1987, Tzekov & Arden, 1999, Zaharia, et al., 1987). Therefore, the diabetes induces changes in vision function may be not only secondary to vascular damage but also to neurosensory abnormality (Shirao & Kawasaki, 1998). Once diabetic retinopathy develops, additional electroretinogram (ERG) parameters are altered suggesting that photoreceptor abnormalities also occur. The changes are more pronounced compared to preretinopathy stage and there is a significant correlation between retinopathy severity and the magnitude of the functional loss (Holopigian, et al., 1992, van der Torren & Mulder, 1993, Weiner, et al., 1997). Multifocal ERG (mfERG), which maps local function, are abnormal in eyes of diabetic subjects without retinopathy and, to a greater degree, in eyes with mild or moderate NPDR. Moreover, abnormal mfERG implicit times are predictive of the development of new diabetic retinopathy over one and two years and are spatially associated with the retinopathy (Bearse, et al., 2006).

5. Conclusions

This chapter discuss the functional effect of diabetes mellitus on the retina. Retinal blood flow velocity measurements using the retinal function imager (RFI), discovered abnormal results in patients with various stages of diabetic-related ophthalmic condition. The result shows a significant decrease in arterial and venous velocity of patients with diabetic retinopathy and increase in diabetic patients with apparently normal retina compared to normals. The velocity correlation to blood pressure and heart rate was partially lost in the diabetic population either with or without retinopathy. The same technology was used to visualize capillary details without injecting contrast agents. Various vascular abnormalities like shunts and vascular loops were shown. In addition, examples of enlarged avascular zones in the fovea and ischemic retinal areas were presented. Multi-spectral imaging with the RFI was used to create qualitative oxymetry maps. Oxymetry measurement discovered increase in venous oxygen saturation. Imaging and analysis of changes in retinal reflectance in response to photic stimulation provides important information about retinal functionality. Electrophysiological alternations are present in early diabetes prior to the appearance of overt diabetic retinopathy.

6. References

- (1991). Grading diabetic retinopathy from stereoscopic color fundus photographs--an extension of the modified Airlie House classification. ETDRS report number 10. Early Treatment Diabetic Retinopathy Study Research Group. *Ophthalmology*, 98 (5 Suppl), 786-806.
- Abiko, T., Abiko, A., Clermont, A.C., Shoelson, B., Horio, N., Takahashi, J., Adamis, A.P., King, G.L., & Bursell, S.E. (2003). Characterization of retinal leukostasis and hemodynamics in insulin resistance and diabetes: role of oxidants and protein kinase-C activation. *Diabetes*, 52 (3), 829-837.

- Abramoff, M.D., Kwon, Y.H., Ts'o, D., Soliz, P., Zimmerman, B., Pokorny, J., & Kardon, R. (2006). Visual stimulus-induced changes in human near-infrared fundus reflectance. *Invest Ophthalmol Vis Sci*, 47 (2), 715-721.
- Aiello, L.M. (2003). Perspectives on diabetic retinopathy. *Am J Ophthalmol*, 136 (1), 122-135.
- Ansari, N.H., Zhang, W., Fulep, E., & Mansour, A. (1998). Prevention of pericyte loss by trolox in diabetic rat retina. *J Toxicol Environ Health A*, 54 (6), 467-475.
- Apple DJ, R.M. (1985). Ocular Pathology. Clinical applications and self-assessment. . (St Louis, Toronto, Princeton: Mosby.
- Applegate, R.A., Bradley, A., van Heuven, W.A., Lee, B.L., & Garcia, C.A. (1997). Entoptic evaluation of diabetic retinopathy. *Invest Ophthalmol Vis Sci*, 38 (5), 783-791.
- Arend, O., Remky, A., Harris, A., Bertram, B., Reim, M., & Wolf, S. (1995). Macular microcirculation in cystoid maculopathy of diabetic patients. *Br J Ophthalmol*, 79 (7), 628-632.
- Arend, O., Wolf, S., Jung, F., Bertram, B., Postgens, H., Toonen, H., & Reim, M. (1991). Retinal microcirculation in patients with diabetes mellitus: dynamic and morphological analysis of perifoveal capillary network. *Br J Ophthalmol*, 75 (9), 514-518.
- Bearse, M.A., Jr., Adams, A.J., Han, Y., Schneck, M.E., Ng, J., Bronson-Castain, K., & Barez, S. (2006). A multifocal electroretinogram model predicting the development of diabetic retinopathy. *Prog Retin Eye Res*, 25 (5), 425-448.
- Blair, N.P., Feke, G.T., Morales-Stoppello, J., Riva, C.E., Goger, D.G., Collas, G., & McMeel, J.W. (1982). Prolongation of the retinal mean circulation time in diabetes. *Arch Ophthalmol*, 100 (5), 764-768.
- Bradley, A., Applegate, R.A., Zeffren, B.S., & van Heuven, W.A. (1992). Psychophysical measurement of the size and shape of the human foveal avascular zone. *Ophthalmic Physiol Opt*, 12 (1), 18-23.
- Bresnick, G.H., & Palta, M. (1987). Oscillatory potential amplitudes. Relation to severity of diabetic retinopathy. *Arch Ophthalmol*, 105 (7), 929-933.
- Burgansky-Eliash, Z., Nelson, D.A., Bar-Tal, O.P., Lowenstein, A., Grinvald, A., & Barak, A. (2010). Reduced retinal blood flow velocity in diabetic retinopathy. *Retina*, 30 (5), 765-773.
- Bursell, S.E., Takagi, C., Clermont, A.C., Takagi, H., Mori, F., Ishii, H., & King, G.L. (1997). Specific retinal diacylglycerol and protein kinase C beta isoform modulation mimics abnormal retinal hemodynamics in diabetic rats. *Invest Ophthalmol Vis Sci*, 38 (13), 2711-2720.
- Chung, E.J., Roh, M.I., Kwon, O.W., & Koh, H.J. (2008). Effects of macular ischemia on the outcome of intravitreal bevacizumab therapy for diabetic macular edema. *Retina*, 28 (7), 957-963.
- Conrath, J., Giorgi, R., Raccach, D., & Ridings, B. (2005). Foveal avascular zone in diabetic retinopathy: quantitative vs qualitative assessment. *Eye*, 19 (3), 322-326.
- de la Rubia, G., Oliver, F.J., Inoguchi, T., & King, G.L. (1992). Induction of resistance to endothelin-1's biochemical actions by elevated glucose levels in retinal pericytes. *Diabetes*, 41 (12), 1533-1539.
- do Carmo, A., Lopes, C., Santos, M., Proenca, R., Cunha-Vaz, J., & Carvalho, A.P. (1998). Nitric oxide synthase activity and L-arginine metabolism in the retinas from streptozotocin-induced diabetic rats. *Gen Pharmacol*, 30 (3), 319-324.

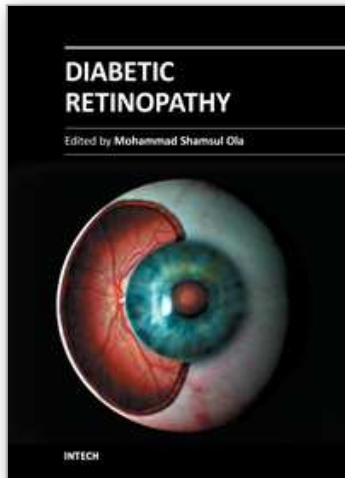
- Dodge, A.B., & D'Amore, P.A. (1992). Cell-cell interactions in diabetic angiopathy. *Diabetes Care*, 15 (9), 1168-1180.
- Frederiksen, C.A., Jeppesen, P., Knudsen, S.T., Poulsen, P.L., Mogensen, C.E., & Bek, T. (2006). The blood pressure-induced diameter response of retinal arterioles decreases with increasing diabetic maculopathy. *Graefes Arch Clin Exp Ophthalmol*, 244 (10), 1255-1261.
- Frostig, R.D., Lieke, E.E., Ts'o, D.Y., & Grinvald, A. (1990). Cortical functional architecture and local coupling between neuronal activity and the microcirculation revealed by in vivo high-resolution optical imaging of intrinsic signals. *Proc Natl Acad Sci U S A*, 87 (16), 6082-6086.
- Gardiner, T.A., Archer, D.B., Curtis, T.M., & Stitt, A.W. (2007). Arteriolar involvement in the microvascular lesions of diabetic retinopathy: implications for pathogenesis. *Microcirculation*, 14 (1), 25-38.
- Gillies, M.C., & Su, T. (1993). High glucose inhibits retinal capillary pericyte contractility in vitro. *Invest Ophthalmol Vis Sci*, 34 (12), 3396-3401.
- Grinvald, A., Bonhoeffer, T., Vanzetta, I., Pollack, A., Aloni, E., Ofri, R., & Nelson, D. (2004). High-resolution functional optical imaging: from the neocortex to the eye. *Ophthalmol Clin North Am*, 17 (1), 53-67.
- Grinvald, A., Lieke, E., Frostig, R.D., Gilbert, C.D., & Wiesel, T.N. (1986). Functional architecture of cortex revealed by optical imaging of intrinsic signals. *Nature*, 324 (6095), 361-364.
- Grunwald, J.E., Bursell, S.E. (1996). Hemodynamic changes as early markers of diabetic retinopathy. *Current Opinion in Endocrinology and Diabetes*, 3, 298-306.
- Grunwald, J.E., Riva, C.E., Sinclair, S.H., Brucker, A.J., & Petrig, B.L. (1986). Laser Doppler velocimetry study of retinal circulation in diabetes mellitus. *Arch Ophthalmol*, 104 (7), 991-996.
- Guan, K., Hudson, C., Wong, T., Kisilevsky, M., Nrusimhadevara, R.K., Lam, W.C., Mandelcorn, M., Devenyi, R.G., & Flanagan, J.G. (2006). Retinal hemodynamics in early diabetic macular edema. *Diabetes*, 55 (3), 813-818.
- Haefliger, I.O., & Anderson, D.R. (1997). Oxygen modulation of guanylate cyclase-mediated retinal pericyte relaxations with 3-morpholino-sydnonimine and atrial natriuretic peptide. *Invest Ophthalmol Vis Sci*, 38 (8), 1563-1568.
- Hammer, M., Vilser, W., Riemer, T., Mandecka, A., Schweitzer, D., Kuhn, U., Dawczynski, J., Liemt, F., & Strobel, J. (2009). Diabetic patients with retinopathy show increased retinal venous oxygen saturation. *Graefes Arch Clin Exp Ophthalmol*, 247 (8), 1025-1030.
- Hanazono, G., Tsunoda, K., Kazato, Y., Tsubota, K., & Tanifuji, M. (2008). Evaluating neural activity of retinal ganglion cells by flash-evoked intrinsic signal imaging in macaque retina. *Invest Ophthalmol Vis Sci*, 49 (10), 4655-4663.
- Hanazono, G., Tsunoda, K., Shinoda, K., Tsubota, K., Miyake, Y., & Tanifuji, M. (2007). Intrinsic signal imaging in macaque retina reveals different types of flash-induced light reflectance changes of different origins. *Invest Ophthalmol Vis Sci*, 48 (6), 2903-2912.
- Hardarson, S.H., Harris, A., Karlsson, R.A., Halldorsson, G.H., Kagemann, L., Rechtman, E., Zoega, G.M., Eysteinnsson, T., Benediktsson, J.A., Thorsteinsson, A., Jensen, P.K., Beach, J., & Stefansson, E. (2006). Automatic retinal oximetry. *Invest Ophthalmol Vis Sci*, 47 (11), 5011-5016.

- Hardarson, S.H., & Stefansson, E. (2010). Oxygen saturation in central retinal vein occlusion. *Am J Ophthalmol*, 150 (6), 871-875.
- Hersh, P.S., Green, W.R., & Thomas, J.V. (1981). Tractional venous loops in diabetic retinopathy. *Am J Ophthalmol*, 92 (5), 661-671.
- Holopigian, K., Seiple, W., Lorenzo, M., & Carr, R. (1992). A comparison of photopic and scotopic electroretinographic changes in early diabetic retinopathy. *Invest Ophthalmol Vis Sci*, 33 (10), 2773-2780.
- Hudson, C., Flanagan, J.G., Turner, G.S., Chen, H.C., Rawji, M.H., & McLeod, D. (2005). Exaggerated relative nasal-temporal asymmetry of macular capillary blood flow in patients with clinically significant diabetic macular oedema. *Br J Ophthalmol*, 89 (2), 142-146.
- Izhaky, D., Nelson, D.A., Burgansky-Eliash, Z., & Grinvald, A. (2009). Functional imaging using the retinal function imager: direct imaging of blood velocity, achieving fluorescein angiography-like images without any contrast agent, qualitative oximetry, and functional metabolic signals. *Jpn J Ophthalmol*, 53 (4), 345-351.
- Jeppesen, P., & Bek, T. (2006). Impaired retinal autoregulation in small retinal arterioles before and after focal laser treatment for diabetic maculopathy. *Br J Ophthalmol*, 90 (2), 198-201.
- Joussen, A.M., Poulaki, V., Tsujikawa, A., Qin, W., Qaum, T., Xu, Q., Moromizato, Y., Bursell, S.E., Wiegand, S.J., Rudge, J., Ioffe, E., Yancopoulos, G.D., & Adamis, A.P. (2002). Suppression of diabetic retinopathy with angiopoietin-1. *Am J Pathol*, 160 (5), 1683-1693.
- Kempner, J.H., O'Colmain, B.J., Leske, M.C., Haffner, S.M., Klein, R., Moss, S.E., Taylor, H.R., & Hamman, R.F. (2004). The prevalence of diabetic retinopathy among adults in the United States. *Arch Ophthalmol*, 122 (4), 552-563.
- King, G.L., Shiba, T., Oliver, J., Inoguchi, T., & Bursell, S.E. (1994). Cellular and molecular abnormalities in the vascular endothelium of diabetes mellitus. *Annu Rev Med*, 45, 179-188.
- Kohner, E.M., & Dollery, C.T. (1970). Fluorescein angiography of the fundus in diabetic retinopathy. *Br Med Bull*, 26 (2), 166-170.
- Kohner, E.M., Patel, V., & Rassam, S.M. (1995). Role of blood flow and impaired autoregulation in the pathogenesis of diabetic retinopathy. *Diabetes*, 44 (6), 603-607.
- Konno, S., Feke, G.T., Yoshida, A., Fujio, N., Goger, D.G., & Buzney, S.M. (1996). Retinal blood flow changes in type I diabetes. A long-term follow-up study. *Invest Ophthalmol Vis Sci*, 37 (6), 1140-1148.
- Landa, G., Garcia, P.M., & Rosen, R.B. (2009). Correlation between retina blood flow velocity assessed by retinal function imager and retina thickness estimated by scanning laser ophthalmoscopy/optical coherence tomography. *Ophthalmologica*, 223 (3), 155-161.
- Malonek, D., & Grinvald, A. (1996). Interactions between electrical activity and cortical microcirculation revealed by imaging spectroscopy: implications for functional brain mapping. *Science*, 272 (5261), 551-554.
- Matsugi, T., Chen, Q., & Anderson, D.R. (1997a). Adenosine-induced relaxation of cultured bovine retinal pericytes. *Invest Ophthalmol Vis Sci*, 38 (13), 2695-2701.
- Matsugi, T., Chen, Q., & Anderson, D.R. (1997b). Suppression of CO₂-induced relaxation of bovine retinal pericytes by angiotensin II. *Invest Ophthalmol Vis Sci*, 38 (3), 652-657.

- McMillan, D.E. (1975). Deterioration of the microcirculation in diabetes. *Diabetes*, 24 (10), 944-957.
- McMillan, D.E. (1978). Rheological and related factors in diabetic retinopathy. *Int Ophthalmol Clin*, 18 (4), 35-53.
- Mintz-Hittner, H.A., Knight-Nanan, D.M., Satriano, D.R., & Kretzer, F.L. (1999). A small foveal avascular zone may be an historic mark of prematurity. *Ophthalmology*, 106 (7), 1409-1413.
- Miyamoto, K., Hiroshiba, N., Tsujikawa, A., & Ogura, Y. (1998). In vivo demonstration of increased leukocyte entrapment in retinal microcirculation of diabetic rats. *Invest Ophthalmol Vis Sci*, 39 (11), 2190-2194.
- Nelson, D.A., Krupsky, S., Pollack, A., Aloni, E., Belkin, M., Vanzetta, I., Rosner, M., & Grinvald, A. (2005). Special report: Noninvasive multi-parameter functional optical imaging of the eye. *Ophthalmic Surg Lasers Imaging*, 36 (1), 57-66.
- Paget, C., Lecomte, M., Ruggiero, D., Wiernsperger, N., & Lagarde, M. (1998). Modification of enzymatic antioxidants in retinal microvascular cells by glucose or advanced glycation end products. *Free Radic Biol Med*, 25 (1), 121-129.
- Parving, H.H., Viberti, G.C., Keen, H., Christiansen, J.S., & Lassen, N.A. (1983). Hemodynamic factors in the genesis of diabetic microangiopathy. *Metabolism*, 32 (9), 943-949.
- Rimmer, T., Fallon, T.J., & Kohner, E.M. (1989). Long-term follow-up of retinal blood flow in diabetes using the blue light entoptic phenomenon. *Br J Ophthalmol*, 73 (1), 1-5.
- Riva, C.E., Sinclair, S.H., & Grunwald, J.E. (1981). Autoregulation of retinal circulation in response to decrease of perfusion pressure. *Invest Ophthalmol Vis Sci*, 21 (1 Pt 1), 34-38.
- Robinson, F., Riva, C.E., Grunwald, J.E., Petrig, B.L., & Sinclair, S.H. (1986). Retinal blood flow autoregulation in response to an acute increase in blood pressure. *Invest Ophthalmol Vis Sci*, 27 (5), 722-726.
- Sakata, K., Funatsu, H., Harino, S., Noma, H., & Hori, S. (2006). Relationship between macular microcirculation and progression of diabetic macular edema. *Ophthalmology*, 113 (8), 1385-1391.
- Schmetterer, L., & Wolzt, M. (1999). Ocular blood flow and associated functional deviations in diabetic retinopathy. *Diabetologia*, 42 (4), 387-405.
- Shepro, D., & Morel, N.M. (1993). Pericyte physiology. *Faseb J*, 7 (11), 1031-1038.
- Shirao, Y., & Kawasaki, K. (1998). Electrical responses from diabetic retina. *Prog Retin Eye Res*, 17 (1), 59-76.
- Sims, D.E. (1986). The pericyte--a review. *Tissue Cell*, 18 (2), 153-174.
- Sinclair, S.H., Grunwald, J.E., Riva, C.E., Braunstein, S.N., Nichols, C.W., & Schwartz, S.S. (1982). Retinal vascular autoregulation in diabetes mellitus. *Ophthalmology*, 89 (7), 748-750.
- Srinivasan, V.J., Chen, Y., Duker, J.S., & Fujimoto, J.G. (2009). In vivo functional imaging of intrinsic scattering changes in the human retina with high-speed ultrahigh resolution OCT. *Opt Express*, 17 (5), 3861-3877.
- Takagi, C., Bursell, S.E., Lin, Y.W., Takagi, H., Duh, E., Jiang, Z., Clermont, A.C., & King, G.L. (1996). Regulation of retinal hemodynamics in diabetic rats by increased expression and action of endothelin-1. *Invest Ophthalmol Vis Sci*, 37 (12), 2504-2518.

- Tyrberg, M., Ponjavic, V., & Lovestam-Adrian, M. (2008). Multifocal electroretinogram (mfERG) in patients with diabetes mellitus and an enlarged foveal avascular zone (FAZ). *Doc Ophthalmol*, 117 (3), 185-189.
- Tzekov, R., & Arden, G.B. (1999). The electroretinogram in diabetic retinopathy. *Surv Ophthalmol*, 44 (1), 53-60.
- van den Born, B.J., Hulsman, C.A., Hoekstra, J.B., Schlingemann, R.O., & van Montfrans, G.A. (2005). Value of routine funduscopy in patients with hypertension: systematic review. *Bmj*, 331 (7508), 73.
- van der Torren, K., & Mulder, P. (1993). Comparison of the second and third oscillatory potentials with oscillatory potential power in early diabetic retinopathy. *Doc Ophthalmol*, 83 (2), 111-118.
- van Hecke, M.V., Dekker, J.M., Nijpels, G., Moll, A.C., Heine, R.J., Bouter, L.M., Polak, B.C., & Stehouwer, C.D. (2005). Inflammation and endothelial dysfunction are associated with retinopathy: the Hoorn Study. *Diabetologia*, 48 (7), 1300-1306.
- van Hecke, M.V., Dekker, J.M., Nijpels, G., Stolk, R.P., Henry, R.M., Heine, R.J., Bouter, L.M., Stehouwer, C.D., & Polak, B.C. (2006). Are retinal microvascular abnormalities associated with large artery endothelial dysfunction and intima-media thickness? The Hoorn Study. *Clin Sci (Lond)*, 110 (5), 597-604.
- Weiner, A., Christopoulos, V.A., Gussler, C.H., Adams, D.H., Kaufman, S.R., Kohn, H.D., & Weidenthal, D.T. (1997). Foveal cone function in nonproliferative diabetic retinopathy and macular edema. *Invest Ophthalmol Vis Sci*, 38 (7), 1443-1449.
- Yap, M., Gilchrist, J., & Weatherill, J. (1987). Psychophysical measurement of the foveal avascular zone. *Ophthalmic Physiol Opt*, 7 (4), 405-410.
- Yoshida, A., Fekke, G.T., Morales-Stoppello, J., Collas, G.D., Goger, D.G., & McMeel, J.W. (1983). Retinal blood flow alterations during progression of diabetic retinopathy. *Arch Ophthalmol*, 101 (2), 225-227.
- Zaharia, M., Olivier, P., Lafond, G., Blondeau, P., & Brunette, J.R. (1987). Lobular delayed choroidal perfusion as an early angiographic sign of diabetic retinopathy: a preliminary report. *Can J Ophthalmol*, 22 (5), 257-261.
- Zatz, R., & Brenner, B.M. (1986). Pathogenesis of diabetic microangiopathy. The hemodynamic view. *Am J Med*, 80 (3), 443-453.

IntechOpen



Diabetic Retinopathy

Edited by Dr. Mohammad Shamsul Ola

ISBN 978-953-51-0044-7

Hard cover, 356 pages

Publisher InTech

Published online 24, February, 2012

Published in print edition February, 2012

The aim of this book is to provide a comprehensive overview of current concepts in pathogenesis, diagnosis and treatments of diabetic retinopathy. It provides a collection of topics written by excellent authors, covering discussions on advances in understanding of pathophysiology, immunological factors and emerging concepts, relating to clinical aspects and treatment strategies. The contents of the book will not only provide a resource for our knowledge but also improve diagnosis and treatment options for those patients who suffer vision loss due to diabetic retinopathy.

How to reference

In order to correctly reference this scholarly work, feel free to copy and paste the following:

Zvia Burgansky-Eliash (2012). The Effect of Diabetes Mellitus on Retinal Function, Diabetic Retinopathy, Dr. Mohammad Shamsul Ola (Ed.), ISBN: 978-953-51-0044-7, InTech, Available from:
<http://www.intechopen.com/books/diabetic-retinopathy/the-effect-of-diabetes-mellitus-on-retinal-function>

INTECH
open science | open minds

InTech Europe

University Campus STeP Ri
Slavka Krautzeka 83/A
51000 Rijeka, Croatia
Phone: +385 (51) 770 447
Fax: +385 (51) 686 166
www.intechopen.com

InTech China

Unit 405, Office Block, Hotel Equatorial Shanghai
No.65, Yan An Road (West), Shanghai, 200040, China
中国上海市延安西路65号上海国际贵都大饭店办公楼405单元
Phone: +86-21-62489820
Fax: +86-21-62489821

© 2012 The Author(s). Licensee IntechOpen. This is an open access article distributed under the terms of the [Creative Commons Attribution 3.0 License](#), which permits unrestricted use, distribution, and reproduction in any medium, provided the original work is properly cited.

IntechOpen

IntechOpen