

We are IntechOpen, the world's leading publisher of Open Access books Built by scientists, for scientists

4,800

Open access books available

122,000

International authors and editors

135M

Downloads

Our authors are among the

154

Countries delivered to

TOP 1%

most cited scientists

12.2%

Contributors from top 500 universities



WEB OF SCIENCE™

Selection of our books indexed in the Book Citation Index
in Web of Science™ Core Collection (BKCI)

Interested in publishing with us?
Contact book.department@intechopen.com

Numbers displayed above are based on latest data collected.

For more information visit www.intechopen.com



Neck Dissection of the Head and Neck Sarcoma

Yuki Saito and Takahiro Asakage

*Department of Otolaryngology, Head and Neck Surgery,
The University of Tokyo,
Japan*

1. Introduction

Sarcomas of the Head and Neck (SHN) are rare tumors of connective tissue origin that comprise less than 1% of head and neck malignancies. SHN account for approximately 5% to 10% of all sarcomas (Bruce, 2004). They arise in any soft tissue or osseous tissues of the region and may be found in patients of any age or gender. This chapter we will present the essential elements of diagnosis and resection or neck dissection of head and neck sarcoma.

Diagnosis of SHN is a diagnostic challenge. Although biopsy by FNA identified the correct specific sarcoma type in only 21% of cases, FNA led to an appropriate diagnostic biopsy in 88% (Costa et al., 1996). In only 7% of cases were the FNA findings misleading (benign or inflammatory) and in 5% of cases the reading was interpreted as inadequate. More recently, FNA biopsies of sarcoma were more often interpreted as showing a lower grade than that determined by final analysis of the fully resected specimen (Jones et al. 2002). Superficial and accessible lesions or lesions with inconclusive results from prior closed biopsy should be biopsied by incisional or excisional technique; fine needle aspiration or core needle biopsy should be reserved for deeper and less accessible lesions (Schalow & Broecker, 2003). Frequently the initial procedure for patients with a mass suspected to be Rhabdomyosarcoma is a biopsy, usually open, which obtains an adequate specimen for pathological, biological and treatment protocol studies. There may be instances when core needle biopsy is appropriate, such as metastatic disease or small lesions in areas that will be treated primarily by chemotherapy and radiotherapy (Rodeberg et al, 2002). Since lymphoma and nasopharyngeal carcinoma would show the same signal intensity characteristics as sarcomas on magnetic resonance, tissue biopsy is imperative for correct diagnosis (Flympas et al. 2009).

The main therapy for soft tissue sarcomas of the head and neck is en-bloc resection with a margin of normal tissue. The adequacy of surgical resection seems to be a major determinant of outcome for sarcomas. The difficulty with en-bloc resection in these tumors relates to the proximity of important neurovascular structures and vital organs, as well as the cosmetic and functional morbidity resulting from such radical extirpative procedures. It is known that some soft-tissue sarcomas develop a pseudocapsule as a result of compression of adjacent tissues. This may obscure the true invasive nature of these neoplasms. Sarcomas tend to extend outside this pseudocapsule and invade tissues that may seem uninvolved during surgery. Because of the anatomical challenges of en-bloc resection for soft tissue sarcomas of the head and neck, positive margins should prompt the addition of adjuvant radiotherapy. Death from SHN is often a consequence of uncontrolled local disease as it is from metastases, unlike other sarcomas where local salvage options are often available.

Most soft tissue sarcoma spread in a longitudinal direction within the muscle groups where they originate. They generally respect barriers to tumor spread, such as bones, interosseous membrane, major fascial planes, etc, and this feature should be exploited in planning tissue preserving approaches to management. As they extend, lesions invade muscle and contiguous structures or other vital anatomy (de Bree et al, 2010).

Most SHN present with localized disease with metastasis being present in fewer than 10% of cases at the time of diagnosis and initial treatment. Predominant risk is to the lungs. Lymph node metastasis is considered an infrequent event in the natural history of soft tissue sarcomas. The rarity of such lymph node metastasis has made the study of their natural history difficult. Most published series are small, retrospective studies, and as individual studies are hard to interpret. The overall incidence of lymph node metastasis was estimated to be 10%. Lymphatic spread in sarcomas are rare, and that lymphatic spread is more frequently associated with certain histologic types. Those are, rhabdomyosarcomas, epithelioid sarcomas, angiosarcomas, and synovial sarcomas. Bone sarcomas may also present with regional lymph node disease, which carries a very adverse outcome. (Fong et al, 1993)

We discuss the previous reports of neck metastasis and neck dissection of main subtypes of Head and neck sarcoma.

1 Rhabdomyosarcoma, 2 Fibrous tumor (desmoid tumor, fibrosarcoma, dermatofibrosarcoma protuberans), 3 Angiosarcoma 4 Synovial sarcoma, 5 Osteosarcoma, 6 Chondrosarcoma, 7 Ewing's sarcoma.

2. Rhabdomyosarcoma

The rhabdomyosarcoma (RMS), a skeletal muscle subtype, is the most common soft tissue sarcoma in children, comprising about 50% of these tumors. In contrast, adult rhabdomyosarcomas comprise less than 10% of all soft tissue sarcomas. The head and neck are the most common primary sites for RMS in children and teenagers, followed by the genitourinary tract, limbs, thorax, and retroperitoneum. The tumor head and neck subsites include the orbit, parameningeal sites (nasopharynx, nasal cavity, paranasal sinuses, temporal bone, pterygopalatine fossa, and the infratemporal fossa), and non-parameningeal sites. Tumors that invade the orbit only have a better prognosis. (Moretti, 2010)

Subtypes may be histologically classified as: embryonic (which may be subdivided into embryonic, botryoid, and spindle cell tumors), alveolar, or pleomorphic. In children, about 60% are embryonic tumors, 20% are alveolar tumors, 15% are not classified, and 5% are pleomorphic tumors. The embryonic subtype has a better prognosis in children, but is more aggressive in adults. The alveolar subtype has a poor outcome because of its propensity to metastasize at a distance. The pleomorphic subtype occurs predominantly in adults. (World Health Organization Classification of Tumours [WHO] Tumors of Soft Tissue and Bone, 2010)

2.1 Treatment

Prior to the introduction of antineoplastic drugs, surgery played the central role in the cure of patients with RMS; in the last four decades, the development of multi-agent chemotherapy protocols resulted in a significant improvement in long-term survival: from 25% in 1970, to approximately 70% nowadays. In the head and neck area, a distinction is drawn between parameningeal rhabdomyosarcoma (PM-RMS) and RMS of other localizations. RM-RMS arises at sites with a particularly close anatomic relationship with the meninges such as nasopharynx, nasal cavity, paranasal sinuses, middle ear and mastoid, infratemporal and

pterygopalatine fossa. They represent a particular surgical challenge. Surgical excision may lead to unacceptable mutilations and incomplete resection in most cases. These tumours have a high likelihood of meningeal extension, which is considered a fatal pattern of progression. Most authors conclude that multi-agent chemotherapy combined with radiation is the primary treatment modality offered to children with PM-RMS. Surgery prior to chemotherapy is recommended if there is no intracranial extension, if complete resection seems feasible and if it won't lead to unacceptable morbidity. (Gradoni, et al. 2010)

2.2 Lymphatic metastasis and neck dissection

Head and neck RMS has proven able to spread to cervical lymph nodes. Comparing the two most frequent histologic subtypes i.e. embryonal and alveolar, the latter showed a higher tendency to metastasize through the lymphatic route. According to some authors, elective treatment of the neck is not justified. In view of the low incidence of cervical lymph node metastases of merely 3% according to the IRS (Intergroup Rhabdomyosarcoma Study), Rodeberg et al. saw no indication for conducting elective neck dissection (Rodeberg et al.2002). Wurm recommends elective neck dissection in patients with alveolar RMS when surgery on primary tumour is planned (Wurm, 2005). Callender et al. found regional metastasis in 15-38% of their patients respectively and inferred that elective neck dissection offers a benefit (Callender, 1995). Controversy exists also over treating the N+ neck with additional radiotherapy or neck dissection. If nodes are metastatic and complete primary tumour resection is feasible, neck dissection is recommended; while, if the lymph nodes are positive but the primary tumour is unresectable, they should be included in the radiotherapy field.

2.3 Case report

An 22 year-old female, who had been treated for retinoblastoma at six months of age, presented for evaluation of left temporal swelling. She had underwent enucleation of the bilateral eyeball and 40 Gy irradiation to the left orbit at 1 years of age. Examination revealed a firm mass overlying the left temporal muscle (Figure 1) and left cervical

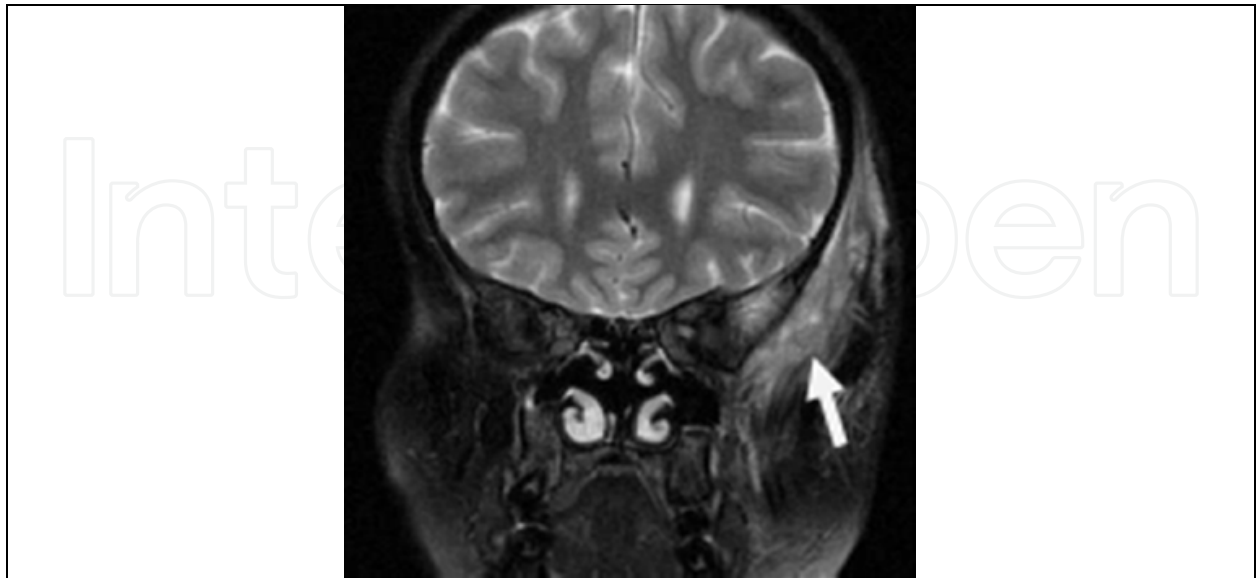

Fig. 1. A 22-year-old female case of Rhabdomyosarcoma, infantile type of the temporal muscle (arrow). She underwent the combination of chemotherapy and radiation 9 years ago, now she was free of disease. (Our experience case)

lymphadenopathy. Biopsy revealed that the tumor was Rhabdomyosarcoma, embryonal type. Metastatic work-up was negative including lumbar puncture, bone scan, and chest CT. The patient received treatment with chemotherapy consisting of vincristine 2 mg/m², actinomycin D 0.5 mg/m², and cyclophosphamide 2.2g/m² (VAC) every 3 weeks for 13 courses. Also she was irradiated 24Gy between 5 courses and 6 courses. She was followed closely after completing chemotherapy. The patient was alive and well with no evidence of disease 80 months after last treatment.

3. Fibrous tumor (Malignant fibrous histiocytoma, Desmoid tumor, and Fibrosarcoma)

Since the late 1970s malignant fibrous histiocytoma (MFH) were the most common soft tissue sarcoma of middle and late adulthood. The existence of “malignant fibrous histiocytoma” as a distinct entity is now considered controversial and at best is regarded as a heterogeneous group of tumors without a specific known line of differentiation. Current nomenclature recognizes the entities undifferentiated high grade pleomorphic sarcoma, and myxofibrosarcoma (Montgomery et al. 2009).

Desmoid tumors, or aggressive deep-seated fibromatosis, are part of a rare group of fibrous tissue proliferations which tend to be locally aggressive but have no propensity for metastasis. Desmoid tumors are uncommon and slow-growing tumors with a propensity for recurrence even after complete resection. The natural history of desmoid tumors is not well-defined and poorly understood. Location of tumors can limit therapeutic options and result in significant morbidity with or without surgical resection. While there is no risk of degeneration from fibromatosis to fibrosarcoma, this is a distinct type of soft tissue sarcoma. Unfortunately, there are also no distinct clinical characteristics of fibrosarcoma, and disease is poorly described in the context of all fibroblastic tumors. Classic fibrosarcomas are seen in persons aged 30–55 years. Fibrosarcomas can be part of the spectrum of radiation-induced or radiation-associated sarcomas, representing about 15% of the histologic subtypes. Treatment options are dictated by location, and surgical resection remains the mainstay of curative therapy. Dermatofibrosarcoma protuberans (DFSP) is a specific form of soft tissue sarcoma which is nearly always considered a low-grade sarcoma. These tumors are prone to recurrence, with high local recurrence rates of up to 60% following resection. Occasionally, DFSP will undergo transformation to classic fibrosarcoma (Wong et al, 2008).

3.1 Treatment

The management of soft tissue sarcomas in the head and neck is primarily surgical. Sarcomas also tend to grow along fascial planes. For these reasons, the surgical resection of sarcomas require a wide resection which respects fascial compartments and includes a generous amount of uninvolved tissue beyond the tumour margins. For most cancer types, a 2.0- to 3.0-cm margin including resection of the underlying fascia is recommended. The critical anatomy of the head and neck limits the capacity to obtain these wide surgical margins. Sarcomas arising in the head and neck have a higher local recurrence rate and a worse disease-specific survival than sarcomas arising at other sites. (Brockstein, 2004)

3.2 Lymphatic metastasis and neck dissection

The incidence of lymph node metastasis of fibrosarcoma was found to be 4.4-5.1 %. It is generally agreed that because of the rarity of lymph node metastasis, elective neck dissection for fibrosarcoma is generally not indicated. (Fong et al, 1993)

3.3 Case report

A 62-year-old male was referred to our hospital for the left neck mass. He had been underwent the removal of the left neck mass and the pathological diagnosis was extra-abdominal desmoid. A MRI showed the high intensity mass of the Gd-enhanced T1 weighted image in the Level III area and infiltrate to the surrounding muscles (figure 2). He was underwent the removal of the tumor, encased by the sternocleidomastoid muscle and deep cervical muscles, with preservation of the internal jugular vein and phenic nerve. He was free of disease after the 3 years.

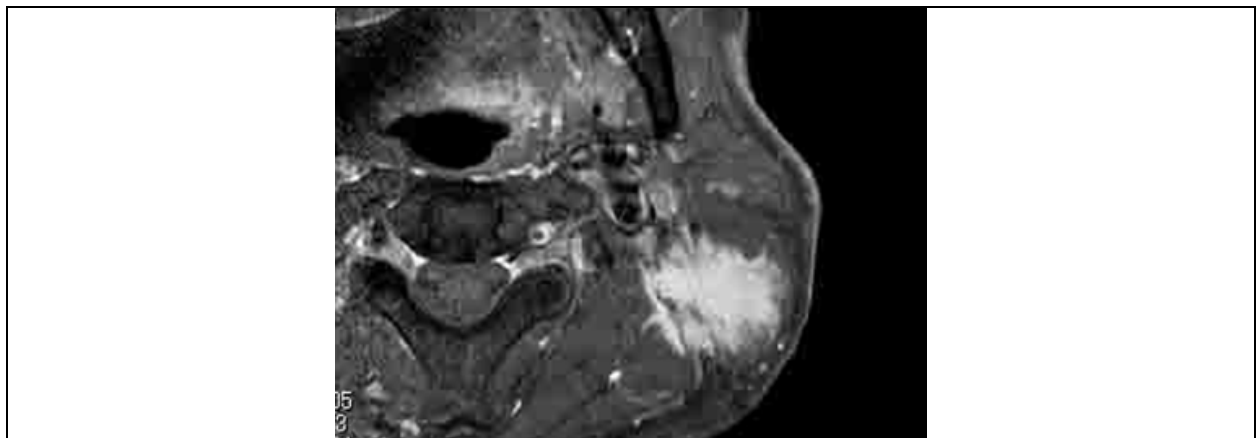


Fig. 2. A 62-year-old male case of desmoid. He underwent the removal encased by the surrounding muscles. After the 3 years operation, now he was free of disease. (Our experience case)

4. Angiosarcoma

Angiosarcomas are a subtype of soft-tissue sarcoma and are aggressive, malignant endothelial-cell tumors of vascular or lymphatic origin (Young et al, 2010). Treatment is challenging in many cases and the prognosis is poor. Angiosarcoma can arise in any soft-tissue structure or viscera and cutaneous angiosarcomas typically involve the head and neck, particularly the scalp (27%). Angiosarcomas are subdivided into cutaneous angiosarcoma, lymphoedema-associated angiosarcoma, radiation-induced angiosarcoma, primary-breast angiosarcoma, and soft-tissue angiosarcoma, and most reports include several angiosarcoma subtypes. There is some evidence that tumor behaviour might depend on site of origin, although whether differences between cutaneous, radiation induced, breast, and visceral angiosarcomas are caused by biological differences or differences in clinical presentation and treatment is unclear.

4.1 Treatment

There are no randomised trials and few prospective studies, most published reports of angiosarcoma treatment are retrospective case series. Treatment has been included in

management guidelines for other soft tissue sarcomas. Radical surgery with complete resection is the primary treatment of choice. Involved margins resection are common because of the invasive and often multifocal nature of angiosarcomas, which confer a worse prognosis. Angiosarcomas have an overall 5 year survival of about 35%. Even with localised disease, the most optimistic survey suggests only 60% of patients survive for more than 5 years, with a median survival of 7 months (Young,2010). However, there are reports of some long-term survivors with metastatic disease, but which prognostic factors are important is unclear.

4.2 Lymphatic metastasis and neck dissection

The incidence of lymph node metastasis of angiosarcoma was found to be 13.5 % (Fong, 2010). Angiosarcoma is particularly prone to nodal metastasis. Prognosis of such metastasis is poor, but certainly not hopeless. Neck dissection is appropriate treatment for isolated metastasis to regional lymph nodes and might provide long-term survival.

5. Synovial sarcoma

Synovial sarcoma is a malignant soft-tissue neoplasm uncommonly found in the head and neck. Although synovial sarcoma is usually found near large joints and bursae of the extremities, it rarely arises from synovial membranes. It accounts for approximately 8% of all soft-tissue sarcomas. Only 10% of all synovial sarcomas occur in the head and neck, and these rarely have an obvious association with synovial structures (Amble et al,1997). Synovial sarcoma were most commonly located in the neck (60%); thus, the most common symptoms were a neck mass and neck pain. Ninety percent of Synovial sarcoma have an identifiable translocation between chromosomes 18 and X that results in the fusion of the SYT gene on chromosome 18 and the SSX-1 or SSX-2 gene on chromosome X (Harb et al, 2007).

5.1 Treatment

As with other soft tissue sarcomas, radical surgery with complete resection is the primary treatment of choice. Unfortunately, up to 50% of Synovial sarcoma recur, usually within 2years. Some 40% metastasis, commonly to lungs and bone and also regional lymph nodes. The best outcome are in childhood patients, in tumors which are <5cm in diameter, have < 10 mitoses/ 10 hpf and no necrosis, and when the tumor is eradicated locally. (Christopher et al, 2010)

5.2 Lymph node metastasis and neck dissection

Although not normally a feature of sarcomas, metastasis to regional lymph nodes occurs in 12.5% of cases of synovial sarcoma in the head and neck and 23% of cases in the extremities (Roth et al, 1975). Neck dissection is appropriate treatment for isolated metastasis to regional lymph nodes and may provide long-term survival.

6. Osteosarcoma

Osteosarcoma is the most common primary malignancy of bone. These tumors typically originate in the extremities and the pelvis, with only 6–10% of patients presenting with a head and neck primary tumor (Russell et al, 2003). The mandible and maxilla are the predominate locations of head and neck osteosarcoma (HNOS), although extragnathic bone

as well as soft tissues sites may be affected. The peak age of incidence for osteosarcoma outside the head and neck is in the adolescent years. In contrast, HNOS most commonly affects patients in their 30s. Distant metastases have been reported in 10–20% of patients with HNOS, compared with 53–75% of patients with disease arising outside the head and neck. The 5-year, disease-specific survival rate for patients with HNOS has been poor, with most studies reporting survival rates of 23–37%. Management of osteosarcoma outside the head and neck prior to the standardized use of chemotherapy resulted in worse 5-year survival rates of 10–20%. It is widely accepted that wide surgical excision is the mainstay of therapy for patients with HNOS. Adjuvant treatment with radiotherapy and/or chemotherapy also has been administered. For patients with osteosarcoma arising outside the head and neck, surgery also is considered a key component in therapy, but the addition of neoadjuvant and/or adjuvant chemotherapy has improved survival markedly. The Multi-Institution Osteosarcoma Study identified an increase in the 6-year, event-free survival rate from 11% with surgery alone to 61% when chemotherapy was given postoperatively.¹³ Over the last 2 decades, the standard therapy for patients with non-head and neck osteosarcoma has evolved to routinely include both neoadjuvant and adjuvant chemotherapy. With these regimens, long-term survival rates of 70–80% are being obtained. Whether these same results can be obtained in patients with HNOS is not yet known.

6.1 Treatment

The mainstay of treatment of head and neck osteosarcoma is surgery. Adjuvant postoperative RT is indicated for those with close or positive margins. The role of adjuvant chemotherapy is unclear.

6.2 Lymph node metastasis and neck dissection

The AJCC (2010) definitions of TNM showed that any regional lymph node metastasis (N1) classified to Stage IVB. It suggested to the extremely poor prognosis in front of the neck metastasis of the osteosarcoma. In rare case, Extraskeletal osteosarcoma was present, That is a high-grade malignant sarcomas defined (1) soft tissue origin and no attachment to the bone or periosteum, (2) a uniform sarcomatous pattern (to exclude the possibility of a mixed malignant mesenchymal tumor), with production of osteoid and/or cartilage matrix. We reported a young patient with highly malignant HNOS, which was excised but was subsequently complicated by local and distant metastases. (Saito et al, 2008)

6.3 Case report

A 17-year-old Japanese man with no history of trauma or irradiation was referred to the hospital with complaints of a swelling in the left side of the neck that had been gradually increasing in size. Physical examination showed a smooth, stony hard, mobile mass measuring 24 x 30 mm in the left submandibular region. A computed tomographic scan (figure 3) showed a calcified mass measuring 23 x 18 mm in size, unattached to the hyoid bone or the mandible. The tumor was mildly adherent to the suprahyoid muscles. It was excised along with surrounding muscle. The surgical margin was free of in the direction of the hyoid bone. Three months after the operation, the patient developed massive local recurrence of the tumor. We removed the tumor encased by the surrounding muscles. Postoperatively, the patient received a course of radiotherapy. However, 4 months after the second operation, he developed left facial nerve palsy and complained of sudden hearing loss on the left side. A CT scan showed

tumor recurrence in the temporal bone, occupying the middle cranial fossa. The patient and his family selected chemotherapy instead of surgery, but 1 month after the start of chemotherapy consisting of Cisplatin 125mg/body and Pirarubicin 60mg/body, the patient developed intracranial hemorrhage and died of hydrocephalus.

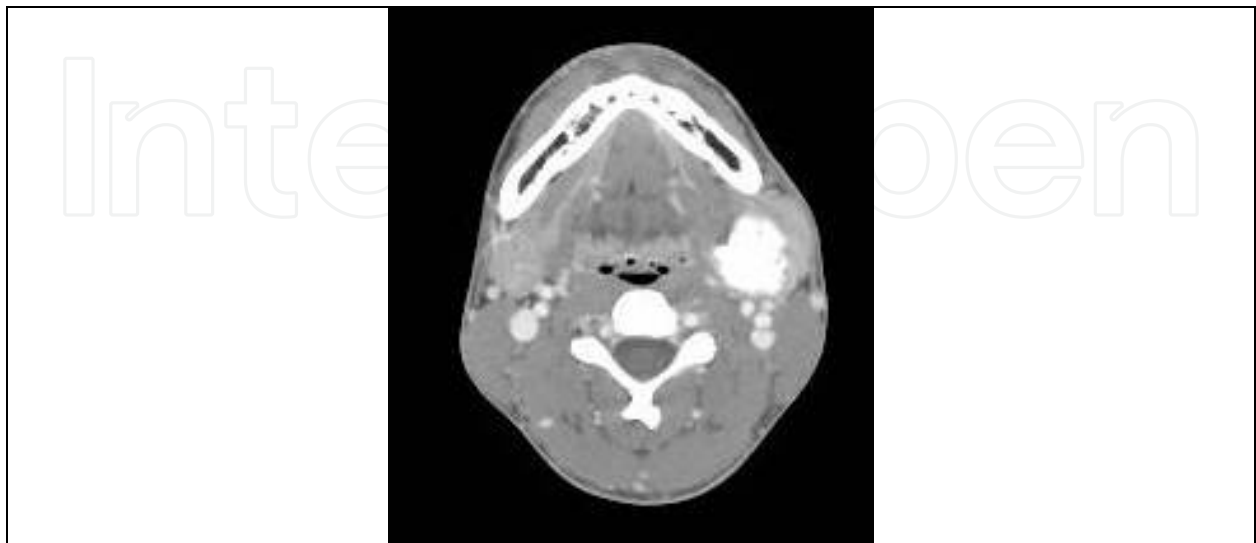


Fig. 3. A case of extracranial osteosarcoma of 17-year-old male. (Our experienced case)

7. Chondrosarcoma

Chondrosarcoma is a malignant tumor in which the tumor cells form chondroid (cartilage) but not osteoid. Although chondrosarcoma most commonly arises from either cartilaginous structures or bone derived from chondroid precursors, chondrosarcoma may also arise in areas where cartilage is not normally found. Skull bones were the predominant tissue (59.7%) arose chondrosarcoma. Among these cases were 7.7% originating in the mandible. laryngotracheal cases were about 23.4% in all cases. The other sites were oral cavity, pharynx, and orbit (Koch et al, 2000).

These tumors developing in soft tissue presumably arise from cartilaginous differentiation of primitive mesenchymal cells. Chondrosarcomas develop more commonly in bone than cartilage. However, a sufficiently large number develop from laryngeal cartilage, so that chondrosarcoma is the most common sarcoma developing in the larynx.

It is noteworthy that more than 90% of laryngotracheal chondrosarcoma cases were low grade and occurred in older patients (>50 years). These associations suggest that laryngotracheal tumors represent a form of chondrosarcoma that should be distinguished from cases arising in osseous sites of the head and neck that are more commonly characterized by a younger age and a higher grade. The recognized difficulty in discriminating between the benign laryngeal chondromatous lesions and low-grade chondrosarcomas confounds the interpretation of tumor behavior at this site. It is possible that the large number of low-grade chondrosarcomas identified within the cartilaginous laryngotracheal site may reflect the inclusion of some benign cases erroneously diagnosed as cancer. Despite ongoing study, a widely accepted approach to analysis of cytogenic or proliferative characteristics has yet to surpass grading as an independent predictor of the biologic behavior of chondrosarcoma (Koch et al,2000).

7.1 Treatment

Head and neck chondrosarcomas are generally slow-growing tumors with an indolent course. Yet, owing to the locally aggressive nature and the propensity to recur if not adequately treated, most studies recommend wide en bloc surgical resection as the mainstay of treatment. Conservative resection of low-grade lesions of the larynx has been proven effective in several reports. Organ preservation may be achieved with such an approach, which has important functional outcome implications (Hong et al, 2009).

7.2 Lymph node metastasis and neck dissection

In the largest series to date representing 151 cases of chondrosarcoma of the head and neck, Weiss and Bennett noted that "metastasis is not common and generally occurs late in the disease, usually after multiple surgical manipulations." (Weiss & Bennett, 1986) Mark et al stated that "only 1/18 (5%) patients recurred in regional lymph nodes without elective neck treatment, further justifying the accepted approach of not electively treating the neck in head and neck sarcomas." (Mark et al, 1993)

7.3 Case report

A 55-year-old female was referred to us in 2003 because of a 2-years history of hoarseness. She also complained about having dyspnea and had underwent tracheostomy. Direct laryngoscopy revealed a smooth, firm subglottic mass at the subglottis. The CT scan showed a mass that had eroded almost half of the left cricoid cartilage (Figure 4), and the biopsy revealed chondroma. An excision of the tumor and 4/5 cricoid cartilage was resected. A tracheofissure was done at the end of the operation to put a stent T tube in place. Histopathologic examination of the surgical specimen confirmed a grade I chondrosarcoma. 27 months later, direct laryngoscopy was done with no evidence of recurrence. After all, we reconstructed the anterior wall of trachea by the costal cartilage. Up until now, the patient has been followed up regularly. In May 2011, 8 years after surgery, she was in perfect health except for a paralysis of the left vocal cord.

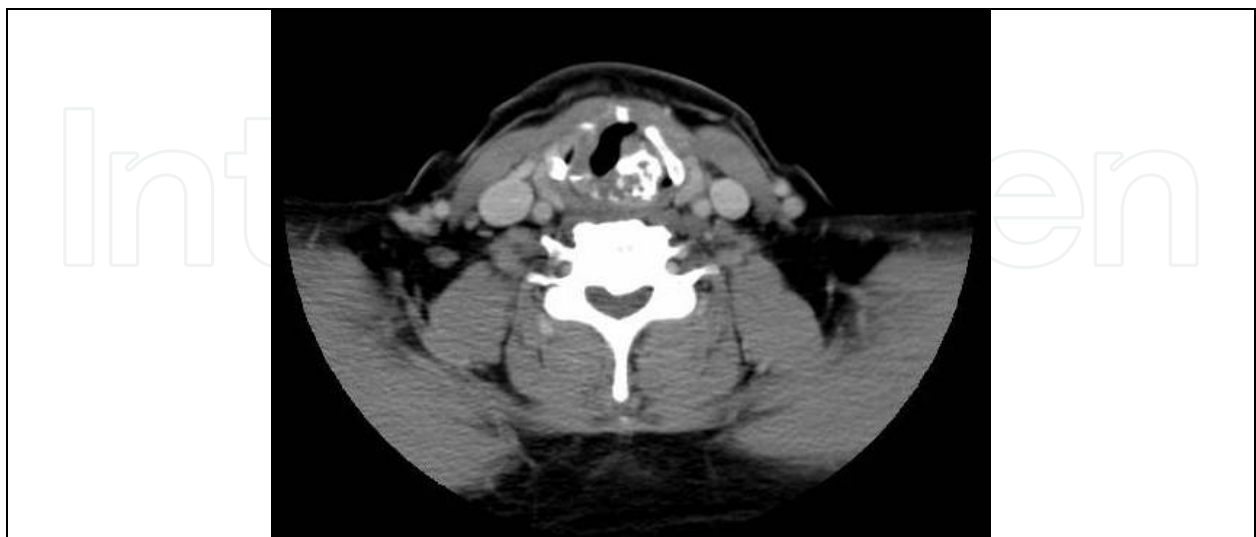

Fig. 4. A case of laryngeal chondrosarcoma of 40-year-old female. She was underwent operation with laryngeal preservation 9 years ago. Now she was free of disease with laryngeal function. (Our experienced case)

8. Ewing's sarcoma

Ewing's sarcoma arising in the head and neck region is extremely rare, comprising 1-4% of all cases of Ewing's sarcoma. Most authors claim a better prognosis for Ewing's sarcoma of the head and neck region as compared to that arising in other anatomic locations. The most commonly affected bones in the head and neck region are the skull, the mandible and the maxilla. There has also been case reports of localized Ewing's sarcoma affecting the orbital roof, the retropharynx and the nasal cavity (Allam et al, 1999).

8.1 Treatment

Surgery after chemotherapy is the current standard of cure. Despite the lack of randomized trials comparing different local treatment modalities in Ewing' Sarcoma, wide surgical resection is considered the treatment of choice. It reduces the local relapse rate, improves the overall survival and may avoid radiotherapy. Ludwig affirms that chemotherapy alone is an ineffective measure in achieving local control of disease (Ludwig, 2008). Thus, it is commonly accepted that an attempt at complete tumour resection should always be made. Nevertheless chemoradiation may be a reasonable alternative to surgery for treatment of tumours that are resectable only with an unacceptable degree of mutilation.

8.2 Lymph node metastasis and neck dissection

Lymphnodes metastasis from Ewing's sarcoma are very rare. The nodal status included as a prognostic indicator in the American Joint Committee on Cancer (AJCC) staging system has even been considered irrelevant by some authors. Considering this, it can be argued that elective neck dissection is not indicated. Nevertheless, as best as we could determine, this argument is not discussed in the literature.

9. Conclusion

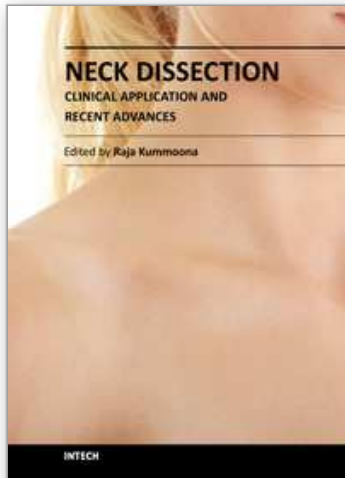
Head and neck sarcomas are rare tumors and represent a heterogeneous group of tumours of different histological variants. Subtyping of sarcomas is increasingly important because of the development of biologic response modifiers. Although traditional morphological assessment is the foundation of clinical decision making, immunohistochemistry and molecular biology are useful for diagnosis, prognosis and identification of possible targets for molecular therapy. The management of sarcomas in the head and neck is primarily surgical. Since, in head and neck sarcomas it is difficult to obtain wide margins during surgical treatment, because of anatomic constraints, most patients with locally resectable tumours undergo post-operative irradiation. Modern reconstructive surgery makes more extensively resection possible and may improve local tumour control, while providing acceptable cosmetic and functional results. Adjuvant systemic chemotherapy seems to improve outcome, but its benefit must be weighted against associated toxicities. Survival of patients with head and neck soft tissue sarcoma varies from 50 to 80% and depends on prognostic factors as tumour grade, margin status and tumour size. With further insight into the biology of soft tissue sarcoma and the combination of new treatment options with modern imaging techniques, we will most certainly be able to improve clinical outcome in patients with soft tissue sarcoma in the upcoming years.

10. References

- Allam A, El-Husseiny G, Khafaga Y, Kandil A, Gray A, Ezzat A, Schultz H. (1999) Ewing's Sarcoma of the Head and Neck: A Retrospective Analysis of 24 Cases. *Sarcoma*. 3(1):pp.11-5.
- Amble FR, Olsen KD, Nascimento AG, Foote RL (1992). Head and neck synovial cell sarcoma. *Otolaryngol Head Neck Surg*. 107(5),Nov,pp.631-7.
- Brockstein B (2004). Management of sarcomas of the head and neck. *Curr Oncol Rep*. 6(4),Jul,pp321-327
- Callender TA, Weber RS, Janjan N, Benjamin R, Zaher M, Wolf P, el-Naggar A (1995). Rhabdomyosarcoma of the nose and paranasal sinuses in adults and children. *Otolaryngol Head Neck Surg*. 112(2),Feb,pp.252-257.
- Costa MJ, Campman SC, Davis RL, Howell LP (1996). Fine-needle aspiration cytology of sarcoma: retrospective review of diagnostic utility and specificity. *Diagn Cytopathol*. 15(1),Jul,pp23-32.
- Christopher D.M.Fletcher, K.Krishnan Unni, Fredrik Mertens (2010). *World Health Organization Classification of Tumours. Pathology & Genetics Tumours of Soft Tissue and Bone*. 6 Skeletal muscle tumours pp.127-134,IARC
- Christopher D.M.Fletcher, K.Krishnan Unni, Fredrik Mertens (2010). *World Health Organization Classification of Tumours. Pathology & Genetics Tumours of Soft Tissue and Bone*. 9 Tumours of uncertain differentiation pp.200-204,IARC
- de Bree R, van der Waal I, de Bree E, Leemans CR (2010). Management of adult soft tissue sarcomas of the head and neck. *Oral Oncol*. 46(11),Nov,pp.786-90
- Fong Y, Coit DG, Woodruff JM, Brennan MF (1993). Lymph node metastasis from soft tissue sarcoma in adults. Analysis of data from a prospective database of 1772 sarcoma patients. *Ann Surg*. 217(1),Apr,pp.72-77.
- Fyrmpas G, Wurm J, Athanassiadou F, Papageorgiou T, Beck JD, Iro H, Constantinidis J. (2009) Management of paediatric sinonasal rhabdomyosarcoma. *J Laryngol Otol*. 123(9),Sep,pp.990-6.
- Gradoni P, Giordano D, Oretti G, Fantoni M, Ferri T (2010). The role of surgery in children with head and neck rhabdomyosarcoma and Ewing's sarcoma. *Surg Oncol*. 19(4),Dec,pp.e103-9.
- Harb WJ, Luna MA, Patel SR, Ballo MT, Roberts DB, Sturgis EM (2007). Survival in patients with synovial sarcoma of the head and neck: association with tumor location, size, and extension. *Head Neck*. 29(8),Aug,pp.731-40.
- Hong P, Taylor SM, Trites JR, Bullock M, Nasser JG, Hart RD (2009). Chondrosarcoma of the head and neck: report of 11 cases and literature review. *J Otolaryngol Head Neck Surg*. 38(2),Apr,pp.279-85
- Jones C, Liu K, Hirschowitz S, Klipfel N, Layfield LJ (2002). Concordance of histopathologic and cytologic grading in musculoskeletal sarcomas: can grades obtained from analysis of the fine-needle aspirates serve as the basis for therapeutic decisions? *Cancer*. 96(2),Apr,pp83-91.
- Koch BB, Karnell LH, Hoffman HT, Apostolakis LW, Robinson RA, Zhen W, Menck HR (2000). National cancer database report on chondrosarcoma of the head and neck. *Head Neck*. 22(4),Jul,pp.408-25.
- Ludwig JA (2008). Ewing sarcoma: historical perspectives, current state-of-the-art, and opportunities for targeted therapy in the future. *Curr Opin Oncol*. 20(4),Jul,pp.412-8.

- Mark RJ, Tran LM, Sercarz J, Fu YS, Calcaterra TC, Parker RG(1993). Chondrosarcoma of the head and neck. The UCLA experience, 1955-1988. *Am J Clin Oncol.* 16(3),Jun,pp.232-7.
- Montgomery PQ, Peter H.Rhys Evans, Patrick J.Gullane (2009). *Principles and Practice of Head and Neck Surgery and Oncology*.Second Edition. Sarcomas of Head and Neck. ,pp.455-479,Informa healthcare
- Moretti G, Guimarães R, Oliveira KM, Sanjar F, Voegels RL(2010). Rhabdomyosarcoma of the head and neck: 24 cases and literature review. *Braz J Otorhinolaryngol.* 76(4),Aug,pp.533-7
- Schalow EL, Broecker BH(2003). Role of surgery in children with rhabdomyosarcoma. *Med Pediatr Oncol.* 41(1),Jul,pp.1-6
- Rodeberg DA, Paidas CN, Lobe TL, Brown K, Andrassy RJ, Crist WM, Wiener ES. (2002). Surgical Principles for Children/Adolescents With Newly Diagnosed Rhabdomyosarcoma: A Report from the Soft Tissue Sarcoma Committee of the Children's Oncology Group. *Sarcoma*,6(4),pp.111-22.
- Roth JA, Enzinger FM, Tannenbaum M(1975). Synovial sarcoma of the neck: a followup study of 24 cases. *Cancer.* 35(4),Apr,pp.1243-53.
- Saito Y, Miyajima C, Nakao K, Asakage T, Sugasawa M(2008). Highly malignant submandibular extraskelatal osteosarcoma in a young patient. *Auris Nasus Larynx.* 35(4),Dec,pp.576-8.
- Smith RB, Apostolakis LW, Karnell LH, Koch BB, Robinson RA, Zhen W, Menck HR, Hoffman HT(2003). National Cancer Data Base report on osteosarcoma of the head and neck. *Cancer.* 98(8),Oct,pp.1670-80.
- Weiss WW Jr, Bennett JA(1986). Chondrosarcoma: a rare tumor of the jaws. *J Oral Maxillofac Surg.* 44(1),Jan,pp.73-9.
- Wong SL(2008). Diagnosis and management of desmoid tumors and fibrosarcoma. *J Surg Oncol.*97(6),May,pp.554-8.
- Wurm J, Constantinidis J, Grabenbauer GG, Iro H(2005). Rhabdomyosarcomas of the nose and paranasal sinuses: treatment results in 15 cases. *Otolaryngol Head Neck Surg.* 133(1), Jul,pp.42-50.
- Young RJ, Brown NJ, Reed MW, Hughes D, Woll PJ(2010). Angiosarcoma. *Lancet Oncol.* 11(10), Oct,pp.983-91.

IntechOpen



Neck Dissection - Clinical Application and Recent Advances

Edited by Prof. Raja Kummoona

ISBN 978-953-51-0104-8

Hard cover, 164 pages

Publisher InTech

Published online 22, February, 2012

Published in print edition February, 2012

Neck Dissection - Clinical Application and Recent Advances is a leading book in neck surgery and represents the recent work and experiences of a number of top international scientists. The book covers all techniques of neck dissection and the most recent advances in neck dissection by advocating better access to all techniques of neck dissection; e.g. Robotic surgery (de Venice) system, a technique for detection of lymph node metastasis by ultra sonography and CT scan, and a technique of therapeutic selective neck dissection in multidisciplinary treatment. This book is essential to any surgeon specializing or practicing neck surgery, including Head Neck Surgeons, Maxillofacial Surgeons, ENT Surgeons, Plastic and Reconstructive Surgeons, Craniofacial Surgeons and also to all postgraduate Medical & Dental candidates in the field.

How to reference

In order to correctly reference this scholarly work, feel free to copy and paste the following:

Yuki Saito and Takahiro Asakage (2012). Neck Dissection of the Head and Neck Sarcoma, Neck Dissection - Clinical Application and Recent Advances, Prof. Raja Kummoona (Ed.), ISBN: 978-953-51-0104-8, InTech, Available from: <http://www.intechopen.com/books/neck-dissection-clinical-application-and-recent-advances/neck-dissection-of-the-head-and-neck-sarcoma>

INTECH
open science | open minds

InTech Europe

University Campus STeP Ri
Slavka Krautzeka 83/A
51000 Rijeka, Croatia
Phone: +385 (51) 770 447
Fax: +385 (51) 686 166
www.intechopen.com

InTech China

Unit 405, Office Block, Hotel Equatorial Shanghai
No.65, Yan An Road (West), Shanghai, 200040, China
中国上海市延安西路65号上海国际贵都大饭店办公楼405单元
Phone: +86-21-62489820
Fax: +86-21-62489821

© 2012 The Author(s). Licensee IntechOpen. This is an open access article distributed under the terms of the [Creative Commons Attribution 3.0 License](#), which permits unrestricted use, distribution, and reproduction in any medium, provided the original work is properly cited.

IntechOpen

IntechOpen