

# We are IntechOpen, the world's leading publisher of Open Access books Built by scientists, for scientists

**4,800**

Open access books available

**122,000**

International authors and editors

**135M**

Downloads

Our authors are among the

**154**

Countries delivered to

**TOP 1%**

most cited scientists

**12.2%**

Contributors from top 500 universities



**WEB OF SCIENCE™**

Selection of our books indexed in the Book Citation Index  
in Web of Science™ Core Collection (BKCI)

Interested in publishing with us?  
Contact [book.department@intechopen.com](mailto:book.department@intechopen.com)

Numbers displayed above are based on latest data collected.

For more information visit [www.intechopen.com](http://www.intechopen.com)



# A Brief History of Cervical Lymphadenectomy

Jeremiah C. Tracy  
Tufts Medical Center,  
Department of Otolaryngology – Head and Neck Surgery  
USA

## 1. Introduction

Head and neck cancer is an aggressive disease with substantial morbidity associated with local invasion and regional lymphatic spread. Local spread through lymphatic channels is the most common course of disease progression; and nodal disease is often regarded as the most important prognostic factor in malignancy of the head and neck. [Ferlito 2006, Shah] It has been estimated that the presence of lymphatic metastases indicates a 50% decrease in survival; with contralateral nodal disease indicating another 50% decrease. [Leemans 1993, 1994]

Neck dissection describes a procedure involving the en bloc removal of some or all of the lymphatic organs of the head and neck. In current practice the procedure is often performed simultaneously with resection of a primary tumor of the head and neck. The scope of the resection is quite variable and, throughout history, has been a source of some debate. In 1988 the American Head and Neck Society formed a task group to synthesize a standard nomenclature regarding neck dissection, their recommendations have gained near universal acceptance throughout North America and internationally as well. [Robbins 1991, 2002, 2008]

Currently the American Head and Neck Society classifies cervical lymphadenectomy into 4 categories:

1. Radical neck dissection
2. Modified radical neck dissection
3. Selective neck dissection
4. Extended neck dissection

A radical neck dissection is defined as en bloc excision of lymph node levels I-V (Figure 1) along with the internal jugular vein (IJV), sternocleidomastoid muscle (SCM), and spinal accessory nerve (SAN). A modified radical neck dissection also involves the complete removal of levels I-V but with sparing of one or more of the nonlymphatic structures (IJV, SCM, SAN). A selective neck dissection is defined as a procedure that removes anything other than levels I-V. The nomenclature of selective neck dissection assumes that IJV, SCM, and SAN are all preserved unless otherwise noted. The specific levels removed are listed in parentheses (ie. SND [I-III]). Finally, an extended neck dissection is any procedure that removes additional structures beyond those involved in a radical neck dissection, for example superior mediastinal lymph nodes, or the external carotid artery. Very complete and specific recommendations regarding classification and terminology are clearly laid out in publications by Robbins et al. [Robbins 1991, 2002, 2008]

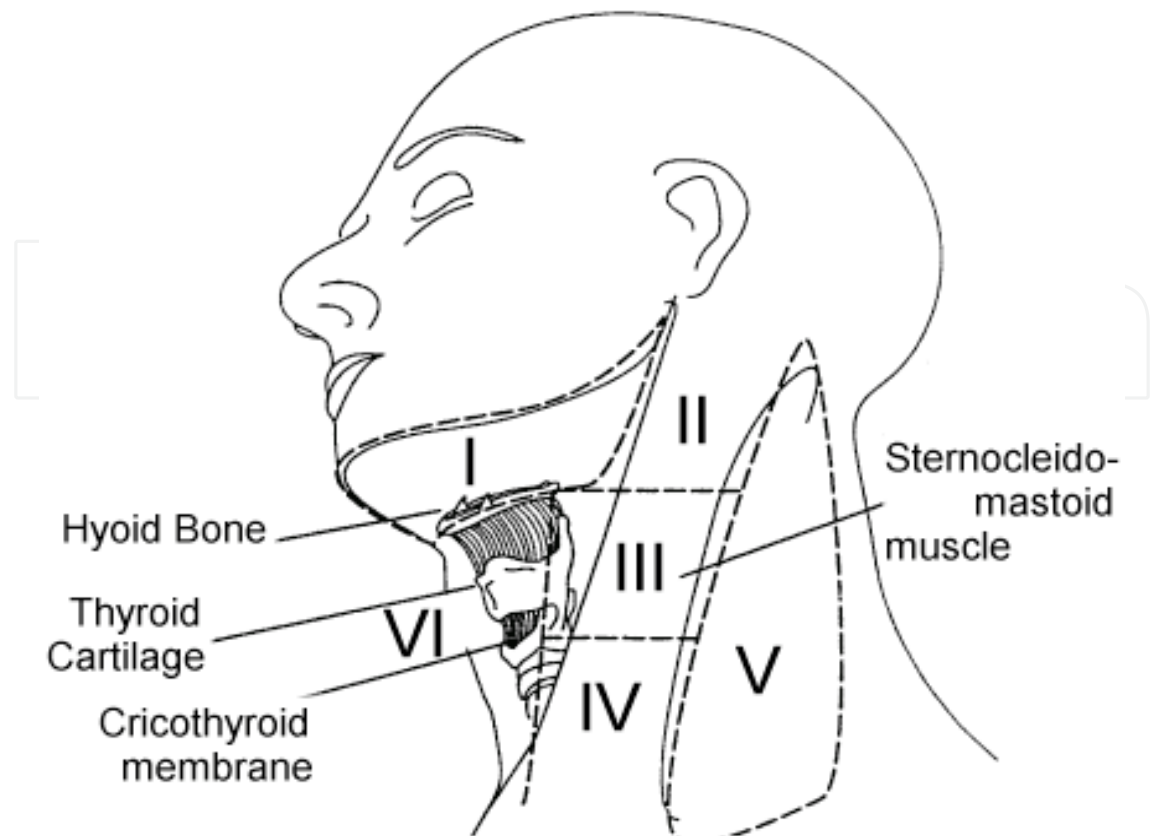


Fig. 1. Lymph node levels of the neck, as first defined and applied by the Memorial Hospital head and neck service. [website]

There is still no strict consensus regarding the indications for each type of procedure, however some broad guidelines do exist. Generally speaking, radical neck dissection is recommended in the management of recurrent disease or disease that grossly involves associated non-lymphatic structures. Modified radical neck dissection has become the standard treatment of clinically apparent neck disease. Selective neck dissection is generally used when elective neck dissection is performed, that is, treatment of patients with no clinical evidence of neck disease but a primary tumor that is high risk for lymphatic spread. Recent studies have supported the application of selective neck dissection in treating clinically apparent disease as well. [Robbins 2004, 2005]

Squamous cell carcinoma accounts for more than 85% of malignancy of the upper aerodigestive tract. Neck dissection is most frequently performed as a treatment for squamous cell carcinoma, however it is also utilized in most other types of head and neck malignancy. Aside from squamous cell carcinoma, neck dissection is often employed in the management of thyroid, cutaneous, and salivary malignancy.

## 2. Early history

The importance of cervical lymphatic disease has been recognized for well over one hundred years. Indeed, many surgeons of the 19<sup>th</sup> century regarded neck disease in mucosal cancers as an indication of incurability. Surgical treatment of malignant tumors of the neck have been described as far back as the early 1800's, generally with significant patient mortality associated. [Rinaldo 2008, Folz 2007, 2008]. Maximilian von Chelius famously

stated “once the growth in the mouth has spread to the submaxillary gland, complete removal of the disease is impossible.” [Chelius 1847] In order to treat lymphatic metastases, physicians and scientists had first to realize a modern paradigm of medicine.

Prior to the 18<sup>th</sup> century, western medicine was dominated by the humoral theory of disease. A lack of understanding of the nature of malignant disease and its spread through lymphatic channels would certainly make the principles of modern neck dissection elusive. Humoralism is a theory of medicine often attributed to Hippocrates, although it probably had its roots in older civilizations of Egypt or Assyria. The basis of humoralism is that there are four essential humors of the human body: blood, phlegm, black bile, and yellow bile. Disease is the imbalance of these humors and treatments aimed at restoring balance by medication or by letting of one or more of the humors.[Sudhoff] This philosophy was embraced by Galen and other scientists of western medicine until the 15<sup>th</sup> and 16<sup>th</sup> centuries. (Figure 2) During this time dissections and experiments by Andreus Vesalius, William




Fig. 2. Portrait of Andreas Vesalius; reproduced from *De Humani Corporis Fabrica*, Volume 1. Vesalius' contributions in the field of anatomy led Renaissance scientists to reconsider many fundamental principles of the earlier Hippocratic medicine. [Vesalius]

Harvey, and other greats of the scientific revolution began to shed doubt on many of the essential principles of Hippocratic medicine. [Folz 2008, Harvey, Shapin] Advances in science and technology ultimately led to Virchow's proposal of "cell theory" at the turn of the 19<sup>th</sup> century. [Virchow] Modern biology has been built upon the principles of cell theory. The mid 19<sup>th</sup> century also saw two great leaps forward in the progress of surgery. In 1846 John Collins Warren performed a neck mass excision at Massachusetts General Hospital under general anesthesia using ether (Figure 3). This well-publicized event marks the birth of modern general anesthesia, which has allowed longer more extensive surgeries, more delicate dissection and hemodynamic control; not to mention the benefit to patient comfort. [Folz 2007, Major] The second well-documented surgical development of the era was Joseph Lister's proposal that infection is caused by spread of microorganisms. He demonstrated that by maintaining sterile technique using antiseptics like phenol and carbolic acid; one could drastically reduce the rate of surgical site infections. [Lister]



Fig. 3. John Collins Warren performs the first neck surgery on a patient under general anesthesia at Massachusetts General Hospital 1846. "The First Operation Under Ether" oil painting by John Cutler Hinckley.

The 1800's also, and not coincidentally, mark the same era in which head and neck oncology was first accurately recognized and described. That is, the recognition that neck disease represents lymphatic spread from primary malignancy of the upper aerodigestive tract. It was in the late 1800's that the first modern descriptions of neck dissection are documented. When and who performed the first neck dissection is a subject of some controversy [Ferlito 2007, Towpik 1990] Rinaldo recently documented the early history of neck dissection well in a paper that highlighted early attempts at en bloc cervical lymphadenectomy by what he termed "the four giants of 19<sup>th</sup> century surgery" (Kocher, Billroth, von Langenbeck, and von Volkmann). These publications generally described removal of malignant neck masses, with or without an associated primary tumor. They represent single cases or small case series, and they generally describe tumor excision rather than a planned resection of cervical lymphatics. In this era of neck dissection, outcomes were quite poor. [Rinaldo 2007, Kocher 1880, Langenbeck 1875]

One candidate for first neck dissection was described in an 1880 publication by Emil Theodor Kocher. [Kocher] Kocher described his now well-known "y-shaped" incision in order to remove upper neck lymphatics en bloc with the submandibular gland and oral cavity primary tumors. Kocher advocated for the systematic removal of the submandibular gland and associated lymph nodes in addition to the primary site when performing floor of mouth and tongue resections through a transcervical approach. This is distinct from earlier publications by Warren and von Langenbeck that were aimed at simply removing a discrete neck tumor. [Warren 1837, Langenbeck 1875]

The eponym "Kocher incision" (Figure 4) to describe this approach to oral cancer was first coined by Henry T. Butlin, who has been called "the father of British head and neck surgery." [Uttley 2000] In a landmark publication, Butlin presented a case series on the surgical management of tongue cancer. [Butlin 1885] In this paper he demonstrated that patients who underwent resection of submandibular lymph nodes (regardless of lymphatic spread at the time of operation) had better recurrence and survival outcomes than those that

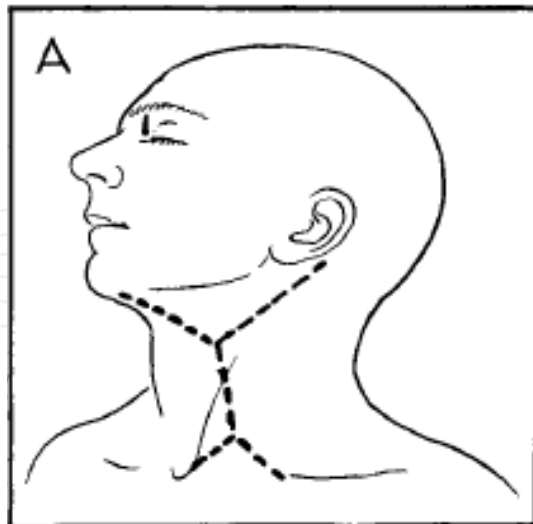


Fig. 4. The Kocher incision describes a y-shaped incision with the long arm running along the anterior border of the SCM, extending from the mastoid tip to the clavicle; and the short arm extending anteriorly to allow full exposure of the submandibular triangle. Above, the Martin modification maintains obtuse-angled skin flaps for better perfusion at the flap tips, also a second inferior "y" to allow greater supraclavicular exposure.

did not. In the paper he strongly advocated for “prophylactic” (what today would be described as elective) resection of submandibular lymph nodes in all cases of tongue cancer. This likely was the start of one of the great questions that still persists in modern head and neck oncology: when to treat the clinically negative neck.

Most recent publications recognize Jawdyski of Poland as the first to perform a radical neck dissection. In 1888 he published the report of cervical lymphadenectomy involving all lymphatics from the mandible to the sternum as well as the internal jugular vein, sternocleidomastoid, and spinal accessory nerve. This case also involved ligation of the common carotid artery as the tumor was invading this structure. The procedure described is indeed quite similar if not identical to a current radical neck dissection. Unfortunately Jawdyski published few other works. His career was cut short when he died of infection at the young age of 45. [Towpik 1990]

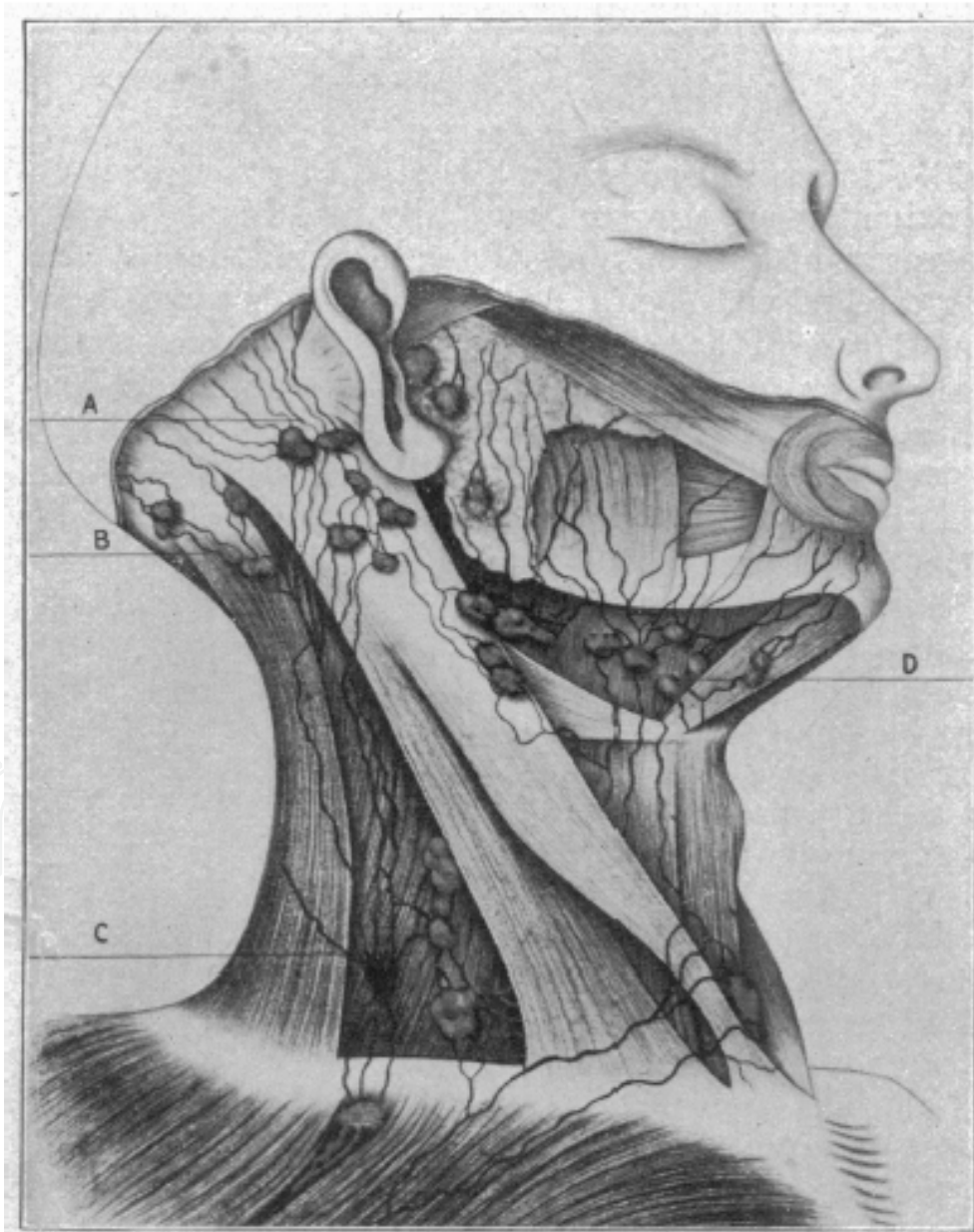
### 3. The early 20<sup>th</sup> century

At the beginning of the 20<sup>th</sup> century George Crile of the United States published a series of cases of “cervical lymphadenectomy,” performed to manage lymphatic spread of head and neck malignancies. The data was first presented in the 1905 annual Transactions of the Southern Surgical and Gynecologic Society. Later, it received national (and international) attention after being published in the Journal of the American Medical Association in 1906. [Crile 1905,1906] The paper reported a series of 132 cases. It included illustrations and a detailed description of the procedure (Figure 5). Subsequently the eponym “Crile procedure” was attached to cervical lymphadenectomy in the United States for several decades. The paper demonstrates a thorough understanding of cervical lymphatic spread, with the basic surgical principles based largely on Halsted’s work in the field of breast surgery.

Crile’s paper included a thoughtful discussion of the management of head and neck lymphatic disease, advocating for en bloc excision of all superficial lymphatic’s of the neck in cases of clinical disease. Although credited with inventing the radical neck dissection, Crile proposed more limited lymphadenectomy in cases of clinically negative lymph nodes, or when non-lymphatic structures were not clearly involved in the surgical specimen. The data presented supports improved outcomes in terms of both recurrence and survival in patients who underwent radical neck dissection vs selective neck dissection (of course modern terminology was not used). In the subgroup with clinically positive neck disease and at least 3-year follow up, Crile observed an 18% (9/48) vs 75% (9/12) survival rate in those that underwent selective versus radical neck dissection. [Crile 1906]

Aside from the controversy regarding whether or not Crile is truly to be credited with performing the first neck dissection, the importance of this paper is agreed upon. At the time of its publication, Crile’s was the largest series available on the subject of neck dissection. Further, Crile included a discussion of the question of elective neck dissection. Crile was generally in favor of elective treatment, citing the previous work of Butlin (although Crile’s data did not address the issue directly). Most importantly, Crile’s paper included an analysis that indicated improved outcomes when neck dissection was performed as a complete en bloc cervical lymphadenectomy, rather than removing only grossly diseased nodes. Simply put, Crile recognized that treatment of malignant neck disease must involve complete cervical lymphadenectomy rather than simply excising those cervical lymph nodes that were grossly diseased. He further provided data in a relatively

large case series supporting this claim. In this way Crile proposed the first standardized treatment algorithm in the management of lymphatic metastases of the head and neck. Based largely on Crile's observations, the 20<sup>th</sup> century was characterized by a movement towards more aggressive management of clinical lymphatic disease. Blair and Brown demonstrated an increasingly intricate understanding of the disease process and discussed a large series of cases. Their paper was the first to report a standardized application of radiation therapy in treating cervical nodal disease, although the role of radiation at that time was exclusively one of salvage therapy. Their 1933 publication gave quite detailed descriptions of the surgical techniques, as well as indications and contraindications (Figure 6). The authors also outlined criteria for "unresectability" that were surprisingly similar to those employed today.





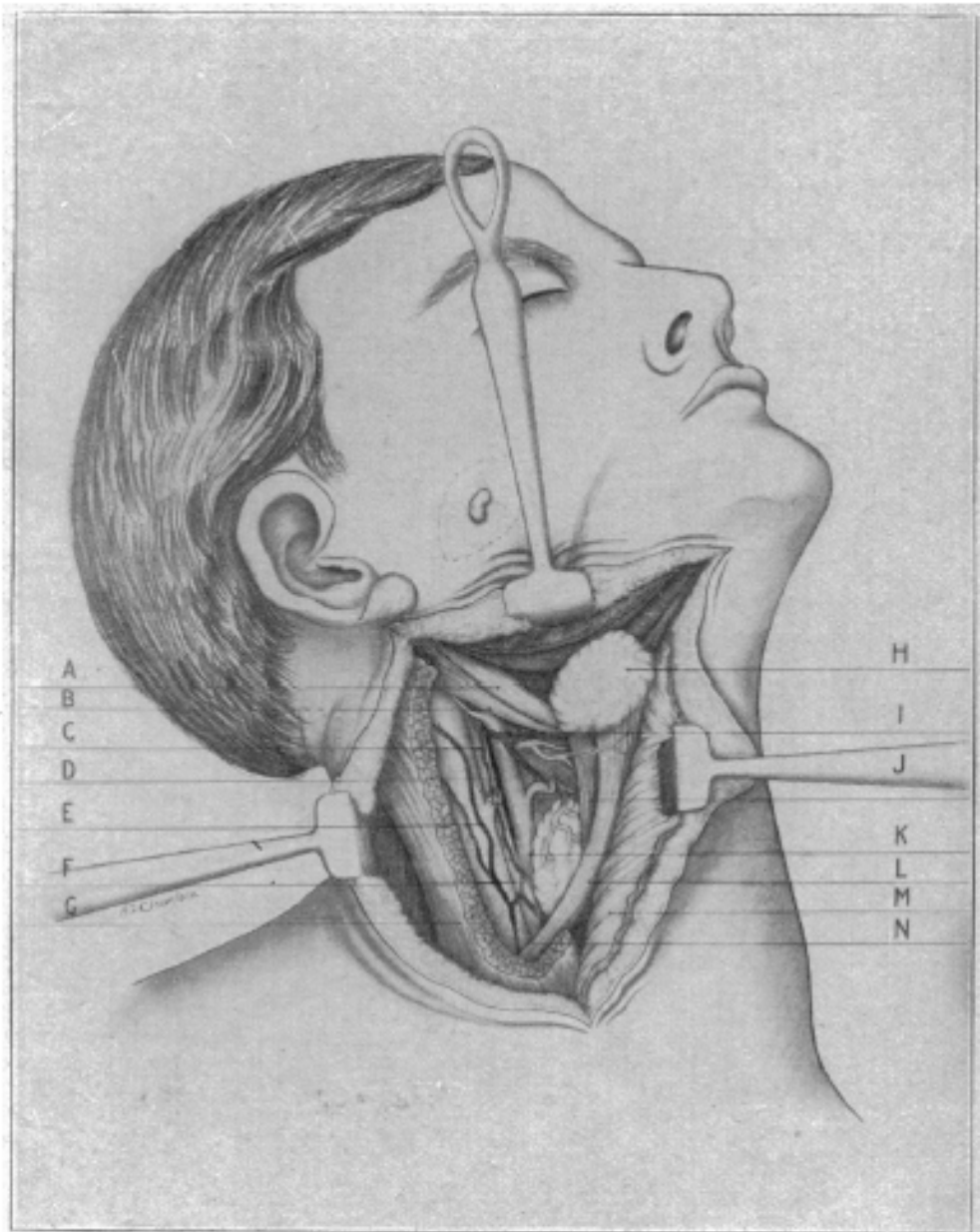


Fig. 5. A. Superficial lymph nodes of the neck by George Crile. B. Diagram of a neck dissection performed on a patient with a cutaneous malignancy.

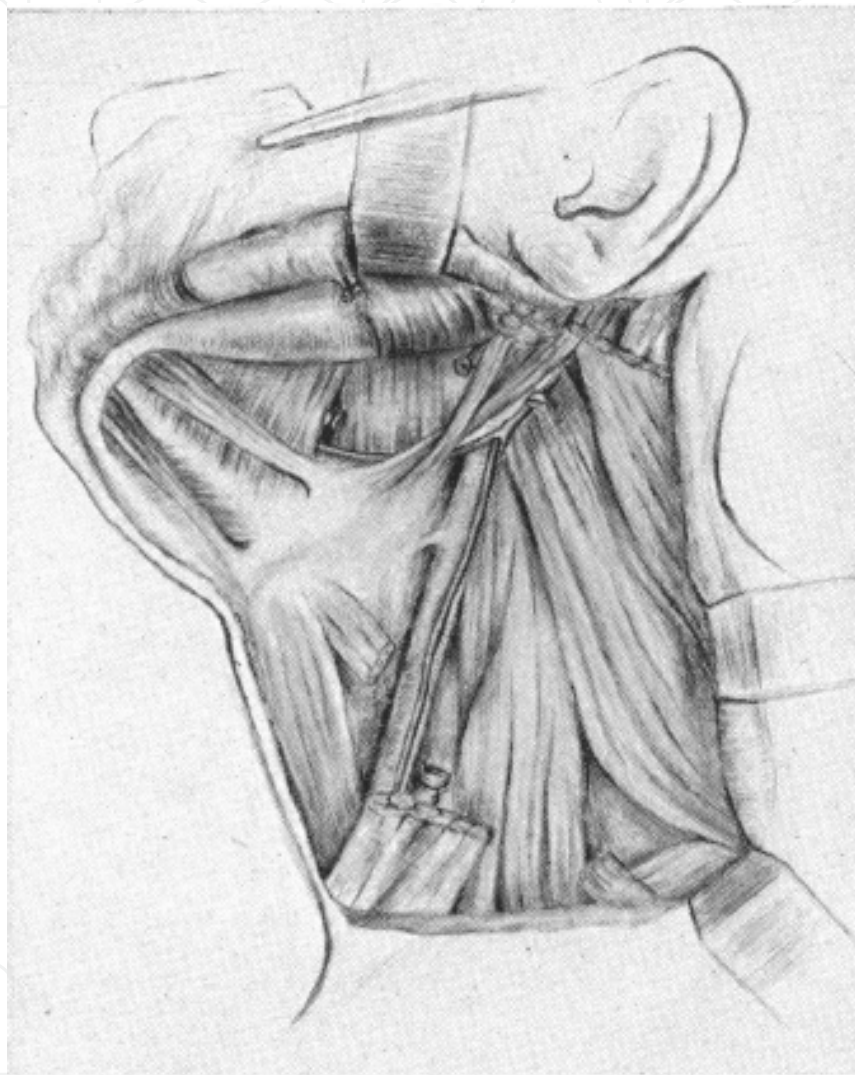


Fig. 6. Surgical field after neck dissection from Blair and Brown. Note a radical neck dissection with removal of SAN, SCM, IJV, and submandibular gland has been performed.

#### 4. Controversy regarding technique and application

In 1951 Hayes Martin published his landmark paper, reporting on 1450 Cases performed at Memorial Hospital in New York over a 22 year period. Martin argued unequivocally for radical neck dissection in all cases of nodal disease: "In our opinion the partial operation should never be used." Regarding preservation of the spinal accessory nerve: "After repeated observations of the surgical anatomy of this nerve in relation to the upper portion of the internal jugular chain of lymphatic's, we are unalterably opposed to any attempt to preserve the nerve itself." The paper did not address recurrence rates between radical versus modified or selective neck dissections as it was practice at Memorial Hospital to perform radical neck dissection on all patients with clinical neck disease (Figure 7). The data presented demonstrated a much lower peri-operative mortality rate than previous publications: 1-2%. However it supported the previously documented high mortality associated with head and neck cancer in general, citing that 50% of the 334 patients who underwent isolated neck dissection were dead of disease at 5 years. [Martin 1951]

Martin's paper included publication of data from a survey that was sent to head and neck surgeons regarding opinions on the indications for elective neck dissection. Ultimately the data reflected extreme variation between surgeons. Martin concluded that his data generally support a role for elective surgery for primary tongue cancer, with more dubious indications in cases of laryngeal disease. Ultimately, however, this publication left the role of elective neck dissection unsettled.

The question of staged versus simultaneous radical neck dissection was also addressed. Earlier authors (including Crile cited above) noted high risk of increased intracranial pressure in patients undergoing bilateral internal jugular vein ligation simultaneously. [Sugarbaker, Crile] Martin's series included 66 patients who underwent simultaneous bilateral neck dissection, none of whom suffered peri-operative mortality. The recommendation based on this series was that neck dissections be staged by 3 weeks if disease permits, however if excision of the primary site requires exposure of both sides of the neck then neck dissection was performed simultaneously.

The direct language used in Martin's paper regarding radical versus partial neck dissection reflected a great controversy in the field of head and neck surgery. There remained many head and neck surgeons who commonly performed more limited neck dissection. Suarez is generally regarded as developing the functional neck dissection, a technique of cervical lymphadenectomy very similar to what is currently described as modified radical or selective neck dissection. [Suarez 1963, Ferlito 2005, Bocca 1964] Suarez' publication in 1963 demonstrated comparable levels of regional disease control with significantly decreased morbidity after these more conservative procedures. Suarez' paper contributed a very sophisticated description of the lymphatic drainage of the head and neck (Figure 8). It accurately described the different drainage patterns typical of head and neck malignancy based on primary tumor location.

Suarez' paper may be pinpointed as the start of a movement that has occurred in the later half of the 20<sup>th</sup> century towards modified radical and selective neck dissections.

In 1978 Jesse, Ballantyne, et al compared radical neck dissection with neck dissection that spared the spinal accessory nerve. They found no discrepancy in rate of disease recurrence between these two groups, even when controlling for disease severity. [Jesse 1978] Later, various studies comparing radical to various degrees of modified radical neck dissection demonstrated comparable rates of recurrence. [Spiro JD 1998, Byers 1988] Refinements in the

field of radiation oncology likely allowed for this experimentation, as the availability and efficacy of radiation salvage therapy allowed for more conservative surgical practices. [Mendenhall 1995]

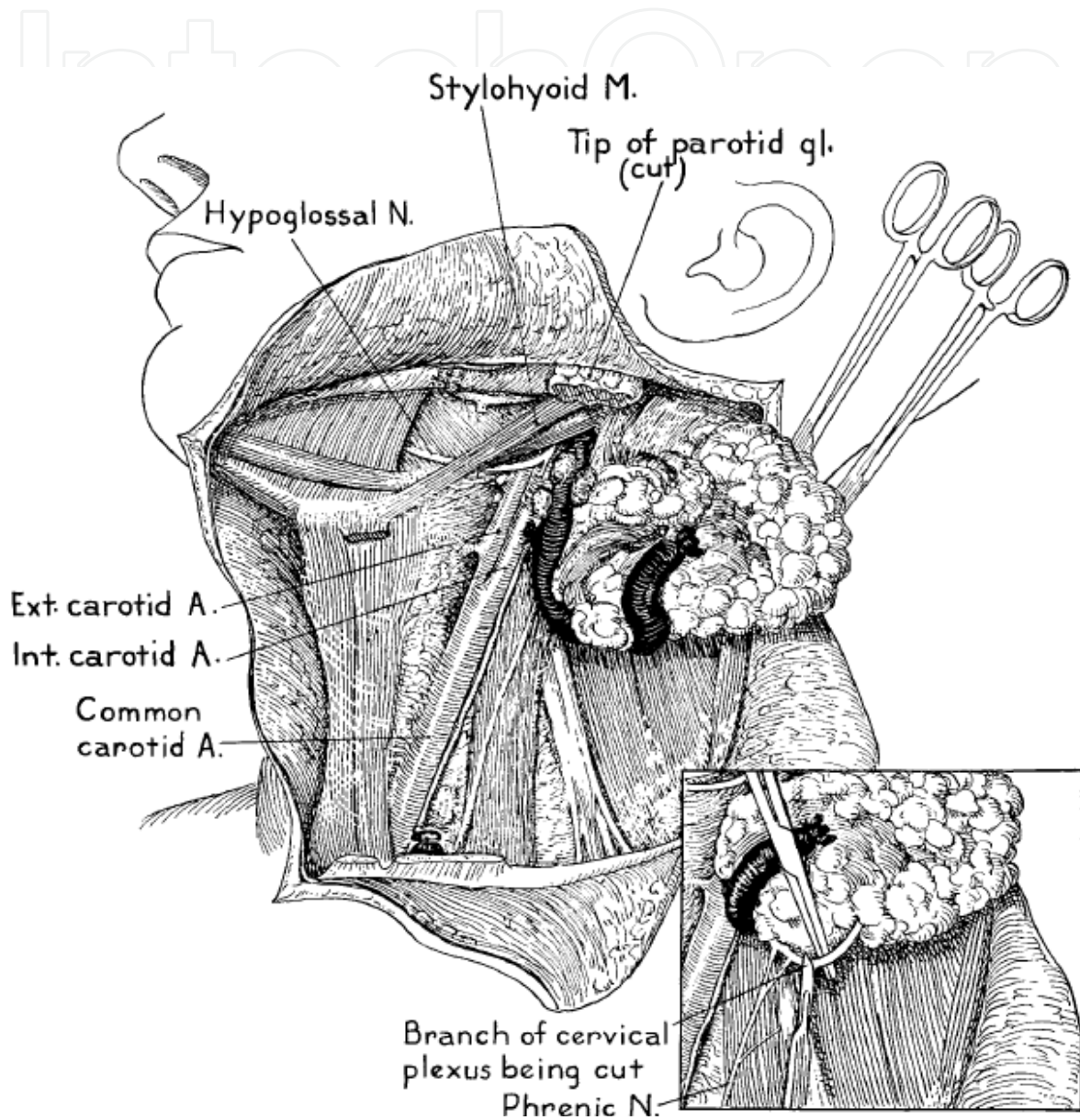


Fig. 7. En bloc removal of radical neck dissection specimen from Martin et al 1951. [Martin 1951]

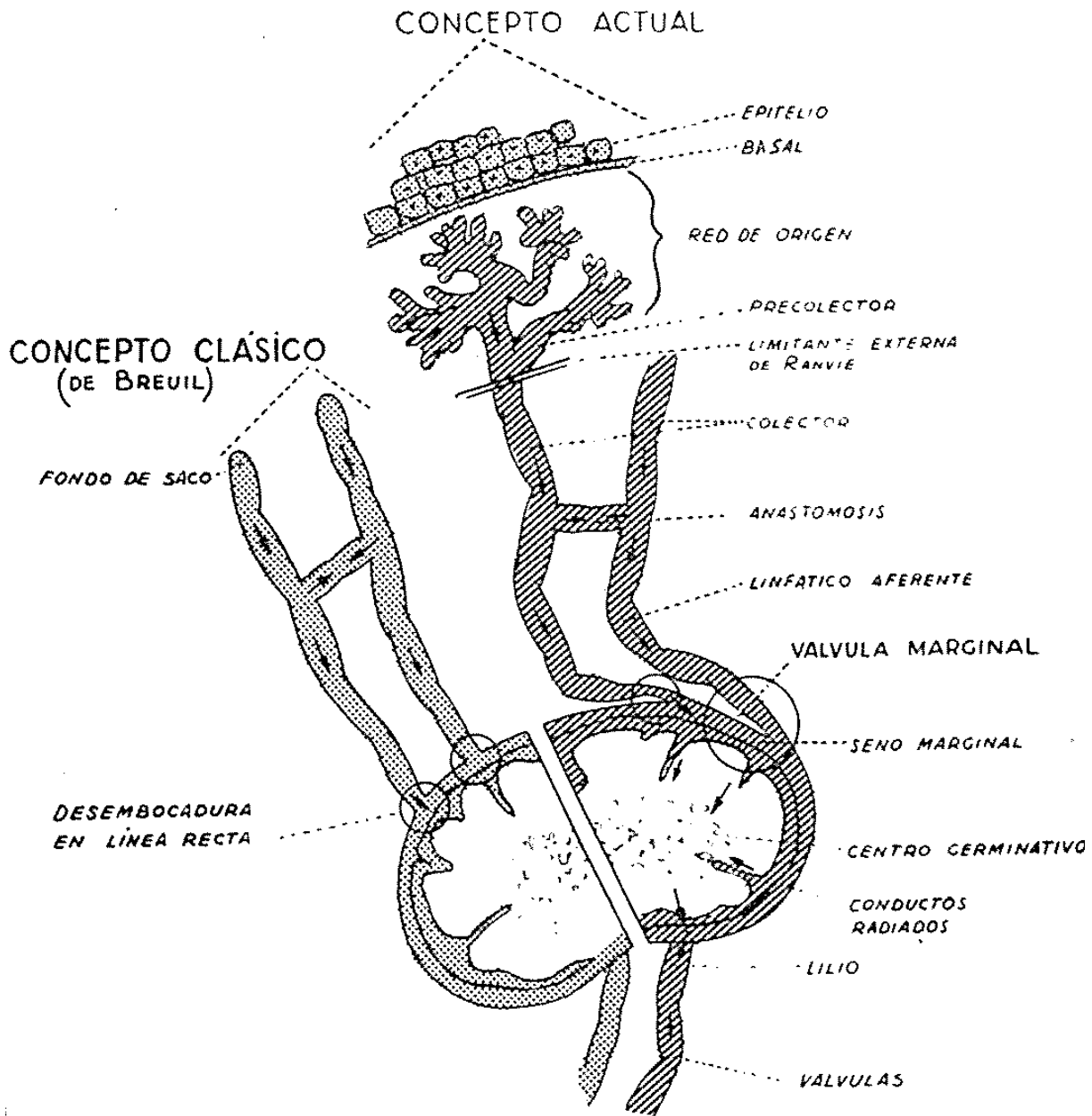


Fig. 8. A diagram of microscopic lymphatic anatomy from Suarez 1963. [Suarez 1963]

The basis of modern selective neck dissection lies in a sophisticated understanding of lymphatic drainage patterns of the head and neck. The contribution of Suarez was described above. In 1972 Robert M. Lindberg published a report on the surgical pathologic specimens from neck dissections. Lindberg reviewed 2,044 surgical specimens from the MD Anderson Cancer Institute in Texas; and reported the distribution of pathologically positive nodes. This data set provided a wealth of knowledge regarding pattern of lymphatic spread based on primary site as well as tumor stage classification. His results supported many of Suarez' earlier recommendations and have led to our current guidelines regarding the application of selective neck dissection.

## 5. Current practice and future directions

In 1991 the American Head and Neck Society published guidelines regarding classification and nomenclature of neck dissection that have gained acceptance throughout much of the world. Under those guidelines all procedures are classified as radical neck dissection, modified radical neck dissection, selective neck dissection, and extended neck dissection (as described above). The current indications (and contraindications) to neck dissection are very much intertwined with the definitions of the procedures themselves.

There remains a great deal of variation regarding the application of these procedures in the management of head and neck cancer. Common areas of discrepancy include the role of elective neck dissection, modified radical versus therapeutic selective neck dissection, bilateral versus unilateral neck dissection and the timing in cases of bilateral surgery. A thorough description of the current nomenclature and indications for neck dissection are outside the scope of this chapter, however in reviewing the history of neck dissection; there is much to be learned regarding the current guidelines in cervical lymphadenectomy.

Spread to local lymph nodes is the course of disease progression in head and neck malignancy. Neck disease is a key prognostic factor with regards to recurrence after treatment as well as overall survival. Even with refined radiation therapy techniques available, the primary management of lymphatic disease is surgical resection. Procedures aimed at partial or complete cervical lymphadenectomy have been performed at least since the mid 19<sup>th</sup> century, with varying degrees of success. The current standard of care in head and neck oncology is a product of the history outlined above. In the case of neck dissection, we can see how the course of events shapes our understanding of a disease and our attempts at its eradication.

The current era is a very exciting time in head and neck oncology. Technology has grown at an exponential rate over recent decades and we, as clinicians, are still struggling to apply these resources to medical care. Much has been learned over the previous centuries but there are daunting obstacles yet to overcome. Important areas of current research include the expanding role of chemotherapy and radiation therapy in head and neck cancer. [Wolf 1990] Further, microbiologic techniques such as polymerase chain reaction and immunohistochemical staining have enabled researchers to identify microscopic foci of disease in surgical specimens. The way that this information should be applied to treatment has yet to be determined. Other procedures such as lymphoscintigraphy have become standard of care in other malignant diseases such as breast cancer and melanoma, however the utility in head and neck oncology has yet to be defined.

Neck dissection has been a vital aspect of head and neck cancer treatment since neoplastic disease was first described. Current studies in technology, radiation, and epidemiology will allow us to further perfect the technique and application of this procedure.

## 6. References

- Blair VP, Brown JP. The treatment of cancerous or potentially cancerous cervical lymph nodes. *Ann Surg* 1933;98:650-61.
- Bocca E. E' videment "fonctionel" du cou dans la therapie de principe des metastases ganglionnaires du cancer du larynx (Introduction a` la presentation d'un film). *J Fr Oto-rhinolaryngol* 1964;13:721-3.

- Byers RM, Wolf PF, Ballantyne AJ. Rationale for elective modified neck dissection. *Head Neck Surg* 1988;10:160-7.
- Crile GW. Excision of cancer of the head and neck. With special reference to the plan of dissection based on one hundred and thirtytwo operations. *JAMA* 1906;47:1780-6.
- Crile GW. On the surgical treatment of cancer of the head and neck. With a summary of one hundred and twenty-one operations performed upon one hundred and five patients. *Trans South Surg Gynecol Assoc* 1905;18:108 - 27.
- Chelius JM, South JF. *A System of Surgery*. Tr. from the German and accompanied with additional notes and observations by John F. South, vol. III. Philadelphia: Lea & Blanchard; 1847. p. 515.
- Deschler DG and Day T. *Pocket Guide to TNM Staging of Head and Neck Cancer and Neck Dissection Classification*. Alexandria, VA. American Academy of Otolaryngology - Head and Neck Surgery; 2008.
- Ferlito A, Rinaldo A. Neck dissection: historical and current concepts. *Am J Otolaryngol*. 2005;26:289-295.
- Ferlito A, Rinaldo A, Silver CE, Shah JP, Suarez C, Medina JE, Kowalski LP, Johnson JT, Strome M, Rodrigo JP, Werner JA, Takes RP, Towpik E, Robbins KT, Leemans CR, Herranz J, Gavilan J, Shaha JR, Wei WI. Neck dissection: then and now. *Auris Nasus Larynx*. 2006; Vol 33: 365-374.
- Ferlito A, Johnson JT, Rinaldo A, Pratt LW, Fagan JJ, Weir N, Suárez C, Folz BJ, Bieñ S, Towpik E, Leemans CR, Bradley PJ, Kowalski LP, Herranz J, Gavilán J, Olofsson J. European surgeons were the first to perform neck dissection. *Laryngoscope*. 2007 May;117(5):797-802.
- Folz BJ, Ferlito A, Silver CE, Olofsson J, Bradley PJ, Bieñ S, Towpik E, Weir N, Rinaldo A. Neck dissection in the nineteenth century. *Eur Arch Otorhinolaryngol*. 2007 May;264(5):455-60
- Folz BJ, Silver CE, Rinaldo A, Fagan JJ, Pratt LW, Weir N, Seitz D, Ferlito A. An outline of the history of head and neck oncology. *Oral Oncol*. 2008 Jan;44(1):2-9.
- Harvey, William. *On the Motion of the Heart and Blood in Animals*. London: George Bell and Sons 1889.
- Jawdyn' ski F. Przypadek raka pierwotnego szyi. t.z. raka skrzelowego Volkmann'a. Wyciecie nowotworu wraz z rezekcyjã tętnicy szyjowej wspo' lnej i z' yły szyjowej wewne, trznej. Wyzdrowienie. *Gaz Lek* 1888;8:530-7.
- Kocher T. Ueber Radicalheilung des Krebses. *Dtsch Z Chir* 1880;13:134-66.
- Langenbeck B. Totalexstirpation des Kehlkopfes mit dem Zungenbein, einem Theil der Zunge, des Pharynx und Oesophagus. *Berl Klin Wschr* 1875;12:33.
- Leemans CR, Tiwari R, Nauta JJ, et al. Regional lymph node involvement and its significance in the development of distant metastases in head and neck carcinoma. *Cancer* 1993;71:452 - 6.
- Leemans CR, Tiwari R, Nauta JJ, et al. Recurrence at the primary site in head and neck cancer and the significance of neck lymph node metastases as a prognostic factor. *Cancer* 1994;73:187 - 90.
- Lister BJ. On the antiseptic principle in the practice of surgery. 1867. *Clin Orthop Relat Res*. 2010 Aug;468(8):2012-6.

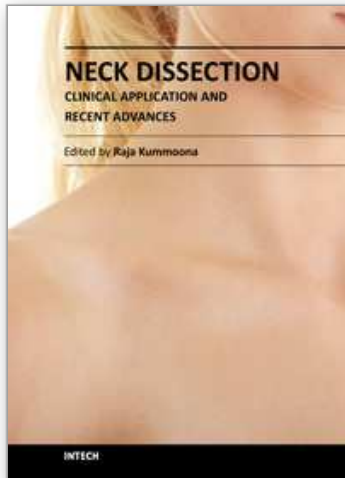
- Major RH. A history of medicine. Vol II. Thomas, Springfield; 1954: pp 752-754
- Martin HE, Del Valle B, Ehrlich H, Cahan WG. Neck dissection. *Cancer* 1951;4:441-99.
- Mendenhall WM, Parsons JT, Buatti JM, Stringer SP, Million RR, Cassisi NJ. Advances in radiotherapy for head and neck cancer. *Semin Surg Oncol* 1995;11:256-64.
- Patel KN, Shah JP. Neck dissection: past, present, future. *Surg Oncol Clin N Am* 2005;14:461-77.
- Rinaldo A, Ferlito A, Silver CE. Early history of neck dissection. *Eur Arch Otorhinolaryngol.* 2008; 265:1535-1538.
- Robbins KT, Medina JE, Wolfe GT, Levine PA, Sessions RB, Pruet CW. Standardizing neck dissection terminology. Official report of the Academy's Committee for head and neck surgery and oncology. *Arch Otolaryngol Head Neck Surg* 1991;117:601-5.
- Robbins KT, Clayman G, Levine P, Medina J, Sessions R, Shaha A, et al. Neck dissection classification update. Revisions proposed by the American Head and Neck Society and the American Academy of Otolaryngology – Head and Neck Surgery. *Arch Otolaryngol Head Neck Surg* 2002;128:751-8.
- Robbins KT, Ferlito A, Suarez C, Brizel DM, Bradley PJ, Pellitteri PK, et al. Is there a role for selective neck dissection after chemoradiation for head and neck cancer? *J Am Coll Surg* 2004;199:913-6.
- Robbins KT, Doweck I, Samant S, Vieira F. Effectiveness of super-selective and selective neck dissection for advanced nodal metastases after chemoradiation. *Arch Otolaryngol Head Neck Surg* 2005; 131:965-9.
- Robbins KT, Shaha AR, Medina JE, Califano JA, Wolf GT, Ferlito A, Som PM, Day TA. Consensus statement on the classification and terminology of neck dissection. *Arch Otolaryngol Head Neck Surg.* 2008 May;134(5):536-8.
- Shah JP, Strong E, Spiro RH, Vikram B. Neck dissection: current status and future possibilities. *Clin Bull* 1981;11:25-33.
- Spiro JD, Spiro RH, Shah JP, Sessions RB, Strong EW. Critical assessment of supraomohyoid neck dissection. *Am J Surg.* 1988 Oct;156(4): 286-289.
- Shapin S. *The Scientific Revolution.* Chicago: Univ. of Chicago Pr. 1996.
- Suarez O. Distant and lymphatic metastases of cancer of the larynx and hypopharynx. *Rev Otorrinolaringol* 1963;23:83-99.
- Sudhoff, Karl. *Essays in the History of Medicine.* Medical Life Press, New York 1926; 67-104.
- Towpik E. Centennial of the first description of the en bloc neck dissection. *Plast Reconstr Surg* 1990;85:468-70.
- Uttley AR, McGurk M. Sir Henry Trentham Butlin: the father of British head and neck surgery. *Br J Oral Maxillofac Surg.* 2000 Apr;38(2):114-20.
- Vesalius A. *De Humani Corporis Fabrica.* 1543. On the Fabric of the Human Body, translated by W. F. Richardson and J. B. Carman. 5 vols. San Francisco and Novato: Norman Publishing, 1998-2009.
- Virchow, RLK. *Cellular Pathology as Based upon Physiological and Pathological Histology.* London: John Churchill, 1860.
- Warren JC. *Surgical Observations on Tumours, with Cases and Operations.* Boston: Crocker and Brewster; 1837.
- Website. [http://www.aboutcancer.com/neck\\_nodes\\_level.gif](http://www.aboutcancer.com/neck_nodes_level.gif).



Wolf et al. Induction chemotherapy plus radiation compared with surgery plus radiation in patients with advanced laryngeal cancer. The Department of Veterans Affairs Laryngeal Cancer Study Group. N Engl J Med. Jun 1991;324(24):1685-90.

IntechOpen

IntechOpen



## **Neck Dissection - Clinical Application and Recent Advances**

Edited by Prof. Raja Kummoona

ISBN 978-953-51-0104-8

Hard cover, 164 pages

**Publisher** InTech

**Published online** 22, February, 2012

**Published in print edition** February, 2012

Neck Dissection - Clinical Application and Recent Advances is a leading book in neck surgery and represents the recent work and experiences of a number of top international scientists. The book covers all techniques of neck dissection and the most recent advances in neck dissection by advocating better access to all techniques of neck dissection; e.g. Robotic surgery (de Venice) system, a technique for detection of lymph node metastasis by ultra sonography and CT scan, and a technique of therapeutic selective neck dissection in multidisciplinary treatment. This book is essential to any surgeon specializing or practicing neck surgery, including Head Neck Surgeons, Maxillofacial Surgeons, ENT Surgeons, Plastic and Reconstructive Surgeons, Craniofacial Surgeons and also to all postgraduate Medical & Dental candidates in the field.

### **How to reference**

In order to correctly reference this scholarly work, feel free to copy and paste the following:

Jeremiah C. Tracy (2012). A Brief History of Cervical Lymphadenectomy, Neck Dissection - Clinical Application and Recent Advances, Prof. Raja Kummoona (Ed.), ISBN: 978-953-51-0104-8, InTech, Available from: <http://www.intechopen.com/books/neck-dissection-clinical-application-and-recent-advances/a-brief-history-of-cervical-lymphadenectomy>

**INTECH**  
open science | open minds

### **InTech Europe**

University Campus STeP Ri  
Slavka Krautzeka 83/A  
51000 Rijeka, Croatia  
Phone: +385 (51) 770 447  
Fax: +385 (51) 686 166  
[www.intechopen.com](http://www.intechopen.com)

### **InTech China**

Unit 405, Office Block, Hotel Equatorial Shanghai  
No.65, Yan An Road (West), Shanghai, 200040, China  
中国上海市延安西路65号上海国际贵都大饭店办公楼405单元  
Phone: +86-21-62489820  
Fax: +86-21-62489821

© 2012 The Author(s). Licensee IntechOpen. This is an open access article distributed under the terms of the [Creative Commons Attribution 3.0 License](#), which permits unrestricted use, distribution, and reproduction in any medium, provided the original work is properly cited.

IntechOpen

IntechOpen