

We are IntechOpen, the world's leading publisher of Open Access books Built by scientists, for scientists

4,800

Open access books available

122,000

International authors and editors

135M

Downloads

Our authors are among the

154

Countries delivered to

TOP 1%

most cited scientists

12.2%

Contributors from top 500 universities



WEB OF SCIENCE™

Selection of our books indexed in the Book Citation Index
in Web of Science™ Core Collection (BKCI)

Interested in publishing with us?
Contact book.department@intechopen.com

Numbers displayed above are based on latest data collected.
For more information visit www.intechopen.com



Detection of Poxvirus Using Transmission Electron Microscopy Techniques During Outbreak in Bay-Winged Cowbird (*Gnorimopsar Chopi*)

M.H.B. Catroxo¹, A.M.C.R.P.F. Martins¹,
S. Petrella² and L. Milanelo³

¹ Biological Institute of São Paulo, São Paulo, SP,

² Adolfo Lutz, Institute São Paulo, SP,

³ Tietê Ecological Park, São Paulo, SP,
Brazil

1. Introduction

Gnorimopsar chopi is a bird with blackish plumage, smooth and silky look, found throughout the Brazilian territory, except in the Amazon State. It is one of the singing birds most wanted by illegal trade and is listed as endangered to extinction by the Brazilian Institute of Environment and Renewable Natural Resources (IBAMA). Avian pox or variola avium is a infectious disease of worldwide distribution, that infect poultry, pet and wild birds of many species which result in economic losses to the poultry industry and commercial aviaries (Tripathy et al., 2000; Weli & Tryland, 2011).

Poxvirus infection has been considered one of important extinction factors for the endangered avian species in Hawaii and in North America (Friend & Franson, 1999; Smits et al., 2005; Kim & Tripathy, 2006).

The etiologic agent is a member of the genus *Avipoxvirus*, *Chordopoxvirinae* subfamily, *Poxviridae* family (Van Riper & Forrester, 2007). The genome is linear, double-stranded DNA molecule varying in size from 260 to 309 kpb and encodes 260 putative genes (Moss, 2007). Virus particles measure 270 x 450 nm and are composed of an electron dense, centrally located core and two lateral bodies that are visible in ultrathin sections. In negative stained preparations the membrane displays an outer coat composed of a random arrangement of tubules (Carter & Cheville, 1981).

The disease is characterized by cutaneous or wet pox, diphtheric or wet pox and septicemic forms. The cutaneous form is the most common in Passeriformes. In this form occurs the development of nodular proliferative skin lesions on the unfeathered parts of the body, legs, feet, face at the base of the beak and eyelids. In the diphtheric form, fibronecrotic lesions occur in the membranes of the upper respiratory tract and esophagus. Anorexia, letargy, ruffled plumage, respiratory distress, somnolence, cyanosis and death characterize septicemic poxvirus infections (Ritchie et al., 1994).

The virus may be mechanically transmitted by insect vectors such as mosquitoes, mites or ticks, by direct contact with another infected bird, by contact with contaminated food, water, semen or surfaces (Metz et al., 1985; Ritchie & Carter, 1995).

The course of the disease is influenced by strain, route of infection, and the species of bird (Ensley et al., 1978).

The incubation period of Avipoxvirus is usually less than a week but may be up to 30 days. The morbidity rate during an outbreak may reach 100% (Ritchie et al., 1994).

Non-specific stress factors are associated with viral reactivation (Ritchie et al., 1994).

Transmission electron microscopy is a classic tool for the diagnosis of poxviruses, where the viral particles with characteristic morphology are present in large numbers in swabs, biopsies or dry crusts (OIE, 2008). This method has typically been used by national reference or research laboratories to identify avianpoxvirus (Weli et al., 2004).

The aim of this study was to detect the presence of avianpoxvirus particles in samples of skin lesions of *Gnorimopsar chopi* using negative staining (rapid preparation) immunocytochemistry (immunolabeling with colloidal gold particles) and resin embedding techniques.

2. Material and methods

2.1 Description of the outbreak

In the period of the 2005 to 2007, during illegal commercialization of Brazilian birds, 60 bay-winged cowbird (*Gnorimopsar chopi*) were apprehended and being forwarded to the CRAS (Wild Animals Recovery Center, Ecological Park of Tietê). After one or two months, 45 birds presented cutaneous lesions in the feet. Some of them also had lesions on the beak and wings. The animals also been presented clinical signs of anorexia, emaciation, locomotion difficulties, diarrhea, dehydration and death. The birds were sent to the Electron Microscopy Laboratory of the Biology Institute of São Paulo to investigate viral agents. Scabs and fragments of skin lesions collected of these birds were processed for transmission electron microscopy utilizing negative staining (rapid preparation), resin embedding and immunocytochemistry techniques.

2.2 Negative staining technique (rapid preparation)

In the negative staining the scabs and fragments of skin lesions were suspended in phosphate buffer 0.1 M, pH 7.0. Drops of the obtained suspension were placed in contact with metallic copper grids with carbon stabilized supporting film of 0.5% collodium in amyl acetate. Next, the grids were drained with filter paper and negatively stained at 2% ammonium molybdate, pH 5.0 (Brenner & Horne, 1959; Hayat & Miller, 1990; Madeley, 1997).

2.3 Resin embedding technique

Thin slices of scabs and fragments of skin lesions were fixed in 2.5% glutaraldehyde in 0.1M, pH7.0 phosphate buffer and pos-fixed in 1% osmium tetroxide in the same buffer. After dehydration in cetonic series, the fragments were embedded in Spurr resin (González-

Santander, 1969; Luft, 1961). Ultrathin sections were cut on the LKB ultratome and mounted on copper grids. The sections were stained by combination of uranyl acetate-lead citrate (Watson, 1958; Reinolds, 1963).

2.4 Immunocytochemistry technique

At the immunolabeling technique with colloidal gold particles for negative staining, the copper grids were placed in contact with viral suspension and, after removing excess with filter paper, the same were put on specific primary antibody drops. After successive washings in PBS drops, the grids were incubated in protein A drops in association with 10 nm gold particles (secondary antibody). Grids were then contrasted at 2% ammonium molybdate, pH 5.0 (Knutton, 1995). Observations were made in a Philips EM 208 electron microscope, at 80 kV.

3. Results

Among the 45 analyzed animals, all of them (100%) presented in feet, and occasionally in beaks and wings, small yellowish-brown proliferative nodules or scabs of different sizes, characteristic of cutaneous form (fig. 1, arrow).



Fig. 1. Nodular and crusted lesions on the feet of *Gnorimopsar chopi* (arrow).

3.1 Negative staining technique (rapid preparation)

On the transmission electron microscopy by the negative staining technique, two types of poxvirus particles were visualized in all the analyzed samples. the M form, with regular spaced thread-like ridges comprising the exposed surface (fig. 2, big arrow), measuring 280 x 230 nm and the C form or stain-penetrated particle showing the dumbbell-shaped core (fig. 3, arrow) measuring 360 x 330 nm.

3.2 Resin embedding technique

Using the resin embedding technique (positive staining) were visualized in the ultrathin sections, three types of intracytoplasmic inclusion bodies. The type A or Bollinger body (fig. 4), outlined by membrane, containing in its interior a great number of mature particles (fig. 4,

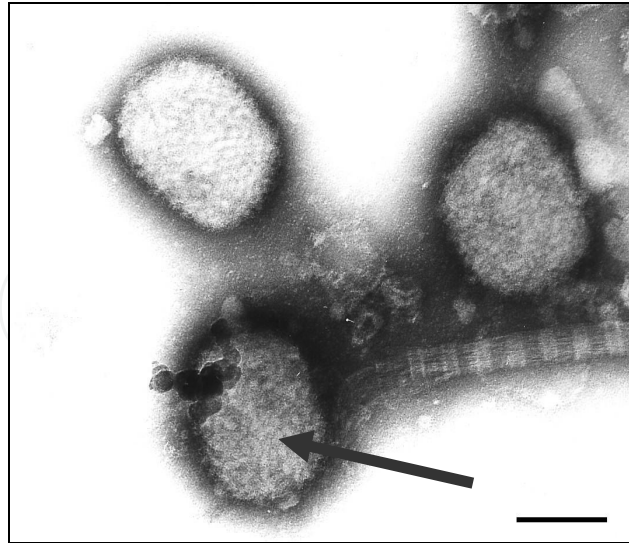


Fig. 2. Negatively stained avian poxvirus particles showing the M form, with regular spaced thread-like ridges comprising the exposed surface (arrow). Bar: 180 nm.

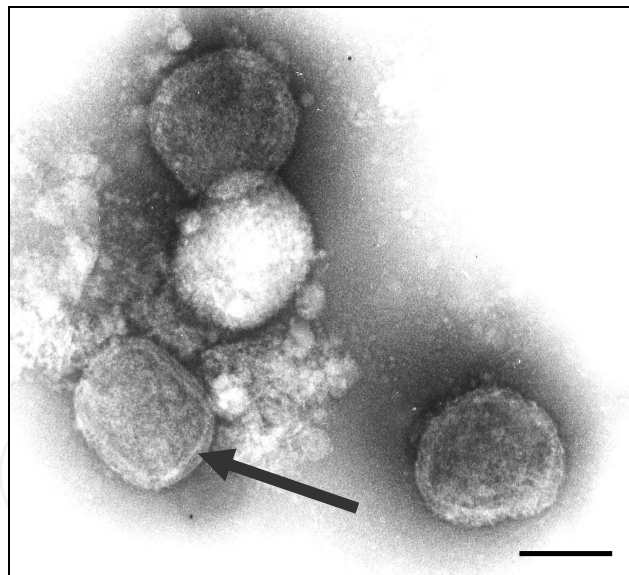


Fig. 3. Negatively stained avian poxvirus particles showing the C form or stain-penetrated particle revealing the dumbbell-shaped core (arrow). Bar: 200 nm.

arrow), measuring 200 x 300 nm, revealing the inner dumbbell-shaped core (fig. 5, big arrow), two lateral bodies (fig. 5 minor arrow) and an external envelope (fig. 5, blue arrow). In the type B electron dense inclusions bodies, viral particles budding of dense amorphous material were observed (figs. 6 and 7, arrow). Fibrillar inclusions constituted by groups of fibrils (fig. 8, arrow) were disposed in groups varying from 2 up to 7 and sometimes showed cross striations.

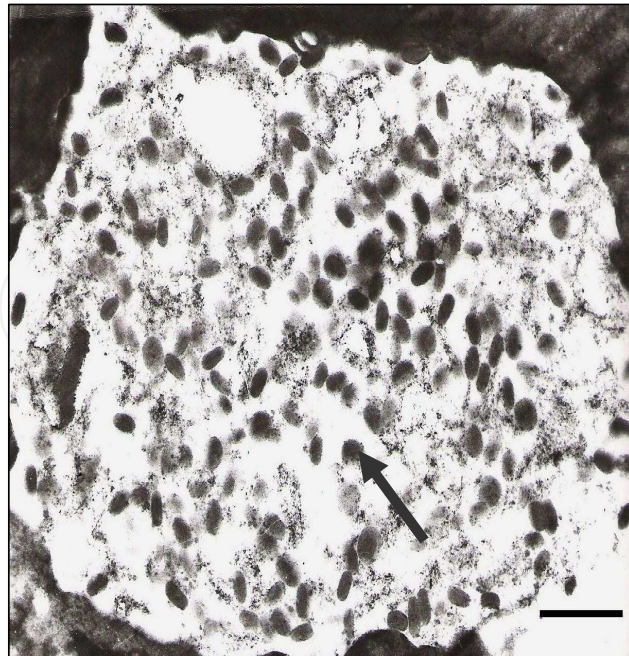


Fig. 4. Ultrathin sections of the scabs fragments showing type A or Bollinger intracytoplasmic inclusion bodies, containing mature particles (arrow). Bar: 1040 nm.

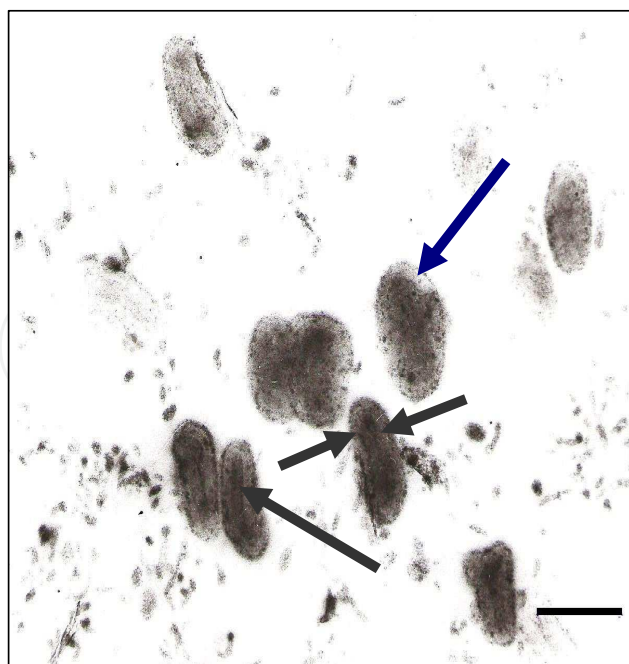


Fig. 5. Ultrathin sections of the skin lesions fragments, showing mature particles with inner dumbbell shaped core (big arrow), lateral bodies (minor arrow) and external envelope (blue arrow). Bar: 280 nm.

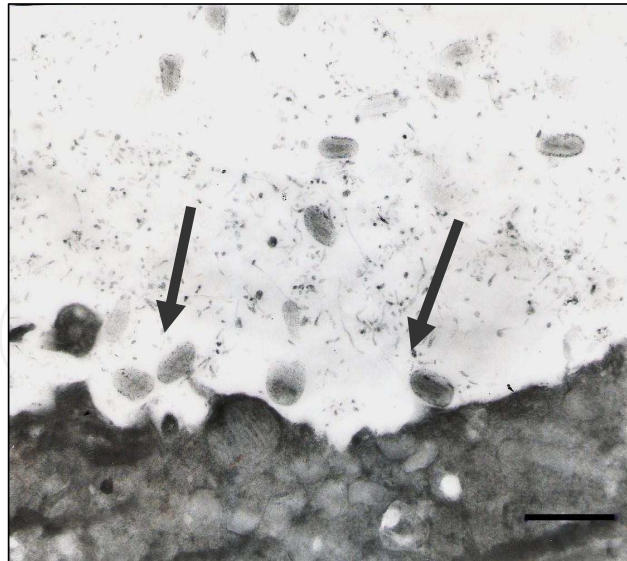


Fig. 6. Ultrathin sections of the scabs fragments revealing type B electron dense inclusions bodies with viral particles budding of dense amorphous material (arrow). Fig. 6 - Bar: 600 nm.

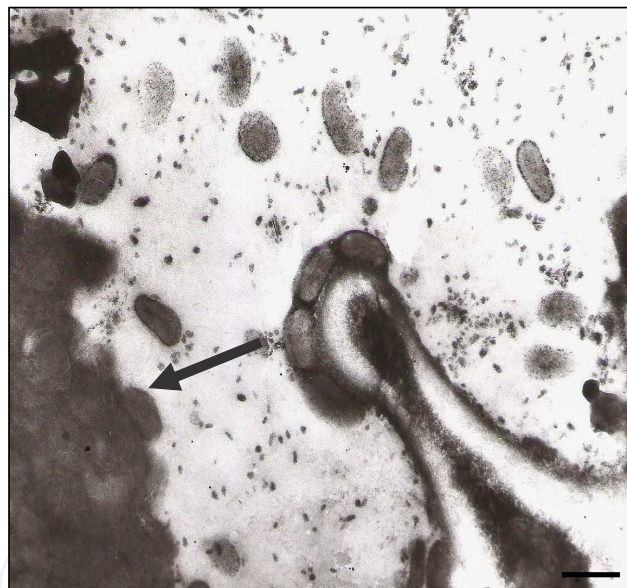


Fig. 7. Bar: 430 nm.

3.3 Immunocytochemistry technique

In the immunocytochemistry technique, the antigen-antibody interaction was strongly enhanced by the dense gold particles over the viruses (Fig. 9, arrow).

4. Discussion

In this paper the presence of nodular proliferative and crusted lesions, was observed in feet de 45 (100%) de 60 bay-winged cowbird (*Gnorimopsar chopi*) examined. Some of them also had lesions on the beak and wings.

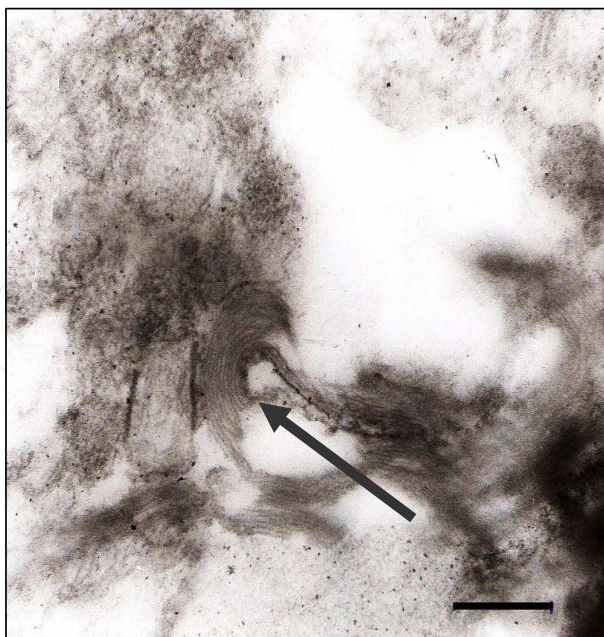


Fig. 8. Ultrathin sections of the skin fragments revealing fibrillar inclusions constituted by groups of fibrils or lamellae (arrow). Bar: 320 nm.

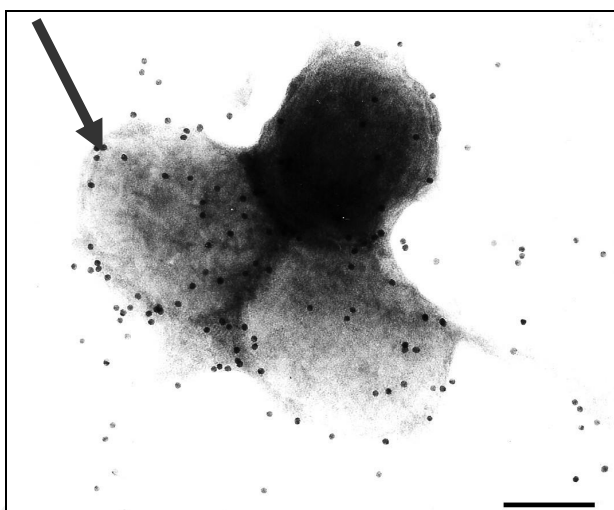


Fig. 9. In the immunocytochemistry technique, the antigen-antibody interaction was strongly enhanced by the dense colloidal gold particles (arrow) over the avipoxvirus particles. Bar: 130 nm.

Lesions similar have been described in other birds (Goodpasture & Anderson, 1961; Trapp, 1980; Van Riper et al., 2002; Catroxo et al., 2009).

Lesions can interfere with perching when occur on the feet or legs and frequently lead to development of secondary infections (Van Riper III & Forrester, 2007).

Clinical signs of lack appetite, weight lost, difficulties of locomotion, diarrhea, dehydration and death were observed in all birds of this study. This has been documented in similar occurrence of avianpox in other avian species (Mc Donald et al., 1981; Docherty et al., 1991; Ostrowski et al., 1995; Gerlach et al., 1998; Kreuder et al., 1999; Catroxo et al., 2009).

By means of the negative staining technique, poxvirus particles were identified in suspension of skin fragments, as been seen in other cases (Tantawi et al., 1981; Terragino et al., 1981; Docherty et al., 1991; Allwright et al., 1994; Gulbahar et al., 2005; Kulich et al., 2008; Catroxo et al., 2009; Shivaprasad et al., 2009).

In the present ultrastructural study, intracytoplasmic inclusion bodies of different types were found. The analysis of ultrathin sections of skin lesions showed the presence of type A or Bollinger intracytoplasmic inclusion bodies, containing oval, mature or complete viral particles, measuring on the average, 330 x 260 nm, with an inner dumbbell-shaped core. These morphological characteristics described by us were similar to those found in other birds species (Tripathy & Reed, 2003; Smits et al., 2005; Beyut & Haligur, 2007; Kulich et al., 2008; Saito et al., 2009; Shivaprasad et al., 2009; Catroxo et al., 2009).

The observation of immature intracytoplasmic particles, budding of a dense amorphous material or type B inclusion body, agrees with findings of other authors (Purcell et al., 1972; Thiele et al., 1979, Sadosiv et al., 1985; Catroxo et al., 2009).

We also observed fibrillar intracytoplasmic inclusions, constituted by groups of fibrils or lamellae, disposed in groups varying from 2 to 7, occasionally showing cross striations. These ultrastructural aspects were also reported by other authors in avipoxvirus studies (Catroxo et al., 2009).

The avian poxvirus were intensely labeled by colloidal gold, when we applied the immunocytochemistry method, also used to detect these viruses in skin lesions in other passerines (Catroxo et al., 2009).

All birds in our study were sudden death. During avipox outbreak, mortality can reach 80 to 100% in canaries and other finches in contrast with lower mortality observed in chicken and turkey (Tripathy & Reed, 2003).

The increased population of mosquitoes during the summer at the place of the outbreak probably contributed to the sudden onset of the outbreak. Other sucking insects such flea and mite are considered to be important vectors for the spread of avian poxvirus (Ritchie et al., 1994; Gustafson et al., 1997).

Prevention and control measures, such vaccination, quarantine for new birds, control of arthropods, prevention and reduction of stress, cleaning and disinfecting of cages should be instituted to farms and zoos (Ritchie et al., 1994).

It is very important to confirm the presence of the ethiological viral agent in the samples. Infection as other agents, such papilloma virus, mites, flies and mycotoxins may produce like lesions in the skin (Tripathy & Reed, 2003).


Our results obtained through the techniques mentioned in this study to detect avipoxvirus particles in these birds, allowed rapid preventive measures to control the disease, preventing spread to commercial breeder farms and aviaries with economic losses thus protecting and preserving these endangered species.

To our knowledge, this is the first report of avian poxvirus infection in bay-winged cowbird (*Gnorimopsar chopi*).

5. References

- Allwright, D.M.; Burger, W.P.; Geyer, A. & Wessles, J. Avian pox in ostriches. *J. S. Afri. Vet. Assoc.*, 65 (1): 23-5, 1994.
- Brenner, S. & Horne, R. W. A negative staining method for high resolution electron microscopy of viruses. *Biochem. Biophys. Acta.*, 34:103, 1959.
- Bohls, R.L.; Linares, J.A.; Gross, S.L.; Ferro, P.J.; Silvy, N.J.; Collisson, E.W. Phylogenetic analyses indicate little variation among reticuloendotheliosis viruses infecting avian species, including the endangered Attwater's prairie chicken. *Virus Res.*, 119:187-94, 2006.
- Carter, J.K.V. & Cheville, N.F. Isolation of surface tubules of fowlpox virus. *Avian Dis.*, 25:454-62, 1981.
- Catroxo, M. H. B.; Pongiluppi T.; Melo, N. A.; Milanelo, L.; Petrella, S.; Martins, A. M. C. P. F.; Rebouças, M. M. Identification of poxvirus under transmission electron microscopy during outbreak period in wild birds, in São Paulo, Brazil. *Int. J. Morphol.*, 27(2):577-585, 2009.
- Docherty, D.E.; Long, R. I.; Flickinger, E.L. & Locker, L.N. Isolation of poxvirus from debilitating cutaneous lesions on four immature grackles (*Quiscalus sp.*). *Avian Dis.*, 35 (1): 244-7, 1991.
- Ensley, P.K.; Anderson, M.P.; Costello, M.L.; Powell, H.C. & Cooper, R. Expornitic of avian pox in a zoo. *J. Am. Vet. Med. Assoc.*, 173:1111-4, 1978.
- Friend, M.; Franson, J.C. & Ciganovich, E.A. (Eds). *Field Manual of Wildlife Diseases: General Field Procedures and Diseases of Birds*. Washington, Ed. Washington D.C., United States Geological Survey, 1999. pp.163-170.
- Gonzales-Santander, R. Técnicas de microscopia eletrônica en biología. Madrid. Ed. Aguilar, 1969. 666p.
- Goodpasture, E.W. & Anderson, K. Isolation of a wild avian pox virus inducing both cytoplasmatic and nuclear inclusions. *Am. J. Pathol.*, 40:437-53, 1961.
- Gülbahar, M.Y.; Çabalar, M. & Boynukara, B. Avipoxvirus infection in quails. *Turk. J. Vet. Anim. Sci.*, 29: 449-4, 2005.
- Gustafson, C.R.; Bickford, A.A.; Cooper, G.L. & Charlton, B.R. Sticktight fleas associated with fowl pox in a backya chicken flock in California. *Avian. Dis.*, 41: 1006-9, 1997.
- Hayat, M. A. & Miller, S. E. Negative Staining. Mc. Graw-Hill Publ. Company., 1990. 235p.
- Kim, T. & Tripathy, D.N. Evatuation of pathogenicity of avian poxvirus isolates from endangered Hawaiian wild birds in chickens. *Avian Dis.*, 50(2):288-91, 2006.
- Knutton, S. Electron microscopical methods in adhesion. *Meth. Enzymol.*, 253:145-58, 1995.
- Kulich, P.; Roubalová, E.; Dubská, L.; Sychra, O.; Smid, B.; Literák, I. Avipoxvirus in blakcaps (*Sylvia atricapilla*). *Avian Pathol.*, 37(1):101-7, 2008.
- Luft, J. A. Improvements in an epoxy resin embedding methods. *J. Biophys. Biochem. Cytol.*, 9:409-14, 1961.
- Madeley, C. R. Electron microscopy and virus diagnosis. *J. Clin. Pathol.*, 50:454-6, 1997.
- Metz, A.L.; Hatcher, L.; Newman, A.J. & Halvorson, D.A. Venereal pox in breeder turkeys in Minnesota. *Avian Dis.*, 29 (3): 850-3, 1985.
- Moss, B. Poxviridae: The viruses and their replication. In: *Virology*, Philadelphia, USA, 5 th. Ed. Lippincot Williams & Wilkins, 2007. pp.2905-75.
- OIE. Manual of Diagnostic Tests & Vaccines for Terrestrial Animal. In: *Fowlpox*. França, Paris, 6 th ed., 2008. pp. 531-7.

- Ostrowski, S.; Dorrestein, G.M.; Ancrenas, M. & Saint-Jalme, M. Debilitating cutaneous poxvirus lesion on two captive houbara bustards (*Chlamydotis undulata*). *Avian Dis.*, 39(4): 904-11, 1995.
- Purcell, D.A.; Clarke, J.K.; McFerran, B.J. & Hughes, D.A. The morphogenesis of pigeonpox virus. *J. Gen. Virol.*, 15: 79-83, 1972.
- Reinolds, E.S. The use of lead citrate at high pH as an electron-opaque stain in electron microscopy. *J. Cell. Biol.*, 17:208-12, 1963.
- Ritchie, B.W. & Carter, K. *Avian viruses: Function and control*. Lake Worth, Florida, Ed. Publishing Incorporated, 1995. pp.285-311.
- Ritchie, B.W.; Harrison, G.J. & Harrison, L.R. *Avian Medicine: Principles and application*. Florida, Ed. Wingers Publishing Inc., 1994. pp.865-74.
- Sadosiv, E.C.; Chang, P.W. & Gulka, G. Morphogenesis of canary poxvirus and its entrance into inclusion bodies. *Am. J. Vet. Res.*, 46 (2): 529-35, 1985.
- Shivaprasad, H.L.; Kim, T.; Tripathy, D.; Woolcook, P.R.; Uzal, F.; Unusual pathology of canary poxvirus infection associated with high mortality in young and adult breeder canaries (*Serinus canaria*). *Avian Pathol.*, 38(4):311-6, 2009.
- Smits, J.E.; Tella, J.L.; Carrete, M.; Serrano, D. & López, G. Na epizootic of avian pox in endemic short-toed larks (*Calandrella rufescens*) and berthelot's pipits (*Anthus berthelotti*) in the Canary Island, Spain. *Vet. Pathol.*, 42: 59-65, 2005.
- Terregino, C.; Catelli, E.; Delogu, M.; Capua, I. & Tonelli, A. Poxvirus infection in a blue bonnet owls from Florida. *J. Wildl. Dis.*, 145 (9): 264, 1999.
- Thiele, J.; Kiel, H. & Adolphs, H.D. Avian pox virus. An ultrastructural study on a cherrug falcon. *Brief report. Arch. Virol.*, 62 (1): 77-82, 1979.
- Trapp, J.L. Avian pox in the gray-crowned rosy finck in Alaska. *North Am. Birds Bander.*, 5 (2): 146-7, 1980.
- Tripathy, D.N.; Schnitzlein, W.M.; Morris, P.J.; Janssen, D.L.; Zuba, J.K.; Massey, G.; Atkinson, C.T. Characterization of poxviruses from forest birds in Hawaii. *J. Wildl. Dis.*, 36:225-30, 2000.
- Tripathy, D.N., and W.M. Reed. 2003. Pox. In *Diseases of Poultry*, 11th Ed., Y.M. Saif, H.J. Barnes, J.R. Glisson, A.M. Fadly, and L.R. McDougald (eds.). Iowa State University Press, Ames, Iowa, U.S.A., pp. 253-269.
- Van Riper III, C.V.; Riper, S.G.V. & Hansen, W.R. Epizootiology and effect of avian pox on hawaiian forest birds. *The Auk.*, 119(4): 929-42, 2002.
- Van Riper III, C. & D. J. Forrester. *Avian pox*. In: *Infectious Diseases of Wild Birds*. Ames, IA, Ed. Blackwell Publishing, 2007. pp.131-176.
- Watson, M. L. *Staining of tissue sections for electron microscopy with heavy metals*. *J. Biophys. Biochem. Cytol.*, 4:475-8, 1958.
- Weli, S.C.; Okeke, M.I.; Tryland, M.; Nilssen, O. & Traavik, T. Characterization of avipoxviruses from wild birds in Norway. *Can. J. Vet. Res.*, 68: 140-5, 2004.
- Weli, S. & Tryland, M. Avipoxviruses: infection, biology and their use as vaccine vectors. *Virol. J.*, 8(49):1-15, 2011.



A Bird's-Eye View of Veterinary Medicine

Edited by Dr. Carlos C. Perez-Marin

ISBN 978-953-51-0031-7

Hard cover, 626 pages

Publisher InTech

Published online 22, February, 2012

Published in print edition February, 2012

Veterinary medicine is advancing at a very rapid pace, particularly given the breadth of the discipline. This book examines new developments covering a wide range of issues from health and welfare in livestock, pets, and wild animals to public health supervision and biomedical research. As well as containing reviews offering fresh insight into specific issues, this book includes a selection of scientific articles which help to chart the advance of this science. The book is divided into several sections. The opening chapters cover the veterinary profession and veterinary science in general, while later chapters look at specific aspects of applied veterinary medicine in pets and in livestock. Finally, research papers are grouped by specialisms with a view to exploring progress in areas such as organ transplantation, therapeutic use of natural substances, and the use of new diagnostic techniques for disease control. This book was produced during World Veterinary Year 2011, which marked the 250th anniversary of the veterinary profession. It provides a fittingly concise and enjoyable overview of the whole science of veterinary medicine.

How to reference

In order to correctly reference this scholarly work, feel free to copy and paste the following:

M.H.B. Catroxo, A.M.C.R.P.F. Martins, S. Petrella and L. Milanelo (2012). Detection of Poxvirus Using Transmission Electron Microscopy Techniques During Outbreak in Bay-Winged Cowbird (*Gnorimopsar Chopi*), *A Bird's-Eye View of Veterinary Medicine*, Dr. Carlos C. Perez-Marin (Ed.), ISBN: 978-953-51-0031-7, InTech, Available from: <http://www.intechopen.com/books/a-bird-s-eye-view-of-veterinary-medicine/detection-of-poxvirus-using-transmission-electron-microscopy-techniques-during-outbreak-in-bay-winge>

INTECH
open science | open minds

InTech Europe

University Campus STeP Ri
Slavka Krautzeka 83/A
51000 Rijeka, Croatia
Phone: +385 (51) 770 447
Fax: +385 (51) 686 166
www.intechopen.com

InTech China

Unit 405, Office Block, Hotel Equatorial Shanghai
No.65, Yan An Road (West), Shanghai, 200040, China
中国上海市延安西路65号上海国际贵都大饭店办公楼405单元
Phone: +86-21-62489820
Fax: +86-21-62489821

© 2012 The Author(s). Licensee IntechOpen. This is an open access article distributed under the terms of the [Creative Commons Attribution 3.0 License](#), which permits unrestricted use, distribution, and reproduction in any medium, provided the original work is properly cited.

IntechOpen

IntechOpen