

# We are IntechOpen, the world's leading publisher of Open Access books Built by scientists, for scientists

4,800

Open access books available

122,000

International authors and editors

135M

Downloads

Our authors are among the

154

Countries delivered to

TOP 1%

most cited scientists

12.2%

Contributors from top 500 universities



WEB OF SCIENCE™

Selection of our books indexed in the Book Citation Index  
in Web of Science™ Core Collection (BKCI)

Interested in publishing with us?  
Contact [book.department@intechopen.com](mailto:book.department@intechopen.com)

Numbers displayed above are based on latest data collected.  
For more information visit [www.intechopen.com](http://www.intechopen.com)



# The Evolution of VATS Lobectomy

Alan D. L. Sihoe

*Division of Cardiothoracic Surgery, Department of Surgery,  
Li Ka Shing Faculty of Medicine, The University of Hong Kong,  
China*

## 1. Introduction

Video-Assisted Thoracic Surgery (VATS) has without doubt been the most significant advance in thoracic surgery over the past half century. No other single innovation has so totally revolutionized the way thoracic surgeons perform their craft, or so greatly improved the surgical experience for patients undergoing thoracic operations worldwide.

In any surgical specialty, patients in the 21<sup>st</sup> Century are already well aware of the benefits of minimally invasive surgery. Thoracic surgery is no exception. Throughout the world, patients requiring major lung resection surgery are increasingly demanding that they receive VATS. The trend for ever increasing proportions of lung resections being performed with a VATS approach is inexorable. This is true around the globe, from Asia to Europe to North America. It is becoming ever more difficult for thoracic surgeons to justify *not* using a VATS in the face of overwhelming evidence for the benefits of this approach – not only in terms of reducing patient morbidity, but also in improving surgical outcomes.

Yet behind the hype and glamour of VATS today, there are aspects of the approach that even many experienced thoracic surgeons tend to overlook. It is often forgotten that VATS was first used for major lung resection two decades ago. During its infancy, VATS lobectomy was often dismissed as a gimmick or a fad with only limited niche applicability in thoracic surgery as a whole. The story of how VATS lobectomy matured, developed and evolved over the past 20 years to become the mainstream approach it is today contains many lessons for the modern thoracic surgeon. These include: realizing the importance of accurately defining a minimally invasive surgical approach such as VATS; establishing reliable outcome measures to objectively validate its efficacy; and continuing efforts to improving its outcomes and affirm its role in modern clinical practice.

This chapter aims to provide an overview of how VATS lobectomy has evolved over the past two decades from a minor novelty into a fundamental pillar of thoracic surgical practice. The many innovations made and insights gained during the maturation of the VATS approach have had profound influence on how thoracic surgery as a whole is practiced today.

## 2. Historical background

VATS surgeons worldwide have generally attributed the origination of thoracoscopic therapy to the Swedish physician Hans Christian Jacobaeus (Jacobaeus, 1910; Braimbridge,

2000; Sihoe & Yim, 2008). Towards the end of the 19th century, he first used a modified cystoscope to examine the pleural cavity under local anesthesia. Using a simple candle as a light source, Jacobaeus peered through the rigid tube to look inside the chest. He primarily used this technique of direct thoracoscopy technique to lyse adhesions in order to collapse the lungs as this was the prevailing treatment for tuberculosis at the time. This technique was adopted throughout Europe in the early decades of the 20th century. As this method of direct visualization through a tube has now become forever linked to the term 'thoracoscopy', many VATS surgeons today resolutely refer to modern VATS as 'Video-Assisted Thoracic Surgery' and never 'thoracoscopic surgery' (Lewis, 1996).

The introduction of streptomycin in 1945, and ever improving medical treatment of tuberculosis spelled the end of a period of enthusiasm for traditional therapeutic thoracoscopy. It is only in the last few decades that interest in minimally invasive thoracic surgical therapy was rekindled by two key technological developments. First, the marriage of the rod lens with solid state video systems and micro-cameras in the early 1980s allowed a panoramic view of the hemithorax, instead of the previous tunnel-like vision with direct thoracoscopy. Second, the availability of new endoscopic instruments like the linear mechanical stapler opened up new vistas for a spectrum of diagnostic and therapeutic procedures. From these advances, Video-Assisted Thoracic Surgery (VATS) was born. The video-thoracoscope unit with its own light source provides a well-illuminated, magnified operative view of the thorax, providing very high resolution for details surpassing even that provided by conventional headlight and magnifying loops. Although initially used for simpler diagnostic purposes, the tremendous success of laparoscopic cholecystectomy in the mid-1980s gave impetus to surgeons to apply VATS for therapy of intra-thoracic conditions. Before long, the potential advantage of the VATS approach for reducing post-operative morbidity and pain began gaining widespread notice. The first major meeting on VATS was held in January 1992 in San Antonio, Texas in conjunction with the Society of Thoracic Surgeons meeting, representing the baptism of a newborn technique (Mack et al, 1993). Over the subsequent years, VATS has become established and developed in many centers in North America, Asia, Europe, Australia and South America (Yim et al, 1998a). Its applications as a diagnostic approach and as a therapeutic modality for benign thoracic diseases have now been firmly incorporated into mainstream thoracic surgery. Throughout the 1990s, VATS gradually became the approach of choice for thoracic procedures such as diagnosis of solitary lung nodules, diffuse pulmonary infiltrates and pleural disease; and simpler therapeutic procedures such as for pneumothorax and excisions of mediastinal lesions. With growing experience with the technique, it was inevitable that more complex pulmonary operations were being performed using VATS.

### 3. The genesis of VATS lobectomy

For one whole century since the first lung resection was performed in 1891 by Tuffier, the posterolateral thoracotomy - and less frequently the median sternotomy and the clam-shell incisions for bilateral pulmonary procedures - have been the preferred modes of surgical access (Brambridge, 2000). Unfortunately, although these incisions generally provide good surgical exposure, they are also among the most painful incisions in all of surgery. The trauma of access is often described as worse than that of the procedure itself. It has been reported that 5% to 80% of patients experience significant levels of pain at two months or more after a standard thoracotomy (Rogers & Duffy, 2000; Karmakar & Ho, 2004). This pain

can persist in up to 30% of patients at 4 to 5 years after surgery. It has previously been suggested that the pain can result from a combination of skin incision, muscle splitting, rib fracturing, costo-chondral dislocation, pleural injury, diathermy burning, neuroma formation at the wound, and so on. Above all, many surgeons believe that the single most important element is the forcible spreading of the ribs during thoracotomy.

The rationale for VATS pulmonary resection is that by using video technology to minimize the surgical access required, most of these pain-causing elements can be reduced, particularly rib-spreading. The challenge to the first pioneers of VATS lobectomy, however, was how to negotiate the delicate hilar structures – particularly the pulmonary arteries which can easily tear and bleed. Using the small access ports envisaged, innovative strategies or exquisite skill would be required to tackle the structures situated on the medial side of the lobe, often buried by overlying parenchyma and fused fissures.

One of the first to report large series of lobectomies for lung cancer using the VATS approach was Dr Ralph Lewis (Lewis et al, 1992; Lewis, 1995). The technique his group described used 4 ports and explicitly called for the avoidance of rib-spreading. The mediastinal lymph nodes are excised, the fissures divided with endoscopic staplers, and the hilar structures skeletalized. The hilar structures (pulmonary artery, pulmonary vein and lobar bronchus) are then simultaneously stapled in their normal anatomic configuration using two firings of a stapler device. This bold but simple technique permitted efficient resection of a lung lobe in the early days of VATS when the intricate skills needed for conventional isolation-ligation of individual hilar structures via the small incision were still being developed. Even in the early 1990s, in his first 200 consecutive patients using this technique, Lewis claimed impressively short average operating times of 79.5 minutes and length of hospital stay of 3.07 days (Lewis & Caccavale, 2000). There was no mortality and minor complications were only noted in 13% of patients. Importantly, no patient developed a bronchopleural fistula despite the use of simultaneous stapling. After a mean follow-up of 34 months, recurrence-free survival was claimed in 141 out of 171 patients with primary lung cancers (even though less than half had post-operative stage I disease), and 7 deaths were unrelated to neoplasm.

However, despite such promising results, Lewis' simultaneous stapling technique met with considerable skepticism from the more traditional-minded thoracic surgeons' community (Pearson, 2000). Although Lewis and colleagues made a very sound argument that simultaneous stapling was a safe and even historically-proven technique for lobectomy (Lewis, 1995; Lewis & Caccavale, 2000), their approach failed to become established into the mainstream in the face of overwhelming conservatism. Since then, VATS lobectomy has generally conformed worldwide to the strategy of individual isolation-ligation of hilar structures. Nonetheless, Lewis' simultaneous stapling technique has never been discredited on clinical evidence. It can achieve a quick and safe means of removing a lobe, and can still play a part in the surgeon's armamentarium for selected patients when an expeditious lobectomy is required.

The individual isolation-ligation strategy took over as the mainstream for VATS lobectomy subsequently. As the early VATS surgeons tackled the challenge of the hilar structures, the initial instinct was to apply the conventional individual isolation-ligation of open thoracotomy but using smaller wounds. This conventional approach involved dissection of the pulmonary vessels via the interlobar fissure first, then completing the fissures, and finally dividing the bronchus (Roviaro et al, 1993; Kirby et al, 1993; Yim et al, 1996). The

advantage of this strategy was that it was immediately familiar for conventional thoracic surgeons – all that was required was getting used to doing the same operation via smaller wounds. The anatomy and intra-thoracic views were essentially familiar, and this made it simpler for surgeons to take the leap into the unfamiliar world of video images. Again, early reported results were encouraging with low mortality and short hospital stays.

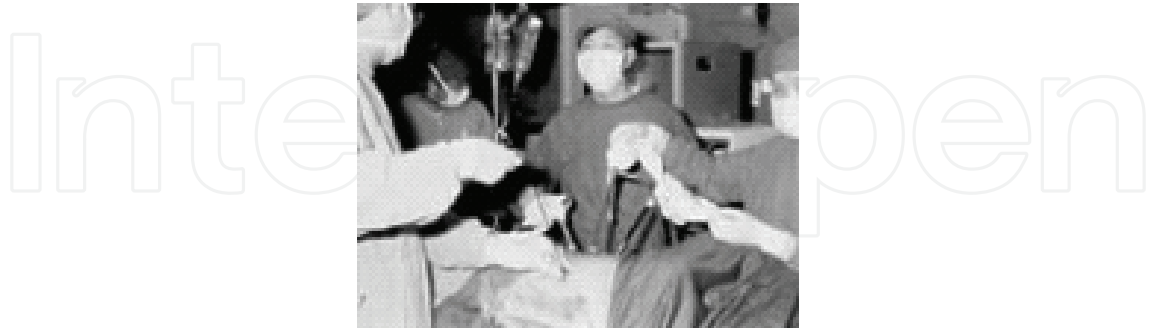

Fig. 1. Professor Anthony Yim was a pioneer of VATS lobectomy in Asia, developing some of the fundamental techniques of this new surgical approach in the 1990s. His work played a pivotal role in establishing VATS lobectomy as a key pillar of modern thoracic surgery. As seen in this early photo from Hong Kong, the basic elements used in the early days of VATS would remain very familiar to the VATS surgeon of today.

However, it was gradually realized that simply copying the open thoracotomy approach (hilum, then fissure, then bronchus) was not necessarily ideal when performing VATS (Roviaro et al, 2000). In particular, the relatively fixed positions of the delicate hilar vessels made them hazardous to isolate and ligate individually. The rigidity of the ribs, the narrowness of the intercostals spaces, and the lack of angulation of the early staplers meant that stapler insertion around the vessels were often difficult - sometimes perilous - undertakings. Some surgeons preferred traditional ligature of the vessels with thread, but this in turn can be limited by the difficulty of intracorporeal knotting through small incisions, especially in patients with deep chests or tight intercostals spaces. The problem is only partly solved with the use of specially designed knot-pushers (Yim & Lee, 1995).

It was only gradually appreciated that the slightly different views and access presented during VATS may require slightly different surgical strategies compared to open thoracotomy. With a conventional postero-lateral thoracotomy, looking straight down into the chest while standing behind the patient made it logically to employ a fissure-first or a posterior-to-anterior dissection strategy. With VATS, where the camera is usually placed at a lower level than the working port(s), this is often more difficult. Instead, working in an anterior-to-posterior direction, tackling vein the artery then bronchus, seemed to work better. The pulmonary vein is almost always easiest to approach first with the video-thoracoscope, with little overlying tissue obscuring it. Once divided, the pulmonary artery branches are usually easy to expose without having to dissect laboriously through often fused interlobar fissures. Indeed, adept use of the video-thoracoscope can make this dissection of the arteries from this more medial aspect of the lobe a much more feasible proposition than with open thoracotomy. Dr Robert McKenna was among the first to advocate such a strategy (McKenna, 1994), and the gradual acceptance of this approach as the mainstream meant that most VATS surgeons nowadays tend to stand anterior to the patient when performing a lobectomy, instead of behind the patient as during a lobectomy via postero-lateral thoracotomy.

By the mid-1990s, the basic technique of VATS lobectomy had become progressively better defined. Certain key concepts were becoming consolidated into the maxim of the VATS surgeon. The ribs were not to be spread. Hilar vessels were to be individually isolated and divided. The sequence of hilar dissection may differ from open surgery. It was also becoming evident that staplers were a quintessential component of a VATS lobectomy, even if conventional ligation and suturing could still be used in some cases. With the key ingredients in place, VATS lobectomy appeared set to take on the thoracic surgery world.

#### **4. The rise and fall of early VATS lobectomy**

In establishing any new surgical approach, it is first necessary to demonstrate its safety for patients. With VATS lobectomy, the results of early case series universally ranged from good to excellent. The overall surgical mortality of 0-2% for VATS compared favorably to the conventional technique (Yim et al, 1998a; McKenna et al, 1998; Sihoe & Yim, 2008). Major complications and post-operative morbidity from VATS resections are relatively uncommon (Yim & Liu 1996; Walker, 2000), and minor complication rates are no higher than with open thoracotomy. Tumor implantation following VATS was an early concern (Downey et al, 1996). However, even in a series in which wound protection was not routinely carried out, port site recurrence was noted in only 0.26% (Parekh et al, 2001). This already low figure could be further minimized by routine use of a wound protector, gentle handling of tissue, and copious irrigation of the hemithorax prior to closure (Sihoe & Yim, 2008). Early studies further showed that VATS took similar operating times as open surgery, but consistently produced similar or lower levels of blood loss (Demmy & Curtis, 1999; Sugiura et al, 1999).

In return for equivalent safety as open surgery, VATS delivered the promise of less post-operative pain for patients. Early evidence confirmed that patients who undergo resections via the VATS approach experience less immediate post-operative pain than those having the thoracotomy approach. This has been documented in several large case controlled studies either by objective assessment in terms of analgesic requirements (Yim et al, 1996; Walker et al, 1996), or subjective assessment in terms of pain scoring, usually in the form of a visual analogue scale (Giudicelli et al, 1994; Yim et al, 1996; Demmy & Curtis, 1999). A trend for reduced post-operative analgesic requirement was also seen in early studies comparing VATS with thoracotomy for lobectomy (Kirby et al, 1995; Sugiura et al, 1999). The reduced pain translated into faster recovery, resulting in significantly shorter hospital stays and earlier return to pre-operative work or activities (Demmy & Curtis, 1999; Sugiura et al, 1999).

By the mid to late 1990s, there was already widespread interest in this minimally invasive approach to lung resection surgery. Although relatively few surgeons were actively performing lobectomies this way, the rise of VATS was strikingly reflected in the large volumes of publications in this field. By the turn of the century, the number of papers published in indexed journals on VATS or 'thoracoscopic' lobectomy was being counted in hundreds. It seemed that VATS lobectomy would soon replace open lobectomy in our specialty, so popular was the approach becoming in academic circles. However, this honeymoon period was abruptly brought to a halt.

An early, small, multi-institutional, randomized, prospective study of lobectomy performed through VATS compared to thoracotomy showed no significant benefits for using VATS in terms of pain reduction (Kirby et al, 1995). In another cross-sectional, questionnaire-based study, Landreneau and colleagues reported that the incidence of chronic post-operative pain

at one year following VATS was also not different from thoracotomy (Landreneau et al, 1994). Over the years, these studies have been frequently quoted by opponents of VATS to suggest that the benefits of VATS may not extend to the long-term or were not clinically important. Very soon, a number of similar papers followed suit, questioning whether VATS gave patients any real benefit at all. In a separate study comparing VATS and open lobectomy, no statistical differences could be found in the pain assessment after 1 week, nor were any differences detected between groups with respect to respiratory muscle strength or 6-minute walking distance (Nomori et al, 2001). Without doubt, these reports slowed the general acceptance of VATS lobectomy by surgeons in some countries for a number of years. Unsurprisingly, a survey of the General Thoracic Surgery Club members in 1997 showed that the majority considered this application unacceptable (Mack et al, 1997). In that survey, 60% of respondents used VATS less than 20% of the time and 38.1% expressed concern regarding overuse. In particular, several concerns were raised. First, the safety of fine anatomical dissection of the hilum in an essentially closed chest was questioned. Second, there was skepticism over the adequacy of clearance for oncological lung resections with curative intent. Third, although the short term benefits of VATS to patients were intuitively obvious, its long term advantages over conventional surgery remained unclear. Fourth, the relatively high costs of the endoscopic equipments and VATS-related consumables cast doubt on the cost-effectiveness of this.

Clearly, before VATS lobectomy could progress further as a viable surgical option, these concerns needed to be fully addressed. The pleasant surprise was that not only did the subsequent soul-searching by VATS proponents overcome these obstacles, it also revealed a great deal about the fundamental principles of lung cancer surgery itself.

## 5. Defining VATS lobectomy

When contemplating why some reports of VATS were emerging showing poorer than expected outcomes, it soon became clear that not all those reports were describing the same operation. Careful comparison of published reports confirmed that the 'VATS lobectomy' being reported was not a unified technique, but several variations existed (Yim et al 1998b; Sihoe & Yim 2008). During the initial scramble to become the first to report results with this new surgical technique, this procedure was developed almost simultaneously at different centers, with each unit carrying its own characteristics (Brambridge, 2000). Not surprisingly, they did so with little consensus over some details of the technique. For example, how long an incision does one allow for a utility "minithoracotomy" before it becomes a "thoracotomy"? How often should one operate through the minithoracotomy as opposed to the video monitor? How much rib spreading can we afford before the benefits of minimal access surgery are lost?

As a result of this lack of standardization in defining the VATS lobectomy procedure, some authors had been loosely applying the term "VATS" to describe any thoracic surgery in which a video-thoracoscope is prepared, often for little more than illumination of the thoracic space while the operation is performed essentially via an open approach (Yim et al 1998b). In some instances, some authors were even tolerating a degree of rib-spreading when performing supposed 'VATS lobectomy' (Nomori et al, 2001). The number and position of ports used also varied considerably between centers. At first, the VATS community was very tolerant of such variations (Sihoe & Yim 2008). After all, the thinking went, how did it matter whether the surgeon was looking at the monitor throughout the

operation or frequently chose to peek through the wounds directly? As it turned out, it mattered a great deal.

In a couple of landmark papers, Shigemura and colleagues compared three well-defined surgical approaches for lobectomy: 'complete' VATS (c-VATS) using purely endoscopic techniques with 100% monitor vision without rib-spreading minithoracotomy; 'assisted' VATS (a-VATS) performing the main procedures via rib spreading and using a minithoracotomy (10 cm long) with both monitor and direct vision; and open thoracotomy (20 cm long) with direct vision only (Shigemura et al, 2004 & 2006). In these studies, the average operative time was longer for c-VATS ( $246 \pm 47$  minutes) than for a-VATS ( $169 \pm 27$  minutes) or open surgery ( $159 \pm 28$  minutes) ( $P < 0.05$ ), but estimated blood loss was lower for c-VATS ( $96 \pm 65$  mL), and there was no significant difference in the number of dissected lymph nodes. Recovery time objectively analyzed by an accelerometer was shorter in patients undergoing c-VATS than in patients undergoing a-VATS or open surgery ( $p < 0.05$ ). Median length of hospitalization was shorter for patients undergoing c-VATS ( $11.8 \pm 2.7$  days) than for patients undergoing a-VATS and open procedures ( $P < 0.05$ ). It was therefore elegantly demonstrated that strict adherence to a completely endoscopic approach could give measurably better outcomes. In effect, it became no longer possible to consider any compromise in technique (as in a-VATS) as acceptable when describing a proper VATS lobectomy.

As a consequence of this realization, VATS surgeons have now applied much stricter definitions when describing VATS lobectomy. The Cancer and Leukemia Group B (CALGB) 39802 trial of the American Society of Clinical Oncology has produced perhaps the most authoritative and accepted definition of the approach thus far (Swanson et al, 2007). In this trial of the safety and feasibility of c-VATS, VATS lobectomy has been defined by the following criteria: no rib spreading; a maximum length of 8 cm of the access incision for removal of the lobectomy specimen; individual dissection of the vein, arteries, and airway for the lobe in question; and standard node sampling or dissection (identical to an open thoracotomy). All specimens were placed in an impermeable bag and removed through the access incision. This definition carries the key points emphasized by the pioneers of VATS lobectomy to reduce surgical access trauma, filtering out 'pseudo-VATS' techniques that gave compromised results (Yim, 2002; Sihoe & Yim, 2008). However, it also allowed enough flexibility for individual surgeons to adapt the approach to their own tastes – as will be discussed below.

Once the definition of VATS lobectomy was re-established, it became once more possible to clearly demonstrate the benefits of the minimally invasive approach over thoracotomy. Since the turn of the century, we have witnessed a second burst of publications espousing the virtues of VATS, no less compelling than the first burst of the early to mid 1990s. A large systematic review of 39 papers involving over 6000 patients compared VATS with thoracotomy with the majority of those papers published since the turn of the century (Whitson et al, 2008). Acknowledging the CALGB definition of VATS lobectomy, this study once more reaffirmed that compared with thoracotomy, VATS lobectomy was associated with significantly shorter chest tube duration, shorter length of hospital stay, and improved survival at 4 years after resection. Furthermore, in a secondary analysis of data from the American College of Surgeons Oncology Group Z0030 randomized clinical trial comparing VATS with open lobectomy for lung cancer, it was also found that VATS gave advantages (Scott et al, 2010). In summary, VATS gave less atelectasis requiring bronchoscopy (0% vs 6.3%,  $P = 0.035$ ), fewer chest tubes draining for longer than 7 days (1.5% vs 10.8%;  $P = 0.029$ ), and shorter median length of stay (5 days vs 7 days;  $P < 0.001$ ).



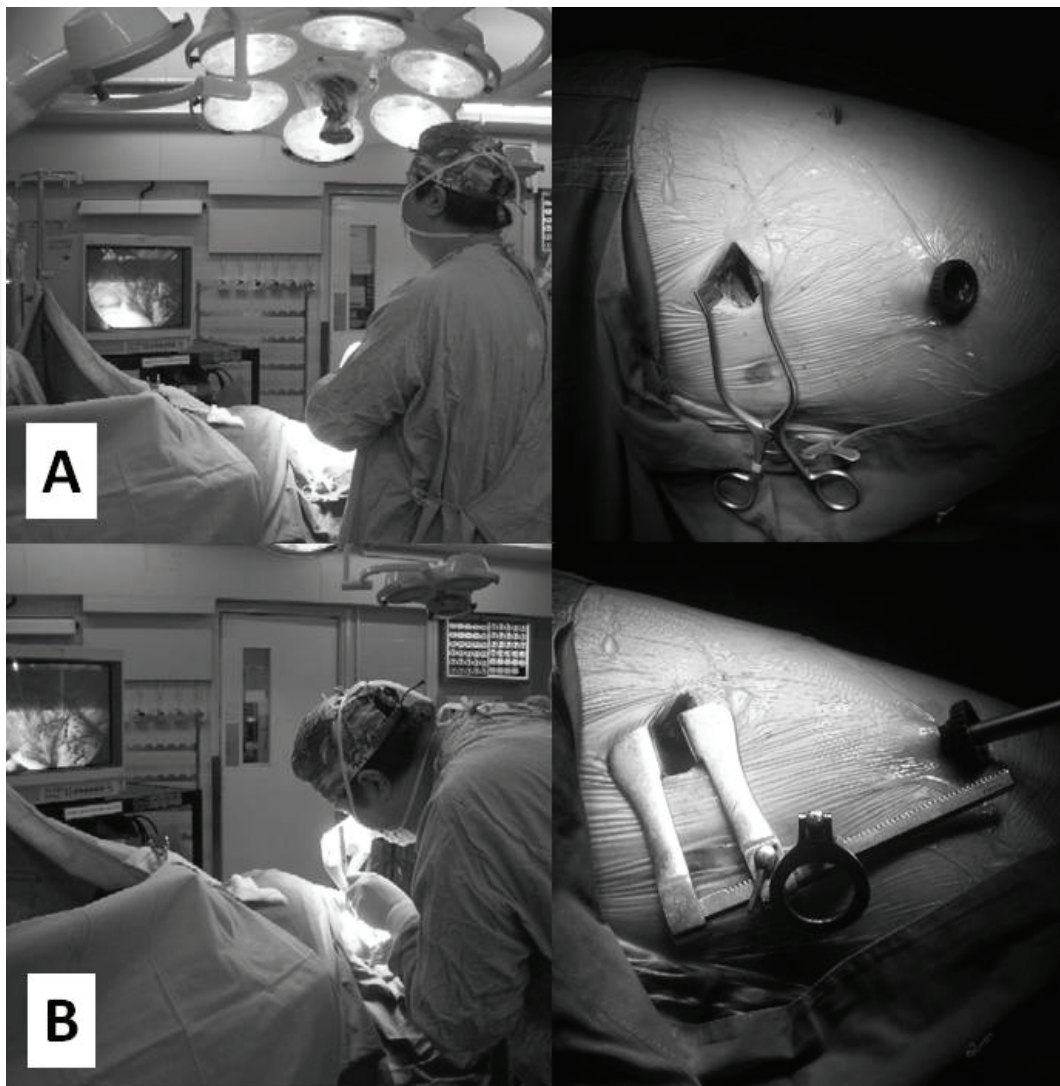


Fig. 2. It is actually not difficult for the casual observer to distinguish whether 'complete' VATS or 'assist' VATS is being performed, even if the wounds appear very similar in size at the end of the operation. In 'complete' VATS (A), the surgeon operates using monitor vision exclusively and can therefore stand comfortably upright throughout the operation. Only gentle skin retraction is occasionally used at the utility port. In 'assisted' VATS (B), the surgeon operates some or most of the time using direct vision via the utility port and consequently is often seen stooping over the patient to 'peek in'. To allow enough room for both direct vision and instrumentation through that port, some degree of rib retraction must typically be used.

It is therefore confirmed that VATS gives clinical advantages once clearly defined. However, this in turn raises the question: 'why?' What is so special about the criteria used for defining VATS that they can significantly impact on outcomes?

Looking at the four listed criteria of the CALGB definition, it is clear that the length of the main incision is not that important. Even when a large number of reports using a large range of wound lengths are considered together, the advantage of VATS over thoracotomy is well maintained (Whitson et al, 2008). Neither is the use of individual isolation-ligation of the hilar structures that important - as evidenced by the excellent results reported by

surgeons using a simultaneous stapling technique (Lewis et al, 1992; Lewis, 1995). Even the extent of lymph node dissection is not the critical issue, as similar outcomes in terms of morbidity are seen regardless of how much dissecting is done (Sagawa et al, 2002; Watanabe et al, 2005; Denlinger et al, 2010). What is left of the CALGB criteria is therefore perhaps the most important: avoidance of rib-spreading.

It has been demonstrated that pain or aching can occur in up to 50-70% of patients at two months or more after thoracotomy (Rogers & Duffy, 2000; Karmakar & Ho, 2004). In 5% of these patients, the pain has been described as 'severe and disabling,' and over 40% of patients may still have some degree of pain at one year after surgery. Patients with such post-thoracotomy pain typically describe their pain as being burning, aching, electrical and/or shock-like in quality (Benedetti et al, 1998a; Rogers & Duffy, 2000), and responding poorly to the use of opiates (Benedetti et al, 1998b). These characteristics are the same as those of recognized neuropathic pain syndromes, such as post-herpetic neuralgia and diabetic peripheral neuropathy (Nicholson, 2000; Laird & Gidal, 2000). These all suggest that one of the key mechanisms of post-thoracotomy pain may be neuropathic. Specifically, the rib-spreading during thoracotomy may be causing substantial compression and hence neuropraxic damage to the intercostals nerves. Emerging physiological studies are now gradually confirming this hypothesis (Benedetti et al, 1998a; Rogers et al, 2002; Maguire et al, 2006; Bolotin et al, 2007). In turn, this means that the benefits of VATS over thoracotomy may to a large degree be explained by the eschewing of rib-spreading and intercostals nerve trauma.

This understanding not only helps in lowering morbidity after thoracotomy (such as by increasing use of VATS), but also in improving outcomes after VATS itself. This is because VATS does not absolutely eliminate intercostal nerve trauma as will be discussed below, and this understanding gained by simply appreciating the fundamental definition of VATS may also help in its treatment.

## **6. Improving the validation of outcomes following VATS lobectomy**

Besides honing of the definition of VATS lobectomy, another key factor in the resurgence of this surgical approach since the 1990s has been the improvement in quality of the clinical research published to investigate its worth.

Following from the early success of laparoscopy in abdominal surgery, initial reports on VATS focused on the benefits it promised in terms of reduced pain with the smaller wounds. But how can pain be accurately assessed? Most clinical studies even today use patient self-reporting of levels of pain. The most common self-reporting tools are the Visual-Analog Scale or a simple 10-point numeric score. These are very simple to use and readily understood by both patients and fellow clinicians. However, they are well recognized to be subject to a wide range of confounding variables. For example, these may include patient socio-economic factors, chronic pain or analgesic use pre-operatively, other sources of post-operative satisfaction or dissatisfaction, and so on. The result is both a certain degree of unreliability and considerable variance in the scores collected. The latter in particular may have contributed to some of the more negative findings about VATS in the aforementioned studies of the mid and late 1990s (Landreneau et al, 1994; Kirby et al, 1995; Nomori et al, 2001). Other methods to quantify pain directly are also problematic. More sophisticated pain scores - such as the McGill Pain Scale - have been suggested. However, these are not

tailored for use in post-operative patient, and they are often too complex and unwieldy to use in the setting of an acute surgical ward. Counting the use of analgesics is also not ideal. If a standardized post-operative protocol of regular analgesic is used, not enough difference may be shown between VATS and open patients. However, if a very flexible 'as required' analgesic regimen is used the results will again be confounded by factors such as individual patient pain thresholds and prejudices about taken medications. Early reports describing such results also demonstrated that it is hard to compare results sometimes between different cohorts or studies. For example, does a VATS patient taking two tablets of a non-steroidal anti-inflammatory drug daily have more or less pain than a thoracotomy patient taking a total of 10 tablets of a mild opiate over five days? For all these reasons, early studies reporting the alleged benefits of VATS lobectomy came in for considerable criticism over the years.

Learning from these lessons, VATS surgeons have taken to using surrogate measures of reduced morbidity. If pain is reduced, would this not be reflected in shorter hospital stays and earlier return to work? Again, almost every clinical study on VATS suggests that the minimally invasive approach shortens lengths of stay, but again such results are prone to bias. Although chest drain durations can be crudely regulated by defining drainage volume and air leak cessation criteria triggering removal, lengths of stay are much more subject to confounding variables such as clinician desire to send a VATS patient home or patient keenness or reluctance to leave hospital just days after major surgery. It is already recognized that, for example, that in general, the hospital length of stay in Asian institutions is longer than in North American institutions, reflecting the influence of cultural factors that undermines the usefulness of this outcome measure (Whitson et al, 2008). The same can apply to early reports using return to work to demonstrate the benefit of VATS.

Further efforts to display the morbidity reduction with VATS are now coming to fruition though. One of the methods is to compare pre- and post-operative Quality of Life (QoL). There is increasing realization that post-operative QoL is very important to the cancer patient. It has been shown that patients tend to be more concerned about post-operative functional status and performance in activities of daily living than in abstract survival statistics (Cykert et al, 2000). On a more practical level for VATS researchers, many excellent and well-validated QoL assessment tools are widely available. One detailed survey used the EORTC QLQ-C30 and EORTC QLQ-LC13 questionnaires designed to assess QoL in lung cancer patients, supplemented by a self-designed, nine-item surgery-specific questionnaire (Li et al, 2002). The survey was conducted on patients who received lung resections with curative intent for early stage lung cancer either by a VATS approach (median follow-up time of 33.5 months) or by an open thoracotomy approach (39.4 months). Statistically comparable levels of QoL and functional status were noted in both groups, although there was a trend for the VATS group to show better QoL scores and lower incidences of fatigue, dyspnea, coughing, and pain. Since then, an increasing number of papers have confirmed that VATS offers patients better QoL following lobectomy than thoracotomy, providing a much more reliable, quantifiable proof of its advantage (Handy et al, 2010; Rueth & Andrade, 2010).

Another important but often overlooked measure of both post-operative pain and QoL after thoracic surgery is the impairment of shoulder function following thoracic surgery. Shoulder function can be impaired following a thoracotomy by a combination of neurological injury during patient positioning, division of shoulder girdle muscles, direct

injury to the long thoracic nerve, and as a result of the significant post-operative pain from the wound. By reducing such surgical trauma and post-operative pain, VATS lung resections may reduce the incidence of post-operative shoulder dysfunction. Previous studies have reported that the strengths of the latissimus dorsi and serratus anterior muscles may be better preserved following VATS when compared to thoracotomy (Landreneau et al, 1993; Giudicelli et al, 1994). In a prospective study, Li et al reported that short-term shoulder strength and range of movement were significantly better in patients who received VATS pulmonary resection than those who received thoracotomy (Li et al, 2003). Again, such studies provide more objective evidence of morbidity reduction after VATS.

There is emerging evidence that VATS causes less depression of pulmonary function after lung resection surgery than thoracotomy. Kaseda reported that both the forced expiratory volume in one second (FEV1) and forced vital capacity (FVC) values measured at three months post-operatively were significantly preserved relative to pre-operative values in patients who underwent lobectomy by a VATS approach compared to those receiving a thoracotomy approach ( $p < 0.0001$ ) (Kaseda et al, 2002). In another similar study, post-operative PaO<sub>2</sub>, SaO<sub>2</sub>, peak flow rates, FEV1 and FVC were all found to be better on post-operative days 7 and 14 in patients who had VATS rather than thoracotomy for lung resection (Nakata et al, 2000). Blood oxygenation, lung diffusion capacities, 6-minute walk test results, and recovery of vital capacity and cardio-pulmonary function after surgery all tend to be better after VATS than after various forms of open thoracotomy for pulmonary resections (Nagahiro et al, 2001; Nomori et al, 2002 & 2003a).

The most exciting attempt to prove that VATS causes less trauma than thoracotomy have come from studies looking at the impact of surgery on inflammatory and immune markers. There is now a wealth of literature showing that the body's immune function is better preserved following laparoscopic surgery compared to its open counterparts in general abdominal surgery. In thoracic surgery, one study has now demonstrated that patients with clinical stage I lung cancer undergoing VATS lobectomy had significantly reduced post-operative release of both pro-inflammatory (interleukins 6 and 8) and anti-inflammatory cytokines (interleukin 10) into the plasma compared to those having conventional resection (Yim et al, 2000a). Similar findings were also reported in a smaller Japanese study which showed significantly reduced cytokine release (interleukins 6 and 8) into the pleural fluid in the VATS lobectomy group compared to the open group (Sugi et al, 2000a). In a small randomized, prospective study from Edinburgh, it was also shown that VATS lobectomy was associated with a lesser effect on the post-operative fall in circulating T (CD4) cells and natural killer (NK) cells (Leaver et al, 2000). Lymphocyte oxidation was also less suppressed by VATS compared to open surgery. The same group also found that a range of acute phase responses - including C-reactive protein, interleukin 6, tumor necrosis factor, P-selectin, and oxygen free radical activity - were also significantly less amongst the VATS patients (Craig et al, 2001). A separate Hong Kong study found that NK cell levels were suppressed to similar degrees on the first post-operative day following both VATS and thoracotomy lung resections for non-small cell lung cancer, but that T lymphocyte numbers were significantly more reduced following thoracotomy (Ng et al, 2005). The levels of NK cells subsequently rose more quickly in the VATS group. These results suggest that the VATS approach was associated with less, and quicker recovery from, post-operative immunosuppression following lung resection surgery than the thoracotomy approach.

In essence, there is evidence now to believe that VATS is associated with less perturbation in both the humoral and cellular immune functions compared to open surgery, at least in the short term (Walker et al, 2000). So far, there have been no reports demonstrating that VATS pulmonary resection confers a lower incidence of post-operative infection than the open approach. It has also been hypothesized that as immunosurveillance may play an important role in the progression of cancer, surgically induced immunosuppression may predispose to increased tumor growth or recurrence. Whether better preservation of the immune system by VATS may lead to improved long term survival is unclear but certainly deserves further investigation (Yim, 2002).

The ongoing quest to show the advantages of VATS lobectomy over open surgery has succeeded not only in emphatically meeting this primary objective, but also in teaching thoracic surgeons some valuable lessons. The need to find more reliable assessors for peri-operative morbidity has been underscored. This in turn has focused attention on matters important to the patient – such as QoL and post-operative function – rather than just abstract statistics interesting to the surgeon. The extension of the quest to demonstrate less physiological harm to the body using VATS has also begun to highlight the potential oncologic advantage of VATS lobectomy – as will be discussed below.

## 7. The oncologic efficacy of VATS lobectomy

Critics of the VATS approach for lung cancer research will say – quite rightly – that all the above benefits of VATS are meaningless if the operation cannot fulfill its primary obligation to provide effective oncologic treatment. As mentioned above, the focus of these early doubts on the oncologic efficacy of VATS lobectomy included: whether VATS allowed fine anatomical dissection for individual isolation-ligation of the hilar structures; whether VATS was a cost-effective means of delivering oncologic therapy; and whether VATS gave adequate clearance for oncological lung resections (Mack et al, 1997). The concern over the ability of VATS to allow lobectomy using an individual isolation-ligation strategy has been resoundingly answered by almost two decades of successful surgery around the world.

The question of cost-effectiveness arose because many centers initially balked at the high consumables costs and potentially longer operating times involved in a typical VATS lobectomy. However, by choosing the right patients for this technique, using mainly conventional instruments, and relying on ligation and suturing in preference to staplers where possible, the consumable costs could be minimized (Yim, 1996). More importantly, VATS promises shorter hospital stays and fewer complications. The savings gained by the shorter stays and having to treat fewer complications tend to offset the higher consumables costs. One study comparing VATS versus open resections for cancer showed that the overall hospital charges were therefore possibly even lower when VATS is used (Nakajima et al, 2000). In experienced hands, VATS major resection could also be as quick an operation as the open approach because less time is needed to open and close the chest. Most centers regularly performing VATS lobectomy no longer find any significant difference in operating times between VATS and open lobectomies (Sihoe & Yim, 2008). Nowadays, the challenge facing VATS lobectomy is ironically not the fear of higher consumables costs, but rather the expectation by patients and/or insurers of lower overall costs – which may even affect compensation for the surgeon in some regions.

The question about whether VATS gives adequate oncologic clearance requires a more complex answer. After all, an anatomic lobectomy is an anatomic lobectomy whether it is

done by a minimally invasive or open approach. How is it possible to demonstrate whether a lobe resected by VATS is any more or less a lobe than one removed via thoracotomy? Instead, the battle of the adequacy of VATS is being waged not over the quantity of the lobe itself, but over the amount of lymph node tissue being resected. Opponents of VATS have long suggested that even if a lobe can be removed by VATS, the approach does not allow radical nodal clearance. The debate over the relative merits of lymph node sampling versus lymph node dissection after lung cancer resection is ongoing and beyond the scope of this chapter. However, even if radical nodal dissection is desired, there is now growing evidence that the adequacy of VATS radical lymphadenectomy approaches that of open surgery both in terms of number and mass of nodal tissue removed. In one study, an open thoracotomy immediately after VATS nodal dissection in the same patient could yield only 3% more nodal tissue – an insignificant amount (Sagawa et al, 2002). Two retrospective studies on non-contemporary cohorts of VATS and thoracotomy patients found that VATS gave similar or slightly less nodal tissue, but survival and staging were not affected (Watanabe et al, 2005; Denlinger et al, 2010). In a more recent prospective study of contemporary VATS and thoracotomy cohorts, VATS was confirmed to yield at least as much nodal tissue as thoracotomy regardless of side, lobe or stage of the lung cancer (Sihoe et al, 2011). In addition, VATS gave higher yields at traditionally ‘trickier’ nodal stations such as the subcarinal nodes (possibly because of the better view VATS afforded in such areas), and the 2-year recurrence-free survival was also higher with VATS. It therefore appears that anatomically-speaking there is no longer a case to suggest VATS is not as oncologically complete as open thoracotomy for lung cancer surgery.

The last bastion of resistance against the adequacy of VATS lobectomy must therefore be long-term survival rates. Ultimately, any quantifiably proven similarity between VATS and thoracotomy intra-operatively must be translated into similar ‘cure’ rates post-operatively. Thankfully, a large volume of evidence has been accumulated over the past two decades in this regard. These have consistently demonstrated similar survival rates between VATS and open lobectomy patients (Sugi et al, 2000b; Rueth & Andrade, 2010). However, a trend has long been noticed by VATS surgeons for a trend of longer survival amongst VATS patients. Studies from Japan have time and again reported remarkable 5-year survival rates of around 90% for stage IA lung cancer patients receiving VATS lobectomy (Sugi et al, 2000b; Kaseda et al, 2002; Watanabe et al, 2005). In a 2008 systematic review of 39 studies comparing VATS with open lobectomy, patients who underwent VATS lobectomy were finally confirmed to have improved survival versus patients with open lobectomy (88.4% vs 71%;  $p = 0.003$ ) (Whitson et al, 2008). More recently, another similar systematic review reported that 5-year survival was significantly improved for patients who undergo VATS lobectomy for early-stage NSCLC (VATS relative risk, 0.72;  $p = 0.04$ ), further suggesting that VATS lobectomy is at least oncologically equivalent to open lobectomy (Yan et al, 2009).

It is still premature to declare with certainty that VATS gives better survival than open lobectomy. Nonetheless, many surgeons have already begun to speculate over reasons why this phenomenon should be possible. The theory gaining most recent attention is that of the effect of VATS on peri-operative immuno-surveillance. It has been shown that tumor cells may be shed into the circulation during lung cancer surgery (Yamashita et al, 2000). In other surgical specialties, it has been demonstrated that the body’s own immune system can help kill or remove such circulating tumor cells – a process often called ‘immuno-surveillance’ (Shariat et al, 2002; Wu et al, 2002). In theory, if the body’s immune function is somehow impaired this

may inhibit the peri-operative removal of tumor cells shed during the operation, which can then manifest as subsequent recurrence or metastasis. It has already been mentioned above that studies now show that VATS causing less immune system disruption than open surgery. Therefore, according to this theory, it should be expected that VATS is associated with better long-term survival. At present, this remains fanciful speculation. However, given the impressive speed at which other advantages of VATS are being discovered, it would not be a surprise to see this theory corroborated by new evidence before too long.

## 8. State of the art

The VATS lobectomy that has established itself as a viable – if not superior – alternative surgical approach to open lobectomy is now practiced widely around the world. In some centers, such as in Hong Kong, VATS lobectomy has been routinely performed for the majority of patients with early stage lung cancer since the mid 1990s (Yim et al, 1996). As said above, other countries have taken up VATS lobectomy at a rather slower pace because of lingering doubts generated by the negative reports of the mid to late 1990s. Nonetheless, over the past several years, major centers several other countries have reached this landmark of over half of all lobectomies being performed using the VATS approach – notably the USA and South Korea. What is most noticeable about the current resurgence of VATS lobectomy compared to the initial rise in the early 1990s is that this time most surgeons are performing the operation according to the same consensus definition of what VATS lobectomy should be. The result is that operations in different centers around the world are now much more similar in the basic characteristics: no rib spreading; a single access incision for specimen retrieval; individual isolation-ligation of the vessels; and systematic nodal dissection. Thankfully, within this broad definition, there remains much scope for variations in the details as individual surgeons adapt their technique to their own preferences – some of which are worth mentioning here. VATS surgeons should never be too proud to refuse adapting the practices of others when they are suitable.

Hong Kong was one of the earliest regions where VATS lobectomy was developed (Yim et al, 1998a). Professor Anthony Yim is undoubtedly the pioneer of this technique in Asia, and his groundbreaking work helped establish its role for lung cancer therapy worldwide. But as mentioned above, in these early days many pioneers strove to replicate open lobectomy via the small VATS incisions. Hence, the sequence of hilar structure dissection was essential unchanged from open surgery (Roviaro et al, 1993; Kirby et al, 1993; Yim et al, 1996). For VATS surgeons in Hong Kong, mediastinal lymph node sampling rather than systematic dissection was the norm, and it was initially deemed acceptable to operate whilst occasionally looking through the main wound. However, these practices soon changed. This author teaches surgical trainees that to operate inside the human chest, the surgeon must place three things inside the patient: his right hand, his left hand, and his pair of eyes. In open thoracotomy, the ribs must be spread apart to permit these three things to enter the patient's chest. With VATS, instruments can replace the right and left hands, and the videothoracoscope can replace the surgeon's eyes. In this way, rib-spreading can be totally avoided, giving the patient less surgical access trauma. However, if the surgeon still resorts to looking through the wounds to operate, the eyes must once again share access through one of the ports with the hand (or instruments). The only way this can be possible is if there is some rib-spreading, wound enlargement, and/or increasing torquing at the ports (see Figure 2). Any of these can negate the supposed benefits of VATS.

Therefore, since the 1990s, the practice of VATS lobectomy in Hong Kong has evolved. This author now strictly foregoes any form of direct vision through the wounds, and operates exclusively using video monitor visualization. The assistant is reminded to avoid torquing the video-thoracoscope via the camera port. Because of the leverage, even slight torquing could result in significant pressure on the intercostal nerve, causing post-operative neuralgia (Yim, 1995). The rigid plastic camera port can be slid back along the thoracoscope out of the wound after the thoracoscope is inserted into the chest, allowing more flexibility of the thoracoscope in the chest with less torquing at the wound (Sihoe & Yim, 2008). A three-port strategy is used, with two 10mm incisions for the camera and instruments respectively, and a third 4cm utility port in the fourth or fifth intercostals space (with no rib-spreading) for specimen retrieval. Both the surgeon and assistant stand anterior to the patient, and both watch the same video monitor throughout the operation, facilitating camera handling by the assistant (instructions from the surgeon are easier to follow without the hindrance of paradoxical movement or resorting to awkward camera orientations). Dissection is from an anterior-to-posterior direction, typically taking the pulmonary vein first, then pulmonary artery the bronchus. The fissures are taken last of all, and staplers are used in a 'fissureless' technique to minimize post-operative air leak (Nomori et al, 2003b). A systematic dissection at all the ipsilateral mediastinal lymph node stations is routinely carried out in all patients.

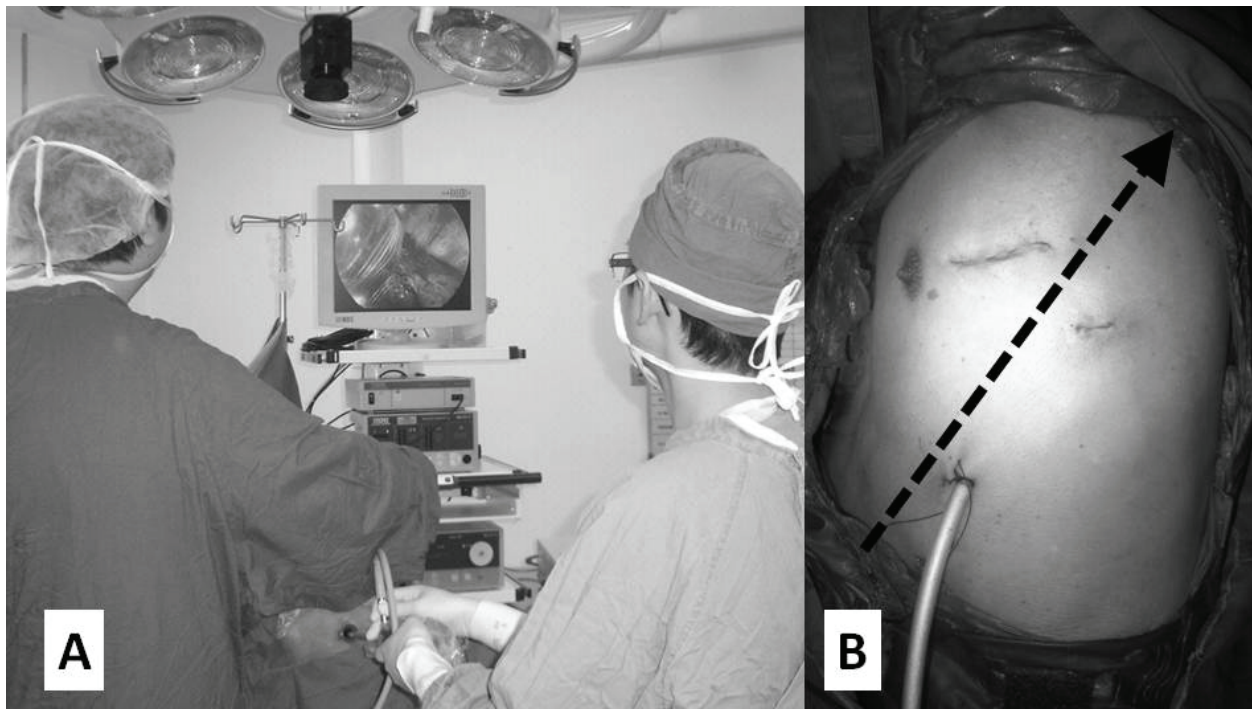


Fig. 3. The photos show the author performing a VATS Left Pneumonectomy (hence the slightly long than usual utility port). (A) Both the surgeon and the assistant stand at the anterior of the patient. (B) The axis of the operation is in an antero-inferior to postero-superior direction as indicated by the arrow. The axis begins at the assistant, goes through the camera port (here used to place the chest drain at the end of the operation), and proceeds straight on to the video monitor. The surgeon 'straddles' the axis anterior to the assistant, with the right and left hands operating comfortably via ports placed either side of this axis. By sharing the same axis and the same monitor, there is better co-ordination between the two throughout the operation and paradoxical camera movements are minimized.



This totally endoscopic c-VATS lobectomy performed in Hong Kong is essentially the same operation found throughout the world nowadays (McKenna et al, 2006; Kim et al, 2010). The basic techniques will be familiar to VATS surgeons from any country: no rib-spreading; surgeon standing anterior to the patient; an anterior-to-posterior strategy; fissureless surgery; and systematic exploration of the nodes. This approach can be summarized as the current state of the art. Certain detail variations exist of course, such as number and size of ports or extent of nodal dissection. However, some VATS surgeons deviate significantly from this basic technique in fine detail (whilst adhering to the same basic principles and definition of VATS lobectomy), and they have achieved success with their modifications. It is worthwhile to consider these variations.

Instead of always standing at the anterior side of the patient, surgeons at several centers in Asia prefer always standing on the right side of the operating table for a VATS lobectomy, regardless of whether the operation is on the right or left lung. In other words, the surgeon would stand anterior to the patient for a left lung operation, but posterior to the patient for a right lung operation. The rationale for this is because for a right-handed surgeon, it is usually ergonomically more comfortable to reach around the patient with the dominant right arm and face the video monitor placed in a more cephalad direction. Proponents of this positioning claim that for the surgeon to stand on the left side of the table, the right arm can be tucked too close to the surgeon's own body for comfortable operating. They claim that by always standing on the right side of the patient, back problems may also be possibly avoided.

Dr Tadasu Kohno of Tokyo, Japan is another leading VATS surgeon in Asia who has developed a rather distinctive strategy for surgeon and assistant positioning (Mun & Kohno, 2008). In this strategy, the surgeon stands posterior to the patient and the camera-holding assistant anterior to the patient. The camera is inserted in the port most anterior on the patient, with the other working ports closer to the surgeon. To ensure the correct orientation of the image on the video-monitor for the surgeon, the camera on the video-thoracoscope is turned so that 'upwards' on the camera and image is towards the anterior of the patient. Because the video-thoracoscope enters the chest via the most anterior camera port, this usually means the camera itself is held almost upside-down by the assistant. The advantage of this strategy is that it best approximates the surgeon's position and views during a traditional open lobectomy via a postero-lateral thoracotomy. This facilitates the transition from open to VATS lobectomy for some surgeons. However, handling the camera in a virtually upside-down position on the opposite side of the operating table from the surgeon requires a very skilled and experienced assistant.

Dr Dominique Gossot of Paris, France also describes an interesting approach to VATS lobectomy (Gossot, 2008). Like Dr Kohno, he also prefers the surgeon standing behind the patient. The peculiar feature of Dr Gossot's technique is that he doesn't create a utility or access port right at the beginning of the operation. He also does not use the more common 3-port strategy. Instead, four to five ports are used to perform the entire operation, with ports sizes ranging from 3mm to 15mm. Only after the lobe has been resected is a utility port created for retrieval of the specimen. It is claimed that by leaving the utility port until the end of the operation, 'use' of this slightly longer incision is only for a brief time and surgical access trauma is minimized. Critics may claim that no rib-spreading is used in modern VATS lobectomy anyway so the size and duration of the utility port does not really contribute significantly to morbidity. Furthermore, whether a shorter duration of having a

utility port can ever compensate for having one or two more ports than conventional c-VATS is also debatable. Only time will tell whether any one strategy is better than the others.

These are just a few examples of the many variations on a theme of VATS lobectomy that exist today. Describing them is just meant to illustrate that the strict modern definition of this operation can still accommodate a range of different interpretations. A sage Chinese leader once famously said: "It doesn't matter if the cat is black or white as long as it catches mice". In a similar way, surgeons should be free to experiment with various technique details to find one suiting their own styles, provided the core principles of VATS lobectomy are adhered to and ensure the patient benefits from the minimally invasive approach.

Regardless of the exact details of the operation used, patients today can expect rapid recovery after a VATS lobectomy (Whitson et al, 2008; Yan et al, 2009; Rueth & Andrade, 2010; Scott et al, 2010). Data collected around the world suggest that mortality is no higher than after open lobectomy, and morbidity rates (typically around 15-20%) are usually lower. Chest drain durations average around 4-5 days, and patients are generally discharged around 4-7 days after surgery. For an ultra-major operation that a mere 30 years ago had a mortality rate approaching 10% and a complication rate of almost 60% (Wilkins et al, 1978; Keagy et al, 1985), these modern figures achieved with VATS are commendable.

## 9. Current challenges, emerging solutions

Despite the current success and popularity of VATS lobectomy, there is no room for VATS surgeons to be complacent. For a start, VATS lobectomy can no longer claim to be the least traumatic mode of curative therapy for lung cancer. Today, ablative therapy (using radio-frequency or microwave energy), stereotactic ('cyberknife') radiosurgery, and stereotactic body radiation therapy (SBRT) all have better claims for that title (Fernando et al, 2005; Pennathur et al, 2009; Crabtree et al, 2010). SBRT is now wholly claimed by Oncologists, and there is no guarantee that surgeons will gain control of ablative and cyberknife therapy. Regardless of the survival rates achievable with these new treatment modalities, to the lay patient they represent an astonishing option that may 'treat' cancer without requiring major surgery. Unless the surgical option is made more palatable for patients, there is no doubt that increasing numbers of patients who are marginally or even completely suitable for surgery may be tempted away from the operating room.

To make VATS lobectomy even better, it is first necessary to appreciate that it is not perfect. First of all, despite the smaller wounds and avoidance of rib-spreading, VATS does not make lobectomy pain-free. It has been found that 52.9% of patients receiving VATS pleurodesis for pneumothorax (in which no rib-spreading is used) experience paresthetic chest wall discomforts which are distinct from classical localized wound pain (Sihoe et al, 2004a). This reported post-operative 'pain' or paresthesia appears characterized by sensations of burning, aching, electrical and/or shock-like in quality - which are all typical of neuropathic pain (Sihoe et al, 2006). In a follow-up study, it was shown that the incidence and nature of the paresthesia remains similar even if the level of surgical trauma is further reduced by performing needlescopic VATS (Sihoe et al, 2005). VATS reduced pain compared to thoracotomy, but was itself still associated with a certain level of neuropathic injury. This injury is most likely caused by the torquing of the video-thoracoscope and instruments at the ports during surgery, and by the placement of a chest tube that is kept for

a few days post-operative. Both of these mechanisms contribute to a degree of intercostals nerve trauma. With this in mind, the surgeon can not only attempt to minimize intra-operative torquing and remove chest tubes at the earliest opportunity, but he/she can also use pharmaco-therapy aimed specifically at treating neuropathic pain. At least one study has now shown that use of Gabapentin - a drug previously used to treat trigeminal and post-herpetic neuralgia - may be effective in alleviating post-operative pain after thoracic surgery (Sihoe et al, 2006). The author now frequently prescribes Gabapentin to patients after VATS lobectomy who experience paresthetic discomforts that are distinct from their sharp, localized wound pain.

To combat pain, another strategy has been to make use of 'pre-emptive' analgesia. Some studies now suggest that a painful stimulus can 'sensitize' the central somatosensory pathways, and hence amplify the response to subsequent painful stimuli (Woolf, 1983; Woolf & Salter, 2000; Dahl & Moiniche, 2004). In theory, any treatment given before or during the operation that can prevent the original painful stimulus from activating this sensitization should therefore reduce the subsequent development and severity of post-operative pain. A randomized trial in patients undergoing needlescopic VATS has now demonstrated that giving local anesthesia at the ports sites prior to making the surgical incisions can significantly reduce post-operative pain for up to a week after surgery (Sihoe et al, 2007). In this author's practice, this concept has been combined with the use of regional neural blockade. In VATS lobectomy patients, a bolus paravertebral blockade using bupivacaine is routinely given after induction of general anesthesia and prior to starting the surgical operation.

Besides pain, the most common complication seen after VATS lobectomy today is air leakage. With the reduced pain, earlier mobilization and better preserved lung function after VATS lobectomy, traditionally common respiratory complications such as atelectasis are increasingly rare. Instead, parenchymal air leakage is not something that is directly influenced by the size of the wounds or non-use of rib-spreading. As a result, air leak rates after VATS lobectomy are generally no different than after open lobectomy. Air leakage is not only the most prevalent postoperative complication after a lobectomy today, it is also the single most common reason for an extended length of hospitalization (Abolhoda et al, 1998). Air leaks occur in up to 58% of patients after a lobectomy, and can persist for 5 days or more in 15-18% of patients (Brunelli & Fianchini, 1999; Isowa et al, 2002; Okereke et al, 2005). Traditionally, if a parenchymal air leak is detected on-table, a variety of surgical techniques can be used to repair it. These include suturing, pleural tent creation, and so on. All of these techniques are possible with VATS, but not necessarily easy to perform given the small ports. Surgical sealants were a potentially easy-to-use solution and previous studies have shown that sealants may help reduce air leaks (Tansley et al, 2006; D'Andrilli et al, 2009). However, for a long time there was no effective means of delivery into the chest via the small VATS wounds. Fortunately, the rise of VATS lobectomy has been paralleled by the development of surgical sealant technology. Modern surgical sealants can now be readily aerosolized and delivered via dedicated endoscopic spray applicators. These make them eminently suitable for use in treating on-table air leaks during VATS. In a recent study looking at the endoscopic spray application of fibrin for on-table air leaks detected during VATS lobectomy, use of fibrin sealant significantly reduced air leak incidence, chest drain durations and lengths of hospital stay (Sihoe et al, 2009). A simple and effective solution for VATS lobectomy's last remaining Achilles' heels is therefore now emerging.

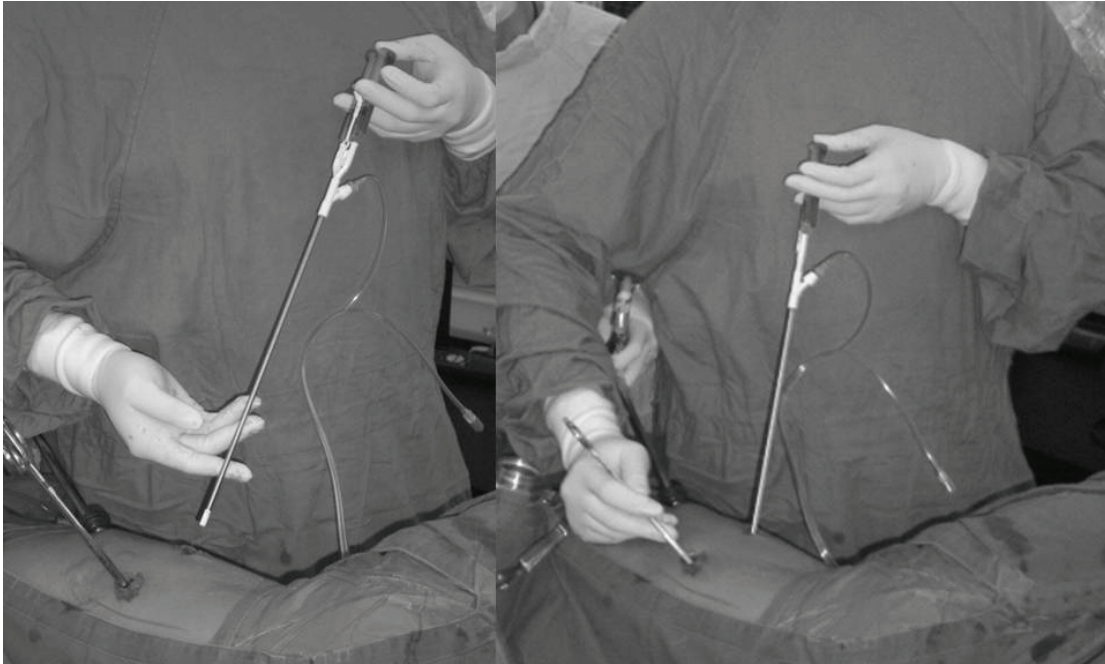

Fig. 4. The latest endoscopic spray applicators allow precise, even and easy delivery of flowable sealants to sites of parenchymal air leak – even via small VATS ports. Evidence is gradually accumulating that support an emerging role for such sealants in selected patients after VATS lobectomy.

It is no use only improving the operation itself if the peri-operative care is not developed to complement the advances. In many traditional thoracic surgery centers, clinical management protocols already exist for how to manage a lung cancer patient who has received lobectomy. In the early days of VATS in Hong Kong, it was noticed that nursing and allied healthcare staff were still managing VATS lobectomy patients according to protocols designed years before for open thoracotomy patients. Mobilization and rehabilitation schedules were slow to take into account the slower recovery of thoracotomy patients, and this meant that VATS patients could not reap the full benefits of the newer minimally invasive approach. Over the past several years, the entire clinical pathway has been re-written in the author's center in Hong Kong to fully complement VATS (Sihoe et al, 2008). The analgesic regime has been revised to reduce the use of opiates – which are both unnecessary given the reduced pain with VATS, and detrimental because the sedation and dizziness caused could delay patient mobilization. In the new VATS pathway, patients are mobilization fully within 24 hours of surgery. Physiotherapy is implemented earlier and more aggressively. Chest drain removal is also expedited. Even post-operative investigations, when a patient opens his/her bowels, and schedules for meeting the patient's relatives are included in the overall clinical pathway package. The literally dozens of items of changes have significantly improved the recovery process of VATS lobectomy patients. Since its implementation, chest drain durations, lengths of hospital stay, rates of complications, and rates of re-admission have all dropped significantly. The lesson learned is that improving operative surgical performance alone must be complemented by appropriate improvements in the ancillary services to bring out the full potential of VATS. However, in the view of this author, using all the above measures to improve surgical outcomes for the individual patient is not the ultimate goal for VATS. Benefiting the individual

patient alone will not ensure the survival of VATS lobectomy in the face of future challenges. Instead, the reduction of morbidity for individual patients must be translated into lowering of thresholds for surgery. If the surgery itself is causing fewer complications and pain, then presumably it can now be offered to patients for whom surgery was previously thought to be 'too high risk'. If this is achieved, then surgery – the only widely established 'cure' for early-stage lung cancer – can reach a larger proportion of the population. 'Marginal' surgical candidates can be offered curative operations instead of compromised therapy (including SBRT) that have only limited chances of achieving tumor eradication.

To this end, some encouraging studies are already emerging. In one study from Hong Kong, VATS lobar and sublobar resection with curative intent was performed in patients with forced expiratory volume in one second on spirometry (FEV1) of <0.8L and/or <50% predicted (Garzon et al, 2006). Patients with such poor lung function would have traditionally been refused any form of curative major lung surgery. However, when VATS was used in this cohort, there was no in-hospital mortality and only a 20% rate of respiratory complications. After a median follow-up of 15 months, only 4% of all patients died of respiratory complications and none of the survivors required home oxygen. In a separate study, VATS and thoracotomy approaches for lung resection with curative intent were compared in lung cancer patients aged over 75 years (Staffa et al, 2010). VATS achieved the same recurrence-free survival rates as open thoracotomy, but at the same time reduced in-hospital complication rates, lengths of post-operative hospital stay, post-discharge complication rates, and also persisting pain at 2 weeks after surgery. Such studies suggest that the list of contra-indications for lung cancer surgery may need to be revised if VATS can be offered. This can potentially offer a hope of effective cure for lung cancer patients previously denied surgery.

## 10. Future directions

Looking ahead, it is already possible to foresee where the continuing evolution of VATS lobectomy may be headed in the near future. Most of these trends are being driven by rapid technological advances. The rise of Endobronchial Ultrasonography (EBUS) may be one of these (Kurimoto & Miyazawa, 2004). With a minute ultrasound probe positioned at the tip of a flexible bronchoscope, the endoscopist can see 'through' the airway walls into the surrounding mediastinal and hilar structures and attempt biopsy of lymph nodes or other tissues. While EBUS is still predominantly being performed by respirologists, it may still play an important role in thoracic surgery. EBUS can be used for routine mediastinal nodal screening in the operating room immediately prior to embarking on a VATS lobectomy. This approach may overcome the aversion of many thoracic surgeons in offering routine mediastinal screening because of the relative morbidity caused by conventional mediastinoscopy. It is also the strongest argument in favor of surgeons taking responsibility for performing EBUS, as surgeons can offer one-stop staging plus therapeutic surgery in the operating (as opposed to staging by the respirologist and then a separate therapeutic procedure by the surgeon). EBUS may also be useful in patients with suspected N2 nodal metastasis who may be candidates for the strategy of upfront neoadjuvant therapy followed by surgery. If EBUS can confirm the metastasis without needing mediastinoscopy, then the mediastinoscopy can be 'saved' until after the neoadjuvant therapy is completed and used for re-staging purposes.

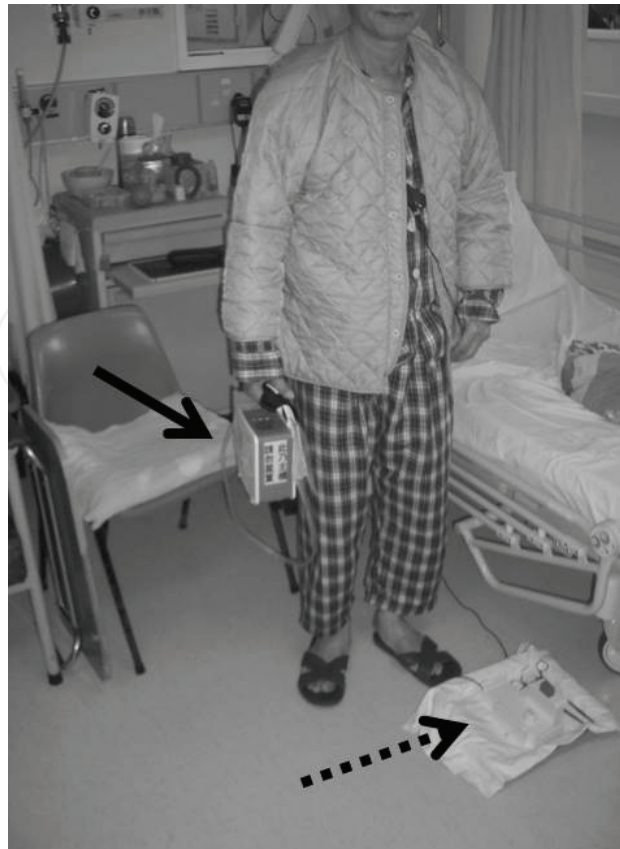


Fig. 5. Using a new portable digital chest drain system (solid arrow), a patient is typically able to mobilize freely within 12-18 hours of a VATS lobectomy. With an inbuilt suction system, the patient's mobility is unrestricted even if suction is required for any reason. When the patient returns to the bedside, the digital drain can simply be placed onto a dock (dotted arrow) which recharges its batteries. Besides promoting post-operative recovery for the patient, the digital drain provides the surgeon an objective, quantified measurement of any air leak via the chest tube. Preliminary clinical evidence suggests that this may improve consistency and hence efficiency of air leak management after VATS lobectomy.

Another emerging technological advance are the new portable digital chest drain systems that have come onto the market over the last few years. Traditional water seal chest drain systems are clumsy and unwieldy. They require attention not to be lifted above the chest level, not to be accidentally tipped over, and not to have the water seal evaporated unnoticed. If suction is required for any reason, connection to an external suction source also effectively ties the patient down like a ball-&-chain restraint. When VATS lobectomy is performed, it is particularly frustrating to see post-operative mobility being restricted not by the surgery but by the use of an old-fashioned chest drain. A modern digital system such as the Medela Thopaz (Medela AG, Switzerland) does away with a water seal altogether, and comes with an inbuilt suction system that maintains a constant, user-set negative pleural pressure without need for any external connection. The result is a compact, portable chest drain that permits complete patient mobility after lobectomy. This complements the early mobility afforded by VATS lobectomy well, and ensures the patient can fully benefit from the minimally invasive approach. An initial survey of patients and nurses on the use of the portable device has already produced preliminary confirmation that chest drain handling

and patient mobility are improved compared to conventional water seal systems (Sihoe & Yeung, 2011). Perhaps more importantly, it has also been shown that use of the digital air flow monitor on a digital system such as the Thopaz can accurately and objectively measure post-operative air leaks after lung surgery (Varela et al, 2009). A study from Hong Kong has already demonstrated that the greater consistency in monitoring air leaks can be translated into more decisive, confident post-operative chest drain management resulting in shortened chest drain durations and lengths of hospital stay (Yeung & Sihoe, 2010). The combination of improved patient recovery and more effective air leak management should prove attractive to surgeons looking to maximize the potential of VATS lobectomy in improving outcomes. In the past few years, increasing numbers of abstracts on the use of digital drain systems have been presented at major thoracic surgical conferences in Asia and Europe, reflecting the growing importance of this new technology.

Of course, the one surgical technology capturing the most attention amongst surgeons and the lay public in recent years is undoubtedly that of robot assisted surgery. The da Vinci robotic surgical system (Surgical Intuitive, Mountain View, CA) allows the surgeon at a console to 'remote control' robot limbs inserted into the patient to perform the operation. The purported advantages of using robot assistance include precise tremor-free manipulations, 3D binocular visualization, excellent ergonomics for the surgeon, and the ability of the robotic arms to minimize torquing of the instruments at each working port (Melfi et al, 2002). Early published series have demonstrated the safety and feasibility of robot assisted surgery within the thorax, even for major lung resection (Varonesi et al, 2010). However, good results have so far mainly been reported by a small number of specialist centers with particular experience using robots, and a couple of recognized drawbacks still remain. The first issue is the complete absence of tactile feedback throughout the operation (D'Amico, 2006). For many operations, the visual information can partly compensate for this. However, tactile feedback is often crucial in thoracic surgery, and whether current robotic technology can consistently address this fundamental limitation during the intricate dissections in the course of a lobectomy remains to be fully proven. The other disadvantage of robot assisted surgery is the costs – both of the initial outlay for the advanced hardware and of the bespoke instruments and consumables that must be purchased for each operation. Because of the very low morbidity rates and excellent outcomes with conventional VATS, it may prove difficult – if not impossible – to ever demonstrate any significant superiority of the robot system over VATS. Conceptually, it is hard to see how a robot assisted lobectomy using four ports can ever be convincingly proven to cause less trauma than a typical c-VATS lobectomy using 3 ports. Consequently, for the foreseeable future at least, making a compelling case for robot assisted surgery in terms of cost-effectiveness will very likely prove futile.

In the inevitably upcoming debates over the relative merits of robot assisted surgery and VATS, it is worth making one telling observation. Many (but not all) reports on robot assisted thoracic surgery appear to have originated from centers that are not generally associated with major well-developed VATS lobectomy programs. Even the authors of leading published reports on robot assisted lobectomy acknowledge that their standard approach to lung lobectomy was through thoracotomy, not VATS (Varonesi et al, 2010). Very few of the established VATS lobectomy centers have switched to using the robot. This peculiar phenomenon suggests that for surgeons used to open surgery, the very intuitive and user-friendly robot systems interface may be easier to master than the different set of hand-eye

skills demanded by VATS lobectomy. This provides non-VATS surgeons an excellent route into the world of minimally invasive thoracic surgery. However, for those who have mastered VATS lobectomy, the robot systems do not seem to offer any advantage or incentive to switch (Swanson, 2010). Again, only time will tell whether the robot systems are a passing fad or an emerging viable alternative approach to lung surgery as VATS once was.

Whatever the potential of robot systems, there is also another possible (and much simpler) direction for minimally invasive thoracic surgery: needlescopic VATS. In this technique, video-thoroscopes and instruments of only 2-3 mm diameter are used, requiring much smaller ports than the typical 5-15mm ports used in conventional VATS. The wounds are typically so small that only barely detectable 'pinpoint' scars remain after surgery - leading to term 'needlescopic' VATS. The principle is that if VATS can improve on open thoracotomy by using smaller wounds, then needlescopic VATS should give better outcomes than conventional VATS by using even smaller wounds. Compared to robot assisted surgery, this approach uses far smaller ports and should be much cheaper. Needlescopic VATS has already been used for a variety of diagnostic and simple therapeutic procedures, such as sympathectomy for palmar hyperhidrosis (Yim et al, 2000b; Lazopoulos et al, 2002; Sihoe et al, 2004b). More recently, needlescopic VATS has been used for pleurodesis surgery in the management of pneumothorax, achieving equivalent efficacy as conventional VATS but with less pain and faster recovery (Sihoe & Lin, 2011). As mentioned above, some VATS surgeons have already begun using 3-5mm instruments in their lobectomy operations, but only as a supplement to conventional VATS instruments (Gossot, 2008). With the potential benefits of the needlescopic approach, it may just be a matter of time before we witness reports of a totally needlescopic VATS lobectomy.

## 11. Conclusions

When VATS lobectomy was first conceived during the heyday of minimally invasive surgery, the pioneers had relatively little understanding of how the approach would benefit patients other than that smaller wounds would create less pain. A good number of reports documented that VATS did indeed cause less pain than traditional open surgery via thoracotomy. However, after the initial flurry of promising results, subsequent reports began painting a rather less flattering picture of VATS, suggesting that VATS may not be as advantageous as first hoped. In the quest to address these disappointing results, several important truths emerged. Firstly, the importance of clearly defining what VATS lobectomy is or is not was realized. Thus clearly defined, it became possible to not only reaffirm that complete VATS does improve patient outcomes, but also to better appreciate why VATS does this. Secondly, the use of standardized, objective and reproducible outcome measures are now providing a far more reliable picture of how much VATS can help the patient receiving lung surgery. This has not only established the role of VATS in lung cancer management, but raised the standards of outcome measurement in thoracic surgery as a whole. Thirdly, the pursuit of answers to questions put forth by critics of VATS has trained VATS surgeons to focus on what the key benefits to be gained from minimally invasive surgery really are. This in turn has led to continued efforts to advance those benefits for patients, culminating in many clinical and technological innovations to improve the state of the art.

It behoves the VATS surgeon to learn the lessons of the first two decades of VATS lobectomy. The evolution of VATS is an ongoing process. Challenges to the role of VATS lobectomy will never cease to emerge. Application of the enterprise and diligence of the



VATS pioneers is necessary to constantly test and evolve the practice of thoracic surgery, ensuring it remains as relevant to patients in the future as it is today.

## 12. References

- Abolhoda A, Liu D, Brooks A, Burt M. Prolonged air leak following radical upper lobectomy. An analysis of incidence and possible risk factors. *Chest* 1998; 113:1507-1510.
- Benedetti F, Vighetti S, Ricco C, Amanzio M, Bergamasco L, Casadio C, Cianci R, Giobbe R, Oliaro A, Bergamasco B, Maggi G. Neuorphysiologic assessment of nerve impairment in posterolateral and muscle-sparing thoracotomy. *J Thorac Cardiovasc Surg* 1998; 115:841-847.
- Benedetti F, Vighetti S, Amanzio M, Casadio C, Oliaro A, Bergamasco B, Maggi G. Dose-response relationship of opioids in nociceptive and neuropathic postoperative pain. *Pain* 1998; 74:205-211.
- Bolotin G, Buckner GD, Jardine NJ, Kiefer AJ, Campbell NB, Kocherginsky M, Raman J, Jeevanandam V. A novel instrumented retractor to monitor tissue-disruptive forces during lateral thoracotomy. *J Thorac Cardiovasc Surg* 2007; 133:949-954.
- Braimbridge MV. Thoracoscopy - a historical perspective. In Yim APC, Hazelrigg SR, Izzat MB, et al (eds): *Minimal Access Cardiothoracic Surgery*. WB Saunders, Philadelphia, USA, 2000, pp 1-10.
- Brunelli A, Fianchini A. Prolonged air leak following upper lobectomy: in search of the key. *Chest* 1999; 116:848.
- Crabtree TD, Denlinger CE, Meyers BF, et al. Stereotactic body radiation therapy versus surgical resection for stage I non-small cell lung cancer. *J Thorac Cardiovasc Surg* 2010; 140:377-386.
- Craig SR, Leaver HA, Yap PL, et al. Acute phase responses following minimal access and conventional thoracic surgery. *Eur J Cardiothorac Surg* 2001; 20:455-463.
- Cykert S, Kissling G, Hansen CJ. Patient preferences regarding possible outcomes of lung resection: what outcomes should preoperative evaluations target? *Chest* 2000; 117:1551-1559.
- Dahl JB, Moiniche S. Pre-emptive analgesia. *Br Med Bull* 2004; 71:13-27.
- D'Amico TA. Robotics in thoracic surgery: applications and outcomes. *J Thorac Cardiovasc Surg* 2006; 131:19-20.
- D'Andrilli A, Andreotti C, Ibrahim M, Ciccone AM, Venuta F, Mansmann U, Rendina EA. A prospective randomized study to assess the efficacy of a surgical sealant to treat air leaks in lung surgery. *Eur J Cardiothorac Surg* 2009; 35:817-821.
- Demmy TL, Curtis JJ. Minimally invasion lobectomy directed toward frail and high-risk patients: a case control study. *Ann Thorac Surg* 1999; 68:194-200.
- Denlinger CE, Fernandez, Meyers BF, et al. Lymph node evaluation in video-assisted thoracoscopic lobectomy versus lobectomy by thoracotomy *Ann Thorac Surg* 2010; 89:1730-1736.
- Downey RJ, McCormick P, LoCicero J, et al. Dissemination of malignant tumors after video-assisted thoracic surgery: A report of twenty-one cases. *J Thorac Cardiovasc Surg* 1996; 111:954-960.

- Fernando HC, De Hoyos A, Landreneau RJ, et al. Radiofrequency ablation for the treatment of non-small cell lung cancer in marginal surgical candidates. *J Thorac Cardiovasc Surg* 2005; 129:639-644.
- Garzon JC, Ng CSH, Sihoe ADL, Manlulu AV, Wong RHL, Lee TW, Yim APC. Video-assisted thoracic surgery pulmonary resection for lung cancer in patients with poor lung function. *Ann Thorac Surg* 2006; 81:1996-2003.
- Giudicelli R, Thomas P, Lonjon T, et al. Video-assisted mini-thoracotomy versus muscle sparing thoracotomy for performing lobectomy. *Ann Thorac Surg* 1994; 58:712-718.
- Gossot D. Technical tricks to facilitate totally endoscopic major pulmonary resections *Ann Thorac Surg* 2008; 86:323-326.
- Handy JR Jr, Asaph JW, Douville EC, Ott GY, Grunkemeier GL, Wu Y. Does video-assisted thoracoscopic lobectomy for lung cancer provide improved functional outcomes compared with open lobectomy? *Eur J Cardiothorac Surg* 2010; 37:451-455.
- Isowa N, Hasegawa S, Bando T, Wada H. Preoperative risk factors for prolonged air leak following lobectomy or segmentectomy for primary lung cancer. *Eur J Cardiothorac Surg* 2002; 21:951.
- Jacobaeus HC. Ueber die Möglichkeit die Zystoskopie bei Untersuchung seröser Höhlungen anzuwenden. *München Med Wchenschr* 1910; 57:2090-2092.
- Karmakar MK, Ho AMH. Postthoracotomy pain syndrome. *Thorac Surg Clin* 2004; 14:345-352.
- Kaseda S, Aoki T. Video-assisted thoracic surgical lobectomy in conjunction with lymphadenectomy for lung cancer. *J Jap Surg Soc* 2002; 103:717-721.
- Keagy BA, Lores ME, Starek PJK, Murray GF, Lucas CL, Wilcox BR. Elective pulmonary lobectomy: factors associated with morbidity and operative mortality. *Ann Thorac Surg* 1985; 40:349-352.
- Kim K, Kim HK, Park JS, et al. Video-assisted thoracic surgery lobectomy: single institutional experience with 704 cases *Ann Thorac Surg* 2010; 89:S2118-S2122.
- Kirby TJ, Mack MJ, Landreneau RJ, et al. Initial experience with video-assisted thoracoscopic lobectomy. *Ann Thorac Surg* 1993; 56:1248-1253.
- Kirby TJ, Mack MJ, Landreneau RJ, Rice TW. Lobectomy video-assisted thoracic surgery versus muscle-sparing thoracotomy: a randomized trial. *J Thorac Cardiovasc Surg* 1995; 109:997-1002.
- Kurimoto N, Miyazawa T. Endobronchial ultrasonography. *Semin Respir Crit Care Med* 2004; 25:425-431.
- Laird MA, Gidal BE. Use of gabapentin in the treatment of neuropathic pain. *Ann Pharmacother* 2000; 34:802-807.
- Landreneau RJ, Mack MJ, Hazelrigg SR, et al. Post-operative pain-related morbidity: video-assisted thoracic surgery versus thoracotomy. *Ann Thorac Surg* 1993; 56:1285-1289.
- Landreneau RJ, Mack MJ, Hazelrigg SR, et al. Prevalence of chronic pain after pulmonary resection by thoracotomy or video-assisted thoracic surgery. *J Thorac Cardiovasc Surg* 1994; 107:1079-1086.
- Lazopoulos G, Kotoulas C, Kokotsakis J, et al. Diagnostic mini-video assisted thoracic surgery: effectiveness and accuracy of new generation 2.0 mm instruments. *Surg Endosc* 2002; 16:1793-1795.
- Leaver HA, Craig SR, Yap PL, Walker WS. Lymphocyte responses following open and minimally invasive thoracic surgery. *Eur J Clin Invest* 2000; 30:230-238.


- Lewis RJ, Caccavale RJ, Sisler GE, et al. One hundred consecutive patients undergoing video-assisted thoracic operations, *Ann Thorac Surg* 1992; 54:421-426.
- Lewis RJ. Simultaneously stapled lobectomy: a safe technique for video-assisted thoracic surgery. *J Thorac Cardiovasc Surg* 1995; 109:619-625.
- Lewis RJ. VATS is not thoracoscopy. *Ann Thorac Surg* 1996; 62:631-632.
- Lewis RJ, Caccavale RJ. Video-assisted thoracic surgical non-rib-spreading simultaneously stapled lobectomy. In Yim APC, Hazelrigg SR, Izzat MB, et al (eds): *Minimal Access Cardiothoracic Surgery*. WB Saunders, Philadelphia, USA, 2000, pp 135-149.
- Li WWL, Lee TW, Lam SSY, Ng CSH, Sihoe ADL, Wan IYP, Yim APC. Quality of life following lung cancer resection: video-assisted thoracic surgery versus thoracotomy. *Chest* 2002; 122:584-589.
- Li WW, Lee RL, Lee TW, Ng CS, Sihoe AD, Wan IY, Arifi AA, Yim AP. The impact of thoracic surgical access on early shoulder function: video-assisted thoracic surgery versus posterolateral thoracotomy. *Eur J Cardiothorac Surg* 2003; 23:390-396.
- Mack MJ, Hazelrigg SR, Landreneau RJ, Naunheim KS. The First International Symposium on Thoracoscopic Surgery. *Ann Thorac Surg* 1993; 56:605-806.
- Mack MJ, Scruggs GR, Kelly KM, et al. Video-assisted thoracic surgery: has technology found its place? *Ann Thorac Surg* 1997; 64:211-215.
- Maguire MF, Latter JA, Mahajan R, David Beggs F, Duffy JP. A study exploring the role of intercostal nerve damage in chronic pain after thoracic surgery. *Eur J Cardiothorac Surg* 2006; 29:873-879.
- McKenna RJ. Lobectomy by video-assisted thoracic surgery with mediastinal node sampling for lung cancer. *J Thorac Cardiovasc Surg* 1994; 107:879-882.
- McKenna RJ, Jr, Wolf RK, Brenner M, et al. Is VATS lobectomy an adequate cancer operation? *Ann Thorac Surg* 1998; 66:1903-1908.
- McKenna Jr RJ, Houck W, Fuller CB. Video-assisted thoracic surgery lobectomy: experience with 1100 cases *Ann Thorac Surg* 2006; 81:421-425.
- Melfi FM, Menconi GF, Mariani AM, et al. Early experience with robotic technology for thoracoscopic surgery. *Eur J Cardiothorac Surg* 2002; 21:864-868.
- Mun M, Kohno T. Video-assisted thoracic surgery for clinical stage I lung cancer in octogenarians. *Ann Thorac Surg* 2008; 85:406-411.
- Nagahiro I, Andou A, Aoe M, et al. Pulmonary function, postoperative pain, and serum cytokine level after lobectomy: a comparison of VATS and conventional procedure. *Ann Thorac Surg* 2001; 72:362-365.
- Nakajima J, Takamoto S, Kohno T, Ohtsuka T. Costs of video thoracoscopic surgery versus open resection for patients with lung carcinoma. *Cancer* 2000; 89:2497-2501.
- Nakata M, Saeki H, Yokoyama N et al. Pulmonary function after lobectomy: video-assisted thoracic surgery versus thoracotomy. *Ann Thorac Surg* 2000 ; 70:938-941.
- Ng CS, Lee TW, Wan S, Wan IY, Sihoe ADL, Arifi AA, Yim AP. Thoracotomy is associated with significantly more profound suppression in lymphocytes and natural killer cells than video-assisted thoracic surgery following major lung resections for cancer. *J Invest Surg* 2005; 18:81-88.
- Nicholson B. Gabapentin use in neuropathic pain syndromes. *Acta Neurol Scand* 2000; 101:359-371.

- Nomori H, Horio H, Naruke T, Suemasu K. What is the advantage of a thoracoscopic lobectomy over a limited thoracotomy procedure for lung cancer surgery? *Ann Thorac Surg* 2001; 72:879-84.
- Nomori H, Horio H, Naruke T, Suemasu K. Posterolateral thoracotomy is behind limited thoracotomy and thoracoscopic surgery in terms of postoperative pulmonary function and walking capacity. *Eur J Cardiothorac Surg* 2002; 21:155-156.
- Nomori H, Ohtsuka T, Horio H, et al. Difference in the impairment of vital capacity and 6-minute walking after a lobectomy performed by thoracoscopic surgery, an anterior limited thoracotomy, an anteroaxillary thoracotomy, and a posterolateral thoracotomy. *Surg Today* 2003; 33:7-12.
- Nomori H, Ohtsuka T, Horio H, Naruke T, Suemasu K. Thoracoscopic lobectomy for lung cancer with a largely fused fissure. *Chest* 2003; 123:619-622.
- Okereke I, Murthy SC, Alster JM, Blackstone EH, Rice TW. Characterization and importance of air leak after lobectomy. *Ann Thorac Surg* 2005; 79:1167-1173.
- Parekh K, Rusch V, Bains M, et al. VATS port site recurrence: a technique dependent problem. *Ann Surg Oncol* 2001; 8:175-178.
- Pearson FG. Commentary. In Yim APC, Hazelrigg SR, Izzat MB, et al (eds): *Minimal Access Cardiothoracic Surgery*. WB Saunders, Philadelphia, USA, 2000, p 151.
- Pennathur A, Luketich JD, Heron DE, et al. Stereotactic radiosurgery for the treatment of stage I non-small cell lung cancer in high-risk patients *J Thorac Cardiovasc Surg* 2009; 137:597-604.
- Rogers ML, Duffy JP. Surgical aspects of chronic post-thoracotomy pain. *Eur J Cardiothorac Surg* 2000; 18:711-716.
- Rogers ML, Henderson L, Duffy JP. Preliminary findings of a neurophysiological assessment of intercostal nerve injury during thoracotomy. *Eur J Cardiothorac Surg* 2002; 21:298-301.
- Roviaro CG, Varoli F, Rebuffat C, et al. Videothoracoscopic major pulmonary resections *Ann Thorac Surg* 1993; 56:779-783.
- Roviaro CG, Varoli F, Vergani C, Maciocco M. Anatomic lung resection. In Yim APC, Hazelrigg SR, Izzat MB, et al (eds): *Minimal Access Cardiothoracic Surgery*. WB Saunders, Philadelphia, USA, 2000, pp 107-114.
- Rueth NM, Andrade RS. Is VATS lobectomy better: perioperatively, biologically and oncologically? *Ann Thorac Surg* 2010; 89:S2107-S2111.
- Sagawa M, Sato M, Sakurada A, et al. A prospective trial of systematic nodal dissection for lung cancer by video-assisted thoracic surgery: can it be perfect? *Ann Thorac Surg* 2002; 73:900-904.
- Scott WJ, Allen MS, Darling G, et al. Video-assisted thoracic surgery versus open lobectomy for lung cancer: a secondary analysis of data from the American College Of Surgeons Oncology Group Z0030 randomized clinical trial. *J Thorac Cardiovasc Surg* 2010; 139:976-983.
- Shariat SF, Lamb DJ, Kattan MW, et al. Association of preoperative plasma levels of insulin-like growth factor I and insulin-like growth factor binding proteins-2 and -3 with prostate cancer invasion, progression, and metastasis. *J Clin Oncol* 2002; 20:833-841.
- Shigemura N, Akashi A, Nakagiri T, Ohta M, Matsuda H. Complete vs assisted thoracoscopic approach. A prospective randomized trial comparing a variety of

- video-assisted thoracoscopic lobectomy techniques. *Surg Endosc* 2004; 18:1492-1497.
- Shigemura N, Akashi A, Funaki S, Nakagiri T, Inoue M, Sawabata N, Shiono H, Minami M, Takeuchi Y, Okumura M, Sawa Y. Long-term outcomes after a variety of video-assisted thoracoscopic lobectomy approaches for clinical stage IA lung cancer: a multi-institutional study. *J Thorac Cardiovasc Surg* 2006; 132:507-512.
- Sihoe ADL, Au SS, Cheung ML, Chow IK, Chu KM, Law CY, Wan M, Yim APC. Incidence of chest wall paresthesia after video-assisted thoracic surgery for primary spontaneous pneumothorax. *Eur J Cardiothorac Surg* 2004; 25:1054-1058.
- Sihoe ADL, Ho KM, Sze TS, et al. Selective lobar collapse for video-assisted thoracic surgery. *Ann Thorac Surg* 2004; 77:278-283.
- Sihoe ADL, Cheung CS, Lai HK, Lee TW, Thung KH, Yim APC. Incidence of chest wall paresthesia after needlescopic video-assisted thoracic surgery for palmar hyperhidrosis. *Eur J Cardiothorac Surg* 2005; 27:313-319.
- Sihoe AD, Lee TW, Wan IY, Thung KH, Yim AP. The use of gabapentin for post-operative and post-traumatic pain in thoracic surgery patients *Eur J Cardiothorac Surg* 2006; 29:795-799.
- Sihoe AD, Manlulu AV, Lee TW, Thung KH, Yim AP. Pre-emptive local anesthesia for needlescopic video-assisted thoracic surgery: a randomised controlled trial. *Eur J Cardiothorac Surg* 2007; 31:103-108.
- Sihoe ADL, Yim APC. Video-Assisted Pulmonary Resections. In: *Thoracic Surgery* (3rd Edition). Patterson GA, Cooper JD, Deslauriers J, Lerut AEMR, Luketich JD, Rice TW, Pearson FG (Eds). Elsevier, Philadelphia, USA, 2008, pp 970-988.
- Sihoe ADL, Cheng LC, Das SR. Protocol-based post-operative management following lung cancer surgery. Presented at: Hospital Authority Convention 2008, May 2008, Hong Kong.
- Sihoe ADL, Lee A, Cheng LC. Aerosolized endoscopic spray application of fibrin for on-table air leaks following lung resection surgery: a case-match study. Presented at: 19th Biennial Congress of the Association of Thoracic and Cardiovascular Surgeons of Asia, October 2009, Seoul, Korea.
- Sihoe ADL, Yeung ESL, Cheng LC, Wang E, Wong MP. Lymph node evaluation during lobectomy for lung cancer: complete video-assisted thoracic surgery versus open surgery. Presented at: 2011 Joint Meeting of the Asian Society for Cardiovascular and Thoracic Surgery and the Association of Thoracic and Cardiovascular Surgeons of Asia, May 2011, Phuket, Thailand.
- Sihoe ADL, Yeung ESL. Use of a portable digital chest drain system in thoracic surgery: a survey of patients and nurses. Presented at: 2011 Joint Meeting of the Asian Society for Cardiovascular and Thoracic Surgery and the Association of Thoracic and Cardiovascular Surgeons of Asia, May 2011, Phuket, Thailand.
- Sihoe ADL, Lin PMF. Needlescopic video-assisted thoracic surgery for primary spontaneous pneumothorax. Presented at: Annual Scientific Meeting 2011 of the International Society for Minimally Invasive Cardiothoracic Surgery, June 2011, Washington, DC, USA.
- Staffa J, Lampl B, Sihoe ADL. Lung cancer resection in elderly patients: VATS offers faster recovery. Presented at: 17th European Congress on General Thoracic Surgery, European Society of Thoracic Surgeons, June 2010, Valladolid, Spain.

- Sugi K, Kaneda Y, Esato K. Video-assisted thoracoscopic lobectomy reduces cytokine production more than conventional open lobectomy. *Jpn J Thorac Cardiovasc Surg* 2000; 48:161-165.
- Sugi K, Kaneda Y, Esato K. Video-assisted thoracoscopic lobectomy achieves a satisfactory long-term prognosis in patients with clinical stage IA lung cancer. *World J Surg* 2000; 24:27-30.
- Sugiura H, Morikawa T, Kaji M et al. Long-term benefits for the quality of life after video-assisted thoracoscopic lobectomy in patients with lung cancer. *Surg Laparosc Endosc* 1999; 9:403-408.
- Swanson SJ, Herndon JE 2nd, D'Amico TA, et al. Videoassisted thoracic surgery lobectomy: report of CALGB 39802—a prospective, multi-institution feasibility study. *J Clin Oncol* 2007; 25:4993-4997.
- Swanson, SJ. Robotic pulmonary lobectomy: the future and probably should remain so. *J Thorac Cardiovasc Surg* 2010; 140:954.
- Tansley P, Al-Mulhim F, Lim E, Ladas G, Goldstraw P. A prospective, randomized, controlled trial of the effectiveness of BioGlue in treating alveolar air leaks. *J Thorac Cardiovasc Surg* 2006; 132:105-112.
- Varela G, Jiménez MF, Novoa NM, Aranda JL. Postoperative chest tube management: measuring air leak using an electronic device decreases variability in the clinical practice. *Eur J Cardiothorac Surg* 2009; 35:28-31.
- Veronesi G, Galetta D, Maisonneuve P, Melfi F, Schmid RA, Borri A, et al. Four-arm robotic lobectomy for the treatment of early-stage lung cancer. *J Thorac Cardiovasc Surg* 2010; 140:19-25.
- Walker WS, Pugh GC, Craig SR, Carnochan FM. Continued experience with thoracoscopic major pulmonary resection. *Int Surg* 1996; 81: 255-258.
- Walker WS, Leaver HA, Craig SR, Yap PL. The immune response to surgery: Conventional and VATS lobectomy. In Yim APC, Hazelrigg SR, Izzat MB, et al (eds): *Minimal Access Cardiothoracic Surgery*. WB Saunders, Philadelphia, USA, 2000, pp 152-167.
- Walker WS. Complications and Pitfalls in Video Assisted Thoracic Surgery. In Yim APC, Hazelrigg SR, Izzat MB, et al (eds): *Minimal Access Cardiothoracic Surgery*. WB Saunders, Philadelphia, USA, 2000, pp 341-348.
- Watanabe A, Koyanagi T, Ohsawa H, et al. Systematic node dissection by VATS is not inferior to that through an open thoracotomy: a comparative clinicopathologic retrospective study *Surgery* 2005; 138:510-517.
- Whitson BA, Groth SS, Duval SJ, Swanson SJ, Maddaus MA. Surgery for early-stage non-small cell lung cancer: a systematic review of the video-assisted thoracoscopic surgery versus thoracotomy approaches to lobectomy. *Ann Thorac Surg* 2008; 86:2008-2018.
- Wilkins EW Jr, Scannell JG, Craver JC. Four decades of experience with resections for bronchogenic carcinoma at the Massachusetts General Hospital. *J Thorac Cardiovasc Surg* 1978; 76:364.
- Woolf CJ. Evidence for a central component of post-injury pain hypersensitivity. *Nature* 1983; 306:686-688.
- Woolf CJ, Salter MW. Neuronal plasticity: increasing the gain in pain. *Science* 2000; 288:1765-1769.

- Wu Y, Yakar S, Zhao L, Hennighausen L, LeRoith D. Circulating insulin-like growth factor-1 levels regulate colon cancer growth and metastasis. *Cancer Res* 2002; 62:1030-1035.
- Yamashita JI, Kurusu Y, Fujino N. Detection of circulating tumor cells in patients with non-small cell lung cancer undergoing lobectomy by video-assisted thoracic surgery: a potential hazard for intraoperative hematogenous tumor cell dissemination. *J Thorac Cardiovasc Surg* 2000; 119:899-905.
- Yeung ESL, Sihoe ADL. Use of a portable digital chest drain system in thoracic surgery improves consistency in air leak management. Presented at: 20th Annual Congress of the Association of Thoracic and Cardiovascular Surgeons of Asia, October 2010, Beijing, China.
- Yan TD, Black D, Bannon PG, McCaughan BC. Systematic review and meta-analysis of randomized and nonrandomized trials on safety and efficacy of video-assisted thoracic surgery lobectomy for early-stage non-small-cell lung cancer. *J Clin Oncol* 2009; 27:2553-2562.
- Yim APC. Minimizing chest wall trauma in video assisted thoracic surgery. *J Thorac Cardiovasc Surg* 1995; 109:1255-1256.
- Yim APC, Lee TW. 'Home-made' knot pusher for extracorporeal ties. *Aust NZJ Surg* 1995; 65:510-511.
- Yim APC. Cost containing strategies in video assisted thoracoscopic surgery: an Asian perspective. *Surg Endosc* 1996; 10:1198-1200.
- Yim APC, Ko KM, Chau WS, et al. Video-assisted thoracoscopic anatomic lung resections: the initial Hong Kong experience. *Chest* 1996; 109:13-17.
- Yim APC, Liu HP. Complications and failures from video assisted thoracic surgery: experience from two centers in Asia. *Ann Thorac Surg* 1996; 61: 538-541.
- Yim APC, Liu H, Izzat MB, et al. Thoracoscopic major lung resection: an Asian perspective. *Semin Thorac Cardiovasc* 1998; 10:326-331.
- Yim APC, Landreneau RJ, Izzat MB, Fung ALK. Is video assisted thoracoscopic lobectomy a unified approach? *Ann Thorac Surg* 1998; 66:1155-1158.
- Yim APC, Wan S, Lee TW, Arifi AA. VATS lobectomy reduces cytokine responses compared with conventional surgery. *Ann Thorac Surg* 2000; 70:243-247.
- Yim APC, Liu HP, Lee TW, et al. 'Needlescopic' VATS for palmar hyperhidrosis. *Eur J Cardiothorac Surg* 2000; 17:697-701.
- Yim APC. VATS major pulmonary resection revisited: controversies, techniques, and results. *Ann Thorac Surg* 2002; 74:615-623.



## **Topics in Thoracic Surgery**

Edited by Prof. Paulo Cardoso

ISBN 978-953-51-0010-2

Hard cover, 486 pages

**Publisher** InTech

**Published online** 15, February, 2012

**Published in print edition** February, 2012

Thoracic Surgery congregates topics and articles from many renowned authors around the world covering several different topics. Unlike the usual textbooks, Thoracic Surgery is a conglomerate of different topics from Pre-operative Assessment, to Pulmonary Resection for Lung Cancer, chest wall procedures, lung cancer topics featuring aspects of VATS major pulmonary resections along with traditional topics such as Pancoast tumors and recurrence patterns of stage I lung disease, hyperhidrosis, bronchiectasis, lung transplantation and much more. This Open Access format is a novel method of sharing thoracic surgical information provided by authors worldwide and it is made accessible to everyone in an expedite way and with an excellent publishing quality.

### **How to reference**

In order to correctly reference this scholarly work, feel free to copy and paste the following:

Alan D. L. Sihoe (2012). The Evolution of VATS Lobectomy, Topics in Thoracic Surgery, Prof. Paulo Cardoso (Ed.), ISBN: 978-953-51-0010-2, InTech, Available from: <http://www.intechopen.com/books/topics-in-thoracic-surgery/the-evolution-of-vats-lobectomy>

**INTECH**  
open science | open minds

### **InTech Europe**

University Campus STeP Ri  
Slavka Krautzeka 83/A  
51000 Rijeka, Croatia  
Phone: +385 (51) 770 447  
Fax: +385 (51) 686 166  
[www.intechopen.com](http://www.intechopen.com)

### **InTech China**

Unit 405, Office Block, Hotel Equatorial Shanghai  
No.65, Yan An Road (West), Shanghai, 200040, China  
中国上海市延安西路65号上海国际贵都大饭店办公楼405单元  
Phone: +86-21-62489820  
Fax: +86-21-62489821



© 2012 The Author(s). Licensee IntechOpen. This is an open access article distributed under the terms of the [Creative Commons Attribution 3.0 License](#), which permits unrestricted use, distribution, and reproduction in any medium, provided the original work is properly cited.

IntechOpen

IntechOpen