

We are IntechOpen, the world's leading publisher of Open Access books Built by scientists, for scientists

4,800

Open access books available

122,000

International authors and editors

135M

Downloads

Our authors are among the

154

Countries delivered to

TOP 1%

most cited scientists

12.2%

Contributors from top 500 universities



WEB OF SCIENCE™

Selection of our books indexed in the Book Citation Index
in Web of Science™ Core Collection (BKCI)

Interested in publishing with us?
Contact book.department@intechopen.com

Numbers displayed above are based on latest data collected.

For more information visit www.intechopen.com



Liver Transplantation for Hepatocellular Carcinoma (HCC)

Alejandro Mejia, Hector Nazario and Parvez Mantry
*The Liver Institute at Methodist Dallas, Texas
USA*

1. Introduction

Hepatocellular carcinoma (HCC) is the third most common cause of cancer mortality worldwide and accounts for 20% of all liver transplants (Wigg, 2010). Its incidence has increased two fold in the last decade and it is the fifth leading cause of cancer in males. The availability of liver transplantation as a cure for chronic liver disease and the demonstration of outcomes exceeding 70% at 5 years after transplantation for HCC have pushed the field to refine this therapy in order to utilize this precious resource in the most effective, fair and safe manner. The combination of a rising incidence of HCC and a flat donor procurement rates has resulted in longer waiting times in many areas. The complex decision making and management issues of patients with HCC, cirrhosis and possibly undergoing oncological therapies while waiting for an organ transplant poses challenges to the management team, not encountered in any other clinical or surgical field.

2. Epidemiology

Hepatocellular carcinoma (HCC) accounts for 85% to 90% of the primary liver cancers (El-Serag & Rudolph, 2007). The alarming results of epidemiologic studies performed over the last 2 decades have raised awareness, and shed light on its magnitude as a public health problem. Hepatoma is the fifth most common cancer worldwide, accounting for roughly 4% of all the new cancers diagnosed. It is currently the third most common cause of cancer-related death in the world (Altekruse, 2009; Parkin, 2005). Recent data presented by the Center for Disease Control and Prevention has liver cancer listed as the ninth leading cause of cancer-related deaths in the United States. In addition, hepatocellular carcinoma has become one of the fastest growing causes of malignancy-related death in this North American country, and its overall age-adjusted incidence has also significantly increased over the last 20 years (El-Serag & Rudolph, 2007).

The incidence of hepatocellular carcinoma differs depending on aspects such as geographic location, sex, age, race and ethnicity, environmental exposure to certain agents, as well as presence of other risk factors. In general, it has been clearly established that the vast majority of the cases of hepatocellular carcinoma occur in the setting of cirrhosis arising from chronic liver disease with approximately 80% of the cases due to chronic hepatitis B and hepatitis C infection (Perz, 2006). Sub-Saharan Africa and Eastern Asia, which are

endemic areas for hepatitis B, are considered among the regions with highest rate of hepatoma. The incidence for men is as high as 35.5/100,000 in China, where more than 50% of all hepatocellular carcinomas occur (El Serag & Rudolph, 2007, as cited in Parkin, 2002). Interestingly, a downtrend in the rate of hepatocellular carcinoma has been seen in several high risk Asian countries. The success of vaccination programs against hepatitis B may be one of the main factors contributing to this decrease (Chang et al., 2009). In contrast to most other Asian countries, Japan's incidence of primary liver cancer is associated to chronic hepatitis C infection which came about after the rampant spread of this virus during the post-World War II years (Yoshizawa, 2002). Recent studies suggest that this incidence is also now decreasing (Tanaka et al., 2008).

The rates of primary hepatic cancer in areas that are considered low risk are well below 10 per 100,000. These include most of Europe, North and South America, Australia and New Zealand (Bosch, 2005). The risk factors for hepatoma in these geographic locations are somewhat different to Sub-Saharan and Asian countries with hepatitis C, alcohol and nonalcoholic fatty liver disease playing a pivotal role. In the United States, for example, the aging large population of chronic hepatitis C infected patients that progress to cirrhosis has caused a disturbing increase in the incidence of hepatocellular carcinoma over the last two decades (Davila, 2004, Kanwal, 2011). This trend has also been seen in other developed nations. In addition to the effect of chronic hepatitis C-related cirrhosis, these countries are experiencing growing problems with heavy alcohol consumption, as well as diabetes and obesity which are associated to nonalcoholic fatty liver disease, and could all lead to cirrhosis and liver cancer (Nordenstedt, 2010).

2.1 Age and sex

The rate of hepatocellular carcinoma is higher across the board in males than females. This has been well documented in multiple registries that looked at different populations affected by this cancer (Bosch et al., 2005). In general, the male to female ratios range between 2:1 and 4:1, with the larger variation seen in regions with higher and intermediate incidence of hepatoma. Interestingly, the discrepancy in rates is up to 5:1 in France (El-Serag & Rudolph, 2007). The grounds for this global disparity between men and women are not well understood, but several theories exist linking this phenomenon to differences in sex-specific exposure to risk factors such as viral hepatitis, alcohol, and tobacco (Donato, 2002). The trophic effects of androgens have also been implicated (Yu et al., 2001).

Hepatocellular carcinoma most commonly occurs in the presence of cirrhosis as a result of long standing chronic liver disease. In general, the process of inflammation and fibrosis that leads to cirrhosis usually takes many years, although it could be accelerated when more than one risk factor is affecting an individual. As a result, most cases of hepatoma are seen in older patients. The age at which the incidence of primary liver cancer peaks in high risk areas is typically lower than in areas of lesser risk, 50 to 60 years old and 70 to 75 years old, respectively. However, it is not uncommon to see hepatocellular carcinoma affecting people ages 20 to 35 in geographic locations of high incidence, and where factors such as chronic hepatitis B and aflatoxins, an environmental toxin and carcinogen, are endemic. Vertical transmission of hepatitis B with over 90% chronicity of infected persons, and early constant exposure to aflatoxins in these areas contribute to the earlier incidence of hepatoma (Bosch, 2005).

2.2 Race and ethnicity

The racial and ethnic variations seen in the incidence of hepatocellular carcinoma are influenced by the geographic distribution of this malignancy. Accordingly, the higher incidence is seen in individuals from Africa and Asia. The migratory patterns of populations moving from intermediate and high risk areas into developed countries, has contributed to change the frequency of primary liver cancer not only globally, but within people living in the same region. In the United States, for example, the highest age-adjusted rates of hepatocellular carcinoma are seen in Asians for both sexes (El-Serag & Rudolph, 2007). This group is followed in occurrence by Hispanics, African Americans and Caucasians. The marked growth in the Hispanic population over the last decade, making it the largest minority in the United States has also had an impact in the liver cancer demographics in this North American nation (El-Serag, 2007).

2.3 Risk factors

Several factors have been associated to hepatocellular carcinoma, being the most relevant viral hepatitis, alcohol, exposure to toxins and nonalcoholic fatty liver disease. In general, any etiology that causes chronic liver disease and that could lead to cirrhosis is a potential risk factor for primary liver cancer. It must be noted that hepatoma can very infrequently occur in the absence of cirrhosis as is the case of some individuals with chronic hepatitis B.

2.3.1 Viral hepatitis

Viral hepatitis, in particular chronic hepatitis B and C, account for over 80% of the cases of primary hepatic cancer. The degree of connection of these two viruses to hepatocellular carcinoma varies depending on the region being evaluated. Most of the hepatitis B-related hepatoma cases are seen in Africa and Asia, whereas most of the hepatitis C-related cases are seen in Europe, the United States and Japan (Bosch et al., 2004). Donato et al. and Shi et al. showed in their respective meta-analysis that chronic hepatitis B and C infection carry a significant risk for hepatoma. This risk was higher in co-infected patients with an odds ratio of 165 and 35.7 in their respective studies (Donato, 1998; Shi, 2005). Individuals with hepatitis B e antigen positivity have also shown to have an increased risk for primary liver cancer with a relative risk of 60.2 compared to a relative risk of 9.6 in those that are hepatitis B e antigen negative (Yang, 2002). Similar observations apply to those who have high hepatitis B DNA levels. In recent times, the improved antiviral therapies against hepatitis B, and the successful vaccination programs have helped lower the incidence of hepatocellular carcinoma particularly in what are considered endemic areas for hepatitis B (Chang et al., 1997; Sung, 2008).

The incidence of hepatitis C-related hepatocellular carcinoma has not seen the same encouraging trend that is been observed in hepatitis B-related cases. This is probably due to the interplay of numerous factors that include the natural history of the hepatitis C virus infection, host responses, age at the time of infection, co-morbidities, and alcohol consumption, to name a few. Approximately 15 to 20% of the chronic hepatitis C-infected individuals will develop cirrhosis over a period of 25 to 30 years from the time of infection (Thein, 2008). In developed countries such as the United States, the majority of the infections occurred from the late 1960s to the 1980s, thus in part explaining the rising number of

persons that are being diagnosed with hepatitis C-related cirrhosis over the last couple of decades (Davis, 2010). Hepatocellular carcinoma develops in this population at a rate of 1 to 4% per year, a worrisome statistic considering the escalating numbers of persons diagnosed with hepatitis C-related cirrhosis.

2.3.2 Alcohol

Alcohol consumption has also been linked to primary liver cancer. Mechanisms for direct toxic or carcinogenic effect have not been well-recognized, but it is clear that extended periods of heavy ingestion of more than 60g per day increment the risk for hepatoma. The synergistic effects of alcohol in the presence of hepatitis B or C or both have been established, and seem to have a greater impact in the risk to develop hepatocellular carcinoma (Donato et al., 2002).

2.3.3 Aflatoxin

A connection between the environmental exposure to aflatoxin, a mycotoxin produced by *Aspergillus* fungus, and primary liver cancer has also been documented. The chronic dietary exposure to high levels of this toxin is seen predominantly in developing countries, where hepatitis B is also prevalent. It has been postulated that the overall contribution of aflatoxin exposure to hepatocellular carcinoma cases worldwide is between 5 and 28% (Y. Liu 2010). However, taking into account that hepatitis B infection seems to play a much greater role in the risk of development of hepatoma in these developing countries, the true contribution of aflatoxins is considered minimal. It appears that the mechanism by which this toxin has carcinogenic effects is by causing mutations in the p53 tumor suppressor gene (Gursoy-Yuzugullu, 2011).

2.3.4 Nonalcoholic fatty liver disease

Nonalcoholic fatty liver disease is the most common form of chronic liver disease in developed countries. When aggressive, this disease can progress to cirrhosis and hepatocellular carcinoma. The alarming obesity epidemic affecting many of these nations, and components of the metabolic syndrome in particular insulin resistance and diabetes, are factors associated with the development of this chronic disease. These factors by themselves have also been related to an increased risk of primary liver cancer (Calle, 2003; El-Serag, 2004). Considering our current understanding of its rising prevalence, nonalcoholic fatty liver disease could also be responsible for a significant number of the idiopathic or cryptogenic cirrhosis cases as well as the cryptogenic cirrhosis-related hepatoma cases that are seen in industrialized countries (Bungianesi, 2002). Recent studies have shed some light of the molecular mechanisms by which fatty liver and obesity could eventually lead to hepatic cancer (Beyazit, 2010; Park et al., 2010; Wree, 2011).

3. Staging systems for HCC

One of the most fundamental steps in the field of Oncology once the diagnosis of cancer has been established is to determine the stage of this malignant process. This step is very important as it provides information about overall survival and prognosis, and could help

guide treatment strategies. The ideal staging system for hepatocellular carcinoma is one that has high discriminatory ability while remaining simple (Dohmen, 2004).

Many staging systems for hepatoma have been developed and presented in reputable medical journals and conferences. Nonetheless, more studies are constantly being published comparing these models, showing results of modifications made to some of these systems or simply introducing new staging classifications into this already complex field that tries to find the most accurate measure of prognosis and survival. The difficulty of coming up with a globally accepted staging system is related to multiple factors. One of the main causes for the current discrepancies is that the risk factors and their contribution to the development of primary liver cancer vary from one geographic area to another (Marrero, 2010). Another key issue is that overall survival of individuals that are diagnosed with hepatocellular carcinoma is not only determined by the extent and characteristics of this malignancy, but also by the liver function of that individual. Considering that over 80% of the cases of hepatoma occur in the presence of chronic liver disease and cirrhosis, the role of liver function in a prognosis model cannot be ignored. However, there is disagreement as to which markers of liver function should be used or included in such models. The use of the available staging classifications differ from one center or institution to another. It depends on their experience, available resources, and the predominant manifestations and characteristics of hepatocellular carcinoma in their region. Some of the main and most studied staging systems will be described below.

3.1 Tumor-node metastasis (TNM) system

The tumor-node-metastasis (TNM) staging system is one of the earliest models developed, and has been widely used for different solid tumors. This system describes the anatomic extent of cancer by evaluating size of the tumor at the primary site as well as the presence or absence of tumor in regional lymph nodes or beyond (Greene & Sobin, 2008). This classification has been studied in populations with hepatocellular carcinoma to assess prognosis. In a recent Chinese study looking at 243 patients with hepatoma undergoing curative resection, TNM classification was better at prognostic stratification and prognostic prediction than other three models (Lu, 2008). Similar conclusions were drawn from another smaller study comparing the prognostic value of TNM to 6 other staging systems (S.B. Choi, 2008). However, additional studies have shown no superiority to other staging classifications (Chen, 2007). There are some drawbacks to the use of this system in primary liver cancer. The main flaw is that liver function is not taken into consideration in this prognostic model. Another problem is that grading and pathologic staging cannot be assessed in the majority of the cases because very few patients with hepatoma undergo surgical therapies (Dohmen, 2004).

3.2 Cancer of the Liver Italian Program (CLIP)

The CLIP scoring system is another option available to evaluate overall survival in patients with hepatocellular carcinoma. This model combines Child-Pugh score, tumor morphology, alpha fetoprotein (AFP) and portal vein thrombosis which were the four independent predictive factors of survival recognized in the multivariate analysis of the original retrospective study (Cancer of the Liver Italian Program [CLIP] Investigators, 1998). By tumor morphology the investigators meant percentage of parenchymal involvement (more

than or less than 50%) and if these were uninodular, multinodular or extensive tumors. Several subsequent studies with large patient populations have demonstrated its prognostic usefulness, including a recent study from Taiwan that compared this system to four other models in 1713 patients with primary liver cancer (Hsu, 2010; Ueno, 2001). A downside to this system is that its tumor morphology classification is too broad for the current practices of aggressive hepatoma screening in high risk populations. Nowadays, more patients are being diagnosed with very small tumors which could limit the use the CLIP score. This model has also been criticized for not discriminating well the cases of advanced stage (CLIP score 4-6), and for classifying most of the patients as early stage (CLIP 0-2), which hampers its stratification capacity (Dohmen 2004; Marrero et al., 2010).

3.3 Japanese Integrated Staging (JIS) and biomarker-combined JIS

In an attempt to also combine liver function and tumor characteristics in order to provide a more precise prognostic appraisal to patients with hepatocellular carcinoma, researchers in Osaka, Japan integrated the Child-Pugh score and the Japanese TNM staging to create the JIS system. In their evaluation of 722 cases with primary liver cancer, they concluded that compared to the CLIP score, their system was better stratifying patients and superior discriminating those cases that were in the early hepatoma phase. Statistically significant differences were seen for the lower JIS scores (Kudo et al., 2003). These findings suggest that this staging system could be more useful in regions where early detection of hepatocellular carcinoma has become more common. Other studies have found encouraging results of this model's ability to predict survival (Chen, 2007; Kudo, 2004; Nanashima, 2005). The main disadvantage of the JIS classification is the inability to discriminate well the cases of advanced stage (JIS score >4).

Biomarkers have been combined to the JIS system to determine if this modification enhances its prognostic value. The biomarker-combined JIS includes the assessment of the following three tumor markers for hepatoma: AFP, *lens culinaris* agglutinin-reactive AFP, and des-gamma-carboxyprothrombin. This modified system was studied in 1,924 patients with primary liver cancer, and proved to be more effective predicting prognosis and stratifying patients than the conventional JIS model (Kitai, 2008). Although this was a large provocative study, this combined system needs to be tested in populations outside of the Asian region.

3.4 Barcelona Clinic Liver Cancer (BCLC) staging system

The Barcelona Clinic Liver Cancer staging system has one peculiarity that is not present in any of the other available prognosis models: it incorporates treatment recommendations in its staging algorithm. The independent predictors of mortality in the original studies were constitutional syndrome, performance status, vascular invasion, and extrahepatic spread (Llovet, 1999a, Llovet, 1999b). By combining in a simple format the evaluation of liver function, tumor stage, performance status, and cancer-related symptoms, and providing suggestions to the best available therapeutic modalities for any particular stage, the BCLC system has demonstrated better predictive value of prognosis and survival stratification when compared to several other staging systems (Cillo, 2004; Guglielmi, 2008). This classification has been gaining wide acceptance as the main staging model used in multiple countries, and supported by several well-respected liver societies. This is related in part to the fact that the BCLC has been externally validated in Asia, Europe and the United States

(Cillo, 2006; Marrero, 2005; J.H. Wang, 2008; Xu, 2010), which has not been accomplished by many of the other staging models. It is also the principal system used in major drug company trials. Some of the criticism to this model is that it includes the subjective factor of performance status, and portal hypertension measurement, which in clinical practice is not routinely done. It also does not provide a classification for patients with single tumors greater than 5 centimeters in diameter or for those with recurrent disease after treatment, situations not infrequently encountered by clinicians treating hepatocellular carcinoma (Sherman, 2011).

There are many other classifications that have been developed to evaluate overall survival and prognosis. Some of these include the Okuda classification, the Chinese University Prognostic Index, the Advanced Liver Cancer Prognostic system, the Groupe d'Etude et de Traitement du Carcinome Hepatocellulaire score, to name a few. Initial studies for several of these models have shown some prognostic value, but they all need further validation in larger more diverse populations.

4. Workup of the patient with diagnosis of HCC

4.1 Imaging studies

The key radiographic feature of hepatocellular carcinoma is the presence of arterial enhancement and venous washout in contrast enhanced imaging studies (Bruix & Sherman, 2010). The clinical staging of this cancer requires radiologic tests that would provide the finest of details about its gross morphology and extent of involvement. This information will be crucial to direct therapeutic decisions and to provide a better estimate of prognosis to the patient.

Liver transplantation is one of the curative treatment options for early stage hepatocellular carcinomas that meet specific criteria. Careful assessment with imaging studies helps select the most suitable candidates for this treatment option. Particular attention is paid to tumor size, the number of lesions, any presence of vascular invasion, as well as evidence of distant metastasis. The most common sites of extrahepatic metastasis are the lungs, abdominal lymph nodes and bones (Katyal, 2000).

Groundbreaking technological advances in computer tomography (CT), magnetic resonance (MR), ultrasonography, and other imaging modalities have been studied to determine their significance in the workup patients with primary liver cancer. Ultrasound has its merit in screening for hepatomas as it is noninvasive, offers no radiation exposure, is readily available in most centers, and is inexpensive compared to other imaging techniques. Unfortunately its sensitivity is not satisfactory in cirrhotic patients, and lesions can be missed (Kim, 2011). Nonetheless, the corner stones and only accepted techniques for staging hepatocellular carcinoma before liver transplantation are contrast-enhanced CT or MR (J.M. Lee, 2011).

4.1.1 Computer tomography (CT)

Computed tomography has proven to be a great tool for the evaluation of hepatocellular carcinoma in affected patients. It is also commonly the test of choice when looking for extrahepatic metastatic disease. The improvements in the scanners, their resolution as well

as the intravenous contrast material used in these studies, has improved the detection of this hepatic malignancy (B.I. Choi, 2010). The use of multidetector CT scans, for example has markedly highlighted the hypervascular characteristics of hepatomas which were not as evident in earlier CT scan technology (K.H. Lee, 2004). The sensitivity of CT scans has increased due to these advances. However, some studies have shown that the improved accuracy of this imaging technique is more apparent in the detection of larger tumors with classic radiographic features, and when the studies are interpreted by more experienced radiologists (Addley, 2011). It seems that in the setting of cirrhosis and when the lesions are smaller than 1 centimeter in diameter, CT has difficulties over and underestimating the diagnosis of hepatocellular carcinoma (Luca, 2010; Ronzoni, 2007). Similar observations have been shown in large and experienced liver transplant centers where the false positive diagnosis rate of primary liver cancer has been reported as high as 8%, and predominantly seen in lesions that were between 0.75 and 1.5 centimeters in diameter (Brancatelli, 2003). Perhaps the continued progress in the field of computed tomography might some day better characterize these small lesions.

4.1.2 Magnetic resonance (MR)

Magnetic resonance imaging provides another suitable option in the staging of hepatocellular carcinoma during the liver transplantation workup. There is ample evidence that attests the important role of MR in the diagnosis and description of hepatomas. The development of faster MR techniques has contributed to obtaining multiphase intravenous contrast-enhanced images that capture with more detail the hypervascular characteristics of this cancer. One of its most important attributes is its superior ability for the detection of small liver tumors, particularly those less than 2 centimeters in diameter (Burrel, 2003; Colli, 2006; Golfieri, 2009; D.H. Lee, 2009). Given the reported higher sensitivities and accuracy detecting these malignant lesions with the newer MR techniques and contrast agents, many transplant centers have adopted MR as their study of choice when evaluating potential transplant recipients with cirrhosis. One cannot forget that as in the case of CT scans and other imaging modalities, the detection and characterization of hepatocellular carcinoma could also be in part influenced by the experience of the radiologists interpreting these studies. MR use is limited in the setting of patients that have certain types of metallic medical implants or other devices, and on those who are claustrophobic or cannot hold their breath. Recently, gadolinium contrast has also been linked to nephrogenic systemic sclerosis which also limits the use contrast-enhanced MR in patients with significant renal failure, a not uncommon situation in the cirrhotic patient population (Idee, 2009). Nonetheless, the current available evidence has MR as the clear frontrunner in the search for the best imaging modality for diagnosing and characterizing hepatocellular carcinoma.

4.1.3 Contrast enhanced ultrasound (CEUS)

Contrast-enhanced ultrasonography's (CEUS) capability of detecting vascular liver lesions, particularly hepatomas, has been studied and shown some promise (Forner, 2008; Jang, 2007). This modality has even demonstrated remarkable sensitivities and accuracy of 87 and 93% respectively, for diagnosing liver cancer in lesions less than 2 centimeters in diameter (Jang, 2009). Other studies have looked at its utility characterizing portal vein thrombosis as malignant or benign. This differentiation is critical as it has major implications for those

patients being evaluated for liver transplantation. When compared to spiral CT for the detection and characterization of portal vein thrombosis in 50 patients with hepatocellular carcinoma and biopsy-proven portal vein thrombosis, CEUS outperformed CT by detecting 100% of the thrombi and correctly characterizing 49/50 (98%) of them. CT modality detected and correctly characterized 68% of these portal vein thrombi, respectively (Rossi, 2008). CEUS has also demonstrated to be as valuable when compared to biopsy for the assessment of the benign or malignant nature of these thrombi (Sorrentino, 2009). Major drawbacks of this modality are that CEUS is still not available in many countries, and that it is operator dependent.

4.1.4 Other imaging studies

Extrahepatic metastasis is not common in early stage hepatocellular carcinoma (Si, 2003). Nevertheless, physicians working at transplant centers fear to miss its presence in a liver cancer patient who is potentially going to be listed for liver transplantation. The United Network for Organ Sharing (UNOS) implemented a policy in which all centers need to include a chest CT to their protocol to evaluate for lung and lymph node metastasis of hepatoma patients being considered for transplantation (United Network for Organ Sharing [UNOS], 2010). Bone is the other preferred site of spread, and although UNOS had included bones scans in the policies implemented in the 1990s, in light recent evidence provided by several studies, this decision was amended in their most recent liver allocation statements. The significant number of false positive or indeterminate results obtained with this modality is a major disadvantage, as well as the costs incurred for a study that has little impact in the selection of patients given its negligible true-positive yield (Koneru, 2005; Sheth, 2005).

The role of positron emission tomography (PET) has also been studied in patients with hepatocellular carcinoma. In general, the sensitivity of this modality for detection of hepatoma that is less than 5 centimeters in diameter has been low (Trojan, 1999; Wolfort, 2010). PET may have some utility identifying extrahepatic metastasis, but the data available is not strong and sufficient enough to widely recommend this practice (Yoon et al., 2007).

4.2 Biopsy

The use of liver biopsies in the setting of hepatocellular carcinoma is controversial. The radiological advances that have taken place over the past decade have markedly improved detection and characterization of this malignancy, thus reducing the need for liver biopsies to confirm the diagnosis. The United Network for Organ Sharing has stated in its liver allocation policy that biopsy is not mandatory in cirrhotic liver transplant candidates with hepatoma as long as the lesion meets imaging criteria (UNOS, 2010). As a result, liver biopsies are now reserved to situations in which the lesion's radiographic studies are not showing the typical features of enhancement in arterial phase and washout in portal venous phase. This rule applies to tumors greater than 2 centimeters in diameter lacking classic features in one imaging modality, and to lesions between 1 and 2 centimeters in diameter with atypical radiographic characteristics in two different imaging modalities (Bruix & Sherman, 2010).

Pathologic staging of hepatocellular carcinoma is established the majority of the time after surgery (resection or transplantation), whereas clinical staging predominantly relies on

imaging studies and is done before the treatment is decided. Some groups advocate obtaining a pretransplant liver biopsy to exclude candidates with poorly differentiated tumors and to identify patients that might need more aggressive bridging therapy. Dubay and colleagues evaluated this and found that in patients exceeding Milan criteria (single tumor not greater than 5 centimeters in diameter or up to 3 tumors none larger than 3 centimeters in diameter) there was a significant increase in overall 5-year survival (61% versus 79%, $p=0.03$) after the introduction of pretransplant liver biopsies and the use of aggressive bridging therapies (Dubay, 2011). The authors of this study conclude that tumor differentiation might be a more important predictor of biologic behavior than other factors such as size, total tumor diameter, multifocality, and microvascular invasion.

Performing liver biopsies in any patient population carries risks that although small, are not negligible. While pain is the most common complication, bleeding is the most feared and important complication. Severe bleeding events requiring hospitalization and other interventions occur anywhere from 1 in 2,500 to 1 in 10,000 in patients with diffuse, nonfocal liver disease (Rockey, 2009). However, the bleeding risk may be higher in cirrhotic patients, who usually have some degree of coagulopathy and thrombocytopenia. Similar increased risk could be expected in cirrhotic individuals in whom a highly vascular lesion such as hepatocellular carcinoma is being percutaneously biopsied (Huang, 1996). Tumor seeding along the needle track after biopsy has also been reported as a complication in this population (Dubay, 2011; Huang, 1996; Schotman, 1999; Sood, 2002). A recent systematic review and meta-analysis showed that the overall incidence of needle track tumor seeding is 2.7%, or 0.9% per year (M.A. Silva, 2008). These statistics are probably not too high because biopsy of primary hepatic cancer is not a common practice nowadays. However, the risks and benefits of biopsying a liver lesion must always be carefully weighed. This procedure should be reserved to instances when there is reasonable doubt about the diagnosis of hepatoma.

4.3 Criteria for liver transplantation

The field of liver transplantation has gone through many transformations since its early days. Over time this surgical procedure evolved from being a treatment option mostly for individuals with irreversible severe liver dysfunction from any acute or chronic illness to also providing a proven curative alternative for patients with early stage hepatocellular carcinoma. Currently, the success rate and outcomes seen in this subset of liver transplant recipients is similar to that of recipients who underwent transplantation for indications other than hepatoma. This is in great part due to the knowledge and understanding obtained from outstanding clinical studies published over the last 20 years (Bismuth, 1993; Figueras, 1997; Iwatsuki, 1991; Mazzaferro, 1996; Tan, 1995). These studies have paved the way to the creation of the criteria for liver transplantation and guidelines that are used today.

4.3.1 Milan criteria

The Milan criteria are at the present time the accepted and recommended measure to determine the liver transplantation candidacy of patients with hepatocellular carcinoma. This criteria described in a landmark paper by Mazzaferro and colleagues, demonstrated that in patients with cirrhosis and a single tumor up to 5 centimeters, or up to three lesions none larger than 3 centimeters, and with no evidence of extrahepatic spread or

macrovascular invasion the 4-year post-transplant survival was similar to that of recipients transplanted for reasons other than liver cancer (Mazzaferro, 1996). These findings of greater than 70% survival rate gave a second chance to the previously aborted efforts of transplanting cirrhotic patients with primary liver cancer. The United Network for Organ Sharing endorses these criteria, and adopted them for their liver allocation policies of patients with hepatocellular carcinoma (UNOS, 2010). Despite being validated by many studies, some believe that the Milan criteria are too restrictive and exclude a subset of patients with hepatoma that could have excellent outcomes if were transplanted (M.F. Silva & Sherman, 2011).

4.3.2 University of California, San Francisco (UCSF) criteria

Several groups have carried out studies in an effort to determine if patients with hepatocellular carcinoma exceeding Milan criteria could have similar survival and recurrence-free rates than those within the criteria. Yao and his colleagues from the University of California, San Francisco (UCSF) were the first to challenge the parameters set by the Milan criteria. In their retrospective study, cirrhotic patients with a single tumor up to 6.5 centimeters, or up to three lesions none larger than 4.5 centimeters, and total tumor diameter of no more than 8 centimeters had a 1-year and 5-year overall survival of 90% and 75.2%, respectively (Yao, 2001). The UCSF criteria were validated by the same group when they prospectively demonstrated comparable recurrence-free survival between the patients meeting Milan criteria and those meeting UCSF criteria (Yao, 2007). Unfortunately, data about overall 5-year survival was not included in that study.

4.3.3 Other criteria

Following the thought provoking findings of UCSF's study, other groups have also ventured into pushing the limits set by the Milan criteria without compromising overall patient survival and hepatoma recurrence rate. However, several shortcomings affect the validity of these studies. Most of them are retrospective studies, many do not clearly define the size of the tumors, in particular the upper limits, and others have small number of patients to provide convincing and significant findings. In contrast, the results of a recent well-designed, prospective, multi-center study from UNOS region 4 support the belief that liver transplantation could benefit patients whose hepatocellular carcinoma exceed Milan criteria. UNOS region 4 criteria showed patient, allograft and recurrence-free survival to be similar between patients meeting Milan criteria and those meeting their suggested criteria which consists of one lesion up to 6 centimeters, up to three nodules none larger than 5 centimeters, and a total tumor diameter less than 9 centimeters. It will be interesting to see if the data from their 5-year follow up still shows comparable survival rates (Guiteau, 2010). In general, the encouraging results seen from many of the extended criteria studies have stimulated the discussion about amending the current selection criteria to include this subgroup of liver cancer patients that could also benefit from transplantation.

5. Bridging therapies

Due to the aggressive nature of HCC, liver transplantation is of paramount importance in the eradication of HCC and cirrhosis, as it results in a 5-year overall survival of 70% and a recurrence rate of less than 15% among patients whose HCC falls within established criteria

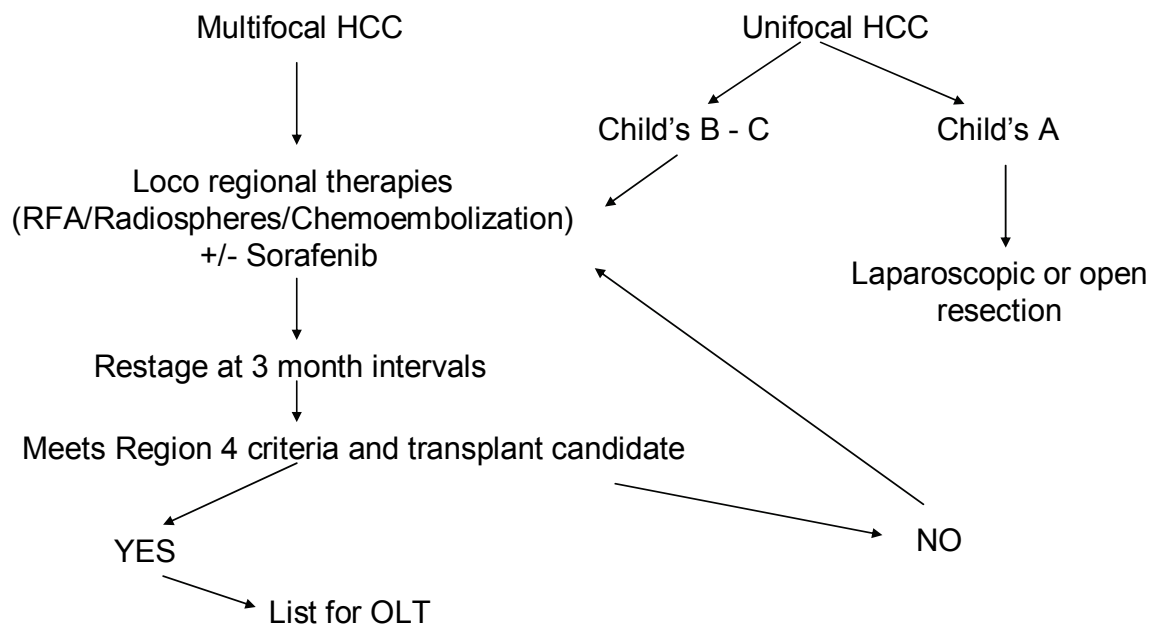
(Decans, 2005; Wigg, 2010). However, fewer than 25% of all patients with HCC qualify for liver transplants. Due to an organ shortage, the average wait period for a liver transplant is 6-9 months. Increased waiting time for HCC patients increases the risk for tumor progression, even with priority listing, and waiting list drop-out, which is defined as withdrawal from the transplant waiting list due to death; tumor progression; or reasons such as becoming too ill for transplantation (Majno, 2010). The dropout rate for HCC patients on the waiting list is 8.7%, 16.9%, and 31.8% at 90, 180, and 365 days respectively. As the doubling time for HCC is approximately 6 months without treatment (Lee, 2007), increased waiting time for transplantation is problematic, and Model for End-Stage Liver Disease (MELD) exception points have been implemented to combat this issue. Since the institution of the MELD system in 2002, transplant candidates with HCC are applicable for listing prioritization via MELD exception points. Patients with HCC within Milan criteria (MC) and in some regions, San Francisco criteria, are granted a MELD exception of 22, followed by upgrades to 25 and 28 every 3 months provided that their tumor burden remains within range. MC is defined as 1 lesion \leq 5 cm or up to 3 lesions \leq 3 cm. Exception points result in shorter time to transplant – in 2007, approximately 62% of patients nationwide underwent transplantation within 3 months of receiving exception points for HCC (Yao, 2008). However, this system can be controversial, as some believe that tumors do not adequately degenerate between the time of ablative therapy and transplantation and that it is safer to wait 6 months after bridging before the patient is transplanted (Roberts, 2010). Others argue that tumor size limits are excessively exclusive and that Milan criteria should be expanded to include a larger tumor burden (Yao, 2008). While patients wait for transplant, loco regional ablative therapy, or bridging therapy, in the form of modalities such as Transarterial Chemoembolization (TACE) and Radiofrequency Ablation (RFA) is often employed with the goals of decreasing the waiting list dropout rate; decreasing the rate of tumor recurrence post transplant; and increasing long term survival after transplant (Lee, 2007). The BCLC staging and treatment strategy incorporates the different ablative therapies in patients with early stage (0); early stage (A); and intermittent stage (B) HCC.

5.1 Goal of ablative therapies

Bridging therapy for HCC serves the following roles: 1) to downstage HCC in patients whose tumor burden is outside MC to make the patient transplantable; 2) to prevent disease progression in patients within MC as they await transplant; and 3) to provide palliative and curative therapy in patients who are not OLTx candidates (Table 1). Bridging therapy can also improve the results of transplantation by excluding patients with recurrent disease or unfavorable tumor biology (Majno, 2010). An example of an integral management of HCC is shown in Graph 1.

Downstaging to Milan/ UCSF criteria
Prevent disease progression on the wait list
Prevent dissemination during liver manipulation at transplant surgery
Tumor therapy in non transplant/ non surgical candidates
Palliative therapy

Table 1. Goal of bridging therapies



Graph 1. HCC Management algorithm at The Liver Institute at Methodist Dallas

5.2 Transarterial chemoembolization (TACE)

Of all bridging therapies, TACE is the most validated and widely studied. TACE consists of occluding blood supply to the tumor or tumors and delivering a chemotherapy agent to the tumor via a branch of the hepatic artery which specifically supplies the tumor. During TACE, a chemotherapy agent such as doxorubicin or cisplatin in combination with lipiodol is injected, followed by an agent such as Gelfoam to occlude the tract. An advantage of TACE is that its use results in a high concentration of chemotherapy to the tumor or tumors; also it is useful in downstaging tumors larger than 3 cm (Pompili, 2005). A disadvantage of TACE is that it is less tolerated among patients with severe hepatic decompensation, such as in patients with ascites and impaired coagulopathy. Also, it is contraindicated in patients with portal vein thrombosis. A meta-analysis of several studies showed a median survival of 20 months with arterial embolization. In one study of 61 patients, the survival rate among those who received TACE at 1 and 4 years post transplant was 87.5% and 69.3%, respectively (Yao, 2008).

5.3 Radiation ablation (RFA)

In RFA, a radiofrequency (RF) probe containing an alternating current of approximately 500 kHz and 131 degrees Fahrenheit, is inserted in or around a hepatic tumor via ultrasound guidance for approximately 4-6 minutes (Yao, 2008). Its mechanism of action is inducing thermal energy to the tissue via electromagnetic energy (Lee, 2007). Many centers use microwave ablation in contrast to RFA with similar or better results. In a study of 40 patients who underwent RFA, the rate of complete necrosis was 51.3% for nodules smaller than 3 cm and 14.3% for larger lesions (Pompili, 2005). In accordance with this study, TACE is perceived as more effective than RFA in treating lesions larger than 3 cm. The limitations of RFA are the anatomical location of the tumor, presence of large ascites, and multifocal HCC, in which cases it cannot be used.

5.4 Percutaneous Ethanol Injection (PEI)

In Percutaneous Ethanol Injection (PEI), ultrasound guidance is used to deliver ethanol over 4-8 sessions performed 1-2 times per week. Its mechanism of action is inducing local tumor necrosis as a result of cellular dehydration, protein denaturalization, and chemical occlusion of tumor vessels (Pompili, 2005). PEI is most effective in treating nodules <3 cm and is overall better tolerated than TACE. However, its major limitation is a high local recurrence rate, which can reach up to 43%. Other limitations include a long treatment time. Overall, RFA has better outcomes than PEI and is better tolerated. In one study, the overall 1-2 year survival rates were higher among patients treated with RFA versus PEI were 86% and 64% versus 77% and 43% respectively (Lencioni, 2010). PEI has similar limitations but less efficacy than RFA and is infrequently used in North America for treatment of HCC.

5.5 Yttrium microspheres

Treatment with Yttrium glass microspheres occurs when a catheter is placed in the hepatic artery and the Therasphere vial, which is comprised of silica containing Yttrium, is rapidly injected. The intent is to deliver 125-150 Gy (12,500 -15,000 rads) of radiation to the tumor or tumors. In a study of 65 patients treated from August 2000 to August 2003, 42 patients (64.6 %) had a significant decrease in tumor size within 4 months. The median survival among Okuda stage I patients was 649 days in historical comparison to a median of 244 days. The median survival among Okuda stage II patients was 302 days in historical comparison to a median of 64 days (Carr, 2004). A benefit of this procedure is that it is generally better tolerated than TACE. Drawbacks are potential radiation to other organ systems and elevated cost. Also, it is also contraindicated in patients with severe liver synthetic dysfunction. To be eligible for treatment, a patient must be relatively well-compensated, with a bilirubin < 2.0 mg/dL, creatinine < 2.0 mg/dL, platelets > 60 K/L, a lung shunt < 16%, and ECOG performance < 2 (Carr, 2004).

5.6 External Beam Radiation Therapy

External Beam Radiation Therapy (EBRT) occurs when radiation is delivered to a tumor after the placement of fiducial markers, which are markers are implanted via sterilized needles under ultrasound or CT guidance. Some clinical reports have demonstrated response rates to EBRT ranging from 80-87.5 for small HCC. EBRT may achieve a 10-12 log decrease in tumor, compared to up to 6 logs associated with chemotherapy. An advantage is that EBRT can be delivered to multiple lesions regardless of the proximity of the tumor or tumors to major hepatic vessels or bile ducts. Another advantage is that it is less costly than procedures such as treatment with Yttrium glass Microspheres: an estimation of EBRT is \$4,047 for treatment and consultation (Wigg, 2010).

6. Surgical therapies for HCC

6.1 Surgical resection for Hepatocellular carcinoma

Surgical resection is contraindicated in patients with decompensated liver disease or Child's B-C classifications. In patients with Child's A cirrhosis and lack of portal hypertension, resection can be offered as an alternative to transplantation. The advantages of resectional therapy over liver transplantation include: no waiting time, no need for long-term

immunosuppression, can be offered to older patients, cost and transplant can be reserved as a salvage therapy. However, liver transplantation can cure not only HCC but also cures the cirrhosis in the remnant liver. Therefore, cancer recurrence in the remnant liver is a significant disadvantage for the resected patients. Poor prognostic factors identified after liver resection for HCC are microvascular invasion, positive margins and older age groups (>65 years old). When resection was offered to patients within Milan criteria, patients with solitary tumors (5 cm or less) had a significantly better 5-year survival rate of 70% versus 46% in patients with 2-3 tumors less than 3 cm (Fan, 2011). In a meta-analysis of the medline database, the 1, 3 and 5 year survivals for liver resection of HCC were 80%, 55% and 37%, respectively. In the same study, liver transplantation for HCC carried a 1, 3 and 5 year survivals of 80%, 70% and 62%, respectively (Morris-Stiff, 2009).

6.2 Salvage liver transplantation after liver resection

The use of resection as a bridge to transplantation has been advocated as a way of solving the organ donor shortage, whereby transplantation is offered only to patients who develop an intrahepatic recurrence. In the United States, a national Consensus Conference on Liver Allocation for HCC, recommended that: 1- a recurrence more than 2 years after resection for HCC of any stage should be considered de novo, and to be considered priority score for HCC if the lesion meets Milan criteria; and 2- a recurrence that presents less than 2 years after resection for a T2 lesion should be eligible for HCC priority score if the lesion meets Milan criteria (Pomfret, 2009). The largest series of salvage transplantation come from French centers with conflicting results: Adam et al (Adam, 2003) report a 5 year survival for salvage transplantation of 29% versus 58% for primary liver transplantation for HCC. In their series, the recurrence rate for liver resection was 77% but only 17% of patients were eligible for salvage transplantation. By utilizing a strategy that offers salvage transplantation for decompensated liver function and positive margins after resection, Belghiti et al (Belghiti, 2003) have shown a comparable 5 year survival for both salvage and primary liver transplantation of 59% and 61%, respectively. The use of resection as a bridge to transplantation may offer important histopathological information that can help identify and subselect patients best suited for transplantation but its application is limited by the fact that only a relatively small number of patients with hepatocellular cancer are candidates for liver resection.

6.3 Laparoscopic resection for HCC

In cirrhotics with preserved liver function and the absence of significant portal hypertension, the laparoscopic approach carries several benefits. Due to the smaller incisions, the collateral abdominal wall circulation is better preserved and an increase in the portal pressure is avoided. Intra-abdominal adhesions are decreased and successful salvage transplantation after laparoscopic resections have been reported (Laurent, 2009). The accepted criteria for laparoscopic approach include: single lesions in peripheral segments of the liver and less than 6 cm in size (Buell, 2008). Outcomes after laparoscopic resection for HCC range from 68 to 74 % 3-year survival (Chen, 2008). In Europe, the 1 and 3 year disease-free survival after laparoscopic resection is 77.5% and 47.1%, respectively (Dagher, 2010); Pittsburgh reported an 88% and 82% disease-free survival at 1 and 3 years, respectively (Nguyen, 2011). The option of laparoscopic or open liver resection for HCC should be

considered in the context of a multidisciplinary approach to the individual patient's tumor, liver reserve and potential transplant candidacy.

7. Liver transplantation for HCC

7.1 Technical considerations of liver transplantation for HCC

Patients undergoing liver transplantation for HCC do not usually have the same degree of liver dysfunction than their counterparts. This difference can be explained for example by the use of allocations systems such as the UNOS (United Network for Organ Sharing), where patients with HCC are prioritized based upon tumor criteria rather than the MELD score. As a result, patients undergoing liver transplantation for HCC can have a lesser degree of portal hypertension and the *hepatectomy* phase of the operation is usually less demanding (Table 2). For this reason, cell savers are usually not needed and should be avoided in case any tumor cells are present in the blood. From the technical standpoint, a few aspects should be considered. Every patient should have a recent staging no older than 3 months when brought in for the transplant. A thorough evaluation of the abdomen and hilum should be performed prior to dividing vital structures and if needed, lymph node biopsies should be obtained to rule out the possibility of metastatic disease. The patients should be informed of the possibility of incidental metastatic disease and no patient should be transplanted with known metastatic disease as this represents a contraindication. The possibility of a back up recipient should be considered in cases where patients are transplanted with criteria exceeding Milan or when the imaging is suggestive of possible metastatic or multifocal disease. Because the hepatectomy involves significant manipulation of the liver, pre-transplant tumor therapies are considered to be 'preventive' in releasing cancer cells in the circulation and are encouraged as a mean to prevent early recurrence of HCC. The survival benefit of pretransplant locoregional therapies has been demonstrated for trans-arterial chemoembolization (Maddala, 2004) and radiofrequency ablation (Pompili, 2005).

Recent Staging imaging (within 3 months)
Back-up recipient available
No cell saver
Explore abdomen and hilar nodes before dividing vital structures
No caval preservation if tumor close to cava
Dissect artery carefully in cases with prior embolization procedures and be prepared for vascular grafts

Table 2. Basic technical principles in Liver Transplantation for HCC

Several techniques are available for the *implantation* of the liver: veno-veno bypass, standard technique with clamp and sew, piggy-back technique and caval preservation with or without temporary portocaval shunt. Different techniques have been compared but no study has proven superiority of any particular technique over the others (Sakai, 2010; Gurusamy, 2011; Viera de Melo, 2011). The caval preservation technique (piggy-back) is the preferred technique at many centers but should be avoided in cases where tumors are close to the retrohepatic inferior vena cava or adjacent to the hepatic vein-caval confluence. In cases where pre-transplant therapies have been performed such as chemo- or radio-

embolization, the gastroduodenal artery has usually been embolized and significant arterial inflammation and fragility can be encountered for the arterial anastomosis. For this reason, arterial grafts should always be available as an alternative mean for reconstruction. The portal vein should be inspected for the presence of thrombus and frozen sections of any large or suspicious clot should be obtained intraoperatively as tumor thrombus is an ominous finding that portends a poor prognosis and is a contraindication for transplantation.

7.2 Immunosuppressive strategies after liver transplantation for HCC

The optimal immunosuppressive regimen for post-transplant HCC patients remains a subject of debate and research. In the patients transplanted for HCC within Milan criteria and without high risk features on explants' pathology, i.e. poor differentiation, vascular invasion or tumor viability, most centers would use the individual program's routine regimen. There is data favoring the use of mammalian target of rapamycin inhibitors (mTORi) as part of the immunosuppression of any patient transplanted for HCC, however this is not widely accepted practice. In a large study based upon the Scientific Registry of Transplant Recipients, 2,491 patients transplanted for HCC were compared to 12,167 patients transplanted for non-HCC diagnoses. In this study, a multivariate analysis demonstrated improved survivals for patients transplanted for HCC and induced with anti-CD25 antibodies or maintained with a sirolimus-based regimen (Toso, 2010). A more challenging clinical scenario comes up when patients present with high risk tumor features, when the liver explants' pathology reveals a larger tumor burden than anticipated and when the recipient presents with tumor recurrence. The use mTORi and sorafenib has been studied as a potential combination against Ras pathway activation in the genesis of hepatocellular carcinoma (Newell, 2009). The use of Everolimus or Sirolimus in combination with Sorafenib has anecdotally been proven to control HCC recurrence (Wang, 2010; Kim, 2011). A close coordination between the transplant and oncology teams should be exercised in this scenario in order to avoid life threatening side effects of the immunosuppressive therapy chosen.

8. Outcomes of liver transplantation for HCC

The outcomes of Liver Transplantation for HCC have improved dramatically due to the introduction of tumor size criteria. In the 1990's, inferior outcomes after transplant were experienced due to recurrence of HCC leading to patient death. An influential observation was made by the Milan group in 1996 and resulted in the *Milan criteria* (Mazzaferro, 1996). This study showed that patients with pretransplant radiological evidence of 2 to 3 tumors ≤ 3 cm in diameter or a single tumor ≤ 5 cm in diameter had a 4 year recurrence free survival of 92% when the explant confirmed the presence of these criteria. The United Network for Organ Sharing in the United States adopted the Milan criteria for transplantation and many publications have confirmed the validity of restricting the tumor size and number. Increasing the number and/or size of transplantable tumors has raised the concern of transplanting a higher incidence of tumors with microvascular invasion, microsatellitosis and poor differentiation (Table 3). In 2001, The UCSF reported outcomes for 70 consecutive patients transplanted at their center and followed for 12 years (Yao et al, 2001). They identified poor survival in patients with pT4 tumors, total tumor diameter ≥ 8

cm, age > 55 years, poorly differentiated histological grade and an α -fetoprotein level > 1000 ng/ml. The survival rates after liver transplantation of patients meeting *the UCSF criteria* (solitary tumor < 6.5 cm, or < 3 nodules with the largest lesion < 4.5 cm and total tumor diameter < 8 cm) on pretransplant imaging was 90% and 75.2%, at 1 and 5 years, respectively. There has been some criticism to the original Milan criteria due to its restrictive nature and for disallowing other potential candidates with HCC who may benefit from transplant. In addition to the UCSF report, another study has demonstrated reasonable outcomes after liver transplantation for HCC. The Metroticket Study group has described the *Up-to Seven criteria*: seven is the result of the sum of size (in cm) and number of tumors for any given HCC (Mazzaferro, 2009). This complex statistical analysis demonstrated that patients who fulfilled the up-to seven criteria but had no microvascular invasion, achieved overall 5-year survivals of 71%. At the present time, the expected survival of Liver Transplantation for HCC at 5 years is 70% and most current allocation systems work under this goal (which equals transplantation for non HCC indications). The future may bring less restrictive allocation rules, as long as the long term benefit is not inferior to the current standards and as long as patients awaiting transplantation for other indications are not disadvantaged.

Macro and Microvascular invasion
Poor differentiation
Microsatellitosis
α -fetoprotein level > 1000 ng/ml
Tumors exceeding standard criteria (Milan, UCSF, Up-to-seven)

Table 3. Poor prognostic factors in Transplantation for HCC

9. Future therapies and challenges

Primary prevention and detection via sophisticated imaging studies, such as MRI and CT, are imperative for the elimination and minimization of HCC. Further research is also necessary in regards to bridging therapy. The development of molecular signatures which predict the natural behavior of HCCs is being explored, and this includes gene arrays which have already shown some promise. We can predict somewhat more accurately now than ever the propensity of tumors to metastasize and recur after transplant with certain markers such as micro vascular invasion or microsatellitosis on the explant specimens. The grade of HCCs, as characterized by an experienced pathologist on biopsy or explant, has gained importance over the years in prognosticating the natural history of the cancer and its risk of recurrence after resection or transplant. Immunohistochemical markers are being constantly developed- and some have already been tested- regarding the presence of positive CK7 and CK 17 staining in HCCs, which portends a more aggressive cancer with higher recurrence rates. The use of systemic chemotherapy in the form of multikinase inhibitors such as sorafenib in combination with ablative procedures such as TACE, RFA or radioembolization has been used with success and is likely to gain momentum in the future. Furthermore, systemic chemotherapy is more frequently employed after surgery or even after transplantation in patients with high risk tumors. An important consideration for bridging therapy is that it is difficult to completely eradicate tumors >3 cm in size or multifocal HCC, and this area especially merits further exploration. Finally, in the era of organ shortage,

alternative curative modalities to transplant are certainly a need of the hour. With advances in laparoscopic surgical techniques, use of portal vein embolization, and adequate and aggressive ablative techniques pre-operatively, more patients than in the previous years can be made suitable for surgical resection safely and effectively. On the vanguard of medicine is the phenomenon of stem cell research and a discussion on HCC is incomplete without its mention- like other solid tumors- it is believed though not completely elucidated that cancer stem cells may have an important role to play in the natural history and response to treatment of HCCs. Although these stem cells in the liver have not been accurately identified, there is intensive investigation in this area (Wen Xu, 2009). The further development of these stem cells has boundless potential in the prognostication and treatment of this cancer.

10. References

- Adam R, Azoulay D, Castaing D et al. Liver resection as a bridge to transplantation for hepatocellular carcinoma on cirrhosis: a reasonable strategy ? *Ann Surg* 2003; 238(4):508-518
- Addley HC, Griffin N, Shaw AS et al. Accuracy of hepatocellular carcinoma detection on multidetector CT in a transplant liver population with explants liver correlation. *Clin Radiol* 2011;66(4):349-56
- Altekruse SF, McGlynn KA, Reichman ME. Hepatocellular carcinoma incidence, mortality, and survival trends in the United States from 1975 to 2005. *J Clin Oncol* 2009;27(9):1485-91
- Belghiti J, Cortes A, Abdalla EK, et al. Resection prior to liver transplantation for hepatocellular carcinoma. *Ann Surg* 2003;238(6):885-892
- Beyazit Y, Kekilli M, Kurt M et al. Role of IL-6 activated STAT3 and TNF expression in obesity-associated hepatocellular carcinoma. *Aliment Pharmacol Ther* 2010;32:304-5
- Bismuth H, Chiche L, Adam R et al. Liver resection versus transplantation in cirrhotic patients with hepatocellular carcinoma in cirrhosis. *Ann Surg* 1993;218:145-51
- Bosch FX, Ribes J, Cleries R et al. Epidemiology of hepatocellular carcinoma. *Clin Liver Dis* 2005;9(2):191-211
- Bosch FX, Ribes J, Diaz M, et al. Primary liver cancer: worldwide incidence and trends. *Gastroenterology* 2004;127(suppl 1):s5-16
- Brancatelli G, Baron RL, Peterson MS et al. Helical CT screening for hepatocellular carcinoma in patients with cirrhosis: frequency and causes of false-positive interpretation. *Am J Roentgenol* 2003;180(4):1007-14
- Bruix J, Sherman M. Management of hepatocellular carcinoma: an update. *American Association for the Study of Liver Diseases*, July 2010
- Buell JF, Cherqui D, Geller DA, et al. World Consensus Conference on Laparoscopic Surgery. The international position on laparoscopic liver surgery: the Louisville Statement, 2008. *Ann Surg*. 2009;250(5):825-830.
- Bungianesi E, Leone N, Vanni E, et al. Expanding the natural history of nonalcoholic steatohepatitis: from cryptogenic cirrhosis to hepatocellular carcinoma. *Gastroenterology* 2002;123:134-40

- Burrel M, Llovet JM, Ayuso C et al. MRI angiography is superior to helical CT for detection of HCC prior to liver transplantation: an explants correlation. *Hepatology* 2003;38(4):1034-42
- Calle EE, Rodriguez C, Walker-Thurmond K, et al. Overweight, obesity and mortality from cancer in a prospectively studied cohort of U.S. adults. *N Engl J Med* 2003;348:1625-38
- Carr, B. Hepatic Arterial Yttrium Glass Microspheres (Therasphere) for Unresectable Hepatocellular Carcinoma: Interim Safety and Survival Data on 65 Patients. *Liver Transplantation* 10 (2004): 107-110.
- Chang MH, Chen CJ, Lai MS et al. Universal hepatitis B vaccination in Taiwan and the incidence of hepatocellular carcinoma in children. Taiwan Childhood Hepatoma Study Group. *N Engl J Med* 1997;336(26):1855-9
- Chang MH, You SL, Chen CJ et al. Decreased incidence of hepatocellular carcinoma in hepatitis B vaccinees: a 20 year follow up study. *J Natl Cancer Inst* 2009;101(19):1348-55
- Chen HY, Juan CC, Ker CG. Laparoscopic liver surgery for patients with hepatocellular carcinoma. *Ann Surg Oncol*. 2008;15(3):800-806.
- Chen TW, Chu CM, Yu JC et al. Comparison of clinical staging systems in predicting survival of hepatocellular carcinoma patients receiving major or minor hepatectomy. *Eur J Surg Oncol* 2007;33(4):480-7
- Choi BI. Advances of imaging for hepatocellular carcinoma. *Oncology* 2010;78(suppl 1):46-52
- Choi SB, Lee JG, Kim KS et al. The prognosis and survival analysis according to seven staging systems of hepatocellular carcinoma following curative resection. *HepatoGastroenterology* 2008;55:2140-5
- Cillo U, Bassanello M, Vitale A et al. The critical issue of hepatocellular carcinoma prognostic classification: Which is the best available? *J Hepatol* 2004;40:124-31
- Cillo U, Vitale A, Grigoletto F et al. Prospective validation of the Barcelona Clinic Liver cancer staging system. *J Hepatol* 2006;44:723-31
- Colli A, Fraquelli M, Casazza G et al. Accuracy of ultrasonography, spiral CT, magnetic resonance, and alpha feto-protein in the diagnosis of hepatocellular carcinoma: a systematic review. *Am J Gastroenterol* 2006;101(3):513-23
- Dagher I, Belli G, Fantini C, et al. Laparoscopic hepatectomy for hepatocellular carcinoma: a European experience. *J Am Coll Surg*. 2010;211:16-23
- Davila JA, Morgan RO, Shaib Y et al. Hepatitis C infection and the increasing incidence of hepatocellular carcinoma: a population-based study. *Gastroenterology* 2004;127:1372-80
- Davis GL, Alter MJ, El-Serag HB, et al. Aging of hepatitis C virus-infected persons in the United States: a multiple cohort model of HCV prevalence and disease progression. *Gastroenterology* 2010;138(2):513-21
- Decans T, Roudot-Thoraval F, Bresson-Hadi, C, et al. Impact of Pretransplantation Transarterial Chemoembolization on Survival and Recurrence After Liver Transplantation for Hepatocellular Carcinoma. *Liver Transpl* 11 (2005): 767-775.
- Dohmen K. Many staging systems for hepatocellular carcinoma: Evolution from Child-Pugh, Okuda to SLiDe. *J Gastroenterol Hepatol* 2004;19(11):1227-32

- Donato F, Boffetta P, Puoti M. A meta-analysis of epidemiological studies on the combined effect of hepatitis B and C virus infections in causing hepatocellular carcinoma. *Int J Cancer* 1998;75(3):347-54
- Donato F, Tagger A, Gelatti U, et al. Alcohol and hepatocellular carcinoma: the effect of lifetime intake and hepatitis virus infections in men and women. *Am J Epidemiol* 2002;155(4):323-31
- Dubay D, Sandroussi C, Sandhu L et al. Liver transplantation for advanced hepatocellular carcinoma using poor tumor differentiation on biopsy as an exclusion criteria. *Ann Surg* 2011;253:166-72
- El-Serag HB, Lau M, Eschbach K, et al. Epidemiology of hepatocellular carcinoma in Hispanics in the United States. *Arch Intern Med* 2007;167(18):1983-9
- El-Serag HB, Rudolph L. Hepatocellular carcinoma: Epidemiology and molecular carcinogenesis. *Gastroenterology* 2007;132(7):2557-76
- El-Serag HB, Tran T, Everhart JE. Diabetes increases the risk of chronic liver disease and hepatocellular carcinoma. *Gastroenterology* 2004;126:460-8
- Fan ST, Poon RT, Yeung C et al. Outcome after partial hepatectomy for hepatocellular cancer within the Milan criteria. *Br J Surg* 2011 Sep; 98 (9):1292-1300
- Figueras J, Jaurrieta E, Valls C et al. Survival after liver transplantation in cirrhotic patients with and without hepatocellular carcinoma: a comparative study. *Hepatology* 1997;25(6):1485-9
- Forner A, Vilana R, Ayuso C et al. Diagnosis of hepatic nodules 20mm or smaller in cirrhosis: prospective validation of the noninvasive diagnostic criteria for hepatocellular carcinoma. *Hepatology* 2008;47(1):97-104
- Freeman AJ, Dore GJ, Law MG, et al. Estimating progression to cirrhosis in chronic hepatitis C virus infection. *Hepatology* 2001;34(4):809-16
- Golfieri R, Marini E, Bazzocchi A et al. Small (≤ 3 cm) hepatocellular carcinoma in cirrhosis: the role of double contrast agents in MR imaging vs. multidetector-row CT. *Radiol Med* 2009;114(8):1239-66
- Greene FL, Sobin LH. The staging of cancer: a retrospective and prospective appraisal. *CA Cancer J Clin* 2008;58(3):180-90
- Guglielmi A, Ruzzenente A, Pachera S et al. Comparison of seven staging systems in cirrhotic patients with hepatocellular carcinoma in a cohort of patients who underwent radiofrequency ablation with complete response. *Am J Gastroenterol* 2008;103:597-604
- Guiteau JJ, Cotton RT, Washburn WK et al. An early regional experience with expansion of Milan criteria for liver recipients. *Am J Transpl* 2010;10(9):2092-8
- Gursoy-Yuzugullu O, Yuzugullu H, Yilmaz M, et al. Aflatoxin genotoxicity is associated with a defective DNA damage response bypassing p53 activation. *Liver Int* 2011;31(4):561-71
- Gurusamy KS, Pamecha V, Davidson BR. Piggy-back graft for liver transplantation. *Cochrane Database Syst Rev* 2011 Jan 19;(1) CD008258
- Hsu CY, Hsia CY, Huang YH, et al. Selecting an optimal staging system for hepatocellular carcinoma: comparison of 5 currently used prognostic models. *Cancer* 2010;116(12):3006-14
- Huang GT, Sheu JC, Yang PM et al. Ultrasound-guided cutting biopsy for the diagnosis of hepatocellular carcinoma: a study based on 420 patients. *J Hepatol* 1996;25:334-8

- Idee JM, Port M, Dencausse A et al. Involvement of gadolinium chelates in the mechanism of nephrogenic systemic fibrosis: an update. *Radiol Clin North Am* 2009;47(5):855-69
- Iwatsuki S, Starzl TE, Sheahan DG et al. Hepatic resection versus transplantation for hepatocellular carcinoma. *Ann Surg* 1991;14(3):221-8
- Jang HJ, Kim TK, Burns PN et al. Enhancement patterns of hepatocellular carcinoma at contrast-enhanced US: comparison with histologic differentiation. *Radiology* 2007;244(3):898-906
- Jang HJ, Kim TK, Wilson SR. Small nodules (1-2cm) in liver cirrhosis: characterization with contrast-enhanced ultrasound. *Eur J Radiol* 2009;72(3):418-24
- Kanwal F, Hoang T, Kramer JT et al. Increasing prevalence of HCC and cirrhosis in patients with chronic hepatitis C virus infection. *Gastroenterology* 2011;40(4):1182-88
- Katyal S, Oliver JH, Peterson MS et al. Extrahepatic metastases of hepatocellular carcinoma. *Radiology* 2000;216(3):698-703
- Kim KA, Kim MJ, Choi JY et al. Development of hepatocellular carcinoma in patients with absence of tumors on a prior ultrasound examination. *Eur J Radiol* 2011, doi:10.1016/j.ejrad.2011.03.053
- Kim R, Aucejo F. Radiologic complete response with sirolimus and sorafenib in a hepatocellular carcinoma patient who relapsed after orthotopic liver transplantation. *J Gastrointest cancer* 2011 Mar ;42 (1):50-3
- Kitai S, Kudo M, Minami Y et al. A new prognostic staging system for hepatocellular carcinoma: value of the biomarker combined Japan Integrated Staging score. *Intervirology* 2008;51(suppl 1):86-94
- Koneru B, Teperman LW, Manzarbeitia C et al. A multicenter evaluation of utility of chest computer tomography and bone scan in liver transplant candidates with stage I and II hepatoma. *Ann Surg* 2005;241:622-8
- Kudo M, Chung H, Haji S et al. Validation of a new prognostic staging system for hepatocellular carcinoma: The JIS score compared with the CLIP score. *Hepatology* 2004;40:1396-1405
- Kudo M, Chung H, Osaki Y. Prognostic staging system for hepatocellular carcinoma (CLIP score): its value and limitations, and a proposal for a new staging system, the Japan Integrated Staging score (JIS score). *J Gastroenterol* 2003;38:207-15.
- Laurent A, Tayar C, Andréoletti M, et al. Laparoscopic liver resection facilitates salvage liver transplantation for hepatocellular carcinoma. *J Hepatobiliary Pancreat Surg*. 2009;16(3):310-4.
- Lee DH, Kim SH, Lee JM et al. Diagnostic performance of multidetector row computed tomography, superparamagnetic iron oxide-enhanced magnetic resonance imaging, and dual-contrast magnetic resonance imaging in predicting the appropriateness of a transplant recipient based on Milan criteria: correlation with histopathological findings. *Invest Radiol* 2009;44(6):311-21
- Lee JM, Trevisani F, Vilgrain V et al. Imaging diagnosis and staging of hepatocellular carcinoma. *Liver Transpl* 2011, doi:10.1002/lt.22369
- Lee KH, O'Malley ME, Haider MA et al. Triple-phase MDCT of hepatocellular carcinoma. *Am J Roentgenol* 2004;182(3):643-9
- Lee, F. Treatment of Hepatocellular Carcinoma in Cirrhosis: Locoregional Therapies for Bridging to Liver Transplant. *Liver Transpl* 13 (2007). 24-26.

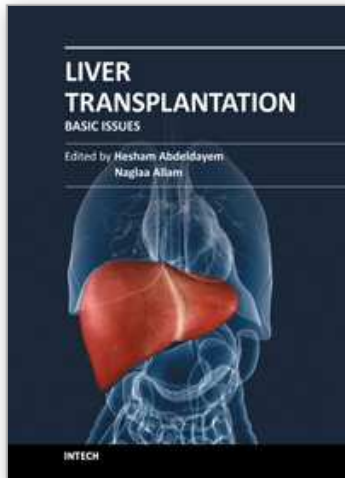
- Lencioni, R., Cioni, D., Crocetti, L., and Bartolozzi, C. "Percutaneous Ablation of Hepatocellular Carcinoma: State-of-the-Art." *Liver Transpl* 10 (2004): 91-96.
- Liu Y, Wu F. Global burden of aflatoxin-induced hepatocellular carcinoma: a risk assessment. *Environ Health Perspect* 2010;118:818-24
- Llovet JM, Bru C, Briux J. Prognosis of hepatocellular carcinoma: the BCLC staging classification. *Semin Liver Dis* 1999;19(3):329-38
- Llovet JM, Bustamante J, Castells A et al. Natural history of untreated nonsurgical hepatocellular carcinoma: rationale for the design and evaluation of therapeutic trials. *Hepatology* 1999;29(1):62-7
- Lu W, Dong J, Huang Z, et al. Comparison of four staging systems for Chinese patients with hepatocellular carcinoma undergoing curative resection: Okuda, CLIP, TNM, and CUPI. *J Gastroenterol Hepatol* 2008;23(12):1874-8
- Luca A, Caruso S, Milazzo M et al. Multidetector-row computer tomography (MDCT) for the diagnosis of hepatocellular carcinoma in cirrhotic candidates for liver transplantation: prevalence of radiological vascular patterns and histological correlation with liver explants. *Eur Radiol* 2010;20(4):898-907
- Maddala YK, Stadheim L, Andrews JC et al. Drop-out rates of patients with hepatocellular cancer listed for liver transplantation: outcome with chemoembolization. *Liver Transpl* 2004;10:449-455
- Majno, P., Mentha, G., and Toso, C. "Transplantation for Hepatocellular Carcinoma: Management of Patients on the Waiting List." *Liver Transpl* 16 (2010): 2-11.
- Marrero JA, Fontana RJ, Barrat A et al. Prognosis of hepatocellular carcinoma: Comparison of 7 staging systems in an American cohort. *Hepatology* 2005;41:707-16
- Marrero JA, Kudo M, Bronowicki JP. The challenge of prognosis and staging for hepatocellular carcinoma. *Oncologist* 2010;15(suppl 4):23-33
- Mazzaferro V, Llovet JM, Miceli R, et al. Predicting survival after liver transplantation in patients with hepatocellular carcinoma beyond the Milan criteria: a retrospective, exploratory analysis. *Lancet oncol* 2009 Jan 10(1):35-43
- Mazzaferro V, Regalia E, Doci R et al. Liver transplantation for the treatment of small hepatocellular carcinoma in patients with cirrhosis. *N Eng J Med* 1996;334(11):693-9
- Morris-Stiff G, Gomez D, de Liguori Carino N et al. Surgical management of hepatocellular carcinoma: is the jury still out ?. *Surg Oncol* 2009 Dec;18(4):298-321
- Nanashima A, Omagari K, Tobinaga S et al. Comparative study of survival of patients with hepatocellular carcinoma predicted by different staging systems using multivariate analysis. *Eur J Surg Onc* 2005;31(8):882-90
- Newell P, Toffanin S, Villanueva A, et al. Ras pathway activation in hepatocellular carcinoma and anti-tumoral effect of combined sorafenib and rapamycin in vivo. *J Hepatol* 2009, Oct ; 51 (4): 725-33
- Nguyen KT, Marsh JW, Tsung A, et al. Comparative benefits of laparoscopic vs open hepatic resection: A critical appraisal. *Arch Surg*. 2011; 146(3):348-356.
- Nordenstedt H, White DL, El-Serag HB. The changing pattern of epidemiology in hepatocellular carcinoma. *Dig Liver Dis* 2010;42(suppl 3):s206-14
- Park EJ, Lee JH, Yu GY et al. Dietary and genetic obesity promote liver inflammation and tumorigenesis by enhancing IL-6 and TNF expression. *Cell* 2010;140:197-08
- Parkin DM, Bray F, Ferlay J et al. Global cancer statistics, 2002. *CA Cancer J Clin* 2005;55(2):74-108

- Perz JF, Armstrong GL, Farrington LA et al. The contributions of hepatitis B virus and hepatitis C virus infections to cirrhosis and primary liver cancer worldwide. *J Hepatol* 2006;45(4):529-38
- Pomfret EA, Washburn K, Wald C et al. Report of a national Conference on Liver Allocation in patients with hepatocellular carcinoma in the United States. *Liver Transpl* 2010;16:262-278
- Pompili M, Mirante VG, Rondinara G et al. Percutaneous ablation procedures in cirrhotic patients with hepatocellular carcinoma submitted to liver transplantation: assessment of efficacy at explant analysis and of safety for tumor recurrence. *Liver Transpl* 2005; 41:1130-1137
- Roberts, J., Vennok, A., Kerlan, R. et al. "Hepatocellular Carcinoma: Ablate and Wait Versus Rapid Transplantation." *Liver Transplantation* 16 (2010): 925-929.
- Rockey DC, Caldwell SH, Goodman Z et al. Liver biopsy. *Hepatology* 2009;49(3):1017-44
- Ronzoni A, Artioli D, Scardina R et al. Role of MDCT in the diagnosis of hepatocellular carcinoma in patients with cirrhosis undergoing orthotopic liver transplantation. *Am J Roentgenol* 2007;189(4):792-8
- Rossi S, Ghittoni G, Ravetta V et al. Contrast-enhanced ultrasonography and spiral CT in detection and characterization of portal vein thrombosis complicating hepatocellular carcinoma. *Eur Radiol* 2008;18:1749-56
- Sakai T, Matsusaki T, Marsh JW et al. Comparison of surgical methods in liver transplantation: retrohepatic caval resection with veno-venous bypass (VVB) versus piggyback (PB) with VVB versus PB without VVB. *Transpl Int* 2010 Dec;23(12):1247-58
- Schotman SN, De Man RA, Stoker J et al. Subcutaneous seeding of hepatocellular carcinoma after percutaneous liver biopsy. *Gut* 1999;45(4):625-6
- Sherman M. Hepatocellular carcinoma: screening and staging. *Clin Liver Dis* 2011;15(2):323-34
- Sheth H, Javed SS, Hilson AJW et al. Radioisotope bone scan in preoperative staging of hepatopancreatobiliary cancer. *Br J Surg* 2005;92(2):203-7
- Shi J, Zhu L, Liu S, et al. A meta-analysis of case-control studies on the combined effects of hepatitis B and C virus infections in causing hepatocellular carcinoma in China. *Br J Cancer* 2005;92(3):607-12
- Si MS, Amersi F, Golish SR et al. Prevalence of metastases in hepatocellular carcinoma: risk factors and impact on survival. *Am Surg* 2003;69(10):879-85
- Silva MA, Hegab B, Hyde C et al. Needle track seeding following biopsy of liver lesions in the diagnosis of hepatocellular cancer: a systematic review and meta-analysis. *Gut* 2008;57(11):1592-6
- Silva MF, Sherman M. Criteria for liver transplantation for HCC: what should the limits be? *J Hepatol* 2011, doi:10.1016/j.jhep.2011.05.012
- Sood A, Midha V, Sood N. Needle track metastasis of primary liver carcinoma after percutaneous needle aspiration. *Am J Gastroenterol* 2002;97(3):765-6
- Sorrentino P, D'Angelo S, Tarantino L et al. Contrast-enhanced sonography versus biopsy for the differential diagnosis of thrombosis in hepatocellular carcinoma patients. *World J Gastroenterol* 2009;15(18):2245-51
- Sun JJ, Tsoi KK, Wong VW, et al. Meta-analysis: Treatment of hepatitis B infection reduces risk of hepatocellular carcinoma. *Aliment Pharmacol Ther* 2008;28(9):1067-77

- Tan KC, Rela M, Ryder SD et al. Experience of orthotopic liver transplantation and hepatic resection for hepatocellular carcinoma of less than 8 cm in patients with cirrhosis. *Br J Surg* 1995;82:253-6
- Tanaka H, Imai Y, Hiramatsu N et al. Declining incidence of hepatocellular carcinoma in Osaka, Japan, from 1990 to 2003. *Ann Intern Med* 2008;148(11):820-6
- The Cancer of the Liver Italian Program (CLIP) Investigators. A new prognostic system for hepatocellular carcinoma: A retrospective study of 435 patients. *Hepatology* 1998;28:751-5
- Thein HH, Yi Q, Dore GJ, et al. Estimation of stage-specific fibrosis progression rates in chronic hepatitis C virus infection: a meta-analysis and meta-regression. *Hepatology* 2008;48(2):418-31
- Toso C, Merani S, Bigam DL et al. Sirolimus-based immunosuppression is associated with increased survival after liver transplantation for hepatocellular carcinoma. *Hepatology*, 2010 Apr; 51 (4):1237-43
- Trojan J, Schroeder O, Raedle J et al. Flourine-18 FDG positron emission tomography for imaging of hepatocellular carcinoma. *Am J Gastroenterol* 1999;94(11):3314-9
- Ueno S, Tanabe G, Sako K, et al. Discrimination value of the new western prognostic system (CLIP score) for hepatocellular carcinoma in 662 Japanese patients. *Cancer of the Liver Italian Program. Hepatology* 2001;34:529-34
- United Network for Organ Sharing. Policies 3.6:organ distribution: allocation of livers. Available at <http://www.unos.org>
- Viera de Melo PS, Miranda LE, Batista LL et al. Orthotopic liver transplantation without venovenous bypass using the conventional and piggyback techniques. *Transplant Proc* 2011 May; 43(4): 1327-33
- Wang JH, Changchien CS, Hu TH et al. The efficacy of treatment schedules according to Barcelona Clinic Liver Cancer staging for hepatocellular carcinoma: Survival analysis of 3892 patients. *Eur J Cancer* 2008;44:1000-6
- Wang Y, Speeg KV, Washburn WK et al. Sirolimus plus sorafenib in treating HCC recurrence after liver transplantation: a case report. *World J Gastroenterol* 2010 Nov 21;16(43):5518-22
- Wen Xu et al. Progress and Prospects in cancer stem cell research in hepatocellular carcinoma. *Chinese Journal of Cancer* 28 (2009): 43
- Wigg, A., Palumbo, K., and Wigg, D. Radiotherapy for Hepatocellular carcinoma: Systemic review of radiobiology and modeling projects indicate reconsideration of its use. *Journal of Gastroenterology and Hepatology* 25 (2010): 664-617.
- Wolfort RM, Papillion PW, Turnage RH et al. Role of FDG-PET in the evaluation and staging of hepatocellular carcinoma with comparison to tumor size, AFP level and histologic grade. *Int Surg* 2010;95(1):67-75
- Wree A, Kahraman A, Gerken G, et al. Obesity affects the liver- the link between adipocytes and hepatocytes. *Digestion* 2011;83:124-33
- Xu LB, Wang J, Liu C et al. Staging systems for predicting survival of patients with hepatocellular carcinoma after surgery. *World J Gastroenterol* 2010;16(41)5257-62
- Yang HI, Lu SN, Liaw YF, et al. Hepatitis B e antigen and the risk for hepatocellular carcinoma. *N Engl J Med* 2002;347(3):168-74

- Yao FY, Ferrel L, Bass NB et al. Liver Transplantation for Hepatocellular carcinoma: expansion of the tumor size limits does not adversely impact survival. *Hepatology* 2001; 33:1394-1403
- Yao FY, Ferrell L, Bass NM et al. Liver transplantation for hepatocellular carcinoma: expansion fo the tumor size limits does not adversely impact survival. *Hepatology* 2001;33:1394-1403
- Yao FY, Xiao L, Bass NM et al. Liver transplantation for hepatocellular carcinoma: validation of the UCSF-expanded criteria based on preoperative imaging. *Am J Transpl* 2007;7(11):2587-96
- Yao F, Kerlan R, Hirose R, et al. Excellent Outcome Following Down-staging of Hepatocellular Carcinoma prior to Liver Transplantation: An Intention-to-treat Analysis. *Hepatology* (2008): 819-827.
- Yoon KT, Kim JK, Kim do Y et al. Role of 18-fluorodeoxyglucose positron emission tomography in detecting extrahepatic metastasis in pretreatment staging of hepatocellular carcinoma. *Oncology* 2007;(suppl 1):104-10
- Yoshizawa H. Hepatocellular carcinoma associated wth hepatitis C virus infection in Japan: projection to the other countries in the foreseeable future. *Oncology* 2002;62(suppl 1):8-17
- Yu MW, Yang YC, Yang SY. Hormonal markers and hepatitis B virus-related hepatocellular carcinoma risk: a nested case-control study among men. *J Natl Cancer Inst* 2001;93(21):1644-51

IntechOpen



Liver Transplantation - Basic Issues

Edited by Prof. Hesham Abdeldayem

ISBN 978-953-51-0016-4

Hard cover, 418 pages

Publisher InTech

Published online 15, February, 2012

Published in print edition February, 2012

This book covers a wide spectrum of topics including history of liver transplantation, ischemia-reperfusion injury, immunology of liver transplantation, viral hepatitis and liver transplantation, other indications for liver transplantation, prognostic factors and perioperative period. The authors of the chapters are experts in their respective fields. They are proponents covering different aspects of liver transplantation and come from many centers across the world. The interdisciplinary approach and the authority of the contributors resulted in a valuable reference to anyone interested in developing a global view in liver transplantation including medical students, residents, fellows, nurses, and practicing physicians and surgeons as well as researchers in the field of liver transplantation.

How to reference

In order to correctly reference this scholarly work, feel free to copy and paste the following:

Alejandro Mejia, Hector Nazario and Parvez Mantry (2012). Liver Transplantation for Hepatocellular Carcinoma (Hcc), Liver Transplantation - Basic Issues, Prof. Hesham Abdeldayem (Ed.), ISBN: 978-953-51-0016-4, InTech, Available from: <http://www.intechopen.com/books/liver-transplantation-basic-issues/liver-transplantation-for-hepatocellular-carcinoma-hcc->

INTECH
open science | open minds

InTech Europe

University Campus STeP Ri
Slavka Krautzeka 83/A
51000 Rijeka, Croatia
Phone: +385 (51) 770 447
Fax: +385 (51) 686 166
www.intechopen.com

InTech China

Unit 405, Office Block, Hotel Equatorial Shanghai
No.65, Yan An Road (West), Shanghai, 200040, China
中国上海市延安西路65号上海国际贵都大饭店办公楼405单元
Phone: +86-21-62489820
Fax: +86-21-62489821

© 2012 The Author(s). Licensee IntechOpen. This is an open access article distributed under the terms of the [Creative Commons Attribution 3.0 License](#), which permits unrestricted use, distribution, and reproduction in any medium, provided the original work is properly cited.

IntechOpen

IntechOpen