

# We are IntechOpen, the world's leading publisher of Open Access books Built by scientists, for scientists

**4,800**

Open access books available

**122,000**

International authors and editors

**135M**

Downloads

Our authors are among the

**154**

Countries delivered to

**TOP 1%**

most cited scientists

**12.2%**

Contributors from top 500 universities



**WEB OF SCIENCE™**

Selection of our books indexed in the Book Citation Index  
in Web of Science™ Core Collection (BKCI)

Interested in publishing with us?  
Contact [book.department@intechopen.com](mailto:book.department@intechopen.com)

Numbers displayed above are based on latest data collected.

For more information visit [www.intechopen.com](http://www.intechopen.com)



# Vascular and Biliary Anastomoses in Deceased Donor Orthotopic Liver Transplantation

Steven Cohn, Julie Stein, Alan Koffron and Vandad Raofi  
*Oakland University William Beaumont School of Medicine / Beaumont Health System  
USA*

## 1. Introduction

The purpose of this chapter is to review the various techniques of implantation for deceased donor liver transplants (DDLT). Given the overall broad nature of the topic, the focus will be exclusively on adult DDLT, without including split liver and living donor liver transplants.

There are a total of five structures that have to be reconstructed in DDLT. These include the suprahepatic and infrahepatic vena cava, the portal vein, the hepatic artery and the bile duct. Prior to describing the various methods of implantation of the donor liver, we will briefly review the different options available for the recipient hepatectomy, as the surgeon's choice of reconstruction of the vena cava will dictate the type of hepatectomy performed. For a bicaval anastomosis, the hepatectomy involves completely dissecting out the supra- and infrahepatic vena cava, mobilizing the inferior vena cava (IVC) off of the retroperitoneum, achieving full vascular isolation and subsequently removing the intrahepatic portion of the IVC with the native liver. In this scenario, the use of venovenous bypass may be required for hemodynamic stability of the patient. The traditional method involves reconstruction of the suprahepatic and infrahepatic donor cava to the corresponding structures in the recipient.

A second option is to preserve the vena cava by dissecting the native liver off of the IVC completely. Subsequently, we describe several ways in which the cava is reanastomosed in the setting of caval preservation. One method is commonly known as the "piggyback" technique where two or all three recipient hepatic veins are joined together into a common orifice which is used as the site of anastomosis. Other configurations of caval anastomosis are also used, including side-to-side and end-to-side techniques. Finally, we discuss a modification of the lateral cavo-cavostomy.

The remainder of the implantation is similar regardless of the method chosen for caval reconstruction. The next anastomosis is usually the portal vein (PV). For the most part, portal vein reconstruction is straightforward unless there is partial or complete thrombosis of the recipient portal vein. If thrombectomy fails, then a venous conduit may be necessary. Other salvage maneuvers are used if even a conduit is not possible.

At this point, the liver is usually reperfused. In some situations, hepatic arterial reperfusion is performed simultaneously with portal, or even precedes portal reconstruction. Close cooperation between the surgical and anesthesia team is necessary at this critical time as reperfusion instability may result.

Hepatic arterial reconstruction probably has the most options, as anatomic variations are common, and depending on surgeon preference, different techniques of reconstruction are available. If there is inadequate inflow from the recipient's hepatic artery or its branches, an arterial conduit between the recipient aorta and donor artery may be necessary.

The last anastomosis is the biliary, which has been dubbed the "Achilles heel" of DDLT. Options for reconstructing the bile duct include common duct to common duct anastomosis for the donor and recipient. The second method is a Roux-en-Y hepaticojejunostomy. We will discuss the indications for a Roux reconstruction, and mention some controversies regarding biliary reconstruction.

While an attempt is made to mention many variations in technique, the reader should bear in mind the fact that there are numerous small modifications that are done on a case by case basis based upon the surgeon's preference and personal experience.

## 2. Recipient hepatectomy

Deceased donor liver transplantation (DDLT) can be divided into several distinct steps. The first is the recipient hepatectomy, followed by the anhepatic phase, and finally reperfusion of the donor graft and completion of the arterial and biliary reconstruction. It would be difficult to simply focus on the implantation of the donor graft without mentioning the recipient hepatectomy, as the choice of vascular reconstruction during the implantation essentially dictates the type of hepatectomy performed.

A key factor to improving outcomes in DDLT is minimizing the cold ischemic time especially in marginal donors or in donation after cardiac death. Therefore, we prefer to have two surgical teams. Once the procurement team has visualized the donor liver and reviewed any biopsies if indicated, the decision is made to proceed or abort the recipient case. If the donor liver is deemed suitable, the recipient is brought to the operating room in preparation for the procedure. Our preference is to have both a pulmonary artery catheter placed for close hemodynamic monitoring, as well as a large bore bypass line placed in the right internal jugular vein in case of need for venovenous bypass.

The hepatectomy can be quite challenging depending on factors such as the degree of portal hypertension, presence of adhesions, and clinical stability of the recipient. Typically, it is started by a bilateral subcostal incision with a vertical midline incision (Figure 1). Previous incisions or anatomy (e.g. presence of ostomy) may dictate where the incision is made. Also, if a combined liver and kidney transplant is planned, the subcostal portion can be made lower on the abdominal wall to facilitate placement of the kidney. With the standard incision, the right side is extended laterally to at least to the mid-axillary line to allow for adequate exposure for both dissection and placement of clamps on the IVC. The upper midline extension is carried to the xiphoid process, and, if necessary, the xiphoid is removed for better exposure of the suprahepatic IVC. The falciform ligament is then taken down and the coronary ligament is dissected until the anterior border of the suprahepatic IVC is identified. Next the left triangular ligament is divided and the left lateral lobe is mobilized. The next step is to mobilize the gastro-hepatic ligament, which would expose the left side of the IVC and the caudate lobe. If there is a replaced left hepatic artery it is ligated at this time.

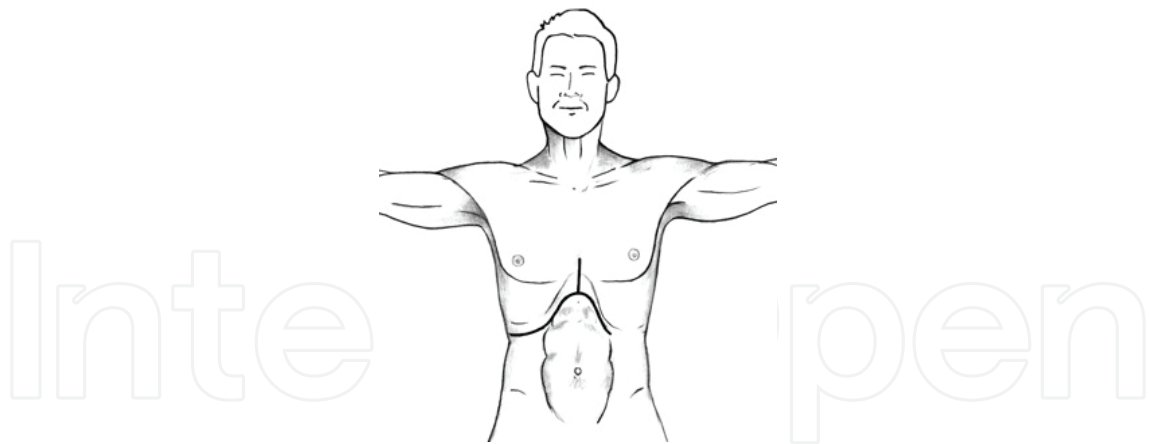


Fig. 1. Typical bilateral subcostal incision with upper midline extension

Dissection of the portal structures proceeds from the left or right side depending on the surgeon's preference. From the left, the gastro-hepatic ligament is divided anterior to the caudate lobe, and the lateral aspect of the portal vein is identified. Staying anterior to the PV, the proper hepatic artery is dissected out and transected. We do not routinely dissect out and divide the right and left hepatic artery individually high up in the hilum. However, some teams prefer to maintain length on the native artery if their preference is to use the bifurcation of the proper hepatic artery for reconstruction. Once the hepatic artery is divided, the only structure anterior to the PV is the common bile duct. This structure is taken down immediately distal to the insertion of the cystic duct. Finally, the only remaining structure in the hilum is the portal vein. At this time the PV is completely skeletonized from its bifurcation distally to near the first pancreatic branch proximally. One needs to ensure that the PV is completely mobilized circumferentially from the surrounding lymphatic and loose areolar tissue.

The next step is mobilization of the IVC. The initial step is to dissect out and obtain control of the infrahepatic IVC. Once the plane of the IVC is established, we continue to the left and mobilize the lateral aspect of the caudate lobe off of the IVC. This is carried in a cephalad direction until the lateral aspect of the suprahepatic IVC is identified immediately above the insertion of the left hepatic vein. When the left side of the IVC is exposed, attention is then directed toward mobilizing the right lobe of the liver. The right triangular and hepatorenal ligaments are taken down and the right lobe is mobilized fully until the suprahepatic IVC is exposed immediately superior to the insertion of right hepatic vein.

At this point, the dissection differs between the standard and caval sparing technique.

## 2.1 Bicaval hepatectomy

For the standard bicaval technique, both the suprahepatic and infrahepatic IVC are circumferentially dissected out. Generally, the right adrenal vein has to be taken down to provide for adequate infrahepatic exposure. Care is taken near the right renal vein, adrenal gland, and right hepatic vein. Gently, the surgeon's index finger is passed behind the suprahepatic IVC and the soft tissue posterior to the IVC is ensnared and retracted forward (Figure 2). This tissue is taken down either with electrocautery or tied off with silk tie if there is any concern for bleeding or retroperitoneal varices.

Once the intrahepatic cava is fully mobilized a test clamp is performed. For this, the surgeon manually compresses both the infrahepatic IVC and the PV, then checks with the anesthesia team to ensure patient stability. If the patient remains hemodynamically stable, then we proceed with the hepatectomy. Initially a clamp is placed on the PV proximally and the distal aspect of the PV is tied off with a silk tie at the level of its bifurcation and transected. Subsequently a vascular clamp is placed on the infrahepatic IVC. This clamp can be either placed in a horizontal or vertical position. Finally, a clamp is placed on the suprahepatic IVC. The recipient's IVC is transected between the clamps and the liver is passed off the field.

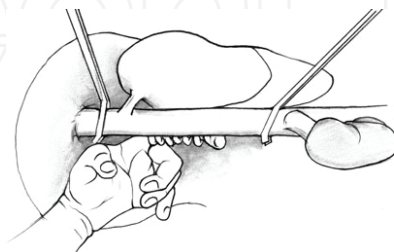


Fig. 2. Hepatectomy with mobilization of retrohepatic vena cava

While this technique avoids the extra time for going on venovenous bypass, two concerns arise. First, is that the recipient may initially be hemodynamically stable, but may become unstable during the anhepatic phase. Second, if there is concern for lack of exposure, such as edematous viscera, small recipient, or a large donor liver, proceeding in the anhepatic phase without bypass can lead to significantly worsening bowel edema and a more technically challenging implantation. For these reasons, we have a very low threshold for going on bypass. In general, however, venovenous bypass is used selectively nowadays depending on the recipient status and the bias of the surgical team (Reddy, 2005).

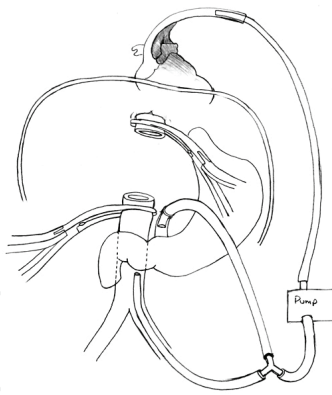


Fig. 3. Venovenous Scheme: Systemic and mesenteric flow travels out of patient through centrifugal pump, and is reintroduced into systemic circulation through either the axillary or jugular vein

To start systemic bypass, a femoral cannula is placed by cut-down or percutaneous technique in either groin, and the infrarenal cava is cannulated. Systemic return is through a cannula placed through cutdown in the axillary vein, or (as we prefer) through a percutaneously placed jugular cannula. Systemic bypass is then initiated while leaving the portal cannula of the circuit still clamped. Subsequently, the PV is clamped and taken down, and the PV cannula is then inserted and full venovenous bypass initiated (Figure 3). In certain situations, only the systemic and/or portal bypass portion of the venovenous circuit

is utilized. Once on venovenous bypass, the infrahepatic and suprahepatic IVC are clamped and the liver is explanted. Rarely, as with a very large liver (e.g. polycystic liver), the hepatectomy is facilitated by removing the left lateral segment of the liver first.

## 2.2 Caval sparing hepatectomy

For the caval sparing technique, the caudate and right lobes are mobilized as before. However, the right adrenal vein is left alone, and no dissection is carried out behind the cava. Instead, starting from the region of the infrahepatic cava, the liver is mobilized off the anterior surface of the IVC. Dissection proceeds either from left to right (or visa versa) depending on the anatomy. All short hepatic veins are dissected out and either tied with silk ties or oversewn with 5-0 prolene for larger branches. Larger retrohepatic veins may also be stapled.

While the PV can be left intact during most of the piggyback dissection, many surgeons prefer to create a temporary end-to-side portacaval shunt to minimize mesenteric congestion and improve hemodynamic stability (Cherqui et al., 1994; Llado´ & Figueras, 2004). Other reasons to use a shunt include decreased bleeding, improved renal function, reduced liver congestion, and improved exposure and mobility of the liver. Shunting is more important when the patient has not developed chronic mesenteric collateralization (e.g. fulminant hepatitis). When partial clamping of the cava is used in conjunction with a shunt, both systemic and mesenteric flow are preserved without the need for venovenous bypass. If no portal decompression is used, the portal vein is left intact as long as possible prior to removing the liver in order to prevent splanchnic congestion (Lerut, 2003).

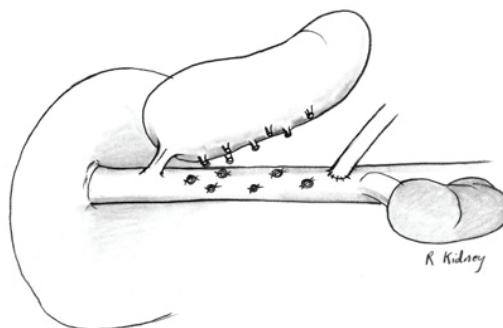


Fig. 4. Caval preservation: Liver is mobilized off retrohepatic cava in a caudal to cephalad direction. Shown above right renal vein is a temporary end-to-side portal caval shunt

The dissection is carried cephalad anterior to the IVC until the IVC ligament is identified, dissected out, and transected. We prefer to use an endovascular stapler on "thick" caval ligaments however one can clamp and cut the IVC ligament, and subsequently suture the remnant stump (large caudate lobes may increase the difficulty). Finally, the hepatic veins are isolated and completely dissected out. Many times, it helps to divide the right hepatic vein which facilitates exposure of the common middle and left trunk.

If a portacaval shunt has not been created, at this time the PV is taken down, and depending on the reconstruction technique, the hepatic veins are either taken with a stapler or a Satinsky clamp is placed on the caval side of the hepatic veins, and the liver is removed. If the hepatic vein cuffs are to be used as part of the recipient anastomosis, the veins are transected intrahepatically to preserve length. The liver is now removed.



Caval sparing techniques are used in large part to maintain systemic (and portal flow, if a temporary portal caval shunt is used) without requiring venovenous bypass. Thus, the dissection is carried out without disturbing systemic flow of the cava. Sometimes, however, either a partially occluding clamp, or complete caval clamping is necessary if troublesome bleeding ensues. (Belghiti et al., 2001). Also, if necessary, venovenous bypass can be used, although proponents of caval preservation usually are striving to avoid systemic bypass.

During the anhepatic phase, once the liver is explanted, the operative field is meticulously examined to ensure adequate hemostasis. This is the best opportunity to visualize the retrohepatic space before the new liver is implanted.

### **3. Anhepatic phase**

The anhepatic phase consists of the IVC and PV reconstruction.

The initial anastomosis in the implantation of the donor liver is the IVC reconstruction. There are several different techniques which we will discuss here. These include the standard bicaval method, the piggyback technique, the lateral cavocavostomy and a modification of the cavocavostomy technique.

#### **3.1 Bicaval technique**

For the standard bicaval reconstruction, both the suprahepatic and infrahepatic IVC of the recipient are already fully clamped. Depending on the patient's clinical status and the surgeon's preference, the patient may already be on venovenous bypass. The donor liver is brought onto the operative field. Some teams prefer to maintain a slow, continuous antegrade flush through the portal vein to keep the liver cold. For the suprahepatic IVC, 3-0 prolene suture is used. Initially the corner stitches are placed on both the donor and recipient suprahepatic IVC and the liver is gently lowered into the surgical field. Both ends are tied and the posterior wall of the IVC is anastomosed first from inside the lumen of both veins. An imbrication technique is used to prevent posterior leaks, and to exclude potentially thrombogenic adventitial surfaces. Subsequently the anterior wall is sutured.

After the suprahepatic IVC anastomosis is complete, attention is turned to the infrahepatic IVC. The anastomosis is created with 4-0 prolene in similar fashion to the suprahepatic IVC. Prior to completing the lower caval anastomoses, the liver needs to be flushed with approximately 1 liter of cold crystalloid solution to remove by products of metabolism, air, and preservation solution. This is especially true if using University of Wisconsin solution which is high in potassium and can cause arrhythmias post-reperfusion. The crystalloid is flushed through the donor's PV and the effluent is drained via the infrahepatic IVC.

When the drainage is complete, the lower IVC anastomosis is completed. Sometimes the lower caval anastomosis is left untied to allow egress of blood if the surgical team prefers to also vent the liver with blood prior to final reperfusion. (Figure 5).

#### **3.2 Classic piggyback technique**

In the case of the piggyback technique, there is no infrahepatic IVC reconstruction. In this case the orifice of the right hepatic vein can be tied or stapled off, and the common opening

of the middle and left hepatic veins of the recipient are sewn to the donor's suprahepatic IVC. However, joining all three hepatic veins and using a common orifice may be associated with less incidence of venous outflow obstruction (Parrilla et al., 1999; Tayar et al, 2011). Usually, it is technically difficult to place a clamp that will include all three veins during the hepatectomy phase. Therefore, in most instances, the orifice of the right hepatic vein and the common orifice of the left and middle hepatic veins are initially clamped separately. Once the liver is removed, a second clamp is placed to include all three veins. The initial clamps are removed and the opening of all three veins are joined together. (Figure 6). Another technique described involves making a horizontal enlargement of the middle/left trunk to decrease outflow obstruction (Lerut et al, 1997).

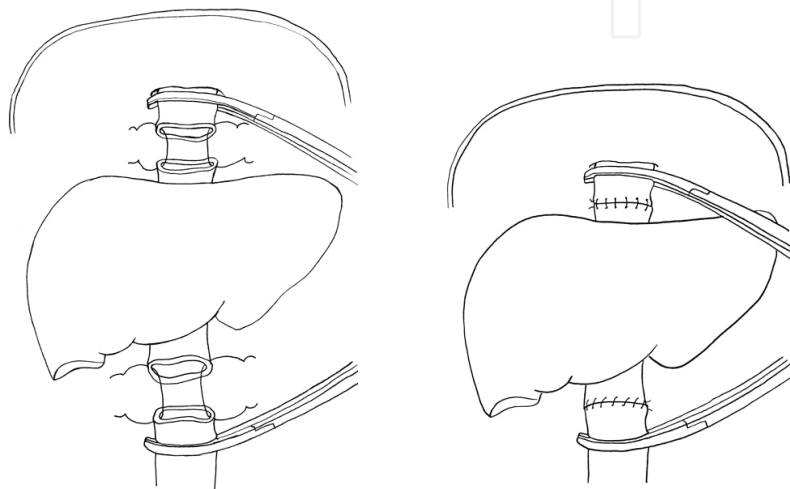


Fig. 5. Bicaaval reconstruction: Suprahepatic anastomosis precedes infrahepatic anastomosis

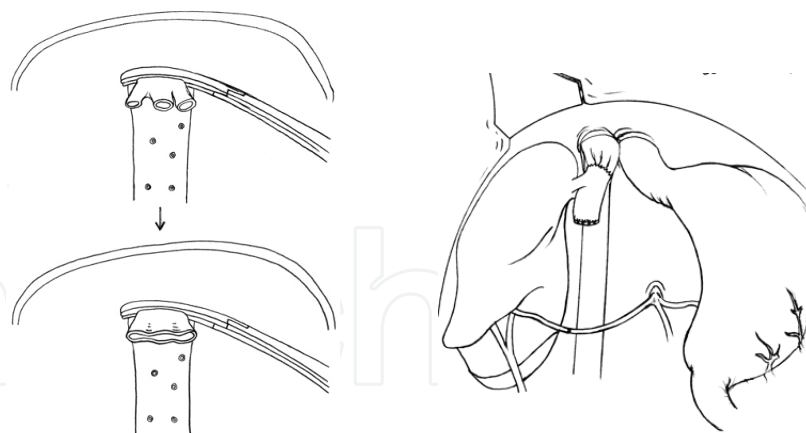


Fig. 6. Classic piggyback reconstruction: Recipient hepatic veins are joined together (all three in this picture), and anastomosed to donor cava

The donor liver is brought onto the operative field. Using 3-0 prolene, the donor's suprahepatic cava is anastomosed to the common orifice of all three hepatic veins of the recipient. Similar to the bicaaval technique the posterior wall is created first. Once the suprahepatic anastomoses is complete, one liter of cold crystalloid solution is flushed through the donor's PV and the effluent is drained through the donor infrahepatic cava. Once the flush is complete, the orifice of the donor infrahepatic IVC is stapled off with a TA



stapler, or double tied off with 0 silk ties. Once again, some teams leave the infrahepatic side open for further blood venting prior to reperfusion.

### 3.3 Piggyback modifications

As surgeons gained more experience with the original piggyback concept, other variations of the caval reconstruction evolved ((Belghiti et al., 1992; Bismuth et al., 1992; Cherqui et al., 1994, Lerut et al, 1997). These were developed to allow preservation of caval flow, and to decrease venous outflow complications. Configurations include lateral side-to-side cavocavostomy and end-to-side cavocavostomy (Figure 7).

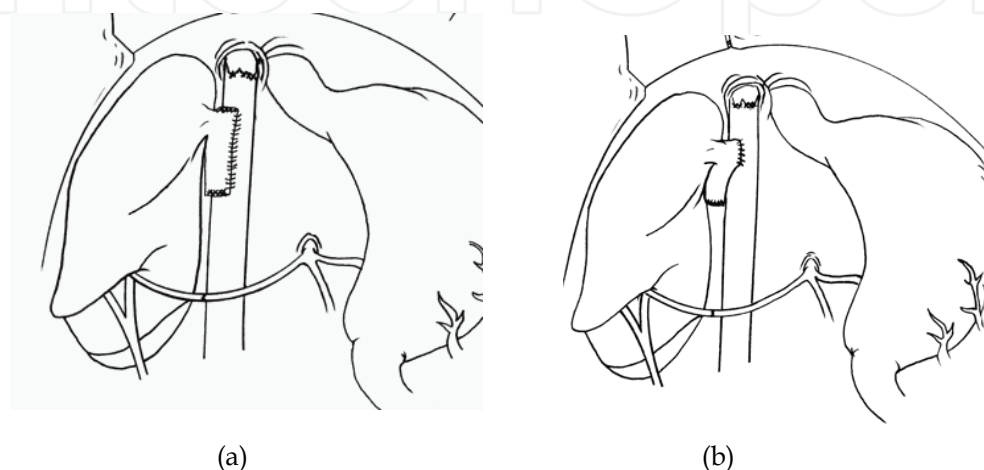


Fig. 7. Piggyback modifications: (a) side-to-side and (b) end-to-side. The recipient hepatic veins have been stapled closed

The hepatectomy for these techniques is similar to that described above for the classic piggyback technique. A portacaval shunt can be created depending on the operating team's preference and the patient's clinical status. To perform the side-to-side anastomosis, the recipient hepatic veins are transected and the donor cava's suprahepatic and infrahepatic openings are eventually closed. A partially occluding clamp is placed on the recipient's cava, and a longitudinal cavotomy is created (approximately 6 cm). A corresponding cavotomy is made on the donor cava, and a side-to-side anastomosis is carried out between the recipient and donor (Figure 8). This anastomosis is usually done from the left side of the table using an intraluminal technique. Depending on the placement of the stay sutures, a triangulated anastomosis can also be fashioned (Dasgupta, 2006).

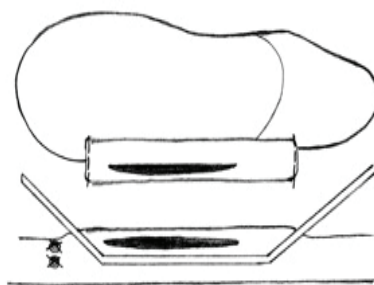


Fig. 8. Lateral-to-lateral cavocavostomy. The recipient hepatic vein orifices have been closed. A partially occluding clamp is placed on recipient side to preserve caval flow

The liver can be flushed with either cold crystalloid solution through the PV prior to completing the PV anastomosis, or blood can be introduced through the completed PV anastomosis and allowed to vent through the open end of the donor cava, which is subsequently stapled closed.

One issue to keep in mind with this technique, is that even though the recipient IVC is not fully clamped, in order to create a longitudinal cavotomy, one needs to partially clamp the IVC and the patient's hemodynamic status needs to be carefully monitored. Advantages of the cavostomy technique include a widely patent anastomosis which minimizes outflow obstruction. Furthermore, this technique allows for better exposure and easier anastomoses in cases with difficult exposure, such as a large donor liver. The mobility and positioning of the liver may even facilitate the biliary anastomosis (Sonnenday et al., 2008).

Other variations of the piggyback technique include the end-to-side configuration (Figure 7a) which may involve enlarging the donor opening with a longitudinal cavotomy through the suprahepatic portion of the donor cava. Also, the recipient hepatic vein orifices may be included, for example, by creating a longitudinal cavotomy through the common trunk of the middle/left veins (Figure 9) (Klintmalm & Busuttil, 2005).

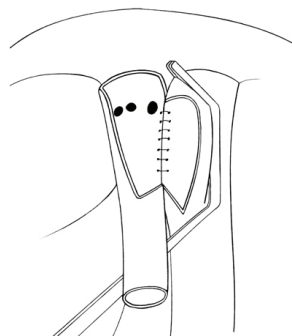


Fig. 9. Another variation utilizing partial caval clamping

### 3.4 Modification of the cavocavostomy

A final variant of the caval anastomoses is to combine the cavocavostomy incision with the orifice of the hepatic veins on both the donor and recipient. This has been referred to as a suprahepatic cavoplasty (Wu et al., 2001) or a triangulating cavocavostomy (Dasgupta et al., 2006). It is similar to the variant of the piggyback technique described above (Figure 9) but creates a much larger cavotomy. Also, this method requires full clamping of the IVC and, therefore, the hemodynamic changes are similar to the standard bicaval technique and the recipient may require the use of complete venovenous bypass.

However, unlike the bicaval technique there is no need for retroperitoneal dissection of the IVC, nor is there a need for piggyback dissection.

For this method, the recipient suprahepatic and infrahepatic IVC are fully dissected out. If the patient tolerates a test clamp, we will proceed with the hepatectomy, otherwise venovenous bypass is initiated. The PV is clamped and transected at its bifurcation. The suprahepatic and infrahepatic IVC are also clamped. Using Metzenbaum scissors, the short hepatics are sharply divided until the level of the hepatic veins. A small patch of the anterior IVC can also be resected along with short hepatics. Subsequently the hepatic veins are also transected intrahepatically, creating a large "triangular" opening along the length of the

intrahepatic IVC which also includes the orifice of the hepatic veins. The orifice of the short hepatic veins are either included in the segment of the anterior IVC that was removed, or for the most part can be excluded by the suture line.

Transected veins that will not become part of the anastomosis are suture repaired, and the three hepatic vein orifices are converted into one opening continuous with the cavotomy. Extraneous tissue on the remnant hepatic veins is trimmed in preparation for the anastomosis (Figure 10).

For the donor liver, a slit is created in the posterior aspect of the IVC starting from and incorporating the suprahepatic caval opening. This cavotomy is created to match the opening of the recipient IVC, but does not extend fully to the infrahepatic IVC of the donor (Figure 10). Using 3-0 prolene, the three corner sutures are placed. Care is taken to avoid compromising the hepatic vein orifices on the donor liver. Initially the right lateral wall is created, followed by the left side, and finally the superior aspect. Sometimes, it may be easier to perform the entire anastomosis from the left side by doing the right suture line intraluminally. Again, one liter of cold crystalloid solution is perfused through the donor PV and effluent is drained through the infrahepatic IVC. The infrahepatic donor cava is stapled closed (or left open for blood venting).

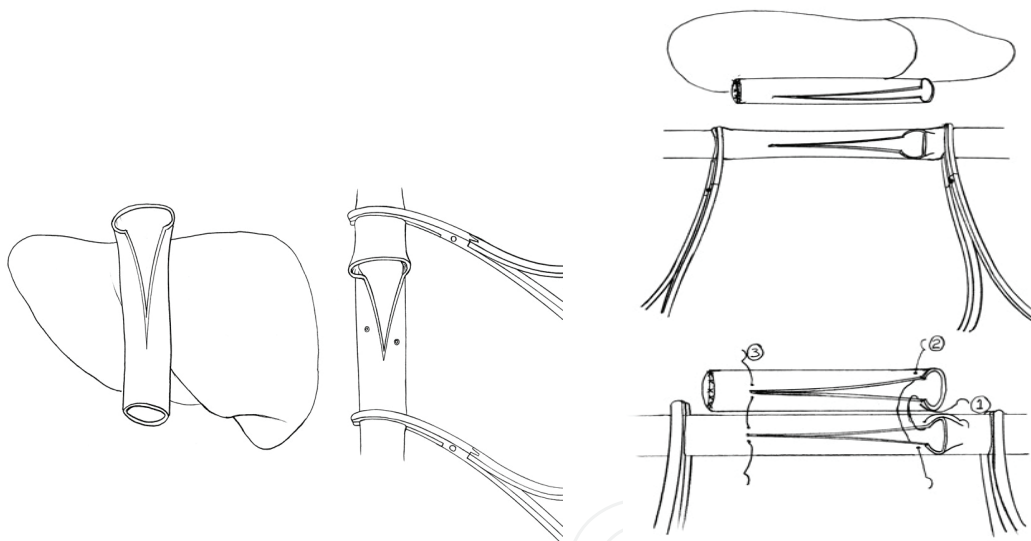


Fig. 10. “Modified” cavocavostomy (triangulated anastomosis). The recipient hepatic vein orifices are incorporated into the anastomosis. The cava is totally occluded. Three corner stitches are shown

Though this modification requires full IVC clamping with potential need for venovenous bypass, it is our preferred method for several reasons. First, it does create the largest possible outflow. Second, in cases with poor exposure, there is no posterior suprahepatic caval anastomosis, and there is better exposure during both the caval reconstruction and after reperfusion to allow examination of the suture line. Finally, since the short hepatic veins will be either removed with the patch of IVC or incorporated into the anastomoses, the hepatectomy phase is considerably shortened since one can simply “cut off” the anterior wall of the cava once the clamps are placed. There is no need to meticulously dissect the liver off the IVC. Furthermore, bleeding during this phase of the hepatectomy is minimized since there is full isolation of the IVC during mobilization of the liver off of the IVC.

The technique can be done expeditiously, and, thus, as experience is gained with the technique, it may be possible to forego systemic and/or portal bypass. In addition, size mismatch problems between donor and recipient are decreased (Wu et al., 2001).

A variant of this technique has been called the “infrahepatic” cavocavostomy. (Khanmoradi, et al., 2009) In this case, the donor cava is opened from the infrahepatic side and the suprahepatic side is closed. A side-to-side anastomosis is created. This technique has been touted as an alternative when either recipient or donor characteristics make using the suprahepatic cava hazardous. For example, if a transjugular shunt is present or if there is a significant size mismatch between donor and recipient. It has also been used as a rescue technique if there is outflow obstruction following a piggyback anastomosis. (Quintini et al., 2008).

To summarize, each of the relative pros/cons of the above techniques have been debated. Advocates for the classic bicaval technique state that most cases can still be done without the need for cava preservation unless, for example, the donor graft is relatively small, or if retroperitoneal inflammation precludes dissection (Klintmalm and Busuttill, 2005). Also, venous outflow complications may be lower with end-to-end anastomosis vs piggyback technique (Glanemann et al., 2002). Some teams have found that, in their hands, venovenous bypass may not even be necessary a majority of the time, even with the classic technique (Vieira de Melo et al., 2011). In cases of unfavorable anatomy, as with a large liver or caudate lobe, classic caval resection may be easier (Navarro et al., 1997).

Advocates for caval preservation state that greater hemodynamic stability, less bleeding, decreased warm ischemic time, improved renal flow, better visualization are advantages of caval preservation. Technical modifications have reduced venous outflow complications (Mehrabani et al., 2009). Also, venovenous bypass with its inherent problems (e.g. air embolism, nerve injury, wound infections) can often be avoided, and splanchnic congestion can be handled with temporary portal caval shunting (Belghiti et al., 1995; Llado' & Figueras, 2004). In many cases, portal shunting can also be avoided if the portal vein is maintained until the hepatectomy is finished (Lerut et al., 2003). With experience, cases originally thought too difficult can be performed with caval preservation (e.g. large polycystic livers, Budd-Chiari, retransplantation) (Belghiti et al., 2001).

Many comparisons have been studied, but it is difficult to achieve large numbers with prospective studies (Perkins, 2007; Kahn et al., 2006; Lai et al., 2011). Ideally, a surgeon can become familiar with all the techniques in order to adapt to different situations (Eghtesad et al., 2005).

### **3.5 Portal vein anastomosis**

Generally speaking, the PV reconstruction is usually the most straightforward of all the anastomoses. This is due to a lack of extra-hepatic PV anatomic variability (unlike the hepatic artery), and the fact that an end to end anastomoses is essentially the only feasible way of reconstructing the donor and recipient portal veins.

There are however two key points that need to be addressed. One is to ensure that there is no redundancy in the PV anastomoses as this can lead to kinking, poor flow, and increased risk of post-transplant PV thrombosis. The second point is the management of chronic PV thrombus in the recipient.

If the patient has been on venovenous bypass, at this time the PV cannula is removed and the PV clamp is replaced back on. Systemic venovenous bypass is continued. In cases where a portacaval shunt has been created, a vascular clamp is placed on the pancreas side, the caval aspect of the shunt stapled off, and subsequently the shunt is transected.

In order to avoid redundancy in the PV anastomoses, one must keep in mind that the distance between the donor and recipient PV is greatly exaggerated during the anhepatic phase. The rib cage is significantly retracted in a cephalad direction and the visceral contents of the abdomen, including the stomach and duodenum, are retracted down during the caval anastomoses.

Though this provides optimal exposure to the IVC and retroperitoneum, one must keep in mind that this does increase the space between the recipient and donor PV stumps. If this is not accounted for, once the retractors are removed, there could be a noticeable kinking and redundancy in the PV anastomoses. To avoid this complication, an attempt must be made to bring the two PV stumps as close to their natural position as possible. Loosening the rib cage retractors or placing folded laparotomy pads behind the dome of the liver are two ways of bringing the donor liver closer to its natural position. On the recipient side, relaxing the bowel retractors allows the foregut, including the duodenum to return to its normal position. We prefer to put a spoon clamp on the donor PV approximately one to one and a half inches proximal to its bifurcation. This helps us gauge both the length of the donor PV needed and also maintains its orientation. The vascular clamps on the donor and recipient PV are lined up to avoid twisting of the two veins. Any excess length on both the recipient and donor PV are trimmed off. The anastomoses is created with either 5-0 or 6-0 prolene. Again, similar to the IVC anastomoses, the back wall is anastomosed initially followed by the front wall (Figure 11). Near the completion of the PV anastomoses, the donor PV clamp is kept on, the recipient clamp is removed, and about 300-500ml of blood is flushed out to remove any potential clots that may have formed and also to flush out the stagnant blood from the viscera. The PV anastomoses is completed while leaving a “growth factor”. Essentially, the running prolene is not tied fully down, and an air knot which would be around one half the diameter of the PV is left to allow for the expansion of the anastomoses once blood flow is restored. This step is done to avoid narrowing at the suture line.

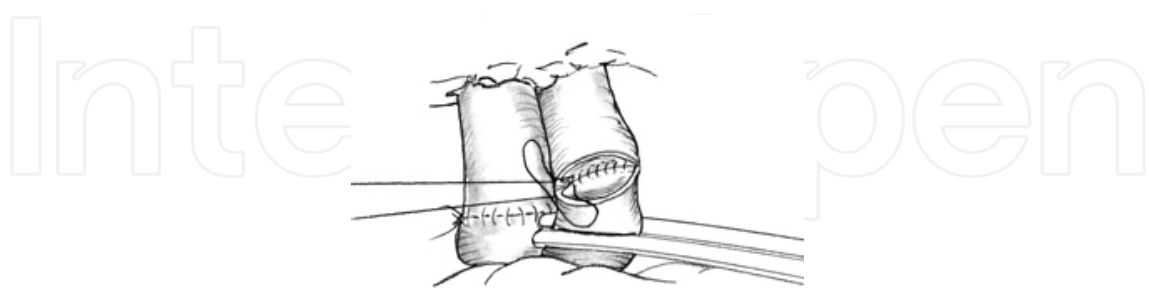


Fig. 11. Portal vein anastomosis. The posterior wall is completed intraluminally. The completed infrahepatic anastomosis is shown

The second potential problem with the PV anastomoses is the chronic PV thrombus that can be encountered in about 15-10% of liver transplant recipients (Yerdel et al., 2000). In the vast majority of cases, this clot is non-occlusive and a simple eversion thrombectomy re-establishes flow. (Dumortiera et al., 2002). This is performed by grasping the edges of the



recipient PV with non-crushing clamps, elevating the thrombus away from the wall of the PV using a dissector, and continuing circumferentially. Once a substantial portion of the clot is mobilized, a grasping instrument- such as ring forceps, can be used to forcefully extract the thrombus (Figure 12). The vascular clamp on the recipient PV will have to be periodically released to allow for full extraction of the thrombus as well as to check inflow. Once adequate thrombectomy has been performed the anastomoses can be completed as described above.

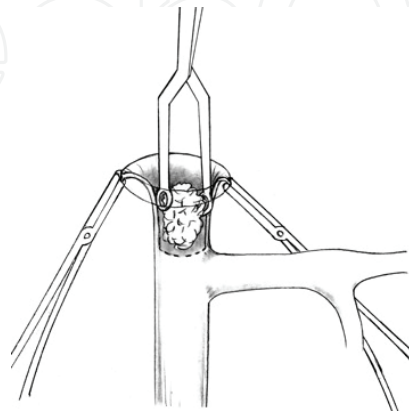


Fig. 12. Eversion thrombectomy of portal vein

If one fails to re-establish flow through the main recipient PV, several options exist. A venous jump graft to the proximal portal vein or the superior mesenteric vein may be constructed using donor iliac vein. This graft is passed behind the stomach and anterior to the pancreas. To perform this, the recipient SMV has to be patent. This structure is dissected out below the level of the transverse colon and proximal to the insertion of the middle colic vein into the SMV. (Nikitin et al., 2009) (Figure 13).

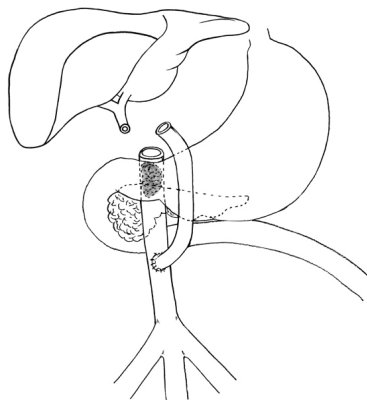


Fig. 13. Venous conduit: Donor iliac vein connects superior mesenteric vein to donor portal vein

In case there is no good target SMV, the inferior mesenteric vein can be used as a potential inflow. Other potential inflow sources include the splenic vein or a large collateral. Finally, if a conduit is not an option, a caval hemi-transposition can be performed. In this technique, the donor PV is anastomosed to the recipient infrahepatic IVC and subsequently the recipient IVC is stapled above the level of the PV anastomoses to divert all flow through the



transplanted liver. Unfortunately, outcomes with this method are inferior as may be expected (Yan et al., 2008; Selvaggi et al., 2007). Even more rarely, a conduit may be constructed using donor vessels to supply arterial blood to the portal vein (arterialization).

#### **4. Reperfusion phase**

After the IVC and PV anastomoses are complete, the next step is reperfusion of the donor liver. Prior to re-establishing flow, one must closely communicate with the anesthesia team to ensure that the patient is ready for reperfusion. During the initial portion of the reperfusion phase, the right heart is exposed to a large volume of cold preservation solution, which may also be high in potassium, and also contains elevated levels of cytokines secondary to the ischemia of the donor organ. This can potentially lead to right heart failure of arrhythmias. Therefore, ensuring that the anesthesia team is ready for reperfusion is of paramount importance.

The sequence of unclamping and reperfusion of the liver depends on the method of IVC reconstruction. In the standard bicaval method or the “triangulation” technique where both the suprahepatic and infrahepatic portions are clamped, initially the suprahepatic IVC clamp is removed and the caval suture lines are closely examined for hemostasis. Second the infrahepatic caval clamp is removed. Finally the PV clamp is removed slowly. If the surgeon’s preference is to vent the first several hundred cc’s of blood, this is done through the untied infrahepatic caval anastomosis, which is subsequently tied. Once reperfusion is complete, all suture lines and the operative field is examined for full hemostasis prior to proceeding. If the patient had been on venovenous bypass, at this time the femoral vein is decannulated.

In the piggyback and cavocavostomy techniques, there is only one caval clamp. Once this clamp is removed and hemostasis is achieved, the PV clamp is removed. If blood is to be vented, this is achieved through an opening in the donor cava which is subsequently closed. As above, reperfusion syndrome is diminished by slowly reestablishing portal flow.

After reperfusion, the liver is assessed. The liver should attain a normal appearance. flow is poor if the liver is soft and dusky; outflow is poor if the liver is abnormally tense and swollen. Some surgeons use a flow meter to assess the portal and arterial flow.

#### **5. Hepatic artery reconstruction**

Usually, hepatic arterial reconstruction follows reperfusion. The order of portal vs arterial reperfusion does not seem to matter; however, sometimes it may be necessary to complete the artery first and reestablish flow to the liver to decrease warm ischemic time (e.g. unexpected difficulty dealing with a portal vein thrombosis) (Busuttil & Klintmalm, 2005).

Unlike the PV, the hepatic artery (HA) anastomoses can be performed in a variety of different ways. This is due in part to variations in the donor and recipient anatomy, the need to optimize inflow and the surgeon’s preference.

For a donor HA with standard anatomy and no replaced or accessory branches, several options exist for reconstruction. The celiac axis with or without a patch of aorta can be used. Alternatively, the celiac axis can be shortened near the take-off of the splenic artery.

Subsequently, the celiac axis and splenic artery orifice are joined to create a fishmouth patch. The stump of the left gastric artery is tied off.

On the recipient side, if the HA had been dissected out above the bifurcation of the left and right hepatic arteries, a small vascular clamp or bulldog can be placed on the proper hepatic artery distal to the gastroduodenal artery (GDA) and the right and left branches of the HA are joined to form a common orifice. A second option is to dissect the proper HA, identify and dissect out the GDA and continue by mobilizing the common HA proximal to the GDA. A vascular clamp is then placed on the common HA, the distal aspect of the GDA is tied off, and a patch is created between the orifice of the GDA and proper HA at this time.

While any combination of the above mentioned options can be used, the main concern with the HA reconstruction is that any excessive length can lead to twisting and looping once the retractors are removed and the liver returns to its native position. This can lead to an increased incidence of HA thrombosis. Therefore, in order to avoid redundancy, our preference is to resect the excess celiac trunk and use the celiac-splenic patch on the donor, which is then anastomosed to the recipient proper HA - GDA patch (Figure 14).

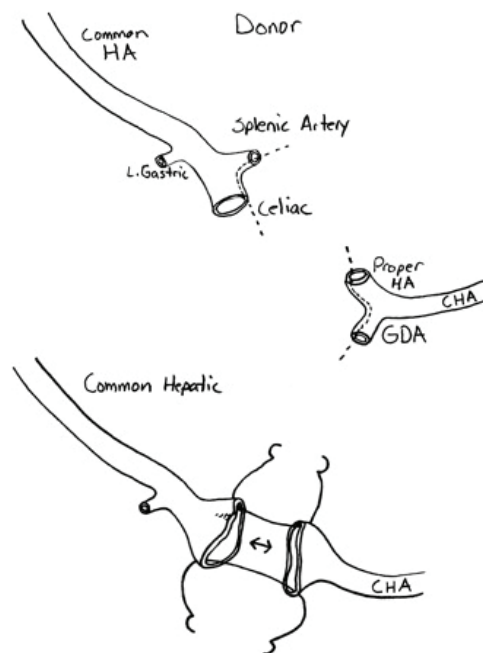


Fig. 14. Typical arterial reconstruction with “common” anatomy. Branch patches are created on both the donor and recipient ends

The two most common variations encountered in the HA anastomoses are replaced ( or accessory) right and left hepatic arteries. In case of a replaced or accessory left HA, the reconstruction is simple. The left HA is kept in continuity with the left gastric artery. On the backtable, the main trunk of the left gastric artery is ligated distal to the take-off of the replaced left HA. There are several small branches coming off the left HA which are also dissected out and tied off. If the splenic-celiac axis patch can be created on the donor without compromising the take-off of the left gastric artery, a standard reconstruction is performed similar to previously described. The second option would be to use the celiac trunk on the donor side and tie off the stump of the splenic artery (Figure 15a).

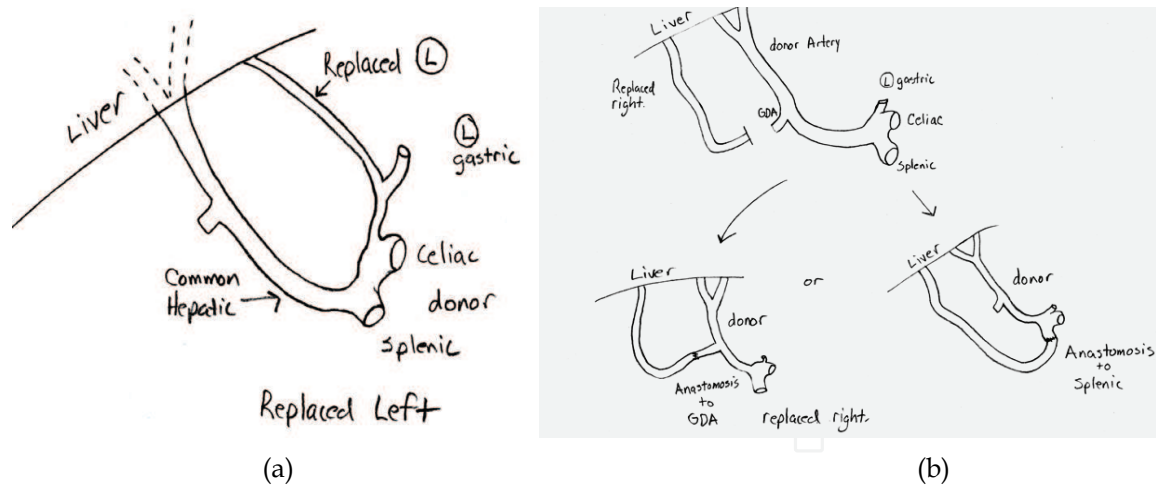


Fig. 15. Hepatic reconstruction examples with (a) replaced left on donor, and (b) replaced right on donor

For a replaced right HA, the reconstruction is technically more challenging. This structure is usually procured with a segment of the superior mesenteric artery (SMA). While several methods have been described, a common technique used is to resect the excess right HA and SMA trunk and subsequently anastomose the lumen directly to the orifice of the donor splenic artery or GDA. Our preference is to use the GDA to minimize the chance of a kink or twist during the reconstruction on the backtable. The replaced right HA orifice is spatulated and the orifice of the GDA is extended onto the common hepatic artery to create for a wider anastomoses and better outflow (Figure 15b).

If variations in recipient anatomy result in inadequate inflow from the common hepatic artery, another inflow source can be used. For example, if the celiac is inadequate (as in arcuate ligament syndrome), the gastroduodenal artery may be dominant. Likewise, if a replaced right is dominant, it may be more appropriate as the recipient vessel. If no vessel is adequate, an aorta to donor artery conduit is created using donor iliac artery. Usually, the infrarenal aorta is chosen as the recipient side, although sometimes the supraceliac aorta is chosen as the proximal side. Similar to a portal venous conduit, it is tunneled retrocolic between the stomach and the pancreas. The tunnel location may vary depending on the anatomy. The aortic side is created with 5-0 prolene and the donor side with 6-0 prolene (Figure 16).

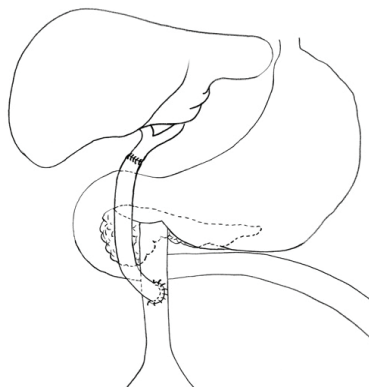


Fig. 16. Arterial conduit: Donor iliac artery connects infrarenal aorta to donor hepatic artery

While the incidence of HA thrombosis is low, both arterial reconstruction of multiple vessels and increased time to arterial reperfusion are risk factors for this complication. (Warner et al., 2011; Oh et al., 2001; Pastacaldi et al., 2001). Therefore, both technique and time are of essence.

## 6. Biliary anastomosis

Once the liver is reperfused, biliary reconstruction is initiated. An end-to-end anastomosis (choledochocholedochostomy) is the most commonly used configuration. Otherwise, a Roux-en-Y is usually chosen as the second choice. Indications for a Roux include technical difficulty apposing the two duct ends (e.g. after removing a large polycystic recipient liver), size discrepancy, and poor condition or blood supply of recipient duct (e.g. during retransplantation).

Another indication for a Roux is a diseased recipient duct. This can be related to choledocholithiasis, biliary atresia, secondary biliary cirrhosis, or primary sclerosing cholangitis. Recently, the tradition of using a Roux for a disease such as primary sclerosing cholangitis has been readdressed, and some authors have reported the use of duct-to-duct anastomosis when there is no evidence of extra-hepatic stricturing involving the distal duct and/or the duct appears visually healthy (Distante et al., 1996; Heffron et al., 2003). The use of choledochoduodenostomy has also been reported. Also, duct to duct anastomosis has been used during retransplantation (Sibulesky et al., 2011)

Whatever technique is chosen, the goal is to achieve a tension-free anastomosis between two well vascularized structures. To start the end-to-end anastomosis, it is helpful to elevate the liver with several packs placed behind the right lobe. The donor and recipient ends are trimmed to achieve healthy, bleeding surfaces. Bleeders are controlled with suture ligation. Cautery is avoided. If the donor side contains the lumen of the cystic duct, a small septotomy is made between the cystic and common hepatic duct to create a common orifice. If the cystic duct opening is not in continuity with the common duct, it is marsupialized to avoid creating a fluid-filled "sac" that may eventually contort the main duct. The anastomosis is accomplished with 5-0 or 6-0 absorbable, monofilament (PDS) creating the posterior wall first. Although many surgeons interrupt the anastomosis, we run the suture line. If size discrepancies exist, one end may need to be spatulated or partially closed to allow anastomosis. Most of the time, this does not seem necessary.

Traditionally, a T-tube is used. It's purpose is to provide access to the biliary system, to allow monitoring of the quantity and quality of bile, and to "splint" the anastomosis. The current trend, however, is to avoid the use of T-tubes. This is due to the recognition that T-tubes may be associated with biliary leaks as well as other technical problems (Riediger et al., 2010; Sotropoulos et al., 2009).

A Roux-en-Y is constructed in a standard fashion, usually dividing the small bowel 15-20 cm distal to the ligament of Treitz, and making a 40cm defunctionalized limb. The bowel anastomosis can be sewn or stapled. The end of the limb is reinforced with a seromuscular imbricating stitch. The limb is brought to the porta through a retro- or antecolic approach. If the colon is present, and the patient has inflammatory bowel disease, a retrocolic position will make subsequent colectomy easier. The donor duct is anastomosed to the

Roux limb with absorbable monofilament. Some surgeons use an internal or external stent (Figure 17).

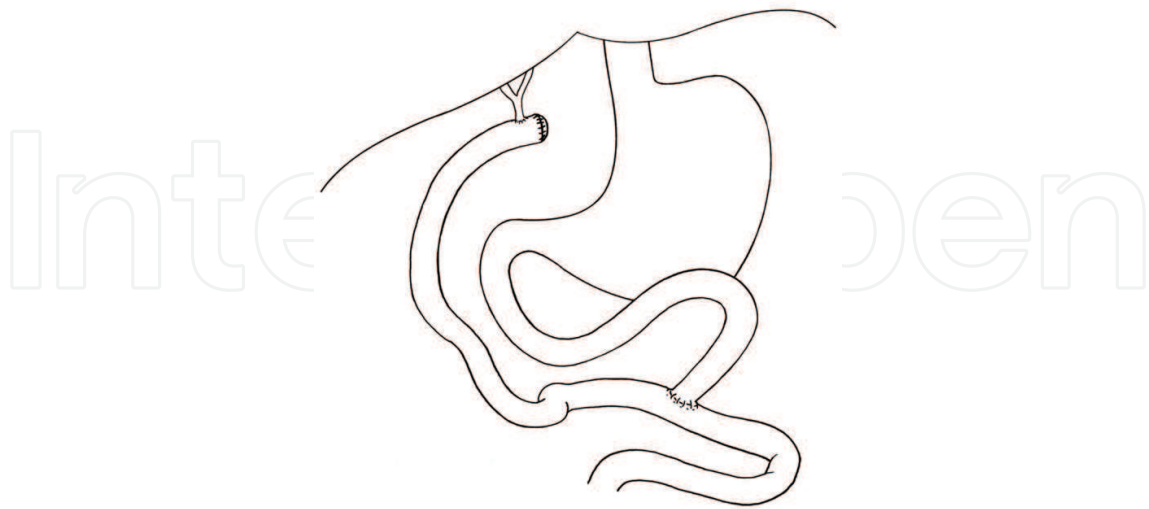


Fig. 17. Roux-en-y biliary anastomosis

## 7. Closure

Once the biliary reconstruction is complete, systematic inspection of the field is carried out. Mechanical hemostasis is achieved. Non-mechanical bleeding is addressed by the anesthesia team. Generally, two drains are left, one behind the right lobe towards the suprahepatic cava, and one near the biliary anastomosis in an infrahepatic position. The midline incision is closed in a single layer, the bilateral subcostal incisions in two layers.

## 8. References

- Belghiti, J, Fekete F, Gayet B, Panis Y, & Sauvanet A,. (1992) A New technique of Side to Side Caval Anastomoses During Orthotopic Hepatic Transplantation Without Caval Occlusion. *Surg Gynecol Obstet*, Vol 75, No.3 ( Sep 1992) pp. 75:270-2.
- Belghiti J, Noun R, & Sauvanet A. (1995) Temporary Portocaval Anastomosis with Preservation of Caval Flow During Orthotopic Liver Transplantation. *Am J Surg*, Vol 169, No 2 (1995), pp. 277-279, ISSN 0002-9610
- Belghiti J, Durand F, Ettore G.M., Farges O, Jerius J, Sauvanet A, & Sommacale D,. (2001) Feasibility and Limits of Caval-Flow Preservation During Liver Transplantation, *Liver Transplantation*, Vol 7, No. 11, (November 2001), pp. 983-987, Online ISSN 1527-6473
- Bismuth H, Castaing D, Shellock DJ. (1992) Liver Transplantation by “Face to Face” Venacavaplasty, *Surgery*, Vol 111, (1992) pp.151-5, ISSN 0039-6060
- Busuttil, R., & Klintmalm, G, (2005) *The Recipient Hepatectomy and Grafting*, In: *Transplantation of the Liver*, Busuttil and Klintmalm, (Editors), pp. 575-588, Elsevier Saunders, ISBN 0-7216-01118-9, Philadelphia, PA, USA
- Cherqui, D, Dhumeaux, N, Duvoux, D, Fagniez, PL, Julien, M, Lauzet, JV, & Rotman, C,. (1994) Orthotopic Liver Transplantation with Preservation of the Caval and



- Portal Flows: Technique and Results in 2 Cases. *Transplantation*, Vol 58, No. 7 (Oct 1994), pp.793-796, ISSN:0041-1333
- Dasgupta, D, Sharpe, J, Prasad KR, Asthana S, Toogood GJ, Pollard, SG, & Lodge, JP. (2006). Triangular and Self-triangulating Cavocavostomy for Orthotopic Liver Transplantation Without Posterior Suture Lines: a Modified Surgical Technique. *Transpl Int.*, Vol 19, No. 2 (Feb 2006), pp. 117-21, ISSN 0934-0874
- Distante V, Farouk M, Kurzawinski TR, Ahmed SW, Burroughs AK, Davidson BR, & Rolles K. (1996) Duct-to-Duct Biliary Reconstruction Following Liver Transplantation for Primary Sclerosing Cholangitis. *Transpl Int*, Vol 9, No. 2 (1996), pp. 126-30, ISSN 0934-0874
- Dumortiera, J, Czyglika, B, Poncet, G, Blanchet M-C, Boucaud, C, Henry, L, & Boillot. Eversion Thrombectomy for Portal Vein Thrombosis During Liver Transplantation. (2002). *American Journal of Transplantation*, Vol 2, No. 10(Nov 2002), pp. 934-938, ISSN 1600-6135
- Eghtesad, B, Fung, J & Kadry, Z. (2005) Technical Considerations in Liver Transplantation: What a Hepatologist Needs to Know (and Every Surgeon Should Practice), *Liver Transplantation*, Vol 11, No 8 (August 2005),pp. 861-871, online ISSN 1572-6473
- Glanemann, M, Settmacher, U, Langrehr, JM, Stange, B, Haase, R, Nuessler, NC, Lopez-Hanninen, E, Podrabsky, P, Bechstein, WO, & Neuhaus, P. (2002). Results of end-to-end Cavocavostomy During Adult Liver Transplantation. *World J Surg*, Vol 26, No. 3 (Mar 2002), pp.342-7, ISSN 0364-2313
- Heffron, T, Smallwood, G, Ramcharan, T, Davis, L, Connor, K, Martinez, E, & Stiebeer, (2003). Duct-to-Duct Biliary Anastomosis for Patients with Sclerosing Cholangitis Undergoing Liver Transplantation. *Transplantation Proceedings*, Vol 35, No.8 (Dec 2003), pp. 3006-7, ISSN 0041-1345
- Khan S, Silva MA, Tan YM, John A, Gunson B, Buckels JA, Mayer D, Bramhall SR, & Mirza DF (2006). Conventional versus piggyback technique of caval implantation: without extra-corporeal venovenous bypass. A comparative study. *Transpl Int*, Vol, 19, No. 10 (2006), pp.795-801, ISSN 0934-0874, online ISSN 1432-2277
- Khanmoradi K, Defaria W, Nishida S, Levi, D, Kato, T, Moon J, Selvaggi, G & Tzakis, A. (2009). Infrahepatic Vena Cavocavostomy, a Modification of the Piggyback Technique for Liver Transplantation. *Am Surgeon*, Vol 75, No. 5 (2009), pp. 421-425, ISSN 0003-1348, online ISSN 1555-9823
- Lai, Q, Nudo, F, Molinaro, A, Mennini, G, Spoletini, G, Melandro, F, Guglielmo, N, Parlati, L, Mordenti, M, Corradini, S, Berloco, P, & Rossi, M. (2011). Does Caval Reconstruction Technique Affect Early Graft Function after Liver Transplantation? A Preliminary Analysis. *Transplantation Proceedings*, Vol 43, No. 4 (2011), pp.1103-1106, ISSN 0041-1345
- Lerut, J, Molle, G, Donataccio, M, De Kock, M, Ciccarelli, O, Laterre, PF, Van Leeuw, V, Bourlier, P, Ville de Goyet, J, Reding, R, Gibbs, P, & Otte, JB. (1997) Cavocaval Liver Transplantation Without Venovenous Bypass and Without Temporary Portocaval Shunting: The Ideal Technique for Adult Liver Grafting? *Transpl Int*, Vol 10, No. 3 (1997), pp.171-179 ISSN 0934-0874




- Lerut, J, Ciccarelli, O, Roggen, F, Laterre P.F., Danse, E, Goffette, P, Aunac, S, Carlier, M, De Kock M, Van Obbergh, L, Veyckemans, F, Guerrieri, C, Reding, R, & Otte, J.B. (2003). Cavocaval Adult Liver Transplantation and Retransplantation Without Venovenous Bypass and Without Portocaval Shunting: a Prospective Feasibility Study in Adult Liver transplantation. *Transplantation*, Vol 25, No. 10 (May 2003), pp.1740-5 ISSN 0041-1337
- Llado', L., & Figueras, J. (2004) Techniques of Orthotopic Liver Ttransplantation. *HPB*, Vol. 6, Number 2 (2004) pp. 69-75, ISSN 1477-2574
- Mehrabi, A, Zhoobin, A.M., Hamidreza, F, Kashfi, A, Hillebrand, N, Möller, S.A., Encke, J, Bëchler, M.W., & Schmidt, J. (2009). A Single-Center Experience of 500 Liver Transplants Using the Modified Piggyback Technique by Belghiti. *Liver Transplantation*, Vol 15, No. 5 (2009), pp.466-474, online ISSN 1527-6473
- Navarro, F., Moine, Marie-Christine Le, Fabre, Jean-Michel, Belghiti, J, Cherqui D., Adam R., Pruvot, F, Letoublon, C, & Domergue J Specific Vascular Complications of Orthotopic Liver Transplantation with Preservation of the Retrohepatic Vena Cava: Review of 1361 Cases. *Transplantation*, Vol 68 No.5 (Sept 15 1999), pp.646-650 ISSN 0041-1337
- Nikitin, D, Jennings, L, Khan, T, Vasani, S, Ruiz, R, Sanchez, E, Chinnakotla, S, Levy, M, Goldstein, R.M., & Klintmalm. (2009). Twenty Years' Follow-Up of Portal Vein Conduits in Liver Transplantation. *Liver Transplantation*, Vol. 15, No. 4 (2009), pp.400-406, online ISSN 1527-6473
- Oh CK, Pelletier SJ, Sawyer RG, Dacus AR, McCullough CS, Pruett TL, & Sanfey HA. Uni- and Multivariate Analysis of Risk Factors for Early and Late Hepatic Artery Thrombosis After Liver Transplantation. (2001) *Transplantation*, Vol 71, No. 6 ( Mar 2001), pp.767-772, ISSN 0041-1337
- Parrilla, P, Sanchez-Bueno, F, Figueras, J, Jaurrieta, E, Mir, J, Margarit, C, Lazaro, J, Herrera, L, Gomez-Fleitas, M, Varo, E, Vicente, E, Robles, R, & Ramirez, P. Analysis of the Complications of the Piggy Back Technique in 1,112 Liver Transplants. *Transplantation*, Vol 67, No. 9 (May 1999), pp. 1214-1217, ISSN 0041-1337
- Pastacaldi S, Teixeira R, Montalto P, Rolles K, & Burroughs AK. Hepatic Artery Thrombosis After Orthotopic Liver Transplantation: A Review of Nonsurgical Causes. *Liver Transpl*, Vol 7, No. 2( 2001) pp.75-81, online ISSN 1527-6473
- Perkins, J. D. (2007). The Evolution of Caval Implantation in Liver Transplantation. *Liver Transplantation* Vol 13, No. 3(Mar 2007), pp.463-467, online ISSN 1527-6473
- Quintini, C, Miller, C.M., Hashimoto, K, Philip, D, Diago Uso, T., Aucejo, F., Kelly, D., Winans, C., Eghtesad, B., Vogt, D., & Fung J. (2008). Side-to-Side Cavocavostomy with an Endovascular Stapler: Rescue Technique for Severe Hepatic Vein and/or Inferior Vena Cava Outflow Obstruction After Liver Transplantation Using the Piggyback Technique. *Liver Transplantation*, Vol 15, No.1 (2008), pp.49-53, online ISSN 1527-6473
- Reddy, K, Mallett, S, Peachey, T (2005). Venovenous Bypass in Orthotopic Liver Transplantation: Time For a Rethink. *Liver Transplantation*, Vol 11, No.7 (July 2005), pp.741-749, online ISSN 1527-6473

- Riediger, C, Muller, M, Michalski, C, Huser, N, Schuster, T, Kleeff, J, & Friess, H. (2010). T-Tube or No T-Tube in the Reconstruction of the Biliary Tract During Orthotopic Liver Transplantation: Systematic Review and Meta-Analysis. *Liver Transplantation*, Vol 16, No. 6 (2010), pp. 705-717, online ISSN 1527-6473
- Selvaggi, G., Weppler, D., Nishida, S., Moon, J., Levi, D., Kato, T., and Tzakis A.G. (2007). Ten-Year Experience in Porto-Caval Hemitransposition for Liver Transplantation in the Presence of Portal Vein Thrombosis. *American Journal of Transplantation*, Vol. 7, No. 2 (2007), pp.454-460, ISSN 1600-6135
- Sibulesky, L, Heckman, M, Perry, D, Taner, C, Willingham, D, & Nguyen. (2011). A Single-Center Experience With Biliary Reconstruction in Retransplantation: Duct-to- Duct or Roux-en-Y Choledochojejunostomy. *Liver Transplantation*, Vol 17, No. 6 (2011), pp. 710-716, online ISSN 1527-6473
- Sonnenday, C, Englesbe, M, Mathur, A, Heidt, D, Magee, J, Punch, J, Sung, R, Welling, T, Woodside, K, & Pelletier, S. (2008). Side-to-Side Cavocavostomy Technique. (video) Accessed Aug 2011, available at <http://www.med.umich.edu/trans/public/liver/cavoplasty.htm>
- Sotiropoulos, G, Sgourakis, G, Radtke, A, Molmenti, E, Goumas, K, Mylona, S, Fouzas, I, Karaliotas, C, & Lang, H. (2009). Orthotopic Liver Transplantation: T-tube or not T-tube? Systematic Review and Meta-analysis of Results. *Transplantation*, Vol 87, No. 11 ( June 2009), pp. 1672-80, ISSN 0041-1337
- Tayar, C., Kluger, M.D., Laurent, A., & Cherqui, D. (2011). Optimizing Outflow in Piggyback Liver Transplantation Without Caval Occlusion: The Three-Vein Technique. *Liver Transplantation*, Vol 17, No 1 (Jan 2011), pp.88-92., online ISSN 1527-6473
- Vieira de Melo, P, Miranda, L., Batista, L., Neto, O, Amorim, B, Sabat, B, Candido, H, Adeodato, L, Lemos, R, Carvalho, G, & Lacerda, C (2011). Orthotopic Liver Transplantation Without Venovenous Bypass Using the Conventional and Piggyback Techniques. *Transplantation Proceedings*, Vol 43, No. 4 (May 2011), pp.1327-1333, ISSN 0041-1345
- Warner, P, Fusai, G, Glantzouniz, GK, Sabin, CA, Rolando, N, Patch, D, Sharma D, Davidson BR, Rolles, K, & Burroughs, AK. (2011). Risk Factors Associated With Early Hepatic Artery Thrombosis After Orthotopic Liver Transplantation - Univariable and Multivariable Analysis. *Transplant Int*, Vol 24, No.4 (April 2011), pp. 401-408, ISSN 0934-0874
- Wu, Y, Voigt, M, Rayhill, S, Katz, D, Rou-Yee, C, Schmidt, W, Miller, R, Mitros, F & Labrecque (2001). Suprahepatic Venacavplasty (Cavaplasty) With Retrohepatic Cava Extension in Liver Transplantation: Experience With First 115 Cases. *Transplantation* 2001; vol 72, No. 8 (Oct 2001), pp.1389-1394, ISSN 0041-1337
- Yan, Mao-Lin, Zeng, Y, Li, B, Xu, Ming-Qing, Wen, Tian-Fu, & Wang, Wen-Tao. (2008). Postoperative Complications After Liver Transplantation with Cavoportals Hemitransposition. *Hepatobiliary Pancreat Dis Int*, Vol. 7, No. 3 (Jun 2008), pp.322-324, ISSN 1499-3872

Yerdel, M, Gunson, B, Mirza, D, Karayalcin, K, Olliff, S, Buckels, J, Mayer, D, McMaster, P & Pirenne, J (2000). Portal Vein Thrombosis in Liver Transplantation: Risk Factors, Screening, Management, and Outcome. *Transplantation*, Vol 69, No.9 (2000), pp.1873-1881, ISSN 0041-1337

IntechOpen

IntechOpen



## **Liver Transplantation - Technical Issues and Complications**

Edited by Prof. Hesham Abdeldayem

ISBN 978-953-51-0015-7

Hard cover, 454 pages

**Publisher** InTech

**Published online** 10, February, 2012

**Published in print edition** February, 2012

This book covers a wide spectrum of topics including, but not limited to, the technical issues in living and deceased donor liver transplant procedures, cell and experimental liver transplantation, and the complications of liver transplantation. Some of the very important topics, such as the arterial reconstruction in living donor liver transplantation, biliary complications, and the post-transplant-lymphoproliferative disorders (PTLD), have been covered in more than one chapter.

### **How to reference**

In order to correctly reference this scholarly work, feel free to copy and paste the following:

Vandad Raofi, Steven Cohn, Julie Koffron and Alan Koffron (2012). Vascular and Biliary Anastomoses in Deceased Donor Orthotopic Liver Transplantation, Liver Transplantation - Technical Issues and Complications, Prof. Hesham Abdeldayem (Ed.), ISBN: 978-953-51-0015-7, InTech, Available from: <http://www.intechopen.com/books/liver-transplantation-technical-issues-and-complications/vascular-and-biliary-anastomoses-in-deceased-donor-orthotopic-liver-transplantation>

**INTECH**  
open science | open minds

### **InTech Europe**

University Campus STeP Ri  
Slavka Krautzeka 83/A  
51000 Rijeka, Croatia  
Phone: +385 (51) 770 447  
Fax: +385 (51) 686 166  
[www.intechopen.com](http://www.intechopen.com)

### **InTech China**

Unit 405, Office Block, Hotel Equatorial Shanghai  
No.65, Yan An Road (West), Shanghai, 200040, China  
中国上海市延安西路65号上海国际贵都大饭店办公楼405单元  
Phone: +86-21-62489820  
Fax: +86-21-62489821

© 2012 The Author(s). Licensee IntechOpen. This is an open access article distributed under the terms of the [Creative Commons Attribution 3.0 License](#), which permits unrestricted use, distribution, and reproduction in any medium, provided the original work is properly cited.

IntechOpen

IntechOpen