

We are IntechOpen, the world's leading publisher of Open Access books Built by scientists, for scientists

4,800

Open access books available

122,000

International authors and editors

135M

Downloads

Our authors are among the

154

Countries delivered to

TOP 1%

most cited scientists

12.2%

Contributors from top 500 universities



WEB OF SCIENCE™

Selection of our books indexed in the Book Citation Index
in Web of Science™ Core Collection (BKCI)

Interested in publishing with us?
Contact book.department@intechopen.com

Numbers displayed above are based on latest data collected.

For more information visit www.intechopen.com



Surgical Options for Chronic Pancreatitis

Fazl Q. Parray¹, Mehmood A. Wani² and Nazir A. Wani³

¹Additional Professor,

²Post doctoral student Lakesure tertiary care Hospital Kochi India

³Ex Dean Faculty and Chairman Surgical Division

Department of Surgery, Sheri-Kashmir Institute of Medical Sciences,
India

1. Introduction

The early teaching used to be “Eat when you can, sleep when you can and don’t operate on the pancreas”. Also the belief was that God put the pancreas at the back because He did not want surgeons messing with it. It was Rufus of Ephesus (c. 100AD) who named the organ “Pancreas” (in Greek Pan: all, Kreas: Flesh or meat). Then it was Homer who used the word ‘sweetbread’ broadly to describe animal flesh (Modilin IM *et al.* Int Hepato-pancreato-biliary association, Indian Chapter, single theme conference; 2002; 1-3:32-46). This organ with the name sweetbread, however, turns quite bitter as soon it develops the pathological condition called chronic pancreatitis. H. Durmen has summarized the anatomical relationship of the pancreas as: “The pancreas cuddles the left kidney, tickles the spleen, hugs the duodenum, cradles the aorta, opposes the inferior vena cava, dallies with the right renal pedicle, hides behind the posterior parietal peritoneum of the lesser sac and wraps itself around the superior mesenteric vessels” (Dionigi R *et al.*). It derives its blood supply from major branches of the celiac and superior mesenteric arteries and it is mandatory for any surgeon operating on the pancreas to develop understanding of its vascular anatomy and its possible variations.

Chronic pancreatitis has been defined as a continuing inflammatory disease of the pancreas characterized by irreversible morphologic changes that typically cause pain and or permanent loss of function (Clain JE, Pearson RK. Surg Clin North Am 1999;79:829-46). An ideal classification system for chronic pancreatitis would be simple, objective, accurate, incorporating etiology, pathogenesis, structure, function and clinical status into one overall scheme. Although these criteria have never been met, several systems have been advocated. The most widely used classification systems include Marseille classification of 1963 (Sarles H. Symposium of Marseille 1963. Besel), with revisions in 1984 and 1987 and the Cambridge classification of 1984 (Sarner M and Cotton PB. Gut 1984;24:756-9). The Cambridge system proves more useful as a staging system once the diagnosis has been established. The Marseille-Rome classification 1987 includes more causal factors but proves to be more useful in defining pancreatitis. The numbers have increased markedly probably due to the changes in alcohol consumption and improved sensitivity of diagnostic tests. Early series from Copenhagen (Copenhagen pancreatitis study. Scand J Gastroenterol 1981;16:305-12), the

U.S.(Reila A *et al.* Mayo clin Proc 1992;67:839-45) and Mexico City(Robles-Diaz G *et al.*; Pancreas 1990;5:479-83) reported a similar incidence of about 4 per 100,000 inhabitants per year and prevalence rate of 45.5 per 100,000 in males and 12.4 per 100,000 in females (Charles S T, Singer MV. Scand J Gastroenterol 2003; 35:136-41). Recent advances in techniques and genetics provide possibilities for early and accurate identification of risk factors leading to chronic pancreatitis. Chronic pancreatitis has been categorized into toxic, idiopathic, genetic, autoimmune, recurrent attacks of acute pancreatitis and obstructive (TIGAR-O risk factor classification system version 1). The classification is based on prevalence of each etiological factor and has implications for potential treatment.

2. Pathogenesis

The hallmark of chronic pancreatitis is the replacement of normal pancreatic tissue with fibrotic tissue. This change leads to mass formation, ductal obstruction, and encasement of other structures or some combination of the above (Amman RW *et al.* Gastroenterology 1984; 86:820-8). The mechanism by which fibrosis takes place is incompletely understood but several advances have been made in the last several years. Ethanol in alcohol or its metabolites are believed to have a direct toxic effect on the pancreas and contribute to the development of chronic pancreatitis (Levy P *et al.* Pancreas 1995; 10:231-8). Ethanol seems to stimulate Pancreatic stellate cells (PSCs) through its metabolite acetaldehyde. PSCs regulate extracellular matrix proteins within the pancreas and collagen deposition within the gland. PSCs also in response to and production of various cytokines results in a self-sustaining cycle of inflammation and fibrosis (Apte MV, Wilson JS. Pancreas 2003; 27:316-20). Pancreatic stone protein (PSP), or lithostathine, is also effected by ethanol and may be over or underproduced in patients of chronic pancreatitis. The role of PSP is to stabilize inorganic ion complexes and to prevent precipitation of calcium carbonate (Bernard JP *et al.* Gastroenterology 1992; 103:1277-84). Alterations in PSP productions can lead to protein plugs or pancreatic duct stones which in turn can lead to ductal obstruction, intraductal and parenchymal hypertension, and subsequent continued cellular and organ damage. Many people over- consume ethanol and still do not develop the disease in contrary to those who consume very little and still develop the disease. The most likely explanation for this is that some patients are born with or develop a genetic predisposition and get the disease by a multistep complex pathway. Several genetic aberrancies have been well implicated like PRSS1, SPINK1, and CFTR and are considered to be most notable for the development of chronic pancreatitis. PRSS1 is involved in trypsin metabolism and regulation of the conversion of pro-pancreatic enzymes to their active form. SPINK1 inhibits intrapancreatic trypsin function to help autodigestion. The cystic fibrosis transcription repair (CFTR) gene is an essential gene for the proper regulation of pancreatic fluid, calcium and bicarbonate secretion. Regulation of bicarbonate also effects the inactive versus active forms of trypsin. The net effect of all these processes is chronic injury to the parenchyma of the pancreas with subsequent fibrosis and collagen deposition. Although this accounts, at least in part, for the mass effect in some patients and for the intraductal and glandular hypertension but may not completely explain why some patients have pain syndromes and others do not. The pathogenesis of pain is almost certainly linked in some degree to the already mentioned facts but still some patients have the disease without any mass effect or any evidence of ductal obstruction (Martin RF and Marion MD. Surg Clinic N Am 2007; 87:1461-1475).

Medical management which consists of enzyme replacement, control of diabetes with insulin and oral analgesics is generally effective, although eventually one third of the patients will need surgery during the course of their disease. The surgical management of pancreatitis has seen its ups and downs over the past few decades.

The risks of pancreatic surgery were initially high but a few surgeons were bold enough to approach the chronically inflamed and enlarged pancreas. A number of surgical procedures have been developed during the 20th century to deal with the condition. Review of literature indicates the maximum efficacy of any procedure to be 85 to 90%. There is no procedure evolved to provide a 100% cure for the condition. (Udani PM *et al* <<http://bhjorg/journal/1999:4102>>)

Dr. Kenneth Warren reported in 1959 that operations for chronic pancreatitis failed when they were not chosen on the basis of pathology observed at the time of operation and all operations were not successful all the time. His statements hold true even for present time (Warren KW. *Gastroenterology* 1959; 36:224-31). Therefore, surgery is aimed at controlling pain and managing complications rather than halting the progression of the disease. An appropriate and effective procedure has been difficult to devise and at the moment there is no clear "market leader" operation and the choice depends up on a grey zone where in pathological picture, patient's condition and available expertise dictate the final procedure the patient undergoes. The trends in choice of operation have not solely been based on better capacity to match the operation with the pathology discovered in the patient but also with the global level of comfort with the operations being performed. The ideal procedure for treating pain in chronic pancreatitis should be the one which is simple, easy to perform, associated with low morbidity and mortality, and at the same time should provide adequate drainage and not augment endocrine and exocrine insufficiency.

3. Indications for surgical intervention

Currently the following are considered the acceptable indications for surgery (Knoeful WT *et al*. *Pancreatology* 2002; 2:379-85).

1. Intractable pain.
2. Suspicion of malignant neoplasm.
3. Non-resolving ductal stenosis.
4. Non-resolving common bile duct stenosis.
5. Pseudo-aneurysms or vascular erosions not controlled by radiological intervention.
6. Endoscopically not controlled large pseudopancreatic cyst.
7. Intractable internal pancreatic fistula.

4. Preoperative evaluation and patient selection

Once a patient has been selected to undergo surgery for pain relief, a thorough preoperative evaluation must be performed. Two important questions must be answered.

1. Will this patient benefit most from a decompression of the pancreatic ductal system or from resection of pancreas?
2. Is this patient harboring a pancreatic malignancy?

The various biochemical and radiological tests for preoperative assessment and diagnosis are as follows.

4.1 Blood tests

Elevations of serum amylase and lipase are found helpful during acute attacks of pain. In the later stages chronic pancreatitis atrophy of the pancreatic parenchyma can result in serum enzyme levels within the reference range, even during acute exacerbations.

While low levels of serum trypsin are specific for advanced chronic pancreatitis, they are not sensitive enough to be helpful in most patients with mild to moderate disease. (Yashke P-e medicine)

Laboratory studies to identify causative factors include serum calcium and triglyceride levels.

4.2 Fecal tests

Steatorrhoea may be present in advanced chronic pancreatitis but neither qualitative nor quantitative fecal fat analysis can detect early disease.

4.3 Direct tests

Tests to detect chronic pancreatitis early are invasive and expensive.

4.3.1 Determination of duodenal aspirates

Pancreatic secretions are stimulated by exogenous secretion to achieve maximal output. The bicarbonate, protease, amylase and lipase output is then measured in the duodenal aspirates. This test is, however, only available in specialized centers.

4.3.2 Determination in pancreatic juice

This test is performed at the time of endoscopic retrograde pancreatography (ERCP). The pancreatic duct is freely cannulated, an external secretagogue is administered and the pancreatic juice is then aspirated out of the duct as it is produced. The bicarbonate, protease, amylase and lipase output is then measured. This test is gaining popularity because most patients undergo ERCP during the evaluation of chronic pancreatitis.

4.4 Indirect test

Non-invasive tests in principle work via oral administration of a complex substance that is hydrolyzed by a specific pancreatic enzyme to release a marker substance. The marker is then absorbed by the intestine and in turn measured in the serum or urine. These tests are capable of detecting moderate to severe degrees of chronic pancreatitis. Liver, renal and intestinal disease may interfere with the interpretation of these tests. They are not freely available in the United States (Yashke P e-medicine; Laukoisch PG. *Int J Pancreatol* 1993 Aug; 14(1):9-20).

4.5 Imaging studies

Structural changes in the pancreas and its ductal system are only seen during the moderate and severe stages of the disease, so most imaging procedures cannot depict early chronic pancreatitis.

4.5.1 Abdominal radiograph

Pancreatic calcification is observed in 30% of cases. They first form in the head and then in body and tail. Paired anteroposterior and oblique views are preferred because the vertebral column may otherwise obscure small specks of calcification.

4.5.2 Computerized tomography

Although CT excels at depicting the morphological changes of advanced chronic pancreatitis, the early changes are beyond its resolution and a normal finding on this study does not rule out chronic pancreatitis. CT is most useful to identify complications and in planning surgical or endoscopic intervention (Yashke P, e-medicine).

4.5.3 Endoscopic retrograde pancreatography (ERCP)

ERCP provides the most accurate visualization of the pancreatic ductal system and has been regarded as the criterion standard for diagnosing chronic pancreatitis. Conversely one limitation of ERCP is that it cannot be used to evaluate the pancreatic parenchyma, and histologically proven chronic pancreatitis has been documented in the setting of normal pancreatogram. The pancreatogram can be classified according to several schemes such as Cambridge criteria (Laukisch et al. *Pancreas* 1996 Mar;12(2):149-52).

A comparison of pancreatogram scoring with direct pancreatic function tests demonstrates good correlation. However, pancreatography tended to show more significant severe changes. ERCP is invasive, expensive, requires complete opacification of the pancreatic duct to visualize side branches and carries a risk of pancreatitis (Yashke P, e-medicine; Catalano MF *et al.* *Gastrointestinal Endoscop* 1998 Jul;48(1):11-7(medline).

4.5.4 Magnetic resonance cholangiopancreatography (MRCP)

MRCP imaging provides information on the pancreatic parenchyma and adjacent abdominal viscera and uses heavily T2 weighted images to visualize the biliary and pancreatic ductal system. The use of secretin during the procedure enhances the quality to enable the diagnosis of early chronic pancreatitis; however, it is relatively safe, reasonably accurate, non-invasive, fast and very useful in planning surgical and endoscopic intervention (Yashke P, e-medicine; Sota JA *et al.* *AJR Am J Roentgenol* 1995;165(6):1397-401(medline).

4.5.5 Endoscopic ultrasound (EUS)

EUS may be the best test for imaging the pancreas as per the recent studies. By placing the transducer immediately adjacent to the pancreas, the endoscopic approach eliminates the

interference by bowel gas and enables the use of high frequency probes to enable acquisition of detailed imaging. Eleven sonographic criteria have been developed that identify characteristic findings of chronic pancreatitis. Using these criteria EUS correlates well with endoscopic pancreatic ductography and intra-ductal secretin tests in moderate and severe disease. EUS may be useful in diagnosing chronic pancreatitis in a subset of patient with non-ulcer dyspepsia. More experience is required to determine its utility in detecting the early stages of chronic pancreatitis (Yashke P, *e-medicine*; Catalano MF *et al.* *Gastrointestinal Endoscop* 1998 Jul;48(1):11-7(medline). The new Rosemont criteria, using a combination of major and/or minor criteria, categorizes the patient as having EUS features that are (1) consistent with chronic pancreatitis, (2) suggestive of chronic pancreatitis, (3) indeterminate of chronic pancreatitis, (4) normal.

The researchers concluded that the new Rosemont classification system represents an improvement over current means of EUS diagnosis for chronic pancreatitis. They acknowledge the results of their deliberations do not provide a validation of their recommendations, but intend to apply these criteria in a manner that provides easy and reproducible means of EUS diagnosis and grading of chronic pancreatitis so that they may be used to help guide patient care and future study design. In an accompanying editorial, Walter G. Park, MD, and ASGE President Jacques Van Dam, MD, PhD, FASGE, division of gastroenterology, Stanford University Medical Center, Cal., state that "despite being less than the perfect criterion standard, it remains the best to date"(EUS-Based Criteria For The Diagnosis Of Chronic Pancreatitis: The Rosemont Classification,*ScienceDaily* (June 29, 2009) American Society for Gastrointestinal Endoscopy).

4.6 Other tests

A secretin stimulated ultrasound study is one way of looking for the resistance to pancreatic juice outflow at the level of the duodenum. The diameter of the pancreatic duct is measured at baseline and then 15 and 30 min after injection of secretin. Dilatation to a diameter greater than normal or for a longer period implies the presence of periampullary stricture or papillary stenosis (Yashke P,*e-medicine*; Catalano MF *et al.* *Gastrointestinal Endoscop* 1998 Jul;48(1):11-7(medline).

5. What is the most appropriate procedure?

The choice of surgical procedure depends upon the indication for surgery and the characteristics of disease in the individual patient. In general it is most appropriate to select a procedure which is likely to achieve the maximum symptomatic pain relief and also maximally preserve the functional pancreatic tissue.(Wani NA *et al.* *Int J Surg* 2007;5:45-56).

Drainage procedures were developed on the basis that the pain in chronic pancreatitis is due to ductal hypertension (Ebbehoj N *et al.* *Scand J Gastroenterol* 1984;19:1066-8) and proper drainage could decompress it. On the other hand the theories of perineural inflammation as the cause of pain lead to the development of resectional procedures (Bockmann DE. *Gastroenterology* 1988;94:1459-69).

5.1 Drainage procedure

1. **Partial:** draining the duct partially,
 - a. Sphincterotomy and sphincteroplasty,
 - b. Duval procedure,
 - c. Puestow Gillesby procedure,
 - d. Leger's procedure,
 - e. Marcadier procedure,
2. **Complete:** draining the main duct completely,
 - I. Pancreaticojejunostomy,
 - a. PartingtonRochelle procedure,
 - b. Bapat's modification of Partington's procedure,
 - II. Pancreaticogastrostomy,
 - a. Moreno Gonzales procedure.

5.2 Resectional procedures

- a. Whipple's operation,
- b. Traversoe Longmire procedure,
- c. Begar's procedure,
- d. Berne modification,
- e. Denervated pancreatic flap,
Warrens denervated pancreatic flap,
Shires denervated splenopancreatic flap,
- f. Subtotal pancreatic resection,
- g. Childs procedure,
- h. Total pancreatectomy,
With duodenal preservation,
Without duodenal preservation.

5.3 Extended drainage procedure

- a. Rumpf's extended drainage.

5.4 Resection with extended drainage

- a. Extended Begar's procedure,
- b. Frey's procedure,
- c. Izbicki V shaped ventral pancreatic excision.

5.5 Pancreatic denervation alone

- a. Left splanchnicectomy with celiac ganglionectomy,
- b. Left splanchnicectomy, celiac ganglionectomy with bilateral vagotomy,
- c. Complete pancreatic denervation,
- d. Transthoracic /videothoroscopic pancreatic denervation:

5.6 Pancreatic auto-transplantation

- a. Islet cell transplantation,
- b. Segmental pancreatic transplantation.

Drainage procedures

These drainage procedures gave pain relief in up to 60-80% cases (Udani PM *et al* <<http://bhjorg/journal/1999:4102>>).

Partial drainage procedures

Sphincterotomy and sphincteroplasty

Transduodenal sphincterotomy was originally proposed by Doubilet and Mulholland for the treatment of chronic pancreatitis with the mistaken belief that the disease was caused by bile reflux (Doubilet H *et al.* J Am Med Assoc 1956;160:521-8). The operation did not prove effective and subsequent attempts to improve pancreatic drainage by dividing the septum between the bile duct and the pancreatic duct have not proved popular (Bartlett MK *et al.* New Engl J Med 1960;262:642-8). In chronic pancreatitis it is unusual to find a uniformly dilated duct obstructed at the termination only therefore it follows that these procedures are unlikely to prove successful; however, early success rates of 50% (Doubilet H *et al.* J Am Med Assoc 1956;160:521-8 Bartlett MK *et al.* New Engl J Med 1960;262:642-8) when pain relief was assessed at 5 years have not been sustained (Bagley FH *et al.* Am J Surg 1981;141:418-21) Although surgical sphincterotomy has largely been given up; similar procedures have been performed endoscopically in the past with enthusiasm (Grim H *et al.* Endoscopy 1989;21:70-4).

Duval procedure

Decompression of the main pancreatic duct is achieved by resection of the pancreatic tail and retrograde drainage of the pancreatic duct via a termino-lateral pancreaticojejunostomy (Figure 1).

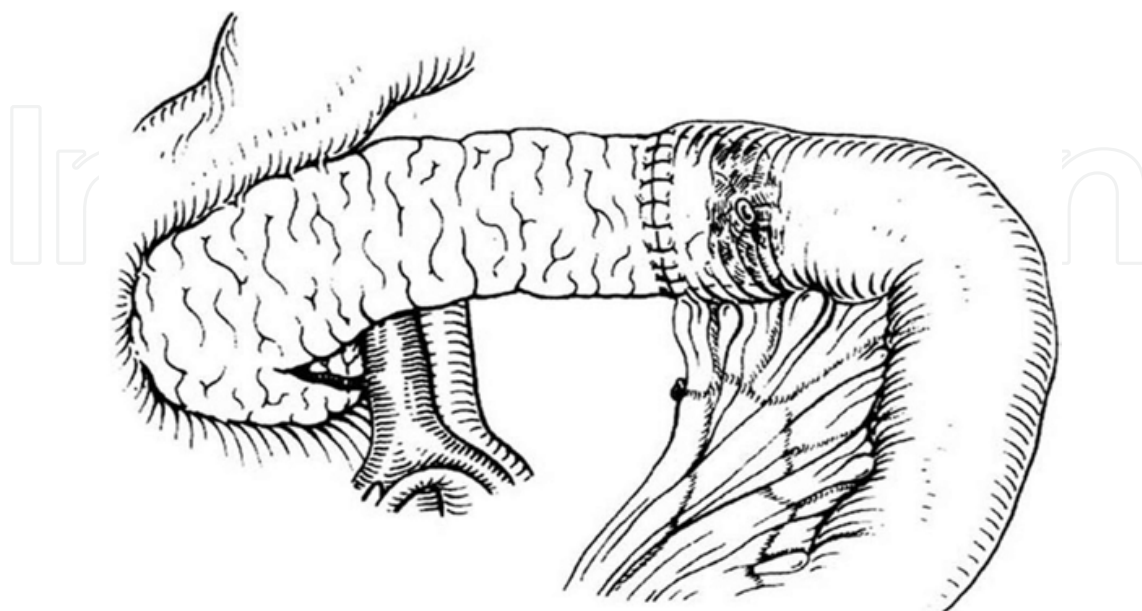


Fig. 1. Duval Procedure

However, this procedure will only be effective if there is a single stricture between pancreatic tail and the ampulla of Vater which in most of the cases is unlikely (Duval MK. *Ann Surg* 1954;140:775-85).

Puestow Gillesby procedure

They recommend a longitudinal opening of the pancreatic duct from the site of the transaction of the duct after resection of the pancreatic tail and spleen to a point to the right of the mesenteric vessels and invagination of the open duct with pancreas into a Roux-en-Y loop of jejunum, thus ensuring a wider drainage of the ductal system. This procedure takes care of multiple strictures seen in chronic pancreatitis (Puestow CB *et al.* *Arch Surg* 1958;76:898-906).

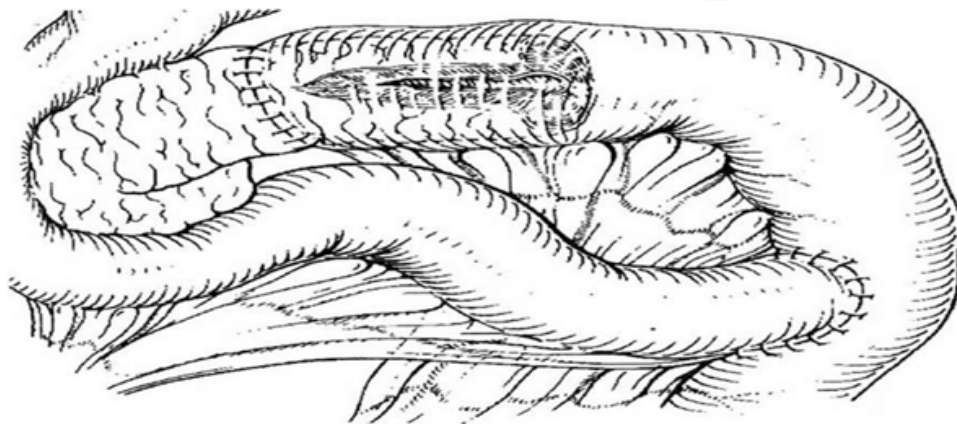


Fig. 2. Puestow Gillsby Procedure

Leger's procedure

This procedure developed for distal strictures involves a 40% distal pancreatectomy with splenectomy followed by opening of the pancreatic duct into a loop of jejunum by a retrograde lateral pancreaticojejunostomy (Leger L *et al.* *Ann Surg* 1974;180:180-91).

Mercadier procedure

Here only the body of the pancreas is drained into a Roux-en-Y loop of jejunum by a side to side anastomosis (Udani PM *et al.* <http://bhjorg/journal/1999:4102>).

Partial drainage procedures have been abandoned because of the small anastomosis which tends to occlude. Also the concept of preservation of the spleen with pancreatic tail is important as it prevents post-splenectomy sepsis (Govil S *et al.* *Br J Surg* 1999;86(7):895-8) and delays the onset of diabetes mellitus (Withigen J *et al.* *Ann Surg* 1974;179:412-8).

Complete drainage procedures

Pancreaticojejunostomy

Partington Rochelle procedure. This procedure is a refined Puestow procedure. It consists of a side to side long pancreaticojejunostomy, at least 10 cm without, resection of the pancreatic tail or the pancreas. However, a dilated main pancreatic duct (minimum 8 mm) is a prerequisite for a good duct to mucosa anastomosis (Partington RF *et al.* *Ann Surg* 1960;152:1037-42). In one of the largest series Greenlee (Greenlee HB *et al.* *World J Surg*

1990;14:70-6) reported significant improvement in 82% of these patients with lateral pancreaticojejunostomy with an extended follow up of up to 25 years. Similar results have been reported by others (Leger L *et al.* Ann Surg 1974;180:180-91;Moreno-Gonzales I *et al.* Br J Surg 1982;69:254). In our experience, this procedure has been performed on more than 130 patients of chronic pancreatitis with a duct size of more than 7 mm since 1985 till date. We strongly are in favour of this procedure in any patient with a duct size of more than 7 mm because of the technical ease, low morbidity, and excellent long-term results. We observed significant long-term improvement in more than 80% of our patients operated at Sher-i-Kashmir Institute of Medical Sciences, Srinagar, Jammu and Kashmir, India.

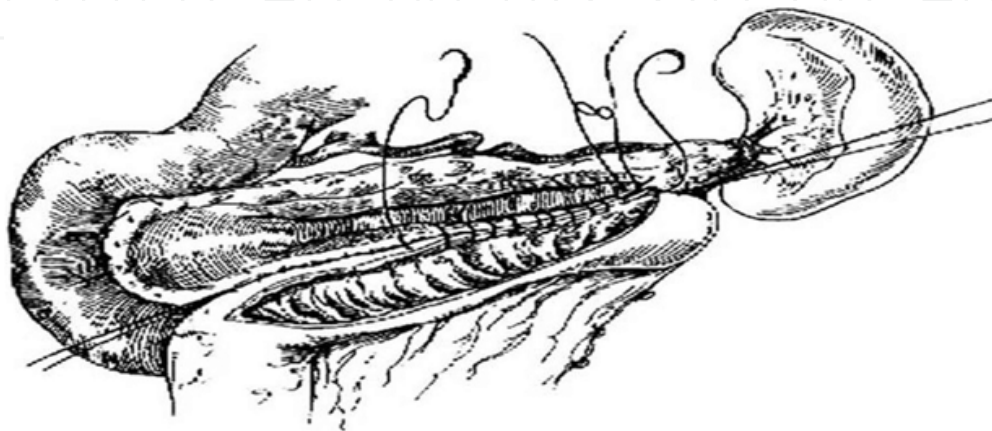


Fig. 3. The Partington Rochelle procedure

Bapat's procedure. It is modification of Partington's procedure. Here the pancreatic duct is opened from head to tail with wide drainage by a side to end pancreaticojejunostomy after fish mouting the jejunal end to a required length. A duct to mucosa anastomosis is performed. Again the prerequisite is a dilated duct of at least 7 mm. This procedure is more physiological and ensures a straight conical dependent anastomosis with effective and complete drainage (Bapat RD. Indian J Gastroenterol 1997 Jul;16(3):119-20).

Pancreaticogastrostomy

Pancreaticogastrostomy has been advocated by some to be a better form of drainage procedure than pancreaticojejunostomy (Pain JA *et al.* Br J Surg 1988;75:220-22). The procedure is performed as a mucosa to mucosa anastomosis over a T tube. A pain relief of up to 79% has been reported (Jordan GL *et al.* Am J Surg 1977;133:46-50); however, more patients developed steatorrhoea because of the inactivation of the pancreatic enzymes by gastric acid. However, most surgeons still regard pancreaticojejunostomy as the drainage operation of choice.

Moreno Gonzales procedure

Pancreatic and bile duct drainage is established into an isolated vascularised loop of jejunum which is then anastomosed to the duodenum. The procedure has potential advantages, it allows the return of bile and pancreatic secretions into the duodenum and there is no pancreaticocibal asynchrony.

In conclusion the patients with ductal dilatation of more than 7-8 mm, no inflammatory mass or ductal abnormality in the head and uncinete process are the most suitable

candidates for lateral pancreaticojejunostomy. The results of pancreaticojejunostomy are difficult to interpret. Many reports have differing indications, different forms of surgery and inadequate follow up. In general however, all forms of drainage procedures tend to worsen over time especially if patients do not abstain from alcohol (Lerut JP *et al.* Ann Surg 1984;199:432-7).

Resectional procedure

The head is considered to be pacemaker of the disease and its complications. A mass in the pancreatic head is found in 30-60% of the patients with chronic pancreatitis (Buchler M *et al.* Am J Surg 1995;169:65-70). No study has yet conclusively shown pain being only attributable to main duct obstruction and it is difficult to think of a good reason to believe so. The pathogenesis of pain is most likely not only related to ductal and parenchymal hypertension but also to the theory of perineural inflammation (Bockmann DE. Gastroenterology 1988;94:1459-69).

In addition lateral pancreaticojejunostomy never drains the second and third order pancreatic ducts, hence the concept led to the development of resectional procedures.

Whipple's operation (1935)

The procedure although first described by Allen O Whipple in 1912, but published much later for malignant lesions of the head of the pancreas is now also used for benign inflammatory mass in the head with a non-dilated pancreatic duct. The procedure consists of a pancreaticoduodenectomy with reconstruction by a pancreaticojejunostomy/gastrostomy, gastrojejunostomy and choledochojejunostomy. The intellectual basis for the shift in resection of the distal pancreas to that of pancreatic head was the concept of the "Pain Pacemaker" being located in the head of the pancreas promulgated by Dr. Longmires. This is a complex and technically challenging procedure with higher mortality rates as compared to drainage procedure, however, with good results. This procedure involves excising normal organs much against the principles of surgery for a benign disorder and has given way to more conservative approaches (Augusto JB *et al.* The Pancreas) However, it is the preferred surgical option if there is any suspicion of malignancy, as in such a situation there should be no compromise on the radicality of the procedure.

Traversoe Longmire procedure

Originally used in 1994 for a peri-ampullary tumor by Watson (Watson K. Br J Surg 1944;31:368-73) it was subsequently used by Traversoe Longmire for chronic pancreatitis in 1978 (Traverso and Longmire. Surg Gynecol Obstet 1978;156:581-6). As a gastrectomy is avoided and the pylorus and the proximal duodenum are preserved it achieves a better postoperative nutritional status, minimizes postgastrectomy syndromes as well as the incidence of marginal ulceration. For these reasons it has almost become the form of resection for patients requiring pancreaticoduodenectomy in chronic pancreatitis. Recent reports on pancreaticoduodenectomy for chronic pancreatitis have recorded a low mortality rate of 0-1%, significant pain relief of 80-100% (Traverso LW *et al.* Ann Surg 1997;226:429-38). The incidence of diabetes increased from 17 to 44% in the preoperative period to 26-64% in the postoperative period (Traverso LW *et al.* Ann Surg 1997;226:429-38; Rossi RL *et al.* Arch Surg 1987;122:416-20). However, the onset of diabetes on follow up rather than immediately

after the surgery suggests progression of the disease rather than the effect of surgery. The procedure got more established after the results of a randomized trial. Two hundred and fourteen patients were randomized to undergo either a standard or a pylorus-preserving Whipple resection. After exclusion of 84 patients on the basis of intraoperative findings, 130 patients (66 standard Whipple operation and 64 pylorus-preserving resection) were entered into the trial. Of these, 110 patients with proven adenocarcinoma (57 standard Whipple and 53 pylorus-preserving resection) were analysed for long-term survival and quality of life. There was no difference in perioperative morbidity. Long-term survival, quality of life and weight gain were identical after a median follow-up of 63.1 (range 4–93) months. At 6 months, capacity to work was better after the pylorus-preserving procedure (77 versus 56 per cent; $P = 0.019$). The conclusion was that both procedures are equally effective for the treatment of pancreatic and periampullary cancer. Pylorus-preserving Whipple resection offers some minor advantages in the early postoperative period, but not in the long term. The same principle applies to managing chronic pancreatitis by using either of the procedure (Seiler, CA *et al.* *British Journal of Surgery*, May 2005; 92,(5): 547–556).

Hans Begar's procedure

This procedure is indicated in chronic pancreatitis with inflammatory mass in the head with medically intractable pain, obstruction of the common bile duct, duodenal stenosis or portal hypertension due to compression of portal vein by inflammatory mass. It is a duodenum sparing resection of the head of the pancreas thus preserving duodenal physiology and normal intestinal continuity which has significance in terms of postoperative nutritional status, blood sugar control and marginal ulceration. Two major steps are involved:

Resection: The pancreas is transected at the border between the head and the body above the superior mesenteric vein leaving a small disk of the head between the common bile duct and the duodenal wall.

Drainage: The body of the pancreas is drained by an end to end pancreaticojejunostomy and the pancreatic head by a side to side anastomosis to the rim of the resection cavity (Yasuda H *et al.* *J Biliary Tract Pancreas* 1990;11:967-73). The procedure seems to be safe with perioperative mortality of 0-0.8%. Significant relief of pain has been reported in 86-92% of patients. It is not associated with fresh development of diabetes in the early postoperative period. However, existing diabetes may worsen in 10-13% of the patients (Beger HG *et al.* *Ann Surg* 1999;230:512-23). Even, late diabetes develops in 21% of the patients due to progression of the disease. DPPHR when compared to PPPD has a superior outcome because of better pain control, weight gain, better glucose tolerance and higher insulin secretion capacity (Buchler M *et al.* *Am J Surg* 1995;169:65-70).

Berne modification: In comparison to Begar's technique this modification spares the dissection of the pancreatic body from the portal vein. After the resection of pancreatic head, a single cavum results which can be anastomosed end to side with a ROUX-en-Y jejunal loop. If stenosis of the intrapancreatic part of the common bile duct cannot be resolved by decompression and resection of the surrounding pancreatic tissue, or if the intrapancreatic portion of the common bile duct is opened accidentally during pancreatic head resection, the wall of the opened bile duct is fixed with single stitches to the surrounding tissues like an opened door and is included in the same anastomosis (Koninger J *et al.* *Surgery* 2008;143(4):490-98).

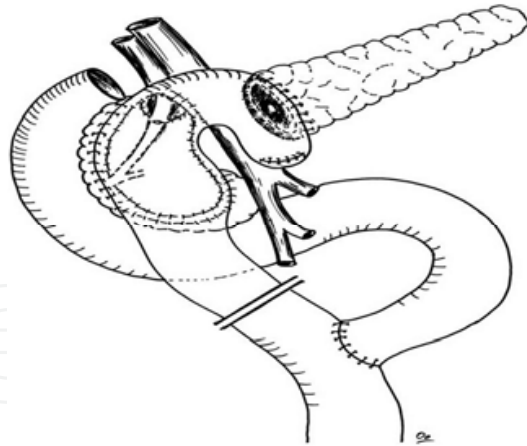


Fig. 4. The Begar's procedure

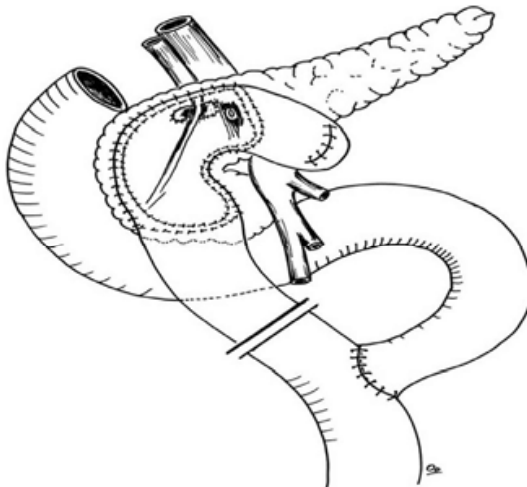


Fig. 5. Berne modification

Denervated pancreatic flaps

In Warren's procedure the pancreas is divided over the portal superior mesenteric vein after ligation of the splenic artery and vein. The pancreatic head is excised leaving a thin rim. The remaining pancreas is not drained. Ligation of splenic vein and artery is presumed to denervate the gland (Warren WD *et al.* Surg Gynecol Obstet 1984;159:581-6). Shires *et al.* described a more elaborate procedure called a denervated splenopancreatic flap for patients with small duct pancreatitis (Shires GT *et al.* Ann Surg 1986;203:568). The procedure includes complete mobilization of the pancreas from the retroperitoneum, resection of the head and the uncinata process leaving a small rim near the duodenum, division of the splenic vein near its junction with the superior mesenteric vein and drainage of the distal pancreatic remnant into a Roux-en-Y limb of jejunum. The complexity of the procedure and its unproven efficacy may limit its usefulness.

Subtotal pancreatic resection

Excision of the body and distal pancreas used to be a commonly performed procedure during 1960-1970 but with the development of better imaging facilities it was noted that disease in the body and the tail is often secondary to disease in the head of the pancreas, thereby limiting its role. This procedure is still indicated when the disease is confined to the

body and tail e.g., pseudocyst, failed pancreaticojejunostomy, non-dilated duct, pseudoaneurysm and when there is disease beyond the neck of pancreas, and the pancreatic duct is oversewn. A concomitant splenectomy is unavoidable in the majority of patients because of dense fibrosis precluding the isolation of the splenic vessels. However, splenic preservation may be possible in 20-34% of patients. Another procedure described by Warsaw in which splenic salvage is achieved by preservation of the short gastric vessels; early mortality is 0-4% (Evans TD *et al.* Br J Surg 1997;84:624-9) and pain relief is 70-88% (Frey CF *et al.* Surg Clin North Am 1989;69:499-528). About 20% develop diabetes in the early postoperative period. Severe hypoglycemic coma and brain damage occur in 2-4% of all such patients (Frey CF *et al.* Surgery of Pancreas 1997;347-55). Further an increased incidence of steatorrhoea is seen in 15% (Frey CF *et al.* Surg Clin North Am 1989;69:499-528)

Childs resection

This procedure first described by Barret and Bowers in 1957 (Barret O *et al.* USAF Med J 1957;8:1037-41); was popularized by Child. It is a 95% distal pancreatectomy. The spleen, the tail, body and uncinata processes are completely removed. The small cuff of the head that is preserved protects the vascularity and common bile duct during surgery. This procedure is performed when lesser procedures have failed or when the entire pancreas is severely diseased (William JF *et al.* Ann Surg 1965;162(4):534-49). Pain relief is about 90% with a mortality of up to 4% while diabetes develops in 50% of patients (Frey CF *et al.* Surgery of Pancreas 1997;347-55) and the incidence of early steatorrhoea increases by 30% (Frey CF *et al.* Surg Clin North Am 1989;69:499-528).

Total pancreatectomy

Total pancreatectomy bringing in its wake permanent endocrine and exocrine deficiency is usually offered as a last resort to patients with chronic pancreatitis who have diffuse involvement of the pancreas with non-dilated ducts, suspicion of malignancy or failed previous procedure. The operative mortality ranges from 0 to 10% and pain relief is achieved in 80% (Frey CF *et al.* Surg Clin North Am 1989;69:499-528). In the absence of counter regulatory hormones control of sugar is very difficult (brittle diabetes). Hypoglycemic attacks after total pancreatectomy can lead to death or irreversible brain damage. Patients who are already insulin dependent and need pancreatic supplementation for steatorrhoea are ideally suited for this procedure.

Duodenum preserving total pancreatectomy

Russel in 1987 reported a total pancreatectomy with duodenal preservation. The operative procedure is extremely tedious; pain relief is achieved in 75-80% of patients and no postoperative deaths have been reported. Early complications include bleeding, sepsis and duodenal fistula. However, at a later stage patients may develop bile duct or duodenal stricture. This procedure is also offered as a last resort as is total pancreatectomy (Easter DW *et al.* Ann Surg 1991;214:575-80).

Extended drainage procedures

Rumpf's extended drainage procedure

This is a combination of Partington's procedure with a transduodenal pancreatic sphincteroplasty. It is indicated when there is a pre-papillary obstruction to the drainage of pancreatic duct due to stones or stricture (Rumpf KD *et al.* Chirurg 1983;54:722-7).

Resection with extended drainage

The reported incidence of inflammatory mass in the head is about 30% of which only 10% are malignant (Marcus WB *et al.* Am J Surg,1995;169:65-70). Resection with extended drainage procedure provides cure in up to 95% of cases (Izbicki JR *et al.*Ann Surg 1995;221(4):350-8).

Extended Begar's procedure

In cases where there are multiple strictures in the left pancreas with an inflammatory mass in the head, this procedure has a superior result. In addition to the duodenum preserving head resection a side to side pancreaticojejunostomy is performed after slitting open the main pancreatic duct.

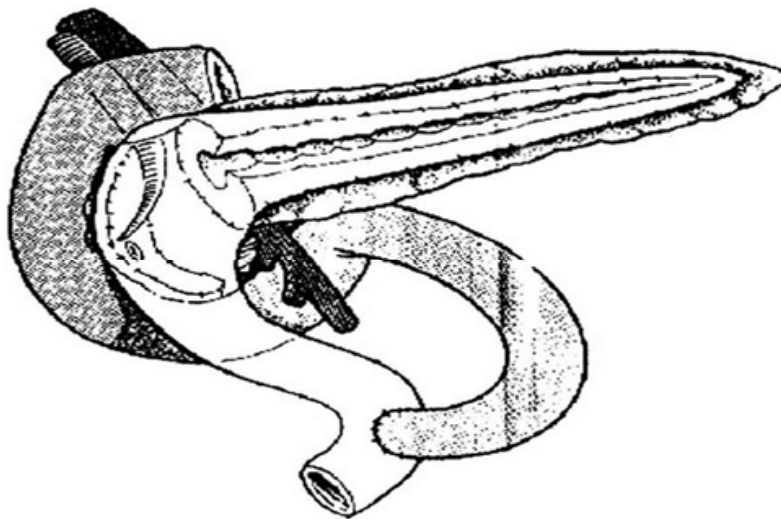


Fig. 6. The Extended Begar's procedure

Frey's procedure

A modified procedure combines lateral pancreaticojejunostomy of Partington Rochelle with coring out of the pancreatic head overlying the ducts of Wirsung and Santorini and the uncinata process using a diathermy, keeping at least 5 mm pancreatic tissue posteriorly and medially. If the duct is less than 8 mm in size mucosa to capsule anastomosis is performed. This procedure is indicated for pain in chronic pancreatitis with its complications like pseudocyst, common bile duct obstruction, pancreatic ascites, fistulae and recurrent pain after lateral pancreaticojejunostomy. It is contraindicated in patients where cancer cannot be excluded (Frey CF. Adv Surg 1999;32:41-85).

Izbicki's "V" shaped ventral pancreatic excision

In this procedure a long "V" shaped excision of ventral aspect of the pancreas is done with a lateral pancreaticojejunostomy by a mucosa to capsule anastomosis. This procedure drains the main as well as the second and third order ducts. This is an ideal procedure for small duct disease with a maximum diameter of the Wirsung's duct less than 3 mm (Izbicki JR *et al.* Ann Surg 1998;227(2):213-14).

Pancreatic denervation alone

Splanchnic nerves and the sympathetic trunks indicate pain arising from the pancreas, extrahepatic biliary ducts and gastrointestinal tract from the level of the stomach to the

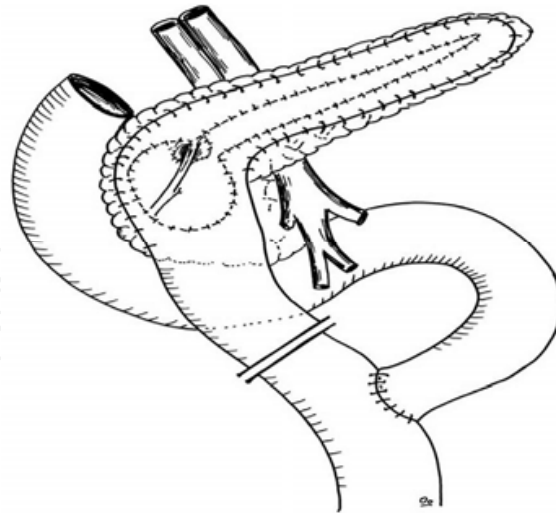


Fig. 7. Duodenum-preserving pancreatic head resection by Frey

rectosigmoid. Interest in surgical neurectomy has progressed by the observation that fibers which mediate pancreatic pain interconnect only through the celiac and superior mesenteric plexus. Various methods of denervation have been described like left splanchnicectomy with celiac ganglionectomy with or without vagotomy. Mallet Guy advocated an extra peritoneal approach through the 12th rib for left splanchnicectomy with celiac ganglionectomy (Mallet Guy PA. *Am J Surg* 1983;145:234). This is done after correcting the extra pancreatic pathology. In a 5-year follow up of these patients there was an 84% overall improvement. However, the failure rate was up to 31% in patients with diffuse pancreatic fibrosis and no discernable extra pancreatic cause (White TT *et al.* *Am J Surg* 1966;112:195). The role of vagal fibers in pancreatic pain is unclear. Generally however, bilateral vagotomy is considered to increase the completeness of pancreatic denervation.

Complete pancreatic denervation

Hirokawa described a more extensive denervation procedure, which includes freeing the pancreas from the posterior abdominal wall and resection of all postganglionic pancreatic nerve plexus including those surrounding the common hepatic and splenic arteries (Hiraoka T *et al.* *Am J Surg* 1986;152:459). Although there are only a small number of patients who have undergone the procedure and this follow up is short; this procedure may provide a reasonable alternative to extensive resection.

Transthoracic/videothoracoscopic pancreatic denervation

There are important thoracic anatomical considerations regarding the innervation to the pancreas. The greater splanchnic nerves are largely responsible for pain in supramesenteric viscera and the nerve trunks lie above the level of the 10th thoracic vertebra and descend along the spine to end in the celiac plexus, similarly the lesser splanchnic plexus. Transthoracic denervation can be achieved by division of the splanchnic nerves with bilateral vagotomy performed through a left thoracotomy. A similar procedure is now performed using a videothoracoscopic technique (Makarewicz W *et al.* *World J Surg* 2003;27:906-11). This minimally invasive procedure achieved results almost equal to those of major abdominal surgery. Follow up of 12 months demonstrated an improved quality of

life. This procedure may be considered for patients who do not meet the anatomic criteria for drainage and those who may not be candidates for major abdominal surgery.

Pancreatic auto-transplantation

Although subtotal and total pancreatectomies successfully alleviate the pain of chronic pancreatitis, patients develop troublesome insulin dependent diabetes mellitus. This can be overcome by auto-transplantation.

Islet cell auto-transplantation

The Mirkowitch technique which is used to prepare partially purified islets produces a fairly large volume of minced digested islet cell tissue which is then injected into a portal vein. Despite slow injection portal pressure is markedly raised several fold. Hinshaw *et al.* developed and tested a more sophisticated islet preparation technique. This technique produced a 5 ml tissue pellet containing 500,000-2000,000 islets for transplantation, no problems were noted with this preparation and the portal pressure remained essentially unchanged. Long-term success (insulin independence) with both these techniques is reported at 40-43% (Hinshaw DB *et al.* Am J Surg 1981;42:118). In recent years total pancreatectomy and islet autotransplantation are done for chronic pancreatitis with intractable pain when other treatment measures have failed, allowing insulin secretory capacity to be preserved, minimizing or preventing diabetes, while at the same time removing the root cause of the pain. Since the first case in 1977, several series have been published. Pain relief is obtained in most patients, and insulin independence preserved long term in about a third, with another third having sufficient beta cell function so that the surgical diabetes is mild. Islet autotransplantation has been done with partial or total pancreatectomy for benign and premalignant conditions. Islet autotransplantation should be used more widely to preserve beta cell mass in major pancreatic resections (Blondet JJ, *et al.* (2007), *Surgical Clinics of North America*, 87(6): 1477-1501).

Segmental pancreatic transplantation

This technique comprises auto-transplantation of the resected body and tail of the pancreas into the thigh following near total pancreatectomy. The splenic vessels are anastomosed to the femoral vessels. The divided end of the pancreas is closed and the duct is ligated or injected with synthetic polymers (e.g., prolamine or neoprene). Duct obliteration is thought to cause rapid and permanent atrophy of the exocrine pancreas and preserves endocrine function. However, others concluded that duct obliteration does not prevent relapse or progression of chronic pancreatitis in the preserved pancreatic segment. Internal drainage of the duct into a Roux-en-Y limb of jejunum has also been reported with good results. Technical success was achieved in up to 80% of patients with pain relief in 80% and insulin independence in 70% (Rossi RL *et al.* Ann Surg 1986;203:626).

Laparoscopic pancreatic resection

Laparoscopic resection of the pancreas is technically quite demanding and most of the surgeons may find it cumbersome and time consuming, hence their adoption has been limited. Although the operation is technically feasible, the benefit of the laparoscopic approach may not be as apparent as that of a less complex laparoscopic procedure (Gagner M *et al.* Surg Endosc 1994;8(5):408-10). Recent years have seen an increasing trend in the use

of laparoscopy for distal pancreatic resection with splenic preservation. In most studies it has been found that distal pancreas resection can be performed as a laparoscopic procedure, with the usual advantages that this techniques has for the patient. Optimal closure of the cut edge of the pancreas and the preservation of the spleen and its main vessels are the most important aspects of this operation (Uranues S,et al. The American Journal of Surgery, Aug 2006;192(2):257-261). Of late surgeons have started comparing the results of robotic surgery versus laparoscopic surgery in pancreatitis which continues still to be in its infancy because of little evidence at present available in literature (Samuel M,et al ,Pancreas(Oct 2010); 39(7): 1109-1111).

6. Ruling out a malignant neoplasm

There is evidence to suggest that chronic pancreatitis could predispose to pancreatic malignancy (Lowenfels AB *et al.* New England J Med 1993;328:1433-7). Studies show that the risk rises with duration from 1.8% at 10 years to 4% at 20 years and it has been speculated that it is due to the increased levels of growth factors(Kore M *et al.* Gut 1994;35:1468-73); another report showed a 6% malignant change of inflammatory head mass at 9 years follow up (Beger HG *et al.* Ann Surg 1999;230:512-23). Concomitant malignancy has been reported in 15-21% of patients undergoing surgery for chronic pancreatitis which may be detected at surgery or on follow up (Ramesh H. Br J Surg 1992;79:544-9). Differentiating a malignant neoplasm in the head of the pancreas from an inflammatory mass of chronic pancreatitis is a major challenge for the surgeon which needs to be addressed at the time of surgery. The head in chronic pancreatitis is hard and enlarged so the hope of detecting carcinoma by palpation is not possible and is only an illusion. A 15% error in sampling as well as interpretation makes frozen section an unreliable tool to exclude malignancy (Campanale RP *et al.* Arch Surg 1985;12:283-8). Therefore a high degree of suspicion is to be entertained in these patients. In such a situation only resection probably pancreaticoduodenectomy should be preferred as any lesser procedure may leave behind the lesion or cause tumor spillage. Frequently, there bypass procedures become necessary after lateral pancreaticojejunostomy. With pylorus preserving resections these additional procedures are not required. This safely and effectively combines the control of complications with the preservation of original anatomy and thus is a more physiological procedure. The relevance of segmental portal hypertension in a patient of chronic pancreatitis is poorly understood. Complications of segmental portal hypertension are rare and its presence should not influence the choice of operation. Complications such as internal fistula, pseudocysts, pancreatico-portal fistula, or pseudoaneurysm require an individualized approach.

7. Conclusion

In conclusion Chronic pancreatitis results from a combination of inherited or acquired genetic predispositions coupled with glandular injury secondary to ingested compounds such as ethanol, prior mechanical injury, or injury secondary to other significant illness. The disease process leads to fibrosis, which yields mass effect and obstructs ductal drainage. Chronic inflammatory changes result in pain syndromes caused by directly injuring nerves and through humoral release of pain neurotransmitters. Ductal obstruction causes conditions to persist that provide a positive feedback loop for continued glandular injury (Martin RF and Marion MD. Surg Cline N Am 2007;87:1461-75).

The old controversy “resection or drainage” is probably now irrelevant. Both have established roles and probably best results are achieved by a combination of both. Chronic pancreatitis is such a complex and variegated disease that there is never a single procedure that would achieve goals in all patients. Therefore, it is important to understand that the choice of surgery has to be individualized to address the pathological change in each patient. However, ultimately it is the surgeons experience and an operative strategy that is slightly modified for every patient that is going to achieve the best possible results and which is what would be ultimately an ideal or somewhat close to ideal procedure for chronic pancreatitis. However, most of the operative procedures described in this monogram need a larger series of treated patients to be followed to adopt a definitive and probably better future strategy for managing this complex problem. However, the good news for a pancreatic surgeon is that operative management can be performed with low mortality and acceptable morbidity. Surgical treatment can provide good pain control, return patients to work, and achieve a satisfactory quality of life in the majority of patients. Longterm mortality is high in a subset of patients (Schnelldorfer T *et al.* J Am Coll Surg 2007;204:1039-1047). Latest literature suggests the role of oral pancreatic enzyme supplementation and dietary modification in improving digestive tract function in people with chronic pancreatitis (The *Medifocus Guidebook on Chronic Pancreatitis*, 123 pages; last updated June 21, 2011).

8. Acknowledgement

- Prof G Q Peer who always trusted and believed in me and infused confidence in me at critical junctures.
- Prof Khursheed Alam Wani -Head Dept of Surgery at SKIMS who always encouraged and facilitated my research work and kept on appreciating my good work at all junctures.
- Prof Nisar A Chowdri who always trusted and believed in me for quality work.
- Dr Sameer H Naqash, Dr Ajaz A Malik and Dr Rouf A Wani, Dr Mubashir A Shah and Dr Munir A Wani my dearest colleagues in the department who always stood by me morally and professionally during the study period.
- Mr Farooq A Nadaf for always sincerely executing my computer work with lots of zeal and commitment.
- My revered parents for their love, affection and blessing.
- My beloved wife Nighat who is a big psychological, emotional and moral support for my all academic work and my sweet kids Shaheem and Liqa who always bear with me in my hours of toil at the cost of their time.
- My dearest students who always gave me lots of love and respect and made me to do better.


9. References

- Augusto JB, Niederhuber JE. (1998). The pancreas. In: Niederhuber JE, Dunwoody SL, editors. *Fundamentals of surgery*. 1st ed. Stanford: Appleton and Lange; p. 375-89.
- Barret O, Bowers WF. (1957). Total pancreatectomy for relapsing and calcinosis of pancreas. *USAF Med J*, 8:1037-41.
- Bartlet MK, Nardi GL. (1960). Treatment of recurrent pancreatitis by transduodenal sphincterotomy and exploration of the pancreatic duct. *New Engl J Med*, 262:642-8.

- Bagley FH, *et al.* (1981). Sphincterotomy or sphincteroplasty in the treatment of pathological mild pancreatitis. *Am J Surg*, 141:418-21.
- Bockmann DE, *et al.* (1988). Analysis of nerves in chronic pancreatitis. *Gastroenterology*, 94:1459-69.
- Buchler M *et al.* (1995). Randomized trial of duodenum preserving pancreatic head resection versus pylorus preserving Whipple in chronic pancreatitis. *Am J Surg*, 169:65-70.
- Bapat RD, *et al.* (1997) Modified Partington procedure for pancreaticojejunostomy in chronic pancreatitis. *Indian J Gastroenterol*, 16(3):122-5
- Beger HG, *et al.* (1999). Duodenum preserving head resection in chronic pancreatitis changes the natural course of the disease. A single centre 26 year experience. *Ann Surg*, 230:512-23.
- Blondet JJ, *et al.* (2007). The Role of Total Pancreatectomy and Islet Autotransplantation for Chronic Pancreatitis. *Surgical Clinics of North America*, 87(6): 1477-1501.
- Copenhagen pancreatitis study.(1981). An interim report from a prospective epidemiological multicentre study. *Scand J Gastroenterol*, 16:305-12.
- Campanale RP, *et al.* (1985). Reliability and sensitivity of frozen section pancreatic biopsy. *Arch Surg*, 12:283-8.
- Catalano MF, *et al.* (1998). Prospective evaluation of endoscopic ultrasonography and secretin test in the diagnosis of chronic pancreatitis. *Gastrointest Endoscop*, 48(1):11-7 [medline].
- Clain JE, Pearson RK. (1999). Diagnosis of chronic pancreatitis: is a gold standard necessary? *Surg Clin North Am*, 79:829-46.
- Duval MK. (1954). Caudal pancreaticojejunostomy for chronic relapsing pancreatitis. *Ann Surg*, 140:775-85.
- Doubilet H, Mulholland JH. (1956). Eight year study of pancreatitis and sphincterotomy. *J Am Med Assoc*, 160:521-8.
- Dionigi R, *et al.* (2006). Chirurgia con CD ROM, *Pancreas*, 14,vol(1-2):705-706.
- Ebbehoj N, *et al.* (1984). Pancreatic tissue pressure in chronic obstructive pancreatitis. *Scand J Gastroenterol*, 19:1066-8.
- Easter DW, Cushieri A. (1991). Total pancreatectomy with preservation of the duodenum and pylorus for chronic pancreatitis. *Ann Surg*, 214:575-80.
- Evans TD, *et al.* (1997). Outcome of surgery for chronic pancreatitis. *Br J Surg*, 84:624-9.
- EUS-Based Criteria For The Diagnosis Of Chronic Pancreatitis: The Rosemont Classification. *ScienceDaily*, June 29, 2009; American Society for Gastrointestinal Endoscopy.
- Fery CF, *et al.* (1989). Pancreatic resection for chronic pancreatitis. *Surg Clin North Am*, 69:499-528.
- Frey CF, Ho HS. (1997). Distal pancreatectomy in chronic pancreatitis. In: Trede M, Carter DC, editors. *Surgery of the pancreas*. New York: Churchill Livingstone; p. 347-5.
- Frey CF. (1999). The surgical management of chronic pancreatitis. The Frey procedure. *Adv Surg*, 32:41-85.
- Grimm H, *et al.* (1989). New modalities for treating chronic pancreatitis. *Endoscopy*, 21:70-4.
- Grenlee HB, *et al.* (1990). Long term results of side to side pancreaticojejunostomy. *World J Surg*, 14:70-6.
- Gagner M, Pomp A. (1994). Laparoscopic Pylorus Preserving Pancreatoduodenectomy. *Surg Endosc*, 8(5):408-10.
- Govil S, Imrie CG. (1999). Value of splenic preservation during distal pancreatectomy for chronic pancreatitis. *Br J Surg*, 86(7):895-8.

- Hinshaw DB, *et al.* (1981). Islet auto-transplantation after pancreatectomy for chronic pancreatitis with a new method of islet preparation. *Am J Surg*, 42:118.
- Hiraoka T, *et al.* (1986). A new surgical approach for treatment of pain in chronic pancreatitis: complete denervation of the pancreas. *Am J Surg*, 152:459.
- Izbicki JR, *et al.* (1995). Duodenum preserving resection of the head of the pancreas in chronic pancreatitis. *Ann Surg*, 221(4):350-8.
- Izbicki JR, *et al.* (1998). Longitudinal V shaped excision of the ventral pancreas for small duct disease in severe pancreatitis. *Ann Surg*, 227(2):213-24.
- Jordan GL, *et al.* (1977). Current status of pancreaticojejunostomy in the management of chronic pancreatitis. *Am J Surg*, 133:46-550.
- Kore M, *et al.* (1994). Chronic pancreatitis is associated with increased concentration of Epidermal growth factor receptor, Transforming growth factor and phospholipase C gamma. *Gut*, 35:1468-73.
- Knoefel WT, *et al.* (2002). Optimizing surgical therapy for chronic pancreatitis. *Pancreatology*, 2:379-85.
- Leger L, *et al.* (1974). Five to 25 years follow up after surgery for chronic pancreatitis in 148 patients. *Ann Surg*, 180:180-91.
- Lerut JP, *et al.* (1984). Pancreaticoduodenal resection surgical experience and evaluation of risk factors in 103 patients. *Ann Surg*, 1999:432-7.
- Lowenfels AB, *et al.* (1993). Pancreatitis and the risk of pancreatic cancer. International pancreatitis study group. *New Engl J Med*, 328:1433-7.
- Laukoisich PG. (1993). Function tests in the diagnosis of chronic pancreatitis. Critical evaluation. *Int J Pancreatol*, 14(1):9-20.
- Lin Y, *et al.* (2003). Nationwide epidemiological survey of chronic pancreatitis in Japan. *J Gastroenterol*, 35: 136-41.
- Moreno-Gonzales I, *et al.* (1982). Biliary and pancreaticoduodenal division by means of an isolated jejunal loop. *Br J Surg*, 69: 254.
- Mallet Guy PA. (1983). Late and very late results of resection of the nervous system in chronic relapsing pancreatitis. *Am J Surg*, 145:234.
- Maras WB, *et al.* (1995). Randomized trial of duodenum preserving pancreatic head resection versus pylorus preserving Whipple in chronic pancreatitis. *Ann Surg*, 221(4):350-8.
- Modlin IM, *et al.* (2002). The evolution of pancreatic therapy. International Hepato-pancreato-biliary Association, Indian chapter, single theme conference, p. 32-46.
- Makarewicz W, *et al.* (2003). Quality of life improvement after videothoroscopic in chronic pancreatitis patients: case control study. *World J Surg*, 27:906-11.
- Martin RF & Marion MD. (2007). Resectional therapy for chronic pancreatitis. *Surg Clin N Am*, 87:1461-75.
- Puestow CB, Gillesby WT. (1958). Retrograde surgical drainage of pancreas for chronic pancreatitis. *Arch Surg*, 76:898-906.
- Partington RF, Rochelle REL. (1960). Modified Puestow procedure for retrograde drainage of the pancreatic duct. *Ann Surg*, 152:1037-42.
- Pain JA, Knight MJ. (1989). Pancreaticogastrostomy: the preferred operation for pain. Pancreaticogastrostomy for chronic pancreatitis. *Am J Surg*, 157:315-7.
- Rumpf KD, Pichlmayr R. (1983). Eirie method Zur Chirurgischen behind lung der chronischen pancreatitis. *Die transduodenal pancreaticoplaslik. Chirurg*, 54:722-7.

- Rossi RL, et al. (1986). Segmental pancreatic auto-transplantation with pancreatic ductal occlusion after near total pancreatic resection for chronic pancreatitis. *Ann Surg*, 203:626.
- Rossi RL, et al. (1987). Pancreaticoduodenectomy in the management of chronic pancreatitis. *Arch Surg*, 122:416-20.
- Robles-Diaz G, et al. (1990). Chronic pancreatitis in Mexico city. *Pancreas*, 5:479-83.
- Reila A, et al. (1992). Increasing incidence of pancreatic cancer among women in Olmsted Country, Minnesota, 1940 through 1988. *Mayo Clin Proc*, 67:839-45.
- Ramesh H, Augustine P. (1992). Surgery in tropical pancreatitis: analysis of risk factors. *Br J Surg*, 79:544-9.
- Sarles H. Pancreatitis. In: Symposium of Marseille 1963. Basel, Switzerland: Karger; 1965.
- Shires III GT, et al. (1986). Denervated splenopancreatic flap for chronic pancreatitis. *Ann Surg*, 203:568.
- Sarner M, Cotton PB. (1984). Definitions of pancreatitis. *Gut*, 24:756-9.
- Sota JA, et al. (1995). MR cholangiopancreatography findings on 3D fast spin echo imaging. *AJR Am J Roentgenol*, 165(6):1397-401 [medline].
- Seiler CA, et al. (2005). Randomized clinical trial of pylorus-preserving duodenopancreatectomy versus classical Whipple resection – long term results. *British Journal of Surgery*, 92 (5) : 547–556,
- Schnelldorfer T, et al. (2007). Operative management of Chronic Pancreatitis: Long term results in 372 patients. *J Am Coll Surg*, 204:1039-1047.
- Samuel M, et al. (Oct 2010). Laparoscopic and da Vinci Robot-Assisted Total Pancreaticoduodenectomy and Intraportal Islet Autotransplantation: Case Report of a Definitive Minimally Invasive Treatment of Chronic Pancreatitis. *Pancreas*; 39(7): 1109-1111.
- Traverso LW, Longmire WP. (1978). Preservation of pylorus in pancreaticoduodenectomy. *Surg Gynecol Obstet*, 156:581-6.
- Traverso LW, Kozarek RA. (1997). Pancreaticoduodenectomy for chronic pancreatitis: anatomical selection criteria and subsequent long term outcome analysis. *Ann Surg*, 226:429-38.
- The Medifocus Guidebook on Chronic Pancreatitis (123 pages; last updated June 21, 2011).
- Udani PM, et al. (1999). Choice of surgical procedure for chronic pancreatitis. <<http://bhj.org/journal/1999:4102>>.
- Uranues S, et al. (2006). Laparoscopic resection of the pancreatic tail with splenic preservation. *The American Journal of Surgery*; 192(2): 257-261
- Watson K. (1944). Carcinoma of ampulla of Vater: successful radical resection. *Br J Surg*, 31:368-73.
- Withigen J, Frey CF. (1974). Islet concentration in the head, body, tail and uncinate process of the pancreas. *Ann Surg*, 179:412-8.
- Warren WD, et al. (1984). A denervated pancreatic flap for control of chronic pain in pancreatitis. *Surg Gynecol Obstet* 1984;159:581-6.
- Wani NA, et al. (2007). Is any surgical procedure ideal for chronic pancreatitis. *International Journal of Surgery*, 5:45-56.
- Yasuda H, et al. (1990). Resection of the head of the pancreas with preservation of biliary tract and duodenum. *J Biliary Tract Pancreas*, 11:967-73.
- Yakshe P. (2004). Chronic pancreatitis, e-medicine article last updated August 25.



Chronic Pancreatitis

Edited by Prof. David Sutherland

ISBN 978-953-51-0011-9

Hard cover, 138 pages

Publisher InTech

Published online 15, February, 2012

Published in print edition February, 2012

Chronic pancreatitis is a disease of diverse etiologies in which pain can be devastating, severely impairing quality of life, and treatment is a challenge. This book covers cutting edge basic science research and clinical diagnosis and treatment issues in chronic pancreatitis. Basic science chapters include studies on amelioration of chronic pancreatitis in rats by bone marrow derived mesenchymal cells; on gene therapy using HSV-Enkephalin to reduce fibrosis, inflammation and pain in a rats; and on pancreatic acinar and island neogenesis according to vascular and matrix dynamics of human and animal tissue. In regard to the clinical aspects, the role of endoscopic ultrasound in detecting the changes of chronic pancreatitis are addressed as well as the endoscopic treatment via duct drainage procedures or stone removal. Finally, the surgical options for chronic pancreatitis (there are well over 20 procedures) are extensively discussed, with a final chapter on total pancreatectomy and islet autotransplant to definitively remove the root cause of the pain with preservation of endocrine function. This book will be valued by basic scientists and clinicians striving to understand the mechanisms of pain in chronic pancreatitis and the treatment options in patients so afflicted.

How to reference

In order to correctly reference this scholarly work, feel free to copy and paste the following:

Fazl Q. Parray, Mehmood A. Wani and Nazir A. Wani (2012). Surgical Options for Chronic Pancreatitis, Chronic Pancreatitis, Prof. David Sutherland (Ed.), ISBN: 978-953-51-0011-9, InTech, Available from: <http://www.intechopen.com/books/chronic-pancreatitis/surgical-options-for-chronic-pancreatitis>

INTECH
open science | open minds

InTech Europe

University Campus STeP Ri
Slavka Krautzeka 83/A
51000 Rijeka, Croatia
Phone: +385 (51) 770 447
Fax: +385 (51) 686 166
www.intechopen.com

InTech China

Unit 405, Office Block, Hotel Equatorial Shanghai
No.65, Yan An Road (West), Shanghai, 200040, China
中国上海市延安西路65号上海国际贵都大饭店办公楼405单元
Phone: +86-21-62489820
Fax: +86-21-62489821

© 2012 The Author(s). Licensee IntechOpen. This is an open access article distributed under the terms of the [Creative Commons Attribution 3.0 License](#), which permits unrestricted use, distribution, and reproduction in any medium, provided the original work is properly cited.

IntechOpen

IntechOpen