

We are IntechOpen, the world's leading publisher of Open Access books Built by scientists, for scientists

4,800

Open access books available

122,000

International authors and editors

135M

Downloads

Our authors are among the

154

Countries delivered to

TOP 1%

most cited scientists

12.2%

Contributors from top 500 universities



WEB OF SCIENCE™

Selection of our books indexed in the Book Citation Index
in Web of Science™ Core Collection (BKCI)

Interested in publishing with us?
Contact book.department@intechopen.com

Numbers displayed above are based on latest data collected.

For more information visit www.intechopen.com



The Use of Ultrasonography in Conservative Management of Cervical Pregnancy

Bing Xu¹, Jo Kitawaki², Yuying Duan¹ and Jilian Ding³

¹*Department of Obstetrics and Gynecology,*

The Affiliated Hospital of Medical College, Qingdao University,

²*Department of Obstetrics and Gynecology, Kyoto Prefectural University of Medicine,*

³*Department of Obstetrics and Gynecology,*

Shanghai East Hospital Affiliated Tongji University,

²*Japan*

^{1,3}*P.R.China*

1. Introduction

Cervical pregnancy is defined as an implantation of a fertilized ovum in the cervical canal. It is a very rare and dangerous form of ectopic pregnancy. The incidence ranges from 1/2500 to 1/12,000 pregnancies, which accounts for approximately 0.15% of all ectopic pregnancies. Rapid crossing of the fertilized ovum through the endometrial cavity and the travel speed of the ovum could be the cause of cervical implantation. An unfertilized ovum may reach the cervical canal and implantation occurs. Although the etiology of cervical pregnancy is unclear, previous uterine procedures such as dilation and curettage (D & C) and cesarean section, pelvic inflammatory disease, use of an intrauterine device (IUD), and in vitro fertilization (IVF) are likely causative or contributing factors. Particularly, with the use of assisted reproductive technology in recent years, the incidence of cervical pregnancy is expected to rise.

Cervical pregnancy is characterized by profuse, even life-threatening hemorrhage, which may lead to an emergency hysterectomy. In cervical pregnancy, the trophoblastic tissue directly invades into the cervix which is predominantly composed of fibrous connective tissue, with only 15% of smooth muscle. Such a cervical environment cannot satisfy the needs of the growing ovum. Pregnancy may eventually terminate when invasion, erosion, or rupture of large vessels results in bleeding. Clinically, the patients present a history of amenorrhea followed by uterine bleeding without cramping pain.

Before the routine use of ultrasound in gynecologic care, cervical pregnancy is rarely diagnosed at early gestational age. Prior to late 1980s, clinical diagnosis of cervical pregnancy was usually made when curettage for misdiagnosed incomplete spontaneous abortion resulted in uncontrollable hemorrhage. Such a condition often presented with life-threatening hemorrhage that frequently required an emergent hysterectomy and even resulted in maternal death. To avoid heavy bleeding and preserve uterus it is crucial to obtain an early and accurate diagnosis. In recent years, the widespread use of high

resolution ultrasound, particularly of the transvaginal sonography, has enabled the early diagnosis of cervical pregnancy, thereby allowing the application of conservative measures for women who desire to preserve fertility and/or obviate hysterectomy. Treatments tend to be more conservative and minimally invasive. In various conservative measures for cervical pregnancy, ultrasonography has progressively become an indispensable tool in diagnosis, interventional guidance, follow-up monitoring and clinical outcomes assessment.

2. Diagnosis of cervical pregnancy

Transvaginal or transabdominal ultrasound has become a standard and indispensable tool in the diagnosis of cervical pregnancy. An ultrasound examination will reveal a gestational sac in a widened cervical canal, with the absence of a gestational sac in the uterus (Figures 1, 2 and 3). The diagnosis is commonly established according to the following criteria described by Hofmann and Timor-Tritsch:

1. Presence of gestational sac or placental texture dominantly within the cervix;
2. No evidence of intrauterine pregnancy;
3. Visualization of an endometrial stripe;
4. Hourglass uterine shape with ballooned cervical canal;
5. Sac with active cardiac motion below the internal os for viable pregnancy.

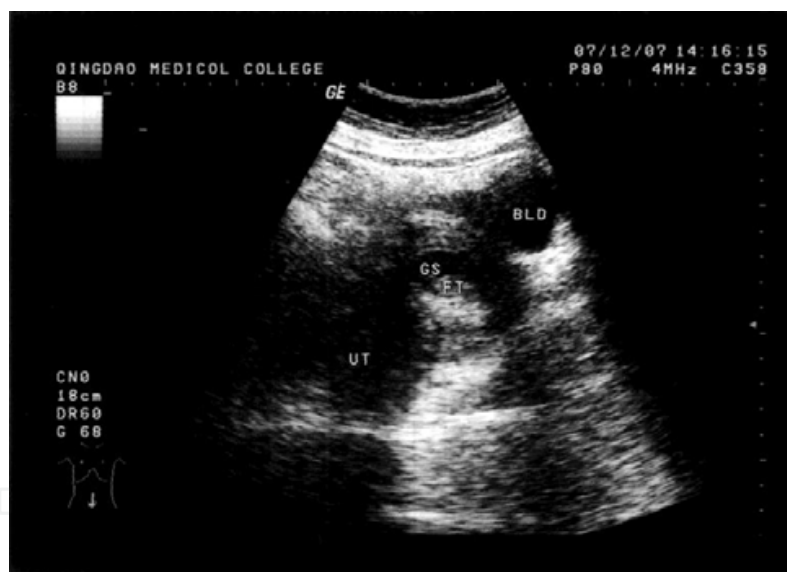


Fig. 1. Transabdominal ultrasound image of the cervical pregnancy. A 45-year-old woman, gravida 3, para 1 was admitted at 7 weeks and 5 days' gestation, presenting with a small amount of bloody vaginal discharge. Transabdominal sonography revealed normal-sized uterus with empty cavity. The gestational sac with a viable fetus is evident under the closed internal os. The β -hCG level was 59,313 mIU/L. UT: uterus; BLD: bladder; GS: gestational sac; FT: fetus

Ultrasound is used to localize and measure the gestational mass. Color Doppler imaging is applied to detect the blood flow of the gestational mass and surrounding tissues (Figure 4A and 4B). For the cases with acute bleeding or the cases that have been treated improperly with misdiagnosis, the combination use of transvaginal and transabdominal ultrasound will

supply more accurate information. Besides, serum β -hCG value is important for the diagnosis and assessment of treatment effect. A cautious vaginal speculum examination should be performed when the patient's physical condition permits.

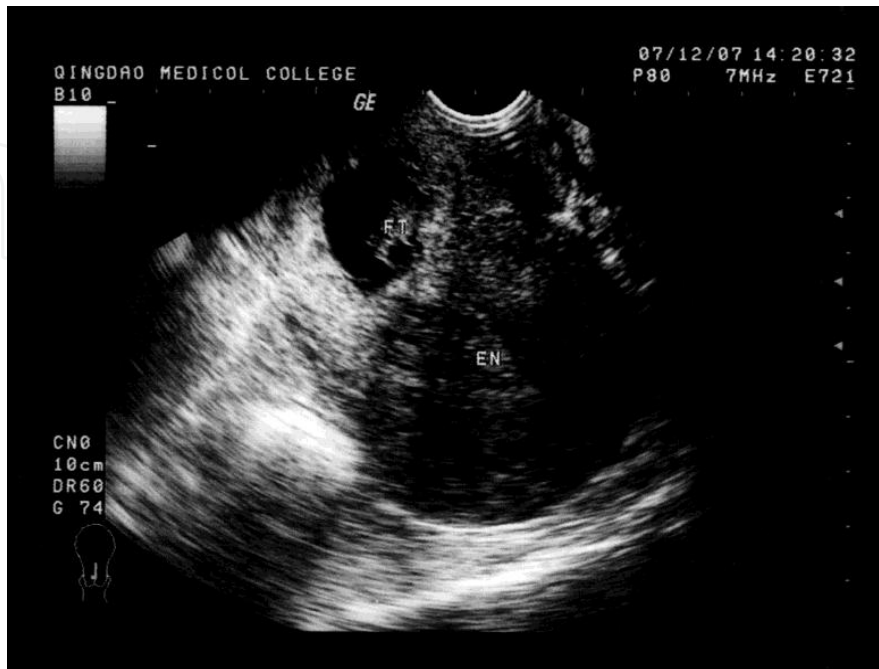

Fig. 2. Tranvaginal ultrasound image of the cervical pregnancy. The same case as described in Figure 1. An empty cavity of uterus with a 35 mm gestational sac containing fetal cardiac activity is evident under the closed internal os. EN: endometrium; FT: fetus

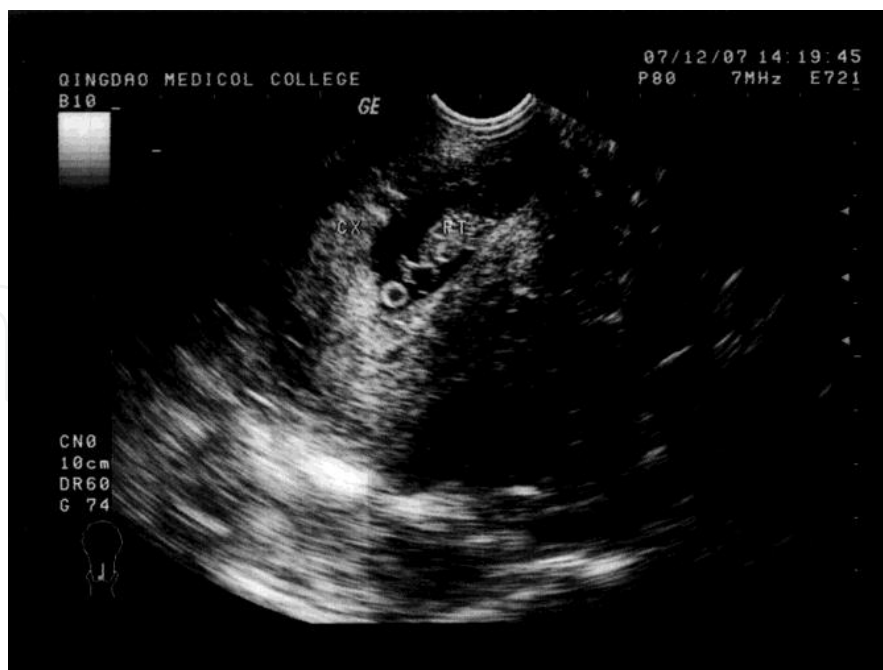

Fig. 3. Tranvaginal ultrasound image of the cervical pregnancy. The same case as described in Figure 1. An enlarged cervix with a viable fetus in a gestational sac is evident under the closed internal os. CX: cervix; FT: fetus

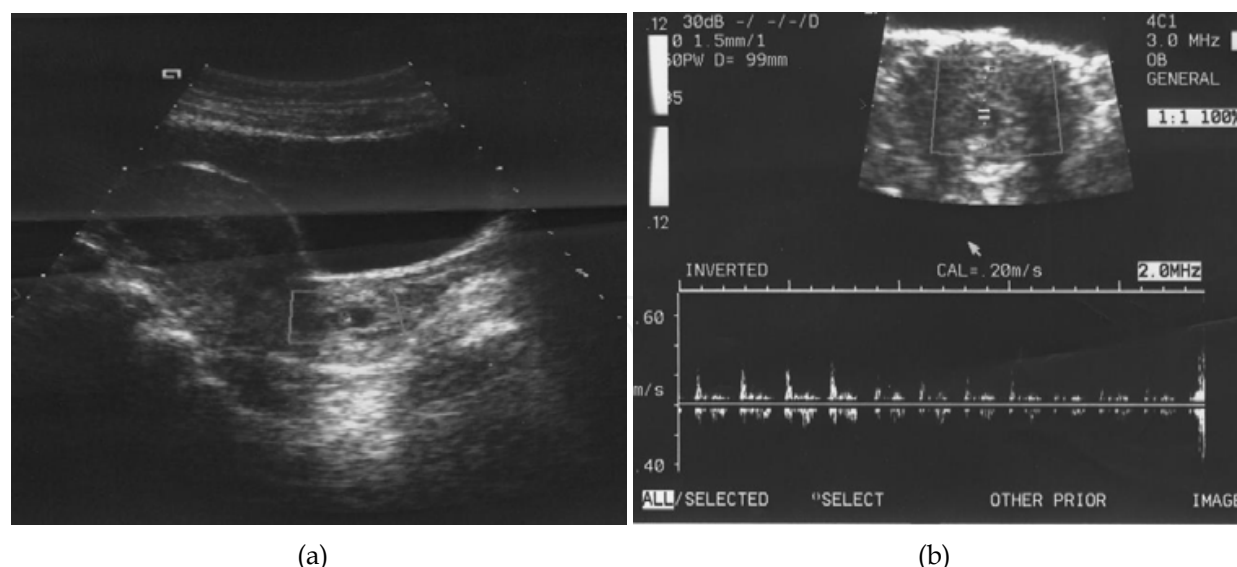


Fig. 4. (a) Ultrasonographic scan of a case of cervical pregnancy. The gestational sac is evident under the closed internal os. (b) Doppler flow velocimetry depicting fetal cardiac activity. (Xu, et al. J Obstet Gynaecol Res. 2007;33:190-4)

2.1 Differential diagnosis of cervical pregnancy

The differential diagnosis of a cervical pregnancy includes other possible abnormal implantations, such as cesarean scar, low uterine corpus and abortion in progression pregnancies.

Caesarean scar pregnancy

A cesarean scar pregnancy is a gestation separated from the endometrial cavity and completely surrounded by the myometrium and the fibrous tissue of the scar. It is also a very rare form of ectopic pregnancy. However, with the caesarean deliveries increased all over the world, the incidence is rising in recent years. The most possible mechanism of cesarean scar pregnancy is because the invasion of the myometrium through a microscopic tract. The microscopic tract is believed to develop from trauma from previous uterine surgeries like caesarean section, myomectomy, and dilatation and curettage. Early diagnosis can promptly offer treatment options to decrease the likelihood of uterine rupture and heavy bleeding. Therefore, it is important to suspect the possibility of scar pregnancy when the gestational sac is found at the level of the uterine isthmus in a patient with a previous caesarean section. Transvaginal ultrasonography combined with Doppler is a reliable tool for diagnosis. Ultrasound imaging presents a gestational sac located in the anterior uterine wall at the isthmus (Figure 5).

Spontaneous abortion in progress

Differentiation from a spontaneous abortion of an early pregnancy can be accomplished by the shape of the uterus, which is generally globular in an intrauterine pregnancy, as well as by the absence of a "sliding sign," where an aborted gestational sac slides against the endocervical canal in response to gentle pressure by the sonographer. On transvaginal scan the gestational sac should be seen in the cervical canal and the sac should appear avascular, reflecting the fact that the sac has been detached from its implantation site.

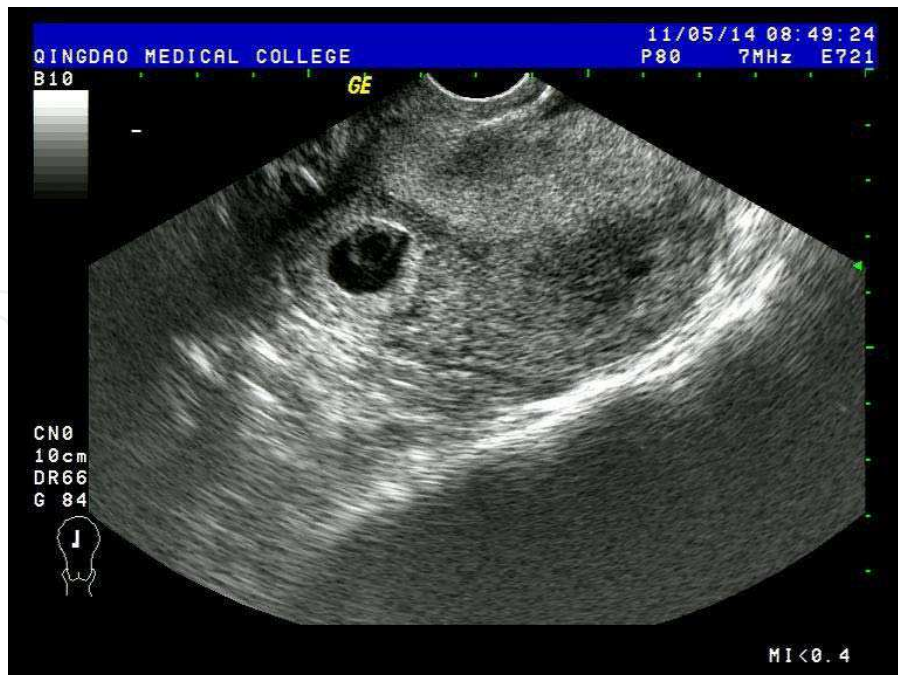

Fig. 5. Transvaginal ultrasound image of a cesarean scar pregnancy. Transvaginal scan revealed a 26 mm gestational sac with fetal pole outside the lower uterine cavity at the level of the isthmus in the anterior uterine wall

Low uterine corpus pregnancy

Low uterine corpus pregnancy should be differentiated from cervical pregnancy. The implantation usually takes place in the lower part of the cavity of the uterus. The gestational sac is located above the internal os of the cervix (Figure 6).

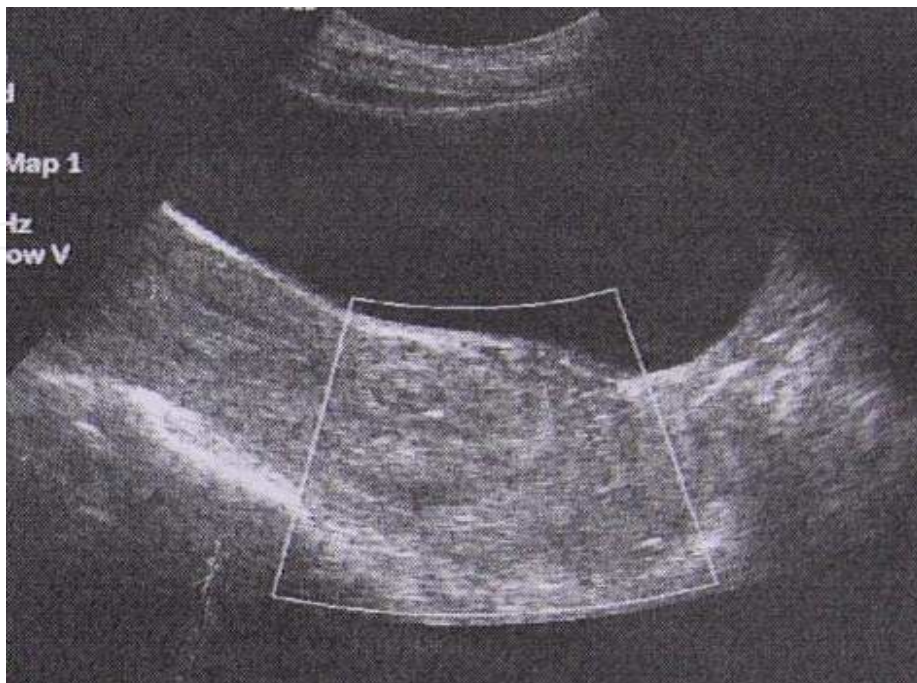


Fig. 6. Transabdominal ultrasound image of pregnancy in low uterine corpus

3. Conservative treatments of cervical pregnancy

The treatment options for cervical pregnancy largely depend on the severity of vaginal bleeding, gestational age, initial serum hCG levels, absence or presence of fetal heartbeat, and the woman's desire to preserve fertility and/or to obviate hysterectomy. Treatments tend to be more conservative and minimally invasive in recent years. Hysterectomy is performed only as a radical treatment in cases of intractable hemorrhage.

Various conservative treatments have been reported previously, such as local or systemic administration of methotrexate (MTX), Foley catheter tamponade, curettage and local prostaglandin injection, cervical cerclage and intra-cervical injections of vasoconstricting agents, laparoscopy-assisted uterine artery ligation combined with hysteroscopic endocervical resection, angiographic uterine artery embolization (UAE). These procedures are used either alone or in combination. However, there is no consensus to date about the best approach mainly due to a lack of evidence derived from large series of clinical cases. Moreover, a risk of hemorrhage accompanies all options available.

UAE has been widely used as a highly effective technique for treating cervical pregnancy. However, recent studies indicate that rebleeding or delayed bleeding can occur after UAE. It is speculated that after complete occlusion of the uterine arteries by UAE, the extensive collateral circulation to the cervix will be established within hours. If the cervical pregnancy is not evacuated soon after UAE, some gestational tissues may remain alive and result in bleeding once again. We recently reported a promising conservative modality treatment--UAE followed by immediate curettage. We recommend this method for the cases with fetal cardiac activity, high serum hCG levels and late gestational age when fertility capacity is desired. The procedure is performed as the following: the UAE procedure is performed using digital subtraction angiography. After the bilateral arteries embolization is confirmed, an experienced gynecologist performed vacuum evacuation and curettage of the cervical canal under ultrasound guidance. After the procedure, vaginal bleeding is closely monitored for at least 48 hours. Outpatient follow-up, including sonographic examinations and β -hCG measurements are performed routinely twice in the first week after the procedure, and then once a week until decreased to normal range. After follow-up, the UAE and curettage technique, complications, vaginal bleeding, the changes of serum hCG level, regression of the uterine cervical mass, recovery of menses, pregnancy and pregnancy outcome are evaluated for the assessment of clinical outcomes. Of the patients treated by this method, quick regression of serum hCG level and cervical mass, fertility preservation, and a short hospital stay are observed.

4. Ultrasound guidance during medical and surgical intervention

During the medical or surgical intervention, ultrasound is used to accurately locate the gestational mass and guide medical injection. Direct injection of potassium chloride (KCl) or MTX into the gestational sac or fetal heart under ultrasound guidance is often used to kill embryo and destruct trophoblast tissues in cervix. It has been proved effective in clinical practice. Combined medical treatment with UAE has been proved to reduce the risk of bleeding. Local injection of prostaglandin and vasoconstricting agents are reported to effectively reduce bleeding. In the recently reported new treatment modality--UAE followed

by immediate curettage, under ultrasound guidance an experienced gynecologist performs vacuum evacuation and curettage of the cervical canal immediately after the bleeding is controlled by the bilateral arteries embolization. With a special emphasis on the clinical outcome, an advantage of this procedure is to complete bleeding control and evacuate gestational tissue in one step, which can lead to a quick recovery.

5. Ultrasound examination in follow-up and clinical outcomes assessment

After the medical or surgical treatment, the vaginal bleeding, the changes of serum hCG level and regression of the uterine cervical mass should be closely monitored. The clinical outcome assessment should be made. Thus, serial sonographic examinations and β -hCG measurements are required in follow-up routinely until cervical contour is recovered to a normal shape on sonogram and gynecological examination, serum β -hCG is reduced to undetectable, and normal menstrual cycle returns. In our previous report, a case of cervical pregnancy treated with UAE only presented intermittent vaginal bleeding again although serious bleeding was successfully controlled by UAE. The ultrasound images consistently revealed a heterogeneous mass in the cervix (Figure 7).

By contrast, in the patients treated by UAE followed by immediate curettage, a quick regression of cervical mass and serum hCG level, fertility preservation and a short hospital stay are observed (Figure 8).

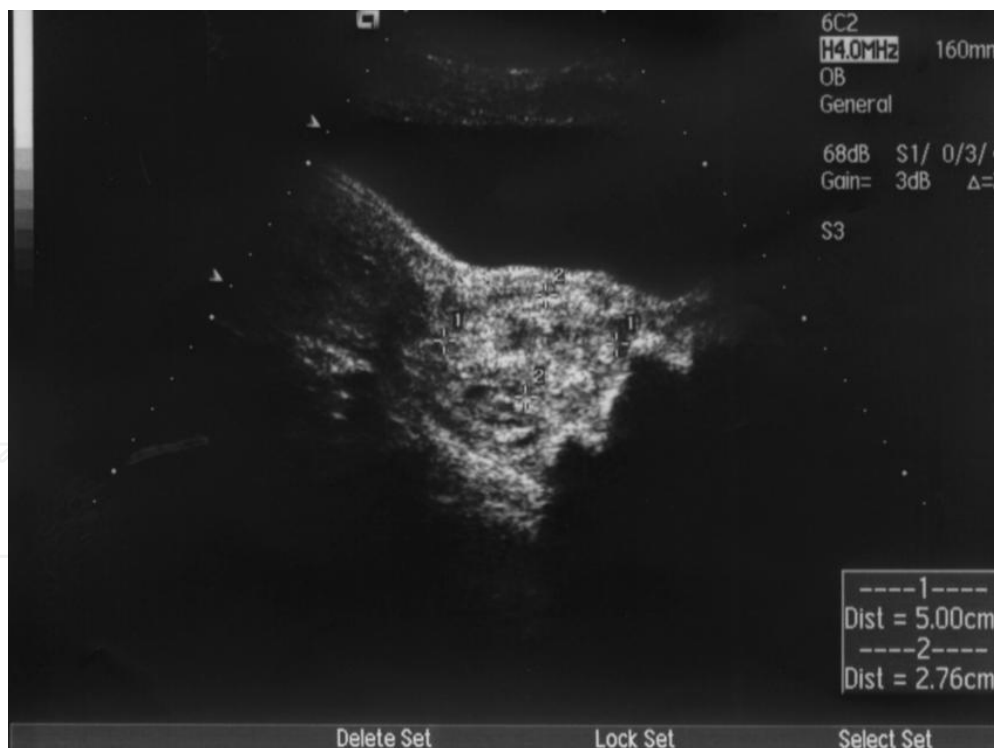


Fig. 7. A failure case of cervical pregnancy treated by UAE only. The sonography consistently revealed a heterogeneous mass in the cervix although serious bleeding was successfully controlled by UAE. The patient presented intermittent vaginal bleeding again. The patient underwent second UAE followed by immediate curettage and obtained complete solution. (Xu, et al. J Obstet Gynaecol Res. 2007;33:190-4)

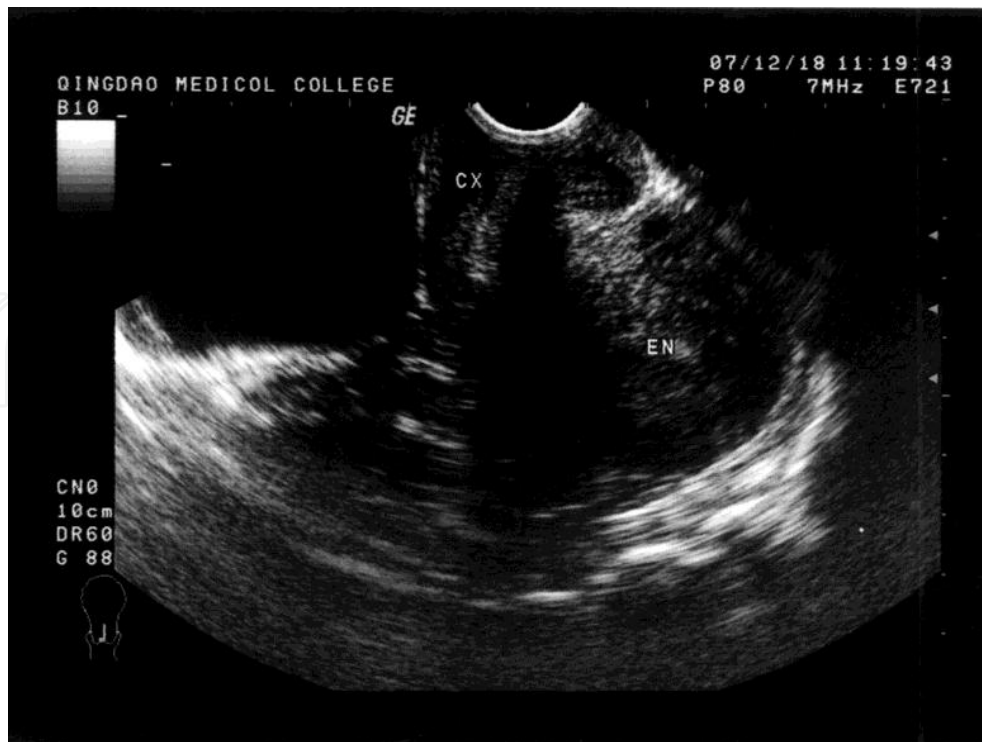


Fig. 8. Tranvaginal ultrasound image of the cervical pregnancy after treatment. The same case as described in Figure 1. Eight days after treatment by UAE followed by curettage, the cervix recovered to normal in contour

6. Conclusion

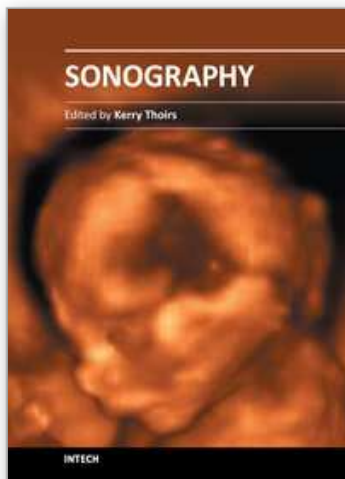
Cervical pregnancy is a very rare and dangerous form of ectopic pregnancy. It is characterized by profuse, even life-threatening hemorrhage, which may lead to an emergency hysterectomy. Recent widespread use of high-resolution ultrasound has enabled the early and accurate diagnosis of cervical pregnancy, thereby allowing the application of conservative measures for women who desire to preserve fertility. In various conservative measures for cervical pregnancy, ultrasonography has progressively become an indispensable tool in diagnosis, interventional guidance, follow-up monitoring and clinical outcomes assessment.

7. References

- [1] Ushakov, FB, Elchalal U, Aceman PJ, Schenker JG. Cervical pregnancy: past and future. *Obstet Gynecol Surv* 1997;52:45-59.
- [2] Frates MC, Benson CB, Doubilet PM et al. Cervical ectopic pregnancy: results of conservative treatment. *Radiology* 1994; 191: 773-5.
- [3] Sherer DM, Dalloul M, Santoso P et al. Complete abortion of a nonviable cervical pregnancy following methotrexate treatment. *Am J Perinatol* 2004; 21: 223-6.
- [4] Hofmann HM, Urdl W, Höfler H, Hönigl W, Tamussino K. Cervical pregnancy: case reports and current concepts in diagnosis and treatment. *Arch Gynecol Obstet.* 1987;241:63-9.

- [5] Timor-Tritsch IE, Monteagudo A, Mandeville EO et al. Successful management of viable cervical pregnancy by local injection of methotrexate guided by transvaginal ultrasonography. *Am J Obstet Gynecol* 1994; 170: 737-9.
- [6] Gun M, Mavrogiorgis M. Cervical ectopic pregnancy: a case report and literature review. *Ultrasound Obstet Gynecol* 2002;19:297-301.
- [7] Jurkovic D, Hackett E, Campbell S. Diagnosis and treatment of early cervical ectopic pregnancy: a review and report of two cases treated conservatively. *Ultrasound Obstet Gynecol* 1996;8:373-80.
- [8] Sherer DM, Lysikiewicz A, Abulafia O. Viable cervical pregnancy managed with systemic Methotrexate, uterine artery embolization, and local tamponade with inflated Foley catheter balloon. *Am J Perinatol* 2003; 20: 263-7.
- [9] Spitzer D, Steiner H, Graf A et al. Conservative treatment of cervical pregnancy by curettage and local prostaglandin injection. *Hum Reprod* 1997;12:860-6.
- [10] Davis LB, Lathi RB, Milki AA, Dahan MH. Transvaginal ligation of the cervical branches of the uterine artery and injection of vasopressin in a cervical pregnancy as an initial step to controlling hemorrhage: a case report. *J Reprod Med.* 2008;53:365-8.
- [11] Kung FT, Lin H, Hsu TY, Chang CY, Huang HW, Huang LY, Chou YJ, Huang KH. Differential diagnosis of suspected cervical pregnancy and conservative treatment with the combination of laparoscopy-assisted uterine artery ligation and hysteroscopic endocervical resection. *Fertil Steril.* 2004;81:1642-9.
- [12] Trambert JJ, Einstein MH, Banks E, Frost A, Goldberg GL. Uterine artery embolization in the management of vaginal bleeding from cervical pregnancy: a case series. *J Reprod Med.* 2005 ;11:844-50.
- [13] Cosin JA, Bean M, Grow D et al. The use of methotrexate and arterial embolization to avoid surgery in a case of cervical pregnancy. *Fertil Steril* 1997;67:1169-71.
- [14] Vedantham S, Goodwin CS, McClucas B et al. Uterine artery embolization: an underused method of controlling pelvic hemorrhage. *Am J Obstet Gynecol* 1997; 176: 938-48.
- [15] Xu B, Wang YK, Zhang YH, Wang S, Yang L, Dai SZ. Angiographic uterine artery embolization followed by immediate curettage: an efficient treatment for controlling heavy bleeding and avoiding recurrent bleeding in cervical pregnancy. *J Obstet Gynaecol Res.* 2007;33:190-4.
- [16] Wang Y, Xu B, Dai S, Zhang Y, Duan Y, Sun C. An efficient conservative treatment modality for cervical pregnancy: angiographic uterine artery embolization followed by immediate curettage. *Am J Obstet Gynecol.* 2011 Jan;204(1):31.e1-7.
- [17] Nakao Y, Yokoyama M, Iwasaka T. Uterine artery embolization followed by dilation and curettage for cervical pregnancy. *Obstet Gynecol.* 2008;111:505-7.
- [18] Yu B, Douglas NC, Guarnaccia MM, Sauer MV. Uterine artery embolization as an adjunctive measure to decrease blood loss prior to evacuating a cervical pregnancy. *Arch Gynecol Obstet.* 2009;279:721-4.
- [19] Hajenius PJ, Roos D, Ankum WM, Van der Veen F. Are serum human chorionic gonadotropin clearance curves of use in monitoring methotrexate treatment in cervical pregnancy? *Fertil Steril.* 1998;70:362-5.
- [20] Akutagawa N, Nishikawa A, Saito T, Sagae S, Kudo R. Conservative vaginal surgery for cervical pregnancy. *BJOG.* 2001;108:888-9.

- [21] Ash S, Farrell SA. Hysteroscopic resection of a cervical ectopic pregnancy. *Fertil Steril*. 1996;66:842-4.
- [22] Suzumori N, Katano K, Sato T et al. Conservative treatment by angiographic artery embolization of an 11-week cervical pregnancy after a period of heavy bleeding. *Fertil Steril* 2003; 80:617-619.
- [23] Nappi C, D'Elia A, Di Carlo C et al. Conservative treatment by angiographic uterine artery embolization of a 12 week cervical ectopic pregnancy. *Hum Reprod*. 1999; 14: 1118-21.
- [24] Takano M, Hasegawa Y, Matsuda H et al. Successful management of cervical pregnancy by selective uterine artery embolization: a case report. *J Reprod Med* 2004; 49: 986-8.
- [25] Hirakawa M, Tajima T, Yoshimitsu K, Irie H, Ishigami K, Yahata H, Wake N, Honda H. Uterine artery embolization along with the administration of methotrexate for cervical ectopic pregnancy: technical and clinical outcomes. *AJR Am J Roentgenol*. 2009;192;6:1601-7.
- [26] Einarsson JI, Michel S, Young AE. Delayed spontaneous expulsion of a cervical ectopic pregnancy: a case report. *J Minim Invasive Gynecol* 2005; 12: 165-7.
- [27] Hidalgo LA, Peñafiel J, Chedraui PA. Management of cervical pregnancy: risk factors for failed systemic methotrexate. *J Perinat Med*. 2004;32:184-6.
- [28] Hung TH, Shau WY, Hsieh TT, Hsu JJ, Soong YK, Jeng CJ. Prognostic factors for an unsatisfactory primary methotrexate treatment of cervical pregnancy: a quantitative review. *Hum Reprod*. 1998;13:2636-42. Review.
- [29] Song MJ, Moon MH, Kim JA, Kim TJ. Serial transvaginal sonographic findings of cervical ectopic pregnancy treated with high-dose methotrexate. *J Ultrasound Med*. 2009;1:55-61.
- [30] Jeng CJ, Ko ML, Shen J. Transvaginal ultrasound-guided treatment of cervical pregnancy. *Obstet Gynecol*. 2007;5:1076-82.
- [31] Leeman L, Wendland C. Cervical ectopic pregnancy: diagnosis with endovaginal ultrasound examination and successful treatment with methotrexate. *Arch Fam Med* 2000;9:72-7.
- [32] Sherer DM, Lysikiewicz A, Abulafia O. Viable cervical pregnancy managed with systemic Methotrexate, uterine artery embolization, and local tamponade with inflated Foley catheter balloon. *Am J Perinatol* 2003; 20: 263-7.



Sonography

Edited by Dr. Kerry Thoirs

ISBN 978-953-307-947-9

Hard cover, 346 pages

Publisher InTech

Published online 03, February, 2012

Published in print edition February, 2012

Medical sonography is a medical imaging modality used across many medical disciplines. Its use is growing, probably due to its relative low cost and easy accessibility. There are now many high quality ultrasound imaging systems available that are easily transportable, making it a diagnostic tool amenable for bedside and office scanning. This book includes applications of sonography that can be used across a number of medical disciplines including radiology, thoracic medicine, urology, rheumatology, obstetrics and fetal medicine and neurology. The book revisits established applications in medical sonography such as biliary, testicular and breast sonography and sonography in early pregnancy, and also outlines some interesting new and advanced applications of sonography.

How to reference

In order to correctly reference this scholarly work, feel free to copy and paste the following:

Bing Xu, Jo Kitawaki, Yuying Duan and Jilian Ding (2012). The Use of Ultrasonography in Conservative Management of Cervical Pregnancy, *Sonography*, Dr. Kerry Thoirs (Ed.), ISBN: 978-953-307-947-9, InTech, Available from: <http://www.intechopen.com/books/sonography/the-use-of-ultrasonography-in-conservative-management-of-cervical-pregnancy>

INTECH
open science | open minds

InTech Europe

University Campus STeP Ri
Slavka Krautzeka 83/A
51000 Rijeka, Croatia
Phone: +385 (51) 770 447
Fax: +385 (51) 686 166
www.intechopen.com

InTech China

Unit 405, Office Block, Hotel Equatorial Shanghai
No.65, Yan An Road (West), Shanghai, 200040, China
中国上海市延安西路65号上海国际贵都大饭店办公楼405单元
Phone: +86-21-62489820
Fax: +86-21-62489821

© 2012 The Author(s). Licensee IntechOpen. This is an open access article distributed under the terms of the [Creative Commons Attribution 3.0 License](#), which permits unrestricted use, distribution, and reproduction in any medium, provided the original work is properly cited.

IntechOpen

IntechOpen