

# We are IntechOpen, the world's leading publisher of Open Access books Built by scientists, for scientists

**4,800**

Open access books available

**122,000**

International authors and editors

**135M**

Downloads

Our authors are among the

**154**

Countries delivered to

**TOP 1%**

most cited scientists

**12.2%**

Contributors from top 500 universities



**WEB OF SCIENCE™**

Selection of our books indexed in the Book Citation Index  
in Web of Science™ Core Collection (BKCI)

Interested in publishing with us?  
Contact [book.department@intechopen.com](mailto:book.department@intechopen.com)

Numbers displayed above are based on latest data collected.

For more information visit [www.intechopen.com](http://www.intechopen.com)



# Morphological Changes of Retinal Pigment Epithelial Detachment in Central Serous Chorioretinopathy

Ari Shinojima and Mitsuko Yuzawa

*Department of Ophthalmology, Surugadai Hospital of Nihon University  
Japan*

## 1. Introduction

Normal retinal tissue consists of the nine-layer sensory retina on the vitreous side and one-layer retinal pigment epithelium on the choroidal side. Serous retinal detachment is a detachment of the sensory retina from the retinal pigment epithelium. Central serous chorioretinopathy (CSC) is a condition causing local serous neurosensory detachment in the macular region. CSC causes circular or oval serous retinal detachment. Spectral domain-optical coherence tomography (SD-OCT) is a useful tool for detecting morphological changes. Spectralis® HRA+OCT (Spectralis Heidelberg retina angiograph optical coherence tomography) uses a super-luminescent diode as the light source, which has a central wavelength of 870 nm. Scanning an object with two different wavelengths allows simultaneous display of the confocal scanning laser ophthalmoscopy (cSLO) image and the OCT image of a chosen plane. Therefore, it is possible to visualize the OCT image of a lesion depicted on angiography (fluorescein angiography or indocyanine green angiography) in the same location. The angiographic image of the structure or the lesion depicted on the OCT image can both be observed. Using Spectralis® HRA+OCT, we performed fluorescein angiography, indocyanine green angiography and OCT during the clinical course of acute central serous chorioretinopathy. We studied in detail the state of the retinal pigment epithelium at the leakage point, and the relations of the leakage point to both pigment epithelial detachment and moderately to highly reflective substances.

## 2. Central serous chorioretinopathy

In 1866, von Graefe described some of the clinical features of “relapsing idiopathic detachment of the macula”, since many reports of CSC were reported. There were a couple of reports about the pathological features of CSC, but they were reported in the era before the development of OCT. The characteristic finding in CSC is the formation of a localized neurosensory retinal detachment caused by leakage of fluid at the level of the retinal pigment epithelium. Although resolution of the serous exudation and restoration of central vision frequently takes place, some patients tend to relapse and develop permanent loss of vision. The age group affected most commonly is young adults between 30 to 50 years of age and particularly middle-aged men unilaterally; however, it can occur at 60 years of age

or older. The pathogenesis of CSC remains incompletely understood, although a variety of risk factors are associated with the development of the disorder. Psychopharmacologic medication use, corticosteroid use, and hypertension are reported to be associated with central serous chorioretinopathy (Tittl et al, 1999), but Kitzmann et al reported that there were no significant risk factors identified for CSC (Kitzmann, 2008). They found that the mean annual age-adjusted incidence per 100 000 was 9.9 (95% confidence interval (CI), 7.4-12.4) for men and 1.7 (95% CI, 0.7-2.7) for women. The incidence of CSC was approximately 6 times higher in men than in women ( $P < 0.001$ ). Median time from diagnosis to recurrence was 1.3 years (range, 0.4-18.2) (Kitzmann, 2008). The chief complaints of CSC patients are image distortion or a small central scotoma, visual disturbance or impaired color vision. In the acute stage, fluorescein angiography shows a focal leak at the level of the retinal pigment epithelium, and this focal leak gradually expands into the shape of a smokestack or an inkblot pattern. In CSC, the presence of damage to the retinal pigment epithelium blood-retinal barrier, with metabolic impairment of retinal pigment epithelium transport causes focal leakage. Indocyanine green angiography shows choroidal vascular abnormalities in CSC. In active CSC, indocyanine green angiography shows choroidal filling delay, venous dilation, and focal choroidal hyperfluorescence surrounding leakage from the retinal pigment epithelium. In CSC, the grayish white lesion seems to be fibrinous exudate that accumulates in the subretinal space on OCT. The fibrinous exudate sometimes appears as a ring-shaped area (Shinojima et al, 2010) (Fig. 1).

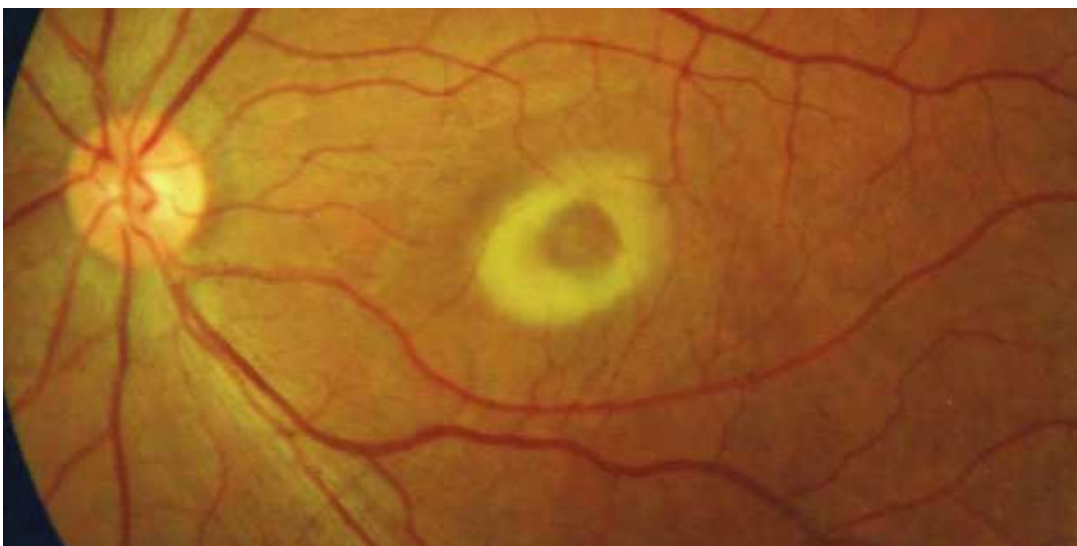

Fig. 1. Citation; Shinojima A, Hirose T, Mori R, Kawamura A, Yuzawa M. (2010). Morphologic findings in acute central serous chorioretinopathy using spectral domain-optical coherence tomography with simultaneous angiography. *Retina*, Figure 4.

## 2.1 Serous retinal detachment and pigment epithelial detachment in CSC

Retinal pigment epithelial detachment (PED) appears ophthalmoscopically as single or multiple, circumscribed, round or oval lesions within the posterior fundus.

There are various types of PED; serous PED, hemorrhagic PED, drusenoid PED and fibrovascular PED. Serous PED is often observed in CSC. A leakage point is often observed at PED in CSC, but some PED is not related to leakage. Recent reports describe many cases

of PED in CSC (Shinojima et al, 2010). A leakage point is often observed at PED in CSC. SD-OCT has allowed the detection of small or shallow PED, which was not previously possible (Fig. 2).

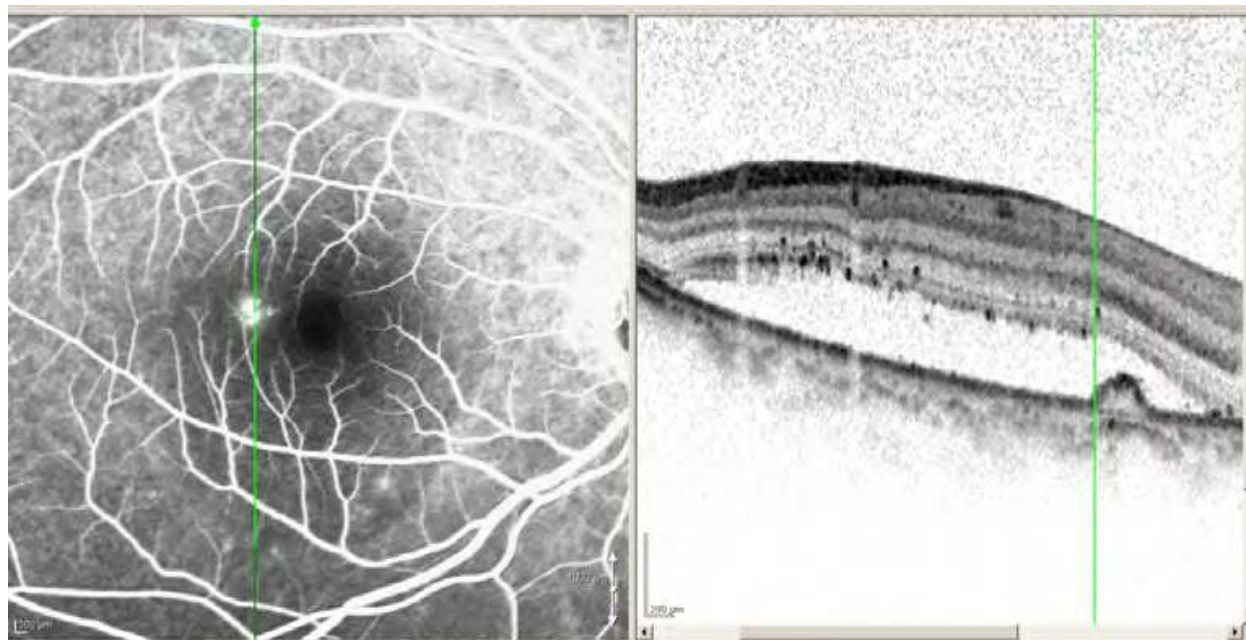


Fig. 2. Citation; Shinojima A, Hirose T, Mori R, Kawamura A, Yuzawa M. (2010). Morphologic findings in acute central serous chorioretinopathy using spectral domain-optical coherence tomography with simultaneous angiography. *Retina*, Figure 3. Simultaneous fluorescein angiography (left) and OCT photographs (right) were obtained in the early phase.

### 2.1.1 Morphological changes in PED

PED are often detected at leakage point in CSC. Fujimoto et al reported that among 23 leakage sites in 21 eyes, Fourier-domain OCT showed retinal pigment epithelium abnormalities in 22 (96%) sites (14 sites [61%] with a PED and 8 [35%] with a protruding or irregular retinal pigment epithelium layer). (Fujimoto et al, 2008). Shinojima et al reported that PED was recognized at 71% of leakage points in acute CSC (Shinojima et al, 2010), but sometimes PED is detected at other sites than the leakage point. In addition, SD-OCT with simultaneous cSLO enabled us to detect tiny PED by examining the area in proximity to the leakage point. We followed the changes in the PED for approximately one year.

### 2.1.2 Morphological changes in PED for approximately one year

Simultaneous photograph of fluorescein angiography and OCT in early phase (Fig. 3). Seven weeks after the onset of subjective symptoms, there is no serous retinal detachment at the PED in the supra-temporal region (white arrow). This PED was confirmed by fluorescein angiography, indocyanine green angiography and OCT findings. Fluorescein angiography showed pooling in the area (Figure 3). Yellow arrow indicates a smokestack pattern of leakage (left). Blue arrowheads indicate highly reflective substances just below the retinal pigment epithelium (right).

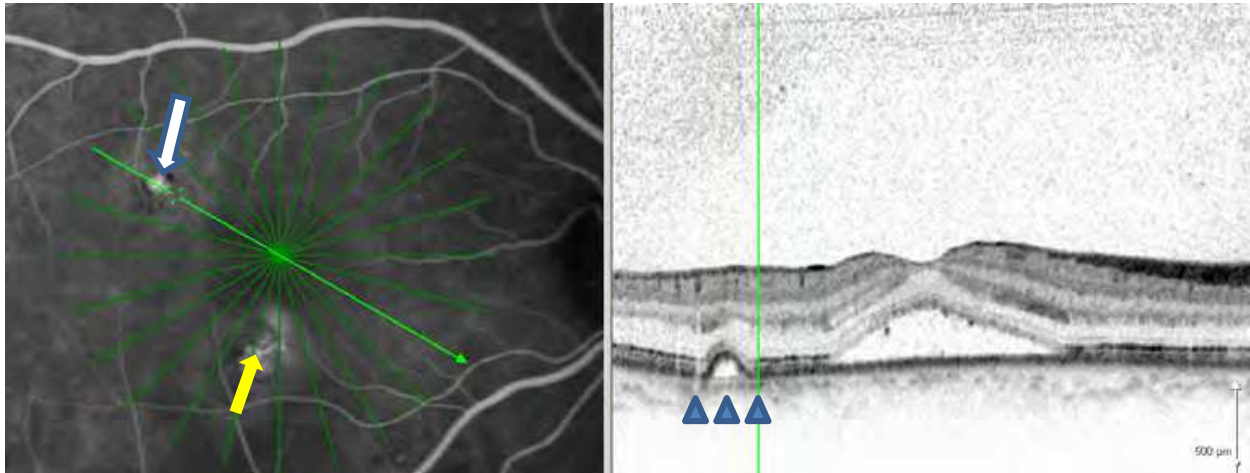


Fig. 3. PED without serous retinal detachment. Simultaneous fluorescein angiography (left) and OCT photographs (right) were obtained in the early phase.

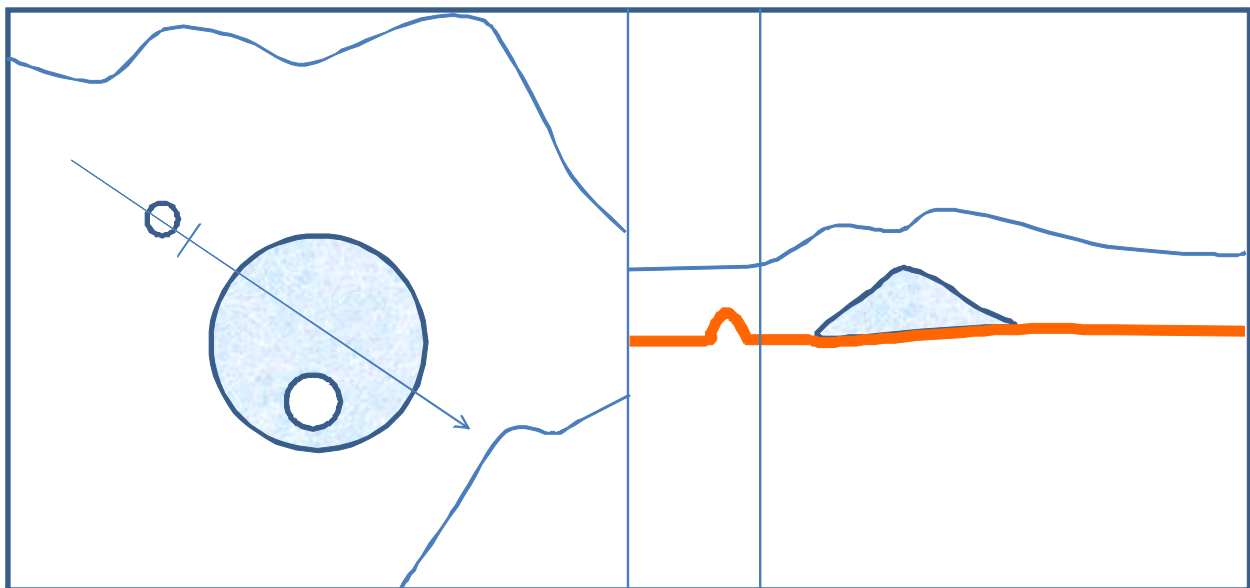


Fig. 4. Schema of Fig. 3. PED in the supra-temporal region without serous retinal detachment. Serous retinal detachment (light blue) and retinal pigment epithelium layer (orange line). There is no serous retinal detachment at the PED in the supra-temporal region.

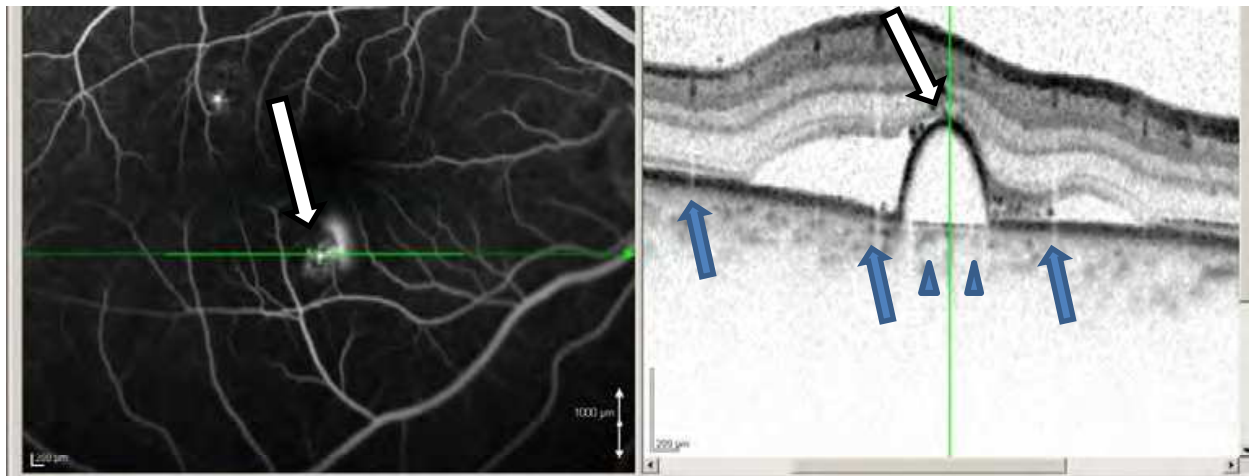


Fig. 5. Citation; Shinojima A, Hirose T, Mori R, Kawamura A, Yuzawa M. (2010). Morphologic findings in acute central serous chorioretinopathy using spectral domain-optical coherence tomography with simultaneous angiography. *Retina*, Figure 2. Seven weeks after the onset of subjective symptoms, i.e., at the same time as in Fig. 3. Simultaneous fluorescein angiography (left) and OCT photographs (right) were obtained in the early phase. The PED at the leakage point is below the sensory retina. White arrow indicates leakage point from pigment epithelial detachment. A smokestack pattern in the early phase and gradual, but increasingly marked, leakage are seen (left). The leakage point corresponds to the central part of the PED on OCT (right). Blue arrows indicate retinal vessel artifacts (right). Other OCT sections show focal serous separation, indicating one serous detachment. Blue arrowheads indicate highly reflective substances just below the retinal pigment epithelium.

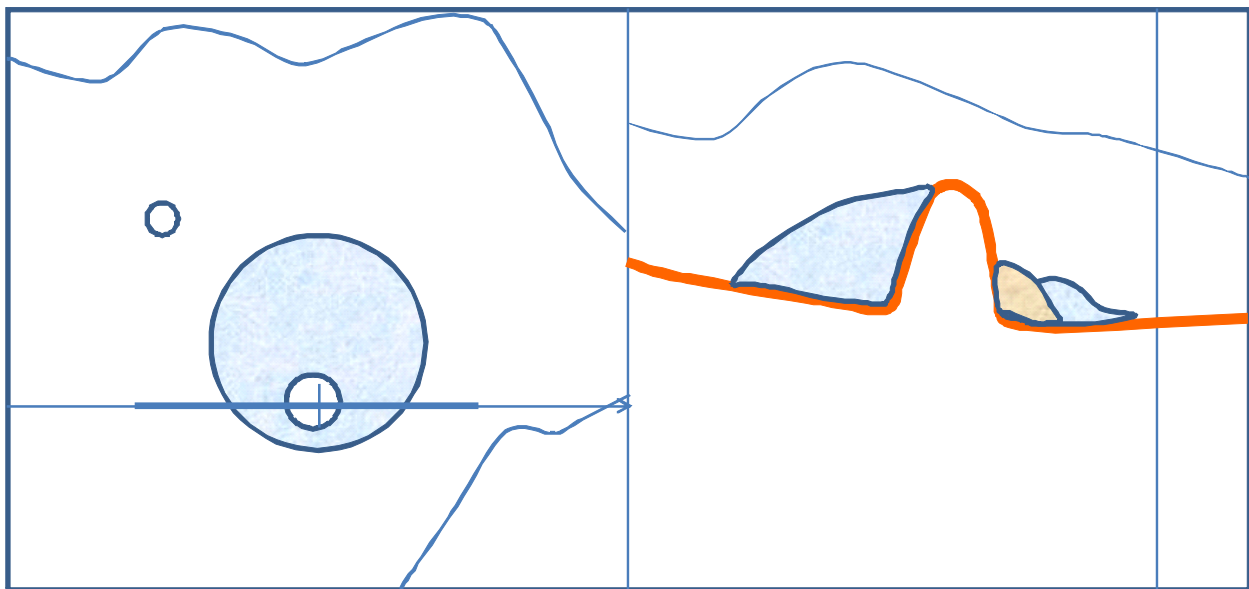


Fig. 6. Schema of Fig. 5. Serous retinal detachment (light blue), substances like fibrin (light brown) and retinal pigment epithelium layer (orange line). Retinal pigment epithelium layer (orange line) is continuous.

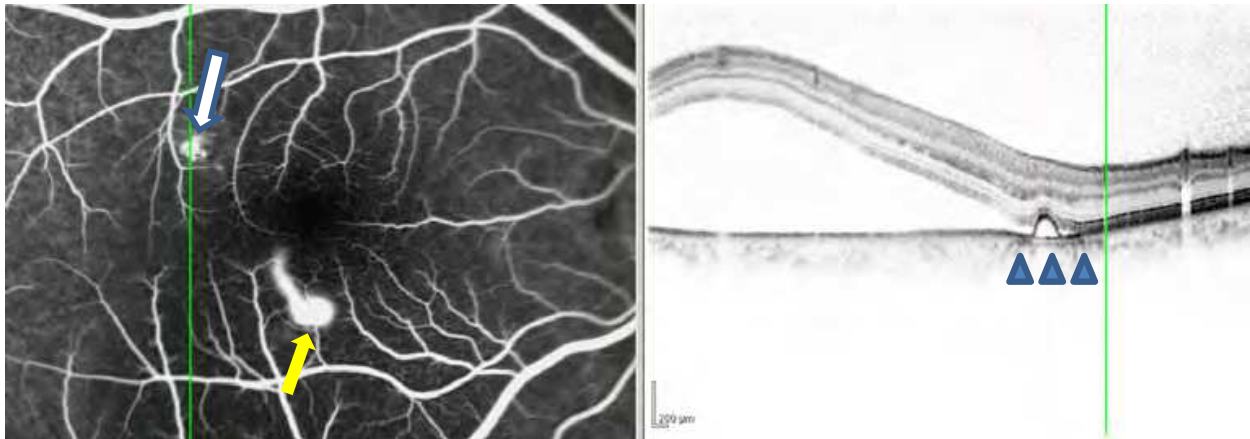


Fig. 7. PED under serous retinal detachment three months after onset. Simultaneous fluorescein angiography (left) and OCT photographs (right) were obtained in the early phase. Although SRD was not detected above PED in the supra-temporal region at seven weeks after the onset of subjective symptoms, as in Fig. 3, SRD slightly reached the PED in the supra-temporal region three months after the onset of subjective symptoms. Fluorescein angiography shows pooling (white arrow). Yellow arrow indicates a marked smokestack pattern of leakage. Blue arrowheads indicate highly reflective substances just below the retinal pigment epithelium.

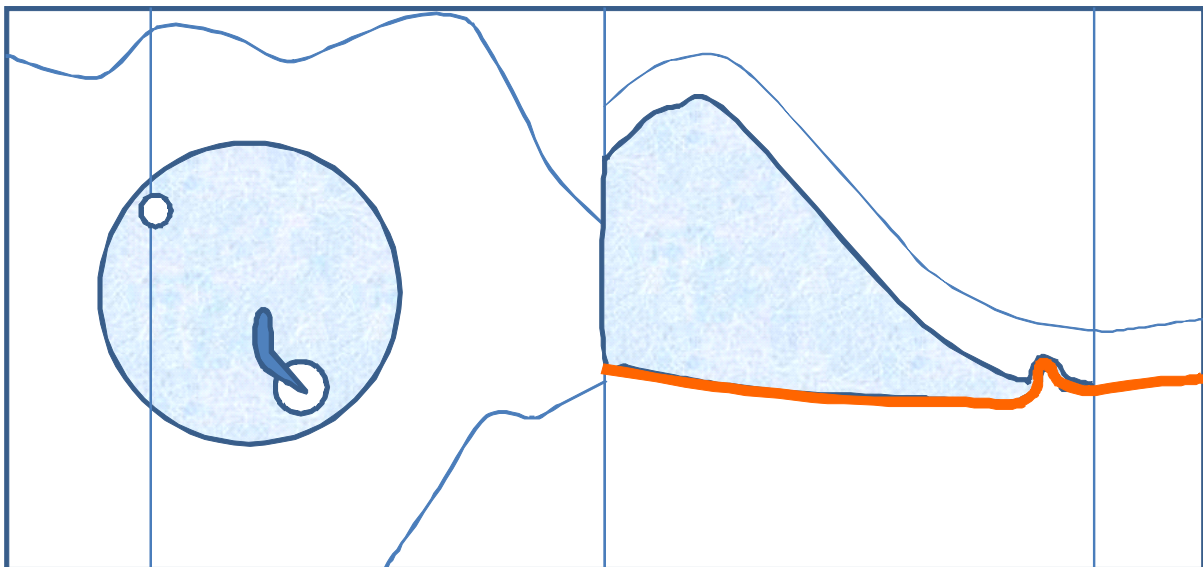


Fig. 8. Schema of Fig. 7. Serous retinal detachment (light blue), smoke-stack leakage (blue) and retinal pigment epithelium layer (orange line). Retinal pigment epithelium layer (orange line) is continuous.

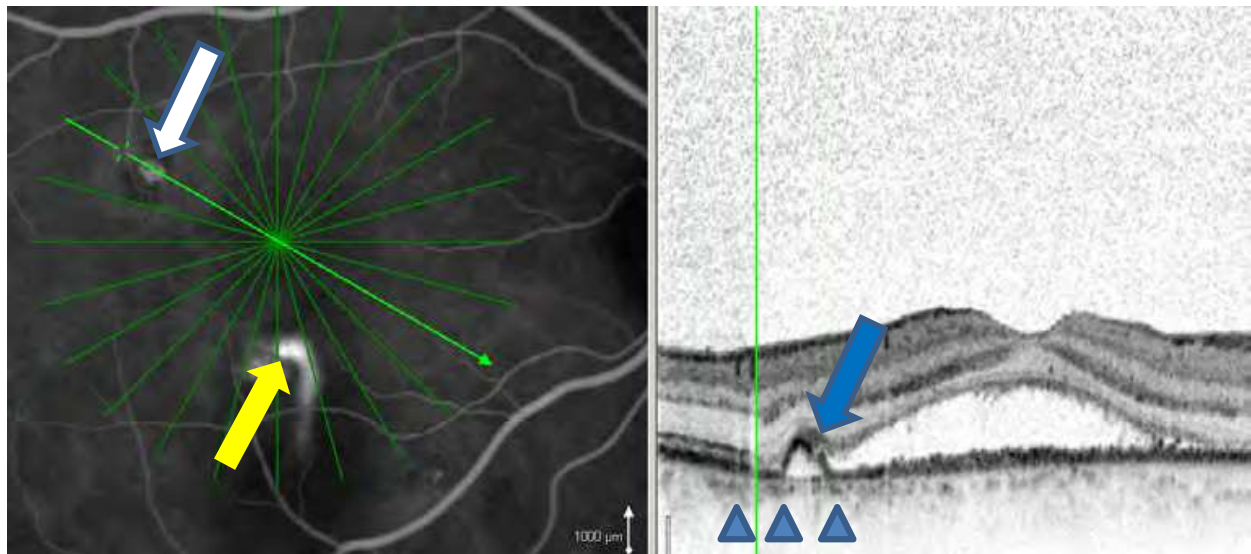


Fig. 9. Retinal pigment epithelium defect in PED. Five and a half months after the onset of subjective symptoms before photocoagulation. Simultaneous fluorescein angiography (left) and OCT photographs (right) were obtained in the early phase. Yellow arrow indicates leakage point. White arrow indicates PED (left). Blue arrow indicates a retinal pigment epithelium layer defect at PED. Blue arrowheads indicate highly reflective substances just below the retinal pigment epithelium (right). Other OCT sections show focal serous separation, indicating a serous detachment.

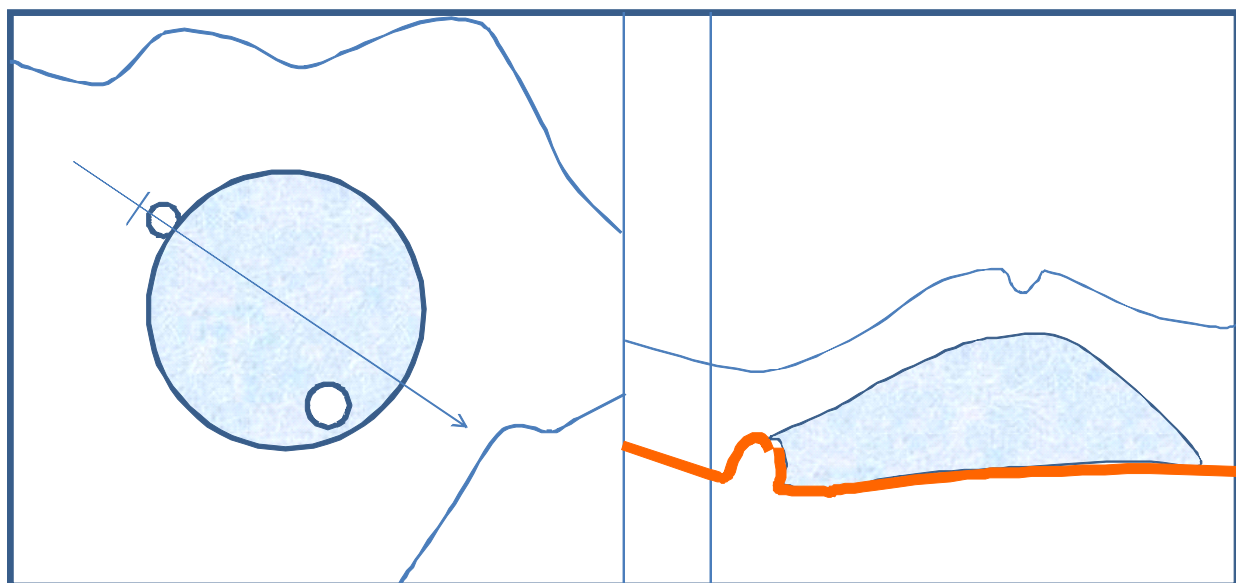


Fig. 10. Schema of Fig.9. Retinal pigment epithelium defect in PED. Serous retinal detachment (light blue) and retinal pigment epithelium layer (orange line). A retinal pigment epithelium defect (right) was detected at the PED in the supra-temporal region without leakage.

In the presence of damage to the retinal pigment epithelium blood-retinal barrier, subretinal fluid is rapidly cleared by passive forces. Thus, it is apparent that retinal pigment



epithelium defects do not by themselves cause serous retinal detachment (Marmor, 1988). This description by Marmor may explain our present findings. A retinal pigment epithelium defect was not detected at the prominent leakage point, as shown in Fig. 5.

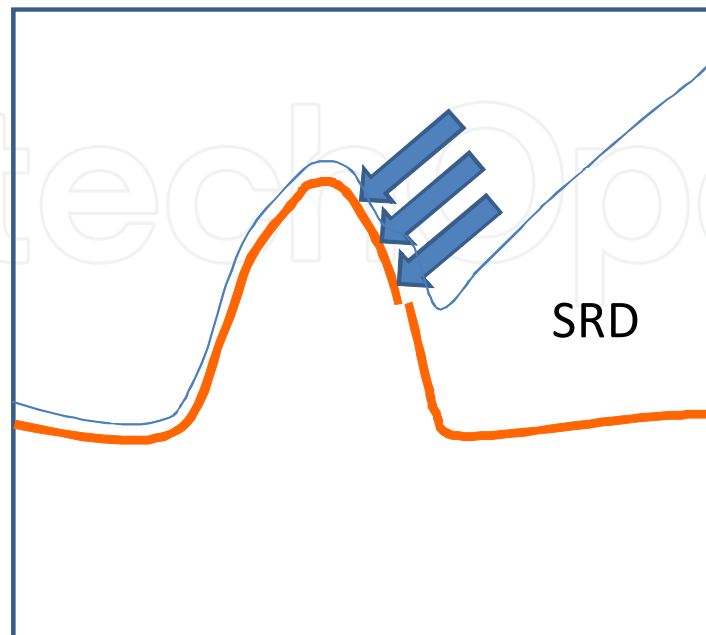


Fig. 11. Schema of Fig.9 about the PED in the supra-temporal region (Fig. 9 left, and Fig. 10 right). Retinal pigment epithelium layer (orange line) defect was detected at the PED in the supra-temporal region without leakage. It appears that PED is pushed by the neurosensory retina (blue arrow).

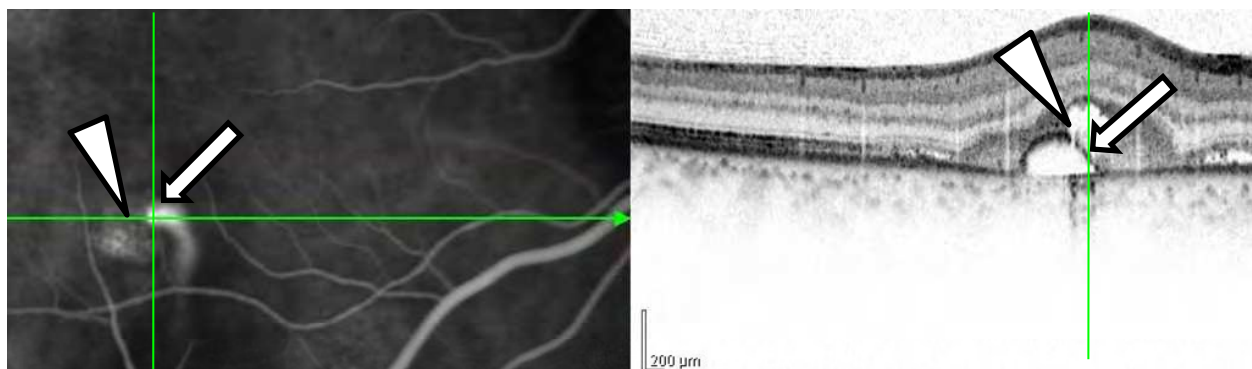


Fig. 12. Citation; Shinojima A, Hirose T, Mori R, Kawamura A, Yuzawa M. (2010). Morphologic findings in acute central serous chorioretinopathy using spectral domain-optical coherence tomography with simultaneous angiography. *Retina, Figure 2*. Five and a half months after the onset of subjective symptoms before photocoagulation. Simultaneous fluorescein angiography (left) and OCT photographs (right) were obtained in the early phase. This figure is the same part in Fig. 5. White arrow indicates leakage point from pigment epithelial detachment. A smoke stack pattern in the early phase and gradual leakage are seen. Highly reflective substances in the subretinal space and a retinal pigment epithelium defect (white arrowhead) can be seen at a point 50  $\mu\text{m}$  from the leakage point at 5.5 months after the onset of subjective symptoms. The RPE layer defect does not involve the inner/outer segment.

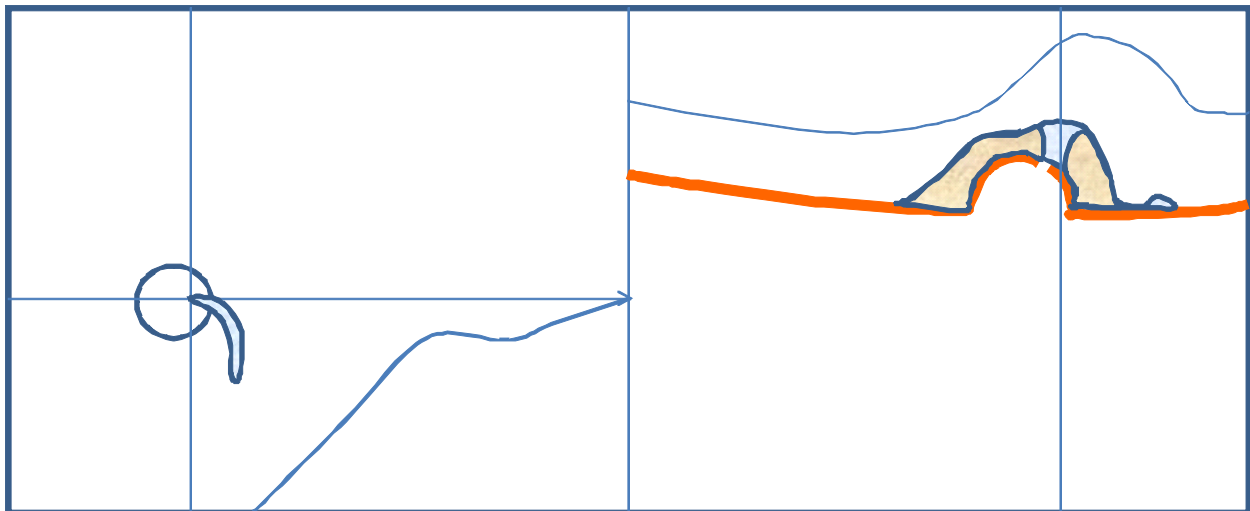


Fig. 13. Schema of Fig. 12. Serous retinal detachment (light blue), substances like fibrin (light brown) and retinal pigment epithelium layer (orange line). Highly reflective substances in the subretinal space (light brown) and a retinal pigment epithelium (orange line) defect can be seen at a point 50  $\mu\text{m}$  from the leakage point at 5.5 months after the onset of subjective symptoms.

The transverse resolution of Spectralis® HRA+OCT is 14  $\mu\text{m}$ , while the retinal pigment epithelium diameter in the macular region is 16  $\mu\text{m}$ . Therefore, it may not always be possible to discern a one-cell defect among a row of retinal pigment epithelium cells with this device. Most retinal pigment epithelium defects in CSC patients may be too small to be detected even by SD-OCT analysis. We also speculate that these minute defects cause minute focal leakage.

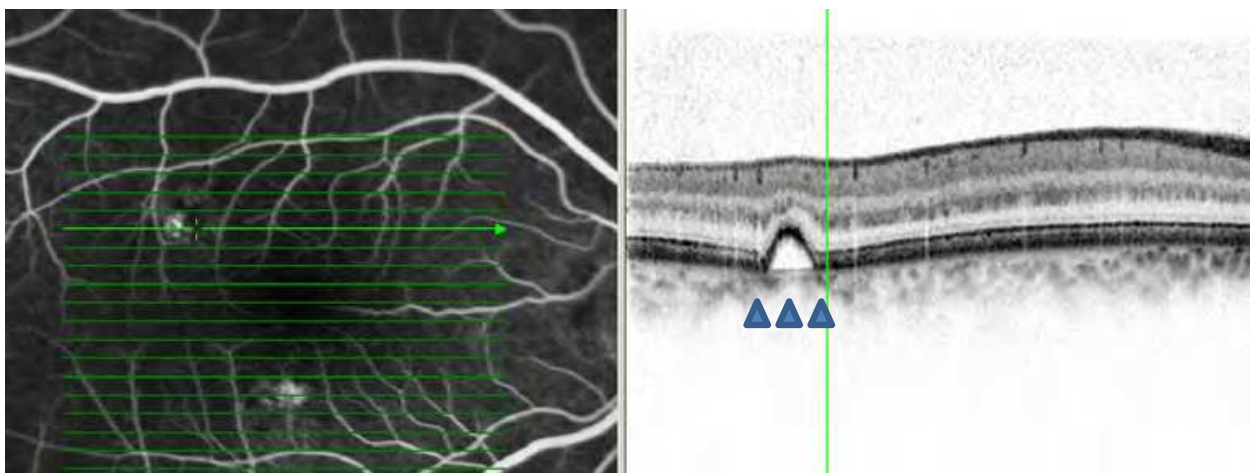


Fig. 14. PED after about 6 months after the photocoagulation. Simultaneous fluorescein angiography (left) and OCT photographs (right) were obtained in the early phase. The retinal pigment epithelium layer is continuous. Blue arrowheads indicate highly reflective substances just below the retinal pigment epithelium.

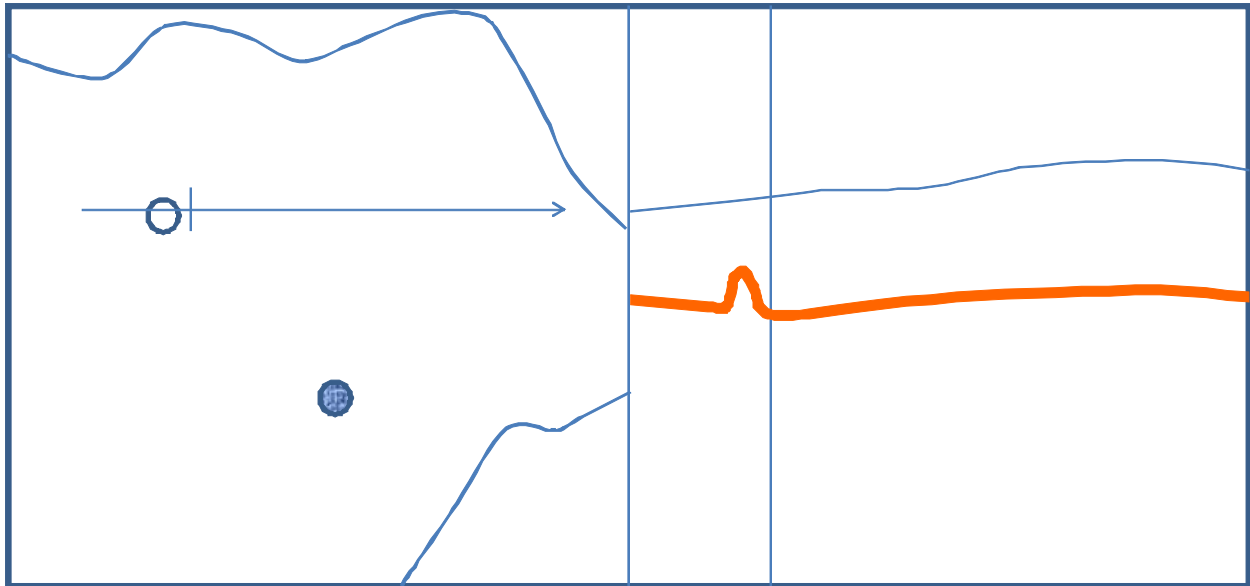


Fig. 15. Schema of Figure 14. about retinal pigment epithelium defect in PED. Retinal pigment epithelium layer (orange line) is continuous. No retinal pigment epithelial defect was detected at the PED in the supra-temporal region. Blue spot indicates the place after photocoagulation

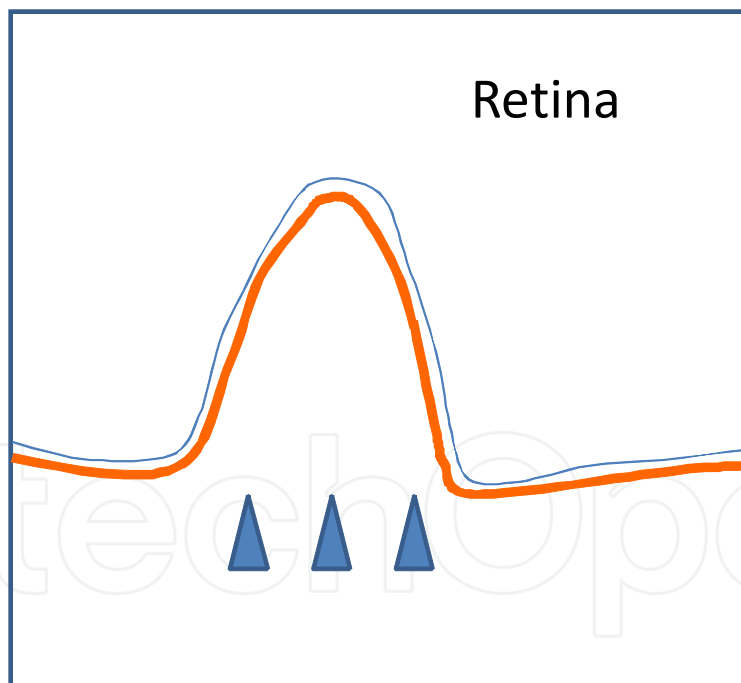


Fig. 16. Schema of Fig. 14 (right) about highly reflective substances below retinal pigment epithelium. The retinal pigment epithelium layer (orange line) is continuous. Blue arrowheads indicate highly reflective substances just below the retinal pigment epithelium.

The form of PED was maintained after reattachment. Highly reflective substances beneath the retinal pigment epithelium (blue arrowhead) undergo serous exudation secondary to congestion of choroidal venules, which may be the reason for maintenance of the formation of PED.

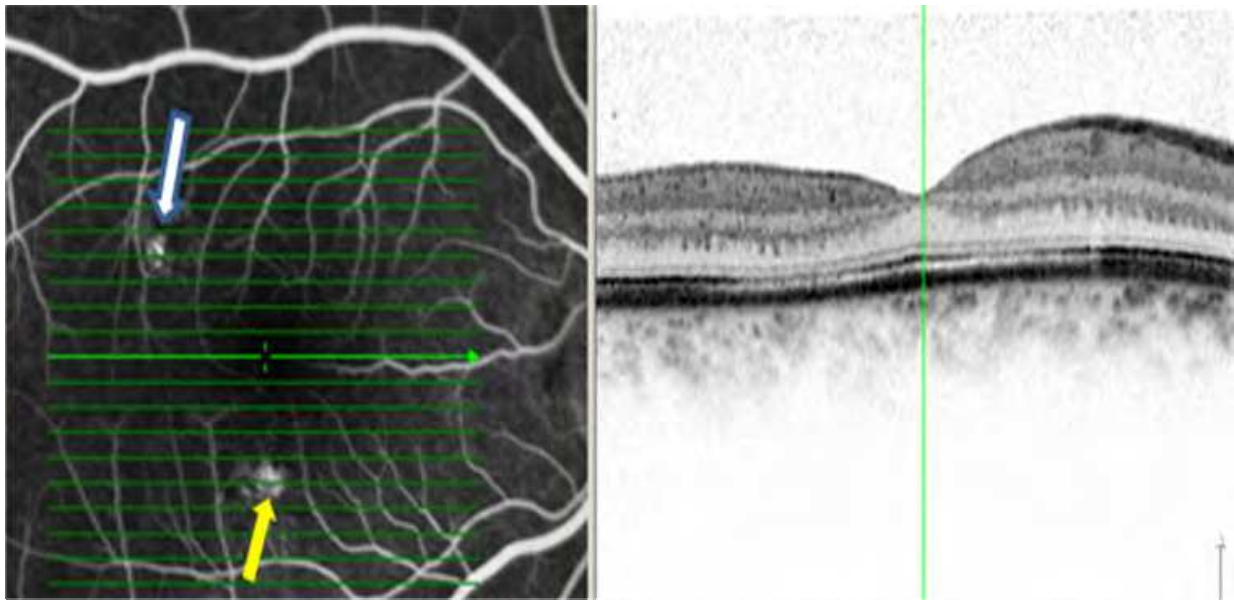


Fig. 17. Reattached serous retinal detachment about 6 months after photocoagulation. Simultaneous fluorescein angiography (left) and OCT photographs (right) were obtained in the early phase. The same time (6 months after photocoagulation) as in Fig. 14, serous retinal detachment has reattached through the fovea (fluorescein angiography +OCT). White arrow indicates PED. Yellow arrow indicates the place after photocoagulation where retinal pigment epithelium irregularities exist. A window defect was confirmed.

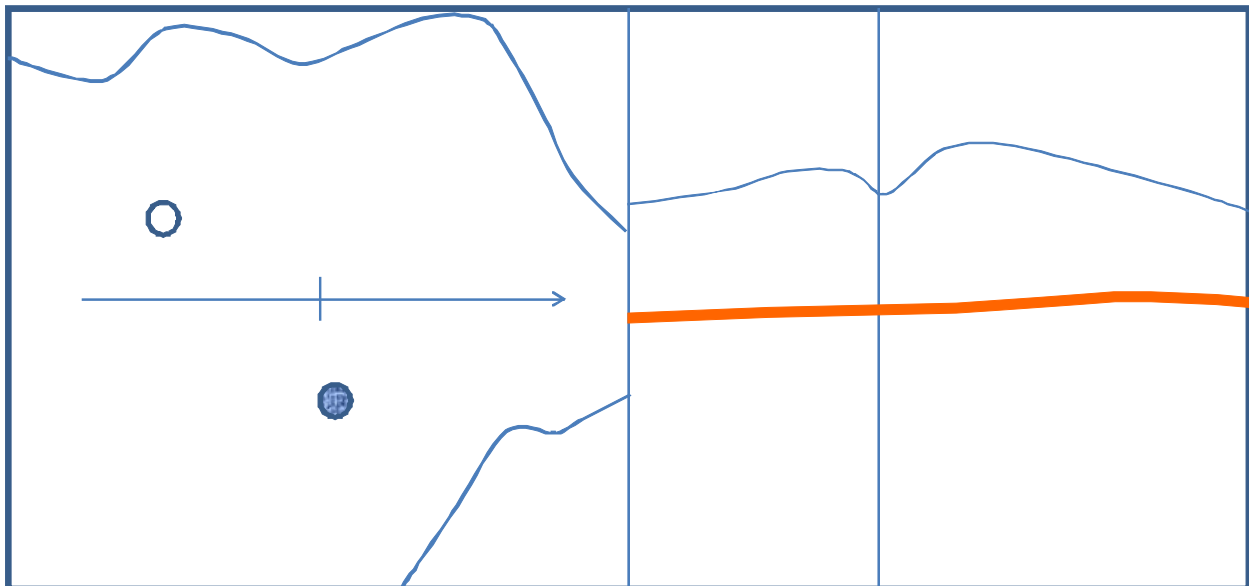


Fig. 18. Schema of Fig. 17. There is no serous retinal detachment through the fovea. The retinal pigment epithelium layer (orange line) is continuous. White spot in the supra-temporal region indicates PED and blue spot indicates the place after photocoagulation.

### 2.1.3 Laser photocoagulation in CSC


Photocoagulation of a leaking point can facilitate resolution of the fluid, but as long as the underlying metabolic dysfunction of the retinal pigment epithelium or choroidal hyperpermeability persists, recurrence is possible.

### 3. Conclusion

A retinal pigment epithelium defect at PED was detected 5.5 months after the onset of subjective symptoms. PED without leakage was restored after photocoagulation. On the other hand, PED with leakage lost its shape and changed into an RPE irregularity by local photocoagulation. Highly reflective substances may be related to PED formation. Even if a retinal pigment epithelium layer defect exists, leakage may not result. The sensory retina may compress damaged retinal pigment epithelium forming a PED, when a serous retinal detachment is reattached, and the PED may collapse morphologically.

### 4. References

- Fujimoto H, Gomi F, Wakabayashi T, Sawa M, Tsujikawa M, Tano Y. (2009). Morphologic changes in acute central serous chorioretinopathy evaluated by Fourier-domain optical coherence tomography. *Ophthalmology*, Vol. 115. No. 9, September 2009, pp. 1494-500, 1500.e1-2.
- Iida T, Hagimura N, Sato T, et al. (2000). Evaluation of central serous chorioretinopathy with optical coherence tomography. *Am J Ophthalmol*, Vol. 129. No.1 , pp. 16-20.
- Kitzmann AS, Pulido JS, Diehl NN, et al. (2008). The incidence of central serous chorioretinopathy. *Br J Ophthalmol*, Vol. 115. No.1, pp. 169-73.
- Marmor MF. New hypothesis on the pathogenesis and treatment of serous retinal detachment. (1988). *Graefes Arch Clin Exp Ophthalmol*, Vol. 226. No. 6. 1988, pp.548-52.
- Shinojima A, Hirose T, Mori R, Kawamura A, Yuzawa M. (2010). Morphologic Findings in Acute Central Serous Chorioretinopathy Using Spectral Domain-Optical Coherence Tomography With Simultaneous Angiography. *Retina*, Vol. 30. No. 2, 2010, pp. 193-202. ISSN:0275-004X
- Tittle MK, Spaide RF, Wong D, et al. (1999). Systemic findings associated with central serous chorioretinopathy. *Am J Ophthalmol*, Vol. 128. No.1 , pp. 63-8.



## **Selected Topics in Optical Coherence Tomography**

Edited by Dr. Gangjun Liu

ISBN 978-953-51-0034-8

Hard cover, 280 pages

**Publisher** InTech

**Published online** 08, February, 2012

**Published in print edition** February, 2012

This book includes different exciting topics in the OCT fields, written by experts from all over the world. Technological developments, as well as clinical and industrial applications are covered. Some interesting topics like the ultrahigh resolution OCT, the functional extension of OCT and the full field OCT are reviewed, and the applications of OCT in ophthalmology, cardiology and dentistry are also addressed. I believe that a broad range of readers, such as students, researchers and physicians will benefit from this book.

### **How to reference**

In order to correctly reference this scholarly work, feel free to copy and paste the following:

Ari Shinojima and Mitsuko Yuzawa (2012). Morphological Changes of Retinal Pigment Epithelial Detachment in Central Serous Chorioretinopathy, Selected Topics in Optical Coherence Tomography, Dr. Gangjun Liu (Ed.), ISBN: 978-953-51-0034-8, InTech, Available from: <http://www.intechopen.com/books/selected-topics-in-optical-coherence-tomography/morphological-changes-of-retinal-pigment-epithelial-detachment-in-central-serous-chorioretinopathy>

**INTECH**  
open science | open minds

### **InTech Europe**

University Campus STeP Ri  
Slavka Krautzeka 83/A  
51000 Rijeka, Croatia  
Phone: +385 (51) 770 447  
Fax: +385 (51) 686 166  
[www.intechopen.com](http://www.intechopen.com)

### **InTech China**

Unit 405, Office Block, Hotel Equatorial Shanghai  
No.65, Yan An Road (West), Shanghai, 200040, China  
中国上海市延安西路65号上海国际贵都大饭店办公楼405单元  
Phone: +86-21-62489820  
Fax: +86-21-62489821

© 2012 The Author(s). Licensee IntechOpen. This is an open access article distributed under the terms of the [Creative Commons Attribution 3.0 License](#), which permits unrestricted use, distribution, and reproduction in any medium, provided the original work is properly cited.

IntechOpen

IntechOpen