

# We are IntechOpen, the world's leading publisher of Open Access books Built by scientists, for scientists

**4,800**

Open access books available

**122,000**

International authors and editors

**135M**

Downloads

Our authors are among the

**154**

Countries delivered to

**TOP 1%**

most cited scientists

**12.2%**

Contributors from top 500 universities



**WEB OF SCIENCE™**

Selection of our books indexed in the Book Citation Index  
in Web of Science™ Core Collection (BKCI)

Interested in publishing with us?  
Contact [book.department@intechopen.com](mailto:book.department@intechopen.com)

Numbers displayed above are based on latest data collected.

For more information visit [www.intechopen.com](http://www.intechopen.com)



# Role of $^{123}\text{I}$ -Metaiodobenzylguanidine Myocardial Scintigraphy in Parkinsonian Disorders

Masahiko Suzuki

*Department of Neurology, The Jikei University School of Medicine, Aoto Hospital, Tokyo, Japan*

## 1. Introduction

Parkinson's disease (PD) is a relatively common neurological disorder in the elderly. However, only 76% of patients considered clinically to have PD are confirmed to have PD after postmortem examination (Hughes et al., 1993). The most common atypical form of parkinsonism is multiple system atrophy (MSA) (Hughes et al., 1994). MSA is clinically characterized by a combination of parkinsonian, autonomic, pyramidal and/or cerebellar symptoms and signs. The differential diagnosis of disorders with parkinsonism is very important because prognosis and treatment options differ substantially (Wenning et al., 1997). However, although the diagnoses of PD and MSA are based on current clinical criteria (Gelb et al., 1999; Gilman et al., 1999), they continue to lack sufficient specificity (Hughes et al., 1992; Litvan et al., 1997), particularly early in the disease course (Osaki et al., 2002).

Extrapyramidal signs in dementia with Lewy bodies (DLB) resemble those seen in PD, although less rest tremor and left/right asymmetry, but more severe rigidity, favors a diagnosis of DLB. The subtle differences in the nature of extrapyramidal signs between DLB and PD may be of limited help in clinically differentiating the two disorders. This is particularly true in the early disease stages because the sensitivity of the clinical diagnosis of DLB based on the consensus criteria of the DLB International Workshop was 0.22 compared with 0.83 based on a neuropathological diagnosis (McKeith et al., 1996).

The clinical features of PD and autosomal recessive juvenile parkinsonism (AR-JP) are also similar. Thus, it may be difficult to differentiate these two disorders. Neuropathological studies in AR-JP have revealed selective degeneration with gliosis of the pigmented neurons of the substantia nigra and locus ceruleus, but generally no Lewy bodies (Takahashi et al., 1994; Mori et al., 1998; Paviour et al., 2004), suggesting that the pathological findings and disease process of AR-JP differ from those of PD.

Metaiodobenzylguanidine (MIBG) is a physiological analogue of noradrenaline (norepinephrine) (Wieland et al., 1981) and  $^{123}\text{I}$ -MIBG myocardial scintigraphy has been used to evaluate postganglionic cardiac sympathetic innervation in parkinsonian disorders (Braune et al., 1999; Orimo et al., 1999; Druschky et al., 2000; Taki et al., 2000; Suzuki et al., 2005).  $^{123}\text{I}$ -MIBG myocardial scintigraphy can be performed safely and is clinically used to estimate local myocardial sympathetic nerve damage in PD (Braune et al., 1998; Orimo et al., 1999; Takatsu et al., 2000a). Myocardial innervation imaging using  $^{123}\text{I}$ -MIBG has also

emerged as a useful method to confirm or exclude the presence of PD (Jost et al., 2010). Thus,  $^{123}\text{I}$ -MIBG scintigraphy is the only method that can distinguish with a high degree of sensitivity and specificity between parkinsonian disorders and PD.

In the present study, we evaluated  $^{123}\text{I}$ -MIBG myocardial scintigraphy in patients with PD, DLB, AR-JP, and MSA in order to enhance the differentiation of PD from these other neurological diseases that mimic PD.

## 2. Material and methods

### 2.1 Patients

A total of 74 subjects were enrolled prospectively based on the criteria outlined below for PD ( $n = 36$ ), DLB ( $n = 6$ ), MSA ( $n = 14$ ), AR-JP ( $n = 2$ ), and normal control groups (NC;  $n = 16$ ). There was no significant difference in age between patients with parkinsonism and NC ( $P = 0.25$ ), and none of the enrolled subjects had clinical evidence of diabetes mellitus or cardiovascular disease. Cases were excluded if no relevant clinical information was provided. In addition, none of the participating subjects were taking drugs that might interfere with  $^{123}\text{I}$ -MIBG uptake (Solanki et al., 1992; Wafelman et al., 1994; Braune et al., 2001).

The diagnosis of probable DLB was made based on the criteria of DLB adopted by the International National Workshop on DLB (McKeith et al., 1996). Six patients with DLB had early recurrent visual hallucinations and delusions unrelated to therapy, marked fluctuations in alertness, progressive cognitive decline, and spontaneous motor features of parkinsonism. These psychiatric symptoms became worse with administration of anticholinergic agents and dopamine agonists.

Thirty-six patients with idiopathic PD (Hoehn and Yahr (HY) stage 1, 8 patients; HY 2, 22 patients; HY 3, 6 patients) showed two or more of the following cardinal features of PD: rest tremor, bradykinesia, muscular rigidity, loss of postural reflexes, and unilateral symptoms; thus fulfilling standard diagnostic criteria 6. All PD patients had a good or excellent initial response to levodopa treatment.

Fourteen patients presented with probable MSA according to the criteria reported by Gilman and colleagues (Gilman et al., 1999); all showed extrapyramidal symptoms and corticospinal dysfunction, sporadic adult-onset, and rapid disease progression without dementia. These patients tended to be unresponsive to levodopa or dopamine agonist therapy.

The study included two patients with AR-JP. Both had consanguineous parents and were only first generation. Their clinical features included early-onset (in the 20s) and levodopa-responsive parkinsonism, diurnal fluctuation, and slow progression of the disease. The disease presented initially with dystonic posture of the legs followed by a gradual development of parkinsonism. Their parkinsonian symptoms were responsive to levodopa, although a gradual decline in the efficacy was noted. The parkinsonian triad was mild, and the tremor was usually fine and postural. The levodopa efficacy was sufficient and the clinical course was benign; however, both showed a clear wearing-off phenomenon.

### 2.2 $^{123}\text{I}$ -MIBG myocardial scintigraphy

$^{123}\text{I}$ -MIBG myocardial scintigraphy was performed in all subjects using an intravenous injection of 111 MBq  $^{123}\text{I}$ -MIBG (Daiichi Radioisotope Laboratories Co, Tokyo, Japan). Single positron emission computed tomographic and planar images of the chest were obtained after 30 minutes for early images and after 4 hours for delayed images, using a triple-headed

gamma camera (MULTI SPECT III, Siemens, IL, USA) equipped with low-energy and high-resolution collimators. The photopeak of <sup>123</sup>I was centered at 159 keV with a 20% energy window. For the anterior planar image, the data was acquired for 4 minutes with a 256 × 256 matrix for image acquisition. The organ uptake of <sup>123</sup>I-MIBG was determined by setting the region of interest (ROI) on the anterior view. An ROI was drawn in the left ventricle of the heart and an angular ROI was also set in the upper mediastinum in early imaging, with the same also used for the delayed imaging. The heart to mediastinum ratio (H/M ratio) represented the average counts per pixel in the heart (H) and mediastinum (M).

### 2.3 Statistical analysis

All data are expressed as mean ± standard deviations. Differences in continuous variables were examined for statistical significance using Student's t-test. A *P* value less than 0.01 was considered to denote a significant difference. All tests were performed with the STATA 8.0 software program (STATA Corporation, College Station, TX). The AR-JP group was excluded from the analysis because of the small number of subjects.

### 3. Results

The normal mean values of the H/M ratio in 16 NC were 2.04 (SD 0.18) (range; 1.86-2.55) in the early phase and 2.12 (0.15) (1.91-2.43) in the delayed phase (Table 1). The mean H/M ratio in the early/delayed phase was 1.25 (0.11) (1.11-1.37)/1.18 (0.12) (1.01-1.39) in patients with DLB, 1.45 (0.19) (1.13-1.79)/1.36 (0.22) (1.03-1.99) in those with PD, and 1.88 (0.27) (1.46-2.34)/1.88 (0.40) (1.33-2.47) in those with MSA, respectively. In patients with DLB, the H/M ratio in the early/delayed phases was significantly lower than in MSA and NC groups. In patients with PD, the H/M ratio in the early/delayed phases was also significantly lower than that in MSA and NC groups. In the early phase, the mean value of H/M ratio in patients with DLB was significantly lower than that in patients with PD. However, the H/M ratio in the delayed phase for patients with DLB was lower than that in PD patients, although the difference was not significant (*P* = 0.015) (Table 1). Overall, there was no significant difference in the early/delayed H/M ratio between the MSA and NC groups (*P* = 0.077, *P* = 0.054, respectively). In the two patients with AR-JP, the H/M ratios in the early/delayed phases were preserved within the same range (1.99/2.13, 2.00/2.10, respectively) as the mean value of H/M ratio in NC (Figure 1).

Diagnosis	n (M/F)	Age (years)	H/M ratio		WR (%)
			Early image	Delayed image	
DLB	6 (5/1)	68 ± 8	1.3 ± 0.1*†¶	1.2 ± 0.1*†	39 ± 5
PD	36 (24/12)	64 ± 9	1.5 ± 0.2*†	1.4 ± 0.2*†	42 ± 6
MSA	14 (8/6)	63 ± 8	1.9 ± 0.3 ns	1.9 ± 0.4 ns	35 ± 7 ns
NC	16 (11/5)	64 ± 9	2.0 ± 0.2	2.1 ± 0.2	35 ± 4

Data are mean±SD. \**P* < 0.001, compared with normal control subjects; ns, not significant, compared with normal control subjects; †*P* < 0.001, compared with MSA; ¶*P* < 0.004, compared with PD. DLB, dementia with Lewy bodies; PD, Parkinson's disease; MSA, multiple system atrophy; NC, normal control subjects; M, male; F, female; H/M ratio, heart to mediastinum ratio.

Table 1. Subjects' background and data summary

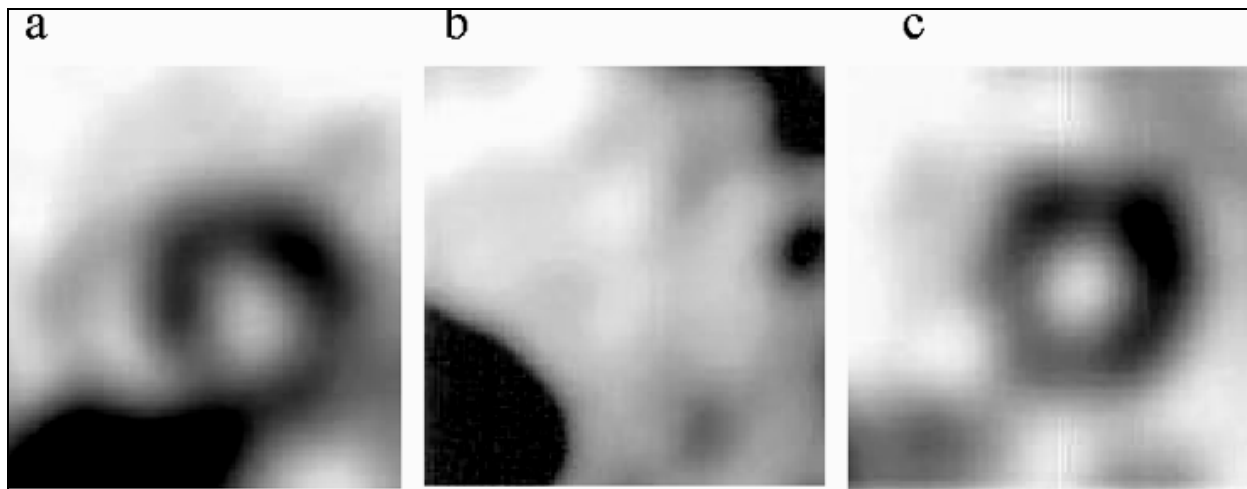


Fig. 1. Short-axis views of  $^{123}\text{I}$ -MIBG myocardial scintigraphy

Short-axis views in the early phase of single-photon emission computed tomography of iodine-123-labeled metaiodobenzylguanidine ( $^{123}\text{I}$ -MIBG) myocardial scintigraphy in a 62-year-old man with autosomal recessive juvenile parkinsonism (a), a 58-year-old man with idiopathic Parkinson's disease (Hoehn and Yahr Stage II, b), and a healthy 62-year-old man (c).

#### 4. Discussion

The major findings of the present study were that 1)  $^{123}\text{I}$ -MIBG uptake of the myocardium was significantly lower in patients with Lewy body disease (LBD) including PD and DLB than in controls, 2) the mean values of both the early and delayed H/M ratios in patients with DLB were significantly lower than those in patients with PD, and 3) the mean values of H/M ratios in the early and delayed phases in patients with MSA and AR-JP were well within the range of healthy control subjects.

Decreased cardiac uptake of  $^{123}\text{I}$ -MIBG has been reported in LBD (Yoshita et al., 2001; Watanabe et al., 2001; Nagayama et al., 2005; Suzuki et al., 2006; Suzuki et al., 2007), and a role for postganglionic cardiac sympathetic nerves in PD was demonstrated (Orimo et al., 2001). Thus, reduced uptake of  $^{123}\text{I}$ -MIBG is considered to reflect lesions in postganglionic cardiac sympathetic neurons in PD. Lower amounts of cardiac  $^{123}\text{I}$ -MIBG uptake were also reported in DLB, even in the early disease stage (Watanabe et al., 2001; Yoshita et al., 2001; Suzuki et al., 2006). These studies suggested that uptake of  $^{123}\text{I}$ -MIBG reflects myocardial sympathetic nerve function and that lowered myocardial  $^{123}\text{I}$ -MIBG uptake could reflect a disturbance of the postganglionic cardiac sympathetic nerves. In this context, the present study indicated marked reduction of  $^{123}\text{I}$ -MIBG uptake in DLB, indicating impairment of the cardiac sympathetic nervous system in this disorder and possible lesions in the postganglionic cardiac sympathetic neurons in DLB, as in PD (Suzuki et al., 2006). These observations might indeed reflect actual cardiac sympathetic denervation, which precedes the neuronal loss in the sympathetic ganglia (Orimo et al., 2005). Cardiac uptake of  $6\text{-}^{18}\text{F}$  fluorodopamine on positron emission tomography, which can also assess cardiac sympathetic innervation, was decreased in patients with PD (Goldstein et al., 1997; Goldstein et al., 2000), supporting that cardiac sympathetic denervation occurs in LBD.

Decreased cardiac uptake of MIBG has been reported even in the early stages of PD, which suggests early involvement of the cardiac sympathetic nerves. To investigate this proposal,



Orimo et al. (2007) immunohistochemically examined heart tissues, the sympathetic ganglia, and the medulla oblongata at the level of the dorsal vagal nucleus in 20 patients with incidental Lewy body disease (ILBD), which is thought to represent a presymptomatic stage of PD, and 10 control subjects, using antibodies against TH and NF. TH- and NF-immunoreactive nerve fibers of fascicles in the epicardium were well preserved in 10 of the 20 patients with ILBD and in all control subjects. In contrast, TH-immunoreactive nerve fibers had almost entirely disappeared in 6 patients and were moderately decreased in 4 of the 20 patients with ILBD. In addition, none of these ILBD patients showed neuronal loss in the dorsal vagal nucleus or sympathetic ganglia (Orimo et al., 2007). These findings suggested that degeneration of the cardiac sympathetic nerve begins even in the presymptomatic stage of PD, when neuronal loss in the dorsal vagal nucleus is not yet evident.

The present study also revealed relatively preserved cardiac  $^{123}\text{I}$ -MIBG uptake in MSA, consistent with previous studies (Yoshita et al., 1998; Nagayama et al., 2005). Taki et al. (2004) previously reported preserved  $^{123}\text{I}$ -MIBG uptake in MSA, suggesting that central and preganglionic neurons are predominantly affected, while postganglionic sympathetic neurons are usually spared. Thus, cardiac  $^{123}\text{I}$ -MIBG uptake could be unimpaired, indicating the significance of  $^{123}\text{I}$ -MIBG imaging as a discriminator between PD and MSA (Yoshita et al., 1998; Braune et al., 1999; Orimo et al., 1999; Druschky et al., 2000; Takatsu et al., 2000a, 2000b). Postmortem studies demonstrated that postganglionic cardiac sympathetic nerve fibers are markedly decreased in all PD patients, but not necessarily in those with MSA, providing substantial evidence of discrepant  $^{123}\text{I}$ -MIBG uptake between PD and MSA (Orimo et al., 2001, 2002). Recent myocardial innervation imaging with  $^{123}\text{I}$ -MIBG scintigraphy also demonstrated a high sensitivity for PD detection and adequate specificity for discriminating between PD and MSA (Köllensperger et al., 2007; Chung et al., 2009; Fröhlich et al., 2010). However, Nagayama et al. (2010) recently suggested that MSA cannot consistently be distinguished from PD based on  $^{123}\text{I}$ -MIBG myocardial scintigraphy. Their study clearly showed that cardiac MIBG uptake is not always preserved in patients with MSA and that approximately 30% of patients with MSA showed decreased MIBG uptake without any correlation to disease duration or severity. The precise mechanisms underlying low cardiac MIBG uptake in MSA patients remain unclear. The same authors also reported an autopsied patient with MSA showing low cardiac MIBG uptake with an incidental LB pathology in addition to a typical MSA pathology (Nagayama et al., 2008). Therefore, the presence of LB pathology may be a suitable explanation for the low myocardial MIBG uptake observed in patients with MSA. The second consensus statement on the diagnosis of MSA gave no advice about the usefulness and reliability of MIBG scintigraphy scanning in the workup of suspected patients with MSA (Gilman et al., 2008), while the Quality Standards Subcommittee of the American Academy of Neurology found insufficient evidence to recommend MIBG cardiac imaging for differentiating PD from MSA (Suchowersky et al., 2006).

In contrast, myocardial uptake of  $^{123}\text{I}$ -MIBG in AR-JP was normal in our study (Suzuki et al., 2005). The H/M ratios in the early and delayed phases in two patients were well within the range for healthy control subjects. These findings might explain the tendency for cardiac sympathetic function to be normal in patients with AR-JP. The pathological background of PD is a systemic distribution of Lewy bodies and Lewy neuritis, spreading to the peripheral autonomic nervous system, including the cardiac plexus (Wakabayashi et al., 1997; Iwanaga et al., 1999). Thus, although the present study included only two patients with AR-JP, it

indicated that cardiac sympathetic nerve denervation occurs in PD, and thus accounted for the decrease in cardiac uptake of  $^{123}\text{I}$ -MIBG in PD patients and not in those with AR-JP. In this regard, quantification of cardiac  $^{123}\text{I}$ -MIBG uptake is considered a valuable tool to identify patients with PD and to distinguish them from patients with other parkinsonian syndromes, including AR-JP (Braune et al., 1999; Orimo et al., 1999; Druschky et al., 2000; Taki et al., 2000). However, a recent study of PD patients showed a low myocardial  $^{123}\text{I}$ -MIBG uptake in one patient with PARK2 mutation and autonomic dysfunction, while early-phase MIBG uptake was normal in all other patients free of autonomic dysfunction (Yoritaka et al., 2011). Similar to the above study, a low uptake of  $^{123}\text{I}$ -MIBG was reported in 1 of 4 patients with PARK2 mutations, with disease duration of 12 years and ill-defined autonomic dysfunction (Quattrone et al., 2008). In addition, 3 patients in the above study who had low  $^{123}\text{I}$ -MIBG uptake were slightly older than the other patients. Incidentally, Estorch et al. (1995) reported that the uptake of  $^{123}\text{I}$ -MIBG decreases with age, suggesting that aging could affect patients with PARK2 mutations. Decreased myocardial uptake of  $^{123}\text{I}$ -MIBG is also considered to indicate the presence of  $\alpha$ -synuclein aggregates in the axons of PD patients (Orimo et al., 2008), while the H/M ratio of patients with PARK2 mutations was reported to be within the range of the normal controls (Suzuki et al., 2005). Moreover, postmortem examination of patients with PARK2 mutations showed well preserved tyrosine hydroxylase immunoreactive nerve fibers in the epicardium (Orimo et al., 2005), suggesting normal functioning myocardial sympathetic nerve terminals in patients with PARK2 mutations. MIBG scintigraphy might be a marker for  $\alpha$ -synuclein in patients with PARK2 mutations; however, there are no pathological reports on the presence of Lewy bodies in patients with PARK2 mutations with low MIBG uptake (Yoritaka et al., 2011).

## 5. Conclusion

The results of the present study indicated that inclusion of  $^{123}\text{I}$ -MIBG myocardial scintigraphy in the clinical assessment can potentially increase the chance of correctly distinguishing LBD from the other parkinsonian syndromes. Our study also indicated a difficulty in the differential diagnosis of PD from DLB by  $^{123}\text{I}$ -MIBG findings alone. In comparison with PD, mild degeneration of the cardiac sympathetic nervous system may occur in patients with MSA. Finally, abnormalities of  $^{123}\text{I}$ -MIBG uptake in genetically identified cases of AR-JP are rare and inconsistent findings. Together, our findings support the conclusions of previous studies that  $^{123}\text{I}$ -MIBG myocardial scintigraphy is a potentially useful tool for the differential diagnosis of LBD based on the decreased  $^{123}\text{I}$ -MIBG uptake in cardiac postganglionic sympathetic nerve fibers.

## 6. References

- Braune, S., Reinhardt, M. & Bathmann, J. (1998). Impaired cardiac uptake of meta- $^{123}\text{I}$  iodobenzylguanidine in Parkinson's disease with autonomic failure. *Acta Neurologica Scandinavica* Vol. 97, pp. 307-314, ISSN 0001-6314
- Braune, S., Reinhardt, M. & Schnitzer, R. (1999). Cardiac uptake of  $^{123}\text{I}$ -MIBG separates Parkinson's disease from multiple system atrophy. *Neurology* Vol. 53, pp. 1020-1025, ISSN 0028-3878

- Braune, S. (2001). The role of cardiac metaiodobenzylguanidine uptake in the differential diagnosis of parkinsonian syndromes. *Clinical Autonomic Research* Vol. 11, pp. 351-355, ISSN 0959-9851
- Chung, E.J., Lee, W.Y. & Yoon, W.T. (2009). MIBG scintigraphy for differentiating Parkinson's disease with autonomic dysfunction from Parkinsonism-predominant multiple system atrophy. *Movement Disorders* Vol. 24, pp. 1650-1655, ISSN 1531-8257
- Druschky, A., Hilz, M.J. & Platsch, G. (2000). Differentiation of Parkinson's disease and multiple system atrophy in early disease stages by means of I-123-MIBG-spect. *Journal of Neurological Sciences* Vol. 175, pp. 3-12, ISSN 0022-510X
- Estorch, M., Carrio, I. & Berna, L. (1995). Myocardial iodine-labeled metaiodobenzylguanidine 123 uptake relates to age. *Journal of Nuclear Cardiology* Vol. 2, pp. 126-132, ISSN 1071-3581
- Fröhlich, I., Pilloy, W. & Vaillant, M. (2010). Myocardial MIBG scintigraphy: a useful clinical tool? : A retrospective study in 50 parkinsonian patients. *Neurological Sciences* Vol. 31, pp. 403-406, ISSN 1590-3478
- Gelb, D.J., Oliver, E. & Gilman, S. (1999). Diagnostic criteria for Parkinson disease. *Archives of Neurol* Vol. 56, pp. 33-39, ISSN 0003-9942
- Gilman, S., Low, P.A. & Quinn, N. (1999). Consensus statement on the diagnosis of multiple system atrophy. *Journal of Neurological Sciences*, Vol. 163, pp. 94-98, ISSN 0022-510X
- Gilman, S., Wenning, G.K. & Low, P.A. (2008). Second consensus statement on the diagnosis of multiple system atrophy. *Neurology*, Vol. 71, pp. 670-676, ISSN 1526-632X
- Goldstein, D.S., Holmes, C. & Cannon, R.O. III. (1997). Sympathetic cardioneuropathy in dysautonomias. *New England Journal of Medicine*, Vol.336, pp. 696-702, ISSN 0028-4793
- Goldstein, D.S., Holmes, C. & Li, S-T. (2000). Cardiac sympathetic denervation in Parkinson disease. *Annals of Internal Medicine*, Vol.133, pp. 338-347, ISSN 0003-4819
- Hughes, A.J., Daniel, S.E. & Kilford, L. (1992). Accuracy of clinical diagnosis of idiopathic Parkinson's disease: A clinico-pathological study of 100 cases. *Journal of Neurology, Neurosurgery, and Psychiatry*, Vol. 55, pp. 181-184, ISSN 0022-3050
- Hughes, A.J., Daniel, S.E. & Blankson, S. (1993). A clinicopathologic study of 100 cases of Parkinson's disease. *Archives of Neurology*, Vol.50, pp. 140-148, ISSN 0003-9942
- Iwanaga, K., Wakabayashi, K. & Yoshimoto, M. (1999). Lewy body-type degeneration in cardiac plexus in Parkinson's and incidental Lewy body diseases, *Neurology*, Vol. 52, pp. 1269-1271, ISSN 0028-3878
- Jost, W.H., Del Tredici, K., & Landvogt, C. (2010). Importance of <sup>123</sup>I-metaiodobenzylguanidine scintigraphy/single photon emission computed tomography for diagnosis and differential diagnostics of Parkinson syndromes. *Neurodegenerative Diseases* Vol. 7, pp. 341-347, ISSN 1660-2862
- Köllensperger, M., Seppi, K. & Liener, C. (2007). Diffusion weighted imaging best discriminates PD from MSA-P: A comparison with tilt table testing and heart MIBG scintigraphy. *Movement Disorders*, Vol. 22, pp. 1771-1776, ISSN 0885-3185
- Litvan, I., Goetz, C.G. & Jankovic, J. (1997). What is the accuracy of the clinical diagnosis of multiple system atrophy? A clinicopathologic study. *Archives of Neurology*, Vol. 54, pp. 937-944, ISSN 0003-9942




- McKeith, I.G., Galasko, D. & Kosaka, K. (1996). Consensus guidelines for the clinical and pathologic diagnosis of dementia with Lewy bodies (DLB): Report of the consortium on DLB international workshop. *Neurology*, Vol. 47, pp. 1113-1124, ISSN 0028-3878
- Mori, H., Kondo, T., & Yokochi, M. (1998). Pathologic and biochemical studies of juvenile parkinsonism linked to chromosome 6q. *Neurology*, Vol. 51, pp. 890-892, ISSN 0028-3878
- Nagayama, H., Hamamoto, M. & Ueda, M. (2005). Reliability of MIBG myocardial scintigraphy in the diagnosis of Parkinson's disease. *Journal of Neurology, Neurosurgery and Psychiatry*, Vol. 76, pp. 249-251, ISSN 0022-3050
- Nagayama, H., Yamazaki, M. & Ueda, M. (2008). Low myocardial MIBG uptake in multiple system atrophy with incidental Lewy body pathology: an autopsy case report. *Movement Disorders*, Vol. 23, pp. 1055-1057, ISSN 1531-8257
- Nagayama, H., Ueda, M. & Yamazaki, M. (2010). Abnormal cardiac <sup>123</sup>I-meta-iodobenzylguanidine uptake in multiple system atrophy. *Movement Disorders*, Vol. 25, pp. 1744-1747, ISSN 1531-8257
- Orimo, S., Ozawa, E. & Oka, T. (2001). Different histopathology accounting for a decrease in myocardial MIBG uptake in PD and MSA. *Neurology*, Vol. 57, pp. 1140-1141, ISSN 0028-3878
- Orimo, S., Ozawa, E. & Nakade, S. (1999). <sup>123</sup>I-metaiodobenzylguanidine myocardial scintigraphy in Parkinson's disease. *Journal of Neurology, Neurosurgery, and Psychiatry*, Vol. 67, pp. 189-194, ISSN 0022-3050
- Orimo, S., Oka, T. & Miura, H. (2002). Sympathetic cardiac denervation in Parkinson's disease and pure autonomic failure but not in multiple system atrophy. *Journal of Neurology, Neurosurgery, and Psychiatry*, Vol. 73, pp. 776-777, ISSN 0022-3050
- Orimo, S., Amino, T. & Itoh, Y. (2005). Cardiac sympathetic denervation precedes neuronal loss in the sympathetic ganglia in Lewy body disease. *Acta Neuropathologica (Berlin)* Vol. 109, pp. 583-588, ISSN 0001-6322
- Orimo, S., Takahashi, A, & Uchihara, T. (2007). Degeneration of cardiac sympathetic nerve begins in the early disease process of Parkinson's disease. *Brain Pathology*, Vol. 17, pp. 24-30, ISSN 1015-6305
- Orimo, S., Uchihara, T. & Nakamura, A. (2008). Axonal  $\alpha$ -synuclein aggregates herald centripetal degeneration of cardiac sympathetic nerve in Parkinson's disease. *Brain*, Vol. 131, pp. 642-650, ISSN 1460-2156
- Osaki, Y., Wenning, G.K. & Daniel, S.E. (2002). Do published criteria improve clinical diagnostic accuracy in multiple system atrophy? *Neurology*, Vol. 59, pp. 1486-1491, ISSN 0028-3878
- Paviour, D.C., Surtees, R.A. & Lees, A.J. (2004). Diagnostic considerations in juvenile parkinsonism. *Movement Disorders*, Vol. 19, pp. 123-135, ISSN 0885-3185
- Quattrone, A., Bagnato, A. & Annesi, G. (2008). Myocardial <sup>123</sup>metaiodobenzylguanidine uptake in genetic Parkinson's disease. *Movement Disorders* Vol. 23, pp. 21-27, ISSN 1531-8257
- Solanki, K.K., Bomanji, J. & Moyes, J. (1992). A pharmacological guide to medicines which interfere with the biodistribution of radiolabelled meta-iodobenzylguanidine (MIBG). *Nuclear Medicine Communications*, Vol.13, pp. 513-521, ISSN 0143-3636

- Suchowersky, O., Reich, S. & Perlmutter, J. (2006). Practice parameter: diagnosis and prognosis of new onset Parkinson disease (an evidence-based review): report of the Quality Standards Subcommittee of the American Academy of Neurology. *Neurology*, Vol. 66, pp. 968-975, ISSN 1526-632X
- Suzuki, M., Hattori, N. & Orimo, S. (2005). Preserved myocardial <sup>123</sup>I-metaiodobenzylguanidine uptake in autosomal recessive juvenile parkinsonism: First case report. *Movement Disorders*, Vol.20, pp. 634-636, ISSN 0885-3185
- Suzuki, M., Kurita, A. & Hashimoto, M. (2006). Impaired myocardial <sup>123</sup>I-metaiodobenzylguanidine uptake in Lewy body disease: Comparison between dementia with Lewy bodies and Parkinson's disease. *Journal of Neurological Sciences*, Vol. 240, pp. 15-19, ISSN 0022-510X
- Suzuki, M., Urashima, M. & Oka, H. (2007). Cardiac sympathetic denervation in bradykinesia-dominant Parkinson's disease. *Neuroreport*, Vol.18, pp. 1867-1870, ISSN 0959-4965
- Takahashi, H., Ohama, E. & Suzuki, S. (1994). Familial juvenile parkinsonism: Clinical and pathologic study in a family. *Neurology*, Vol. 44, pp. 437-441, ISSN 0028-3878
- Takatsu, H., Nishida, H. & Matsuo, H. (2000a). Cardiac sympathetic denervation from the early stage of Parkinson's disease: Clinical and experimental studies with radiolabeled MIBG. *Journal of Nuclear Medicine*, Vol. 41, pp. 71-77, ISSN 0161-5505
- Takatsu, H., Nagashima, K. & Murase, M. (2000b). Differentiating Parkinson disease from multiple-system atrophy by measuring cardiac iodine-123 metaiodobenzylguanidine accumulation. *Journal of the American Medical Association*, Vol. 284, pp. 44-45, ISSN 0098-7484
- Taki, J., Nakajima, K. & Hwang, E.H. (2000). Peripheral sympathetic dysfunction in patients with Parkinson's disease without autonomic failure is heart selective and disease specific. *European Journal of Nuclear Medicine*, Vol. 27, pp. 566-573, ISSN 0340-6997
- Taki, J., Yoshita, M. & Yamada, M. (2004). Significance of <sup>123</sup>I-MIBG scintigraphy as a pathophysiological indicator in the assessment of Parkinson's disease and related disorders: It can be a specific marker for Lewy body disease. *Annals of Nuclear Medicine*, Vol. 18, pp. 453-461, ISSN 0914-7187
- Wafelman, A.R., Hoefnagel, C.A. & Maes, R.A. (1994). Radioiodinated metaiodobenzylguanidine: A review of its biodistribution and pharmacokinetics, drug interactions, cytotoxicity and dosimetry. *European Journal of Nuclear Medicine*, Vol. 21, pp. 545-559, ISSN 0340-6997
- Wakabayashi, K. & Takahashi, H. (1997). Neuropathology of autonomic nervous system in Parkinson's disease. *European Neurology*, Vol. 38, Suppl 2:2-7, ISSN 0014-3022
- Watanabe, H., Ieda, T. & Katayama, T. (2001). Cardiac <sup>123</sup>I-meta-iodobenzylguanidine (MIBG) uptake in dementia with Lewy bodies: Comparison with Alzheimer's disease. *Journal of Neurology, Neurosurgery, and Psychiatry*, Vol. 70, pp.781-783, ISSN 0022-3050
- Wenning, G.K., Tison, F. & Ben Shlomo, Y. (1997). Multiple system atrophy: A review of 203 pathologically proven cases. *Movement Disorders*, Vol. 12, pp. 133-147, ISSN 0885-3185
- Wieland, D.M., Brown, L.E. & Rogers, W.L. (1981). Myocardial imaging with a radioiodinated norepinephrine storage analog. *Journal of Nuclear Medicine*, Vol. 22, pp. 22-31, ISSN 0161-5505

- Yoshita, M. (1998). Differentiation of idiopathic Parkinson's disease from striatonigral degeneration and progressive supranuclear palsy using iodine-123 meta-iodobenzylguanidine myocardial scintigraphy. *Journal of Neurological Sciences*, Vol. 155, pp. 60-67, ISSN 0022-510X
- Yoritaka, A., Shimo, Y. & Shimo, Y. (2011). Nonmotor symptoms in patients with PARK2 mutations. *Parkinson's Disease*, Vol. 2011, pp. 1-5, ISSN 2042-0080
- Yoshita, M., Taki, J. & Yamada, M. (2001). A clinical role for <sup>123</sup>I-MIBG myocardial scintigraphy in the distinction between dementia of the Alzheimer's-type and dementia with Lewy bodies. *Journal of Neurology, Neurosurgery, and Psychiatry*, Vol. 71, pp. 583-588, ISSN 0022-3050

IntechOpen



## **Mechanisms in Parkinson's Disease - Models and Treatments**

Edited by Dr. Juliana Dushanova

ISBN 978-953-307-876-2

Hard cover, 582 pages

**Publisher** InTech

**Published online** 08, February, 2012

**Published in print edition** February, 2012

Parkinson's disease (PD) results primarily from the death of dopaminergic neurons in the substantia nigra. Current PD medications treat symptoms; none halt or retard dopaminergic neuron degeneration. The main obstacle to developing neuroprotective therapies is a limited understanding of the key molecular mechanisms that provoke neurodegeneration. The discovery of PD genes has led to the hypothesis that misfolding of proteins and dysfunction of the ubiquitin-proteasome pathway are pivotal to PD pathogenesis. Previously implicated culprits in PD neurodegeneration, mitochondrial dysfunction, and oxidative stress may also act in part by causing the accumulation of misfolded proteins, in addition to producing other deleterious events in dopaminergic neurons. Neurotoxin-based models have been important in elucidating the molecular cascade of cell death in dopaminergic neurons. PD models based on the manipulation of PD genes should prove valuable in elucidating important aspects of the disease, such as selective vulnerability of substantia nigra dopaminergic neurons to the degenerative process.

### **How to reference**

In order to correctly reference this scholarly work, feel free to copy and paste the following:

Masahiko Suzuki (2012). Role of 123I-Metaiodobenzylguanidine Myocardial Scintigraphy in Parkinsonian Disorders, *Mechanisms in Parkinson's Disease - Models and Treatments*, Dr. Juliana Dushanova (Ed.), ISBN: 978-953-307-876-2, InTech, Available from: <http://www.intechopen.com/books/mechanisms-in-parkinson-s-disease-models-and-treatments/the-role-of-123i-metaiodobenzylguanidine-myocardial-scintigraphy-in-parkinsonian-disorders>

**INTECH**  
open science | open minds

### **InTech Europe**

University Campus STeP Ri  
Slavka Krautzeka 83/A  
51000 Rijeka, Croatia  
Phone: +385 (51) 770 447  
Fax: +385 (51) 686 166  
[www.intechopen.com](http://www.intechopen.com)

### **InTech China**

Unit 405, Office Block, Hotel Equatorial Shanghai  
No.65, Yan An Road (West), Shanghai, 200040, China  
中国上海市延安西路65号上海国际贵都大饭店办公楼405单元  
Phone: +86-21-62489820  
Fax: +86-21-62489821

© 2012 The Author(s). Licensee IntechOpen. This is an open access article distributed under the terms of the [Creative Commons Attribution 3.0 License](#), which permits unrestricted use, distribution, and reproduction in any medium, provided the original work is properly cited.

IntechOpen

IntechOpen