

We are IntechOpen, the world's leading publisher of Open Access books Built by scientists, for scientists

4,800

Open access books available

122,000

International authors and editors

135M

Downloads

Our authors are among the

154

Countries delivered to

TOP 1%

most cited scientists

12.2%

Contributors from top 500 universities



WEB OF SCIENCE™

Selection of our books indexed in the Book Citation Index
in Web of Science™ Core Collection (BKCI)

Interested in publishing with us?
Contact book.department@intechopen.com

Numbers displayed above are based on latest data collected.
For more information visit www.intechopen.com



Prostate Cancer Precursor Diseases

A.G. Papatsoris, C. Kostopoulos, V. Migdalis and M. Chrisofos
*2nd Department of Urology, School of Medicine, University of Athens,
Sismanoglio General Hospital, Athens,
Greece*

1. Introduction

Prostate cancer remains the most common non-cutaneous malignancy in the Western world and is the second leading cause of cancer death in males, after lung cancer (Nelson et al., 2003; Papatsoris & Anagnostopoulos, 2009). Based on experimental and preclinical findings, novel anti-prostate cancer strategies have been developed (Papatsoris & Papavassiliou, 2001; Papatsoris et al., 2005). However, the causes of prostate cancer, prostatic carcinogenesis, and the histological changes preceding and leading to the initiation of prostate cancer have yet to be elucidated. Several research groups are trying to solve the puzzle of prostatic carcinogenesis by focusing within the morphological continuum between benign glands at one end and premalignant lesions and invasive disease at the other (Vis & Van Der Kwast, 2001). In parallel, clinicians are frequently confronted with morphological features on the prostate needle biopsy that, although negative for cancer, raise suspicion of concomitant malignancy.

2. Definition of prostate cancer precursor lesions

There are several criteria that should be met in order to consider a prostatic lesion as premalignant (Vis & Van Der Kwast, 2001). An epidemiological relationship must be revealed, the precursor lesion should present at an earlier age than the cancer, and clear morphological similarities (e.g. cellular, histological, and architectural) should be present. Also, premalignant lesions should be close to their presumed malignant equivalents. The prostate has a greater frequency, severity, and extent of premalignant lesions in comparison with other organs. The definitive proof of a relationship between a premalignant lesion and malignancy is the clinical evidence of progression into invasive prostate cancer.

The earliest report on premalignant prostatic lesions dates back to 1926 (Orteil, 1926). In 1965, *McNeal* described lesions with possible premalignant features in prostatic epithelium (McNeal, 1965). In 1986, *McNeal and Bostwick* described the first criteria for the diagnosis of "intraductal neoplasia" which was classified into three grades (McNeal & Bostwick, 1986). In 1987, *Bostwick and Brawer* introduced the term "PIN" - prostatic intraepithelial neoplasia (Bostwick & Brawer, 1987). At an international conference in 1989, the term "PIN" was accepted as a replacement for various other terms (e.g. intraductal hyperplasia, hyperplasia with malignant change, large acinar atypical hyperplasia, marked atypia, ductal-acinar dysplasia). Initially, PIN was categorized into three grades with regard to architectural and

cytological characteristics, taking into account that the alterations cover a continuum. However, in 1989, at the aforementioned workshop on premalignant prostatic lesions, the classification was altered to low-grade (formerly grade I) and high-grade (formerly grades II and III) PIN - LGPIN and HGPIN, respectively (Bostwick, 1989).

Conventional histopathology examination is used to differentiate precursor lesions of prostate cancer. Benign glands show a continuous basal cell layer, while in prostate cancer the basal cell layer is immunohistochemically absent. Immunostaining for p63 (a p53 homologue) was shown to be useful as a basal cell-specific marker (Signoretti et al., 2000; Shah, 2004). It is frequently used in addition to 34 β E12 immunostaining in difficult diagnostic cases, where the main advantage of p63 over 34 β E12 is that there is less variable staining.

A wide range of “atypical” epithelial proliferative processes with a variety of names, often with confusing and overlapping terminology, has been described. Several morphological lesions have been proposed that may act as potential precursor lesions of prostate cancer. These are the morphologically distinct entities of focal atrophy or post-atrophic hyperplasia (PAH), atypical adenomatous hyperplasia (AAH) or adenosis, and PIN.

3. Prostatic atrophy and PAH

Focal prostatic atrophy reportedly is present in up to 85% of prostates at autopsy (Amin, 1999; Billis, 1998). It should be distinguished from diffuse atrophy, as the latter is not considered premalignant. A role for focal atrophy in the pathogenesis of PIN and/or prostate cancer was proposed by Franks, over 50 years ago (Franks, 1954). *De Marzo* observed that focal atrophic lesions showed an increased proliferative activity of luminal cells and a decreased frequency of apoptosis (DeMarzo et al., 1999). Concerning the classification of focal prostatic atrophy, although there are distinct histologic variants, the terminology is currently non-standardized and no formal classification has been tested for interobserver reliability. According to the current classification focal atrophy lesions were categorized into 4 distinct subtypes as follows: (i) simple atrophy, (ii) simple atrophy with cyst formation, (iii) postatrophic hyperplasia and (iv) partial atrophy (De Marzo et al., 2006).

Simple atrophy consists of atrophic cells lining acini with relatively normal caliber that lack papillary fronds, where the number of glands per unit area does not appear to be increased relative to normal tissue. (De Marzo et al., 2006). Simple atrophy demonstrates strong basal cell-specific antikeratin immunoreactivity (Bostwick, 1996). Simple atrophy with cyst formation is a subtype of simple atrophy. Two general patterns are now encompassed: those containing very large diameter glands (> 1 mm) and those containing smaller, rounded glands. The amount of cytoplasm at times may be so attenuated as to be nearly invisible. When there is significant cytoplasm in the luminal cell, it tends to be clear. Atrophy with cyst formation tends to have less inflammation than the other sub-types (De Marzo et al., 2006). In sclerotic atrophy, the stroma is more extensively sclerosed, resulting in a wider separation of the acinar elements; these continue to have the cytological features described above (DeMarzo et al., 1999; De Marzo et al., 2006). Post-Atrophic Hyperplasia (PAH) consists of acini that are smaller, round and appear in a lobular distribution, often surrounding a somewhat dilated duct with an apparent increase in the number of small glands compared to normal tissue. Some authors tend to refer to some of these lesions as

"lobular atrophy" or "lobular hyperplasia" (De Marzo et al., 2006). In lobular atrophy, the lesion is circumscribed with a central duct surrounded by small acini (Grignon & Sakr, 1996). The acini frequently have ectatic lumens and are lined by a flattened epithelium having scant cytoplasm and hyperchromatic nuclei with inconspicuous nucleoli. Basal cells are present but are difficult to recognize; however, they are readily identified with immunohistochemical stains for 34 β E12 cytokeratin. The stroma is sclerotic and compressed, particularly around the central duct.

PAH, which may closely mimic the histology of prostate cancer, may represent a diagnostic pitfall (Bostwick, 1996). Recent studies have reported that the frequency of PAH in radical prostatectomy specimens was remarkably similar to that in cystoprostatectomy specimens, implying that the simultaneous finding of PAH with prostate cancer is coincidental (Amin, 1999; Grignon & Sakr, 1996). PAH develops in a background of lobular or sclerotic atrophy and so retains many features of these lesions (Anton et al., 1999; Cheville & Bostwick, 1995; Grignon & Sakr, 1996). In PAH, there is an apparent secondary proliferation of small acini. The secretory cells have more abundant pale or clear cytoplasm than in usual atrophy, though generally not as much as in adenocarcinoma or AAH. The nuclei also become less hyperchromatic, and small chromocenters or nucleoli may be seen. The double cell layer is maintained and can be confirmed with basal cell-specific anticytokeratin antibodies. Despite the observation that focal atrophic lesions and PAH consist of flattened and dispersed acini, immunostaining with 34 β E12 cytokeratin is almost always positive and continuous, as it is for benign epithelial glands (Anton et al., 1999; Cheville & Bostwick, 1995).

4. AAH and sclerosing adenosis

The prevalence of AAH in transurethral prostatectomy (TURP) specimens without cancer ranges from 1.6% to 7.3% (Gaudi & Epstein, 1994). In biopsy specimens, the prevalence is lower, for example 0.8% in one series (Gaudin & Epstein, 1995). The increase in frequency of AAH in needle biopsies is presumably related to ultrasound-guided biopsy of the transition zone. AAH can be diagnosed throughout the prostate, but it is most often located in the transition zone of the prostate in intimate association with benign nodular hyperplasia (Bostwick & Qian, 1995). It can also be found near the apex and in the periurethral area (Bostwick, 1996). In AAH, the basal cell layer is discontinuous and fragmented on 34 β E12 cytokeratin immunostaining (Cheng et al., 1998).

There is considerable morphologic evidence suggesting that AAH is associated with low-grade adenocarcinoma arising in the transition zone (Cheville & Bostwick, 1995). AAH, a putative precursor of transition zone adenocarcinoma, has common features with low-grade adenocarcinoma and may cause problems in differential diagnosis, especially in the needle biopsy setting (Srigley, 2004). AAH is a lesion characterized by a proliferation of small acinar structures that mimics adenocarcinoma because of histological similarities (Grignon & Sakr, 1996). At low magnification, the lesion is circumscribed, although the small acini may show some infiltrative features. These acini are seen in association with a usually hyperplastic nodule and are most often at the periphery of the nodule. The nuclei tend to be uniform and round with inconspicuous or small nucleoli. There is limited data that AAH has a proliferation rate higher than hyperplasia but lower than adenocarcinoma (Bostwick & Qian, 1995; Cheng et al., 1998; Grignon & Sakr, 1996). AAH is diploid, as are most examples

of low-grade adenocarcinoma, while a few markers (blood group antigens, peanut agglutinin) show similar patterns of expression in AAH and adenocarcinoma (Grignon & Sakr, 1996). Recent cytogenetic analyses have detected abnormalities of chromosome 8 in a very small proportion (4–7%) of AAH cases (Bostwick & Qian, 1995; Cheng et al., 1998).

Sclerosing adenosis is a circumscribed proliferation of small acinar structures in a cellular spindled sclerotic stroma (Grignon & Sakr, 1996; Srigley, 2004). The acini range from irregular in shape to small, round, and uniform. Usually, there is thickening of the tubular basement membrane, a valuable diagnostic clue (Grignon & Sakr, 1996). Nucleoli are generally inconspicuous but can be prominent in a few cells, while the lumens can contain basophilic mucin or crystalloids (Grignon & Sakr, 1996). Sclerosing adenosis is usually an incidental finding in about 2% of transurethral resection of the prostate (TURP) or radical prostatectomy specimens, (Bostwick et al., 2008; Grignon et al., 1992; Cheng & Bostwick, 2010; Sakamoto et al, 1991) and rarely is present in needle biopsy specimens (Cheng & Bostwick 2010; Srigley, 2004). Sclerosing adenosis may simulate adenocarcinoma and accounts for up to 10% of cases overdiagnosed as adenocarcinoma (Berney et al., 2007; Bostwick & Cheng, 1999; Cheng & Bostwick, 2010). Multiple light microscopic and immunohistochemical features separate typical sclerosing adenosis from adenocarcinoma, including: (i) intact basal cell layer, a finding that can be confirmed immunohistochemically with antibodies directed against high-molecular-weight cytokeratin 34 β E12, (ii) unique immunophenotype of many of the basal and spindle cells in the stroma, including abundant S100 protein and smooth muscle actin (SMA) reactivity, as well as structural characteristics of myoepithelial cells, (iii) cellular spindle cell stroma, (iv) variably thickened basement membrane and (v) absence of significant cytological atypia. (Bostwick et al., 1994; Collina et al., 1992; Grignon et al., 1992; JonesC et al., 1991; Cheng & Bostwick, 2010; Sakamoto et al. 1991; Young & Clement, 1987 ; Young & Clement, 1990). Sclerosing adenosis differs from AAH by displaying myoepithelial features of the basal cells and an exuberant stroma of fibroblasts and loose ground substance (Bostwick et al., 1994).

5. Lesion Suspicious for Cancer (LSC)

As a result of the limited quantity of tissue sampled in prostate biopsies, there is the probability of finding a lesion that raises diagnostic confusion. There may be lesions suspicious for but not conclusive of malignancy. These lesions are small and have a wide diversity of architectural and morphological features. *Vis* proposed the terminology “prostate biopsy suspicious for malignancy” to classify these lesions (Vis et al., 2001). However, histology reports should be unequivocal and as concise as possible and vague diagnoses should not lead to unnecessary biopsy with its associated morbidities.

The controversial diagnostic term “atypical small acinar proliferation” (ASAP) is no longer considered acceptable. It is not considered a diagnostic entity as it can only be diagnosed on needle biopsies and not in prostatectomy specimens. The term ASAP has been replaced by the term “lesion suspicious for cancer” (LSC), as the prostate lesion lacks sufficient criteria to call it a carcinoma. LSC (fig. 1, 2) has gained acceptance as a legitimate way for pathologists to describe minute foci of small prostatic acini that raise the suspicion of carcinoma but that fail to attain the requisite diagnostic threshold for carcinoma (Fadare et al., 2004).

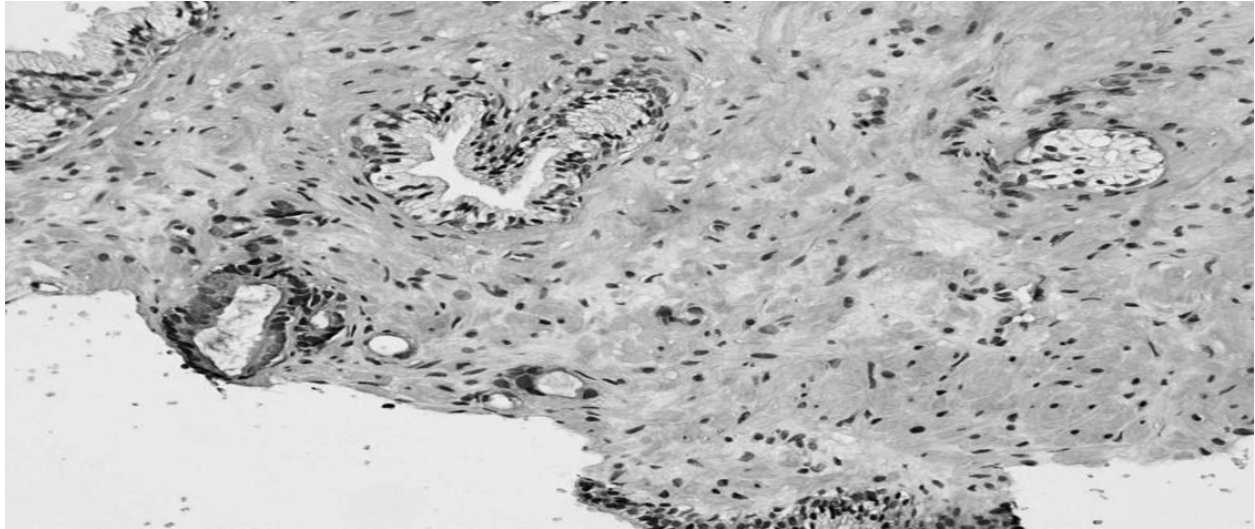


Fig. 1. An accumulation of a few atypical prostatic glands with amphophilic cytoplasm and nuclear enlargement. Compare with benign adjacent glands. This field is consistent with either atypical small prostate gland proliferation or limited prostate adenocarcinoma. (HE \times 200)

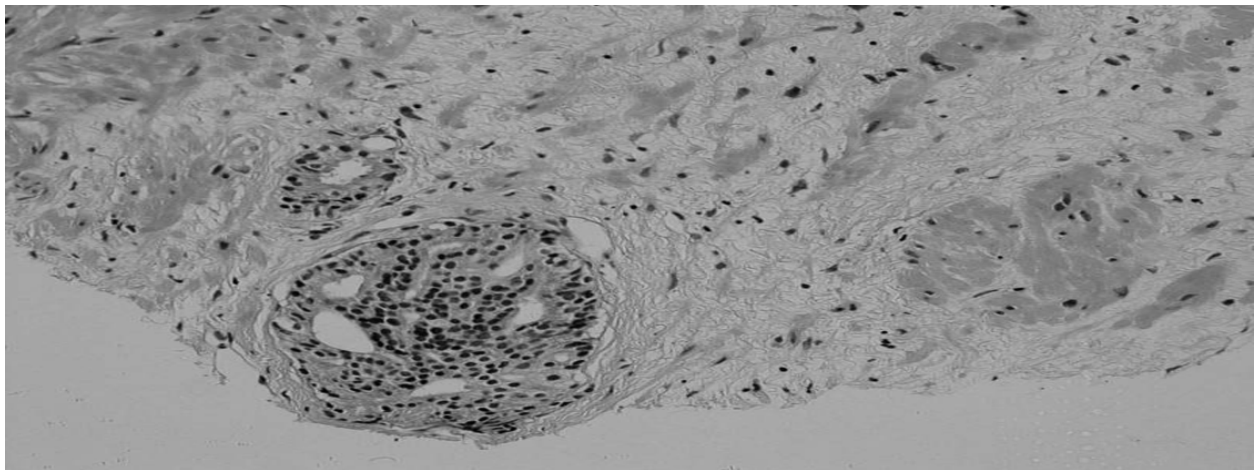


Fig. 2. Atypical cribriform gland at the periphery of a biopsy. Differential diagnosis between HGPIN and cribriform invasive adenocarcinoma may be impossible.

Studies have demonstrated that LSC is diagnosed in 1.5% to 9% of prostatic biopsies and that it predicts definite prostate cancer in about 45% of repeat biopsies (Iczkowski et al., 1997; Iczkowski et al., 1998; Iczkowski & Bostwick, 2000; Iczkowski et al., 2002). Since 1997, there have been efforts to stratify risk in cases of LSC into three categories: likely benign, uncertain, and likely carcinoma (Iczkowski et al., 1997). No single pathologic feature of LSC appeared to increase the likelihood for subsequent cancer (Iczkowski et al., 1998; Iczkowski & Bostwick, 2000; Iczkowski et al., 2002; Scattoni et al., 2005). The mean MIB-1 proliferation index of LSC was significantly higher than in benign prostatic tissue and did not differ from that of low-grade carcinoma.

LSC continues to be associated with a high risk of prostate cancer and requires a repeat biopsy with the extended peripheral zone biopsy scheme (Moore et al., 2005). Sampling

should include multiple sites in the prostate, as in 40% of patients; cancer was in different sites from the initial LSC site. The detection rate was lower for patients with a larger prostate than those with a smaller prostate (Scattoni et al., 2005). Hence, patients with LSC should be followed up and undergo repeat biopsy. The role of radical prostatectomy for LSC is not clear, although *Brausi* advocated that prostatectomy could be the treatment of choice in young men with LSC (Brausi et al., 2004).

6. PIN

6.1 Epidemiology of PIN

Epidemiological studies have demonstrated the presence of PIN in men as early as the fourth decade of life and showed that the incidence and extent of PIN increased with age (Sakr et al., 1993). It has been postulated that PIN pre-dates the onset of prostate cancer by 5–10 years (Sakr et al., 1993). In several autopsy and surgical series, PIN was identified in 60% to 90% of prostates harboring carcinoma and was often close to its presumed invasive equivalent (Qian et al., 1997). Studies showed that PIN was present in 82% of step-sectioned autopsy prostates with cancers, but in only 43% of benign prostates from patients of similar age (Vis & Van Der Kwast, 2001). *Qian* found that 86% of a series of 195 whole-mount radical prostatectomies contained HGPIN, usually within 2 mm of the cancer (Qian et al., 1997).

In the United States, 1,300,000 prostate biopsies are performed annually to detect 230,000 new cases of prostate cancer (Joniau et al., 2007; Steiner, 2003). There are approximately 115,000 cases of isolated HGPIN diagnosed each year, representing an estimated 9% of prostate biopsies (Steiner, 2003). The incidence of HGPIN in biopsies ranges from 1.5% to 16.5%, with an average of 6% (Bostwick et al., 1995; Epstein, 2002). The different incidence of HGPIN in published studies derives from differences in defining HGPIN and in the number of patients.

The most likely explanation to account for the variation in incidence of PIN is interobserver reproducibility (Sakr, 1995). Those pathologists who use a lower threshold to define prominent nucleoli will have a higher incidence of HGPIN. Other plausible explanations for the variation in reported incidence of HGPIN relate to the fixative used and to differences in sampling. Furthermore, the variations from one institution to another can be attributed to variation in the population study, the indications for biopsy, and the biopsy compliance rates. The site of the prostate biopsied, the number of biopsies taken, and the quality and processing technique of the biopsy cores can also influence the incidence of PIN.

HGPIN starts in young individuals and increases with age in Caucasians and African-Americans, but is more prevalent in the latter (Epstein, 1995; Sakr et al., 1996). HGPIN in African-Americans precedes HGPIN in Caucasians by approximately a decade (Epstein, 1995). A more extensive form of HGPIN with multifocal or diffuse involvement of the glands appears at a younger age in African-Americans in comparison with Caucasians (Sakr et al., 1996). The replication of the association of chromosome 8q24 variants with increased prostate cancer risk in Tobago men and the higher frequency of the risk alleles in controls in populations of African ancestry further strengthens the possible role of this genomic region in the disproportionate higher burden of prostate cancer in men of African ancestry (Sakr et

al., 1996). It has also been shown that prostate cancer grows more rapidly in black than in white men and/or earlier transformation from latent to aggressive prostate cancer occurs in black than in white men (Powell et al., 2010).

6.2 Molecular biology of PIN

The development of PIN is characterized by increased expression of several biomarkers that influence the proliferative potential of the dysplastic prostatic cells. Studies of potential biomarkers, such as growth factors, growth factor receptors, oncogene products, glycosylated tumor antigens, and other biomarkers in PIN, are difficult because these lesions are focal.

Unlike the premalignant polyps of the colon, it is difficult to obtain relatively pure preparations of PIN. One approach, to microdissect areas of PIN, is tedious and still may produce results contaminated by surrounding stroma and histologically normal epithelium. In addition, this technique does not allow differentiation of biomarker expression among the various components (basal versus luminal) of the dysplastic gland or duct. For these reasons, immuno - histochemical techniques as well as fluorescence *in situ* hybridization (FISH) is perhaps best suited for the assessment of biomarker expression in PIN.

FISH analysis has demonstrated strong expression of epidermal growth factor receptor (EGFr) mRNA in PIN (Myers & Grizzle, 1996). The c-erbB-2 gene product (p185erbB-2) is a transmembrane receptor that demonstrates significant homology to EGFr. Moderate-to-strong immunoreactivity for p185erbB-2 was noted in the luminal as well as the basal cells of PIN lesions. This immunostaining was frequently equivalent in pattern and intensity to that of adjacent malignant cells. The pattern of expression was typically coarse cytoplasmic immunoreactivity. Increased expression of the growth factor-related receptors p185erbB-2 and p180erbB-3, as well as the product of the *c-met* protooncogene (a transmembrane tyrosine kinase receptor that binds the mitogen hepatocyte growth factor/scatter factor), is frequently detected in the dysplastic luminal cells and in malignant cells of the prostate (Myers & Grizzle, 1996). Mutation of the p53 gene in PIN may precede the development of highly aggressive prostate cancer (Myers & Grizzle, 1996). The expression of the nm-23H1 gene product is strongly expressed in dysplastic and malignant prostatic cells (Myers & Grizzle, 1996).

It has been demonstrated that expression of the proliferative markers Ki-67 and proliferating cell nuclear antigen (PCNA) in PIN is increased as compared to benign prostatic epithelium (Myers & Grizzle, 1996). Increased PCNA expression also has been detected in the nuclei of stromal and endothelial cells adjacent to PIN (Myers & Grizzle, 1996). This may be associated with the observation of a higher density of blood vessels in the vicinity of PIN lesions. In contrast to the enhanced expression of the biomarkers associated with proliferation, decreased expression of prostate specific antigen (PSA), prostate acid phosphatase, and Leu 7 by dysplastic luminal cells is indicative of an impairment of the process of cellular differentiation (Myers & Grizzle, 1996). *Bostwick* demonstrated a decrease in the expression of neuroendocrine markers (neuron-specific enolase, serotonin, chromagranin, and human chorionic gonadotropin) in PIN. Aberrant glycosylation as well as inappropriate expression of glycosylated tumor antigens was demonstrated by enhanced binding of the lectin *Ulex europaeus* and by increased expression of tumor-associated

glycoprotein 72 and the Lewis Y antigen (Myers & Grizzle, 1996). Enhanced expression of proteolytic enzymes, such as cathepsin D and the 72-kD form of collagenase IV, by dysplastic cells may represent an integral event in the development of invasive prostate cancer (Boag & Young, 1994). Moderate-to-strong immunoreactivity for fatty acid synthetase was also detected in PIN (Swinnen et al., 2002).

In HGPIN, studies have demonstrated notable loss of the three critical signaling components of the apoptotic action of transforming growth factor- β ; that is, the transmembrane receptor II (T β RII), the key cell cycle inhibitor p27Kip1, and the protagonist downstream Smad4 receptor-activated protein (Zeng & Kyprianou, 2005). Quantitative evaluation of the apoptotic index revealed significantly less value in HGPIN when compared with adjacent areas of benign prostatic hyperplasia (Zeng & Kyprianou, 2005). Apoptotic profiling of HGPIN may contribute to a better understanding of factors that play a role in deregulated prostate growth (Zeng & Kyprianou, 2005).

Prostate carcinogenesis is the result of the accumulation of multiple genetic changes. The most frequently found chromosomal anomalies are overexpression on chromosomes 7p, 7q, and 8q, and inactivation on chromosomes 8p, 10q, 13q, 16q, and 18q (Joniau et al., 2005). Inactivation of tumor suppression genes, such as NKX3-1 (8p) and PTEN (10q), and overexpression of oncogenes, such as c-myc (8q), play an important role in PIN and the initiation of prostate cancer (Qian et al 1995). These findings support the multi-step theory in which PIN is considered a precursor lesion of prostate cancer.

6.3 Similarities between PIN and prostate cancer

The frequency and extent of PIN lesions increase with age, and this is similar to the increase in diagnosis of prostate cancer (Joniau et al., 2005). HGPIN is found significantly more frequently in prostates with cancer (McNeal & Bostwick, 1986). PIN is predominantly located in the peripheral zone of the prostate, the area in which most clinically important prostate cancers are found, and PIN, like prostate cancer, is often multifocal (Joniau et al., 2005). In an autopsy study, HGPIN was found in 63% of cases solely in the peripheral zone; in 36%, in the peripheral and transition zone; and in 1%, solely in the transition zone (Haggman et al., 1997). These findings are similar to the zonal distribution of prostate cancer.

Several genotypic and phenotypic studies have indicated that there are remarkable morphological, molecular, and biochemical similarities between PIN and prostate cancer (Vis & Van Der Kwast, 2001). Molecular abnormalities in PIN are mostly intermediate between benign gland and cancer, reflecting an impairment of cell-differentiation and regulatory control (Bostwick, 1999). PIN is characterized by cellular crowding and stratification. There is inequality in cell and nuclear size. Hyperchromatism is frequently seen with an enlarged nucleus, often containing prominent nucleoli lines. These changes are also seen in Gleason grade 1-4 prostate cancer (Bostwick et al., 1998). Biochemically, the cells of PIN show changes in the cytoskeletal proteins, secretory proteins, and nuclei that are shared with established prostate malignancies.

Prostate cancer and HGPIN have similar proliferative and apoptotic indices (Bostwick et al., 1998). Mitotic figures and apoptotic bodies increase progressively from nodular hyperplasia to HGPIN (Bostwick et al., 1998). During the malignant transformation of PIN, the basal cell

layer loses its proliferative function, which is transferred to secretory luminal cell types, as demonstrated by Bonkhoff (Bonkhoff, 1996). Moreover, there is a progressive increase in the number of apoptotic bodies from nodular hyperplasia through PIN to prostate cancer (Bostwick et al., 1996). Greater cytoplasmic expression of bcl-2 is observed in PIN and cancer than in benign and hyperplastic epithelium (Bostwick et al., 1996). Two members of the platelet-derived growth factor (PDGF) peptide family, PDGF-A and PDGF- α , are up-regulated in PIN and prostate cancer compared with benign prostatic hyperplasia; BPH (Bostwick et al., 1996). Similarly, there is up-regulation of cathepsinD in PIN and prostate cancer; this autocrine mitogen, which has been studied extensively in other organs as a marker of invasion, correlates with tumor grade and DNA ploidy status in prostate cancer (Bostwick et al., 1996).

Histologically, the atypia observed in HGPIN is virtually indistinguishable from that of prostate cancer except that in HGPIN the basal membrane is still intact (Sakr et al., 1999). As HGPIN progresses, the likelihood of basal cell layer disruption increases. In HGPIN, the basal cell layer is disrupted or fragmented as demonstrated by high-molecular-weight cytokeratin immunolabeling. In prostate cancer, there is a complete loss of the basal cell layer. Both in PIN and prostate cancer, collagenase type IV expression is increased compared to normal prostate epithelium; this enzyme is responsible for basal membrane degradation and thus facilitates invasion (Bostwick et al., 1996). PIN and prostate cancer share several nuclear properties, such as amount of DNA, chromatin texture, chromatin distribution, nuclear perimeter, diameter, and nuclear abnormalities (Baretton et al., 1994).

Several genetic changes encountered in prostate cancer cells can be found in PIN lesions (Bostwick et al., 1996). Allelic loss is common in PIN and prostate cancer (Sakr et al., 1999). The frequent 8p12-21 allelic loss commonly found in prostate cancer is also found in microdissected PIN. Other examples of genetic changes found in prostate cancer that already exist in PIN include loss of heterozygosity at 8p22, 12pter-p12, and 10q11.2 and gain of chromosomes 7, 8, 10, and 12. Alterations in oncogene bcl2 expression and RER+ phenotype are similar for PIN and prostate cancer (Baltaci et al., 2000). As in prostate cancer, there is also evidence of aneuploidy and an increase in microvascular density, both frequently regarded as evidence of aggressiveness in PIN (Montironi et al., 1993).

6.4 LGPIN

In LGPIN (Fig. 3), secretory cells of the lining epithelium proliferate and “pill up” with irregular spaces between them (Bostwick, 2000 ; Newling, 1990). The nuclei are enlarged, vary in size, have normal or slightly increased chromatin content, and possess small or inconspicuous nucleoli (Zeng & Kyprianou, 2005). More prominent nucleoli, when observable, comprise less than 10% of dysplastic cells. The basal cell layer normally surrounding secretory cells of ducts and acini remains intact. In LGPIN, only 0.7% of reported cases reveal evidence of basal cell layer disruption (Newling, 1999).

LPIN is rather difficult to recognize, as it shares common features with normal and hyperplastic epithelium (Bostwick, 2000; Newling, 1999). The most common issue that may lead in some cases to discrepant diagnoses between LGPIN and HGPIN is the definition of “prominent” with regard to nucleolar enlargement and visibility.

It has been suggested that LGPIN should not be commented on in diagnostic reports (Epstein, 2002). Firstly, pathologists cannot reproducibly distinguish LGPIN from benign prostate tissue (Epstein et al., 1995). Secondly, when LGPIN is diagnosed on needle biopsy, these patients are not at greater risk of having prostate cancer on repeat biopsy (Keetch, 1995).

The distinction between HGPIN and LGPIN is based primarily on the extent of cytological abnormalities (prominence of the nucleoli) and secondarily on the degree of architectural complexity (Goeman et al., 2003; Weinstein & Epstein, 1993). Immunostaining studies of microvessel density may help to differentiate HGPIN from LGPIN (Sinha et al., 2004).

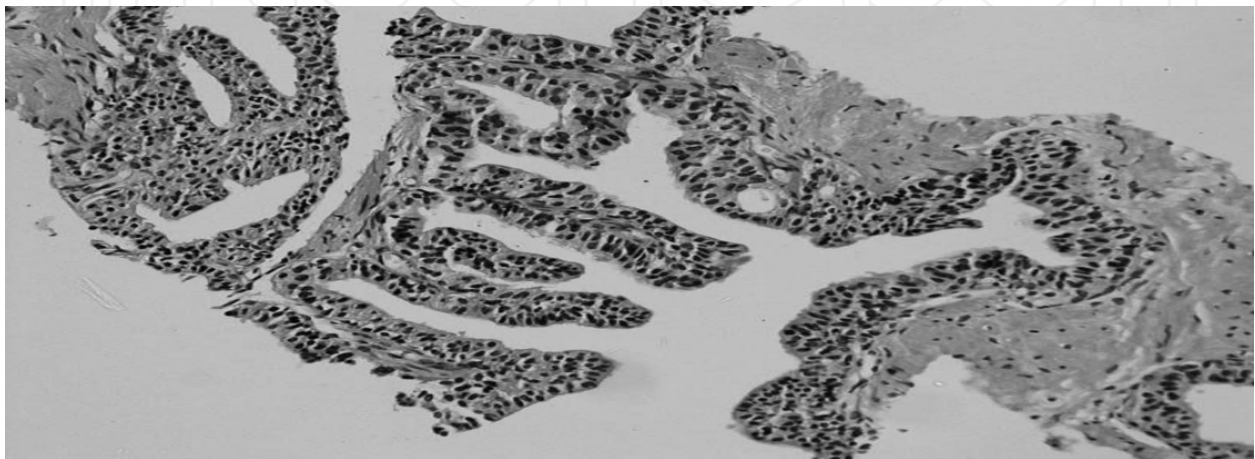


Fig. 3. Papillary structures within a large hyperplastic prostate gland. Minimal nuclear atypia. (HE \times 200)

6.5 HGPIN

6.5.1 Why HGPIN?

PIN was initially divided into three different grades (I-III), which now are reduced to the abovementioned LGPIN for PIN I, and HGPIN for PIN II and III. HGPIN includes PIN II and III for two reasons. Firstly, there was a great deal of inter-observer variability in the distinction between PIN II and III (Epstein et al., 1995). Secondly, the finding of PIN II or III on needle biopsy was associated with the same risk of prostate cancer on subsequent biopsy (Weinstein & Epstein, 1993).

6.5.2 Histology of HGPIN

In HGPIN, uniform morphologic abnormalities are detectable (Vis & Van Der Kwast, 2001). Cells have large nuclei of relatively uniform size, and possess prominent nucleoli that are similar to those of cancer cells (fig. 4, 5). Regarding cytological features, the acini and ducts are lined by malignant cells which are uniformly enlarged with an increased nuclear/cytoplasmic ratio, and with less variation in nuclear size in comparison to LGPIN. In HGPIN, at least 10% of cells demonstrate prominent nucleoli similar to those of carcinoma cells, and the majority of cells show coarse clumping of the chromatin which may be accentuated along the nuclear membrane (Vis & Van Der Kwast, 2001). The expanded nuclear chromatin area probably explains the darker "blue" appearance of the lining which

characterizes HGPIN at low power microscopic examination. Nuclei toward the centre of the gland tend to have blander cytology than peripherally located nuclei.

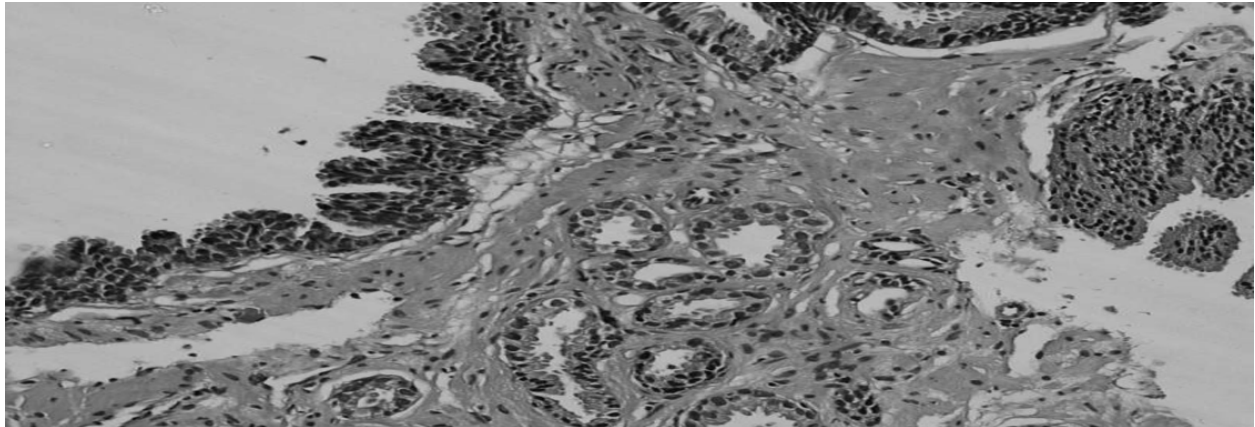


Fig. 4. HGPIN tufted pattern and adjacent carcinoma (with an adequate number of small malignant glands). Small atypical glands are too numerous to represent outpouchings of HGPIN. (HE \times 200)

6.5.3 Patterns of HGPIN

There are four architectural patterns of HGPIN: tufting, micropapillary, flat and cribriform, based on the arrangement of the cells within pre-existing ducts or glands (Vis & Van Der Kwast, 2001). Tufting HGPIN is by far the most common pattern (present in 97% of all HGPINs) followed by micropapillary, flat, and cribriform patterns (Yamauchi et al., 2006). In the flat pattern, nuclear atypia is evident without significant architectural changes. In the tufting pattern, nuclei become more piled up, and undulating mounds of cells are formed. Columns of atypical epithelial cells typically lacking fibrovascular cores characterize the micropapillary pattern. In the cribriform pattern, more complex architectural features, such as a “Roman bridge” and cribriform formation, are encountered.

Patients with HGPIN in only one initial biopsy or a predominant flat/tufting pattern clearly have less risk of cancer being found in subsequent biopsies compared to patients with HGPIN in more than one initial biopsy. Furthermore, a micropapillary and/or cribriform pattern are correlated with a greater risk for development of prostate cancer (Joniau et al., 2005).

Unusual subtypes of HGPIN include PIN with signet-ring morphology and neuroendocrine cells with either Paneth cell-like or small-cell morphology (Bostwick et al., 1993; Vis & Van Der Kwast, 2001). Intraductal HGPIN, in prostates with established cancer, has been associated with high tumor volumes, poorly differentiated tumor components, and a higher progression rate after radical prostatectomy than prostate cancers without these coexisting proliferations (Cohen et al., 2000; McNeal & Bostwick, 1986). Hence, a separate histological entity was proposed, namely, intraductal carcinoma of the prostate, which would be distinguished from HGPIN.

6.5.4 HGPIN and prostate cancer

HGPIN is the most likely precursor of prostatic adenocarcinoma, according to current literature (Dovey et al., 2005; Gaudin et al., 1997; Joniau et al., 2005; Lefkowitz et al., 2002; Pacelli & Bostwick, 1997; Powell et al., 2010; Singh et al., 2009; Vis & Van Der Kwast, 2001). The expression of various biomarkers in HGPIN is either the same as with prostate cancer or intermediate between prostate cancer and benign prostate tissue. The cytological changes are characterized by prominent nucleoli in a substantial proportion ($\geq 5\%$) of cells, nuclear enlargement and crowding, increased density of cytoplasm, and anisonucleosis (Vis & Van Der Kwast, 2001). Ploidy seems not to discriminate between HGPIN and infiltrating cancer (Baretton et al., 1994). Also, studies reveal consistent down-regulation of epithelial cell adhesion molecules and transmembrane proteins in PIN (Vis & Van Der Kwast, 2001). This is accompanied by up-regulation of enzymes responsible for degradation of the extracellular matrix.

Unlike in prostate cancer, incomplete disruption of the basal cell layer can be shown by 34 β E12 cytokeratin immunostaining (Vis & Van Der Kwast, 2001). In HGPIN, more than 50% of abnormal cells are seen to have a disrupted basal cell layer in the acini. Immunohistochemistry is usually not helpful since the lack of a basal cell layer in only a few cribriform or small glands is not sufficient for the diagnosis of cancer. However, in cases where many glands are totally immunonegative for high-molecular-weight cytokeratin, these foci may be diagnostic of cancer. Cases where some of the glands show the expected patchy basal cell layer of PIN and a few, morphologically identical glands are negative for high-molecular-weight keratin should still be diagnosed as HGPIN. In rare cases when sperm can be identified in the glandular lumen, the diagnosis of PIN is favored because only PIN glands are able to communicate with the main prostatic glands that contain sperm; malignant invasive glands cannot retain their continuity with main prostatic glands (Vis & Van Der Kwast, 2001).

In cases of HGPIN with neighboring small atypical glands, the possibility of coexistent invasive carcinoma should be examined (Vis & Van Der Kwast, 2001). When the latter are few, the issue is whether the small glands represent outpouchings or tangential sections of the adjacent HGPIN or whether they represent microinvasive cancer. When these small atypical glands are too many or too crowded to be outpouchings or tangential sections of the HGPIN glands, then the diagnosis of invasive carcinoma can be made (Bostwick et al., 1996).

6.6 Differential diagnosis of PIN

Histologically, PIN can be confused with several benign entities as well as with ductal and acinar adenocarcinoma (fig. 5) of the prostate (Epstein et al., 2002). Benign conditions include prostate central zone hyperplasia, since glands within the central zone at the base of the prostate are complex and large with many papillary infoldings and clear cell cribriform hyperplasia, which consists of crowded cribriform glands with clear cytoplasm (Vis & Van Der Kwast, 2001; Joniau et al., 2005). Both these entities lack significant nuclear atypia. The basal cell layer can display prominent nucleoli but secretory cells can be recognized. Cytologically atypical basal cell hyperplasia usually forms small solid nests of atypical basal

cells, mainly in the central zone; these are inconsistent with PIN, which affects medium- or large-sized glands, mainly in the peripheral zone of the prostate (Vis & Van Der Kwast, 2001). In any case, basal cells can be easily identified by immunohistochemistry either with antibodies against high-molecular-weight cytokeratins (cytoplasmic staining pattern) or against p63 (nuclear staining pattern).

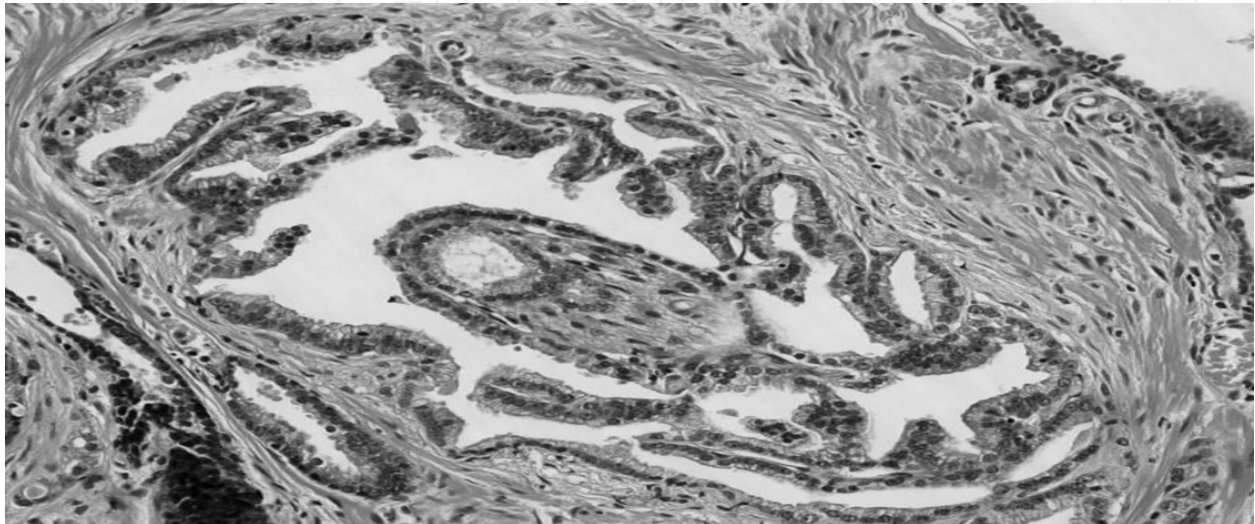


Fig. 5. Complex atypical gland with prominent nucleoli and perineural invasion. Gleason pattern 3 of cribriform adenocarcinoma. Note the coexistent microacinar cancerous pattern on the bottom right. (HE \times 200)

With regard to malignant conditions, cribriform acinar adenocarcinoma can be discriminated from cribriform HGPIN when a sufficient number of cribriform glands totally lack basal cells (Vis & Van Der Kwast, 2001). Furthermore, in cribriform carcinoma, sometimes the appearance of foci of back-to-back glands, rather than true cribriform formations, is evident.

Ductal adenocarcinomas of the prostate may demonstrate a patchy basal cell layer (like PIN), but they develop in the transition zone. They may develop true papillary fronts with fibrovascular cores (in contrast to micropapillary PIN). Ductal adenocarcinoma glands are larger, may contain back-to-back glands, may show extensive comedonecrosis, and are usually fragmented in needle biopsy specimens.

Finally, the possibility of intraductal carcinoma (fig. 6) should be considered when multiple cribriform glands with prominent cytological atypia containing comedonecrosis are encountered (Cohen et al., 2000; McNeal & Bostwick, 1986). In these glands, basal cells can be identified, though this lesion should be distinguished from HGPIN since it appears to be a late event in prostate gland carcinogenesis and warrants immediate therapy.

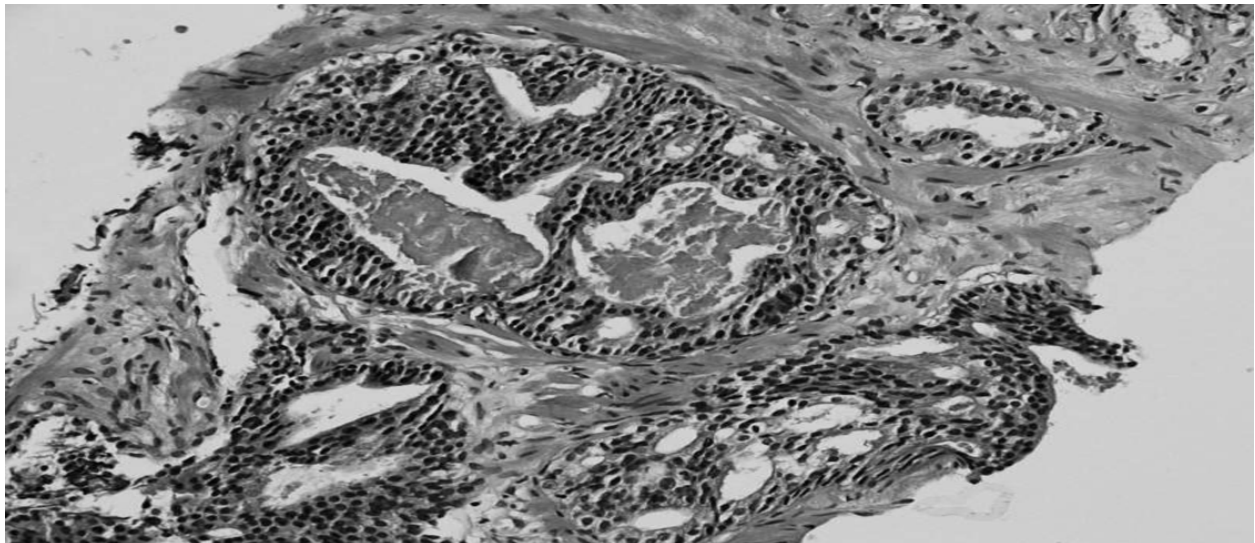


Fig. 6. Many large atypical cribriform glands with extensive comedonecrosis. Retention of basal cell layer remnants would be consistent with intraductal carcinoma rather than HGPIN. (HE \times 200)

6.7 Clinical markers of PIN

6.7.1 PSA

PIN lesions do not contribute to an elevation of serum PSA, PSA density, or a decrease in the free-to-total PSA ratio (Alexander et al., 1996; Darson et al., 1999; Ronnett et al., 1993). PIN lesions show less expression of PSA in luminal cells, as determined by immunohistochemistry, than do benign epithelial glands (Ronnett et al., 1993; Alexander et al., 1996). An elevation of PSA should be attributed to the presence of prostate cancer, BPH, or concurrent prostatic inflammation rather than to the presence of PIN.

Immunohistochemical studies show a lower PSA expression in PIN lesions compared to benign tissue and prostate cancer (Darson et al., 1999). PSA produced by PIN lesions follows the route of least resistance and is excreted in the seminal fluid, whereas cancer forms tissue islands without a surrounding basal layer, and PSA diffuses into the blood.

6.7.2 Potential markers

Swinnen demonstrated that fatty acid synthetase immunostaining intensity tended to increase from LGPIN to HGPIN and prostate cancer (Swinnen et al., 2002). This key enzyme in the de novo production of fatty acids enables cancer progression and invasion. Another enzyme, alpha-methylacyl coenzyme A racemase (AMARC), which plays a key role in the beta-oxidation of fatty acids, is rarely expressed in benign prostatic tissue, in contrast to PIN and prostate cancer (Rubin et al., 2002). A statistically significant association of this biomarker with the risk of prostate cancer is yet to be revealed (Hailemariam et al., 2011). A80, a membrane-bound glycoprotein that is related to exocrine differentiation, may be useful in detecting residual and/or recurrent prostate carcinoma after radiation or hormonal therapy (Coogan et al., 2003). Benign glands are generally negative for A80 except for scattered positive cells in about 15% of glandular hyperplasia (Shin et al., 1989). *Coogan*

demonstrated that A80 immunostaining in prostate cancer, HGPIN, and LGPIN, in 100%, 92%, and 73% of the examined specimens, respectively (Coogan et al., 2003). Markers including kallikrein-related peptidase 2 (KLK2), early prostate cancer antigen (EPCA), PCA3, hepsin, prostate stem cell antigen are under investigation for the early diagnosis and management of prostate cancer (Darson et al., 1997; Sardana et al., 2008). PCA3 is a prostate specific, non-protein coding RNA that is significantly over expressed in prostate cancer, without any correlation to prostatic volume and/or other prostatic diseases like prostatitis. Recent studies have shown the potential of PCA3, in correlation with other markers, to be used as a prognostic marker for prostate cancer (Bourdoumis et al., 2010).

6.8 Management of PIN

6.8.1 Repeat prostate biopsy

As a consequence of programs for the early detection of prostate cancer, the number of biopsies performed and specimens evaluated has increased substantially. False-positive results may strongly influence a man's quality of life through unnecessary psychological stress, unnecessary treatment, and treatment-associated morbidities. Furthermore, for medico-legal reasons, it is obvious that biopsy false-positive results should be minimized. Currently, the consensus is that the finding of focal atrophy, PAH, AAH, or LGPIN on needle biopsy or in TURP material for BPH should not lead to any diagnostic follow-up (Vis & Van Der Kwast, 2001). However, the finding of HGPIN on needle biopsy indicates a field effect by which the entire prostate is at higher risk of harboring cancer (Langer et al., 1996).

The decisions for diagnostic follow-up in men with PIN should take into account the patient's age, physical status, and co-morbidities. In men developing HGPIN in the eighth decade, knowing that the development of symptomatic prostate cancer will probably occur only after 10 years, a policy of watchful waiting should be recommended. (Ravery V, 2009; Vis AN & Van Der Kwast TH, 2001) Men who may not potentially benefit from curative treatment or early hormonal therapy should not undergo follow-up biopsy.

When more extensive repeat biopsy is performed, the likelihood of detecting prostate cancer is increased. If isolated HGPIN is detected in a 12-core biopsy protocol, the cancer incidence in the immediate 12-core repeat biopsy will be only 2% to 3% (Lefkowitz, 2002). In contrast, in repeat biopsies following initial sextant or octant biopsies, the cancer detection rate is 27–30% (Lefkowitz, 2002). However, taking too many biopsies can increase the risk of detecting too many clinically insignificant cancers and can lead to overtreatment (Joniau et al., 2005). Authors have proposed an 8-biopsy regimen, which clearly outperformed the sextant regimen in cancer detection (Joniau et al., 2005; Lefkowitz, 2002).

When follow-up biopsies are performed in men with foci of isolated HGPIN, the site of prostate cancer may not be the same site that raised the suspicion of concurrent carcinoma (Bostwick et al., 1995). The finding of HGPIN after TURP (2.8%-33%) also appears to place men at a higher risk of harboring cancer, although there are few studies on this topic (Gaudin et al., 1997; Pacelli & Bostwick, 1997). It is reasonable to perform needle biopsies on patients, especially younger men, who have HGPIN after TURP.

It has been demonstrated that patients with a flat or tufting HGPIN pattern on initial biopsy clearly have less risk of cancer being found in subsequent biopsy (20%), in comparison with

patients with micropapillary or cribriform pattern, who have a relative risk of 70% (Chan & Epstein, 1999). The isolated finding of HGPIN in the cystoprostatectomy specimen has no clinical implications, and the prognosis of the patient is determined by the initial indication (e.g. invasive bladder cancer) for surgery.

The jury is still out concerning the best repeat biopsy strategy following the diagnosis of PIN on initial prostate biopsy. The length of the interval still needs to be established in large prospective studies (Joniau et al., 2005). Repeat biopsy six weeks after the initial biopsy has led to the diagnoses of prostate cancer in 9% of cases with isolated HGPIN (Chan & Epstein, 1999; Ellis & Brawer, 1995; Kronz et al., 2001; O'Dowd et al., 2000). The risk for finding prostate cancer in repeat biopsies seems to increase with the length of the biopsy interval. Age, PSA, and HGPIN were independent predictors for prostate cancer in repeat biopsies, with HGPIN providing the highest risk ratio (Chan & Epstein, 1999; Langer et al., 1996; Sakr et al., 1996). Most urologists recommend follow-up biopsy after 6–12 months, followed by regular PSA monitoring and repeat biopsies as indicated (Shepherd et al., 1996). Men within screening settings who are diagnosed with isolated HGPIN should be followed at regular intervals, and if clinical suspicion persists, the biopsy should be repeated (Ellis & Brawer, 1995; Kronz et al., 2001; Shepherd et al., 1996). The finding of intraductal HGPIN on initial biopsy needs further investigation with repeat biopsy, because this lesion is related to potentially aggressive cancer.

6.8.2 Chemoprevention

Examples of treated premalignant lesions include cervical intraepithelial neoplasia, ductal CIS (carcinoma *in situ*) of the breast, adenomatous polyps of the colon, and Barrett's esophagus (Sporn, 1999). The American Association for Cancer Research designates intraepithelial neoplasia an important target for chemoprevention (O'Shaughnessy et al., 2002). As HGPIN precedes the development of prostate cancer by several years and is easy identifiable, it is a candidate for chemoprevention. Chemoprevention means the administration of drugs or agents aimed at preventing the initiation and progression of cancer. A number of potential preventive agents have been investigated in patients with HG-PIN, including hormones (flutamide, finasteride, leuprolide acetate) and antioxidants such as lycopene, selenium, and catechins. An association between the E-cadherin/catenin complex and high-grade prostate cancer has been proved and the therapeutic potential of integrin antagonists is being evaluated by ongoing clinical trials with promising results (Drivalos et al., 2011). One of the most promising chemoprevention drugs is the selective oestrogen receptor modulator toremifene citrate (Ravery, 2009). Recognizing the slow growth rate of prostate cancer and the considerable amount of time needed in animal and human studies for adequate follow-up, the noninvasive precursor lesion PIN is a suitable intermediate histological marker to indicate high likelihood of subsequent prostate cancer. HGPIN offers promise as an intermediate endpoint in studies of chemoprevention of prostate cancer (Montironi et al., 1999). Hence, HGPIN is a suitable intermediate histological marker to indicate subsequent likelihood of cancer and it may be worth monitoring young men with a high risk of developing HG-PIN in the future as potential targets for chemoprevention rather than focusing only on chemoprevention in the high-risk HG-PIN patient group (Ravery, 2009).

Anti-androgens (e.g. flutamide) induce the regression of prostatic epithelium by enhancing apoptosis, suppressing proliferative activity, and inhibiting angiogenesis in BPH, PIN, and prostate cancer (Montironi et al., 1994). PIN is ablated by androgen deprivation therapy, as a result of accelerated apoptosis with subsequent exfoliation of cells into the glandular lumens (Montironi et al., 1994). Studies have documented that angiogenesis in the surrounding stroma of HGPIN glands is severely decreased via suppression of vascular endothelial growth factor (VEGF) production after androgen deprivation therapy (Papatsoris & Papavassiliou, 2001). A marked decrease in the extent and prevalence of HGPIN occurs in patients treated with anti-androgens in comparison to untreated patients (Bostwick & Qian, 1999). It has been suggested that anti-androgens might halt or reverse the process of carcinogenesis and prevent the transition of HGPIN to overt prostate cancer (Bostwick & Qian, 1999; Lieberman et al., 2001; Montironi et al., 1994; van der Kwast et al., 1999). The observed morphological changes (cytoplasmic clearing, prominent glandular atrophy, decreased ratio of glands to stroma) are reversible, and HGPIN lesions recover rapidly. However, it is unclear whether the histopathologic changes of anti-androgen treatment are clinically important (Lieberman et al., 2001; van der Kwast et al., 1999). Yamauchi demonstrated that the anti-androgen bicalutamide permitted the persistence of PIN after effective chemoprevention of microscopic prostate cancer in a rat model (Yamauchi et al., 2006). Moreover, there is a risk for amplification of the androgen-receptor (AR) gene in androgen-deficient conditions, as in cases of hormone-refractory prostate cancer (Koivisto et al., 1999). The blockage of 5-alpha reductase with finasteride does not seem to have any effect on the incidence of PIN (Yang et al., 1999). In addition to the above, the role of Ras/mitogen-activated protein kinase (MAPK) in prostate cancer, as well as the therapeutic potential of Ras/map inhibitors are currently under investigation (Papatsoris et al., 2007). Furthermore, it has been demonstrated that men with no evidence of prostate cancer on initial biopsy who were pretreated with finasteride had a significantly greater prostate cancer detection rate at one year than had men in the control group; 30% versus 4% (Cote et al., 1998).

Besides anti-androgens, other drugs (e.g. anti-angiogenics agents) and nutritional supplements (e.g. vitamin D, selenium) have been applied in ongoing chemoprevention trials (Montironi et al., 1994). In a prospective trial evaluating the effects of selenium-vitamin E-isoflavonoid supplement in 100 men with isolated HGPIN in octant biopsies, PSA decreased in a large subgroup (64%). In this subgroup, the overall risk of detecting cancer was 24.5%, compared to 55.6% in a smaller subgroup of patients in whom the PSA continued to rise under supplements (Joniau et al., 2005). Bettuzzi administered green tea catechin (GTC) in men with HGPIN and demonstrated that GTC is safe and very effective (Bettuzzi et al., 2006). In particular, after one year, only one prostate cancer was diagnosed among the 30 GTC-treated men (3%), whereas nine cancers were found among the 30 placebo-treated men (30%).

Studies suggest that administration of the nerve-growth factor (NGF) induces a reversion of the androgen-independent / androgen-receptor negative prostate cancer cell lines to a less malignant phenotype, which raises thoughts for a new perspective in prostate cancer therapy (Papatsoris et al., 2007). Moreover, deregulation of the IGF-1/IGF-1-receptor axis has been linked to progression of prostate cancer to androgen independence and new therapeutic possibilities are currently under research (Papatsoris et al., 2005).

The ideal agent and duration of therapy remains to be defined. The selective alpha-estrogen receptor modulator toremifene was investigated in HGPIN. Studies using the transgenic adenocarcinoma of mouse prostate model (TRAMP) and this anti-estrogen demonstrated a reduction in the incidence of HGPIN and prostate cancer, along with an increase in animal survival (Raghow et al., 2002). The statistically significant reduction in the incidence of prostate cancer and the tolerability profile support toremifene's promise as a chemopreventive agent.

Although small, high-risk population trials will remain the key to the early evaluation of novel chemoprevention agents, large-scale, population-based clinical trials will still be necessary to ensure that valid recommendations are made to men regarding chemoprevention. Until the efficacy of chemopreventive agents is confirmed in well-conducted, randomized, controlled studies, there should be a reluctance to offer chemopreventive agents to men with isolated HGPIN on initial biopsy.

6.8.3 Radical prostatectomy and radiotherapy

HGPIN is sometimes associated with a PSA above normal levels; in other words, in these cases, HGPIN could be regarded as T1c prostate cancer (Newling, 1999). The firm evidence that within six months of the first biopsy showing HGPIN, invasive prostate cancer would be diagnosed in 60% of the cases has made some urologists offer radical prostatectomy to this group of patients (Newling, 1999). Nowadays, radical prostatectomy is not regarded as appropriate therapy for the management of patients with HGPIN (Davidson et al., 1995; Montironi et al., 2002; Newling, 1999). It seems logical that malignant histological changes should be seen before such radical therapy is offered. It has been recently shown that PSA and HGPIN focality at biopsy do not enhance cancer predictivity, thus patients who underwent prostate biopsy with a HGPIN diagnosis do not seem to need any different follow-up rebiopsy strategy than patients with a diagnosis of BPH (Gallo et al., 2008).

The prevalence and extent of PIN lesions decreases significantly after radiation therapy. Following such therapy, PIN retains the typical characteristics of untreated PIN and is readily recognized on histopathology (Cheng et al., 1999). The question remains if recurrence after radiation therapy is due to the growth of incompletely eradicated tumor or progression of incompletely eradicated PIN.

6.8.4 Potential anti-PIN agents

- a. **Anti-Angiogenesis Agents.** The changes that occur in HGPIN leading to focal carcinoma include neo-angiogenesis; hence, the use of the anti-angiogenesis agent's thalidomide and platelet growth factor 4 could be important therapeutic interventions (Papatsoris et al., 2005).
- b. **Differentiation Factors.** Retinoids and vitamin D analog are known to improve differentiation of epithelial cells, including prostate epithelium. The development of invasiveness, as seen in HGPIN, is characterized by loss of adhesion facility and dedifferentiation with aneuploid nuclear characteristics; these processes may be sensitive to retinoids or vitamin D analogs (Papatsoris et al., 2005; Banach-Petrosky et al, 2006; Kelloff et al., 1999). Gene therapy and immunotherapy are still experimental in prostate cancer and HGPIN. Serial examination of prostate biopsies and subsequent prostatectomy specimens may give an indication of the effectiveness of these agents.

- c. **Epigenetic Therapeutics** (*Histone Deacetylase Inhibitors, Hypomethylating Agents*). Epigenetic events, such as histone acetylation/deacetylation and aberrant DNA methylation, represent crucial steps in prostate cancer development, which cause alterations in gene expression (e.g. silencing tumor suppressor genes) without changes in the DNA coding sequence (Kopelovich et al., 2003). Epigenetic changes can be reversed by the use of small molecules, such as histone deacetylase (HDAC) inhibitors and hypomethylating agents. Histones are core protein components of nucleosomes, and their acetylation status regulates gene expression. Deacetylated histones are generally associated with silencing gene expression (Marks et al., 2001). HDAC inhibitors have been shown to induce expression of genes linked to growth inhibition and cellular differentiation. Several phase I trials with these agents are ongoing in patients with prostate cancer and/or PIN (Sandor et al., 2002).

A mechanism to switch off tumor suppressor genes is controlled by a chemical modification known as DNA methylation, a normal cellular process whereby cytosines in the DNA become methylated by the enzyme DNA methyltransferase to give 5-methylcytosine (Kang et al., 2004). However, in cancer cells, the methylation process is deregulated, and many genes, including tumor suppressor genes, become abnormally methylated at cytosine bases. Moreover, it seems that aberrant methylation causes recruitment of HDAC, resulting in a more potent transcriptional inhibition of target genes (Patra et al., 2001). Many studies have demonstrated epigenetic silencing of crucial genes, for example, AR, PTEN, and RAR β , during prostate carcinogenesis (Yamanaka et al., 2003). Novel hypomethylating agents are in various stages of experimental and clinical development.

7. Epilogue

Recurrent chromosomal rearrangements have not been well characterized in prostate cancer (Papatsoris et al., 2007). *Tomlins* used a bioinformatics approach to discover candidate oncogenic chromosomal aberrations on the basis of outlier gene expression, followed by RNA ligase-mediated rapid amplification of cDNA ends and sequencing (Tomlins et al., 2005). The authors identified recurrent gene fusions of the 5-prime untranslated region of TMPRSS2 to two ETS transcription factors, ERG or ETV1, in prostate cancer tissues with outlier expression. By using FISH, they demonstrated that 23 of 29 prostate cancer samples harbored rearrangements in ERG or ETV1. Cell line experiments suggested that the androgen-responsive promoter elements of TMPRSS2 mediate the overexpression of ETS family members in prostate cancer. *Yoshimoto* demonstrated that the occurrence of these genetic events, along with Pten haploinsufficiency, in patients with prostate cancer has a significant clinical impact (Yoshimoto et al., 2008). Most importantly, the identification of ERG as a cooperative initiation event in prostate tumorigenesis suggests that ERG targeted therapies, when feasible, may be effective at preventing the transition between HGPIN and invasive cancer, while pharmacological manipulation of the PTEN/PI3K/AKT pathway may represent a powerful chemopreventive and chemotherapeutic tool in the future (Carver et al., 2009). Surprisingly, the above-mentioned translocation was found in about 70–80% of prostate cancers, but not in HGPIN. Finally, the diagnosis of prostate cancer on needle biopsy has been refined because of the recent discovery of AMARC, which preferentially labels prostate adenocarcinoma (Epstein, 2006). Also, in a recent peer review *Epstein* outlined several recommendations when diagnosing PIN or atypical foci suspicious for carcinoma in needle biopsies (Epstein & Herawi, 2006).

In conclusion, prostate cancer precursor lesions include mainly AAH and PIN (Chrisofos et al., 2007). LSC is not considered a precursor lesion of prostate cancer but shares with PIN the increased risk of diagnosing a definite cancer in subsequent biopsies. LGPIN should not be reported by pathologists due to poor inter-observer reproducibility and a relatively low risk of cancer following re-biopsy. The average incidence of HGPIN or LSC on initial needle biopsy is 6%. Following the diagnosis of HGPIN, the risk of cancer is not statistically higher compared with the risk of cancer following a benign diagnosis. Studies have shown that the risk for cancer after HGPIN diagnosis was not higher than the risk reported after diagnosis of BPH (Gallo et al., 2008). In contrast, the average risk of cancer following a diagnosis of LSC is 40%, and such patients should be re-biopsied within three to six months. Cases diagnosed as LSC have the highest likelihood of being changed upon expert review. Potential markers of prostate cancer precursor lesions include fatty acid synthetase, AMARC, and A80. However, clinical and pathological parameters do not help to stratify which men are at greater risk for a cancer diagnosis. Repeat biopsy should include increased sampling of the initial precursor lesion and adjacent ipsilateral and contralateral sites, with routine sampling of all sextant sites. Radical prostatectomy and radiotherapy are not recommended for the management of patients with HGPIN. Until the efficacy of chemopreventive agents is confirmed in well-conducted, randomized, controlled studies, there should be a reluctance to offer such agents to men with prostate cancer precursor lesion on initial biopsy.

8. References

- Alexander EE, Qian J, Wollan PC, Myers R, Bostwick DG. Prostatic intraepithelial neoplasia does not appear to raise serum prostate-specific antigen concentrations. *Urology* 1996; 47: 693–698.
- Amin MB, Tamboli P, Varma M, Srigley JR. Postatrophic hyperplasia of the prostate gland: a detailed analysis of its morphology in needle biopsy specimens. *Am J Surg Pathol* 1999; 23: 925–931.
- Anton RC, Kattan MW, Chakraborty S, Wheeler TM. Postatrophic hyperplasia of the prostate: lack of association with prostate cancer. *Am J Surg Pathol* 1999; 23: 932–936.
- Baltaci S, Orhan D, Ozer G, Tolunay O, Gogous O. Bcl-2 proto-oncogene expression in low- and high- grade prostatic intraepithelial neoplasia. *BJU Int* 2000; 85: 155–159.
- Banach-Petrosky W, Ouyang X, Gao H, Nader K, Ji Y, Suh N, DiPaola RS, Abate-Shen C. Vitamin D inhibits the formation of prostatic intraepithelial neoplasia in Nkx3.1;Pten mutant mice. *Clin Cancer Res* 2006; 12: 5895–5901.
- Baretton GB, Vogt T, Blasenbreu S, Lohrs U. Comparison of DNA ploidy in prostatic intraepithelial neoplasia and invasive carcinoma of the prostate: an image cytometric study. *Hum Pathol* 1994; 25: 506–513.
- Berney DM, Fisher G, Kattan MW et al. Pitfalls in the diagnosis of prostatic cancer: retrospective review of 1791 cases with clinical outcome. *Histopathology* 2007; 51: 452–457.
- Bettuzzi S, Brausi M, Rizzi F, Castagnetti G, Peracchia G, Corti A. Chemoprevention of human prostate cancer by oral administration of green tea catechins in volunteers with high-grade prostate intraepithelial neoplasia: a preliminary report from a one-year proof-of-principle study. *Cancer Res* 2006; 66: 1234–1240.

- Billis A. Prostatic atrophy: an autopsy study of a histologic mimic of adenocarcinoma. *Mol Pathol* 1998; 11: 47-54
- Boag AH, Young ID. Increased expression of the 72-kd type IV collagenase in prostatic adenocarcinoma. Demonstration by immunohistochemistry and in situ hybridization. *Am J Pathol* 1994; 144: 585-591.
- Bonkhoff H. Role of the basal cells in premalignant changes of the human prostate: a stem cell concept for the development of prostate cancer. *Eur Urol* 1996; 30: 201-205.
- Bostwick DG, Qian J. Effect of androgen deprivation therapy on prostatic intraepithelial neoplasia. *Urology* 582 (Suppl 1): S91-S93.
- Bostwick DG, Brawer MK. Prostatic intra-epithelial neoplasia and early invasion in prostate cancer. *Cancer* 1987; 59: 788-794.
- Bostwick DG. Prostatic intraepithelial neoplasia (PIN). *Urology* 1989; 34(Suppl 6): S16-S22.
- Bostwick DG, Amin MB, Dundore P, Marsh W, Schultz DS. Architectural patterns of high-grade prostatic intraepithelial neoplasia. *Hum Pathol* 1993; 24: 298-310.
- Bostwick DG, Dousa MK, Crawford BG, Wollan PC. Neuroendocrine differentiation in prostatic intraepithelial neoplasia and adenocarcinoma. *Am J Surg Pathol* 1994; 18: 1240-1246.
- Bostwick DG, Qian J. Atypical adenomatous hyperplasia of the prostate. Relationship with carcinoma in 217 whole-mount radical prostatectomies. *Am J Surg Pathol* 1995; 19: 506-518.
- Bostwick DG, Qian J, Frankel K. The incidence of high grade prostatic intraepithelial neoplasia in needle biopsies. *J Urol* 1995; 154: 1791-1794.
- Bostwick DG. Prospective origins of prostate carcinoma. Prostatic intraepithelial neoplasia and atypical adenomatous hyperplasia. *Cancer* 1996; 78: 330-336.
- Bostwick DG, Pacelli A, Lopez-Beltran A. Molecular biology of prostatic intraepithelial neoplasia. *Prostate* 1996; 29: 117-134
- Bostwick DG, Shan A, Qian J, Darson M, Maihle NJ, Jenkins RB, Cheng L. Independent origin of multiple foci of prostatic intraepithelial neoplasia: comparison with matched foci of prostatic carcinoma. *Cancer* 1998; 83: 1995-2002.
- Bostwick DG. Prostatic intraepithelial neoplasia is a risk factor for cancer. *Semin Urol Oncol* 1999; 17: 187-198.
- Bostwick DG, Cheng L. Overdiagnosis of prostatic adenocarcinoma. *Semin. Urol. Oncol.* 1999; 17: 199-205
- Bostwick DG. Prostatic intraepithelial neoplasia. *Curr Urol Rep* 2000; 1: 65-70.
- Bostwick DG, Cheng L. *Urologic Surgical Pathology*. New York: Elsevier/Mosby, 2008.
- Bourdoumis A, Papatsoris AG, Chrisofos M, Efstathiou E, Skolarikos A, Deliveliotis C. The novel prostate cancer antigen 3 (PCA3) biomarker. *Int Braz J Urol* 2010; 36: 665-9.
- Brausi M, Castagnetti G, Dotti A, De Luca G, Olmi R, Cesinaro AM. Immediate radical prostatectomy in patients with atypical small acinar proliferation. Over treatment? *J Urol* 2004; 172: 906-908.
- Carver BS, Tran J, Gopalan A, Chen Z, Shaikh S, Carracedo A, Alimonti A, Nardella C, Varmeh S, Scardino PT, Cordon-Cardo C, Gerald W, Pandolfi PP. Aberrant ERG expression cooperates with loss of PTEN to promote cancer progression in the prostate *Nat Genet.* 2009 May; 41: 619-624.
- Chan TY, Epstein JI. Follow-up of atypical prostate needle biopsies suspicious for cancer. *Urology* 1999; 53: 351-355.

- Cheng L, Shan A, Cheville JC, Qian J, Bostwick DG. Atypical adenomatous hyperplasia of the prostate: a premalignant lesion? *Cancer Res* 1998; 58: 389-391.
- Cheng L, Cheville JC, Pisansky TM, Sebo TJ, Slezak J, Bergstralh EJ, Neumann RM, Singh R, Pacelli A, Zincke H, Bostwick DG. Prevalence and distribution of prostatic intraepithelial neoplasia in salvage radical prostatectomy specimens after radiation therapy. *Am J Surg Pathol* 1999; 23: 803-808.
- Cheng Liang, Bostwick D.G. Atypical sclerosing adenosis of the prostate : a rare mimic of adenocarcinoma. *Histopathology* 2010; 56: 627-631.
- Cheville JC, Bostwick DG. Postatrophic hyperplasia of the prostate. A histologic mimic of prostate adenocarcinoma. *Am J Surg Pathol* 1995; 19: 1068-1076.
- Cohen RJ, McNeal JE, Baillie T. Patterns of differentiation and proliferation in intraductal carcinoma of the prostate: significance for cancer progression. *Prostate* 2000; 43: 11-19.
- Collina G, Botticelli AR, Martinelli AM, Fano RA, Trentini GP. Sclerosing adenosis of the prostate. Report of three cases with electronmicroscopy and immunohistochemical study. *Histopathology* 1992; 20: 505-510.
- Coogan C, Bostwick D, Bloom K, Gould V. Glycoprotein A-80 in the human prostate: immunolocalization in prostatic intraepithelial neoplasia, carcinoma, radiation failure, and after neoadjuvant hormonal therapy. *Urology* 2003; 61: 248-252.
- Cote RJ, Skinner EC, Salem CE, Mertes SJ, Stanczyk FZ, Henderson BE, Pike MC, Ross RK. The effect of finasteride on the prostate gland in men with elevated serum prostate-specific antigen levels. *Br J Cancer* 1998; 78: 413-418.
- Chrisofos M, Papatsoris AG, Lazaris A, Deliveliotis C. Precursor lesions of prostate cancer. *Crit Rev Clin Lab Sci* 2007; 44: 243-270.
- Darson MF, Pacelli A, Roche P, Rittenhouse HG, Wolfert RL, Young CYF, Klee GG, Tindall DJ, Bostwick BG. Human glandular kallikrein 2 (hK2) expression in prostatic intraepithelial neoplasia and adenocarcinoma: A novel prostate cancer marker *Urology* 1997; 49: 857-862.
- Darson MF, Pacelli A, Roche P, Rittenhouse HG, Wolfert RL, Saeid MS, Young CY, Klee GG, Tindall DJ, Bostwick DG. Human glandular kallikrein 2 expression in prostate adenocarcinoma and lymph node metastases. *Urology* 1999; 53: 939-944.
- Davidson D, Bostwick D, Qian J, Wollan PC, Oesterling JE, Rudders RA, Siroky M, Stilmant M. Prostatic intraepithelial neoplasia is a risk factor for adenocarcinoma: predictive accuracy in needle biopsies. *J Urol* 1995; 154: 1295-1299.
- DeMarzo AM, Marchi VL, Epstein JI, Nelson WG. Proliferative inflammatory atrophy of the prostate: implications for prostatic carcinogenesis. *Am J Pathol* 1999; 155: 1985-1992.
- De Marzo AM, Platz EA, Epstein JI. A working group classification of focal prostate atrophy lesions. *Am J Surg Pathol*. 2006 30: 1281-1291.
- Dovey Z, Corbishley CM, Kirby RS. Prostatic intraepithelial neoplasia: a risk factor for prostate cancer. *Can J Urol* 2005; 12(Suppl 1): 49-52.
- Drivalos A, Papatsoris AG, Chrisofos M, Efstathiou E, Dimopoulos MA. The role of the cell adhesion molecules (integrins / cadherins) in prostate cancer. MA. *Int Braz J Urol*. 2011; 37: 302-326.
- Ellis WJ, Brawer MK. Repeat biopsy: who needs it? *J Urol* 1995; 153: 1496-1498.

- Epstein JI, Grignon DJ, Humphrey PA, McNeal JE, Sesterhenn IA, Troncoso P, Wheeler TM. Interobserver reproducibility in the diagnosis of prostatic intraepithelial neoplasia. *Am J Surg Pathol* 1995; 19: 873–886.
- Epstein JI. Pathology of prostatic neoplasia. In Walsh PC, Retik AB, Vaughan ED, Wein AJ, Eds. *Campbell's Urology, 8th Ed.* Pp 3025–3037. Philadelphia: Saunders, 2002.
- Epstein JI. What's new in prostate cancer disease assessment in 2006? *Curr Opin Urol* 2006; 16: 146–151.
- Epstein JI, Herawi M. Prostate needle biopsies containing prostatic intraepithelial neoplasia or atypical foci suspicious for carcinoma: implications for patient care. *J Urol* 2006; 175: 820–834.
- Fadare O, Wang S, Mariappan MR. Practice patterns of clinicians following isolated diagnoses of atypical small acinar proliferation on prostate biopsy specimens. *Arch Pathol Lab Med* 2004; 128: 557–560.
- Franks LM. Atrophy and hyperplasia in the prostate proper. *J Pathol Bacteriol* 1954; 68: 617–621.
- Gallo F, Chiono L, Gastaldi E, Venturino E, Giberti C. Prognostic Significance of High-Grade Prostatic Intraepithelial Neoplasia (HGPIN): Risk of Prostatic Cancer on Repeat Biopsies *Urology* September 2008; 72: 628–632.
- Gaudin PB, Epstein JI. Adenosis of the prostate. Histologic features in transurethral resection specimens. *Am J Surg Pathol* 1994; 18: 863–870.
- Gaudin PB, Epstein JI. Adenosis of the prostate Histological features in needle biopsy specimens. *Am J Surg Pathol* 1995; 19: 737–747.
- Gaudin PB, Sesterhenn IA, Wojno KJ, Mostofi FK, Epstein JI. Incidence and clinical significance of high-grade prostatic intraepithelial neoplasia in TURP specimens. *Urology* 1997; 49: 558–563.
- Goeman L, Joniau S, Ponette D, Van der Aa F, Roskams T, Oyen R, Van Poppel H. Is low-grade prostatic intraepithelial neoplasia a risk factor for cancer? *Prostate Cancer Prostatic Dis* 2003; 6: 305–310.
- Grignon DJ, Ro JY, Srigley JR, Troncoso P, Raymond AK, Ayala AG. Sclerosing adenosis of the prostate gland. A lesion showing myoepithelial differentiation. *Am. J. Surg. Pathol.* 1992; 16; 383–391.
- Grignon DJ, Sakr WA. Atypical adenomatous hyperplasia of the prostate: a critical review. *Eur Urol* 1996; 30: 206–211.
- Hailemariam S, Vosbeck J, Cathomas G, Zlobec I, Mattarelli G, Eichenberger T, Zellweger T, Bachmann A, Gasser T, Bubendorf L. Can molecular markers stratify the diagnostic value of high-grade prostatic intraepithelial neoplasia? *Human Pathology* 2011; 42: 702–709.
- Haggman MJ, Macoska JA, Wojno KJ, Oesterling JE. The relationship between prostatic intraepithelial neoplasia and prostate cancer: critical issues. *J Urol* 1997; 158: 12–22.
- Hellpap B, Kollermann J. Atypical acinar proliferation of the prostate. *Pathol Res Pract* 1999; 195: 795–799. Hellpap B, Kollermann J, Oehler U. Limiting the diagnosis of atypical small glandular proliferations in needle biopsies of the prostate by the use of immunohistochemistry. *J Pathol* 2001; 193: 350–353.
- Iczkowski KA, MacLennan GT, Bostwick DG. Atypical small acinar proliferation suspicious for malignancy in prostate needle biopsies: clinical significance in 33 cases. *Am J Surg Pathol* 1997; 21: 1489–1495.

- Iczkowski KA, Bassler TJ, Schwob VS, Bassler IC, Kunnel BS, Orozco RE, Bostwick DG. Diagnosis of "suspicious for malignancy" in prostate biopsies: predictive value for cancer. *Urology* 1998; 51: 749-758. Iczkowski KA, Bostwick DG. Criteria for biopsy diagnosis of minimal volume prostatic adenocarcinoma: analytic comparison with nondiagnostic but suspicious atypical small acinar proliferation. *Arch Pathol Lab Med* 2000; 124: 98-107.
- Iczkowski KA, Chen HM, Yang XJ, Beach RA. Prostate cancer diagnosed after initial biopsy with atypical small acinar proliferation suspicious for malignancy is similar to cancer found on initial biopsy. *Urology* 2002; 60: 851-854
- Jones EC, Clement PB, Young RH. Sclerosing adenosis of the prostate gland. A clinicopathological and immunohistochemical study of 11 cases. *Am. J. Surg. Pathol.* 1991; 15: 1171-1180.
- Joniau S, Goeman L, Pennings J, Van Poppel H. Prostatic intraepithelial neoplasia (PIN): importance and clinical management. *Eur Urol* 2005; 48: 379-385.
- Joniau S, Goeman L, Roskams T, Lerut E, Oyen R, Van Poppel H. Effect of Nutritional Supplement Challenge in Patients with Isolated High-Grade Prostatic Intraepithelial Neoplasia *Urology* 2007; 69: 1102-1106.
- Kang GH, Lee S, Lee HJ, Hwang KS. Aberrant CpG island hypermethylation of multiple genes in prostate cancer and prostatic intraepithelial neoplasia. *J Pathol* 2004; 202: 233-240.
- Keetch DW, Humphrey P, Stahl D, Smith DS, Catalona WJ. Morphometric analysis and clinical follow up of isolated prostatic intraepithelial neoplasia in needle biopsy of the prostate. *J Urol* 1995; 154: 347-351.
- Kelloff GJ, Lieberman R, Brawer MK, Crawford ED, Labrie F, Miller GJ, Kelloff GJ. Strategies for chemoprevention of prostate cancer. *Prostate Cancer Prostatic Dis* 1999; 2 (Suppl): S27-S33.
- Koivisto PA, Schleutker J, Helin H, Ehren-van Eekelen C, Kallioniemi OP, Trapman J. Androgen receptor gene alterations and chromosomal gains and losses in prostate carcinomas appearing during finasteride treatment for benign prostatic hyperplasia. *Clin Cancer Res* 1999; 5: 3378-3382.
- Kopelovich L, Crowell JA, Fay JR. The epigenome as a target for cancer chemoprevention. *J Nat Cancer Inst* 2003; 95: 1747-1757.
- Kronz JD, Allan CH, Shaikh AA, Epstein JI. Predicting cancer following a diagnosis of high grade prostatic intraepithelial neoplasia on needle biopsy: data on men with more than one follow-up biopsy. *Am J Surg Pathol* 2001 ; 25: 1079-1085.
- Langer JE, Rovner ES, Coleman BG, Yin D, Arger PH, Malkowicz SB, Nisenbaum HL, Rowling SE, Tomaszewski JE, Wein AJ, Jacobs JE. Strategy for repeat biopsy of patients with prostatic intraepithelial neoplasia detected by prostate needle biopsy. *J Urol* 1996; 155: 228-231.
- Lefkowitz GK, Taneja SS, Brown J, Melamed J, Lepor H. Follow-up interval prostate biopsy 3 years after diagnosis of high grade prostatic intraepithelial neoplasia is associated with high likelihood of prostate cancer, independent of change in prostate specific antigen levels. *J Urol* 2002; 168: 1415-1418.
- Lieberman R, Bermejo C, Akaza H, Greenwald P, Fair W, Thompson I. Progress in prostate cancer chemoprevention: modulators of promotion and progression. *Urology* 2001; 58: 835-842


- Marks P, Rifkind RA, Richon VM, Breslow R, Miller T, Kelly WK. Histone deacetylases and cancer: causes and therapies. *Nat Rev Cancer* 2001; 1: 194-202.
- McNeal JE. Morphogenesis of prostatic carcinoma. *Cancer* 1965; 18: 1659-1666.
- McNeal JE, Bostwick DG. Intraductal dysplasia: a premalignant lesion of the prostate. *Hum Pathol* 1986; 17: 64-71.
- McNeal JE, Bostwick DG. Intraductal dysplasia: a pre-malignant lesion of the prostate. *Hum Pathol* 1986; 17: 64-71.
- Montironi R, Galluzzi CM, Diamanti L, Taborro R, Scarpelli M, Pisani E. Prostatic intraepithelial neoplasia. Qualitative and quantitative analyses of the blood capillary architecture on thin tissue sections. *Pathol Res Pract* 1993; 189: 542-548.
- Montironi R, Magi-Galluzzi C, Muzzonigro G, Prete E, Polito M, Fabris G. Effects of combination endocrine therapy on normal prostate, prostatic intraepithelial neoplasia, and prostatic adenocarcinoma. *J Clin Pathol* 1994; 47: 906-913.
- Montironi R, Mazzucchelli R, Marshall JR, Bartels PH. Prostate cancer prevention: review of target populations, pathological biomarkers, and chemopreventive agents. *J Clin Pathol* 1999; 52: 793-803. Montironi R, Santinelli A, Mazzucchelli R. Prostatic intraepithelial neoplasia and prostate cancer. *Panminerva Med* 2002; 44: 213-220.
- Moore CK, Karikhalli S, Nazeer T, Fisher HAG, Kaufman RP Jr, Mian BM. Prognostic significance of high grade prostatic intraepithelial neoplasia and atypical small acinar proliferation in the contemporary era. *J Urol* 2005; 173: 70-72.
- Myers RB, Grizzle WE. Biomarker expression in prostatic intraepithelial neoplasia. *Eur Urol* 1996; 30: 153-166.
- Nelson WG, De Marzo AM, Isaacs WB. Prostate cancer. *N Engl J Med* 2003; 349: 366-381.
- Newling DW. PIN I-II: when should we interfere? *Eur Urol* 1999; 35: 504-507.
- O'Dowd GJ, Miller MG, Orozco R & Veltri RW. Analysis of repeated biopsy results within 1 year after noncancer diagnosis. *Urology* 2000; 55: 553-559.
- Orteil H. Involutionary changes in prostate and female breast cancer in relation to cancer development. *Can Med Assoc J* 1926; 16: 237.
- O'Shaughnessy JA, Kelloff GJ, Gordon GB, Dannenberg AJ, Hong WK, Fabian CJ, Sigman CC, Bertagnolli MM, Stratton SP, Lam S, Nelson WG, Meyskens FL, Alberts DS, Follen M, Rustgi AK, Papadimitrakopoulou V, Scardino PT, Gazdar AF, Wattenberg LW, Sporn MB, Sakr WA, Lippman SM, Von Hoff DD. Treatment and prevention of intraepithelial neoplasia: an important target for accelerated new agent development. *Clin Cancer Res* 2002; 8: 314-346.
- Pacelli A, Bostwick DG. Clinical significance of high-grade prostatic intraepithelial neoplasia in transurethral resection specimens. *Urology* 1997; 50: 335-359.
- Papatsoris AG, Papavassiliou AG. Prostate cancer: horizons in the development of novel anti-cancer strategies. *Curr Med Chem Anticancer Agents* 2001; 1: 47-70.
- Papatsoris AG, Karamouzis MV, Papavassiliou AG. Novel insights into the implication of the IGF-1 network in prostate cancer. *Trends Mol Med* 2005; 11: 52-55.
- Papatsoris AG, Karamouzis MV, Papavassiliou AG. Novel biological agents for the treatment of hormone-refractory prostate cancer (HRPC). *Curr Med Chem* 2005; 12: 277-296.
- Papatsoris AG, Karamouzis MV, Papavassiliou AG. The power and promise of "rewiring" the mitogen-activated protein kinase network in prostate cancer therapeutics. *Mol Cancer Ther* 2007; 6: 811-819.

- Papatsoris AG, Liolitsa D, Deliveliotis C. Manipulation of the nerve growth factor network in prostate cancer. *Expert Opin Investig Drugs* 2007; 16: 303-309.
- Papatsoris AG, Anagnostopoulos F. Prostate cancer screening behaviour. *Public Health* 2009; 123: 69-71.
- Patra SK, Patra A, Dahiya R. Histone deacetylase and DNA methyltransferase in human prostate cancer. *Biochem Biophys Res Commun* 2001; 287: 705-713.
- Powell IJ, Bock CH, Ruterbusch JJ. & Sakr W. Evidence Supports a Faster Growth Rate and/or Earlier Transformation to Clinically Significant Prostate Cancer in Black Than in White American Men, and Influences Racial Progression and Mortality Disparity. *J Urol* 2010; 183: 1792-1797.
- Qian J, Bostwick DG, Takahashi S, Borell TJ, Herath JF, Lieber MM, Jenkins RB. Chromosomal anomalies in prostatic intraepithelial neoplasia and carcinoma detected by fluorescence in situ hybridization. *Cancer Res* 1995; 55: 5408-5414.
- Qian J, Wollan P, Bostwick DG. The extent and multicentricity of high-grade prostatic intraepithelial neoplasia in clinically localized prostatic adenocarcinoma. *Hum Pathol* 1997; 28: 143-148.
- Raghow S, Hooshdaran MZ, Katiyar S, Steiner MS. Toremifene prevents prostate cancer in the transgenic adenocarcinoma of mouse prostate model. *Cancer Res* 2002; 62: 1370-1376.
- Ravery V. Towards early and more specific diagnosis of prostate cancer? Identifying a Key Target Population for Chemoprevention and Available Strategies *European Urology Supplements* 2010; 8: 103-107.
- Ronnett BM, Carmichael MJ, Carter HB, Epstein JI. Does high-grade prostatic intraepithelial neoplasia result in elevated serum prostate specific antigen levels? *J Urol* 1993; 150: 386-389.
- Rubin MA, Zhou M, Dhanasekaran SM, Varambally S, Barrette TR, Snada MG, Pienta KJ, Ghosh D, Chinnaiyan AM. Alpha-Methylacyl coenzyme A racemase as a tissue biomarker for prostate cancer. *JAMA* 2002; 287: 1662-1670.
- Sakamoto N, Tsuneyoshi M, Enjoji M. Sclerosing adenosis of the prostate. Histopathologic and immunohistochemical analysis. *Am. J. Surg. Pathol.* 1991; 15: 660-667.
- Sakr WA, Haas GP, Cassin BJ, Pontes JE, Crissman JD. Frequency of carcinoma and intraepithelial neoplasia of the prostate in young male patients. *J Urol* 1993; 150: 379-385
- Sakr WA, Grignon DJ, Haas GP, Schomer KL, Heilbrun LK, Cassin BJ, Powell J, Montie JA, Pontes JE, Crissman JD. Epidemiology of high grade prostatic intraepithelial neoplasia. *Pathol Res Pract* 1995; 191: 838-841.
- Sakr WA, Grignon DJ, Haas GP, Heilbrun LK, Pontes JE, Crissman JD. Age and racial distribution of prostatic intraepithelial neoplasia. *Eur Urol* 1996; 30: 138-144.
- Sakr WA, Brawer MK, Moul JW, Donohue R, Schulman CG, Sakr D. Pathology and biomarkers of prostate cancer. *Prostate Cancer Prostatic Dis* 1999; 2(Suppl1): S7-S14.
- Sandor V, Bakke S, Robey RW, Kang MH, Blagosklonny MV, Bender J, Brooks R, Piekarczyk RL, Tucker E, Figg WD, Chan KK, Goldspiel B, Fojo AT, Balcerzak SP, Bates SE. Phase I trial of the histone deacetylase inhibitor, depsipeptide (FR901228, NSC 630176), in patients with refractory neoplasms. *Clin Cancer Res* 2002; 8: 718-728.
- Sardana G, Dowell B, Diamandis EP. Emerging Biomarkers for the diagnosis and prognosis of prostate cancer. *Clinical Chemistry* 2008 54 : 1951-1960

- Scattoni V, Roscigno M, Freschi M, Deho F, Raber M, Briganti A, Fantini G, Nava L, Montorsi F, Rigatti P. Atypical small acinar proliferation (ASAP) on extended prostatic biopsies: predictive factors of cancer detection on repeat biopsies. *Arch Ital Urol Androl* 2005; 77: 31-36.
- Shah RB, Kunju LP, Shen R, LeBlanc M, Zhou M, Rubin MA. Usefulness of basal cell cocktail (34beta E12+p63) in the diagnosis of atypical prostate glandular proliferations. *Am J Clin Pathol* 2004; 122: 517-523.
- Shepherd D, Keetch DW, Humphrey PA, Smith DS, Stahl D. Repeat biopsy strategy in men with isolated prostatic intraepithelial neoplasia on prostate needle biopsy. *J Urol* 1996; 156: 460-463.
- Shin SS, Gould VE, Gould JE, Warren WH, Gould KA, Yaremko ML, Manderino GL, Rittenhouse HG, Tomita JT, Jansson DS. Expression of a new mucin-type glycoprotein in select epithelial dysplasias and neoplasms detected immunocytochemically with Mab A-80. *APMIS* 1989; 97: 1053-1067.
- Signoretti S, Waltregny D, Dilks J, Isaac B, Lin D, Garraway L, Yang A, Montironi R, McKeonand F & Loda M. *Am J Pathol* 2000; 157: 1769-1775.
- Singh PB, Nicholson CM, Ragavan N, Blades RA, Martin FL, Matanhelia SS. Risk of prostate cancer after isolated high-grade prostatic intraepithelial neoplasia (HGPIN) detected on extended core needle biopsy : a UK hospital experience. *BMC Urol* 2009; 9: 3.
- Sinha AA, Quast BJ, Reddy PK, Lall V, Wilson MJ, Qian J, Bostwick DG. Microvessel density as a molecular marker for identifying high-grade prostatic intraepithelial neoplasia precursors to prostate cancer. *Exp Mol Pathol* 2004; 77: 153-159.
- Sporn MB. Prevention of cancer in the next millennium: report of the chemoprevention working group to the American Association for Cancer Research. *Cancer Res* 1999; 59: 4743-4758
- Steiner MS. High-grade prostatic intraepithelial neoplasia and prostate cancer risk reduction. *World J Urol* 2003; 21: 15-20.
- Swinnen JV, Roskams T, Joniau S, Van Poppel H, Oyen R, Heyns W, Verhoeven G. Overexpression of fatty acid synthase is an early and common event in the development of prostate cancer. *Int J Cancer* 2002; 98: 19-22.
- Tomlins SA, Rhodes DR, Perner S, Dhanasekaran SM, Mehra R, Sun XW, Varambally S, Cao X, Tchinda J, Kuefer R, Lee C, Montie JE, Shah RB, Pienta KJ, Rubin MA, Chinnaiyan AM. Recurrent fusion of TMPRSS2 and ETS transcription factor genes in prostate cancer. *Science* 2005; 310: 644-648.
- Van der Kwast TH, Labrie F, Tetu B. Prostatic intraepithelial neoplasia and endocrine manipulation. *Eur Urol* 1999; 35: 508-510.
- Vis AN, Van Der Kwast TH. Prostatic intraepithelial neoplasia and putative precursor lesions of prostate cancer: a clinical perspective. *BJU Int* 2001; 88: 147-157.
- Vis AN, Hoedemaeker RF, Roobol M, Schroder FH, van der Kwast TH. The predictive value for prostate cancer of lesions that raise suspicion of concomitant carcinoma: an evaluation from a randomized population-based study of screening for prostate cancer. *Cancer* 2001; 92: 524-534.
- Weinstein MH, Epstein JI. Significance of high-grade prostatic intraepithelial neoplasia on needle biopsy. *Hum Pathol* 1993; 24: 624-629.

- Yamanaka M, Watanabe M, Yamada Y, Takagi A, Murata T, Takahashi H, Suzuki H, Ito H, Tsukino H, Katoh T, Sugimura Y, Shiraishi T. Altered methylation of multiple genes in carcinogenesis of the prostate. *Int J Cancer* 2003; 106: 382-387.
- Yamauchi A, Kawai K, Tsukamoto S, Ideyama Y, Shirai T, Akaza H. Persistence of prostatic intraepithelial neoplasia after effective chemoprevention of microscopic prostate cancer with antiandrogen in a rat model. *J Urol* 2006; 175: 348-352.
- Yang XJ, Lecksell K, Short K, Gottesman J, Peterson L, Bannow J, Schellhammer PF, Fitch WP, Hodge GB, Parra R, Rouse S, Waldstreicher J, Epstein JI. Does long-term finasteride therapy affect the histologic features of benign prostatic tissue and prostate cancer on needle biopsy? PLESS Study Group. Proscar Long-Term Efficacy and Safety Study. *Urology* 1999; 53: 696-700.
- Yoshimoto M, Joshua AM, Cunha IW, Coudry RA, Fonseca FP, Ludkovski O, Zielenska M, Soares FA, Squire JA. Absence of TMPRSS2: ERG fusions and PTEN losses in prostate cancer is associated with a favorable outcome. *Mod Pathol* 2008; 21: 1451-1460.
- Young RH, Clement PB. Sclerosing adenosis of the prostate. *Arch. Pathol. Lab. Med.* 1987; 111: 363-366.
- Young RH, Clement PB. 'Pseudoadenomatoid' tumour of prostate. *Histopathology* 1990; 16: 420.
- Zeng L, Kyprianou N. Apoptotic regulators in prostatic intraepithelial neoplasia (PIN): value in prostate cancer detection and prevention. *Prostate Cancer Prostatic Dis* 2005; 8: 7-13.

IntechOpen



Intraepithelial Neoplasia

Edited by Dr. Supriya Srivastava

ISBN 978-953-307-987-5

Hard cover, 454 pages

Publisher InTech

Published online 08, February, 2012

Published in print edition February, 2012

The book "Intraepithelial neoplasia" is till date the most comprehensive book dedicated entirely to preinvasive lesions of the human body. Created and published with an aim of helping clinicians to not only diagnose but also understand the etiopathogenesis of the precursor lesions, the book also attempts to identify its molecular and genetic mechanisms. All of the chapters contain a considerable amount of new information, with an updated bibliographical list as well as the latest WHO classification of intraepithelial lesions that has been included wherever needed. The text has been updated according to the latest technical advances. This book can be described as concise, informative, logical and useful at all levels discussing thoroughly the invaluable role of molecular diagnostics and genetic mechanisms of the intraepithelial lesions. To make the materials easily digestible, the book is illustrated with colorful images.

How to reference

In order to correctly reference this scholarly work, feel free to copy and paste the following:

A.G. Papatsoris, C. Kostopoulos, V. Migdalis and M. Chrisofos (2012). Prostate Cancer Precursor Diseases, Intraepithelial Neoplasia, Dr. Supriya Srivastava (Ed.), ISBN: 978-953-307-987-5, InTech, Available from: <http://www.intechopen.com/books/intraepithelial-neoplasia/prostate-cancer-precursor-diseases>

INTECH
open science | open minds

InTech Europe

University Campus STeP Ri
Slavka Krautzeka 83/A
51000 Rijeka, Croatia
Phone: +385 (51) 770 447
Fax: +385 (51) 686 166
www.intechopen.com

InTech China

Unit 405, Office Block, Hotel Equatorial Shanghai
No.65, Yan An Road (West), Shanghai, 200040, China
中国上海市延安西路65号上海国际贵都大饭店办公楼405单元
Phone: +86-21-62489820
Fax: +86-21-62489821

© 2012 The Author(s). Licensee IntechOpen. This is an open access article distributed under the terms of the [Creative Commons Attribution 3.0 License](#), which permits unrestricted use, distribution, and reproduction in any medium, provided the original work is properly cited.

IntechOpen

IntechOpen