

We are IntechOpen, the world's leading publisher of Open Access books Built by scientists, for scientists

4,800

Open access books available

122,000

International authors and editors

135M

Downloads

Our authors are among the

154

Countries delivered to

TOP 1%

most cited scientists

12.2%

Contributors from top 500 universities



WEB OF SCIENCE™

Selection of our books indexed in the Book Citation Index
in Web of Science™ Core Collection (BKCI)

Interested in publishing with us?
Contact book.department@intechopen.com

Numbers displayed above are based on latest data collected.

For more information visit www.intechopen.com



Colorectal Liver Metastasis: Current Management

Alejandro Serrablo, Luis Tejedor, Vicente Borrego and Jesus Esarte
*Miguel Servet University Hospital
Spain*

1. Introduction

Colorectal cancer (CRC) is the third most frequent in men in developed countries (after lung and prostate tumours) and second among women (after breast cancer), with approximately one million new cases per year throughout the world (550,000 men and 470,000 women), representing 14.6% and 15.2% respectively of all malignant tumours diagnosed. The role of colonoscopy in the screening of this pathology is crucial. CRC affecting the intestine has a high rate of cure (45-50%) with radical surgery. The most frequent metastatic involvement in CRC, after lymph nodes invasion, is seen in the liver.

Several studies have analyzed the pre-operative prognostic factors in patients undergoing liver resection for liver metastases of CRC in order to select patients for surgical treatment. However, intraoperative and post-operative factors have been poorly studied and that could report on the aggressiveness of the tumour and the curative efficacy of the surgery performed. The purpose of surgery is resection of all liver lesions with a tumour-free margin, provided R0 resection (complete resection with no microscopic residual tumour) may be achieved with low morbidity and mortality (Choti et al. 2002; Marin et al. 2009; Lordan & Karanjia 2007) without endangering the life of the patient due to either liver insufficiency or post-operative complications. According to most authors, it should be noted that surgery, however extensive it is, does not prolong survival if residual microscopic or gross tumour is left (Harmantas et al. 1996; Kronawitter et al. 1999).

Since Woodington and Waugh reported the first favourable results of surgical treatment for CRC liver metastases (Woodington & Waugh, 1964), a disease previously considered incurable, to date, a 5- and 10-year survival rates of 35-58% and 20-25% respectively have been achieved, while survival without treatment is less than 2% (Ohlsson et al. 1998; Fong et al. 1999).

The key for indicating the most adequate treatment is the study conducted by a multidisciplinary team (Söreide et al. 2008; Artigas et al. 2007). The difficulty for assessing the indication stems from the fact that the presence of extrahepatic tumour, the possibility of achieving a tumour-free margin and the actual number of liver metastases are frequently known during the laparotomy. Different studies have analyzed the traditional pre-operative factors predicting survival in order to select patients in whom unnecessary surgery could be

avoided. These were factors related to the patient, the primary tumour and the liver metastases (Fong et al. 1999; Nordlinger et al. 1996). However, some authors do not contraindicate surgery in patients with poor prognostic criteria provided a R0 resection may be obtained, as a number of prognostic factors are known only after resection (Marín et al. 2009). These factors include the histological study (number, resection margin size, microsatellites, type of growth, presence of tumour pseudocapsule, tumour differentiation grade, histological type, nuclear grade and number of mitoses/mm²) and the immunohistochemical study of the resected specimen. The latter may combine the markers of cell proliferation and cell cycle control, p53 and Ki67. There is increasing evidence supporting the concept that in human cancer, a minority of cells (tumour stem cells) has acquired characteristics of uncontrolled growth and the ability to form metastases (Reya et al. 2001; Dalerba et al. 2007; Jordan et al. 2006). This hypothesis is supported by different experimental observations made initially in acute myeloid leukaemia (Bonnet D & Dick J 1997) and subsequently in human solid tumours, such as breast (Al-Hajj 2003), brain (Singh et al. 2004; Galli et al. 2004), colorectal (O' Brien et al. 2004; Ricci-Vitiani et al. 2007), head and neck (Prince et al. 2007) and pancreatic cancer (Li et al. 2007). However, this concept continues to be highly controversial and data reported on colorectal cancer are not yet conclusive (Ricci-Vitiani et al. 2007; Hill 2006).

It is therefore interesting to know both the qualitative and quantitative stem cell population in the tumour using markers, such as CD44, CD133, and CD166. The tissue microarray (TMA) technique allows for monitoring and simultaneous evaluation of a great number of samples or tumour series in a single experiment, ensuring homogeneity of the techniques between specimens and validation of the results obtained with various histological, immunohistochemical and in-situ hybridization (FISH) techniques (Battifora 1986; Kononen et al 1998; Milanese-Yearsley et al 2002).

In addition, over the last decade, a revolution in the approach to CRC liver metastases has occurred. Firstly, there was the advent of new chemotherapy drugs that have allowed better control of the disease, higher response rates and longer survival rates. Secondly, this has opened up a greater possibility of surgical rescue in more patients. Aggressive surgical management is called extreme liver surgery: ante-situ, in-situ and ex-situ liver resections are included (Mehrabi et al. 2011; Hoti et al. 2011; Oldhafer et al. 2001).

2. Current diagnostic tools

Imaging of the liver of CRC patients requires high sensitivity and reliable characterization of the lesions, allowing differentiation of malignant from benign tumours. Accurate and timely detection of hepatic metastases has long-range therapeutic and prognostic implications, since untreated liver metastases have a poor prognosis (5-year survival rate of 0–3%) while the resection with curative intent offers a much better one (5-year survival rate from 35% to 58%) (El Khodary et al. 2011). An understanding of the segmental anatomy of the liver is imperative for localization and appropriate management of hepatic neoplasms. The classification proposed by Couinaud (Couinaud 1957) and later modified by Bismuth (Bismuth 1982) provides the surgically relevant information and is easily applicable to cross-sectional imaging techniques, such as computed tomography (CT), magnetic resonance imaging (MRI) and ultrasonography (US).

The imaging assessment of potentially resectable CRC liver metastases, needed for a careful pre-operative selection of patients, should address the following five critical issues:

1. Evaluation of possible liver metastases. Number, size and segmental location of tumours must be determined, as well as their differential diagnosis with benign lesions.
2. Possible hilar lymph node involvement. As they represent metastases from the liver metastases, this lymphatic involvement carries a poor prognosis (survival rates after resection are 3-12%), although the pre-operative diagnosis is difficult.
3. Vascular invasion. Obviously, assessment of vascular invasion is critical when deciding the appropriate surgical strategy.
4. Liver volumetry. Measuring the volume of the future remnant liver when considering extended resections is recommended, since insufficient residual volume of liver parenchyma is a contraindication to surgery.
5. Presence of extrahepatic disease. Although peritoneal carcinomatosis may be very difficult to detect, other extrahepatic involvement is usually diagnosed pre-operatively (Valls et al. 2009).

Imaging techniques used nowadays for diagnosis of these lesions include US, multi-detector CT (MDCT), MRI and fluorine-18-fluorodeoxyglucose positron emission tomography (FDG PET). FDG PET and CT can be combined in order to provide fused images, allowing high spatial resolution and functional information in the same examination (FDG PET/CT). In studies with specificity higher than 85%, the sensitivity for detection of liver metastases is progressively increasing from US to CT, MRI and FDG PET (Kinkel et al. 2002). The extensive literature regarding the benefits and constraints of each of these modalities for detecting liver metastases shows several limitations: inadequate definition of inclusion and exclusion criteria, incomplete reporting of methods, lack of uniform references, etc. The best standard of reference is laparotomy with bimanual palpation and intraoperative ultrasonography (IOUS), but this was used in only a few studies (Valls et al 2001). When a suboptimal standard is used, underreporting of lesions and overestimation of detection rate are the results (van Erkel et al 2002). Another confounding factor is the different methods for reporting sensitivity: per patient (detection of at least one lesion per patient) and per lesion (detection of all lesions per patient). Therefore, it is important to inquire into the results of the current studies, also because improving technology can make results of prior studies superfluous (Lucey et al. 2006).

2.1 Ultrasonography

US is a rapid and non-invasive method for screening patients with suspected liver metastases but, although it is highly efficient in distinguishing patients with diffuse hepatic metastases that involve all the liver, it is more operator dependent than other imaging methods, fails to show parts of the liver in certain patients and its sensitivity (50-70%) and specificity are surpassed by other imaging studies.

The detection of hepatic metastases is substantially improved by contrast-enhanced US (CEUS) compared to conventional B-mode sonography, increasing the sensitivity per lesion from 71% to 87% (Oldenburg & Albrecht 2008). US contrast agents consist of microbubbles of gas that flood the blood pool after intravenous injection and are confined to the vascular compartment. These agents are safe, well tolerated and have very few contraindications.

Metastases behave characteristically in three phases: arterial, portal venous and delayed (El Khodary et al. 2011). CEUS sensitivity and specificity in staging liver metastases (80–95% and 84–98%, respectively) approach those of CT and MRI. In addition, CEUS is useful to improve the detection rate of metastases smaller than 1 cm or of those lesions that are isoechoic with respect to adjacent liver parenchyma, thus improving the performance of sonography in around 13.7% of the cases (Chami et al. 2008).

In general, if an examination of the liver by US is insufficient, then examination by CEUS will also be insufficient. CEUS has limited ability to observe certain parts of the liver, especially in obese patients and/or in cases of steatosis and it is not possible to simultaneously examine multiple lesions in the arterial and early portal phases. Hypervascular metastases and haemangiomas on one hand and metastases and small cysts on the other can be difficult to differentiate (Larsen 2010).

Intraoperative diagnosis is based on IOUS and on diagnostic laparoscopy. IOUS has higher sensitivity than transabdominal US, MDCT and MRI, and allows identification of metastases 0.5 cm in size and defining the relationship between lesion, vessels and biliary structures. With a sensitivity of 98% and a specificity of 95%, IOUS is generally considered the gold standard for detecting liver lesions and is regarded as a routine investigation, modifying the planned surgical intervention in 18–30% of the patients. In addition, Doppler and spectral Doppler facilitate the technique of surgical resection. Laparoscopy, which is not routinely used in the pre-operative evaluation of the advanced disease, allows an assessment of the peritoneal and pelvic spread of the primitive cancer and, with the combined use of laparoscopic ultrasound (LIOUS), enables detection of small metastases, varying the initial surgical plan in 20–30% of the cases (Guglielmi et al. 2005). Contrast enhanced IOUS (CEIOUS) shows some benefit over pre-operative imaging and IOUS since it seems to improve the ability to characterize already detected lesions and facilitate the detection of new metastatic lesions (Fioole et al. 2008; Leen et al. 2006; Nakano et al. 2008; Torzilli et al. 2005).

2.2 Computed Tomography

MDCT has a sensitivity of 70–85% and a specificity of 90%, especially for lesions bigger than 1.5–2 cm. Sensitivity is lower for small subglissonian metastases, even though multi-slice CT allows identification of hepatic lesions of 0.5 cm in size (Guglielmi et al. 2005). Fast data acquisition and breath-hold scanning allows imaging of the liver twice. This bi-phasic contrast-enhanced scan during the arterial-dominant phase and the portal-venous perfusion phase after bolus-like contrast administration, prior to the equilibrium phase, is accepted as standard for the optimised display of the complex vascularization of the liver and potential hepatic lesions. Slice thicknesses of 2 or 4 mm are the most effective for detection of focal liver lesions, with an identical detection rate of 96% for both. 3-D data sets can be produced improving multiplanar imaging, which allows evaluation of subcapsular lesions, demonstration of vascular anatomy and better characterisation of the lesions. Together with improvements in bolus-tracking, MDCT scanning during the various vascular contrast and equilibrium phases allows performing CT-angiography of the liver and mesenteric vessels, which can be important in patients undergoing hepatic resection or transarterial chemo or radio-embolisation. MDCT portal venogram is useful in evaluation of the portal system. Additionally, quantitative perfusion studies can also be done. Thus, MDCT can be used for evaluating the liver lesion, liver parenchyma and hepatic vessels in the same sitting.

It is important to take account of the time elapsed between the radiological study and the operation. One recent study showed that the utility of MDCT as a pre-operative tool to evaluate CRC liver metastases is inversely proportional to the time interval between imaging and surgery, which may explain conflicting reports of the accuracy of MDCT in the literature (Yang et al. 2010).

Hepatic volumetry, necessary to evaluate the feasibility of major hepatectomies, especially in the case of atypical resections, is provided by MDCT software able to highlight different liver segments and to create vascular maps for arterial and portal afferences, and for hepatic vein drainage. The volume of each single segment can be calculated and a simulation of surgical resection can be performed. Information can be displayed using coloured maps or three-dimensional movies (Laghi et al. 2005).

2.3 Magnetic Resonance Imaging

MDCT is usually preferred because it is more widely available and because it is a well-established technique for surveying the extrahepatic abdominal organs and tissues. However, MRI has an advantage in the characterization of focal lesions and is also preferred for patients who cannot receive intravenous iodinated contrast material or when concerns about the risk of radiation from repeated exposure to CT, as in children or young adults, exists. In general, MRI sensitivity varies from 85-90% and its specificity is up to 95%, although a comparison of the performance of MDCT vs. MRI needs to be reassessed periodically, considering the rapid evolution of both technologies and the increase in therapeutic options available.

Contrast media are of two types: the extracellular agents (gadolinium chelates) and the liver specific agents. Gadolinium is used for lesion detection and characterisation while liver specific agents are used as functional agents. The most commonly used substance in contrast-enhanced dynamic MRI is extracellular gadolinium-chelate complex, which provides the greatest diagnostic sensitivity and specificity rates among cross-sectional techniques currently in use. The current standard MRI liver protocol includes a T2-weighted sequence, a T1-weighted sequence and a three-phase technique after administration of gadolinium (arterial-dominant, portal venous and hepatic venous or interstitial). Like CT, the detection of CRC liver metastases using MRI is maximized during the portal venous phase.

The administration of organ-specific contrast agents with hepatocyte specificity (mangafodipir trisodium [MnDPDP], gadobenate dimeglumine [Gd-BOPTA]) or reticuloendothelial system specificity (superparamagnetic iron oxide [SPIO] particles, captured by Kupffer cells) allows an increase in the sensitivity and specificity of the method (Bluemke et al. 2000; Vidiri et al. 2004), but data about their benefits are controversial. Furthermore, these agents are generally costly and not widely available.

Diffusion-weighted MR imaging (DWI) is a recently introduced technique to depict differences in molecular diffusion caused by the random motion of molecules. It provides excellent tissue contrast based on molecular diffusion, which is different from ordinary T1- and T2-weighted images, without the need for a contrast agent (El Khodary et al. 2011). An additional benefit of DWI is the ability to derive quantitative indices, which may be important in the assessment of disease response to novel therapeutics, including anti-vascular and anti-angiogenic therapy, since conventional assessment based on measuring

lesion size is insensitive to early, treatment-related changes (Koh et al. 2006). In summary, DWI is a simple and sensitive method for screening focal hepatic lesions and is useful for differential diagnosis (Koike et al. 2009).

2.4 Positron Emission Tomography

FDG PET is a highly sensitive and specific imaging study detecting hepatic metastases from CRC (92–100% and 85–100% respectively), although for some authors the strength of these data is moderate (Lucey et al. 2006). Several studies have also shown the utility of FDG PET in identifying additional metastatic lesions when initial CT showed single hepatic metastases and, thus, changed the management strategy. Nevertheless, false negative and false positive findings in FDG PET for hepatic metastases are not negligible (Udayasankar et al. 2008) and its positive predictive value (PPV) is not high, leading to some authors to confirm histologically the FDG PET findings suggesting non-resectability (Valls et al. 2009).

Two meta-analyses have demonstrated high diagnostic values of PET in the evaluation of hepatic metastases (Bipat et al. 2005; Wiering et al. 2005), as well as a recent review (Patel et al. 2011) confirming the superior sensitivity of FDG PET for detecting liver metastases on a per patient basis, but not on a per lesion basis. Other papers have shown FDG PET/CT to be slightly less sensitive than MRI with liver-specific contrast agents or dedicated sequences for small lesions (Coenegrachts et al. 2009), but more sensitive than MDCT alone (Kong et al. 2008; Selzner et al. 2004), although its role is not yet clear owing to the small number of studies (Niekel et al. 2010). In the context of CRC metastases, the role of FDG PET/CT is to avoid unnecessary surgery, based on its ability to detect extrahepatic foci of disease (nodal metastases, lung nodules) that are not depicted or characterized as malignant by other imaging methods (Sørensen et al. 2007). In addition, this technology is not suitable for liver resection planning. In patients evaluated with FDG PET prior to surgery, a lower risk of “non-therapeutic laparotomy” (Pawlik et al. 2009) and improved survival (Fernandez et al. 2004) has been observed, reflecting better patient selection.

A recent meta-analysis reviewing more than 3,000 patients found that sensitivity of CT, MR imaging and FDG PET on a per lesion basis were 74.4%, 80.3% and 81.4%, respectively, while on a per patient basis, the sensitivities were 83.6%, 88.2% and 94.1%, respectively. Specificity estimates were comparable. No differences were seen for lesions measuring at least 10 mm. Data about FDG PET/CT were too limited for comparisons with other modalities (Niekel et al. 2010).

In brief, although every modality has benefited from advances in technology, MDCT scanning remains a dominant imaging modality not only for lesion detection and pre-operative planning, but also for treatment monitoring and post-treatment surveillance. High-resolution CT with contrast combined with FDG PET/CT may obviate the need for additional studies and may improve patient management (Bipat et al. 2007; Doan et al. 2010; Vauthey 2006). Dynamic gadolinium-based contrast-enhanced MRI should be reserved for problem solving. MRI has the highest sensitivity for lesion detection, but because of its low sensitivity in detecting extrahepatic disease in the peritoneum and chest, it is not a desirable primary imaging modality (Vauthey 2006) except for evaluating patients who have not previously undergone therapy (Lucey et al. 2006; Niekel et al. 2010). Ultimately, the modality used must be tailored not only to the patient and the clinical situation, but also to the imaging expertise within the institution.

3. Current criteria for resectability

Improvements in pre-operative imaging techniques, patient selection and surgical techniques, as well as the introduction of new cytotoxic and biologic agents for pre-operative and post-operative chemotherapy have improved the resectability rate and almost doubled the 5-year survival rate for patients with CRC liver metastases, from about 30% two decades ago to nearly 60%. In this setting, with the care of these patients rapidly evolving, the standards of care needed to be redefined. The criteria for resectability of these metastases have changed dramatically. Features such as the number of lesions (1 to 3 unilobar metastases), the size of the lesion (less than 5 cm), preferably presenting at least 12 months after resection of the primary tumour, resectable with a minimum margin of 1 cm in width and without hilar adenopathy or extrahepatic disease, are no longer considered as determinant factors regarding resectability and, thereby, are invalid to deny a patient the opportunity of lengthy survival.

Regarding the number of metastasis, Altendorf-Hofmann did not find long-term differences in the survival rates between patients with 1 to 3 metastasis and those with 4 or more, if a R0 resection had been obtained (Altendorf-Hofmann et al. 2003). Moreover, some studies have shown that the degree of response to chemotherapy is a stronger predictor factor for long-term survival than the number of metastasis. Regarding tumour size and prognosis, reports have been conflicting. Evidence shows that size is not a resectability factor, but a factor related to tumour aggressiveness.

It has been shown that the actual width of the surgical margin has no effect on survival as long as the margin is microscopically negative (Figueras et al. 2007; Lordan 2007; Pawlik et al. 2005). A margin greater than 10mm is considered to be optimum, although this has changed too (Casanova et al. 2004). Although surgeons should continue to plan hepatic resection to preserve a "safety zone" and should avoid routine use of "minimum margin" surgery, a predicted margin of less than 1 cm should no longer be considered an exclusion criterion for resection.

Historically, extrahepatic disease has been almost universally accepted as a contraindication to liver resection. Recently, however, some series have shown a 5-year survival rate of 12% to 37% after liver resection in selected patients with extrahepatic disease, independent of the location of that disease (lung, primary colorectal recurrence, retroperitoneal or hepatic pedicle lymph nodes, peritoneal carcinomatosis, miscellaneous) (Elias et al. 2003, 2005). In most cases, incidental peritoneal disease found at laparotomy would contraindicate hepatic resection. In general, resection in such patients should only be considered after documentation of stable/responsive disease with systemic chemotherapy and when an R0 resection of both intrahepatic and extrahepatic disease is feasible. From an anatomic and prognostic perspective, it seems appropriate to recommend that patients with combined liver and extrahepatic disease be reported separately from those meeting the traditional resectable criteria, and be designated as borderline resectable (Vauthey 2007).

Positive hilar lymph nodes are associated with a poor outcome and have been traditionally considered as a contraindication to hepatic resection of CRC liver disease. Recent papers have reported long-term survival in some patients with hilar nodal metastases and have concluded that this patient population may still benefit from hepatic resection and

lymphadenectomy, provided that involved nodes are in the hepatoduodenal-retropancreatic area and not in the common hepatic artery/cealic-axis region (Adam et al. 2008; Jaeck 2003). Although patients with microscopic involvement may derive a benefit from hepatic resection, gross involvement of the hilar nodes should be considered a relative contraindication to resection.

At present, the criteria for resectability include any patient in whom all disease can be removed with a negative margin and who has adequate hepatic reserve. That is to say, instead of resectability being defined by what is removed, now it is sustained by what will remain after resection, including patients with extrahepatic disease (Pawlik et al. 2008). Interestingly, none of the traditional adverse prognostic indicators of recurrence, such as carcinoembryonic antigen more than 200 ng/mL, short disease-free interval, node-positive primary, tumour size more than 5 cm, multiple tumours, or synchronous presentation, precluded long-term survival, except for a positive resection margin (Vauthey 2007).

In 2006, the Consensus Conference on Colorectal Liver Metastases of the American Hepato-Pancreato-Biliary Association (AHPBA) established that CRC liver metastases should be defined as resectable when the disease can be completely resected, two adjacent liver segments can be spared with an adequate vascular inflow and outflow and biliary drainage, and the volume of the liver remaining after resection (future liver remnant [FLR]) will be adequate (at least 20% of the total estimated liver volume for normal parenchyma, 30–60% if the liver is injured by chemotherapy, steatosis or hepatitis, or 40–70% in the presence of cirrhosis, depending on the degree of underlying hepatic dysfunction) (Vauthey 2006). When hepatic metastatic disease is not optimally resectable based on insufficient remnant liver volume, pre-operative chemotherapy, portal vein embolization or staged liver resection can be considered. Also, ablative techniques may be considered alone or in conjunction with resection. All original sites of disease need to be amenable to ablation or resection (Abdalla et al. 2006; Adam et al. 2006; Donadon et al. 2007; Garden et al. 2006).

Resection should be offered to all patients who are suitable candidates and neoadjuvant chemotherapy should be considered in patients who are deemed unresectable at initial evaluation (Doan et al. 2010). Novel chemotherapeutic regimens combining 5-FU, folinic acid and oxaliplatin and/or irinotecan have been associated with improved response rates (approximately 50%), allowing 10–30% of the patients with initially unresectable disease to be successfully treated with liver surgery (Adam et al. 2004). In addition, combination with biologic agents that target angiogenesis and the epidermal growth factor receptor (EGFR), bevacizumab and cetuximab, achieves response rates of up to 70%, increasing these figures (Vauthey 2006). Re-evaluation for resection should be done after 2 or 3 months of pre-operative chemotherapy and every 2 months thereafter. Tumour progression before surgery is associated with a poor outcome, even after potentially curative hepatectomy. Tumour control before surgery is crucial to offer a chance of prolonged remission in patients with multiple metastases (Adam et al. 2004). Patients should be referred early for evaluation for resection. The peri-operative complication rate, including hepatobiliary complications, is higher with lengthy pre-operative chemotherapy and is likely related to the prolonged and sequential use of multiple regimens (de Haas et al. 2011).

Once patients have been diagnosed and a decision made in a multidisciplinary setting that resection is appropriate, it is essential to ensure that patients undergo repeat high quality

abdominopelvic CT (or MRI) within a month of the date of surgery. Chest CT should also be performed at this time.

4. Chemotherapy and surgery

The high recurrence rate and the overall poor “true” survival after surgical resection of CRC liver metastases led to the incorporation of the use of chemotherapy. This treatment can be administered in different strategies: neoadjuvant, peri-operative, adjuvant and conversion or downstaging. The latter is administered to patients with unresectable disease with the goal of downsizing the tumour, re-staging it and re-considering its resection.

Chemotherapy seems to improve outcomes compared with surgery alone. Current chemotherapeutic regimens lead to improved survival in patients with unresectable liver metastases. Resection of the primary tumour and the liver lesions is the optimal management of stage IV CRC with liver metastases. For patients with extensive liver metastases, FOLFOX (folinic acid, 5-fluorouracil and oxaliplatin) and FOLFIRI (irinotecan instead of oxaliplatin) have improved resection rates and survival. Upfront chemotherapy in the asymptomatic patient compared with resection of the primary tumour does not appear to affect survival significantly. However, given that 60% of the patients were alive after 2 years, resection of the primary lesion for palliative reasons and local control must be considered in rectal cancer (Cellini et al. 2010).

Optimal regimens and sequencing of chemotherapies when liver resection is an option are unclear. Some suggest that treatment of resectable liver metastases, in the absence of high-risk features (Fong score) should begin with surgery and consider adjuvant chemotherapy after surgery (Fong et al. 1999). If high-risk features are present, most physicians prefer a short course of systemic pre-operative chemotherapy. Peri-operative therapy and regional therapy with hepatic arterial infusion (HAI) increase disease-free survival (DFS) when compared with surgery alone. In unresectable disease, systemic chemotherapy with or without a biologic agent or HAI with systemic therapy must be considered. If the disease becomes resectable, adjuvant treatment should follow surgery. Adjuvant chemotherapy is usually FOLFOX, but HAI combined with systemic chemotherapy is also an option. The role of adjuvant treatment after liver resection should not be viewed in isolation, but rather in the context of prior treatment, surgical preference and individual patient characteristics. Conducting randomized trials examining the role of adjuvant chemotherapy has been difficult because of the rapidly changing chemotherapy regimens and drugs (Power & Kemeny 2010).

Operated patients with a perforated tumour or a considerable lymphatic burden are considered candidates for neoadjuvant chemotherapy before liver surgery, followed by a re-evaluation after 3 months (Garden et al. 2009). The algorithm of the treatment may be that shown in Figure 1 (Kopetz & Vauthey 2008).

During the treatment with 5-fluorouracil/folinic acid plus oxaliplatin or 5-fluorouracil/folinic acid plus irinotecan, the patients deemed to be resectable should be considered as surgical candidates regardless of the associated adverse predictive factors. The emergence of EGFR antibody agents, which act effectively in patients with K-ras wild-type tumour, fosters treatment individualization (Shimada et al. 2009).

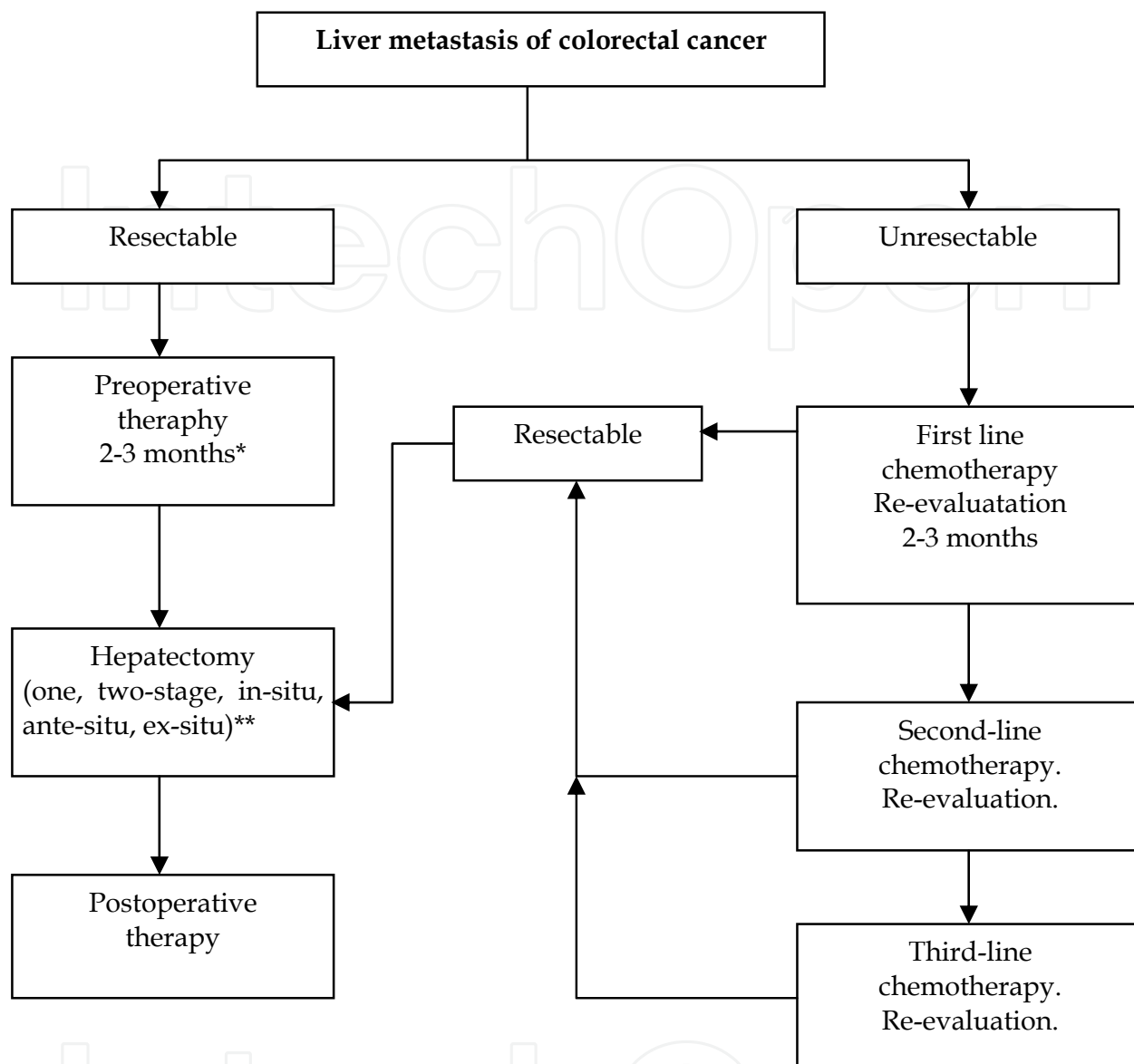


Fig. 1. *Pre-operative therapy depends on the multidisciplinary team and the analyses of the individual case. In some cases, the first option can be resection without pre-operative chemotherapy. **Portal vein embolization (PVE) can be associated to these approaches according to future liver remnants (FLR) volume and the status of the liver (normal, postchemotherapy and cirrhotic).

The efficacy of the peri-operative chemotherapy on survival benefit for resectable liver metastases has not been justified. However, the timing and the indication of the surgery are dramatically changing with the development of chemotherapeutic agents. The overwhelming majority of patients with resectable metastases receive some sort of chemotherapy, although it is not known if the adjuvant regimen is better than the neoadjuvant. The EORTC 40983 study did not demonstrate a clear advantage of pre-operative chemotherapy in patients with initially resectable metastasis, but it could not

answer either if neoadjuvant, adjuvant or peri-operative chemotherapy is superior. Detractors claim that chemotherapy delays surgery while supporters point out that surgery is facilitated and that the treatment provides information on tumour biology (Nordlinger et al. 2008). The surgeon's main concern is to operate on patients with livers affected by chemotherapy, which are usually more rigid, more difficult to manage and tend to bleed more easily. The same study demonstrated that no patient progressed from a resectable disease to an unresectable one, that short cycles of treatment provided minimal liver toxicity, that morbidity was similar in both groups and that survival improved in the chemotherapy sub-group. However, the problem persists over the timing of administering chemotherapy and the management of "ghost lesions" after complete response that cannot be detected with IOUS.

5. Rescuing more patients

In 1986, Ekberg provided several contraindications for the surgery of liver metastases of colorectal origin (4 or more nodules, a size greater than 5 cm, presence of extrahepatic disease and the inability to resect with a margin greater than 1 cm). Others studies corroborated these findings. A thorough analysis of these papers could have reduced their influence realising that they had short series or that their statistical analysis was univariate. As previously stated, these criteria are deemed obsolete. So the question is: can all disease be resected while leaving a functional liver remnant? (Charnsangavej et al. 2006). There exist some innovative strategies that increase the volume of the hepatic remnant. Portal vein embolization (PVE) or ligation causes atrophy of the ipsilateral hemiliver and hypertrophy of the contralateral side. PVE appears to be particularly valuable in patients who present with underlying liver disease. The concomitant administration of chemotherapy may decrease both the tumour load and post-operative recurrences. Furthermore, aggressive approaches in selected cases can provide the only possible cure.

5.1 Downstaging chemotherapy

Downstaging chemotherapy is indicated for metastatic disease and for synchronicity in nonresectable disease. Intravenous or HAI downstaging chemotherapy showed a resectability of 20% (Fusai & Dadvison 2003). The advent of oxaliplatin and irinotecan reached response rates of up to 50% increased over 65% with the addition of bevacuzimab and cetuximab. Although there are no reports of outcomes of liver resection after HAI, its complication rates are so high (57%) that it is dismissed as a first option.

When treating these patients, the question arises as to whether to continue treatment until reaching the maximal effect or stopping once the disease becomes resectable. In general, pre-operative chemotherapy should be stopped once the intrahepatic disease has been downsized to the point where hepatic resection is feasible. Surgery should be considered after 3 or 4 cycles in order to reduce liver toxicity, and therefore surgical morbidity, and to avoid a complete clinical response, difficult to trace intraoperatively. In most patients receiving chemotherapy, a complete response on CT scan does not mean cure (Benoist et al. 2006) due to the fact that in over 80% of the cases there are viable cancer cells in the initial site of the metastasis. Current management of these ghost lesions is to remove all of them if

possible, considering the future liver remnant. In general, all the original sites of disease noted on the pre-therapy imaging need to be resected or ablated.

Since post-operative morbidity affects long-term survival (Laurent et al. 2003), length of chemotherapy treatment must be taken into account. In recent years more and more patients with stable long-term disease (more than 20 months) are considered for surgical treatment. Irinotecan and oxaliplatin have been associated with the development of steatohepatitis. Among patients receiving these drugs, the rates of complications and death after major liver resection are likely to be higher compared to patients not receiving chemotherapy, although this is not completely clear. Albeit systemic treatment is very effective in reducing tumour burden and facilitates the surgical therapy in previously unresectable patients, the recurrence rate is high because of the presence of residual microscopic disease.

5.2 Portal vein embolization

Based on objective data, consensus has been reached on what is an adequate liver remnant and what are the “safe” resection percentages depending on the quality and health of the liver (Zorzi et al. 2007). Figure 2.

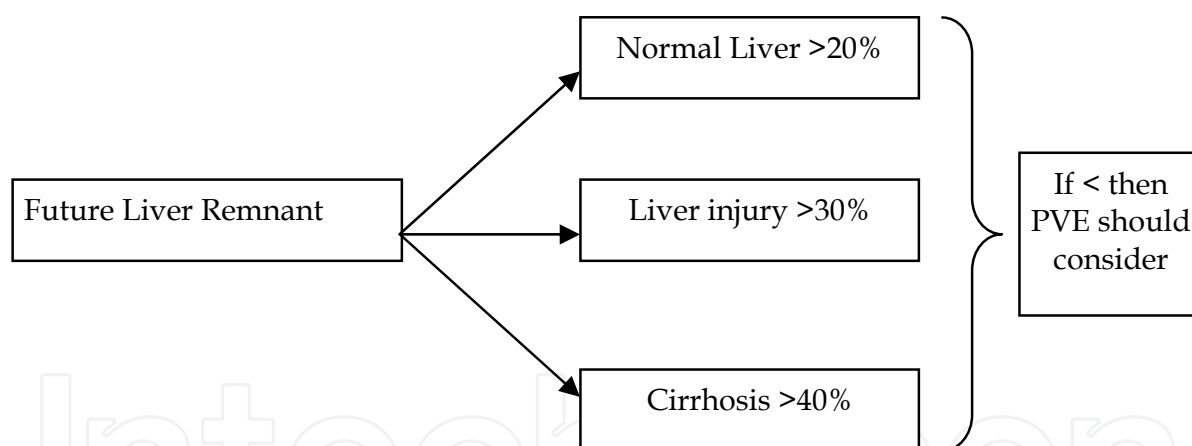


Fig. 2. Minimum FLR volume needed for safe liver resection in patients with normal, intermediate disease or cirrhotic liver (Zorzi et al. 2007).

When the future liver remnant (FLR) is insufficient PVE should be considered. PVE also constitutes a dynamic pre-operative test on the capacity of the liver to respond to the surgical aggression. If a hypertrophy greater than 5% is achieved after PVE, there is a low risk of a terrible post-operative liver insufficiency (Ribero et al. 2007). Chemotherapy does not seem to affect the hypertrophy induced by PVE. A few studies using bevacuzimab recommend a 6 week waiting period between the last dose and the hepatectomy, although its influence on the hypertrophy is unclear.

PVE is well tolerated with minimum side effects such as fever, nausea, and transient abnormality of liver function test. The complication rate is below 5% (Abdallah et al. 2001). Azoulay et al. reported that PVE increased the feasibility of liver resection by 19% and that the actuarial survival rate was 40% at 5 years, similar to that of patients resected without PVE (Azoulay et al. 2000).

5.3 Two-stage hepatectomy

Two-stage hepatectomy is one of the methods to increase the resectability of liver tumours. Its objective is to eliminate the entire tumour burden. The first stage can also be performed together with laparoscopic colorectal resection. It consists of combining two sequential and planned liver resections when it is impossible to resect all liver metastases in a single procedure, while preserving at least 30% of functional liver volume to avoid post-operative liver failure. Frequently, it is associated with peri-operative systemic chemotherapy and PVE, although it is not a rule (Jaeck et al. 2004) (Figure 3).

The first hepatectomy attempts to resect the majority of liver tumours and to get hypertrophy of the remnant liver with or without PVE. The second hepatectomy is performed at least 4 weeks later to allow time for growth and hypertrophy of the FLR. The design of the technique must be meticulous well in advance of the first resection as an important strategy to achieve complete removal, admitting that around 30% of patients will not be rescued on the second hepatectomy.

Usually, on the first hepatectomy the future remnant liver is cleared out of tumours with non-anatomic resections and/or radiofrequency ablation or at most a single segment resection. As mentioned, it can be associated to the removal of the primary colorectal tumour, preferably through a laparoscopic approach or using a "J" incision if it is located on the right colon. After 2 to 4 weeks after the clearance of the FRL, percutaneous PVE is performed. Alternatively, PVE can be done during the first hepatectomy through the ligation and alcoholization of the right portal vein, which is the side more often embolized. The second hepatectomy can be done on the fourth or fifth week after PVE, when an adequate hypertrophy of the non-embolized hemi-liver is achieved.

Some authors recommend pre-operative chemotherapy during the entire process. This should be determined by the criteria of the multidisciplinary team according to each individual case (Adam et al. 2000). We carry out this procedure by performing PVE in the first hepatectomy with or without the removal of the primary tumour. After a 4 week waiting period and a CT confirming an adequate FRL, a second hepatectomy is performed. If during the second stage hepatectomy new liver metastases or extrahepatic lesions are discovered, such as localized peritoneum implants, the procedure can still be performed if a R0 resection can be achieved. A recent series reports a 5 year overall survival rate of 32% for patients on whom the procedure had been completed (Narita et al. 2011).

Two factors affect the success of two-stage hepatectomy: patient selection and optimal chemotherapy regimen. This procedure may be the only therapy able to provide long-term survival and a possible cure for patients with initially unresectable multiple and bilobar CRC liver metastases.

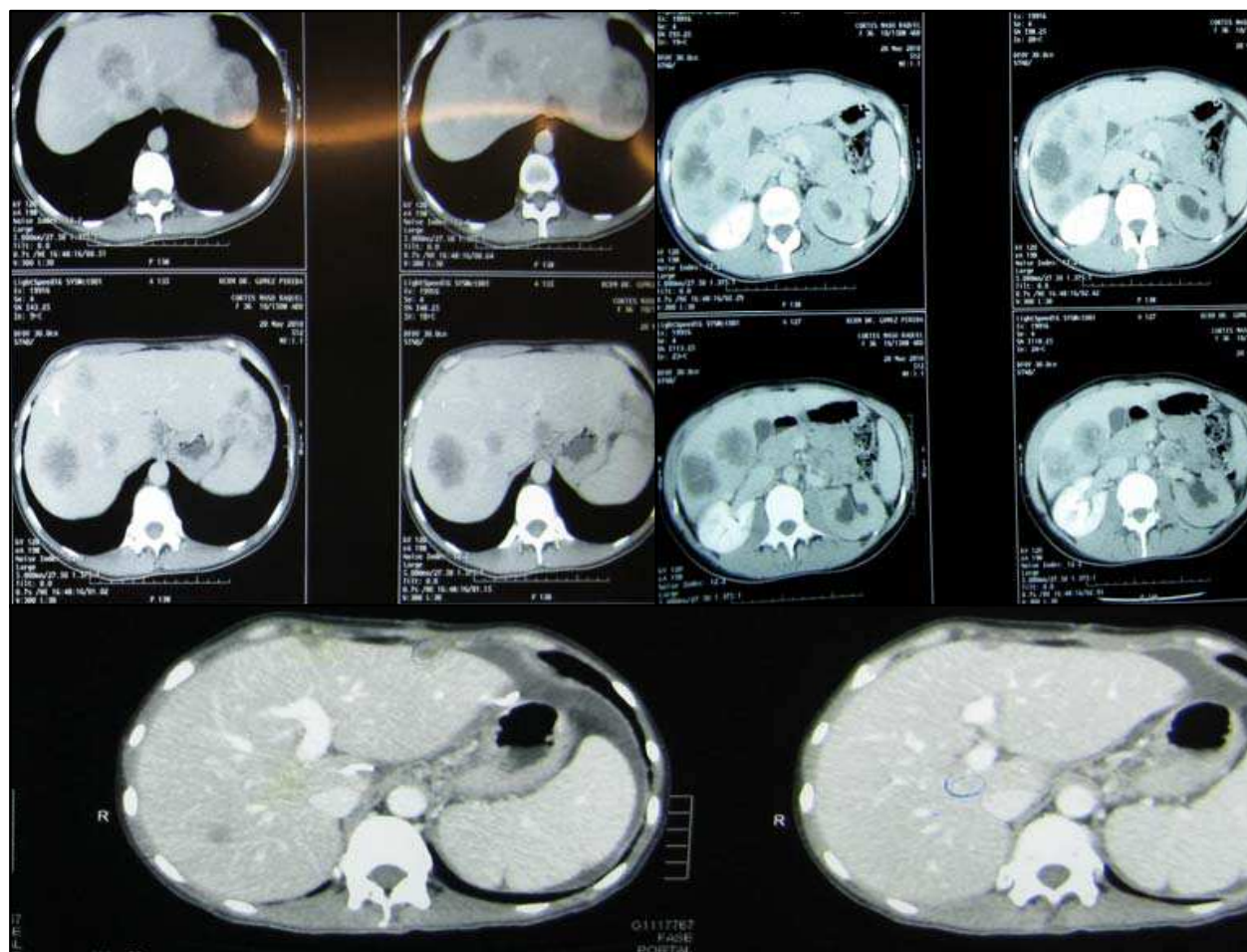


Fig. 3. Multiple and bilobar metastases, right hydronephrosis and rectum cancer involving the right ovary in a 37 year old woman. After chemotherapy treatment, first stage surgery consisted of tumour clearance of the left liver, anterior colorectal resection, right oophorectomy and right PVE (lower pictures). Five weeks later an extended right hepatectomy was performed.

5.4 Synchronicity: Colorectal tumour and liver metastases

On the international registry of liver metastasis from CRC, LiverMet Survey, a 51.7% of synchronicity has been recorded in January 2011 (table 1). This frequent sort of presentation, together with the expansion of the criteria of resectability and the laparoscopic approach for the colorectal and liver surgery, have created a new insight within the multidisciplinary teams.

Sinc/Metac	Number of patients	1 year	3 year	5 year	10 year
Sincronic	6112	90%	58%	39%	22%
Metacronic	5724	90%	60%	43%	26%

Table 1. LiverMet Survey, January 2011. Survival rates in 11836 patients after hepatectomy (with permission).

As mentioned, colon resection can be done on the first stage, or a liver approach can be done first after a downstaging of the liver tumour/tumours. What should be done first depends on

the primary tumour (mainly in cases of rectal cancer that require an ultralow resection or are T3 or T4) and on the volume of liver parenchyma that needs to be removed. If the patient has been downstaged to resectability, the liver should be approached first (if possible) and the colorectal tumour should be operated 4 to 6 weeks later (Figure 4).

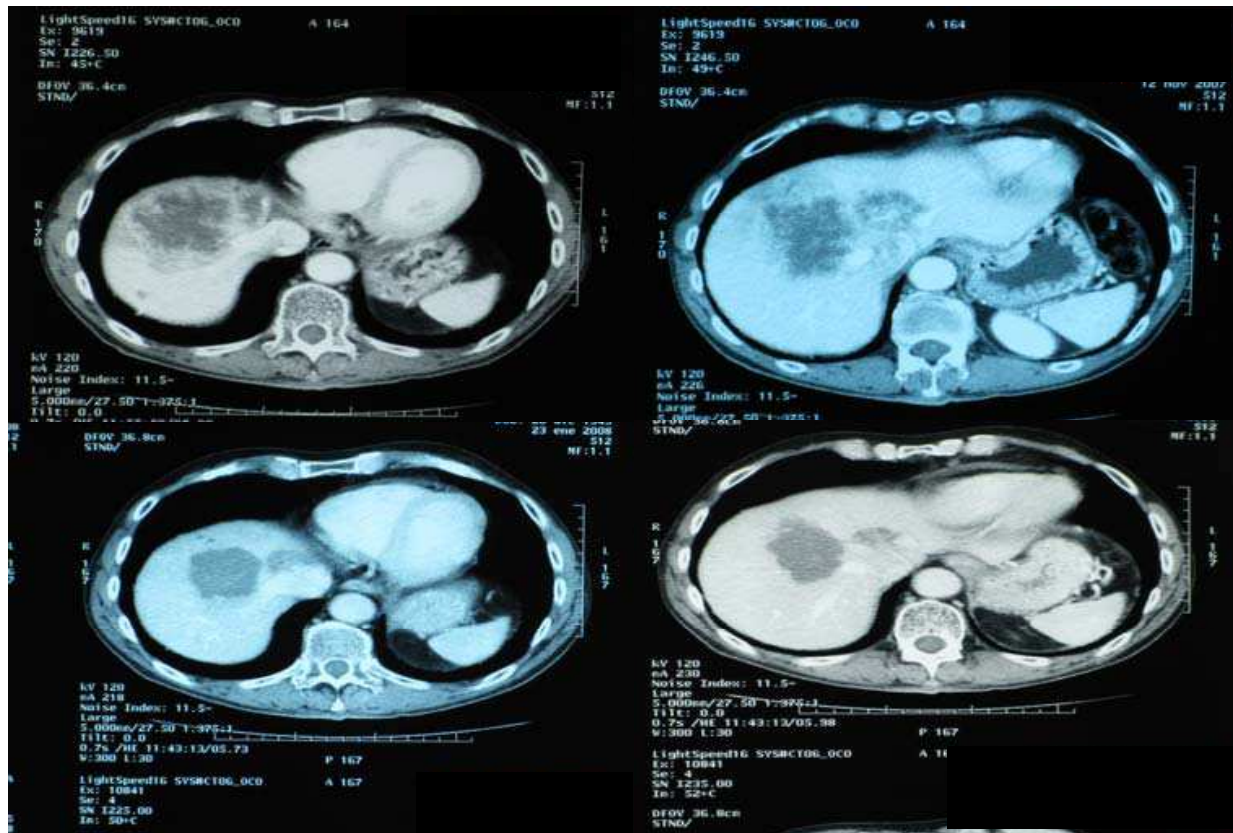


Fig. 4. Large liver metastasis involving the three hepatic veins (upper pictures) in a 61 year old patient with rectal cancer. After 3 months of chemotherapy (lower pictures) the patient underwent left hepatectomy, segment (Sg) 1 and Sg 8 segmentectomies and right hepatic vein reconstruction. Six weeks later the rectal cancer was resected.

5.5 Ante-situ, in-situ and ex-situ procedures: Extreme liver surgery

Liver transplantation has brought with it advances in techniques that can be applied to nontransplant hepatic surgery. The lessons learned from reducing adult-sized livers for implantation in children, living related donor liver transplantation and split liver transplantation can all be applied in the nontransplant setting. Tumours that were considered unresectable with standard techniques can now be considered for resection using in-situ, ante-situ and ex vivo or bench liver surgery. In the last technique, the liver is completely removed from the patient and perfused with preservation solution. A bloodless transection of hepatic parenchyma can then be performed allowing complex reconstruction of hepatic veins or portal structures after which the liver is reimplanted in the patient. The ex vivo technique was first performed by Pichlmayr and colleagues in 1988 and has been applied sparingly in selected patients since then (Hemming et al. 2000).

The common basis for in-situ, ante-situ and ex-situ resection is the total vascular exclusion (TVE) of the liver, and the perfusion of the organ by preservation hypothermic solution.

The principles are the same for the three techniques, which differ only in the extent to which liver is mobilized from its vascular connections, hylum and caval vein. Generally, a veno-venous bypass is used to avoid venous congestion during prolonged caval and portal crossclamping and a hypothermic preservation solution is instilled through the portal vein (Fortner et al. 1978). In a study population about liver resection under TVE, Azoulay et al. concluded that standard TVE of any duration with hypothermic perfusion of the liver, in this issue in-situ procedure, was associated with a better tolerance to ischemia. Furthermore, compared with TVE ≥ 60 minutes, it was associated with better post-operative liver and renal functions and lower morbidity (Azoulay et al. 2005). The main indications of the three techniques are tumours that involve vascular structures of the hylum, venous confluence or inferior vena cava (IVC), or are in close proximity to them. The technique can be used for benign, primary or metastatic tumours. The decision about what technique to use depends on the tumour location and its relationship with the three hepatic veins and caval vein. It is important to notice that the ex-situ technique is losing support due to its high morbidity and mortality. The location of the lesion or lesions in or near the suprahepatic IVC represents a true challenge due to the impossibility of using conventional resection techniques. Furthermore, optimal peri-operative anaesthetic management is crucial in this setting, and the anaesthesia team should be familiar with the hepatic transplant procedure.

The involvement of the inferior vena cava does not necessarily preclude resection (Figure 5). Liver resection with reconstruction of the IVC can be performed in selected cases. The resected IVC may then be replaced with an autogenous vein graft or a prosthetic material. The mortality rate of resection IVC is 4.5-25% and morbidity up to 40% (Azoulay et al. 2005). The increased risk associated with the procedure appears to be balanced by the possible benefits, particularly when the lack of alternative approaches is considered (Hemming et al. 2004).

In conclusion, liver resections, due to the adoption of several advanced techniques, such as vascular exclusion, veno-venous bypass, hypothermic perfusion of the liver (in-situ, ante-situ or ex-situ), have become more common and, when IVC is involved, resection of the vein is no longer considered a contraindication.

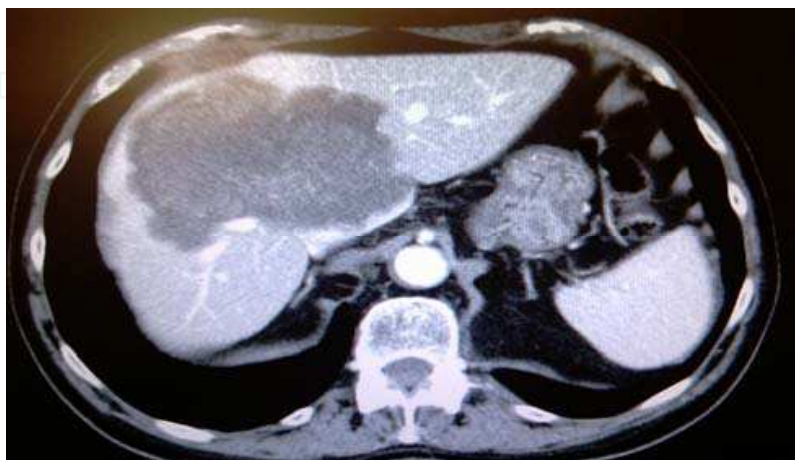

Fig. 5. Huge liver metastasis in a 64 year old patient with colon cancer. First surgery was an extended right hepatectomy plus Sg 1 segmentectomy, after PVE of right and Sg 4 portal veins. A left hemicolectomy was performed 7 weeks later.

6. Repeat resections

The first large series of liver resections for secondary tumours was reported in 1978 (Foster 1978). By improvement in surgical techniques, peri-operative patient's care and management of complications, the morbidity and mortality associated with liver resection were reduced. This has been a very important factor to increase the aggressiveness of the surgical approach.

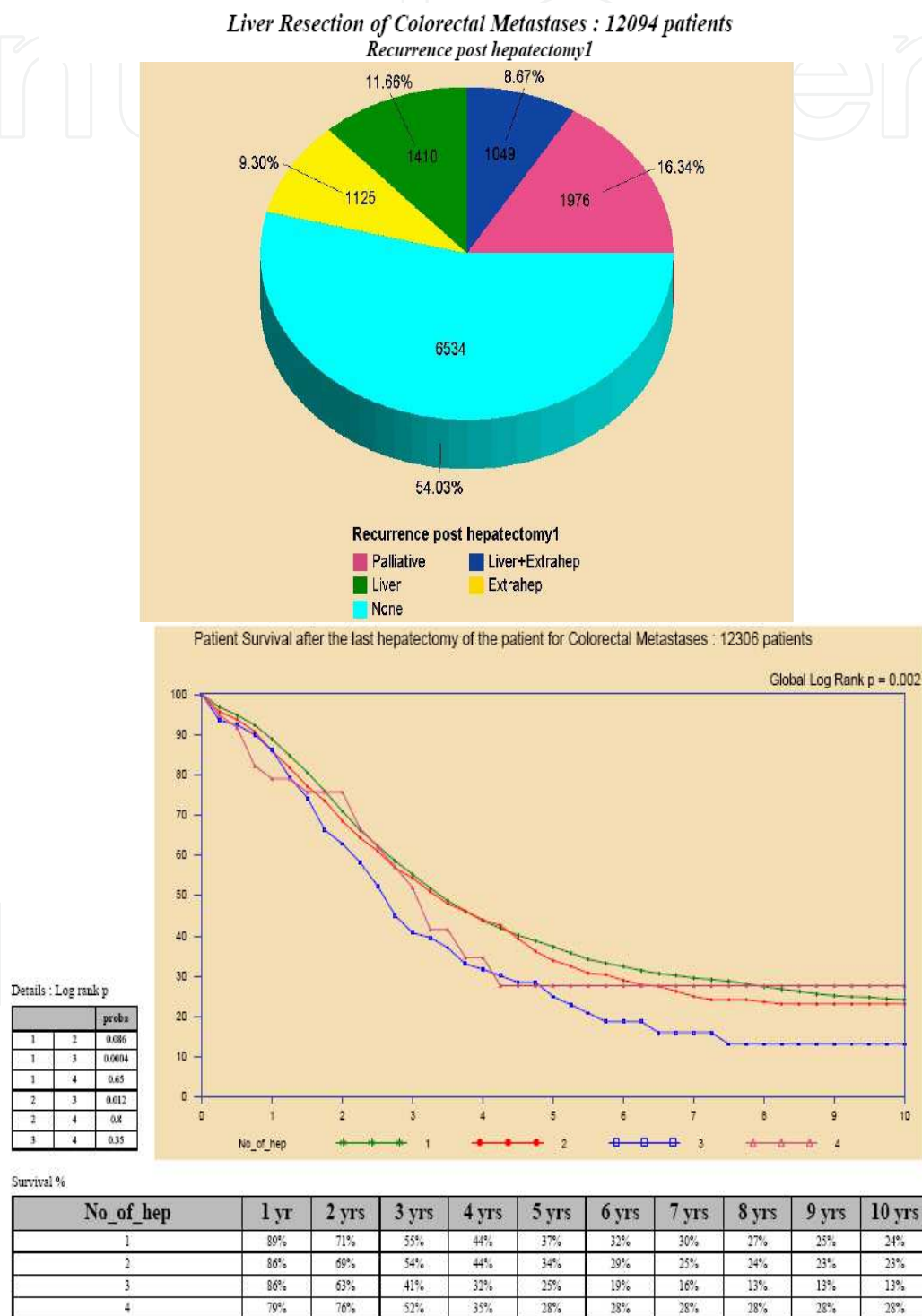


Fig. 6. LiverMet database, with permission.

Liver recurrence of CRC is common (Figure 6) but only 5-27% of the patients are candidates for potentially curative repeated hepatectomy. About 70% of recurrences will be observed within the first 12 months after resection and 92% will be apparent within 24 months (Langenhoff et al. 2009). In medically fit patients, repeat hepatectomy has emerged as a safe and effective procedure under the same criteria of selection of the first hepatectomy. Although the prognostic variables provide rough indicators of prognosis, they should not be used as absolute contraindications to surgery. The multidisciplinary team should plan the strategy individually. Each new re-hepatectomy needs a particular and specific evaluation: disease-free interval, number of metastases, quality of life, general health condition, resectable extrahepatic disease, assessment of residual liver volume, etc. by the multidisciplinary team (Figure 7).

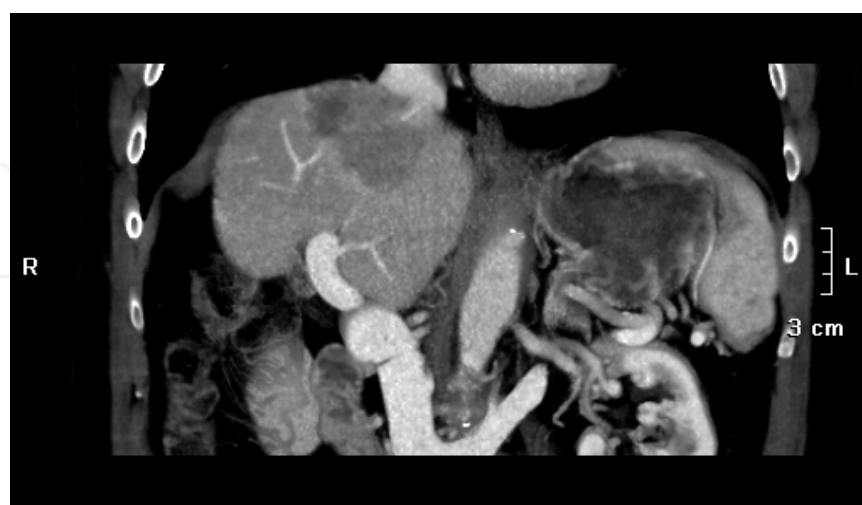
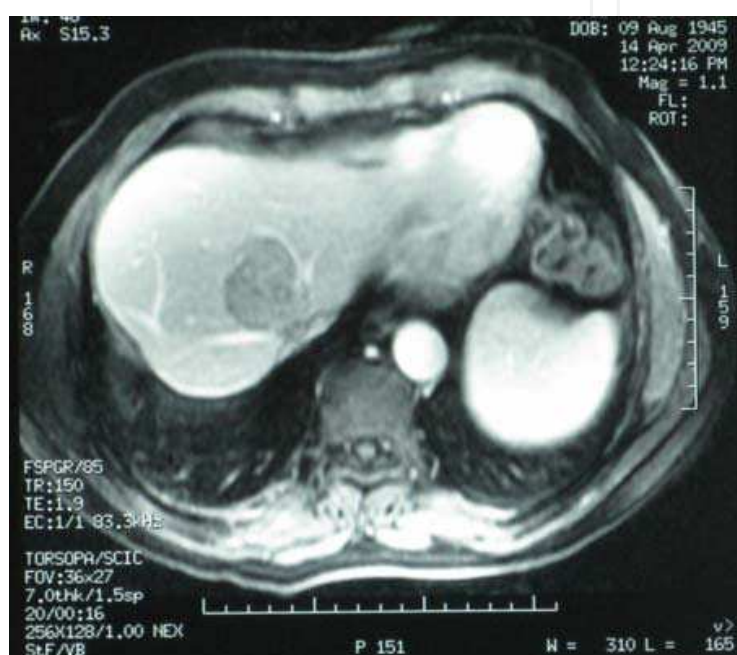
Fig. 7. A 63 year old patient with right hepatectomy plus Sg 4a resection; 24 months later a recurrence involving the only hepatic vein (left hepatic vein) appeared. Tumour was removed and the left hepatic vein was reimplanted in the caval vein using graft prosthesis (less than 60 minutes of total vascular exclusion).

The LiverMet Survey includes 12448 liver resections of which 14.5% are repeated hepatectomies (Figure 8, Table 2). Patients likely to benefit of this approach represent a small and highly selected group. Maybe, an accurate genetic, immunohistochemical and histological profile of the patient's tumour will be able to conclude who will benefit from this aggressive treatment.

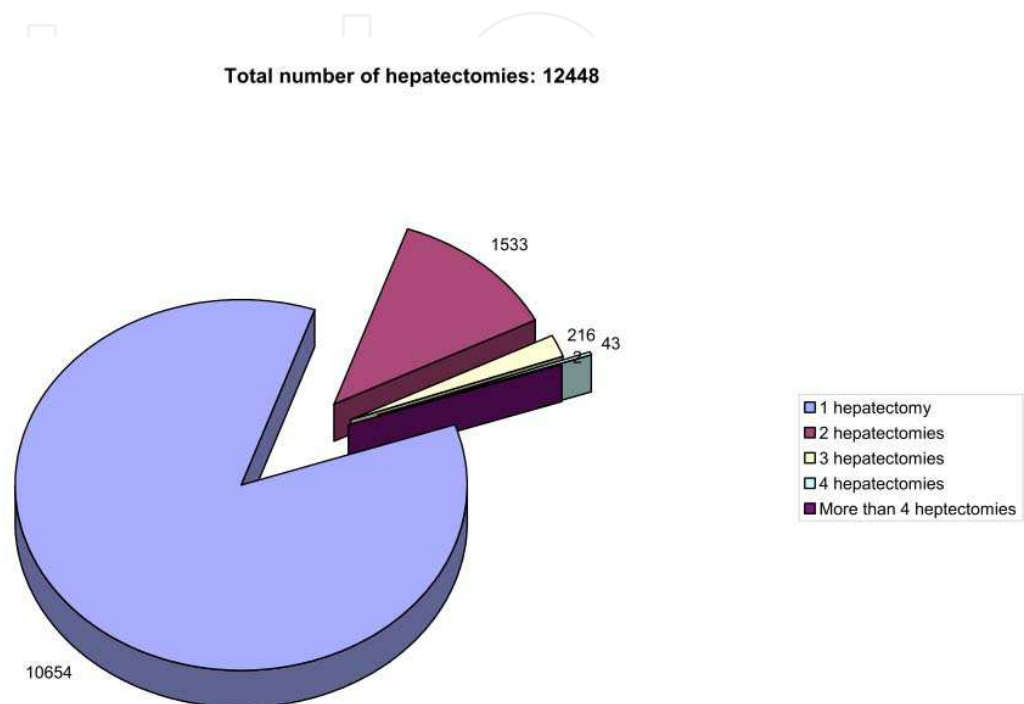


Fig. 8. LiverMet Survey: number of hepatectomies.

Repeat hepatectomies	Patients	% over initial resection	3-years SV	5-years SV
LiverMetsurvey (2011)	1794	15	58	37
Adam et al. (2003)	199	32	54	35
Fernandez - Trigo et al. (1995)	170	No reported		28
Petrowsky et al. (2002)	126	8	51	34
Nordlinger et al. (1994)	116	6	33	
Ishiguro et al. (2006)	111	No reported	74	41
Thelen et al. (2007)	94	12	55	38
Yamamoto et al. (1999)	75	21	48	31
Shaw et al. (2006)	66	9	68	44
Adam et al. (1997)	64	26	60	41
Yan, et al. (2007)	55	14		49
Nishio et al. (2007)	54	10	53	46

Table 2. Repeat hepatectomies series and survival rates.

Recurrence after repeat hepatectomy has been reported in 60–80% of patients (Smith & McCall 2009). A few have resectable disease limited to the liver and may be candidates for a third or even fourth hepatic resection. In our group there are two patients with five hepatectomies. Reports of large repeated hepatectomy series show that 9–30% of patients who underwent a second hepatectomy for colorectal liver metastases had a third resection (Fong et al 1999; Söreide et al. 2008; Yamamoto et al. 1999; Petrowsky et al. 2002) and 4% of them had a fourth resection (Adam et al. 2003; Yamamoto et al. 1999). The safety of multiple repeated hepatic resections has been demonstrated in recent reports, and long-term survivors have been documented (Adam et al. 2003; Nordlinger et al, 1994; Yamamoto et al. 1999; Petrowsky et al. 2002). LiverMet Survey published the largest series (n = 251) of third hepatectomies for recurrent CRC liver metastases with a survival benefit of 29% at 5 years. Adam et al. published a large series of patients who underwent a third liver resection with zero mortality and a morbidity rate of 5%, not significantly different from those who have had only one or two liver resections. In addition, patients with a third liver resection had a survival benefit of 32–38% at 5 years (Adam et al. 2003; Yamamoto et al. 1999). Major hepatectomy is possible in a minority of these patients, who represent a small and highly selected group (Petrowsky et al. 2002).

7. Immunohistochemical markers based on tissue microarrays

The ideal marker predictor of outcome should include the following characteristics: of low cost and easy measure, reproducibility across institutions, and measurable both before and after treatment. Most importantly, this factor would predict major differences in outcome that significantly impact treatment. A clinical example is K-ras status as a predictor of response to therapy with cetuximab, a monoclonal antibody against the EGFR. In a prospective randomized controlled trial, patients with advanced CRC were randomized to receive treatment with or without cetuximab. When stratified for K-ras status, patients with wild type K-ras tumours demonstrated a significant survival advantage compared to those with mutated K-ras tumours, who derived no benefit from the agent. Therefore, patients with mutated K-ras do not receive cetuximab therapy and are spared the toxicity associated with a treatment with no proven benefit. To date, there is no specific clinical risk score or biomarker that specifically prognosticates or guides therapy for patients with resectable CRC liver metastases to this degree. This marker may combine the immunohistochemical markers of cell proliferation and cell cycle control, p53 and Ki67.

Surface antigen CD133 is a cell membrane glycoprotein that is considered as a cell surface marker expressed in stem cells of hematopoietic immature cells, but not in mature blood cells. CD133 has also been shown to be a marker of immature neuronal stem cells (Karoui et al. 2006). Two antibodies, CD133/1 or AC133 and CD133/2 (AC141), recognize it. CD133+ cells in colon cancer are helpful markers for detection of tumour initiating cells (Karoui et al. 2006) (Figure 9).

CD44 is considered as a cell membrane marker or epithelial cell adhesion molecule (*EpCAM*). Its phenotype *EpCAM^{high}-CD44⁺* is becoming established as a good marker for immature stem cells of human colon mucosa in certain series (Ieta et al. 2008) (Figure 10).

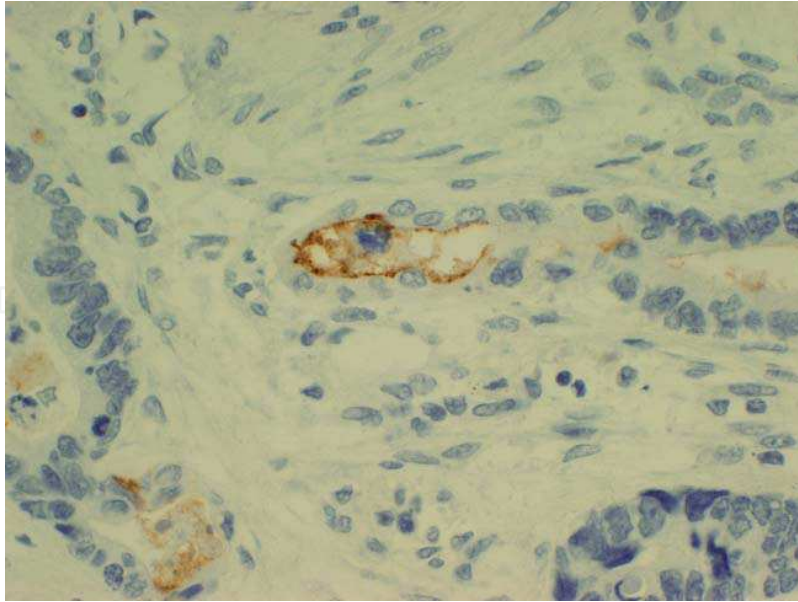


Fig. 9. Immunohistochemical pathological study. Positive membrane staining for stem cell markers CD133, CS-130127, CD133 (32AT1672) in most cells of metastatic adenocarcinoma. Santa Cruz Biotechnology®, Inc (x100).

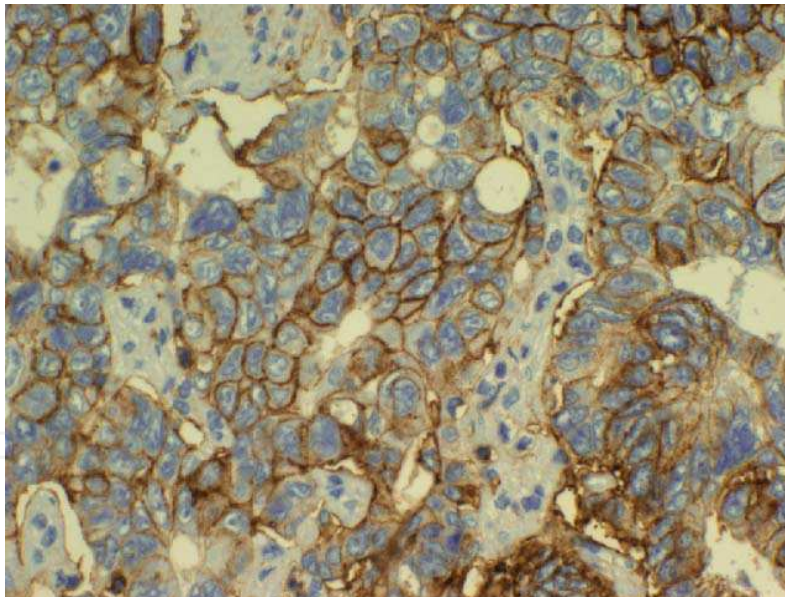


Fig. 10. Immunohistochemical pathological study. Positive membrane staining for stem cell markers CD44, *EpCAM*^{high}-CD44⁺ in most cells of metastatic adenocarcinoma. Santa Cruz Biotechnology®, Inc (x400).

CD166 is considered as a marker for both cell membrane or epithelial cell adhesion molecule (*EpCAM*) and cytoplasm (Figure 11). It is a marker of mesenchymal stem cells whose role in carcinogenesis is not fully clear (Ieta et al. 2008). Its phenotype *EpCAM*^{high}-CD166⁺ added to *EpCAM*^{high}-CD44⁺ is starting to be considered as an additional marker of immature stem cells in human colon mucosa (Dalerba et al. 2007).

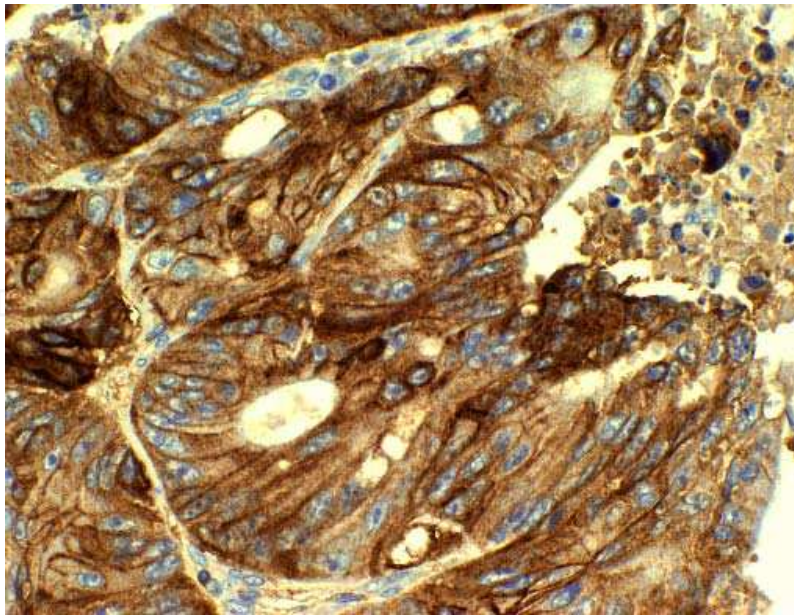


Fig. 11. Immunohistochemical pathological study. Positive membrane staining for stem cell markers CD166, 35264, CD166 LYO 1 mL *EpCAM^{high}-CD166⁺* in most cells of metastatic adenocarcinoma. Menarini Diagnostics® (x40).

Borrego et al. (2010) analyzed, as did Kokudo et al. (2002), p53 expression. The immunohistochemical markers tested in their study (p53, Ki-67) were not poor prognostic factors, in agreement with Saw et al. (2002). By contrast, authors such as Tanaka et al. 2004 reported that p53 or Ki-67 expression had a negative impact on survival. It should be noticed, however, that in Borrego-Estella et al.'s study survival was longer than 5 years in patients with high Ki-67 levels and in those with a high mitotic index (>10 mitosis/mm²), which is also another expression of the tumour proliferation index. However, no significant relationship was found between cell proliferation, as measured by Ki-67 and p53, whose changes express a loss of cell cycle control, and survival.

For O'Brien et al. (2007), most CD133⁺ stem cells had a 200-fold greater oncogenic potential than CD133⁻ cells for development of CRC. In addition, this subpopulation is able to maintain itself and to differentiate and become established again as a tumour when transplanted in certain solid organs of experimental animals. For Borrego-Estella et al. significant trends were found in their series with regard to membrane CD133 and CD166 markers. According to O'Brien et al. and Ricci-Vitiani et al. 2007, in several CRC, CD44 was more determinant than CD133, because CD44 was expressed in tumour lines not expressing CD133.

To compare the results of Borrego et al. with other groups is difficult since many authors (Fong et al. 1999; Pawlik et al. 2005) did not performed immunohistochemical studies. However, regarding immunohistochemical markers, more significant results were not achieved probably because the only technique performed was immunohistochemistry array, but not flow cytometry or other molecular biology techniques.

Another interesting marker, microsatellite instability, is a measure of the inability of the DNA mismatch repair system to correct errors that occur during DNA replication. It is the alternative pathway to chromosomal instability with loss of heterozygosity in colorectal

carcinogenesis. Microsatellite instability has been suggested to be prognostic for survival and predictive for response to therapy in patients with colorectal cancer.

In conclusion, many studies have analyzed pre-operative prognostic factors in patients undergoing liver resection for hepatic metastases from CRC in order to select patients for surgery. However, intraoperative and post-operative factors have been poorly analyzed. Future studies should establish post-operative prognostic factors through histological and immunohistochemical tests based on the tissue microarray technique.

8. References

- Abdalla EK., Adam R., Bilchik AJ., Jaeck D., Vauthey JN., Mahvi R. (2006). Improving Resectability of Hepatic Colorectal Metastases: Expert Consensus Statement. *Annals of Surgical Oncology*, 13(10): 1271-1280
- Abdallah EK., Hicks ME., Vauthey JN. (2001) Portal vein embolization: rationale, technique and future prospects. *Br J Surg* 88: 165-175
- Adam R., Laurent A., Azoulay D., Castaing D., Bismuth H. (2000). Two-stage hepatectomy: a planned strategy to treat unresectable liver tumour. *Ann Surg* 232: 777-785
- Adam R., Bismuth H., Castaing D., Waechter F., Navarro F., Abascal A., Majno P., Engerran L. (1997) Repeat hepatectomy for colorectal liver metastases. *Ann Surg* 225: 51 -60
- Adam R., Pascal G., Azoulay D., Tanaka K., Castaing D., Bismuth H. (2003) Liver resection for colorectal metastases: the third hepatectomy. *Ann Surg* 238: 871 - 83
- Adam R., de Haas RJ., Wicherts DA., Aloia TA., Delvart V., Azoulay D., Bismuth H., Castaing D. (2008) Is hepatic resection justified after chemotherapy in patients with colorectal liver metastases and lymph node involvement? *J Clin Oncol* 26(22): 3672-80
- Adam R., Delvart V., Pascal G., Castaing D., Azoulay D., Giacchetti S., Paule B., Kunstlinger F., Ghémard O., Levi F., Bismuth H. (2004) Rescue surgery for unresectable colorectal liver metastases downstaged by chemotherapy: a model to predict long-term survival. *Ann Surg* 240:644-657
- Adam R., Pascal G., Castaing D., Azoulay D., Delvart V., Paule B., Levi F., Bismuth H. (2004) Tumour progression while on chemotherapy: a contraindication to liver resection for multiple colorectal metastases? *Ann Surg* 240:1052-1061.
- Adam R., Lucidi V., Bismuth H. (2004) Hepatic colorectal metastases: methods of improving resectability. *Surg Clin N Am* 84 659-671
- Al-Hajj M., Wicha MS., Benito-Hernandez A., Morrison SJ., Clarke MF. (2003) Prospective identification of tumorigenic breast cancer cells. *Proc Natl Acad Sci USA*; 100:3983-3988
- Altendorf-Hofmann A., Scheele J. (2003) A critical review of the major indicators of prognosis after resection of hepatic metastases from colorectal carcinoma. *Surg Oncol Clin N Am* 12: 165-192
- Artigas V., Marín Hargreaves G., Marcuello E., Pey A., González JA., Rodríguez M., Moral A., Monill JM., Sancho J., Pericay C., Trías M. (2007) Surgical resection of liver metastases from colorectal carcinoma. Experience in Sant Pau Hospital. *Cir Esp* 81: 339-44
- Azoulay D., Castaing D., Smail A., Adam R., Cailliez V., Laurent A., Lemoine A., Bismuth H. (2000). Resection of non-resectable liver metastases from colorectal cancer after percutaneous portal vein embolization. *Ann Surg* 4: 480-486

- Azoulay D., Eshkenazy R., Andreani P., Castaing D., Adam R., Ichai P., Naili S., Vinet E., Saliba F., Lemoine A., Gillon MC., Bismuth H. (2005). In situ hypothermic perfusion of the liver versus standard total vascular exclusion of complex liver resection. *Ann Surg* 241: 277-285
- Battifora H. (1986) The multitumour (sausage) tissue block: novel method for immunochemical antibody testing. *Lab Invest* 55:244-8
- Belli G., D'Agostino A., Ciciliano F., Fantini C., Russolillo N., Belli A. (2002) Liver resection for hepatic metastases: 15 years of experience. *J Hepatobiliary Pancreat Surg* 9 (5): 607 - 613
- Benoist S., Brouquet A., Penna C., Julié C., El Hajjam M., Chagnon S., Mitry E., Rougier P., Nordlinger B. (2006) Complete response of colorectal liver metastases after chemotherapy: does it mean cure? *J Clin Oncol* 20;24(24):3939-45
- Bipat S., van Leeuwen MS., Comans EF., Pijl ME., Bossuyt PM., Zwinderman AH., Stoker J. (2005). Colorectal liver metastases: CT, MR imaging, and PET for diagnosis-meta-analysis. *Radiology* 237: 123-31
- Bipat S., van Leeuwen MS., IJzermans JNM., Comans EFL., Planting AST., Bossuyt PMM., Greve J-W., Stoker J. (2007) Evidence-based guideline on management of colorectal liver metastases in the Netherlands. *Ned J Med* 63(1): 1-14
- Bismuth, H. (1982) Surgical anatomy and anatomical surgery of the liver. *World J Surg* 6: 3-9, ISSN 0364-2313
- Bluemke DA., Paulson EK., Choti MA., DeSena S., Clavien PA. (2000) Detection of Hepatic Lesions in Candidates for Surgery: Comparison of Ferumoxides-Enhanced MR Imaging and Dual-Phase Helical CT. *AJR* 175: 1653-1658
- Bonnet D., Dick J. (1997) Human acute myeloid leukemia is organized as a hierarchy that originates from a primitive hematopoietic cell. *Nature Medicine* 3:730-737
- Borrego V., Serrablo A., Hörndler C. (2010). Study of liver metastases of colorectal cancer with surgical rescue. Identification of prognostic biological markers. University of Salamanca Editions. Collection VITOR. 1st Ed. pp. 243-248. ISBN: 978-84-7800-205-4.
- Casanova D., Figueras J., Pardo F. (2004) Metástasis hepáticas. In: Guía Clínica de la Asociación Española de Cirugía: Cirugía hepática. Arán, Madrid; pp 164-76.
- Cellini C., Hunt SR., Fleshman JW., Birnbaum EH., Bierhals AJ., Mutch MG. (2010) Stage IV rectal cancer with liver metastases: is there a benefit to resection of the primary tumour? *World J Surg* 34(5): 110
- Chami L., Lassau N., Malka D., Ducreux M., Bidault S., Roche A., Elias D. (2008). Benefits of Contrast-Enhanced Sonography for the Detection of Liver Lesions: Comparison with Histologic Findings. *AJR* 190: 683-690
- Charnsangavej C, Clary B, Fong Y., Grothey A., Pawlik TM., Choti MA. (2006). Selection of patients for resection of hepatic colorectal metastases: expert consensus statement. *Ann Surg Oncol* 13 (10): 1261-1268.
- Choti M., Sitzmann J., Tiburi ME., Sumetchotimetha W., Rangsin R., Schulick RD., Lillemoe KD., Yeo CJ., Cameron JL. (2002). Trends in long term survival following liver resection for hepatic colorectal metastases. *Ann Surg* 235: 759-66.
- Coenegrachts K., De Geeter F., ter Beek L., Walgraeve N., Bipat S., Stoker J., Rigauts H. (2009). Comparison of MRI (including SS SE-EPI and SPIO-enhanced MRI) and FDG-PET/CT for the detection of colorectal liver metastases. *Eur Radiol* 19(2): 370-379
- Couinaud C (1957). Le Foie, Études Anatomiques et Chirurgicales. Masson

- Dalerba P., Cho RW., Clarke MF. (2007) Cancer stem cells and tumour metastasis: first steps into uncharted territory. *Ann Rev Med* 58:267-284.
- de Haas R J., Wicherts DA., Andreani P., Pascal G., Saliba F., Ichai P., Adam R., Castaing D., Azoulay D. (2011) Impact of Expanding Criteria for Resectability of Colorectal Metastases on Short- and Long-Term Outcomes After Hepatic Resection. *Ann Surg* 253(6): 1069-1079
- Doan P L., Vauthey JN., Palavecino M., Morse MA. (2010) Colorectal Liver Metastases. In: *Malignant Liver Tumours. Current and Emerging Therapies*. Clavien PA, Breitenstein S (Ed), pp. 342-6, Wiley-Blackwell
- Donadon M., Ribero D., Morris-Stiff G., Abdalla EK., Vauthey JN. (2007) New Paradigm in the Management of Liver-Only Metastases From Colorectal Cancer. *Gastrointest Cancer Res* 1(1): 20-27
- El Khodary M., Milot L., Reinhold C. (2011) Imaging of Hepatic Metastases. In: *Liver Metastasis: Biology and Clinical Management*. Brodt P (Ed), pp. 307-353, Springer Science+Business Media B.V., ISBN 978-94-007-0291-2, New York
- Elias D., Liberale G., Vernerey D., Pocard M., Ducreux M., Boige V., Malka D., Pignon JP., Lasser P. (2005) Hepatic and extrahepatic colorectal metastases: when resectable, their localization does not matter, but their total number has a prognostic effect. *Ann Surg Oncol* 12: 900-909.
- Elias D., Ouellet JF., Bellon N. (2003) Extrahepatic disease does not contraindicate hepatectomy for colorectal liver metastases. *Br J Surg* 90: 567-574.
- Fernandez-Trigo V., Shamsa F., Sugarbaker PH.. (1995) Repeat liver resections from colorectal metastasis. Repeat Hepatic Metastases Registry. *Surgery* 117: 296-304
- Fernandez FG., Drebin JA., Linehan DC., Dehdashti F., Siegel BA., Strasberg SM. (2004) Five-year survival after resection of hepatic metastases from colorectal cancer in patients screened by positron emission tomography with F-18 fluorodeoxyglucose (FDG-PET). *Ann Surg* 240(3): 438-50
- Figueras J., Burdio F., Ramos E., Torras J., Llado L., Lopez-Ben S., Codina-Barreras A., Mojal S. (2007). Effect of subcentimeter nonpositive resection margin on hepatic recurrence in patients undergoing hepatectomy for colorectal liver metastases. Evidences from 663 liver resections. *Annals of Oncology* 18: 1190-1195
- Fioole B., de Haas RJ., Wicherts DA., Elias SG., Scheffers JM., van Hillegersberg R., van Leeuwen MS., Borel Rinkes IH. (2008) Additional value of contrast enhanced intraoperative ultrasound for colorectal liver metastases.. *Eur J Radiol* 67(1): 169-7
- Fong Y., Fortner J., Sun RL., Brennan MF., Blumgart LH. (1999) Clinical score for predicting recurrence after hepatic resection metastatic colorectal cancer: analysis of 1001 consecutive cases. *Ann Surg* 230:309-18.
- Fortner JG., Kim DK., MacLean BJ., Barrett MK., Iwatsuki S., Turnbull AD., Howland WS., Beattie EJ Jr. (1978). Major hepatic resection for neoplasia: personal experience in 108 patients. *Ann Surg* 188: 363-371
- Foster JH. (1978) Survival after liver resection for secondary tumours. *Am J Surg* 135: 389-394
- Fusai G., Dadvison BR. (2003) Strategies to increase the resectability of liver metastases from colorectal cancer. *Cancer* 20: 431-496.
- Galli R., Binda E., Orfanelli U., Cipelletti B., Gritti A., De Vitis S., Fiocco R., Foroni C., Dimeco F., Vescovi A. (2004) Isolation and characterization of tumourigenic, stem like neural precursors from human glioblastoma. *Cancer Res* 64:7011-7021.

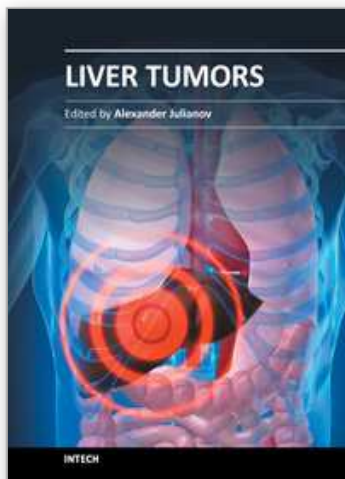
- Garden OJ., Rees M., Poston GJ., Mirza D., Saunders M., Ledermann J., Primrose JN., Parks RW. (2006). Guidelines for resection of colorectal cancer liver metastases. *Gut* 55 (Suppl 3): iii1-iii8
- Guglielmi A., Pachera S., Ruzzenente A. Surgical Therapy of Hepatic Metastases. In: Delaini GG. Rectal Cancer: New Frontiers in Diagnosis, Treatment and Rehabilitation. © Springer-Verlag Milan 2005
- Harmantas A., Rotstein LE., Langer B. (1996) Regional versus systemic chemotherapy in the treatment of colorectal carcinoma metastatic to the liver. Is there a survival difference? Metanalysis of the published literature. *Cancer* 78: 1639-45. PMID: 8859174.
- Hemming AW., Chari RS., Cattral MS. (2000). Ex vivo resection. *Can J Surg* 43(3): 222-224
- Hemming AW., Reed AL., Langham MR Jr., Fujita S., Howard RJ. (2004) Combined Resection of the Liver and Inferior Vena Cava for Hepatic Malignancy. *Ann Surg* 239: 712-721
- Hill RP. (2006) Identifying cancer stem cells in solid tumours: case not proven. *Cancer Res* 66: 1891-1895.
- Hoti E., Salloum C., Azoulay D. (2011) Hepatic resection with in situ hypothermic perfusion is superior to other resection techniques. *Dig Sur*; 28(2): 94-9
- Ieta K., Tanaka F., Haraguchi N., Kita Y., Sakashita H., Mimori K. (2008) Biological and genetic characteristics of tumour initiating cells in colon cancer. *Ann Sur Oncol* 15: 638-648.
- Ishiguro S., Akasu T., Fujimoto Y., Yamamoto J., Sakamoto Y., Sano T., Shimada K., Kosuge T., Yamamoto S., Fujita S., Moriya Y. (2006) Second hepatectomy for recurrent colorectal liver metastasis: analysis of preoperative prognostic factors. *Ann Surg Oncol* 13: 1579 - 87
- Jaeck D. (2003) The significance of hepatic pedicle lymph nodes metastases in surgical management of colorectal liver metastases and of other liver malignancies. *Ann Surg Oncol* 10: 1007-1011
- Jaeck D., Oussoultzoglou E., Rosso E., Greget M., Weber JC., Bachellier P. (2004) Two-stage hepatectomy procedure combined with portal vein embolization to achieve curative resection for initially unresectable multiple and bilobar colorectal liver metastases. *Ann Surg* 240: 1037-1049.
- Jordan CT., Guzman ML., Noble M. (2006) Cancer stem cells. *N Engl J Med* 355: 1253-1261.
- Karoui M., Penna C., Amin-Hashem M., Mitry E., Benoist S., Franc B., Rougier P., Nordlinger B. (2006) Influence of preoperative chemotherapy on the risk of major hepatectomy for colorectal liver metastases. *Ann Surg* 243: 1-7.
- Kinkel K., Lu Y., Both M., Warren RS., Thoeni RF. (2002) Detection of hepatic metastases from cancers of the gastrointestinal tract by using noninvasive imaging methods (US, CT, MR Imaging, PET): a meta-analysis. *Radiology* 224: 748-756
- Koh DM., Scurr E., Collins DJ., Pirgon A., Kanber B., Karanjia N., Brown G., Leach MO., Husband JE. (2006) Colorectal hepatic metastases: quantitative measurements using single-shot echo-planar diffusion-weighted MR imaging. *Eur Radiol* 16: 1898-1905
- Koike N., Cho A., Nasu K., Seto K., Nagaya S., Ohshima Y., Ohkohchi N. (2009) Role of diffusion-weighted magnetic resonance imaging in the differential diagnosis of focal hepatic lesions. *World J Gastroenterol* 14; 15(46): 5805-5812
- Kokudo N., Miki Y., Sugai S., Yanagisawa A., Kato Y., Sakamoto Y., Yamamoto J., Yamaguchi T., Muto T., Makuuchi M. (2002). Genetic and histological assessment

- of surgical margins in resected liver metastases from colorectal carcinoma: minimum surgical margins for successful resection. *Arch Surg* 137: 833-40
- Kong G., Jackson C., Koh D., Lewington V., Sharma B., Brown G., Cunningham D., Cook G. (2008) The use of 18F-FDG PET/CT in colorectal liver metastases-comparison with CT and liver MRI. *Eur J Nucl Med Mol Imaging* 35(7): 1323-1329
- Kononen J., Bubendorf L., Kallioniemi A., Bärklund M., Schraml P., Leighton S., Torhorst J., Mihatsch MJ., Sauter G., Kallioniemi OP. (1998) Tissue microarrays for high-throughput molecular profiling of tumour specimens. *Nat Med* 4: 844-7.
- Kopez S., Vauthey JN. (2008) Perioperative chemotherapy for resectable liver metastases. *Lancet* 22: 371(9617): 1007-16
- Kronawitter U., Kemeny N., Heelan R., Fata F., Fong Y. (1999) Evaluation of chest computed tomography in the staging of patients with potentially resectable liver metastases from colorectal cancer. *Cancer* 86: 229-35
- Laghi A., Sansoni I., Celestre M., Paolantonio P., Passariello R. (2005) Computed Tomography. In: Focal Liver Lesions Detection, Characterization, Ablation. Lencioni R, Cioni D, Bartolozzi C (Ed). Springer-Verlag Berlin Heidelberg
- Langenhoff BS., Krabbe PF., Ruers TJ. (2009) Efficacy of follow-up after surgical treatment of colorectal liver metastases. *Eur J Surg Oncol* 35: 180-186
- Larsen LPS. (2010) Role of contrast enhanced ultrasonography in the assessment of hepatic metastases: A review. *World J Hepatol* 27; 2(1): 8-15
- Laurent C., Sa Cunha A., Couderc P., Rullier E., Saric J. (2003) Influence of postoperative morbidity on long-term survival following liver resection for colorectal metastases. *Br J Surg* 90(9): 1131-6
- Leen E., Ceccotti P., Moug SJ., Glen P., MacQuarrie J., Angerson WJ., Albrecht T., Hohmann J., Oldenburg A., Ritz JP., Horgan PG. (2006) Potential value of contrast-enhanced intraoperative ultrasonography during partial hepatectomy for metastases: an essential investigation before resection? *Ann Surg* 243: 236-240
- Li C., Heidt DG., Dalerba P., Burant CF., Zhang L., Adsay V., Wicha M., Clarke MF., Simeone DM. (2007) Identification of pancreatic cancer stem cells. *Cancer Res* 67: 1030-1037.
- Lordan JT., Karanjia ND. (2007) Size of surgical margin does not influence recurrence rates after curative liver resection for colorectal cancer liver metastases. *Br J Surg* 94: 1133-1138
- Lucey BC., Varghese J., Soto JA. (2006) Hepatic Disorders: Colorectal Cancer Metastases, Cirrhosis, and Hepatocellular Carcinoma. In: Evidence-Based Imaging. Medina LS, Blackmore CC. Springer Science+Business Media, Inc. New York
- Marín C., Robles R., Pérez D., López A., Parrilla P. (2009) Prognostic factors after resection of colorectal cancer liver metastases. *Cir Esp* 85: 32-39
- Mehrabi A., Fonouni H., Golriz M., Hofer S., Hafezi M., Rahbari NN., Weitz J., Büchler MW., Schmidt J. (2011) Hypothermic ante situm resection in tumours of the hepatocaval confluence. *Dig Surg* 28(2): 100-8
- Milanes-Yearsley M., Hammond ME., Pajak TF., Cooper JS., Chang C., Griffin T., Nelson D., Laramore G., Pilepich M. (2002) Tissue microarray: a cost and time-effective method for correlative studies by regional and national cancer study groups. *Mod Pathol* 15: 1366-1373
- Nakano H., Ishida Y., Hatakeyama T., Sakuraba K., Hayashi M., Sakurai O., Hataya K. (2008) Contrast-enhanced intraoperative ultrasonography equipped with late

- Kupffer-phase image obtained by sonazoid in patients with colorectal liver metastases. *World J Gastroenterol* 28; 14(20): 3207-3211
- Narita M., Oussoultzoglou E., Jaeck D., Fuchschuber P., Rosso E., Pessaux P., Marzano E., Bachellier P. (2011) Two-stage hepatectomy for multiple bilobar colorectal liver metastases. *Br J Surg* 98(10): 1463-75
- Niekel MC., Bipat Sh., Stoker J. (2010) Diagnostic Imaging of Colorectal Liver Metastases with CT, MR Imaging, FDG PET, and/or FDG PET/CT: A Meta-Analysis of Prospective Studies Including Patients Who Have Not Previously Undergone Treatment. *Radiology* 257(3): 674-684
- Nishio H., Hamady ZZ., Malik HZ., Fenwick S., Rajendra Prasad K., Toogood GJ., Lodge JP. (2007) Outcome following repeat liver resection for colorectal liver metastases. *Eur J Surg Oncol* 33: 729-34
- Nomura K., Kadoya M., Ueda K., Fujinaga Y., Miwa S., Miyagawa S. (2007) Detection of Hepatic Metastases From Colorectal Carcinoma: Comparison of Histopathologic Features of Anatomically Resected Liver With Results of Pre-operative Imaging. *J Clin Gastroenterol* 41(8):789-95
- Nordlinger B., Vaillant JC., Guiguet M., Balladur P., Paris F., Bachellier P., Jaeck D. (1994) Survival benefit of repeat liver resections for recurrent colorectal metastases: 143 cases. Association Francaise de Chirurgie. *J Clin Oncol* 12 :1491-6
- Nordlinger B., Guiguet M., Vaillant JC., Balladur P., Boudjema K., Bachellier P. (1996) Surgical resection of colorectal carcinoma metastases to the liver. A prognostic scoring system to improve case selection, based on 1568 patients. *Cancer* 77: 1254-62
- Nordlinger B., Sorbye H., Glimelius B., Poston GJ., Schlag PM., Rougier P., Bechstein WO., Primrose JN., Walpole ET., Finch-Jones M., Jaeck D., Mirza D., Parks RW., Collette L., Praet M., Bethé U., Van Cutsem E., Scheithauer W., Gruenberger T. (2008) Perioperative chemotherapy with FOLFOX4 and surgery versus surgery alone for resectable liver metastases from colorectal cancer (EORTC Intergroup trial 40983): a randomised controlled trial. *Lancet* 371: 1007-16
- O'Brien CA., Pollett A., Gallinger S., Dick JE. (2007) Chemotherapy and cancer stem cells. *Nature* 445: 106-10
- Ohlsson B., Stenram U., Tranberg KG. (1998) Resection of colorectal liver metastases: 25 year experience. *World J Surg* 22: 268-76
- Oldenburg A., Albrecht T. (2008) Baseline and contrast-enhanced ultrasound of the liver in tumour patients. *Ultraschall Med* 29(5): 488-98. Abstract
- Oldhafer KJ., Lang H., Malago M., Testa G., Broelsch CE. (2001) Ex-situ resection and resection of the in-situ perfused liver: are there still indications? *Chirurg* 72(2): 131-7. Abstract
- Patel S., McCall M., Ohinmaa A., Bigam D., Dryden DM. (2011) Positron emission tomography/computed tomographic scans compared to computed tomographic scans for detecting colorectal liver metastases: a systematic review. *Ann Surg* 253(4): 666-71
- Pawlik T., Assumpcao L., Vossen J., Buijs M., Gleisner A., Schulick R., Choti M. (2009) Trends in nontherapeutic laparotomy rates in patients undergoing surgical therapy for hepatic colorectal metastases. *Ann Surg Oncol* 16(2): 371-378
- Pawlik TM., Schulik RD., Choti MA. (2008) Expanding Criteria for Resectability of Colorectal Liver Metastases. *Oncologist* 13(1): 51-64
- Petrowsky H., Gonen M., Jarnagin W., Lorenz M., DeMatteo R., Heinrich S., Encke A., Blumgart L., Fong Y. (2002) Second liver resections are safe and effective treatment

- for recurrent hepatic metastases from colorectal cancer: a bi - institutional analysis. *Ann Surg* 235: 863-71
- Power DG., Kemeny NE. (2010) Role of adjuvant therapy after resection of colorectal cancer liver metastases. *J Clin Oncol* 28(13): 2300-9
- Prince ME., Sivanandan R., Kaczorowski A., Wolf GT., Kaplan MJ., Dalerba P., Weissman IL., Clarke MF., Ailles LE. (2007) Identification of a subpopulation of cells with cancer stem cell properties in head and neck squamous cell carcinoma. *Proc Natl Acad Sci USA* 104: 973-8
- Reya T., Morrison SJ., Clarke MF., Weissman IL. (2001) Applying the principles of stem cell biology to cancer. *Nature* 414: 105-11
- Ribero D., Abdallah EK., Madoff DC., Donadon M., Loyer EM., Vauthey JN. (2007) Portal vein embolization before major hepatectomy and its effects on regeneration, resectability and outcome. *Br J Surg* 94: 1386-96
- Ricci-Vitiani L., Lombardi DG., Pilozzi E., Biffoni M., Todaro M., Peschle C., De Maria R. (2007) Phenotypic characterization of human colorectal cancer stem cells. *Nature* 445: 111-5
- Saw RP., Koorey D., Painter D., Gallagher PJ. (2002) p53, DCC and thymidylate synthase as predictors of survival after resection of hepatic metastases from colorectal cancer. *Br J Surg* 89: 1409-15
- Schwartz L., Brody L., Brown K., Covey A., Tuorto S., Mazumdar M., Riedel E., Jarnagin W., Getrajdman G., Fong Y. (2006) Prospective, blinded comparison of helical CT and CT arterial portography in the assessment of hepatic metastasis from colorectal carcinoma. *World J Surg* 30(10): 1892 -901
- Selzner M., Hany TF., Wildbrett P., McCormack L., Kadry Z., Clavien PA. (2004) Does the novel PET/CT imaging modality impact on the treatment of patients with metastatic colorectal cancer of the liver? *Ann Surg* 240: 1027-34
- Shaw IM., Rees M., Welsh FK., Bygrave S., John TG. (2006). Repeat hepatic resection for recurrent colorectal liver metastases is associated with favourable long - term survival. *Br J Surg* 93: 457-64
- Singh SK., Hawkins C., Clarke ID., Squire JA., Bayani J., Hide T., Henkelman RM., Cusimano MD., Dirks PB. (2004) Identification of a subpopulation of cells with cancer stem cell properties in head and neck squamous cell carcinoma. *Nature* 432: 396-401
- Shimada H., Tanaka K., Endou I., Ichikawa Y. (2009). Treatment of colorectal liver metastases: a review. *Langenbecks Arch Surg* 394 (6): 973-83
- Smith MD., McCall JL. (2009) Systematic review of tumour number and outcome after radical treatment of colorectal liver metastases. *Br J Surg* 96(10): 1101-13
- Söreide JA., Eiriksson K., Sandvik O., Viste A., Horn A., Johnsen G., Grønbech JE. (2008) Surgical treatment of liver metastases from colorectal cancer. *Br J Surg* 128: 50-3.
- Sørensen M., Mortensen FV., Høyer M., Vilstrup H., Keiding S. and The Liver Tumour Board at Aarhus University Hospital. (2007). FDG-PET improves management of patients with colorectal liver metastases allocated for local treatment: a consecutive prospective study. *Scand J Surg* 96: 209-13
- Tanaka K., Shimada H., Miura M., Fujii Y., Yamaguchi S., Endo I., Sekido H., Togo S., Ike H. (2004) Metastatic tumour doubling time: most important prehepatectomy predictor of survival and nonrecurrence of hepatic colorectal cancer metastasis. *World J Surg* 28: 263-70

- Thelen A., Jonas S., Benckert C., Schumacher G., Lopez-Hänninen E., Rudolph B., Neumann U., Neuhaus P. (2007) Repeat liver resection for recurrent liver metastases from colorectal cancer. *Eur J Surg Oncol* 33: 324-8
- Torzilli G., Del Fabbro D., Palmisano A., Donadon M., Bianchi P., Roncalli M., Balzarini L., Montorsi M. (2005) Contrast-enhanced intraoperative ultrasonography during hepatectomies for colorectal cancer liver metastases. *J Gastrointest Surg* 9: 1148-53
- Udayasankar U., Chamsuddin A., Mittal P., Small WC. (2008) Diagnostic Imaging and Image-Guided Interventions of Hepatobiliary Malignancies. In: *Imaging in Oncology*. Blake MA, Kalra MK. Springer Science+Business Media, LLC. New York
- Valls C., Andia E., Sanchez A., Guma A., Figueras J., Torras J, Serrano T. (2001) Hepatic Metastases from Colorectal Cancer: Preoperative Detection and Assessment of Resectability with Helical CT. *Radiology* 218: 55-60
- Valls C., Martinez L., Ruiz S., Alba E. (2009). Radiological Imaging of Liver Metastases. In: *Liver Metastases*. Vauthey JN, Hoff PMG, Audisio RA, Poston GJ (Eds), pp. 1-13 Springer-Verlag London, ISBN 978-1-84628-946-0
- van Erkel AR., Pijl MEJ., van den Berg-Huysmans AA., Wasser MNJM., van de Velde CJH., Bloem JL. (2002). Hepatic Metastases in Patients with Colorectal Cancer: Relationship between Size of Metastases, Standard of Reference, and Detection Rates. *Radiology* 224: 404-9
- Vauthey JN. (2007) Colorectal Liver Metastases: Treat Effectively Up Front and Consider the Borderline Resectable. *J Clin Oncol* 25(29): 4524-5
- Vauthey JN. The AHPBA 2006 Consensus Conference: Focus on Improving Resectability in Patients With Hepatic Colorectal Metastases. *Medscape Oncology*. Posted: 03/31/2006. Available from: <http://www.medscape.org/viewarticle/524135>
- Vidiri A., Carpanese L., D'Annibale M., Caterino M., Cosimelli M., Zeuli M., David V., Crecco M. (2004) Evaluation of Hepatic Metastases from Colorectal Carcinoma with MR-Superparamagnetic Iron Oxide. *J Exp Clin Cancer Res* 23(1): 53-60
- Wagman LD., Byun TE. (2009) Managing colorectal cancer liver metastases. *Oncology* 23 (12): 1063-71
- Wiering B., Krabbe PFM., Jager GJ., Oyen WJG., Ruers TJF. (2005) The Impact of Fluor-18-Deoxyglucose-Positron Emission Tomography in the Management of Colorectal Liver Metastases: A Systematic Review and Metaanalysis. *Cancer* 104 (12): 2658-70
- Woodington GF., Waugh JM (1963). Results of resection of metastatic tumours of the liver. *Am J Surg* 105:24
- Yamamoto J., Kosuge T., Shimada K., Yamasaki S., Moriya Y., Sugihara K. (1999) Repeat liver resection for recurrent colorectal liver metastases. *Am J Surg* 178: 275-81
- Yan T., Sim J., Black D., Niu R., Morris DL. (2007) Systematic review on safety and efficacy of repeat hepatectomy for recurrent liver metastases from colorectal carcinoma. *Ann Surg Oncol* 14: 2069-77
- Yang S., Ho S., Hanna SS., Gallinger S., Wei AC., Kiss A., Law C. (2010) Utility of preoperative imaging in evaluating colorectal liver metastases declines over time. *HPB* 12(9): 605-9
- Zorzi D., Laurent A., Pawlik TM., Lauwers GY., Vauthey JN., Abdalla EK. (2007) Chemotherapy-associated hepatotoxicity and surgery for colorectal liver metastases. *Br J Surg* 94(3): 274-86



Liver Tumors

Edited by Prof. Alexander Julianov

ISBN 978-953-51-0036-2

Hard cover, 200 pages

Publisher InTech

Published online 03, February, 2012

Published in print edition February, 2012

This book is oriented towards clinicians and scientists in the field of the management of patients with liver tumors. As many unresolved problems regarding primary and metastatic liver cancer still await investigation, I hope this book can serve as a tiny step on a long way that we need to run on the battlefield of liver tumors.

How to reference

In order to correctly reference this scholarly work, feel free to copy and paste the following:

Alejandro Serrablo, Luis Tejedor, Vicente Borrego and Jesus Esarte (2012). Colorectal Liver Metastasis: Current Management, Liver Tumors, Prof. Alexander Julianov (Ed.), ISBN: 978-953-51-0036-2, InTech, Available from: <http://www.intechopen.com/books/liver-tumors/colorectal-liver-metastasis-current-management>

INTECH
open science | open minds

InTech Europe

University Campus STeP Ri
Slavka Krautzeka 83/A
51000 Rijeka, Croatia
Phone: +385 (51) 770 447
Fax: +385 (51) 686 166
www.intechopen.com

InTech China

Unit 405, Office Block, Hotel Equatorial Shanghai
No.65, Yan An Road (West), Shanghai, 200040, China
中国上海市延安西路65号上海国际贵都大饭店办公楼405单元
Phone: +86-21-62489820
Fax: +86-21-62489821

© 2012 The Author(s). Licensee IntechOpen. This is an open access article distributed under the terms of the [Creative Commons Attribution 3.0 License](#), which permits unrestricted use, distribution, and reproduction in any medium, provided the original work is properly cited.

IntechOpen

IntechOpen