

# We are IntechOpen, the world's leading publisher of Open Access books Built by scientists, for scientists

**4,800**

Open access books available

**122,000**

International authors and editors

**135M**

Downloads

Our authors are among the

**154**

Countries delivered to

**TOP 1%**

most cited scientists

**12.2%**

Contributors from top 500 universities



**WEB OF SCIENCE™**

Selection of our books indexed in the Book Citation Index  
in Web of Science™ Core Collection (BKCI)

Interested in publishing with us?  
Contact [book.department@intechopen.com](mailto:book.department@intechopen.com)

Numbers displayed above are based on latest data collected.

For more information visit [www.intechopen.com](http://www.intechopen.com)



# Diagnostic Values of Electrophysiology in Ophthalmology

Morteza Movassat  
*Tehran University of Medical Sciences,  
Farabi Hospital  
Iran*

## 1. Introduction

The main function of the eye is converting received light energy to neuronal impulses by some chemical interactions in posterior segment; then, these impulses, after some processing, will be transferred to visual cortex by the visual pathways. Striate cortex located at posterior pole of brain is where which creates vision through a complicated physiological phenomena.

Electrodiagnosis in ophthalmology is a method that investigates this process functionally and can help in many complicated situations.

Two important characteristics make this paraclinic method different from others; to be both functional and objective. Many ocular tests as angiography, ultrasonography and OCT are objective but not functional, and some, as perimetry and contrast sensitivity test are functional but not objective. This is why electrodiagnostic tests are problem solving and conclusive in equivocal instances specially when encountered to forensic or legal cases with probability of simulation.

Electrodiagnosis in ophthalmology includes electroretinography (ERG), electro-oculography (EOG) and visual evoked potentials (VEP); ERG evaluates function of posterior segment of the eye specially sensory retina; EOG, also, evaluates function of the posterior segment of the eye with more focus on retinal pigment epithelium (RPE), and VEP evaluates function of visual pathways and striate cortex.

It should be reminded that aside from these advantages, these tests are not ones to be ordered without proper indications, and their results must be interpreted by someone familiar with pathogenesis of ocular diseases.

## 2. History

The history of recording of electroretinogram goes back to Einthoven and Jolly in 1908 and then, to Kahn and Lowenstein in 1924, with their works on modifying electrodes; but it was Granit's investigations during 1933-1947 that differentiated ERG's components in human. The work of Noell, Tomita, Brindly and Brown showed the origin of these components and paved the way for clinical use of ERG. In a separate research, Brown's group blocked central

retinal artery of cat during ERG recording, and proved the relation between a-wave and photoreceptors (Brown & Wiesel, 1961). The relation between b-wave and Muller cells was shown by Miller and Dowling (Miller & Dowling, 1970); and Riggs introduced contact lens electrodes in 1941, and opened the perspective of practical use of ERG in ophthalmology; then Karpe emphasized on diagnostic value of ERG even in eyes with hazy media (Karpe, 1982).

In electro-oculography, Kris's works helped to find the slow electrical changes of the eye in rest condition which cause a posterior-anterior electrical vector, and he showed that this potential changes differ in dark and light adapted eyes (Kris, 1958); then Arden suggested comparing these potentials in light and dark adaptation and based a diagnostic index, which, today, we know it as Arden ratio (Arden & Kelsey, 1962).

History of visual evoked potentials reaches to Adrian and Matthews in 1934, who explained responses of occipital lobes in electroencephalogram. Then Monnier, in 1952, by placing scalp electrodes on occiput, recorded waves with latencies of about 90-120 msec. Ciganek, later in 1961, described some components of VEP (Ciganek, 1961) and Gastaut and Regis explained that the most invariable component of VEP is P<sub>2</sub> wave. Harding and colleagues designed a pattern/reversal stimulation for VEP and ruled out the hypothesis claiming that some components of VEP are ERG waves. Finally, Halliday brought experimental works of VEP to clinical use in 1972. (Halliday et al, 1972).

### 3. Biological and biochemical bases of tests

#### 3.1 Electroretinography

Photoreceptors, rods and cones, containing photosensitive pigments, are responsible for converting light energy into neuronal impulses, and retinal pigment epithelium (RPE) has a fundamental role in this process. Extracellular matrix, filling subretinal space is medium for molecular interactions between choroid, RPE and sensory retina. RPE cells' membrane with Na<sup>+</sup> and K<sup>+</sup> ATPase affects inflow and outflow of ions in this matrix (Ostwald & Steinberg, 1980) and by this ionic transferring, initial conversion of light energy to neuronal impulses occurs. RPE also has an important role in absorption of scattered lights entering eyes which can interfere visual function. Opsin, a photosensitive protein derivative in outer segment of photoreceptors, is in close relation with ionic changes of extracellular matrix. By photochemical and then chemo-electrical interactions of these pigment components, resting potential of inner segment of photoreceptors changes to action potential. Inner segment-Muller cell's processes complex makes outer limiting membrane which separates molecularly interphotoreceptor space from neural retina (Lam, 2005). Muller cells with long processes are present in many layers of retina, from outer to inner limiting membranes, and make glial structure of the sensory retina. By changing the potassium and carbohydrate level (Newman, 1993), these cells share electrical response and thus affect ERG. Interphotoreceptor matrix, mentioned earlier, contains some soluble and insoluble compounds with a retinol-binding protein, showing the role of vitamin A metabolism in visual function. On the other hand, close anatomical and physiological relationship between choroid, RPE and sensory retina explains why pathology of each can affect others, and this is the cause of relative overlapping of results of ERG, EOG and VEP tests. In bright light or photopic vision, cones with three pigments, red, green, and blue sensitive are responsive; but in dim light or scotopic vision rods containing rhodopsin, are active.

Bipolars and ganglion cells, in association with horizontal, amacrine and Muller cells, receive impulses from photoreceptors and, after some processing, transfer them to visual pathways. These pathways begin from optic nerves and continue through chiasm, optic tracts, geniculate bodies and optic radiations, and terminate in visual cortex.

The role of horizontal cells, physiologically, is interesting. These cells connect neuronal cells together in a manner that makes possible for a large number of photoreceptors and bipolars to connect with a small groups of ganglion cells and higher centers neurons to produce "receptive field". Some parts in these fields work synergic and some parts antagonistic and this mechanism makes anatomical basis for center-surround antagonism and On/Off responses. In fact perception of movement, direction and form are complicated visual functions which need too many physiological interactions that are not completely understood.

### 3.2 Electro-oculography

Depolarization of the basal surface of RPE due to light stimulation causes a transepithelial negative charge with a posterior-anterior vector which can be measured as a positive charge in anterior pole of the eye. This slow changing potential is, in fact, resting potential of eye and if light adaptation occurs, this potential reaches to a maximum. Dividing maximum peak in light by minimum trough in dark gives Arden ratio which helps to differentiate normal from pathologic cases. Horizontal saccades of the eye during test help to eliminate other electrical charges affecting globes and cause electrodes, placed close to the canthi, receive only globes potentials. In contrast with ERG that shows action potentials in sensory retina, the EOG reflects resting potential of the eye as a dipole and shows RPE function.

### 3.3 Visual evoked potentials

Brain cortex with main intrinsic neuronal activity responds to external stimuli, and if stimulation has visual nature, the response will be visual evoked. By placing skin electrodes on occiput and stimulation of the eyes with light, the cortical responses to visual stimuli can be obtained. Any pathology in macular ganglion cells, optic nerves, chiasm, optic tracts, geniculate bodies, optic radiations and striate cortex can affect the VEP results. But this test specially helps when functional defects overcome anatomical changes and clinical examinations and neuro-imagings results are equivocal. Considering optic nerves fibers crossing in chiasm and also, combination of signals in cortex, VEP is a hemi-bilateral brain response to unilateral stimulation of the eye.

Occiput is an area of skull near to some parts of visual cortex which are responsive for foveal area and central 10° of visual field. Ganglion cells of retina and neurons of higher centers are in different kinds; magnocellular for perception of movement, parvocellular for visual acuity and color vision, and koniocellular for perception of form. This functional variety of ganglion cells in association with horizontal cells role, mentioned earlier, give us ability of not only seeing, but also distinction of the position of things in our environment. For evaluation of these complicated functions, the visual stimuli should have some characteristics other than simple light flashes. Formed stimuli with several patterns are designed for this mean. Pattern/reversal and pattern onset/offset checks, horizontal and

vertical bars, full-field and quadrant-field patterns in black/white or colored, are several forms of stimulations used for pattern VEP.

#### **4. Characteristics of normal electroretinogram**

Full-field ERG is the most common used method of electroretinography. Stimulation of extensive area of fundus and obtaining whole response of retina gives full-field ERG.

##### **4.1 ERG components**

Three principal components and some less distinctive wavelets make standard ERG.

###### **4.1.1 a-wave**

A prominent negative wave arising from inner segment of photoreceptors, also known as late receptor potential. This wave reflects the function of outer retina, RPE and choroid.

###### **4.1.2 b-wave**

A more prominent but positive wave which originates from On bipolar cells and Muller cells. Ionic interactions between these cells, triggered by light stimulations, are main factor to produce this wave (Heckenlively & Arden, 2006). This component reflects the function of middle layers of retina which receive its vasculature from central retinal artery and vein.

###### **4.1.3 Oscillatory potentials**

4-6 wavelets on ascending part of b-wave, representing inhibitory feedback circuit in inner plexiform layer due to bipolar-amacrine cells interactions. Initial wavelets originate from cones and subsequent ones originate from rods (Wachtmeister, 1998). These oscillations can be obtained by a separate protocol in both dark and light adaptations. Although mechanism of formation of these wavelets are not well understood, but their high sensitivity to hypoxia gives them a diagnostic value in retinal vascular disorders.

In addition to these major components of standard (full-field) ERG, there are some minor ones, usually exploited in research works. Of these, early receptor potentials originating in outer segment of photoreceptors, d-wave which is off-response in photopic ERG, d.c-component referring RPE function and e-wave or delayed off-response (Lam, 2005) are noteworthy.

To separate responses of rods from cones, test is performed first in scotopic condition (with patching eyes for 20' in a dark room), with blue, orange, red and white lights; then the eyes will be dazzled with bright light for about 4' (light adaptation) for photopic ERG.

Both cone and rod photoreceptors respond to stimulations in both dark adapted (scotopic) and light adapted (photopic) eyes; but in scotopic vision rods' function is prevailed, while in photopic vision cones mostly are involved.

Two data of each component should be measured for interpretation of response:

- Implicit time (I.T.): time between the end of stimulation and wave peak, in m.sec.

- Amplitude: the height of wave in microvolts; in a-wave it is measured from iso-electric line and in b-wave from a-wave peak to b-wave peak. These data vary in different conditions of adaptation and, also due to several variables as age, race, refractive errors, pupil size and unit amplifier. For this reasons, it is recommended to evaluate normal range in each electrodiagnostic center; but international society for clinical electrophysiology of vision (ISCEV) declares normal data every 3 years which can be referred to.

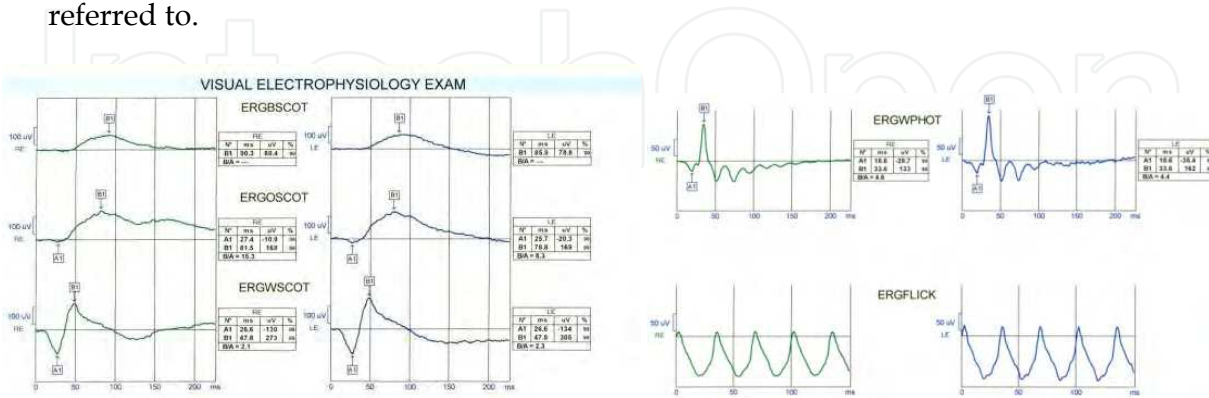


Fig. 1. Normal standard ERG. Right, scotopic with blue, orange, and white lights. Left, photopic (up) and flicker (down).

	Implicit time a- wave(ms)	Amplitude a- wave(micro V)	Implicit time b-wave(ms)	Amplitude b-wave(b-a) (micro V)
ERG-25dB (rod response)				Average=232±60
ERG-0dB (mixed response)	Average=25.2±1	Average=197±25	Average=46.9±3	Average=365±80
	Implicit time a- wave(ms)	Amplitude a- wave(micro V)	Implicit time b-wave(ms)	Amplitude b-wave(b-a) (micro V)
Photopic ERG	Average=19.1±2	Average=25.0±5	Average=31.6±1	Average=90±15
Flicker ERG			Average=34.2±1	Average=118±17

Table 1. Normal values of ERG in ISCEV protocol.

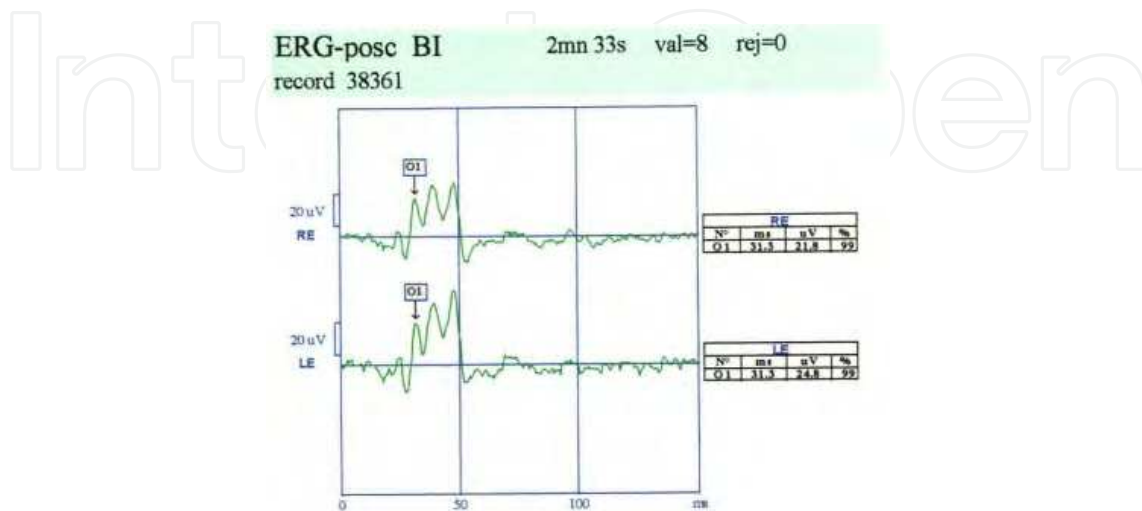


Fig. 2. Normal oscillatory potentials.

## 4.2 Specialized techniques of ERG

### 4.2.1 Flicker (focal) ERG

Some differences in physiology of cones and rods can help to separate their responses in ERG. Retractory period of rods is about 100 msec., which means rods can not respond to stimulations with frequency higher than 10 Hz, but cones with much shorter retractory period can respond to stimulations with frequency up to 30 Hz(flicker ERG). By using different frequencies of stimulation, these two systems can be differentiated physiologically but not anatomically; of course, because of high concentration of cones in macula, flicker ERG practically shows macular function.

### 4.2.2 Bright flash ERG

Severe haziness of ocular media as seen in corneal leukoma, pathologic cataract, condensed vitreous opacities and deformed ocular tissues due to trauma may be candidates for surgical procedures to gain better vision. The main question will be visual potential or outcome in these eyes. Also in recent globe lacerations, the catastrophe of sympathetic ophthalmia of the other eye, although very rare, should be kept in mind. ERG and VEP, by using bright or intensified flashes, which can pass ocular haziness, are helpful for making decision.

### 4.2.3 Chromatic ERG

In suspected cases of color blindness, ERG with different wavelengths can show color vision abnormalities objectively; this method helps in vocational and legal cases.

### 4.2.4 Pattern ERG

Representing ganglion cells function, which are more concentrated in macula, pattern ERG is a test to evaluate inner retina and optic nerve disorders. Visual acuity measurement in preverbal children, evaluation of nerve fibers loss in glaucoma, and diseases involving inner retina, as seen in longstanding retinal detachments are special clinical indications of this test. Stimuli with frequency of 3 Hz, give transient response with three components of N<sub>35</sub>, P<sub>50</sub> and N<sub>95</sub> waves; the numbers show wave's implicit time. Stimuli with frequency of 5 Hz or higher give steady-state sinusoidal response. In ganglion cells disorders, amplitude of P<sub>50</sub> component is reduced, while in optic nerve lesions N<sub>95</sub> wave shows pathology. Steady-state response changes are comparable with N<sub>95</sub> component in transient response.

Stimuli are pattern/reversal checker-board with 48' size checks and 100% contrast which covers 10-16 degrees of central visual field. Pupil dilation is not necessary (Lam, 2005).

### 4.2.5 Multifocal ERG (m.f.ERG)

Using physics and mathematics, m.f.ERG is a method designed to evaluate small local lesions in fundus, specially cone involvements. 61 to 241 white/black scaled hexagons stimulate posterior pole of the eye conforming central 50 degrees of visual field in a pseudorandom, m-sequence program. Simulating random, but known by system's software, it works in a manner that in each time of stimulation each hexagon has 50% chance to be on or off. After amplifying responses, they will be matched together for finding the area of retina related to each hexagon. In fact m.f.ERG waveforms are not true recorded responses,

but mathematical data in which, response of each hexagon is measured by adding all recordings following a white frame and then subtracting all recordings following a black frame (Lam,2005). For this type of analysis, the number of hexagons in each frame should be odd and equal to number of stimulations in each test. After matching responses (adding and subtracting) the sum response of all hexagons but one, will be zero and only one response remains which correlates with its related location in fundus. Stimulation with frequencies up to 75 Hz give first order kernels ( $k_1$ ) which represent function of outer retina, and stimulation with higher frequencies give second order kernels ( $k_2$ ) showing function of ganglion cells. Test with more hexagons in each frame gives more precise localization of lesion, but noise-to-signal ratio will be higher.

Pupil dilation and maintained central fixation are critical to obtain accurate topographical responses. Although binocular test is possible, monocular results are more assured.

Each  $k_1$  response includes  $N_1$ ,  $P_1$  and  $N_2$  components in which  $N_1$  and  $P_1$  accord roughly to a-wave and b-wave in standard ERG.

Print-outs may be designed as concentric rings showing 2, 5, 10, and 15 degrees of central visual fields which are more used for small lesions in fovea and perifovea; or it may be designed in four quadrants, used in more peripheral involvement in posterior pole.

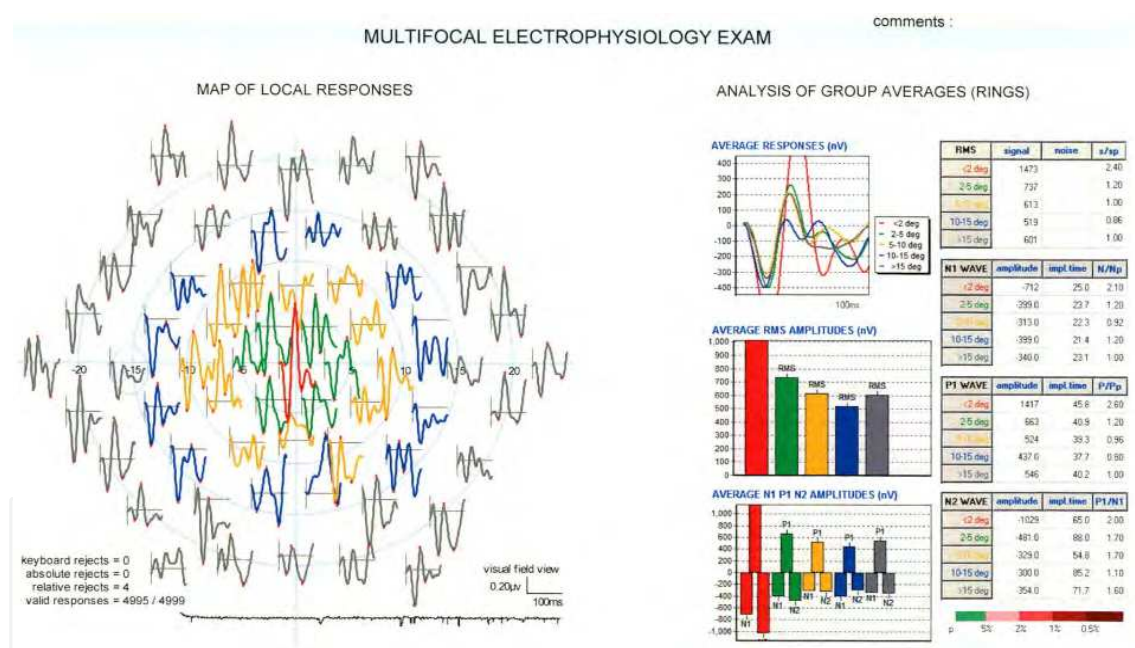


Fig. 3. Normal m.f.ERG. Concentric rings show the locations of the responses.

### 4.3 Recording of electroretinogram

Electroretinography unit consists of stimulator, electrodes, connectors, amplifier, computer and printer.

#### 4.3.1 Stimulator

Usually a standing monitor with a chin-rest 33 away from the screen. Flash or pattern stimulations are given to the eyes in different colors and forms. Of course flash stimulations



in a Ganzfeld bowl are preferred in full-field ERG for better stimulation of center-directed elements in retina. For kids and patients not able to sit in front of monitor, stimulations can be given by a portable flasher.

#### 4.3.2 Electrodes

Several kinds of electrodes are available. For active or positive electrodes, Burian-Allen and Dawson-Trick-Litzkow (DTL) are more known. These are solid contact lenses which touch the cornea via a conductive gel.

In case of pattern ERG gold foil or fibers are used for active electrodes, mounting inferior lid border which makes possible better receiving of pattern stimuli by patient. Reference or negative electrodes are skin plaques and are placed on lateral wall of orbits posterior to globes. Ground or earth electrode is to reduce the noise and may be placed on auricle.

Cornea should be anesthetized with topical anesthetics and pupils should be in full dilation in all methods of ERG except pattern ERG. The sites of electrodes on skin should be cleaned carefully and conducting gel should be used for electrode-skin attachment.

#### 4.3.3 Connectors

Made of fine wire which connect electrodes with amplifier.

#### 4.3.4 Amplifier

Amplifier is to empower and making recordable the responses which are weak and not obtainable if not amplified. The characteristics of amplifier are important in any unit and its range of amplifying affects the range of normal data in each system.

#### 4.3.5 Computer

Computer may be as a desktop or laptop, containing several softwares for several kinds of programs including type of stimulation, receiving responses, averaging data, analyzing components, and finally, saving results in files.

#### 4.3.6 Printer

Printer is last part of unit and gives print-outs of results, showing responses and data of components.



Fig. 4. Electrophysiology unit: Monitor, showing checker-board for stimulation, amplifier and laptop with several softwares for different tests.

## 5. Characteristics of normal electro-oculogram

EOG is sum up of many square-shaped waveforms due to horizontal back and forth saccades of the eyes fixing 2 red diodes located 15 degrees to the right and left of the primary gaze on monitor or in a bowl (Lam,2005).

### 5.1 EOG Component

After some saccades for orientation of patient, test starts in darkness for about 10' in which, potential gains its minimum (dark trough); then continues in light for about 10' in which, maximum potential (light peak) is reached. The light peak potential divided by dark trough potential gives Arden ratio. The time length of each saccade is about 1.5 sec. and patient has a while for rest between some of them.

Normal range of Arden ratio is about 1.8-2.2 in ISCEV protocol; ratios between 1.8 and 1.6 are considered borderline and ratios less than 1.6 are abnormal.

### 5.2 EOG recording

#### 5.2.1 EOG electrodes

Four silver-silver chloride skin electrodes are attached to skin via a conductive gel, close to four canthi. One ground electrode is placed on forehead or auricle to decrease noise. In each horizontal saccade, the electrode close to cornea becomes active and the opposite one becomes reference electrode. The electrode close to medial canthus of one side is matched with electrode close to lateral canthus of the other side in connecting to amplifier, causing homonymous electrical polarization in each saccade.

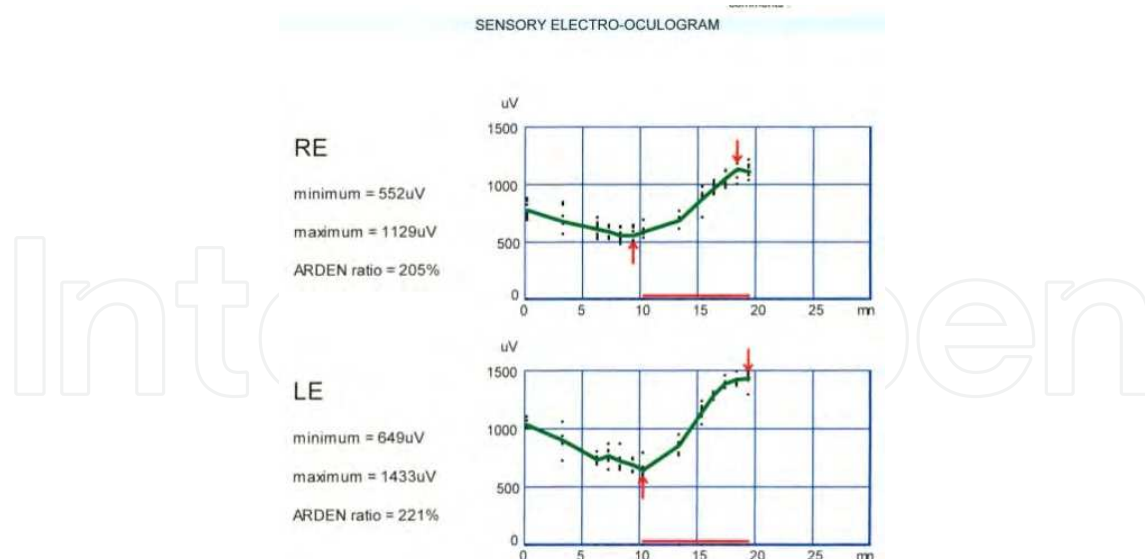


Fig. 5. Normal EOG, showing dark trough and light rise.

#### 5.2.2 Monitor or a bowl

A monitor or a bowl with a chin-rest 33 away of screen, with fixation lights, and ability to be dark or light. Patient should sit in front of monitor to follow the fixation light. In

background luminance of about 50-100 cd/sqm, pupils should be dilated; but in higher luminance, about 400-600 cd/sqm, dilation is not needed.

**5.2.3 Other parts**, including connectors, amplifier, computer and printer are same as ERG test.

Considering duration of the test and its method, EOG can not be performed in poor physical conditions, severe strabismus, severe nystagmus, preverbal children and under general anesthesia.

## **6. Characteristics of normal visual evoked potentials**

Visual, formed or unformed, stimulations of the eye, usually mono-ocularly, and then, obtaining electrical responses from striate cortex, is known as VEP test. Standard VEP is performed with flash or pattern stimuli with their special indications and limitations; also, there are some special new methods finding their clinical utilities in recent years.

### **6.1 Recording of visual evoked potentials**

#### **6.1.1 Electrodes**

Usually intra-dermic disposable needles. Active electrodes are placed one centimeter away ofinion on either side, and referring electrodes are placed on mid-point of a hypothetical line betweeninion and nose base. Ground electrode, reducing noise, is placed on auricle.

**6.1.2** Connectors connect the electrodes with amplifier which empowers responses up to recordable level.

**6.1.3** Stimulation unit, a monitor with ability to give flash or pattern stimulations; in cases not able to sit in front of monitor, stimulations can be given by a portable stimulator.

In pattern VEP, patient sits one meter away of monitor, wearing his or her correction, and fixes with one eye the fixation spot at the center of monitor; the other eye is patched. In flash method, patient puts his or her chin on chin-rest 33 away of monitor and looks with one eye to the flashing screen.

Stimulation with frequencies of 5 Hz or less give transient VEP, but higher frequencies give steady-state VEP which has special indications.

Neurologists prefer positive downward peak, but positive upward peaks are recommended in ophthalmology.

If performed binocularly, amplitude of waves increases some.

**6.1.4** Laptop with several softwares to choose the kind of test and analyzing the responses.

**6.1.5** Printer gives printed results and data of components.

### **6.2 Methods and components of VEP**

Because of high noise-to-signal ratio, averaging of responses to multiple stimulations, usually 64, is recommended. Due to the same reason variability of responses specially in amplitude, between two eyes and also, between different subjects is expected.

Dilation of pupils is not recommended unless in severe miosis, which can cause delayed responses.

### 6.2.1 Flash VEP

Indicated in cases with poor vision or poor fixation ability and nystagmus, this method gives an overall information about visual pathways. The response includes N<sub>1</sub>, P<sub>1</sub>, N<sub>2</sub>, P<sub>2</sub>, and N<sub>3</sub> components; most prominent and diagnostic one is P<sub>2</sub> wave.

### 6.2.2 Pattern onset/offset VEP

With fixed black/white checks stimulations, interrupted by iso-luminant blank screen, this method of pattern VEP is indicated in visual acuity evaluation in uncooperative cases. The response consists first positive, second negative, and third positive components with implicit time about 75 msec., 125 msec. and 150 msec.

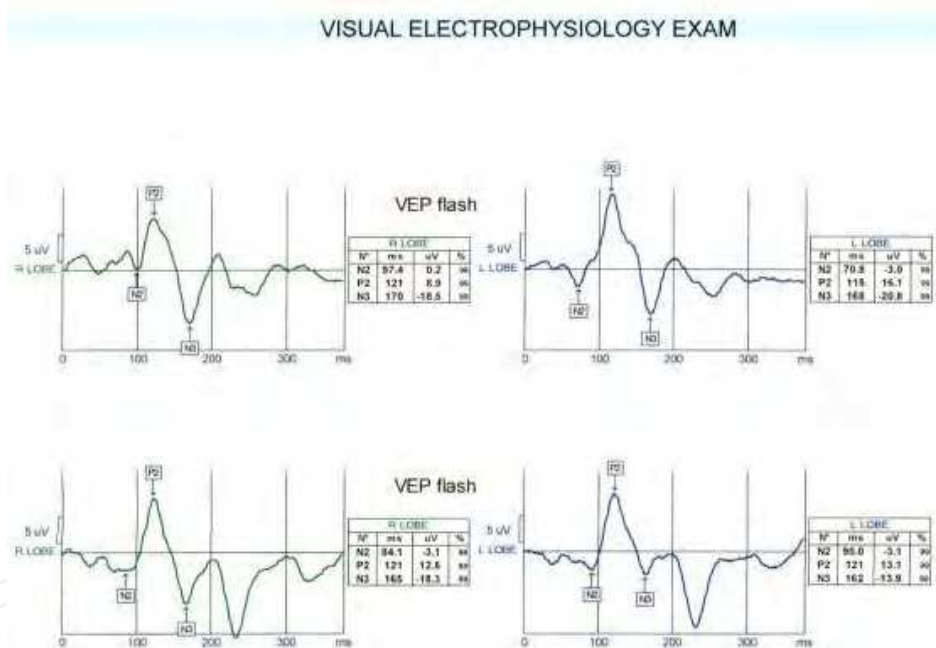


Fig. 6. Normal flash VEP; right eye(up) and left eye(down) responses.

### 6.2.3 Pattern/ reversal VEP(P/R VEP)

Most preferred and most commonly used method of VEP is P/R VEP. Comparing with other methods, responses of P/R VEP are more consistent, and by using several forms of patterns, even the precise location of lesion can be guessed. Check sizes can vary, but usually 15', 30', and 60' checks are used; about 64 stimulations with reversing sites of black and white squares are projected to the eye and after averaging, responses will be obtained which consist of N<sub>75</sub>, P<sub>100</sub> and N<sub>135</sub> components. P<sub>100</sub> wave is the most prominent and the most diagnostic component of P/R VEP.

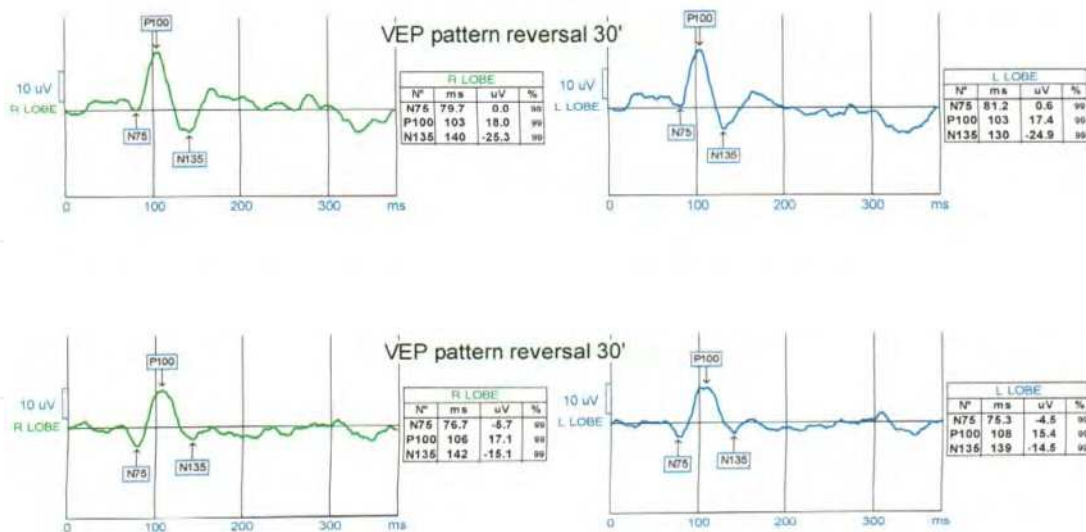


Fig. 7. Normal P/R VEP; right eye (up) and left eye (down) responses.

### 6.2.4 Multifocal VEP

Similar to m.f.ERG, alternating black/white checks, in a special design of pseudorandom and m-sequence, is used for stimulation, and software of computer cross-correlates the responses with sectors in fundus and visual pathways. In fact m.f.VEP is an objective evaluation of visual field, which is helpful in cases with poor cooperation for perimetry.

### 6.2.5 Sweep VEP

Stimulation of eyes with high-frequency, temporal reversing patterns gives steady-state VEP response.

By using two methods of spatial and contrast frequency (Lam,2005), this test can measure visual acuity in preverbal children. In spatial frequency method, rate of temporal frequency is fixed but the width of black/white bars decreases gradually; in contrast frequency method, spatial and temporal frequencies are fixed while contrast of bars decreases. Recording responses during spatial or contrast changes, gives information about visual functions of the case, which are roughly comparable with Snellen chart and contrast sensitivity test.

	Implicit time P <sub>2</sub> (ms)	Amplitude P <sub>2</sub> (microV)
Flash VEP	Average=112±11	Average=9±5
	Implicit time P <sub>100</sub> (ms)	amplitudeP <sub>100</sub> (microV)
Pattern 60°	Average=103±7	Average=12±6
Pattern 30°	Average=106±3	Average=16±7
Pattern 15°	Average=110±5	Average=13±7
Pattern 7°	Average=125±10	Average=10±6

Table 2. Normal values of flash and P/R VEP in ISCEV protocol.

## 7. Clinical applications and indications of tests

As mentioned earlier, because of close anatomical and functional relationships between choroid, RPE, sensory retina, and visual pathways which originate from ganglion cells in retina, electrodiagnostic, ERG, EOG and VEP, results are overlapping in many disorders. But, considering pathogenesis of diseases, the most indicated test should be performed. Therefore, physicians who order tests should be familiar with chorioretinal and visual pathways disorders and clinical examinations are recommended strongly.

### 7.1 Disorders affecting ERG

#### 7.1.1 Rod-cone degeneration or R.P. disease

A hereditary retinal dystrophy, mostly autosomal recessive, less autosomal dominant and least sex-linked, which starts with night blindness and continues with visual field constriction, reduced visual acuity, and fundus changes of pigment spicules and arterial narrowing. R.P disease may be seen in many systemic metabolic and neurologic disorders. Of these, Usher syndrome, Refsum's disease, Bassen-kornzweig syndrome, Hurler and Sanfilippo mucopolysaccharidosis, Laurence-Moon and Bardet-Biedl neurologic syndromes should be mentioned (Spaide, 1999).

ERG changes: delayed and reduced waves, first in scotopic and then in photopic responses.

In autosomal dominant form which has better prognosis, ERG may be some detectable, even up to middle-age, but in other forms, flat or non-detectable ERG is common finding when the disease passed initial stages.

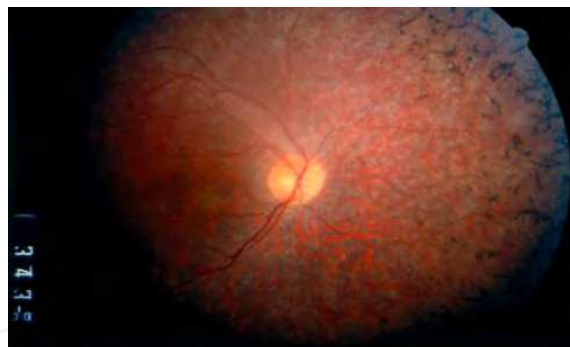

Fig. 8. RP disease or rod-cone degeneration.

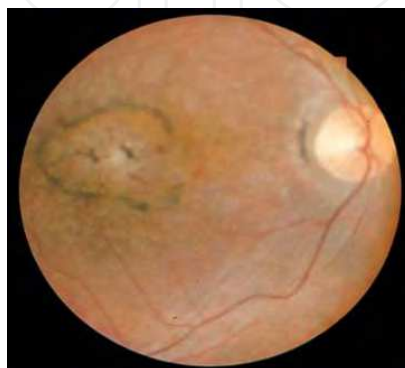

Fig. 9. Inverse RP disease.

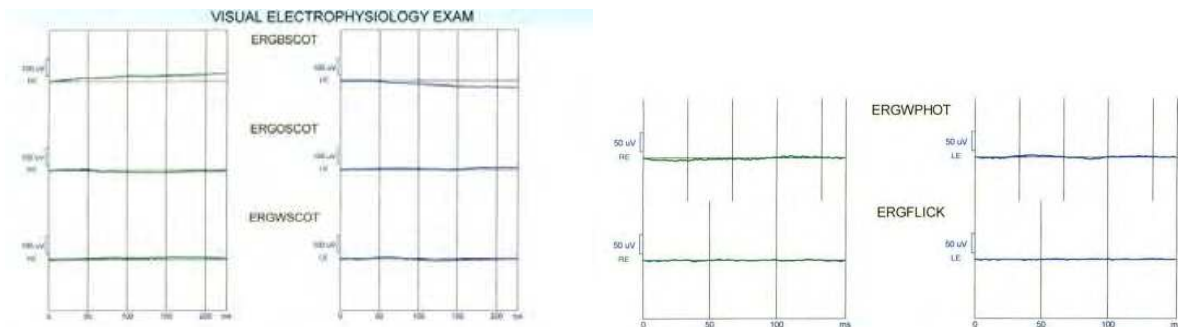


Fig. 10. Flat or non-detectable ERG in RP disease(right, scotopic ; left up, photopic; down, flicker).

### 7.1.2 Cone-rod degeneration

Also known as inverse R.P., starts with photophobia and reduced visual acuity that show cone involvement before rod degeneration. A rare form of disease involves cone system only.

ERG changes: Here, delay and amplitude reduction is more severe in flicker ERG, but finally, flat ERG in both scotopic and photopic responses is usual; m.f.ERG can help in primary stages without gross fundus changes, differentiating this disease from other disorders.

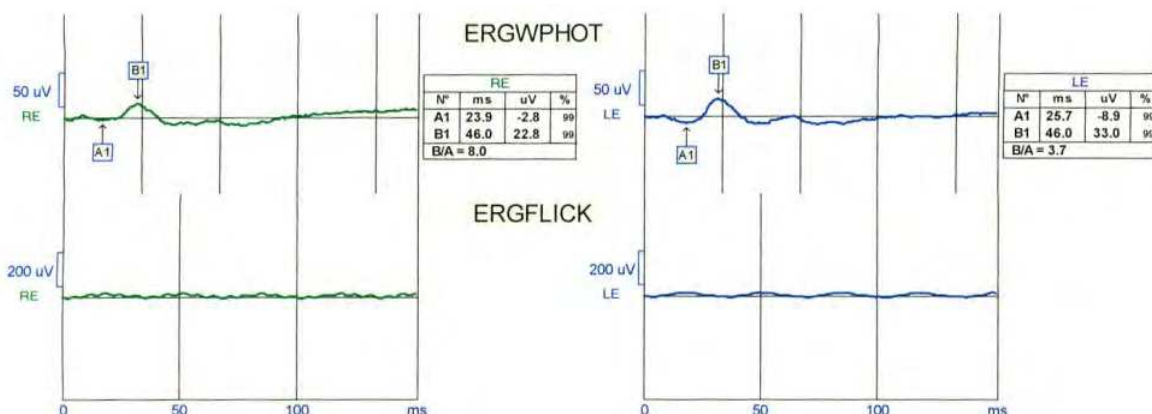


Fig. 11. Photopic and flicker ERG in cone-rod degeneration; flicker response(down) is severely reduced.

### 7.1.3 Avitaminosis A

Avitaminosis A with clinical symptoms and signs and ERG changes similar to R.P. disease; rarely seen today, but may occur in malabsorption. If treated timely, it is reversible.

### 7.1.4 Leber's Congenital Amaurosis (LCA)

LCA is ,in fact, congenital form of R.P disease. Patients suffer from low vision, manifesting with wandering eye movements or nystagmus and poor reactions to visual stimulations in neonatal life. Vast majority of cases are inherited in autosomal recessive trait (Ryan, 2006); and most of them have a high degree of hyperopia. Fundus changes, if observed, are mild but may progress in older ages.

ERG changes: Nearly flat or completely non-detectable ERG is routine response, differentiating it from delayed visual maturity (Movassat et al,2008 ).

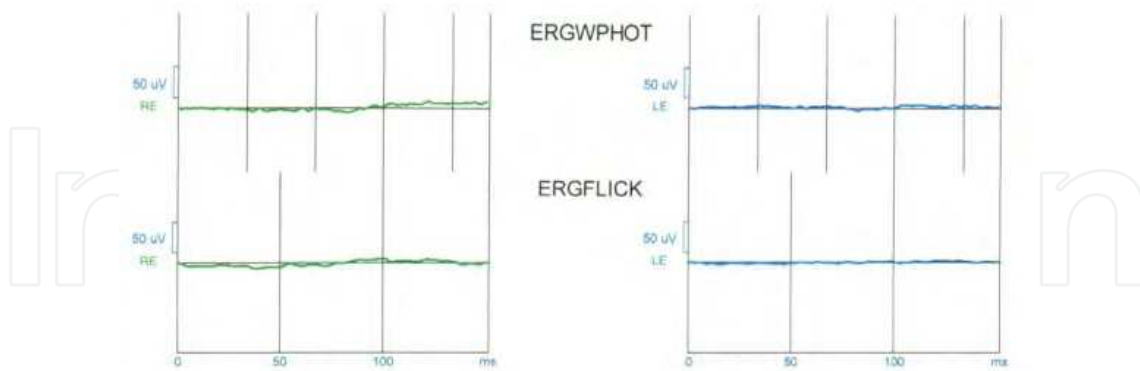


Fig. 12. Flat ERG, photopic and flicker, in LCA.

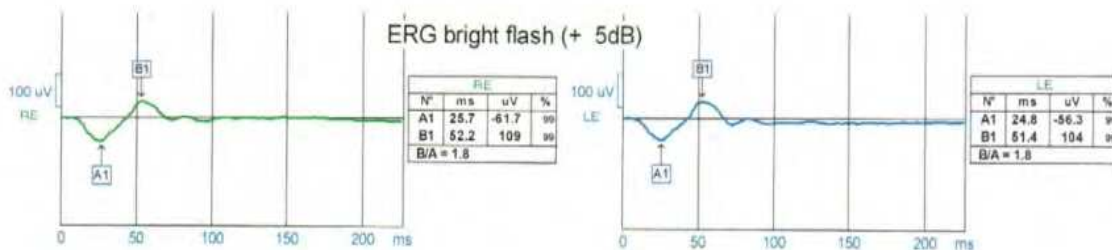


Fig. 13. Normal photopic ERG in delayed maturity.

### 7.1.5 Congenital Stationary Night Blindness (CSNB)

A group of hereditary diseases, with congenital non-progressing night blindness, and usually good visual acuity. Normal fundus is common finding, but in some types, white pigmentary changes without arterial narrowing (fundus albipunctatus) may be seen.

ERG changes: Abnormal scotopic, but normal photopic and flicker responses . Type 1 CSNB has totally flat scotopic ERG with all wavelengths, but type 2 has flat response with blue light, but negative ERG(a-wave only) with white light in scotopic ERG (Ryan, 2006).

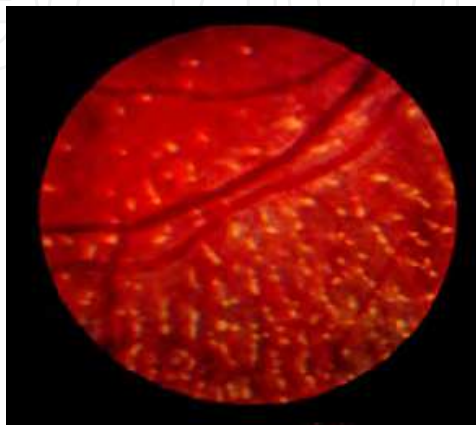


Fig. 14. Fundus albipunctatus.



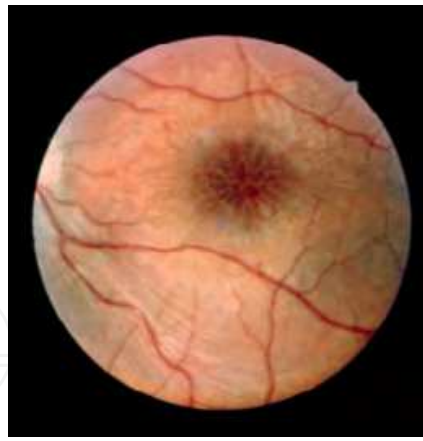

Fig. 15. X-linked retinoschisis.

X-linked retinoschisis with foveal cystic change is a subgroup of CSNB, with negative ERG that is characteristic when confronted with fundus changes.

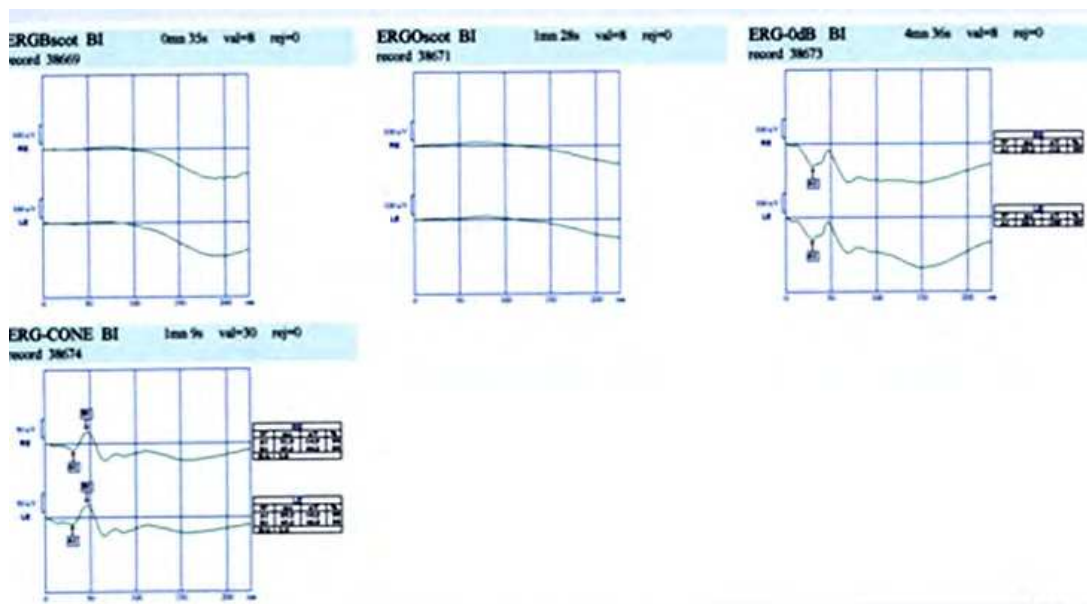


Fig. 16. Scotopic(up) and photopic(down) ERG in CSNB, showing negative ERG with white light in scotopic condition.

### 7.1.6 Achromatism

This group of anomalies is due to physiologically abnormal cone system, which causes color blindness. In complete, or typical rod monochromatism, all three types of cones have dysfunction. Although rare, this autosomal recessive monochromatism causes total color blindness associated with reduced visual acuity. In cone monochromatism, color blindness is incomplete, and cones not involved, work normally and patient has some color vision ability.

ERG changes: Normal scotopic, subnormal photopic, but non-detectable flicker responses are characteristic for rod monochromatism. In cone monochromatism flicker responses are reduced but not totally non-detectable.

### 7.1.7 Chorio-retinal vascular disorders

Central retinal artery (CRA), supplying blood of inner retina, if occluded causes painless total visual loss due to retinal ischemia. Branch retinal artery occlusion causes field defects due to ischemic changes in involved area. Central or branch venous occlusions causing severe blood circulation defects, although not so emergent as arterial occlusions, may result in serious late-onset complications which need close follow up. High blood pressure, diabetes and hyperlipidemia are predisposing factors for vascular disorders of retina.

ERG changes: Non-detectable b-wave, but normal a-wave (negative ERG) is ERG response in central retinal artery occlusion. In ophthalmic artery occlusion, affecting both choroid and retina, ERG is totally non-detectable.

Delayed and then reduced b-wave, initially in scotopic, and then in all conditions, is ERG response in branch or central retinal venous occlusions. Severe reduction of b-wave amplitude is a poor prognostic index, and b/a amplitude ratios less than 1 predicts neovascular complications, recommending prophylactic laser therapy (Lam, 2005). In stasis or incomplete occlusions, delayed b-wave in full-field and flicker ERG reflects the severity of ischemia.

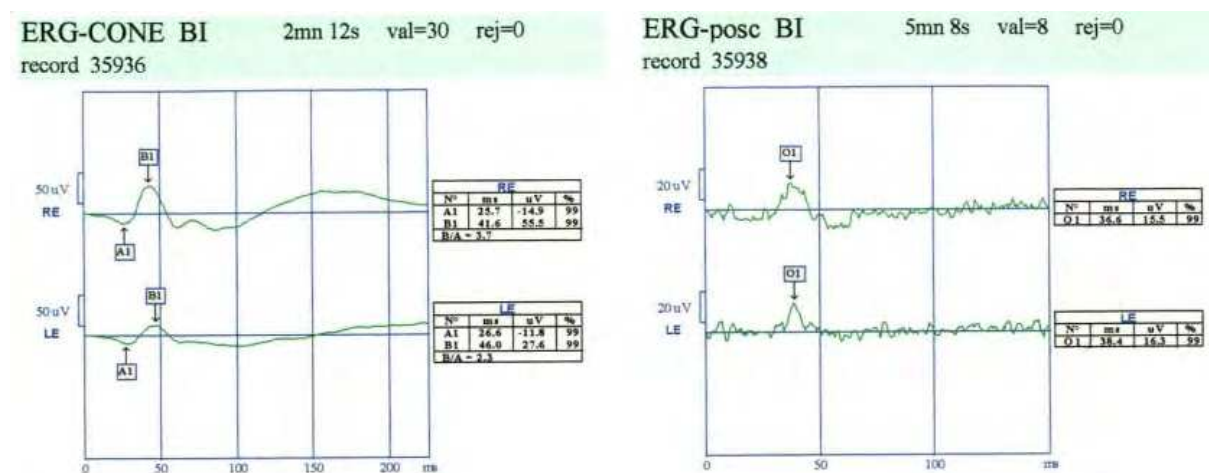


Fig. 17. Photopic(left) and oscillatory(right) potentials in a hypertensive case with branch retinal vein occlusion in left eye(down).

ERG helps in diabetes at two whiles. In patients with no diabetic retinopathy, normal or reduced oscillatory potentials indicate the ischemic condition of the retina and help for follow up planning (Lam, 2005 ;Movassat et al.,2008 ). In patients with non-proliferative retinopathy, changes of b-wave help to evaluate the degree of retinal ischemia and forecast occurrence of proliferative retinopathy, which help for timely laser therapy; m.f.ERG, also, can evaluate macular dysfunction objectively, and in association with angiography and OCT, is useful in proper treatment of diabetic macular edema.

### 7.1.8 Choroidal dystrophies

Of this group, autosomal recessive gyrate atrophy, helicoid peripapillary degeneration, X-linked recessive choroideremia, and central areolar choroidal atrophy, are diseases which can affect RPE and outer retina.

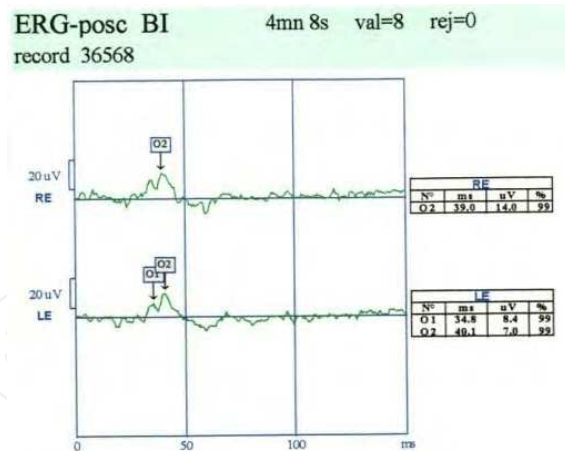


Fig. 18. Abnormal oscillatory potentials in a diabetic case without retinopathy.

ERG changes: Delayed and reduced waves, first in scotopic and then in photopic responses are usual. Occurring later with less severity than seen in retinal dystrophies, ERG responses reflect the stage of disease. EOG results parallels with ERG, showing RPE involvement too.

### 7.1.9 Chorioretinal inflammations

Congenital or acquired, disseminated or localized, chorioretinal inflammations and infections destruct the choroid, RPE, and retina and, if scar formation be extensive, the visual outcomes will be poor.

ERG changes: In localized macular involvements, m.f.ERG can evaluate the tissue destruction, and has both diagnostic and prognostic values.

In disseminated forms, full-field ERG can help for differential diagnosis and, also, can be used for follow up in cases receiving treatment.

### 7.1.10 Intra-ocular foreign bodies and drug-induced retinal toxicity

Intra-ocular metallic foreign bodies can cause metallosis which is more severe in case of copper (chalcosis), but more encountered in case of iron (siderosis).

Involving epithelial cells of the eye, they cause inflammation, and finally may terminate to severe permanent visual loss.

ERG changes: Following a short period of supernormal responses, delayed and reduced amplitude of components, specially in b-wave and first in scotopic condition, indicate starting of metallosis. It should be reminded that ocular traumas itself, can reduce ERG responses, and in risky removal of foreign bodies, it is recommended to wait for a few weeks and repeat the test for better evaluation. Non-detectable responses indicate poor results of surgery, but do not mean hopeless eye.

Of systemic drugs with retinal toxicity, chloroquine and hydroxychloroquine, indicated in rheumatoid arthritis and systemic lupus erythematosus, are ones to be mentioned. These drugs which bind with melanin may cause severe permanent visual loss before fundus changes. Diminished foveal reflex, bull's eye and peripheral pigmentary changes appear

when permanent paracentral scotomas are produced. Periodic ocular examinations, perimetry and ERG test are recommended in these cases.

ERG changes: Full-field ERG in progressed retinal toxicity, and flicker ERG in earlier stages can show the pathology.

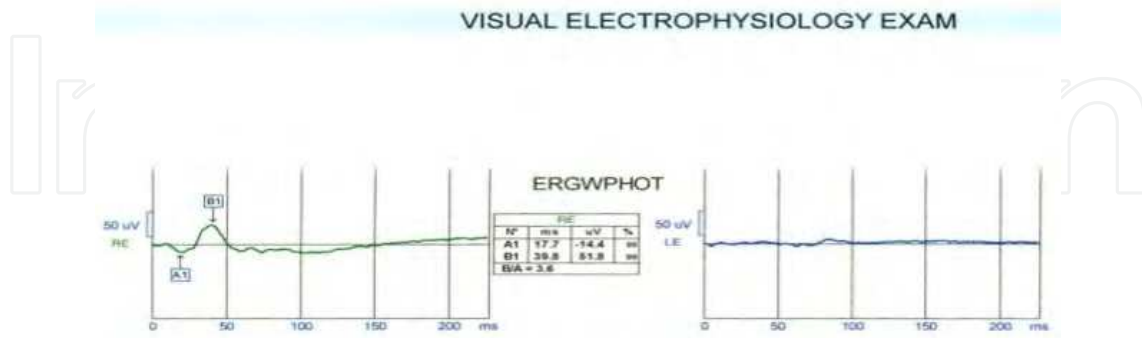


Fig. 19. Flat ERG in left eye due to siderosis bulbi.

In asymptomatic patients with normal visual acuity, m.f.ERG is a choice test in preclinical toxicity, showing reduced responses in rings pertained to fovea and perifovea (Lam, 2005).

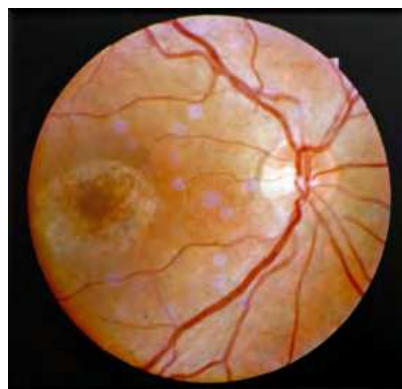

Fig. 20. Bull's eye due to chloroquine toxicity.

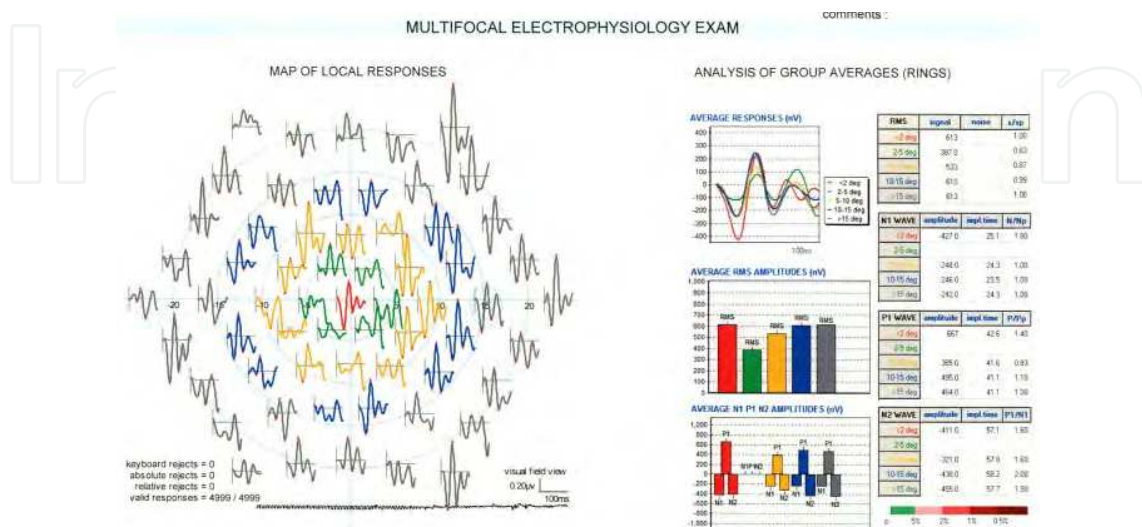


Fig. 21. Reduced response of m.f.ERG in chloroquine toxicity in perifovea.

### 7.1.11 Hazy ocular media

Deformed ocular tissues and hazy media in cases which need additional ocular surgery are dilemma in ophthalmology. In one side is a, probably, hopeless globe with risk of sympathetic ophthalmia with legal or forensic point of view, and in other side is an injured eye which may be treatable, although with very poor outcome. Other situations similar with these, are eyes with pathologic cataract, non-absorbing vitreous hemorrhagia, probably associated with fundus lesions, and longstanding corneal opacities with potential retinal lesions or amblyopia. In all these cases taking a proper decision is very difficult and is not only a clinical matter. In these situations functional and objective tests as, ERG and VEP, can help.

ERG changes: Any positive response of bright flash full-field ERG and VEP recommends to preserve the traumatized globe. In other causes of hazy media mentioned, comparing electrodiagnostic results with clinical conditions gives clue to prognose the outcome of procedure if indicated.

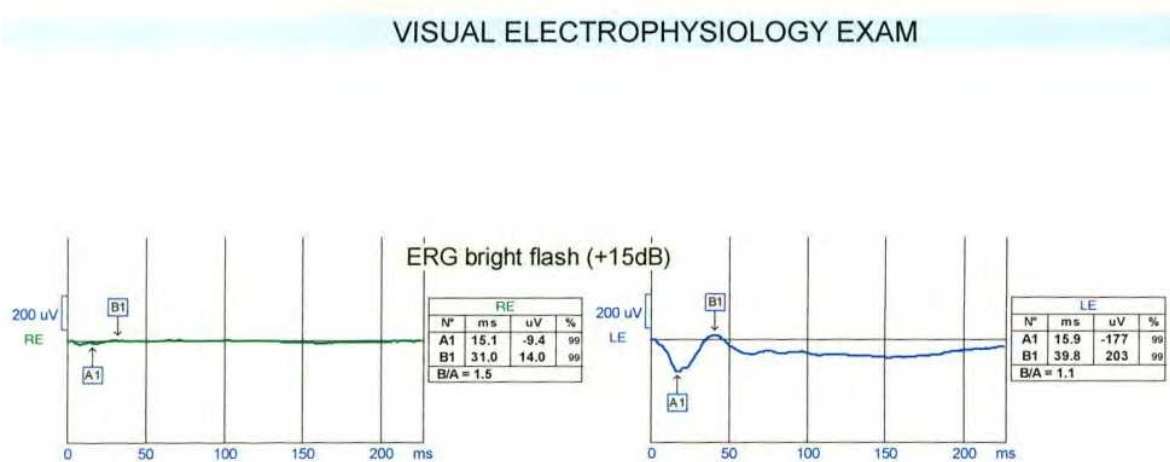


Fig. 22. Bright flash ERG in globe laceration of the right eye.

## 7.2 Disorders affecting EOG

In addition to outer retina disorders affecting EOG as ERG, there are some diseases, specially macular dystrophies and degenerations, in which EOG is a valuable diagnostic test.

### 7.2.1 Best vitelliform disease

An autosomal dominant dystrophy due to lipofuscin accumulation in RPE, which causes an egg-yolk-like appearance in macula. Several progressing stages from vitelliform to pseudohypopion and then to vitelliruptive and finally choroidal neovascularization and scar formation make the course of disease. In spite of characteristic macular changes, patients may have nearly good vision. With more tissue destruction, visual acuity reduces and macular hemorrhagia, edema and scar formation cause serious visual complications.

EOG changes: Severely decreased light rise of EOG, causing reduced Arden ratio, with normal full-field ERG is a characteristic dichotomy in Best disease (Spaide, 1999; Lam, 2005).

When RPE changes cause macular photoreceptors' dysfunction, flicker ERG and m.f.ERG show some reduced amplitude.

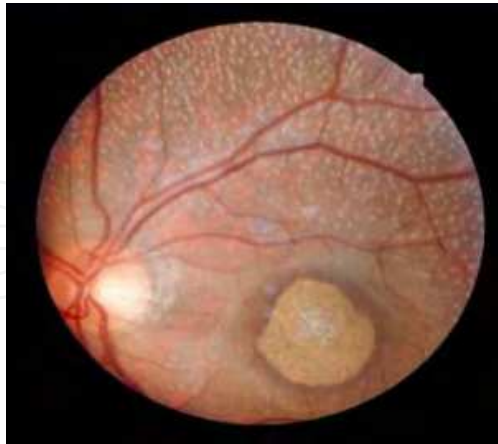

Fig. 23. Stargardt disease.

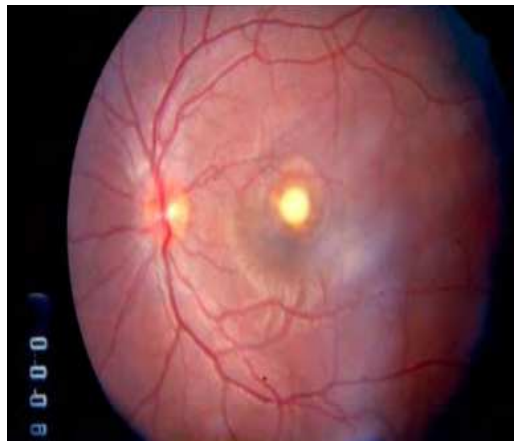


Fig. 24. Best vitelliform disease.

### 7.2.2 Stargardt and fundus flavimaculatus

This autosomal recessive macular dystrophy differs clinically with Best in early-onset decreased vision, even in pre-clinical stage. With characteristic beaten-metal macular appearance, usually surrounded with fishtail-like flecks, this disease is the most prevalent macular dystrophy.

EOG changes: Low Arden ratio, but not so severe as seen in Best disease. Flicker ERG, m.f.ERG and pattern ERG are abnormal, indicating involvement of macular sensory retina in Stargardt disease.

### 7.2.3 Pattern macular dystrophies

This group includes several diseases, with some similarity to Best disease in inheritance and clinical course. Of these, granular, reticular and specially, butterfly pattern dystrophies have characteristic macular appearance which, with almost good visual acuity, are easily diagnosed.

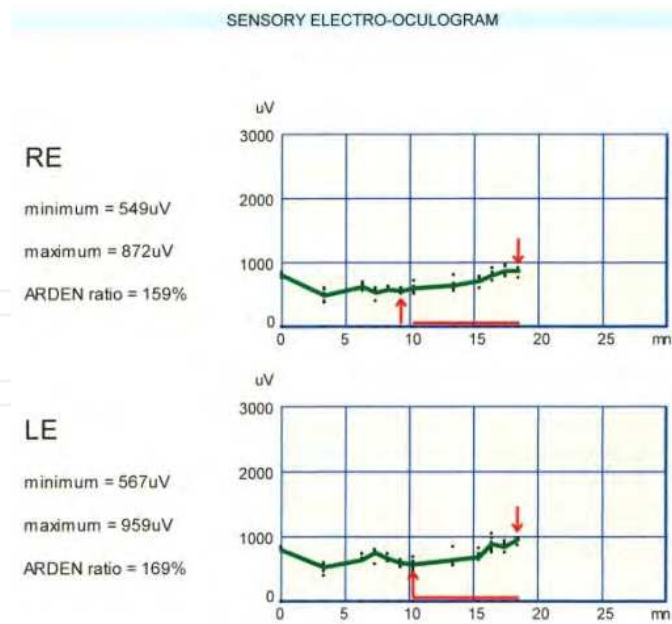


Fig. 25. EOG response in Stargardt disease.

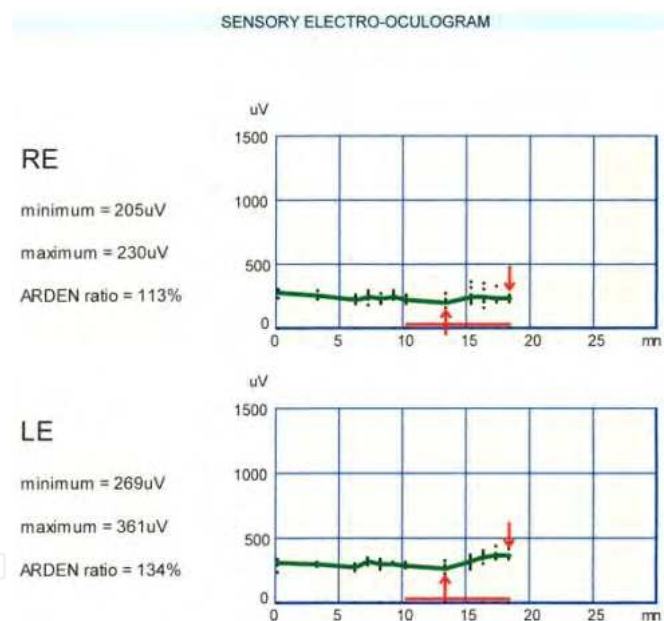


Fig. 26. EOG response in Best disease.

EOG changes: Nearly normal or subnormal EOG response is usual. In severely abnormal response of EOG, close follow up is recommended to foresee serious complications. There are some other RPE dystrophies and degenerations in which EOG can help for differential diagnosis.

### 7.3 Disorders affecting VEP

Involvement of visual pathways is probable in all cases of unexplained visual loss. VEP test can help for diagnosis in disorders affecting retinal ganglion cells, optic nerves, chiasm, optic tracts, geniculate bodies, optic radiations and striate cortex.

### 7.3.1 Optic neuritis

Optic neuritis, isolated or in systemic nervous system (CNS) disorders as multiple sclerosis (MS), HIV infection, neuromyelitis optica and so on, may occur as papillitis or retrobulbar neuritis. Visual loss varies from mild to severe, even no light perception. Pain during eye movement and afferent pupillary defect are positive clinical ocular findings. M.S disease is the most common cause of optic neuritis. MRI is a valuable paraclinic test in these patients, but its results may be equivocal and not conclusive in mild involvements.

VEP changes: Changes of P<sub>100</sub> component of pattern/reversal VEP can be a valuable diagnostic index in optic neuritis. In mild retro-bulbar neuritis without severe visual loss, delayed P<sub>100</sub> wave helps to diagnose the problem. In recurrent optic neuritis, delay and reduced amplitude of P<sub>100</sub>-or-P<sub>2</sub> wave have prognostic value (Lam, 2005).

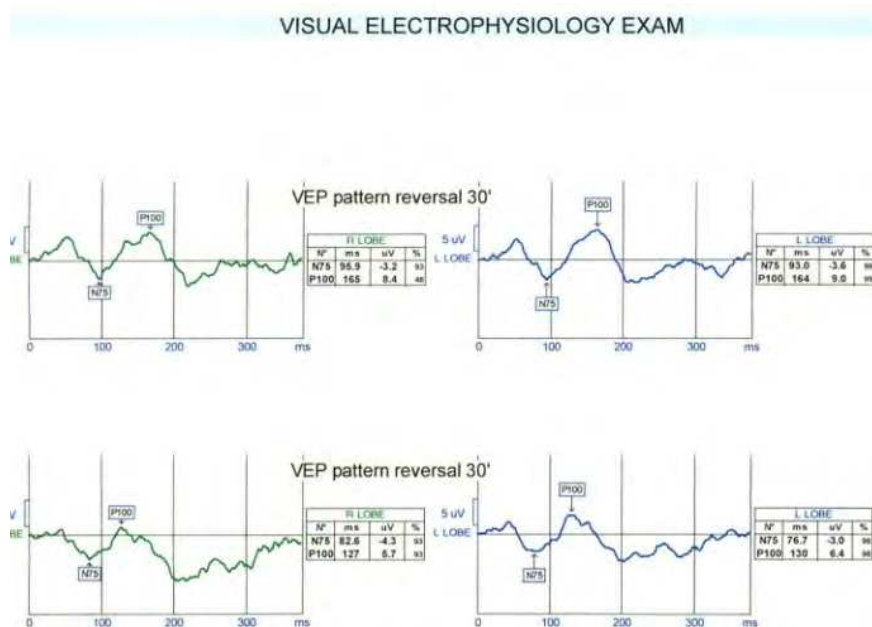


Fig. 27. P/R VEP in M.S. disease; delayed P<sub>100</sub> wave specially in right eye(up).

In MS cases without any ocular complaint, delayed P<sub>100</sub> component may be seen which confirms visual pathways involvement (Gronseth & Ashman, 2000; Movassat et al, 2009). In suspected new attack of disease, also changes of VEP is helpful for diagnosis.

### 7.3.2 Optic neuropathies

This group of diseases with vast etiologic factors, causes suddenly or gradually visual loss; optic disc swelling or pallor may be seen in some cases. Of those with more clinical interest are ischemic optic neuropathy (ION), traumatic optic neuropathy (TON), toxic optic neuropathy (due to methanol, lead, and nutritional or B<sub>12</sub> vitamin deficiency), hereditary optic neuropathy, and compressive optic neuropathy.

VEP changes: Delayed and reduced P<sub>100</sub>-or-P<sub>2</sub> component show abnormalities, specially in challenging situations. In ischemic and toxic neuropathies, VEP can help to evaluate the recovery or deterioration; in traumatic neuropathy, it helps to evaluate the visual function and also, in follow up of cases; and in hereditary optic neuropathy like the Leber



neuropathy it helps for differential diagnosis. In Leber hereditary optic neuropathy which involves both eyes with an interval of weeks to months (Lam, 2005), in addition to VEP changes, N<sub>95</sub> component of pattern ERG is also reduced, showing pathology of ganglion cells of retina too.

Optic neuropathy in glaucoma, although related to high intra-ocular pressure, is another disease in which VEP, specially m.f.VEP, can help to decide when to shift to other drugs or to surgery or when therapy should be started in ocular hypertension.

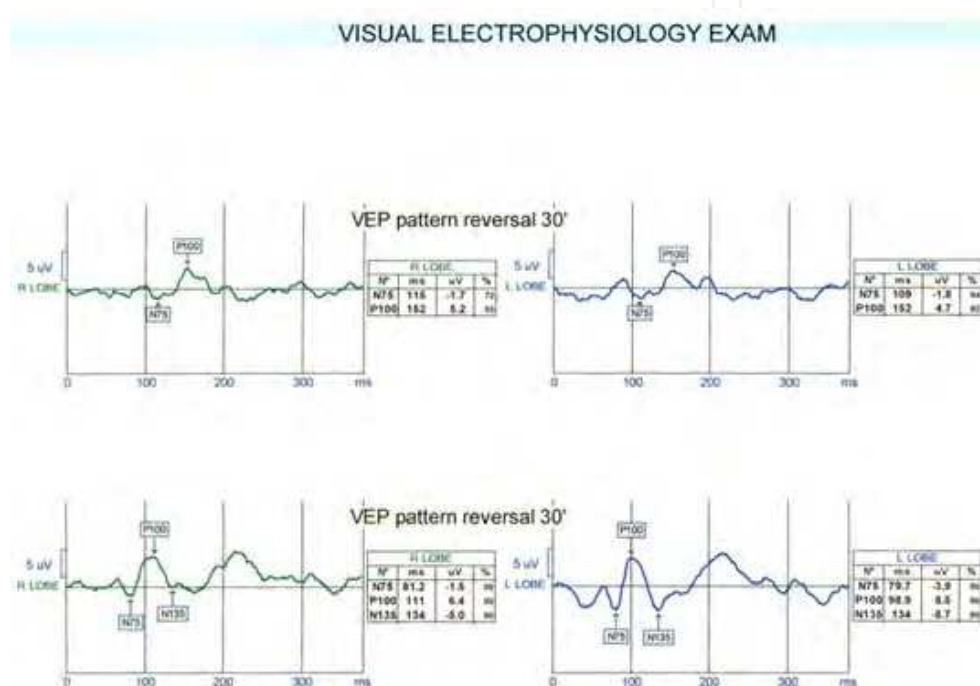


Fig. 28. P/R VEP in ischemic optic neuropathy in right eye(up); reduced and delayed P<sub>100</sub> wave is diagnostic.

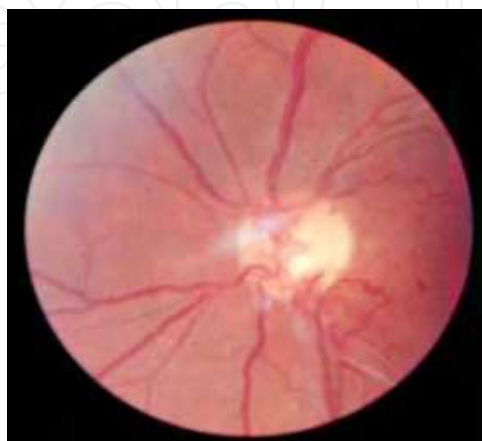

Fig. 29. Leber's optic neuropathy.

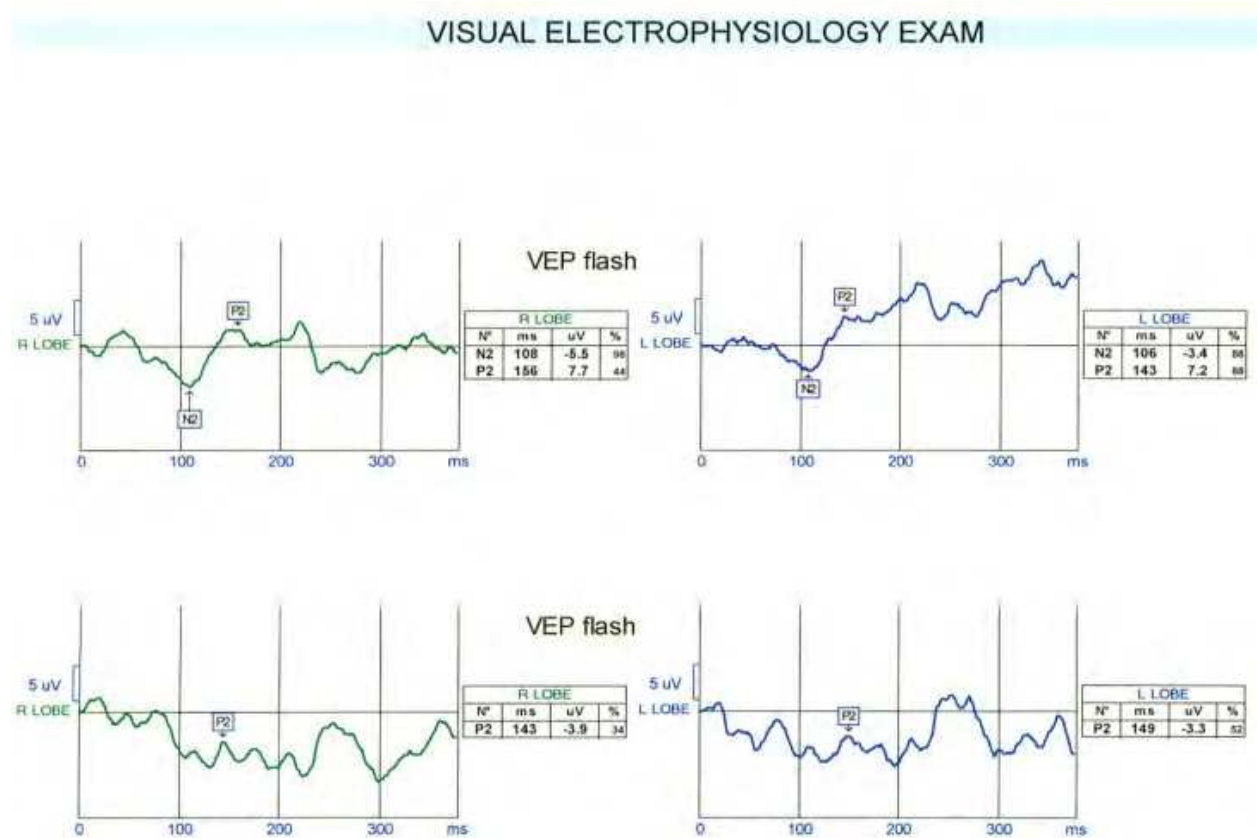


Fig. 30. Flash VEP in Leber's optic neuropathy.

### 7.3.3 Central Nervous System (CNS) disorders


Several diseases in this group can affect visual pathways and striate cortex, but visual complications are not initial and predominant manifestations in many of them. In cortical blindness due to CNS lesions and in Alzheimer disease, affecting visual memory, visual symptoms may draw attention before other manifestations. Neuro-degeneration in Alzheimer (Prisi et al,2001) may cause agnosia which may be first symptom of disease. Also in patients suffering from stroke, encephalitis and head trauma the geniculate bodies, optic radiations and visual cortex may be involved.

VEP changes: VEP, specially m.f.VEP helps to document the visual problems. Also pattern ERG can show retinal ganglion cells degeneration.

## 8. References

- Arden GB, Kelsey JH (1962). Changes produced by light in the standing potential of the human eye *JPhysiol*, 1962 May; 161(2):189-204, ISSN: 0022-3751
- Brown KT, Wiesel T N(1961). Analysis of the intraretinal electroretinogram in the intact cat eye. *J Physiol*, 1961 Sep; 158(2):257-280, ISSN: 0022-3751
- Ciganek ML (1961). The EEG response (evoked potential) to light stimulus in man. *Electroencephalogr Clin Neurophysiol*, 1961 Apr; 13:165-72 , ISSN: 0013-4694
- Halliday AM, McDonald WI, Mushin J (1972). Delayed visual evoked response in optic neuritis. *Lancet*, 1972 May 6; 1 (7758): 982-985, ISSN: 0140-6736

- Heckenlively John R. and Arden Geoffrey B. (2006). *Principles and practice of clinical electrophysiology of vision*, the MIT Press, ISBN: 0-262-08346-9, England
- Karpe G. (1982). Basis of clinical electroretinography. *Acta Ophthalmol* 1982; 60:123-132, ISSN:1755-3768
- Kris C (1958). Corneo-fundal potential variations during light and dark adaptation. *Nature*, 1958 Oct 11, 182: 1027-1028, ISSN: 0028-0836
- Lam Byron L. (2005). *Electrophysiology of vision; clinical testing and applications*, Taylor and Francis, ISBN: 0-8247-4068-8, USA.
- Miller RF, Dowling JE (1970). Intracellular responses of the Muller (glial) cells of mudpuppy retina: Their relation to b-wave of the electroretinogram. *J Neurophysiol*, 1970 May; 33 (3): 323-41 ISSN: 0022-3077
- Movassat Morteza, Roohipour Ramak, Nili-Ahmadabadi Mehdi (2008). A case series study of Leber's congenital amaurosis, clinical description and ERG. *Iranian journal of ophthalmology*, 2008; 20(3):33-38 ISSN: 1735-4153
- Movassat Morteza, Modarresi Mohsen, Mansouri Mohammad-Reza, Nili-Ahmadabadi Mehdi, Rajabi Mohammad-Taher (2008). Oscillatory potentials in diabetic retina without retinopathy. *Iranian Journal of Ophthalmology*, 2008;20 (1): 20-24 ISSN: 1735-4153
- Movassat Morteza, Piri Niloufar, Nili-Ahmadabadi Mehdi (2009). Visual evoked potential study in multiple sclerosis disease, *Iranian Journal of Ophthalmology* 2009; 21(4): 37-44, ISSN: 1735-4153
- Newman EA (1993). Membrane physiology of retinal glial (Muller) cells. *J Neurosci*, 1993 Aug; 13(8): 3333-45, ISSN: 0270-6474
- Ostwald TJ, Steinberg RH (1980). Localization of frog retinal pigment epithelium Na<sup>+</sup> K<sup>+</sup> ATPase. *Exp Eye Res*, 1980; 31: 351-360, ISSN: 0014-4835
- Pinckers A, Broekhuysen R.M. (1983). The EOG in rheumatoid arthritis. *Acta Ophthalmol*, 1983 Oct; 61(5): 831-7, ISSN: 1755-3768
- Ryan, Stephen J. , Hinton David R. (2006). *Basic science and inherited retinal diseases*, Elsevier Mosby. ISBN-13: 978-0-323-02598-0;-10: 0-323-02598-6 USA
- Spaide Richard F. (1999). *Diseases of the retina and vitreous*. W.B Saunders Company. ISBN: 0-7216-8005-4
- Wachtmeister L. (1998). Oscillatory potentials in the retina: what do they reveal. *Prog Retinal Eye Res* 1998; 17: 485-521 ISSN: 1350-9462



## **Electrophysiology - From Plants to Heart**

Edited by Dr. Saeed Oraii

ISBN 978-953-51-0006-5

Hard cover, 202 pages

**Publisher** InTech

**Published online** 03, February, 2012

**Published in print edition** February, 2012

The outstanding evolution of recording techniques paved the way for better understanding of electrophysiological phenomena within the human organs, including the cardiovascular, ophthalmologic and neural systems. In the field of cardiac electrophysiology, the development of more and more sophisticated recording and mapping techniques made it possible to elucidate the mechanism of various cardiac arrhythmias. This has even led to the evolution of techniques to ablate and cure most complex cardiac arrhythmias. Nevertheless, there is still a long way ahead and this book can be considered a valuable addition to the current knowledge in subjects related to bioelectricity from plants to the human heart.

### **How to reference**

In order to correctly reference this scholarly work, feel free to copy and paste the following:

Morteza Movassat (2012). Diagnostic Values of Electrophysiology in Ophthalmology, *Electrophysiology - From Plants to Heart*, Dr. Saeed Oraii (Ed.), ISBN: 978-953-51-0006-5, InTech, Available from: <http://www.intechopen.com/books/electrophysiology-from-plants-to-heart/diagnostic-values-of-electrophysiology-in-ophthalmology>

**INTECH**  
open science | open minds

### **InTech Europe**

University Campus STeP Ri  
Slavka Krautzeka 83/A  
51000 Rijeka, Croatia  
Phone: +385 (51) 770 447  
Fax: +385 (51) 686 166  
[www.intechopen.com](http://www.intechopen.com)

### **InTech China**

Unit 405, Office Block, Hotel Equatorial Shanghai  
No.65, Yan An Road (West), Shanghai, 200040, China  
中国上海市延安西路65号上海国际贵都大饭店办公楼405单元  
Phone: +86-21-62489820  
Fax: +86-21-62489821

© 2012 The Author(s). Licensee IntechOpen. This is an open access article distributed under the terms of the [Creative Commons Attribution 3.0 License](#), which permits unrestricted use, distribution, and reproduction in any medium, provided the original work is properly cited.

IntechOpen

IntechOpen