

We are IntechOpen, the world's leading publisher of Open Access books Built by scientists, for scientists

4,800

Open access books available

122,000

International authors and editors

135M

Downloads

Our authors are among the

154

Countries delivered to

TOP 1%

most cited scientists

12.2%

Contributors from top 500 universities

**WEB OF SCIENCE™**Selection of our books indexed in the Book Citation Index
in Web of Science™ Core Collection (BKCI)

Interested in publishing with us?
Contact book.department@intechopen.com

Numbers displayed above are based on latest data collected.

For more information visit www.intechopen.com

Single Port Laparoscopic Surgery

Carus Thomas

*Department of General, Visceral and Trauma Surgery,
Center for Minimally Invasive Surgery,
Klinikum Bremen-Ost/ Gesundheit Nord GmbH,
Germany*

1. Introduction

In the last two decades, almost every operation in the abdominal and thoracic cavity - from a simple diagnostic laparoscopy to esophagectomy - has been successfully performed by minimally invasive technique. In interventions such as cholecystectomy for symptomatic cholelithiasis or sigmoid resection for recurrent diverticulitis the laparoscopic, minimally invasive procedure is now considered standard.

It should not go unmentioned that Erich Mühe from Böblingen/ Germany performed the first laparoscopic cholecystectomy worldwide in 1985 with his "Galloskop", a multi channel single-port trocar. (1) Giuseppe Navarra from Italy published 1997 his "one-wound-cholecystectomy" with standard trocars introduced through one skin incision. (2)

Since the first transvaginal NOTES cholecystectomy (natural orifice transluminal endoscopic surgery) in 2007 (3) special interest lays in minimizing the access trauma to reach a (nearly) scarless surgery. In 2008 the first special trocars to perform a laparoscopic operation through one small incision became available (single port laparoscopic surgery). From this time "standard" laparoscopy via 3 - 4 incisions had to compete with NOTES and single port laparoscopic surgery.

In a very short time multidisciplinary applications were developed and are still expanding. Single port laparoscopic surgery has potential advantages for e.g. postoperative pain, wound infections and cosmesis. This chapter will give an overview of technology, handling and clinical application.

2. Single port laparoscopic surgery

In single port laparoscopic surgery the surgeon operates through a single access point, usually the patient's umbilicus. Several expressions are used to describe these procedures:

SPL	single-port laparoscopy
SPT	single-port technique
SPA	single-port(al) access
SPICES	single-port incisionless conventional equipment-utilizing surgery

SILS	single incision laparoscopic surgery
OPUS	one-port umbilical surgery
TUE	transumbilical endoscopic surgery
LESS	laparoscopic-endoscopic single site
NOTUS	natural orifice transumbilical surgery
E-NOTES	embryonic
NOTES	(= umbilical access)

The term "SILS" is registered by the company Covidien, "LESS" is usually used by the company Olympus. We generally use the neutral term "SPL" for single port laparoscopy.

2.1 Special devices and instruments

To perform single port procedures successfully many surgeons use special devices and instruments. There is an increasing number of products for both groups.

2.1.1 Special trocars and access ports

Single port access starts with a 15 - 20 mm skin incision in the umbilicus or at the lower circumference of the umbilicus. (Figure 1) For special indications like e.g. SPL-IPOM incisional hernia repair the access is positioned on the right or left side of the patient's abdomen.

After dissecting the subcutaneous tissue and opening the ventral fascia, the rectus muscles are pulled to both sides with Langenbeck hooks. The posterior sheath and the peritoneum are pulled upwards and opened by scissors. The Langenbeck hooks are placed under the peritoneum (Figure 2). If there are local adhesions, they can be dissected by finger or sharply under direct visual control.

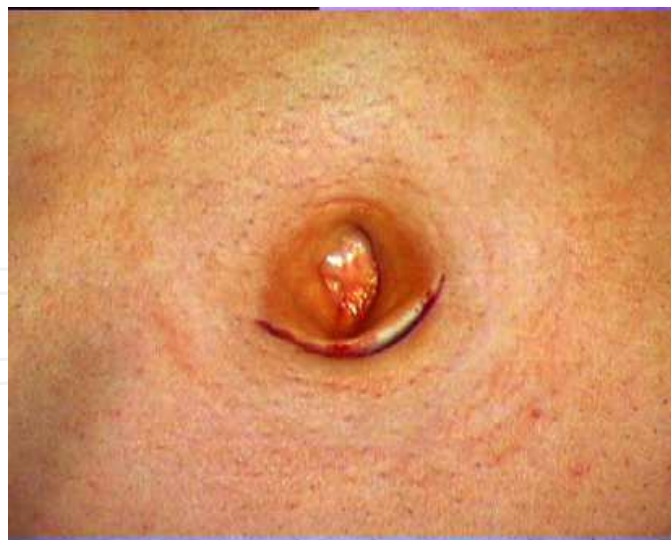


Fig. 1. Subumbilical incision for single port laparoscopy

A special single port device can then be introduced through this access. Starting in 2008 with the single-use TriPort system (Advanced Surgical) many different devices were developed in the last years. Examples for single-use devices are TriPort and QuadPort (now: Olympus), SILS-Port (Covidien), GelPOINT (Applied Medical) and Uni-X (Pnavel).

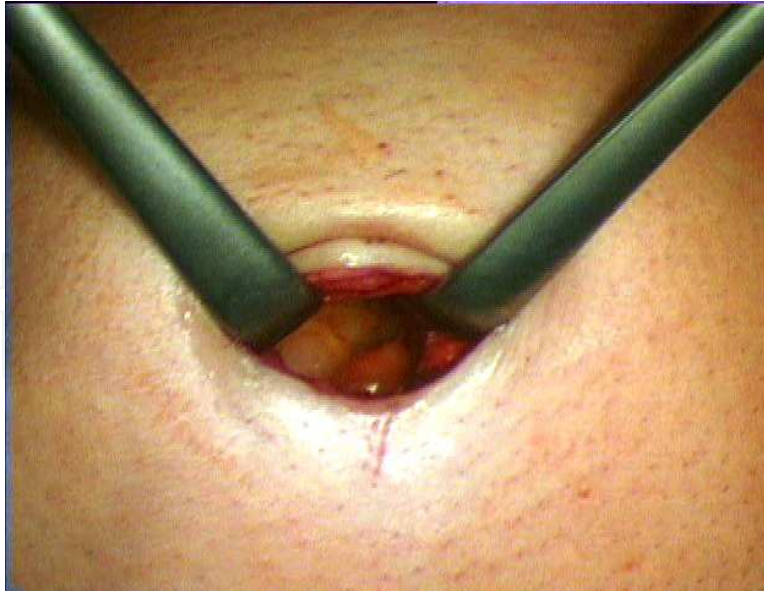


Fig. 2. Open access to the abdominal cavity

Reusable single port devices were developed by Karl Storz company with the X-Cone and EndoCone.

In the following examples are shown how to handle these special devices.

Usage of the SILS-Port (Covidien)

The SILS-Port is a flexible device for single-use with three open channels for the insertion of 5 - 12 mm trocars and one channel with a tube for gas supply. The widening at both ends allows a secure fit under the peritoneum and prevents dislocation into the abdomen. (Figure 3)

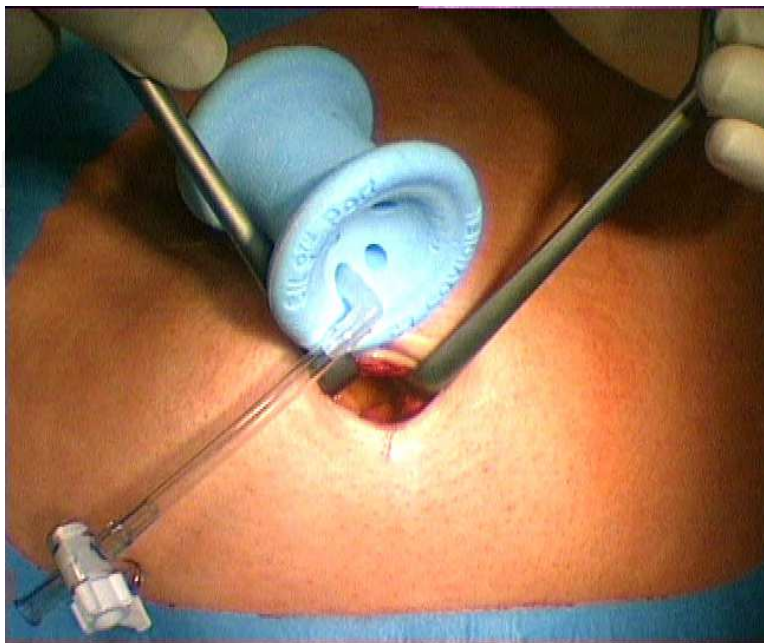

Fig. 3. Shape of the SILS-Port

By pushing the lower widening together, the SILS-Port can be easily pushed into the opening. If the incision is smaller than 20 mm, it is helpful to use a lubricant. (Figure 4)

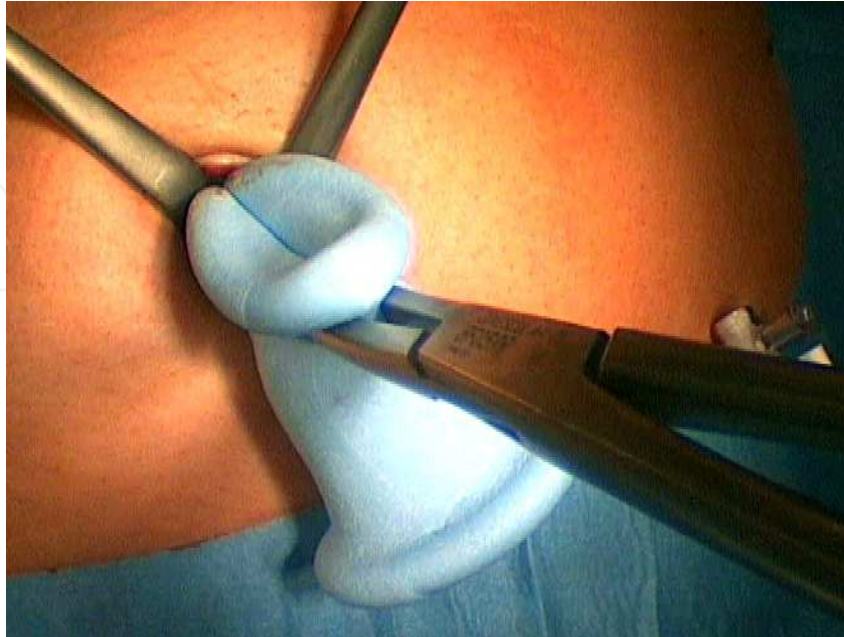


Fig. 4. Introducing the SILS-Port

After correct placement gas supply is connected and three trocars are gently pushed into the channels. We normally use one flexible 5 mm trocar for use of a curved instrument, one straight 5 mm trocar for a standard instrument and another 5 (or 10) mm trocar for the optic. (Figure 5). You can as well use only straight trocars, single-use or reusable from 5 to 12 mm diameter size.

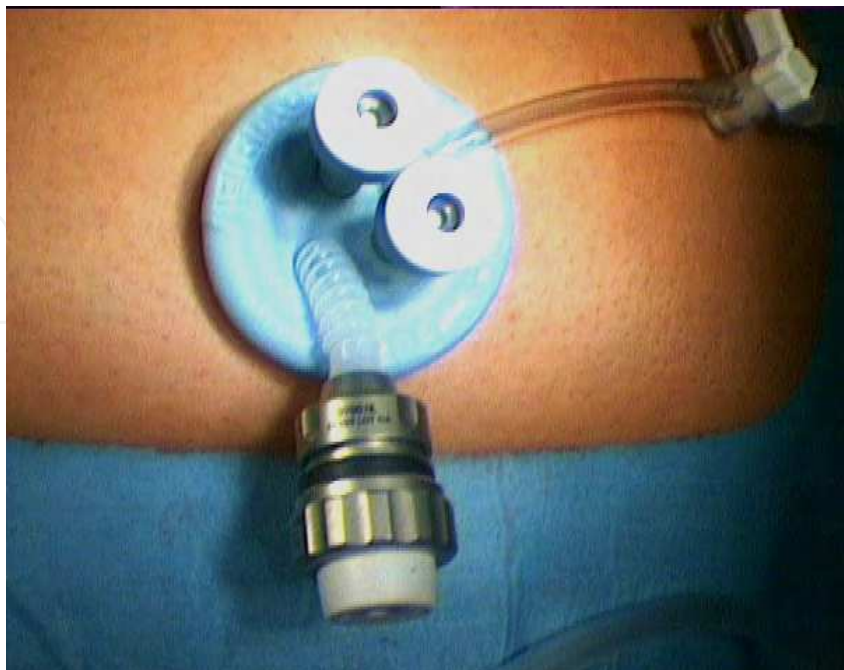


Fig. 5. SILS-Port with 3 trocars and gas supply

Usage of the TriPort (Olympus)

The TriPort device is an example for a single-use single port system, which consists of two (or more) pieces. A flexible tube is introduced into the abdominal cavity while a head piece is mounted on the tube. (Figure 6)

The tube is then pulled upwards until the inner ring of the tube touches the peritoneum. (Figure 7)

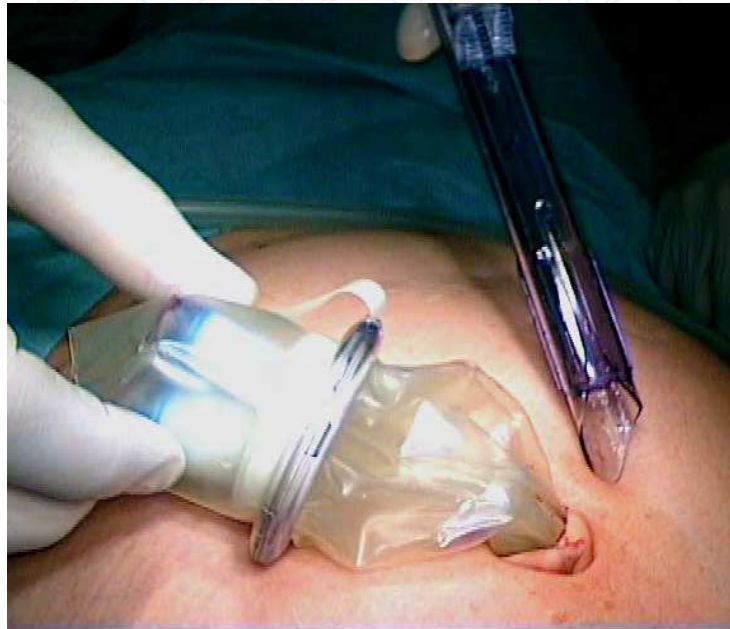

Fig. 6. TriPort with inserted tube and introducer

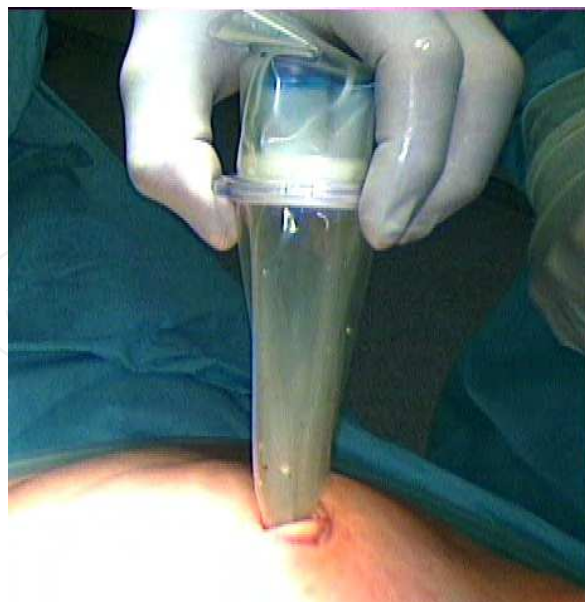

Fig. 7. Tensioned tube and head piece

The head piece is pushed down to abdominal wall to give enough tension for a stable fixation. (Figure 8)



Fig. 8. Head piece in final position

This position is held by mounting two brackets. The ready system has one port for gas supply and 3 ports with silicone valves for the instruments. (Figure 9)

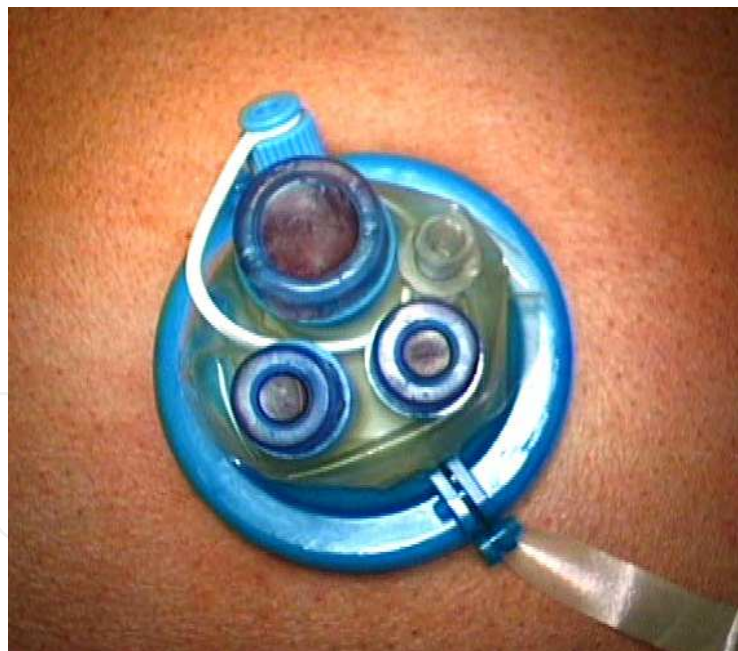

Fig. 9. TriPort with 3 valves and gas supply

Usage of the X-Cone (Karl Storz)

The X-Cone represents a reusable system, which consists of 2 specially shaped metal hooks and one rubber cap with 5 valves. The metal hooks are shell-shaped at the top and build a semi-circular tube at the bottom. The two half-tubes are plugged together and can be easily introduced through the incision. (Figure 10)

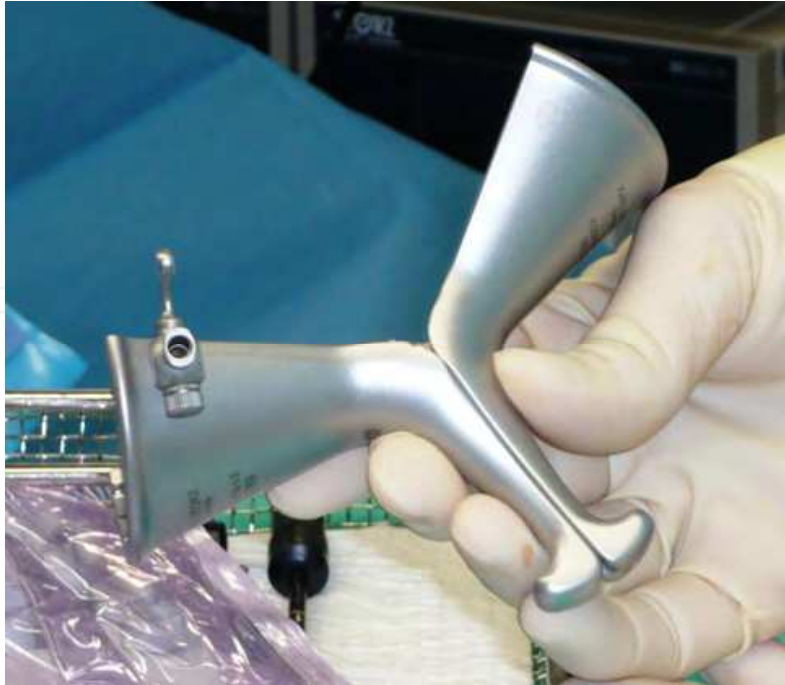

Fig. 10. X-Cone with closed half-tubes

When the half-tubes are inside the abdominal cavity, the upper portions are folded together. They form a ring and bring the lower portions in an X-shape. (Figure 11)

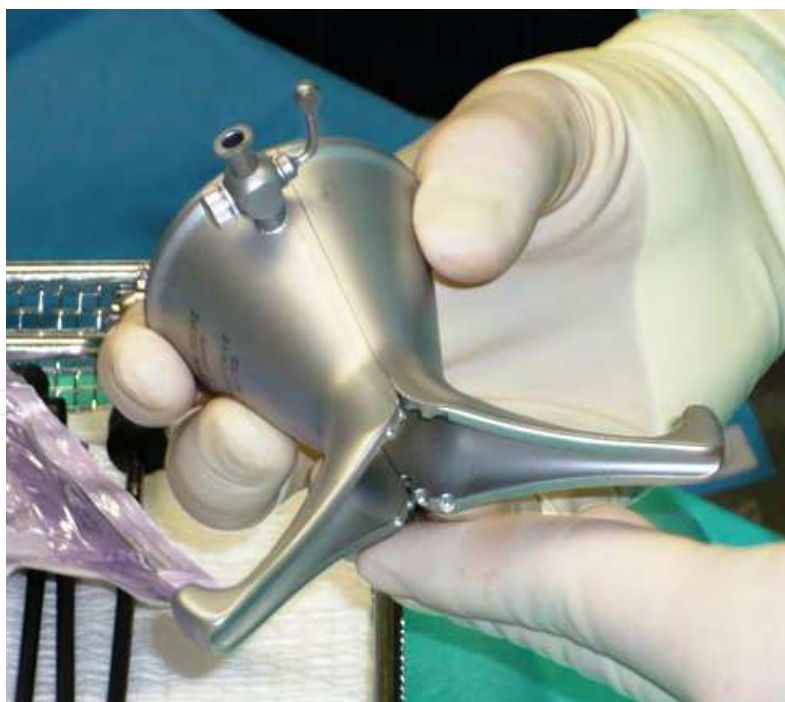


Fig. 11. X-Cone with closed upper portions in X-shape

Finally a rubber cap with 5 valves for one optic and up to 4 instruments is mounted on the ring. The rubber cap has to be replaced when it is worn while the metal parts can be used hundreds of times. (Figure 12)

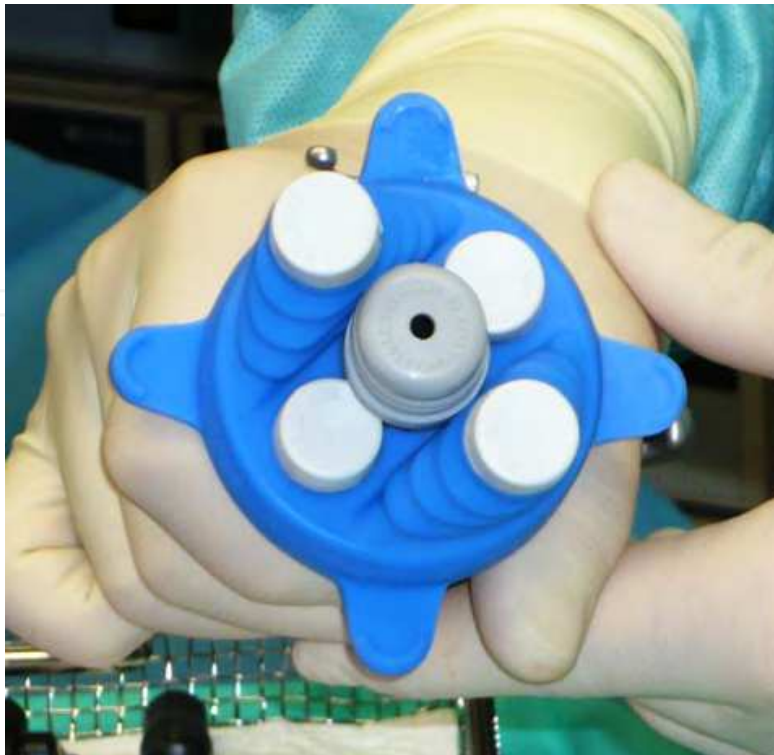


Fig. 12. X-Cone with rubber cap and 5 valves

To pull out the resected organs, the rubber cap is removed for an easy access. (Figure 13)

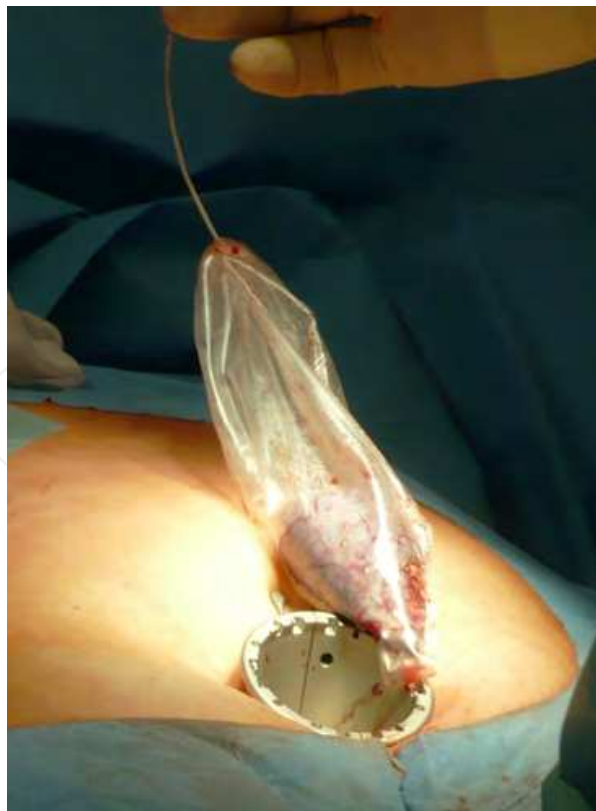

Fig. 13. Extraction of a gallbladder through the open X-Cone

Due to their construction the systems have specific advantages and disadvantages. A rigid shaft like with the X-Cone leads in comparison to the flexible ports to a tighter fit in the abdominal wall with a good gas tightness. The mobility of the instruments shafts is a bit more restricted. A very flexible approach as the TriPort makes the introduction easier but may lead to slight dislocation and corresponding gas loss especially in long during operations. The SILS-Port takes a middle position with a good stability and enough flexibility.

The development of single-port devices is still in the beginning. Many other will follow with its specific characteristics, advantages and disadvantages. Currently the surgeon chooses the type of single-port device according to his personal experiences.

2.1.2 Special instruments

When a single port device is used, one or two working instruments are introduced in a parallel way close to the optic. The surgeon's hands and the optics interfere with each other and restrict the mobility.

Two paths are followed to facilitate this problem: instruments which are bendable inside the abdominal cavity or curved instruments extend the distance between hands and optic. The same effect can be achieved by an optic with a movable lens or a bendable shaft.

One example of a curved instrument is shown in Figure 14. It is constructed with a standard shaft, which allows a full 360° rotation, and a curved tip. The view is not limited by parallel instrument tips and triangulation is much easier. Additionally the "knee" of the tip helps to keep other organs away from the preparation zone.

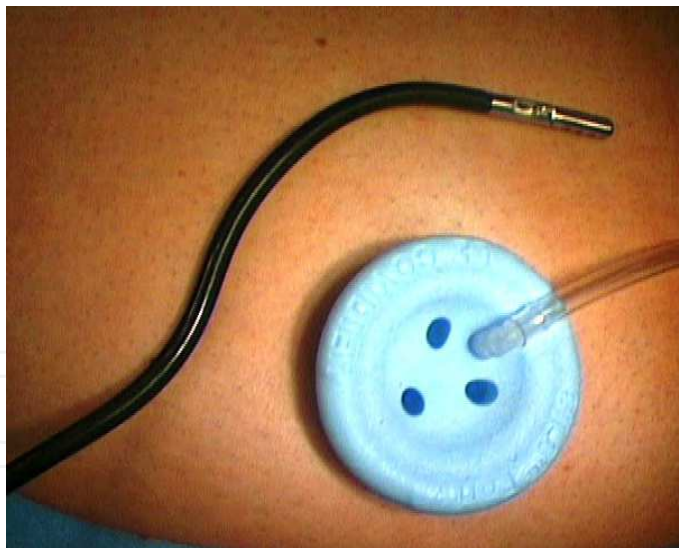

Fig. 14. Curved single-port instrument (forceps by Carus)

2.1.3 Optical devices

In standard or "conventional" laparoscopy, optical devices with a 0° or 30° lens are normally used. The instruments do not touch the optic, because the working trocars are far enough away from the optic. There will be no disturbing interference between surgeon's hands and the optic.

In single port laparoscopy the proximity between hands and optic represent the greatest problem. In addition to using special instruments an optic with a movable lens or a bendable shaft is very helpful.

By turning the lens to 60 or more degrees, the camera-holding hand can be moved down and gives space for the working hands. (Figure 15)

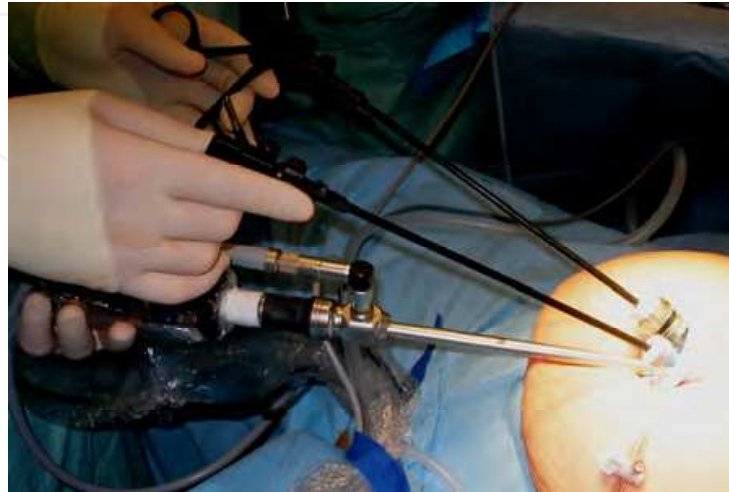


Fig. 15. Single-port optic with movable lens in 60° position during single port cholecystectomy

2.2 Clinical application

Modern techniques allow laparoscopic surgeons to perform complex operations with great certainty. Numerous studies (4) demonstrate the benefits to the patient by a lower need for analgetics, partially reduced perioperative complications, a better cosmetic result and a rapid convalescence. (5, 6)

The spectrum of single port laparoscopic surgery (SPLS) is broad and includes operations from simple diagnostic laparoscopy to gastrectomy or liver resection. SPLS does not lead to an expansion of existing spectrum but offers the chance to further minimize the access trauma with a new technique and ergonomics. The implementation of SPLS requires excellent laparoscopic skills.

In the following some elective operations, which are increasingly performed in SPLS, are described.

2.2.1 Single port laparoscopic cholecystectomy

Up to now single port laparoscopic cholecystectomy is the most commonly practised single port procedure. Pubmed literature search shows 136 results for “single port laparoscopic cholecystectomy” and 55 results for “SILS cholecystectomy” on July 21st 2011. (e.g. 6, 7, 8, 9)

After umbilical access the optic (5 or 10 mm) and 2 instruments are introduced through a single port device. The gallbladder is lifted with the left hand; preparation is performed by the right hand of the surgeon. (Figure 16)

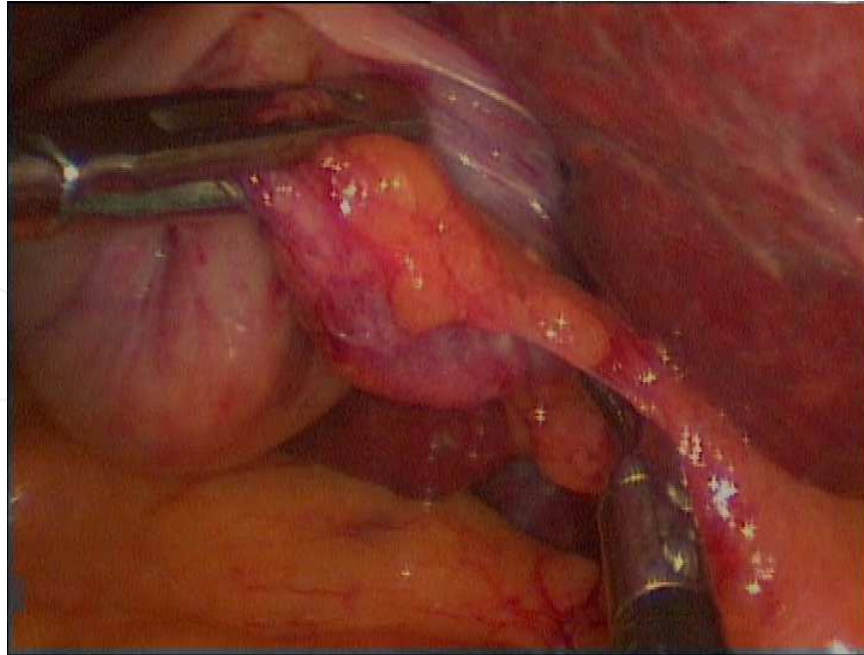


Fig. 16. Single port preparation with curved forceps (left) and straight dissector (right)

Because of the more difficult triangulation in single port technique exposure of the Calot triangle is challenging. It requires much more accuracy than in “conventional” laparoscopy. (Figure 17)

After adequate exposure of cystic duct and cystic artery, both structures are dissected between metal or absorbable clips. The gallbladder is lifted with the curved forceps, the resection can then be easily done with an ultrasonic hook. (Figure 18)

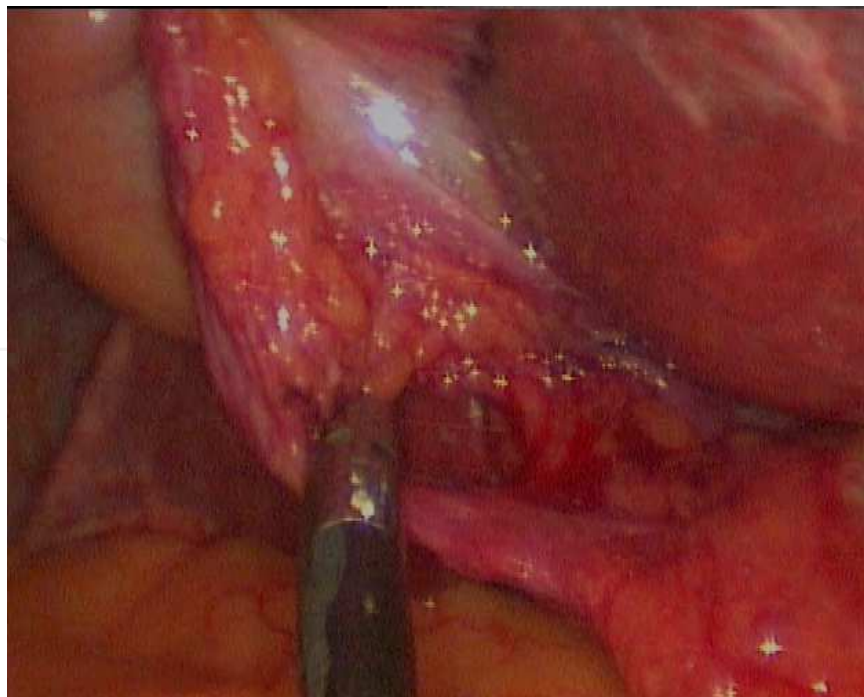


Fig. 17. Exposure of the cystic duct and its confluence with the common bile duct

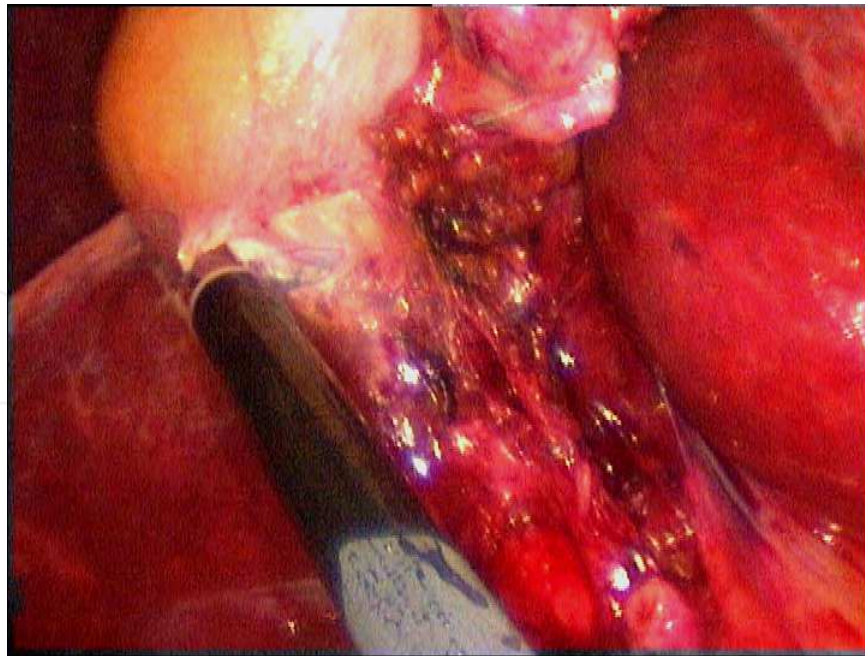


Fig. 18. Resection of the gall bladder with ultrasonic hook

After complete resection the gallbladder is put into an endobag and pulled out of the abdominal cavity together via the single port device. (Figure 19) The use of an intraabdominal drain is optional.

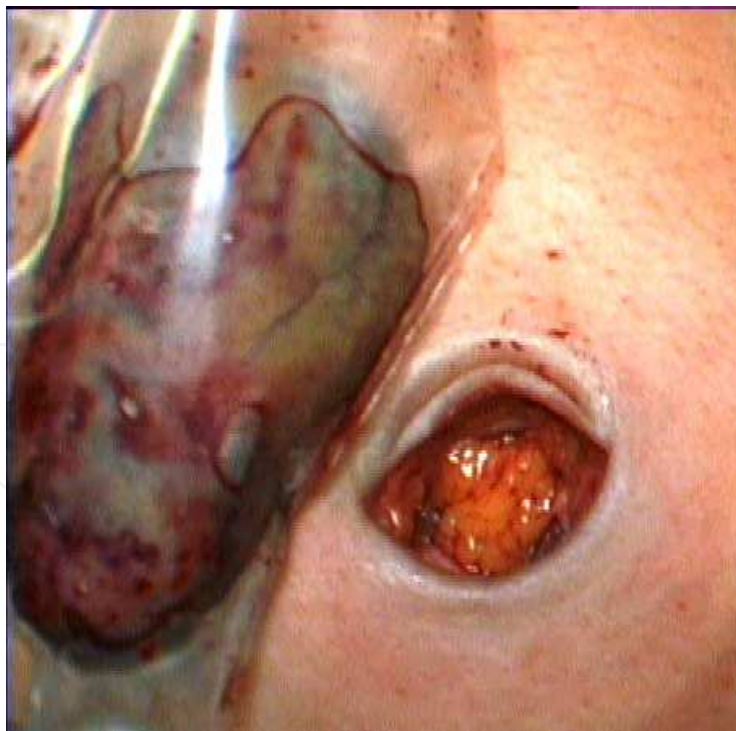


Fig. 19. Removal of the gallbladder via the single port incision

Some surgeons use extra tools like an auxiliary 3 - 5 mm trocar in the right upper abdomen or transabdominal sutures to lift the gallbladder and facilitate the single port procedure. We

prefer “pure” single port operations with only one incision to offer the patient the least traumatic access.

Previously published studies show similar good results for single port and “conventional” laparoscopic cholecystectomy.

The small incision for single port access leads to an almost invisible scar and less postoperative pain. (5, 6, 8, 9) Disadvantages of single port cholecystectomy are a prolonged operation time (plus 10 - 45 minutes), more difficult exposure of important anatomic structures and higher costs. (10, 11)

2.2.2 Single port laparoscopic unroofing of liver cysts

Several publications (e.g. 12, 13) describe the successful laparoscopic unroofing of symptomatic, non-parasitic liver cysts - especially in segments VII and VIII. The first single-port fenestration of a liver cyst was described in 2010 by Mantke et al. (14). We use the single port access as our standard operation for symptomatic liver cysts which are close to the liver surface.

The access and the instruments are similar to single port cholecystectomy. Using an optic with a flexible lens helps to expose structures on the lateral aspect of the right liver lobe. (Figures 20 and 21)

The unroofing and resection of the anterior cystic wall can be easily done with an ultrasonic hook or scissors. (Figure 22)

The resected tissue (Figure 23) is put into an endobag and removed via the single port device.

Although there are less than 5 publications up to now - mostly single case descriptions - single port technique could be a safe and feasible procedure for surgical therapy of symptomatic liver cysts in selected patients.

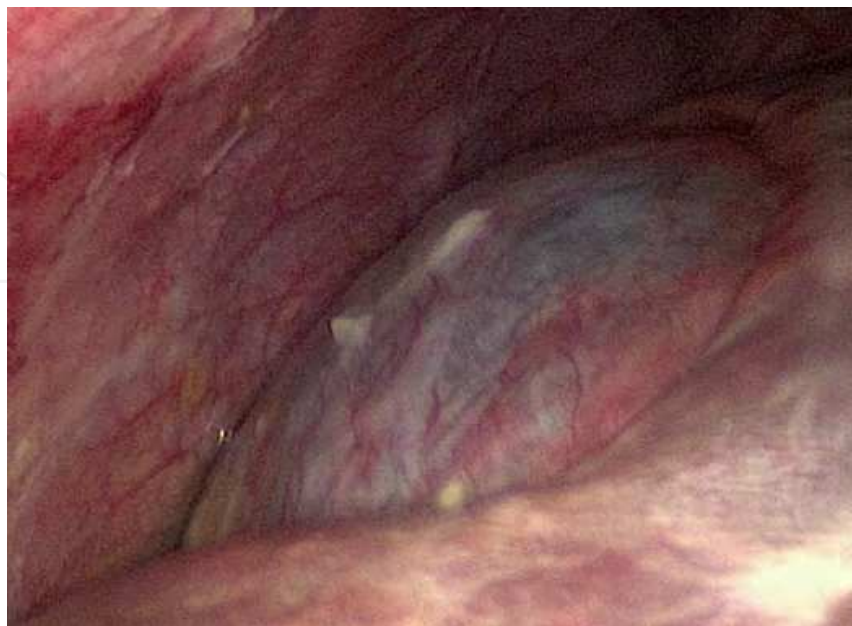

Fig. 20. Symptomatic liver cyst (segment VII): 0° view

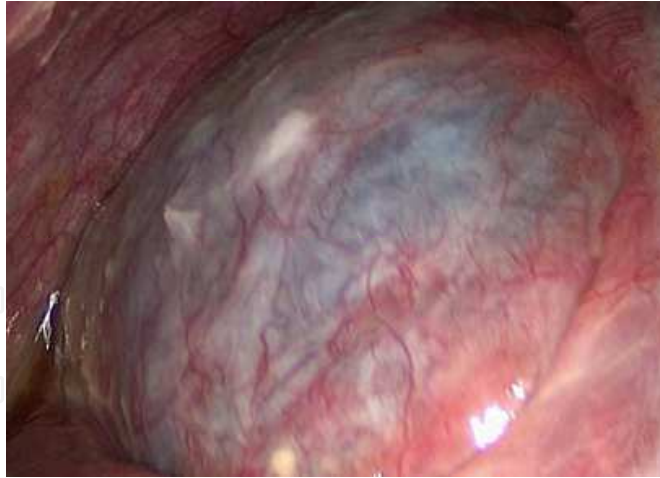

Fig. 21. Symptomatic liver cyst (segment VII): 60° view

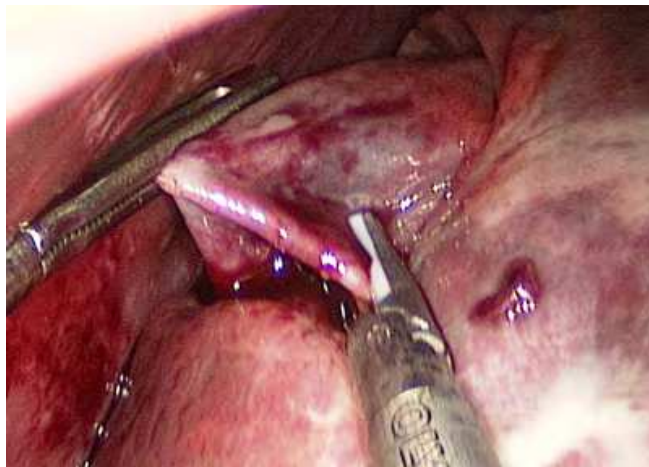


Fig. 22. Resection of a symptomatic liver cyst (segment VII)

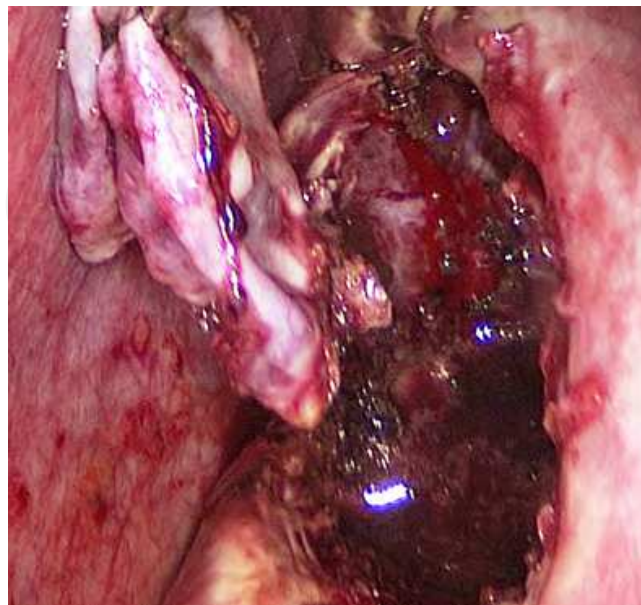


Fig. 23. Unroofed liver cyst with resected anterior wall

2.2.3 Single port colorectal operations

All kinds of colorectal operations have been successfully performed in single port technique. The spectrum reaches from “simple” colostomy to proctocolectomy and J-pouch reconstruction (15).

More than 150 single port colonic procedures are published with a monthly increasing number. The most frequent operation is – like in “conventional” laparoscopic surgery – the sigmoid resection for recurrent diverticulitis or small sigmoid cancers. The technique of preparation, dissection, resection and anastomosis does not differ from standard laparoscopic sigmoid resection. Handling and lifting of a large or elongated sigma is more difficult with a subjective feeling of a “missing hand”.

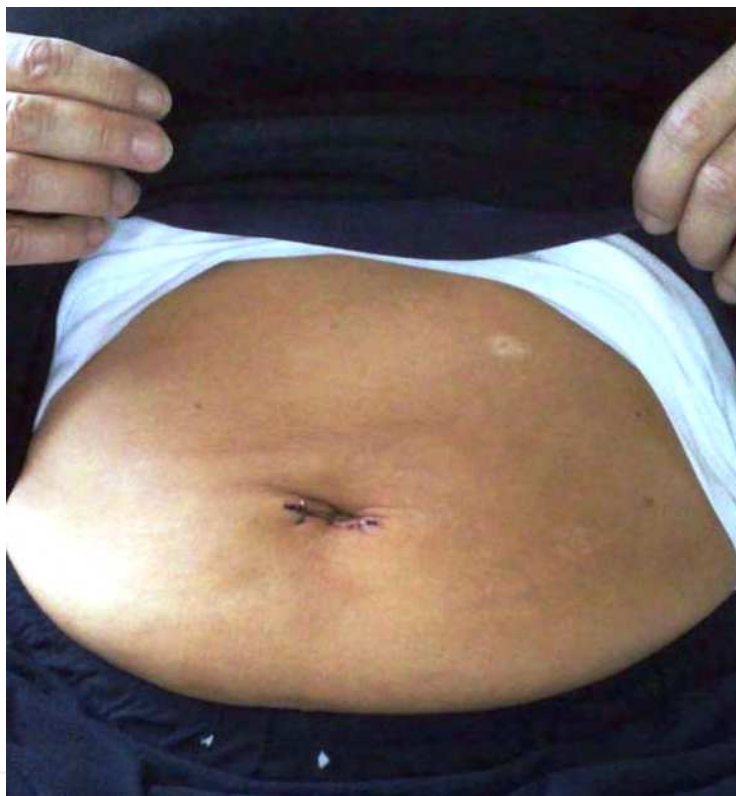

Fig. 24. 2nd day after single port laparoscopic sigmoid resection

There are no significant differences in colorectal surgery between single port or multi port access, conversion rate from single to multi port access lies between 5 – 10 %. (15, 16)

Although the umbilical incision has to be 3 – 4 or sometimes even up to 6 centimetres for the removal of the bowel, the cosmetic result and the almost painless postoperative course are impressive. (5, 15) Figure 24 shows a 56 years old female patient on 2nd day after single port laparoscopic sigmoid resection for recurrent diverticulitis.

2.2.4 Summary of clinical applications

Potential advantages and disadvantages of single port laparoscopic surgery are listed in following table 1.

Laparoscopic procedure	Effect of single port technique
Diagnostic laparoscopy	Higher costs by single-use instruments
Adhesiolysis	Limited use in case of complex adhesions
Appendectomy	Higher costs by single-use instruments
Cholecystectomy	Safe and effective, better cosmetic result, difficult in advanced inflammation
Inguinal herniotomy	Suitable for transabdominal technique difficult for extraperitoneal technique
Fundoplication	Very difficult when using intracorporeal Suturing technique
Gastric sleeve and wedge resections	Suitable when using linear staplers
Gastric bypass	Limited use by complexity of procedure
Pancreatic resections	Suitable for left resections, limitation for complex resections
Colorectal procedures	Suitable for uncomplicated resections
Splenectomy	Difficult in splenomegaly
Gynecological and urological procedures	Suitable for non-complex operations

Table 1. Clinical applications of single port laparoscopic surgery

3. Conclusion

Single port laparoscopic surgery offers the possibility to further minimize the access trauma to the abdominal wall. Recent publications and our own experience have shown that the new method is safe and efficient. For the surgeon it is technically much more demanding to perform a complex laparoscopic procedure via a single port trocar than via 3 – 5 trocars. The patient may benefit from reduced postoperative pain, better cosmetic results and a faster recovery.

A comparison between single port and “conventional” laparoscopic surgery is shown in table 2.

Actually single port laparoscopic surgery shows disadvantages concerning the limitation for complex operations and higher costs by using a single port special trocar.

As with any new technology a further development of instruments and surgical skills is necessary to overcome the limitations. With a wider spread extra costs will decrease.

To show significant advantages compared to “conventional” laparoscopic surgery, randomized studies are necessary.

	Single port laparoscopic surgery	“Conventional” laparoscopic surgery
First access	Special technique	Verres needle or open
Optic	Always via single port	Different positions possible through working trocars
Triangulation	Limited, difficult	Almost unlimited, easy
Dissection and resection	Difficult in complex operations	Easy by variable trocar positions
Handling	Difficult, feeling of “missing hand”	Easy by variable trocar positions
Suitable for complex operations	Limited use	Less limitations
Wound care	Only one incision, scar almost invisible	Several incisions
Postoperative complications	Very rare	Very rare
Cosmetic result	Very good	Good
Costs	Extra costs by single port trocar	No extra costs
Significant benefit	Not known	Not known


Table 2. Comparison between single port and “conventional” laparoscopic surgery

4. References

- [1] Mühe, E. (1992). Laparoscopic cholecystectomy follow up. *Endoscopy* 24:754-758
- [2] Navarra, G.; Pozza, E.; Occhionorelli, S. et al. (1997). One-wound laparoscopic cholecystectomy. *Br J Surg* 84:695
- [3] Marescaux, J.; Dallemagne, B.; Perretta, S. (2007). Surgery without scars: a report of transluminal cholecystectomy in a human being. *Arch Surg* 142(9):823-826
- [4] Schwenk, W.; Haase, O.; Neudecker, J.; Müller, J.M. (2005). Short term benefits for laparoscopic colorectal resection. *Cochrane Database Syst Rev*. 20(3):CD003145
- [5] Carus, T. (2010). Single-port technique in laparoscopic surgery. *Chirurg* 81:431-439
- [6] Langwieler, T.E.; Back, M. (2011). Single-port access cholecystectomy. Current status. *Chirurg* 82:406-410
- [7] McGregor, C.G.; Sodergren, M.H.; Aslanyan, A.; Wright, V.J. et al. (2011). Evaluating systemic stress response in single port vs. multi-port laparoscopic cholecystectomy. *J Gastrointest Surg*. 15(4):614-622

- [8] Hernandez, J.M.; Morton, C.A.; Ross, S. et al. (2009). Laparoendoscopic single site cholecystectomy : the first 100 patients. *Am Surg* 75(8):681-685
- [9] Langwieler, T.E.; Nimmesgern, T.; Back, M. (2009). Singleport access in laparoscopic cholecystectomy. *Surg endosc* 23(5):1138-1141
- [10] Aprea, G.; Coppola Bottazzi, E.; Guida, F.; Masone, S.; Persico, G. (2011). Laparoendoscopic single site (LESS) versus classic video-laparoscopic cholecystectomy : a randomized prospective study. *J Surg Res.* 166(2):e109-112
- [11] Ma, J.; Cassera, M.A.; Spaun, G.O.; Hammill, C.W.; Hansen, P.D.; Aliabadi-Wahle, S. (2011). Randomized controlled trial comparing single-port laparoscopic cholecystectomy and four-port laparoscopic cholecystectomy. *Ann Surg.* 254(1):22-27
- [12] Tagaya, N.; Nemoto, T.; Kubota, K. (2003). Long-term results of laparoscopic unroofing of symptomatic solitary nonparasitic hepatic cysts. *Surg Laparosc Endosc Percutan Tech.* 13(2):76-79
- [13] Weber, T.; Sendt, W.; Scheele, J. (2004). Laparoscopic unroofing of nonparasitic liver cysts within segments VII and VIII: technical considerations. *J Laparoendosc Adv Surg Tech A.* 14(1):37-42
- [14] Mantke, R.; Wicht, S. (2010). Single-port liver cyst fenestration combined with Single-port laparoscopic cholecystectomy using completely reusable instruments. *Surg Laparosc Endosc Percutan Tech* 20:28-30
- [15] Vestweber, V.; Straub, E.; Kaldowski, B. et al. (2011). Single-port colonic surgery. Techniques and indications. *Chirurg* 82:411-418
- [16] Diana, M.; Dhumane, P.; Cahill, R.A.; Mortensen, N.; Leroy, J.; Marescaux, J. (2011). Minimal invasive single-site surgery in colorectal procedures: Current state of the art. *7(1):52-60*

IntechOpen



Advances in Laparoscopic Surgery

Edited by Dr Arshad Malik

ISBN 978-953-307-933-2

Hard cover, 148 pages

Publisher InTech

Published online 01, February, 2012

Published in print edition February, 2012

Laparoscopic surgery, also called minimal access surgery, has revolutionized the field of surgery over the past few years. It has gained worldwide popularity and acceptance by surgeons and patients alike. Minimal scarring, less pain, and shorter hospital stay are the main reasons behind the global appeal of this novel technique. There has been a tremendous improvement in the technique, as well as in the instruments. The technique has passed through the stages of simple laparoscopic surgery to advanced levels, where more complicated procedures are being successfully attempted. The recent introduction of robotic surgery is also gaining popularity, in addition to single port laparoscopic surgery (SILS), which can be scarless surgery. Most of the surgical procedures, which were considered contraindication for the laparoscopic approach, have eventually become the most common and acceptable indications today. This book is intended to provide an overview of the most common procedures performed laparoscopically, as well as some recent advancements in the field.

How to reference

In order to correctly reference this scholarly work, feel free to copy and paste the following:

Carus Thomas (2012). Single Port Laparoscopic Surgery, *Advances in Laparoscopic Surgery*, Dr Arshad Malik (Ed.), ISBN: 978-953-307-933-2, InTech, Available from: <http://www.intechopen.com/books/advances-in-laparoscopic-surgery/single-port-laparoscopic-surgery>

INTECH
open science | open minds

InTech Europe

University Campus STeP Ri
Slavka Krautzeka 83/A
51000 Rijeka, Croatia
Phone: +385 (51) 770 447
Fax: +385 (51) 686 166
www.intechopen.com

InTech China

Unit 405, Office Block, Hotel Equatorial Shanghai
No.65, Yan An Road (West), Shanghai, 200040, China
中国上海市延安西路65号上海国际贵都大饭店办公楼405单元
Phone: +86-21-62489820
Fax: +86-21-62489821

© 2012 The Author(s). Licensee IntechOpen. This is an open access article distributed under the terms of the [Creative Commons Attribution 3.0 License](#), which permits unrestricted use, distribution, and reproduction in any medium, provided the original work is properly cited.

IntechOpen

IntechOpen