

We are IntechOpen, the world's leading publisher of Open Access books Built by scientists, for scientists

4,800

Open access books available

122,000

International authors and editors

135M

Downloads

Our authors are among the

154

Countries delivered to

TOP 1%

most cited scientists

12.2%

Contributors from top 500 universities

**WEB OF SCIENCE™**Selection of our books indexed in the Book Citation Index
in Web of Science™ Core Collection (BKCI)

Interested in publishing with us? Contact book.department@intechopen.com

Numbers displayed above are based on latest data collected.

For more information visit www.intechopen.com

Laparoscopy in Trauma Patients

Cino Bendinelli¹ and Zsolt J. Balogh^{1,2}

¹John Hunter Hospital, Newcastle, NSW,

²University of Newcastle, NSW,
Australia

1. Introduction

The burden of major trauma, predominantly blunt in nature, continues to rise in most countries. More often the young are affected with lifelong debilitating consequences. Minimally invasive techniques, such as laparoscopic procedures, have become standard for the treatment of many surgical conditions, being able to minimize the impact of surgery, to reduce postoperative pain, time in hospital, time to recover, and to improve cosmetic outcomes.

The use of laparoscopy as an aid in the diagnosis of abdominal trauma was first described in 1977 (Simon, Gazzaniga, Carnevale). In 1988 Cuschieri compared diagnostic peritoneal lavage with a laparoscopy (using a 4-mm scope) in blunt abdominal trauma patients demonstrating that laparoscopy carried a higher positive predictive value when compared to diagnostic peritoneal lavage (Cuschieri). Since then, the use of laparoscopy in abdominal trauma has increased exponentially. In trauma patients laparoscopy may avoid unnecessary (non-therapeutic) laparotomy, may improve operative visualisation of diaphragm, and may allow laparoscopic repair of these injuries.

Despite these clear potentialities, laparoscopy has not yet gained wide acceptance and it is not consistently performed in trauma patients. There are several reasons for this.

1. In bleeding, or potentially bleeding patients, timing is of essence. The logistics for laparoscopy set up of theatre still takes longer than for open surgery. Once the operation has started it takes longer to gain access, identify the bleeder and, especially, control it when compared to a trauma laparotomy.
2. In haemodynamically normal patients with spleen injuries a diagnostic laparoscopy may increase the splenectomy rate.
3. The risk of missing injuries (hollow viscus mainly) is high. A literature review reports a 41% to 77% rate of missed injuries when used as a diagnostic tool to perform abdominal exploration (Villavicencio). This is very much operator dependent, but it may carry disastrous outcomes.
4. Logistics wise most trauma happens at night when staff may be less motivated to embark in a time consuming procedure.

2. Indication

In trauma patients laparoscopy maybe used either as a diagnostic or as a therapeutic tool. Both are generally indicated only for patients with normal hemodynamics and in which major bleeding is not expected.

3. Diagnostic laparoscopy

Exploratory laparotomy in either blunt or penetrating abdominal trauma patients with suspected intra-abdominal injuries is associated with a high negative (non-therapeutic) laparotomy rate and a high procedure-related morbidity (41% according to Renz). Diagnostic laparoscopy in trauma patients is reported to spare a median of 57% (range, 17–89%) of non-therapeutic laparotomy (Stefanidis). Depending on centres, indications for diagnostic laparoscopy varies widely including suspected intraabdominal injury after blunt trauma, abdominal stab wounds with proven or equivocal penetration of fascia, abdominal gunshot wounds with doubtful intraperitoneal trajectory, diagnosis of diaphragmatic injury from penetrating trauma to the thoracoabdominal area, and creation of a transdiaphragmatic pericardial window to rule out cardiac injury. The sensitivity, specificity, and diagnostic accuracy of diagnostic laparoscopy when used to predict the need for laparotomy range from 75 to 100% (Hori). When diagnostic laparoscopy has been used as a screening tool (conversion to laparotomy with the first encounter of a positive finding: peritoneal penetration in penetrating trauma or free blood in blunt trauma patients), the number of missed injuries is <1% (Hori). For penetrating trauma a sensitivity of 80–100%, specificity of 38–86%, and accuracy of 54–89% have been consistently reported (Villavicnezio, Leppaniemi).

Most trauma centres include diagnostic laparoscopy in the algorithm for management of patients with penetrating thoraco-abdominal trauma (Fig 1) (Biffl, Sugrue, Zantut, Lin, Mallat, Fabian). Patients without signs of shock, evisceration, or peritonitis undergo a “screening laparoscopy” to identify peritoneal or diaphragmatic penetration. In this setting screening laparoscopy is a better tool compared to local wound exploration (especially in large body habitus, uncooperative patient and thoraco abdominal injuries). Diaphragmatic injuries occur in up to 20% of patients with penetrating thoracoabdominal trauma (Friese, Powel). These are often undetected, remain clinically silent, only to present later with life-threatening complications associated with diaphragmatic herniation. Diagnostic laparoscopy is not useful in posterior abdominal wall penetration to rule out retroperitoneal injuries.

An extension of diagnostic laparoscopy includes laparoscopic pericardial window for exclusion of cardiac injury in patients with thoracoabdominal penetrating wounds, normal hemodynamic status and free pericardial fluid at ultrasound. The pericardial membrane needs to be incised with endoshears and electrocautery must not be used to prevent possible dysrhythmia or myocardial damage (McMahon).

Following blunt abdominal trauma hemodynamic instability and a positive FAST (Focused Abdominal Sonography in Trauma) or Diagnostic Peritoneal Aspiration mandates immediate midline laparotomy. Laparoscopy may play a role in patients with blunt abdominal trauma, who are not bleeding, but have unclear findings on CT (bowel

wall thickening, stranding of the mesentery, dilated bowel loops, extraluminal retroperitoneal air and/or free fluid without solid organ injury) and the patient's clinical status is only suspicious or not assessable (comatose patients). In this subgroup of patients delay in diagnosis occurs in up to 5% of cases and contributes to increased morbidity from 10 to 30% (Mathonet). Laparoscopy for blunt trauma reported a sensitivity of 90–100%, specificity of 86–100%, and accuracy of 88–100% for bowel injuries (Villavicencio and Aucar)

Findings of FAST can be categorised into three groups: those without injuries, those with injuries who do not require surgical treatment, and those who require repair which may be accomplished laparoscopically depending on the laparoscopic skills of the surgeon.

4. Therapeutic laparoscopy

The guidelines for diagnostic laparoscopy, published by the Society of American Gastrointestinal and Endoscopic Surgeons, stated that diagnostic laparoscopy is contraindicated when there is obvious intra-abdominal injury or peritonitis (Hori).

Many AA have challenged this and, over the last 20 years, sporadic groups, with a specific interest in laparoscopy, have first demonstrated FAST to be a safe and consistent diagnostic tool in both blunt and penetrating trauma and then proved therapeutic laparoscopy to be safe in repairing the encountered injuries.

Laparoscopic repairs of injuries to virtually every organ have been described. Injuries to diaphragm (Simon), parenchymal organs and gastro-intestinal tract (Cherkasov, Lin) have been successfully repaired laparoscopically. Large case series exist from institutions that provide full definitive laparoscopic management of any injuries (also in shocked and actively bleeding patients) with no or minimal missed injuries and dismal conversion rate (Cherkasov, Lin).

Actively bleeding spleen injuries may be treated laparoscopically. Patients who continue to bleed following embolization or with high grade spleen injuries are treated with laparoscopic application of collagen–fibrinogen human thrombin seal on oozing lacerations and if a major bleeding is encountered laparoscopic splenectomy is then performed (Olm, Marzano).

Non-operative management of hepatic and splenic injuries is successful in up to 80% of instances. Many of these patients (up to 75% in high grade injuries) will demonstrate signs of inflammatory response due to the haemoperitoneum (fever, leukocytosis, discomfort, and tachycardia) (Letoublon). The use of laparoscopy to remove the old blood from the peritoneal cavity maybe accomplished safely and maybe beneficial (Carillo). During the procedure the solid organs and the clots on their surface are left alone to avoid any potential haemorrhage. Bilioma and biliary peritonitis due to bile duct injuries may also be treated with collagen–fibrinogen human thrombin seal and/or drained laparoscopically. (Carillo Sugrue, Marzano).

Small lacerations of stomach, duodenum, small bowel, and colon can be repaired laparoscopically. When an anastomosis or a long repair is required these are usually performed extracorporeally through a small focused celiotomy (Hope Streck, Ianelli).

5. Contraindication

Although some centres have questioned it (Cherkasov) haemodynamic instability is currently the absolute contraindication for laparoscopy. The main reason for this is that bleeding identification and control cannot be performed rapidly by laparoscopic means (Ball, Hori).

Concomitant severe traumatic brain injury should also exclude laparoscopy. Some animal models (Goetler), case reports (Mobbs), and extrapolation from series of patients with abdominal compartment syndrome suggest that intracerebral pressure maybe increased by high abdominal pressures (Joseph).

Contraindications such as previous abdominal scars are relative, as optical port can create a safe access, but if intraabdominal adhesions prevent full and confident exploration the procedure should be converted.

Tension pneumothorax is always a possible complication when a diaphragmatic injury allows CO₂ to fill the pleural cavity. As discussed above, this is diagnosed earlier when using low flow rate for induction of pneumoperitoneum and best treated with prompt chest drain insertion. A chest drain should always be available during the procedure (Ball).

One of the most important contraindication will always be lack of inadequate laparoscopic skills. A screening laparoscopy to rule out peritoneal violation is an easy task, full abdominal exploration is a time consuming challenging procedure, and laparoscopic repair of bowel an advanced laparoscopic skill.

6. Technique

Positioning and preparation of the patient for trauma laparoscopy is essentially the same as for any trauma laparotomy. The theatre is warm and instruments for a conversion to laparotomy or access to the thorax should readily available. The patient is placed supine on a beanbag and well strapped. Bed tilting is crucial to allow gravity to retract abdominal organs and to increase working space. Pneumoperitoneum is achieved with low CO₂ flow and maintained at low pressures (8–12 mmHg). Low flow rate allows timely detection of a tension pneumothorax (increased ventilatory pressures and/or hypotension). Should this occur the pneumoperitoneum is immediately released and a size 32Fr chest drain is inserted on the most likely side. The procedure is then carried out open (Fabian).

Diagnositc laparoscopy is achieved trough a 10mm umbilical port best inserted with an open technique. A 30degree laparoscope (5-10mm in diameter) allows optimal visualization of abdominal wall, diaphragms and liver/spleen dome. Tilting the bed in Trendelenburg position or reverse Trendelenburg position allows visualization of lower and upper abdomen. For paracolic gutters exploration lateral tilting is required. In the case of penetrating wounds, air leaks trough the skin may need to be controlled with sutures or external digital pressure. In most cases visceral handling is necessary and easily carried out with 5mm atraumatic bowel graspers through two paramedian 5mm ports placed on the umbilical line. A 5mm laparoscope (which carries less light and may be inadequate in bloody fields) allows liberal interchange of the instruments between the ports. Peritoneal violation can be determined easily and reliably.

Performing a full laparoscopic exploration of the abdominal cavity in search for injuries requires a systematic approach which follows all principles of open exploratory laparotomy (Kawahara). Indirect signs of bowel injury, such as digestive fluids or purulent liquids must be carefully looked for. Methylene blue administered IV or via the nasogastric tube may help to identify urologic or proximal bowel injuries. Some AA advocate laparoscopic assisted diagnostic peritoneal lavage to rule out bowel injuries through absence of alkaline phosphatase, bile or fibers in the lavage. This concept may add to diagnostic laparoscopy sensitivity in excluding gut injuries and make most trauma surgeon more confident in adopting it.

The bowel requires to be examined using the hand-over-hand technique with small bowel graspers from the ligament of Treitz to the terminal ileum. The colon is inspected from the cecum to the rectum and the supramesocolic space is inspected from the abdominal esophagus to the duodenum including spleen, liver and gallbladder. A laparoscopic full Kocher manoeuvre is accomplished in right lateral decubitus, the hepatic flexure of the colon is mobilized to the left side using the harmonic scalpel. The peritoneum is incised lateral to duodenum and blunt dissection mobilizes the duodenum medially in order to explore its dorsal aspect (Gorecki, Cherkasov, Kawahara, Lin).

For therapeutic laparoscopy more ports are usually necessary and usually titrated based on the surgical procedure required and the size of the patient. Extensive laparoscopic expertise is mandatory, to be able to treat patients with intestinal perforations. Laparoscopic suturing of bowel injuries is carried out with either silk or Vycril suture (Hope, Tytgal). An extra port may be necessary to achieve lining up of the bowel. If possible the bowel should be inflated and the suture line submerged in saline to rule out air leaks. Diaphragm repairs are best achieved with braided non absorbable sutures and large needles.

For splenectomy 4 ports are necessary: one 10-mm umbilical port, two 5-mm ports at left subcostal margin (for retraction and irrigation purposes); a 12-mm port below the left subcostal margin at mid-clavicular line. Right lateral tilting of the bed and reverse Trendelenberg allow suspending the spleen for optimal laparoscopic visualization. Subcapsular hematomas and coagulum are not disturbed to minimize bleeding. Using the harmonic scalpel (or Ligasure) the splenocolic ligament is first taken down from the lower pole of the spleen. The gastrosplenic ligament with short gastrics is then divided with harmonic scalpel (or Ligasure). The splenic hilum is secured and divided with several applications of a 35-mm linear endovascular stapling device. Prompt conversion may be necessary if massive bleeding is encountered. Hand assistance, with a hand port in order to control the hilar blood vessels (Ren) may be handy! This is particularly true when active bleeding is obscuring the field or when the endovascular stapling device fails.

Hand assistance can be performed readily and should be considered a potential adjunct to minimally invasive surgical procedure.

Conversion to celiotomy is mandated when visceral exploration is not adequate (obesity or tenacious postoperative adhesences), or when hemodynamic instability arises during laparoscopy. Although laparoscopy does offer potential benefits, the trauma surgeon should

never let the lure of a “minimally invasive” procedure compromise patient care or the use of sound clinical judgment.

7. Sequale of trauma

Laparoscopy is a well validated technique to repair abdominal wall and diaphragmatic defects, which may follow blunt or penetrating trauma. These procedures are less controversial and considered safer mainly because they are carried out as elective procedures, with a clear plan in terms of ports placement and methods of repair. There is usually no need to explore the abdomen in search for other injuries. Diaphragmatic defects are best repaired with direct suture. When the defect is too large an expanded polytetrafluoroethylene or double layered prosthesis is utilized (Matz, Baldassarre). The mesh is secured with a combination of endoscopic tacks and laparoscopic suturing (Bobbio). Endoscopic tacks should not be used on the diaphragm, due to the risks of lung and heart injury (Bendinelli).

8. Future

The future holds exciting advances for this field of surgery through innovative developments. All AA agree that an improvement in instrumentation is still required. In the near future laparoscopic management of abdominal trauma will play a greater role in the treatment of haemodynamically stable patients and might one day be a reasonable option for unstable patients.

Further research needs to analyse outcome measures of laparoscopic techniques in comparison to traditional laparotomy. The beneficial effect of laparoscopic treatment of injuries should be investigated further before the widespread adoption of this approach.

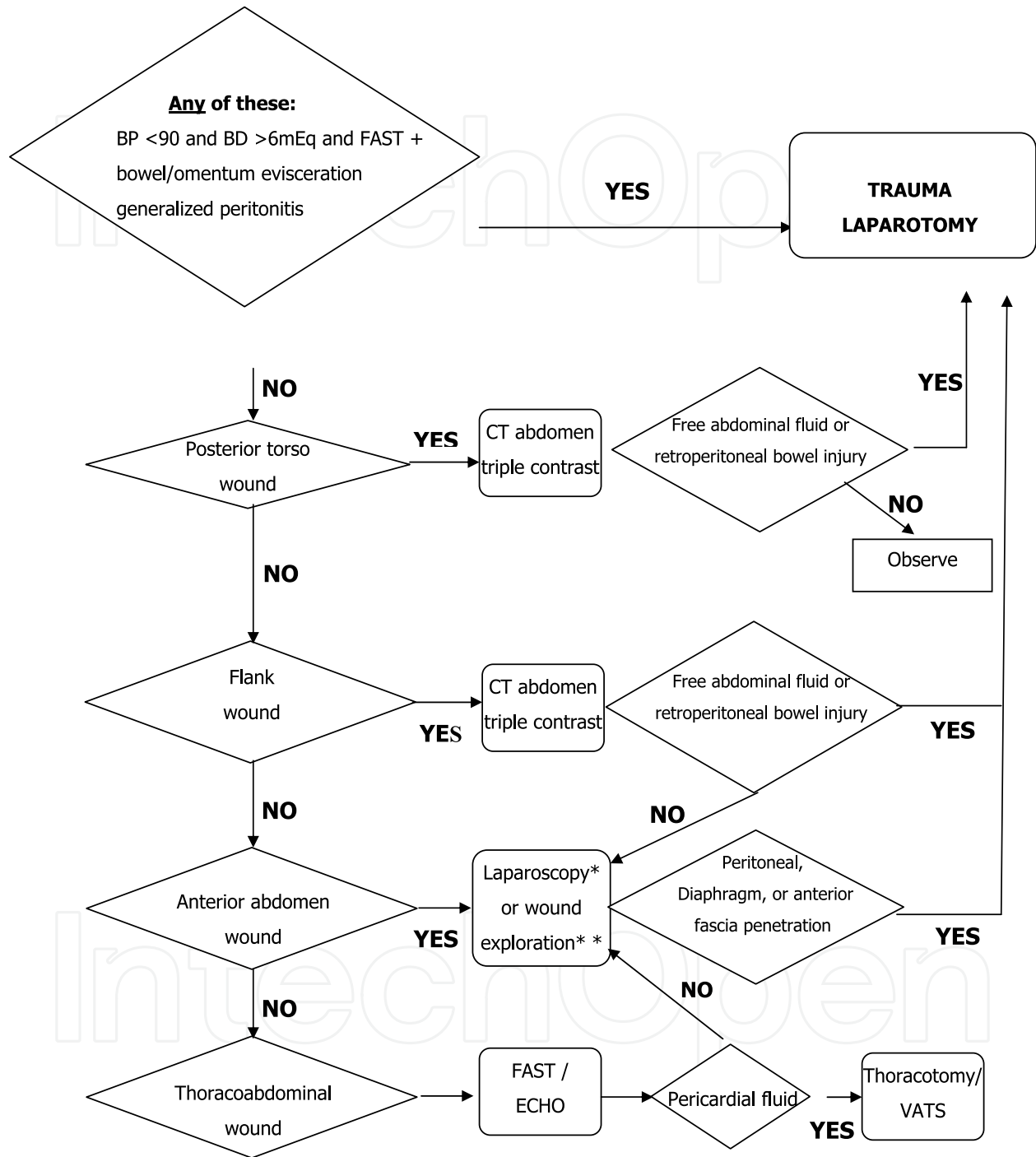
The main concern will always be missed injuries. To minimize the risk of missing bowel injuries it might be worth to combine explorative laparoscopy with laparoscopic lavage using the standard laboratory criteria (Otomo). This concept, which is definitely intriguing although logistically demanding, warrants further evaluation (Vinces).

The learning curve typical of any procedure (especially laparoscopic ones) will have to be better understood. Adequate training and support to Trauma Surgeon should be provided by dedicated laparoscopists both in Operating Theatre and in *ad hoc* courses.

With the current obese pandemia laparoscopy may be even more beneficial, as many penetrating injuries do not reach the abdominal cavity or if they do organs may be more protected by thick omentum. This must be compared to the higher morbidity rate of a full midline laparotomy in obese patients.

Screening laparoscopy for penetrating abdominal trauma using only local anaesthetics can be performed in the Emergency Department in awake patients (Weinberg). Laparoscopy may become a triage tool in Emergency Department (discharge versus laparotomy) and would be of great value in busy metropolitan Trauma Centres.

Laparoscopy typically minimizes the insult of surgery and may also play a role in reducing the incidence of Systemic inflammatory response syndrome (SIRS) often seen in multiple injured trauma patients.



*Wound exploration is recommended only in thin and cooperative patients.


Fig. 1. Institutional guidelines for penetrating torso trauma

9. References

- Baldassarre E, Valenti G, Gambino M, Arturi A, Torino G, Porta IP, Barone M. The role of laparoscopy in the diagnosis and the treatment of missed diaphragmatic hernia after penetrating trauma. *J Laparoendosc Adv Surg Tech A*. 2007;17:302-6.
- Ball CG, Kirkpatrick AW. Intra-abdominal hypertension and the abdominal compartment syndrome. *Scand J Surg* 2007;96:197-204.
- Bendinelli C, Martin A, Balogh ZJ. Strangulated intercostal liver herniation subsequent to blunt trauma. First report with review of the world literature. Staged management and laparoscopic repair. *ANZJS*: 2012 (in press).
- Biffi WL, Moore EE. Management guidelines for penetrating abdominal trauma. *Curr Opin Crit Care*. 2010 Sep (in press)
- Bobbio, L. Ampollini, G. Prinzi, et al. Endoscopic Repair of an Abdominal Intercostal Hernia. *Surg Laparosc Endosc Percutan Tech* 2008; 18:523-525.
- Carnevale N, Baron N, Delaney HM. Peritoneoscopy as an aid in the diagnosis of abdominal trauma: a preliminary report. *J Trauma* 1977; 17:634-41.
- Carobbi A, Romagnani F, Antonelli G, Bianchini M. Laparoscopic splenectomy for severe blunt trauma: initial experience of ten consecutive cases with a fast hemostatic technique. *Surg Endosc*. 2010;24:1325-30.
- Carrillo EH, Reed DN Jr, Gordon L, Spain DA, Richardson JD. Delayed laparoscopy facilitates the management of biliary peritonitis in patients with complex liver injuries. *Surg Endosc* 2001, 15:319-22.
- Cherkasov M, Sitnikov V, Sarkisyan B, Degtirev O, Turbin M, Yakuba A. Laparoscopy versus laparotomy in management of abdominal trauma. *Surg Endosc*. 2008;22:228-31
- Como JJ, Bokhari F, Chiu WC, Duane TM, Holevar MR, Tandoh MA, Ivatury RR, Scalea TM. Practice management guidelines for selective nonoperative management of penetrating abdominal trauma. *J Trauma*. 2010;68:721-33.
- Cui H, Luckerth P, Peralta R. Laparoscopic management of penetrating liver trauma: a safe intervention for hemostasis. *J Laparoendosc Adv Surg Tech A*. 2007;17:219 -222.
- Cuschieri A, Hennessy TP, Stephens RB, Berci G. Diagnosis of significant abdominal trauma after road traffic accidents: preliminary results of a multicentre clinical trial comparing minilaparoscopy with peritoneal lavage. *Ann R Coll Surg Engl*. 1988;70:153-5.
- Degiannis E, Bowley DM, Smith MD. Minimally invasive surgery in trauma: technology looking for an application. *Injury* 2004;35:474-8.
- Fabian TC, Croce MA, Stewart RM, Pritchard FE, Minard G, Kudsk KA. A prospective analysis of diagnostic laparoscopy in trauma. *Ann Surg*. 1993;217:557-65.
- Feliz A, Shultz B, McKenna C, Gaines BA. Diagnostic and therapeutic laparoscopy in pediatric abdominal trauma. *J Pediatr Surg* 2006;41:72-7.
- Friese RS, Coln CE, Gentilello LM. Laparoscopy is sufficient to exclude occult diaphragm injury after penetrating abdominal trauma. *J Trauma*. 2005;58:789-92.
- Gaines BA, Rutkoski JD. The role of laparoscopy in pediatric trauma. *Semin Pediatr Surg*. 2010;19:300-3.
- Gazzaniga AB, Slanton WEW, Bartlett RH. Laparoscopy in the diagnosis of blunt and penetrating injuries to the abdomen. *Am J Surg* 1976; 131:315-18.
- Goettler CE, Bard MR, Toschlog EA. Laparoscopy in trauma. *Curr Surg* 2004;61:554-9.

- Gorecki PJ, Cottam D, Angus LDG, et al. Diagnostic and therapeutic laparoscopy for trauma: a technique of safe and systematic exploration. *Surg Laparosc Endosc Percutan Tech* 2002;12:195-8.
- Hope WW, Christmas AB, Dg Jacobs, RF Sing. Definitive laparoscopic repair of penetrating injuries to the colon and small intestine: A Case Report. *J Trauma*. 2009;66:931-932.
- Hori Y; SAGES Guidelines Committee. Diagnostic laparoscopy guidelines : This guideline was prepared by the SAGES Guidelines Committee and reviewed and approved by the Board of Governors of the Society of American Gastrointestinal and Endoscopic Surgeons (SAGES), November 2007. *Surg Endosc*. 2008;22:1353-83.
- Huscher CGS, Mingoli A, Sgarzini G, Brachini G, Ponzano C, Di Paola M, Mondini C. Laparoscopic treatment of blunt splenic injuries: initial experience with 11 patients. *Surg Endosc* 2006;20:1423-1426.
- Iannelli A, Fabiani P, Karimjee BS, Baque P, Venissac N, Gugenheim J. Therapeutic laparoscopy for blunt abdominal trauma with bowel injuries. *J Laparoendosc Adv Surg Tech A*. 2003;13:189-191.
- Joseph DK, Dutton RP, Aarabi B, Scalea TM. Decompressive laparotomy to treat intractable intracranial hypertension after traumatic brain injury. *J Trauma*. 2004; 57:687-95.
- Kawahara NT, Alster C, Fujimura I, Poggetti RS, Birolini D. Standard examination system for laparoscopy in penetrating abdominal trauma. *J Trauma*. 2009;67:3:589-95.
- Leppaniemi A, Haapiainen R. Diagnostic laparoscopy in abdominal stab wounds: a prospective, randomized study. *J Trauma* 2003; 54):636-45.
- Letoublon C, Chen Y, Arvieux C, Voirin D, Morra I, Broux C, Risse O. Delayed celiotomy or laparoscopy as part of the nonoperative management of blunt hepatic trauma. *World J Surg*. 2008;32:1189-93.
- Lin HF, Wu JM, Tu CC, Chen HA, Shih HC. Value of diagnostic and therapeutic laparoscopy for abdominal stab wounds. *World J Surg*. 2010;34:1653-62.
- Livingston DH, Lavery RF, Passannante MR, Skurnick JH, Baker S, Fabian TC, Fry DE, Malangoni MA. Free fluid on abdominal computed tomography without solid organ injury after blunt abdominal injury does not mandate celiotomy. *Am J Surg* 2001; 182: 6-9.
- Mallat AF, Mancini ML, Daley BJ, Enderson BL. The role of laparoscopy in trauma: a ten-year review of diagnosis and therapeutics. *Am Surg*. 2008;74:1166-70.
- Marks JM, Youngelman DF, Berk T. Cost analysis of diagnostic laparoscopy vs laparotomy in the evaluation of penetrating abdominal trauma. *Surg Endosc*. 1997;11:272-6.
- Marzano E, Rosso E, Oussoultzoglou E, Collange O, Bachellier P, Pessaux P. Laparoscopic treatment of biliary peritonitis following nonoperative management of blunt liver trauma. *World Journal of Emergency Surgery* 2010, 5:26.
- Matz A, Landau O, Alis M, Charuzi I, Kyzer S. The role of laparoscopy in the diagnosis and treatment of missed diaphragmatic rupture. *Surg Endosc*. 2000;14:537-9.
- McMahon DJ, Sing RF, Hoff WS, Schwab CW. Laparoscopic transdiaphragmatic diagnostic pericardial window in the hemodynamically stable patient with penetrating chest trauma. A brief report. *Surg Endosc*. 1997;11:474-5.
- Mobbs RJ, Ow Yang M. The dangers of diagnostic laparoscopy in the head injured patient. *J Clin Neurosci* 2002;9:592-3.
- Nasr WI, Collins CL, Kelly JJ. Feasibility of laparoscopic splenectomy in stable blunt trauma: a case series. *J Trauma*. 2004; 57:887- 889.

- Olmi S, Scaini A, Erba L, Bertolini A, Guaglio M, Croce E. Use of fibrin glue (Tissucol) as a hemostatic in laparoscopic conservative treatment of spleen trauma. *Surg Endosc.* 2007;21:2051-4.
- Otomo Y, Henmi H, Mashiko K, Kato K, Koike K, Koido Y, Kimura A, Honma M, Inoue J, Yamamoto Y. New diagnostic peritoneal lavage criteria for diagnosis of intestinal injury. *J Trauma* 1998;44: 131-139.
- Powell BS, Magnotti LJ, Schroepel TJ, Finnell CW, Savage SA, Fischer PE, Fabian TC, Croce MA. Diagnostic laparoscopy for the evaluation of occult diaphragmatic injury following penetrating thoracoabdominal trauma. *Injury.* 2008;39:530-4.
- Pucci E, Brody F, Zemon H, Ponsky T, Venbrux A. Laparoscopic splenectomy for delayed splenic rupture after embolization. *J Trauma* 2007;63:687-690.
- Renz BM, Feliciano DV. Unnecessary laparotomies for trauma: a prospective study of morbidity. *J Trauma* 1995;38:350-6.
- Simon RJ, Rabin J, Kuhls D. Impact of increased use of laparoscopy on negative laparotomy rates after penetrating trauma. *J Trauma.* 2002;53:297-302.
- Sitnikov V, Yakubu A, Sarkisyan V, Turbin M. The role of video-assisted laparoscopy in management of patients with small bowel injuries in abdominal trauma. *Surg Endosc.* 2009;23:125-9.
- Stefanidis D, Richardson WS, Chang L, Earle DB, Fanelli RD. The role of diagnostic laparoscopy for acute abdominal conditions: an evidence-based review. *Surg Endosc.* 2009;23:16-23.
- Streck CJ, Lobe TE, Pietsch JB, Lovvorn HN III. Laparoscopic repair of traumatic bowel injury in children. *J Pediatr Surg.* 2006;41:1864-1869.
- Sugrue M, Balogh Z, Lynch J, Bardsley J, Sisson G, Weigelt J. Guidelines for the management of haemodynamically stable patients with stab wounds to the anterior abdomen. *ANZ J Surg.* 2007;77:614-20.
- Tytgat SH, Zwaveling S, Kramer WL, van der Zee DC. Laparoscopic treatment of gastric and duodenal perforation in children after blunt abdominal trauma. *Injury.* 2010 Dec (in press)
- Uranüs S, Dorr K. Laparoscopy in Abdominal Trauma. *Eur J Trauma Emerg Surg* 2010; 1.
- Villavicencio RT, Aucar JA. Analysis of laparoscopy in trauma. *J Am Coll Surg.* 1999;189:11-20.
- Vinces FY, Madlinger RV. Laparoscopic exploration and lavage in penetrating abdominal stab wounds: a preliminary report. *Ulus Travma Acil Cerrahi Derg.* 2009;15:109-12.
- Weinberg JA, Magnotti LJ, Edwards NM, Claridge JA, Minard G, Fabian TC, Croce MA. "Awake" laparoscopy for the evaluation of equivocal penetrating abdominal wounds. *Injury.* 2007;38:60-4.
- Zantut LF, Ivatury RR, Smith RS, Kawahara NT, Porter JM, Fry WR, Poggetti R, Birolini D, Organ CH Jr. Diagnostic and therapeutic laparoscopy for penetrating abdominal trauma: a multicenter experience. *J Trauma.* 1997;42:825-31.



Advances in Laparoscopic Surgery

Edited by Dr Arshad Malik

ISBN 978-953-307-933-2

Hard cover, 148 pages

Publisher InTech

Published online 01, February, 2012

Published in print edition February, 2012

Laparoscopic surgery, also called minimal access surgery, has revolutionized the field of surgery over the past few years. It has gained worldwide popularity and acceptance by surgeons and patients alike. Minimal scarring, less pain, and shorter hospital stay are the main reasons behind the global appeal of this novel technique. There has been a tremendous improvement in the technique, as well as in the instruments. The technique has passed through the stages of simple laparoscopic surgery to advanced levels, where more complicated procedures are being successfully attempted. The recent introduction of robotic surgery is also gaining popularity, in addition to single port laparoscopic surgery (SILS), which can be scarless surgery. Most of the surgical procedures, which were considered contraindication for the laparoscopic approach, have eventually become the most common and acceptable indications today. This book is intended to provide an overview of the most common procedures performed laparoscopically, as well as some recent advancements in the field.

How to reference

In order to correctly reference this scholarly work, feel free to copy and paste the following:

Cino Bendinelli and Zsolt J. Balogh (2012). Laparoscopy in Trauma Patients, *Advances in Laparoscopic Surgery*, Dr Arshad Malik (Ed.), ISBN: 978-953-307-933-2, InTech, Available from:
<http://www.intechopen.com/books/advances-in-laparoscopic-surgery/laparoscopy-in-trauma-patients>

INTECH
open science | open minds

InTech Europe

University Campus STeP Ri
Slavka Krautzeka 83/A
51000 Rijeka, Croatia
Phone: +385 (51) 770 447
Fax: +385 (51) 686 166
www.intechopen.com

InTech China

Unit 405, Office Block, Hotel Equatorial Shanghai
No.65, Yan An Road (West), Shanghai, 200040, China
中国上海市延安西路65号上海国际贵都大饭店办公楼405单元
Phone: +86-21-62489820
Fax: +86-21-62489821

© 2012 The Author(s). Licensee IntechOpen. This is an open access article distributed under the terms of the [Creative Commons Attribution 3.0 License](#), which permits unrestricted use, distribution, and reproduction in any medium, provided the original work is properly cited.

IntechOpen

IntechOpen