

We are IntechOpen, the world's leading publisher of Open Access books Built by scientists, for scientists

4,800

Open access books available

122,000

International authors and editors

135M

Downloads

Our authors are among the

154

Countries delivered to

TOP 1%

most cited scientists

12.2%

Contributors from top 500 universities



WEB OF SCIENCE™

Selection of our books indexed in the Book Citation Index
in Web of Science™ Core Collection (BKCI)

Interested in publishing with us?
Contact book.department@intechopen.com

Numbers displayed above are based on latest data collected.

For more information visit www.intechopen.com



Torsades de Pointes Associated with Takotsubo Cardiomyopathy: Is It Preventable?

Dan Justo, Arie Steinvil and Itzhak Shapira

*Departments of Geriatrics and Cardiology, Tel-Aviv Sourasky Medical Center,
Affiliated to Sackler School of Medicine, Tel-Aviv University, Tel-Aviv,
Israel*

1. Introduction

Takotsubo cardiomyopathy is characterized by transient left ventricular systolic dysfunction and apical dyskinesia (ballooning) in the absence of significant obstructive coronary artery disease. Most patients with Takotsubo cardiomyopathy are females. An emotional stress is believed to be the main trigger of Takotsubo cardiomyopathy (Bybee & Prasad, 2008). Electrocardiographic features of Takotsubo cardiomyopathy might include: ST elevation, T wave inversion, and QT interval prolongation (Thakar et al., 2011).

QT interval prolongation might precede Torsades de Pointes - a potentially deadly polymorphic ventricular tachycardia. Female gender, left ventricular systolic dysfunction, recent conversion of atrial fibrillation to sinus rhythm, administering QT interval prolonging agents, hypokalemia, hypocalcemia, severe hypomagnesemia, and high-degree atrioventricular block, are all risk factors for acquired QT interval prolongation and Torsades de Pointes (Antzelevitch, 2007; Roden, 2004).

The incidence of QT interval prolongation among patient with Takotsubo cardiomyopathy is higher than 50% (Abe et al., 2003; Cangella et al., 2007; Fang et al., 2008; Wittstein et al., 2005), but the incidence Takotsubo cardiomyopathy-associated Torsades de Pointes is probably much lower. It is of great importance to study the clinical circumstances leading to Torsades de Pointes in patients with Takotsubo cardiomyopathy-associated QT interval prolongation since Torsades de Pointes might be fatal, while the prognosis of Takotsubo cardiomyopathy is usually good (Bybee & Prasad, 2008).

Takotsubo cardiomyopathy-associated Torsades de Pointes has been reported in 2005 for the first time (Denney et al., 2005). We have reviewed this case report and additional 14 reports (Akashi et al., 2003; Boulouffe et al., 2007; Finsterer et al., 2007; Furushima et al., 2008; Ghosh et al., 2009; Hirose et al., 2008; Inoue et al., 2009; Kurisu et al., 2008; Mahida et al., 2009; Nault et al., 2007; Okada et al., 2007; Patel et al., 2007; Sasaki et al., 2006) concerning Takotsubo cardiomyopathy-associated Torsades de Pointes in 2009, and we have concluded that males with Takotsubo cardiomyopathy-associated QT interval prolongation are at risk for Takotsubo cardiomyopathy-associated Torsades de Pointes although most patients with Takotsubo cardiomyopathy are females. There has been a trend in the mean maximal QT interval being longer among patients with Takotsubo

cardiomyopathy-associated Torsades de Pointes relative to patients with Takotsubo cardiomyopathy-associated QT interval prolongation. Moreover, most patients with Takotsubo cardiomyopathy-associated Torsades de Pointes have had risk factors for Torsades de Pointes other than female gender and left ventricular systolic dysfunction (Samuelov-Kinori et al., 2009). Additional 12 patients with Takotsubo cardiomyopathy-associated Torsades de Pointes have been reported since then (Ahn et al., 2011; Gotyo et al., 2009; Grilo et al., 2010; Kawano et al., 2010; Micallef et al., 2010; Pacha et al., 2010; Peters & Klein, 2011; Purvis et al., 2009; Rotondi et al., 2010; Wedekind et al., 2009; Yamada et al., 2011). We have currently examined whether our previous conclusions are true in face of these new publications. Moreover, we have studied if Torsades de Pointes has been possibly preventable in patients with Takotsubo cardiomyopathy-associated Torsades de Pointes.

2. Material and methods

2.1 Retrieval of reports

We performed a literature search by using the following keywords: "Apical ballooning", "Arrhythmia", "Stress cardiomyopathy", "Sudden death", "Syncope", "Takotsubo", and "Torsades de Pointes". The references in each report were further reviewed for additional publications. Only full-length reports were reviewed. The study group included all patients with Takotsubo cardiomyopathy-associated Torsades de Pointes that had been reported until July 2011. The control group included patients with Takotsubo cardiomyopathy-associated QT interval prolongation that had been reviewed previously (Samuelov-Kinori et al., 2009).

2.2 Risk factors for Torsades de Pointes

Each case report was analyzed for the presence of risk factors for Torsades de Pointes other than female gender and left ventricular systolic dysfunction: recent conversion of atrial fibrillation to sinus rhythm, administering QT interval prolonging agents, hypokalemia (<3.5 mmol/L), hypocalcemia (<8.5 mg/dL), severe hypomagnesaemia (<1 mg/dL), and high-degree atrioventricular block (Antzelevitch, 2007; Roden, 2004). Since genetic analysis was not available for all patients, suspicion of congenital long QT syndrome was also considered a risk factor for Torsades de Pointes, and was defined as QT interval prolongation in the baseline ECG recorded before Takotsubo cardiomyopathy appearance or following its resolution. QT interval prolongation was defined as QTc >430 msec for male patients and QTc >450 msec for female patients according to the Bazett's formula (Bazett, 1920). We used the QTc that was mentioned in the text of each case report by the authors. In few cases we measured the QT interval length in lead II and calculated the QTc according to the ECG strip enclosed.

2.3 Preventable Torsades de Pointes

Each case report of Takotsubo cardiomyopathy-associated Torsades de Pointes was analyzed for the presence or the absence of treatment and prevention measures taken once QT interval prolongation had been noticed and prior to Torsades de Pointes appearance in face of the above-mentioned risk factors for Torsades de Pointes – regardless of whether Takotsubo cardiomyopathy diagnosis had already been made.

2.4 Statistical analysis

Continuous variables were expressed as mean \pm standard error. Student t-test was used to compare between mean values of continuous variables with parametric distributions. Mann-Whitney test was used to compare between mean values of continuous variables with non-parametric distributions. Fisher's exact test was used to compare between incidence and prevalence of categorical variables. Two-tailed $p < 0.05$ was considered statistically significant. Version 17.0 of the SPSS statistical package was used for all statistical analyses (SPSS Inc., Chicago, IL, USA).

3. Results

Reports concerning 113 patients were reviewed. The study group included 27 patients with Takotsubo cardiomyopathy-associated Torsades de Pointes. The control group included 86 patients with Takotsubo cardiomyopathy-associated QT interval prolongation. Mean age of all patients was 65.1 ± 1.2 years. Most patients were females ($n=102$; 90.3%). All patients with Takotsubo cardiomyopathy-associated Torsades de Pointes survived, although one patient died of other complications more than two months following Torsades de Pointes (Hirose et al., 2008).

Although most patients were females, the prevalence of male gender was significantly higher among patients with Takotsubo cardiomyopathy-associated Torsades de Pointes relative to patients with Takotsubo cardiomyopathy-associated QT interval prolongation (odds ratio 4.6; 95% Confidence Interval 1.3-16.7). Mean maximal QTc interval was significantly higher among patients with Takotsubo cardiomyopathy-associated Torsades de Pointes relative to patients with Takotsubo cardiomyopathy-associated QT interval prolongation even prior to Torsades de Pointes appearance. There were no statistical differences between patients with Takotsubo cardiomyopathy-associated Torsades de Pointes and patients with Takotsubo cardiomyopathy-associated QT interval prolongation in terms of mean age, mean lowest ejection fraction, and mean peak Troponin levels (table 1).

		Takotsubo-associated QT interval prolongation (n=86)	Takotsubo-associated Torsades de Pointes (n=27)	p value
Male gender	n (%)	5 (5.8%)	6 (22.2%)	0.021
Age (years)	n available Mean \pm SE	86 64.7 \pm 1.2	27 66.2 \pm 3.2	0.680
Maximal QTc interval (msec)	n available Mean \pm SE	58 555.9 \pm 8.4	25 670.2 \pm 37.1	0.006
Maximal QTc interval prior to Torsades de Pointes (msec)	n available Mean \pm SE	58 555.9 \pm 8.4	16 676.8 \pm 49.7	0.029
Lowest ejection fraction (%)	n available Mean \pm SE	50 36.5 \pm 1.4	11 37.2 \pm 4.0	0.850
Peak Troponin levels (ng/mL)	n available Mean \pm SE	39 5.6 \pm 2.5	13 1.7 \pm 0.8	0.383

Table 1. Clinical characteristics of reported patients

Overall, 17 (62.9%) patients with Takotsubo cardiomyopathy-associated Torsades de Pointes had one or more risk factors for Torsades de Pointes other than female gender and left ventricular systolic dysfunction, while only two (2.3%) patients with Takotsubo cardiomyopathy-associated QT interval prolongation had risk factors for Torsades de Pointes (odds ratio 71.4; 95% Confidence Interval 14.3-355.5; $p < 0.0001$). Electrolyte depletion, i.e., hypokalemia and/or severe hypomagnesemia ($n=7$; 25.9%), and high-degree atrioventricular block ($n=5$; 18.5%), were the most prevalent risk factors for Torsades de Pointes and the last triggers for Torsades de Pointes. Four (14.8%) patients were also taking QT interval prolonging agents, although initiation of these agents was not the last trigger for Torsades de Pointes in any case (table 2).

Among patients with Takotsubo cardiomyopathy-associated Torsades de Pointes, the arrhythmia was diagnosed prior to Takotsubo cardiomyopathy most of the times ($n=19$; 70.4%), and in seven (25.9%) patients Torsades de Pointes was diagnosed upon admission to the emergency department. Nevertheless, Torsades de Pointes was possibly preventable in seven (25.9%) patients: In four patients with QT interval prolongation and apparent electrolyte depletion, hypokalemia and/or severe hypomagnesemia were corrected only following Torsades de Pointes appearance; in three patients with QT interval prolongation and high-degree atrioventricular block, pacemaker was implanted only following Torsades de Pointes appearance (table 2). In other patients, risk factors for Torsades de Pointes were diagnosed only following Torsades de Pointes appearance, or they were addressed too late.

4. Discussion

We have studied reports concerning patients with Takotsubo cardiomyopathy-associated QT interval prolongation and reports concerning patients with Takotsubo cardiomyopathy-associated Torsades de Pointes in order to characterize the clinical circumstances leading to Torsades de Pointes in patients with Takotsubo cardiomyopathy. We have done this before in 2009 (Samuelov-Kinori et al., 2009), but reports concerning patients with Takotsubo cardiomyopathy-associated Torsades de Pointes have almost doubled since then, and it is time to examine if our previous conclusions are still true in face of these new publications. Moreover, we have studied if Torsades de Pointes has been possibly preventable in patients with Takotsubo cardiomyopathy-associated Torsades de Pointes.

Consistent with our previous observation (Samuelov-Kinori et al., 2009), male patients with Takotsubo cardiomyopathy-associated QT interval prolongation are at higher risk for Torsades de Pointes compared with female patients with Takotsubo cardiomyopathy-associated QT interval prolongation, although most patients with Takotsubo cardiomyopathy are females (Bybee & Prasad, 2008). This finding is coherent with a recognized paradox which is still unexplained: women have longer QT interval compared with men but lower incidence of sudden death (Larsen & Kadish, 1998).

In our previous review there has been a trend in the mean maximal QT interval being longer among patients with Takotsubo cardiomyopathy-associated Torsades de Pointes relative to patients with Takotsubo cardiomyopathy-associated QT interval prolongation, although most of the times QT interval prolongation has been noticed only following Torsades de Pointes appearance (Samuelov-Kinori et al., 2009). In face of the new reports concerning patients with Takotsubo cardiomyopathy-associated QT interval prolongation, the trend has become statistically significant: mean maximal QTc interval is significantly higher among

First author	Age	Sex	Diagnosed first	Risk factors for QT interval prolongation and Torsades de Pointes other than female gender and left ventricular systolic dysfunction	Was Torsades de Pointes preventable?
Denney	32	M	Torsades	None	No
Kurisu	78	M	Torsades	Atrioventricular Block	Possibly
Kurisu	87	F	Torsades	Atrioventricular Block	Possibly
Nault	76	M	Torsades	HypoK	Possibly
Okada	77	M	Takotsubo	None	No
Akashi	67	F	Torsades	None	No
Boulouffe	68	F	Takotsubo	None	No
Finsterer	75	F	Torsades	Recent A.Fib conversion	No
Furushima	61	F	Torsades	QT interval prolongation at baseline ECG	No
Ghosh	59	F	Takotsubo	HypoK	Possibly
Patel	72	F	Torsades*	None	No
Sasaki	22	F	Torsades*	HypoK	No
Hirose	63	F	Takotsubo	HypoK + recent A.Fib conversion	No
Inoue	82	F	Torsades*	Atrioventricular Block	No
Mahida	55	F	Torsades	None	No
Micallef	58	F	Takotsubo	None	No
Pacha	64	F	Takotsubo	Recent A.Fib conversion + Amiodarone + HypoCa	No
Grilo	37	F	Torsades	Congenital long QT syndrome + Ketoconazole	No
Rotondi	57	F	Takotsubo	HypoK + HypoMg + HypoCa	Possibly
Wedekind	81	F	Torsades*	None	No
Gotyo	70	M	Torsades	None	No
Purvis	67	F	Torsades	HypoMg + Fluoxetine	Possibly
Kawano	80	M	Torsades	HypoK	No
Yamada	89	F	Torsades*	Atrioventricular Block	No
Yamada	81	F	Torsades	Clarythromycin	No
Peters	50	F	Torsades*	None	No
Ahn	78	F	Takotsubo	Atrioventricular Block	Possibly

Table 2. Clinical characteristics of patients with Takotsubo cardiomyopathy-associated Torsades de Pointes

patients with Takotsubo cardiomyopathy-associated Torsades de Pointes relative to patients with Takotsubo cardiomyopathy-associated QT interval prolongation even prior to Torsades de Pointes appearance. This finding is of great clinical significance beyond statistical significance: mean maximal QTc interval is remarkably high (676.8 msec) in patients with Takotsubo cardiomyopathy-associated Torsades de Pointes prior to Torsades de Pointes appearance - more than 120 msec higher relative to mean maximal QTc interval in patients with Takotsubo cardiomyopathy-associated QT interval prolongation without Torsades de Pointes appearance. This large difference in QT interval prolongation should urge physicians to start treatment and to take prevention measures as soon as possible prior to Torsades de Pointes appearance.

As with our previous review (Samuelov-Kinori et al., 2009), most patients with Takotsubo cardiomyopathy-associated Torsades de Pointes have one or more risk factors for Torsades de Pointes other than female gender and left ventricular systolic dysfunction. Electrolyte depletion and high degree atrioventricular block are the most prevalent risk factors and last triggers for Torsades de Pointes. But this time we have also shown that Torsades de Pointes is possibly preventable in one quarter of the patients should electrolyte depletion and high degree atrioventricular block have been addressed earlier.

4.1 Limitations

Our study is based on a small number of published case reports. Accordingly, the above-mentioned findings are suggestive rather than conclusive. We assume that there are more incidents of Torsades de Pointes in patients with Takotsubo cardiomyopathy that have not been published; for example, when physicians are reluctant to report their deceased patients. Indeed, in all the above-mentioned reports patients have survived Torsades de Pointes. Accordingly; we believe that our findings are more likely an underestimation of the true prevalence of the clinical circumstances that might lead to Torsades de Pointes in Takotsubo cardiomyopathy patients.

4.2 Clinical implications

This study defines four risk factors for Torsades de Pointes in patients with Takotsubo cardiomyopathy whom already have QT interval prolongation to begin with: male gender, marked QT interval prolongation, electrolyte depletion, and high degree atrioventricular block. Electrolyte depletion and high degree atrioventricular block are also last triggers for Torsades de Pointes in patients with Takotsubo cardiomyopathy. Accordingly, we believe electrolyte depletion and high degree atrioventricular block should be addressed as soon as possible in patients with Takotsubo cardiomyopathy in general, and in patients with marked QT interval prolongation in particular.

5. Conclusion

Men with Takotsubo cardiomyopathy-associated QT interval prolongation are at risk for Torsades de Pointes. Most patients with Takotsubo cardiomyopathy-associated Torsades de Pointes have risk factors for Torsades de Pointes other than female gender and left ventricular systolic dysfunction. Electrolyte depletion and high degree atrioventricular block are the most prevalent risk factors and last triggers for Torsades de Pointes. We wish to raise

the awareness of risk factors for Torsades de Pointes in patients with Takotsubo cardiomyopathy-associated QT interval prolongation.

6. References

- Abe, Y.; Kondo, M.; Matsuoka, R.; Araki, M.; Dohyama, K. & Tanio, H. (2003). Assessment of clinical features in transient left ventricular apical ballooning. *Journal of the American College of Cardiology*, Vol.41, No.5, (March 2003), pp.737-742, ISSN 0735-1097
- Ahn, JH.; Park, SH.; Shin, WY.; Lee, SW.; Lee, SJ.; Jin, DK.; Lee, HM. & Eun, JY. (2011). Long QT Syndrome and Torsade de Pointes Associated with Takotsubo Cardiomyopathy. *Journal of Korean medical science*, Vol.26, No.7, (July 2011), pp.959-961, ISSN 1011-8934
- Akashi, YJ.; Nakazawa, K.; Kida, K.; Ryu, S.; Takagi, A.; Kishi, R.; Kunishima, T.; Sakakibara, M. & Miyake, F. (2003). Reversible ventricular dysfunction (takotsubo cardiomyopathy) following polymorphic ventricular tachycardia. *Canadian Journal of Cardiology*, Vol.19, No.4, (March 2003), pp.449-451, ISSN 0828-282X
- Antzelevitch, C. Ionic, molecular, and cellular bases of QT-interval prolongation and torsade de pointes. *Europace*, Vol.9, Suppl.No.4, (September 2007), pp.iv4-15, ISSN 1099-5129
- Bazett, HC. (1920). An analysis of the time-relations of electrocardiograms. *Heart*, Vol.7, (1920), pp.353-370, ISSN 1355-6037
- Boulouffe, C.; Vanpee, D. & Gabriel, L. (2007). Stress-induced cardiomyopathy: takotsubo left ventricular dysfunction. *American Journal of Emergency Medicine*, Vol.25, No.2, (February 2007), pp.243-244, ISSN 0735-6757
- Bybee, KA. & Prasad, A. (2008). Stress-Related Cardiomyopathy Syndromes. *Circulation*, Vol.118, No.4, (July 2008), pp.397-409, ISSN 0009-7322
- Cangella, F.; Medolla, A.; De Fazio, G.; Iuliano, C.; Curcio, N.; Salemme, L.; Mottola, G. & Agrusta, M. (2007). Stress induced cardiomyopathy presenting as acute coronary syndrome: Tako-Tsubo in Mercogliano, Southern Italy. *Cardiovascular Ultrasound*, Vol.5, (October 2007), pp.36, ISSN 1476-7120
- Denney, SD.; Lakkireddy, DR. & Khan, IA. (2005). Long QT syndrome and torsade de pointes in transient left ventricular apical ballooning syndrome. *International Journal of Cardiology*, Vol.100, No.3, (April 2005), pp.499-501, ISSN 0167-5273
- Fang, CC.; Jao, YT.; Yi, C.; Yu, CL.; Chen, CL. & Wang, SP. (2008). Transient left ventricular apical ballooning syndrome: the first series in Taiwanese patients. *Angiology*, Vol.59, No.2, (April-May 2008), pp.185-192, ISSN 0003-3197
- Finsterer, J.; Stöllberger, C.; Sehnal, E.; Valentin, A.; Huber, J. & Schmiedel, J. (2007). Apical ballooning (Takotsubo syndrome) in mitochondrial disorder during mechanical ventilation. *Journal of cardiovascular medicine (Hagerstown, Md.)*, Vol.8, No.10, (October 2007), pp.859-863, ISSN 1558-2027
- Furushima, H.; Chinushi, M.; Sanada, A. & Aizawa, Y. (2008). Ventricular repolarization gradients in a patient with takotsubo cardiomyopathy. *Europace*, Vol.10, No.9, (September 2008), pp.1112-1115, ISSN 1099-5129

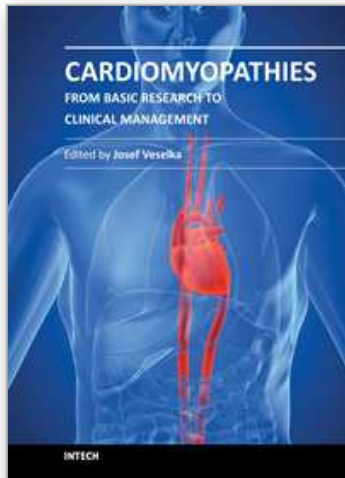
- Ghosh, S.; Apte, P.; Maroz, N.; Broor, A.; Zeineh, N. & Khan, IA. (2009). Takotsubo cardiomyopathy as a potential cause of long QT syndrome and torsades de pointes. *International Journal of Cardiology*, Vol.136, No.2, (August 2009), pp.225-227, ISSN 0167-5273
- Gotyo, N.; Kida, M.; Horiuchi, T. & Hirata, Y. (2009). Torsade de pointes associated with recurrent ampulla cardiomyopathy in a patient with idiopathic ACTH deficiency. *Endocrine journal*, Vol.56, No.6, (June 2009), pp.807-815, ISSN 0918-8959
- Grilo, LS.; Pruvot, E.; Grobéty, M.; Castella, V.; Fellmann, F. & Abriel, H. (2010). Takotsubo cardiomyopathy and congenital long QT syndrome in a patient with a novel duplication in the Per-Arnt-Sim (PAS) domain of hERG1. *Heart Rhythm*, Vol.7, No.2, (September 2010), pp.260-265, ISSN 1547-5271
- Hirose, K.; Yamaguchi, H.; Oshima, Y.; Choraku, M.; Hirono, A.; Takamori, N. & Tamura, K. (2008). Severe respiratory failure and torsades de pointes induced by disopyramide in a patient with myasthenia gravis. *Internal Medicine*, Vol.47, No.19, (October 2008), pp.1703-1708, ISSN 1349-7235
- Inoue, M.; Kanaya, H.; Matsubara, T.; Uno, Y.; Yasuda, T. & Miwa, K. (2009). Complete Atrioventricular Block Associated With Takotsubo Cardiomyopathy. *Circulation Journal*, Vol.73, No.3, (March 2009), pp.589-592, ISSN 1346-9843
- Kawano, H.; Matsumoto, Y.; Arakawa, S.; Satoh, O. & Hayano, M. (2010). Premature atrial contraction induces torsades de pointes in a patient of Takotsubo cardiomyopathy with QT prolongation. *Internal Medicine*, Vol.49, No.16, (August 2010), pp.1767-1773, ISSN 1349-7235
- Kurisu, S.; Inoue, I.; Kawagoe, T.; Ishihara, M.; Shimatani, Y.; Nakama, Y.; Ohkawa, K.; Maruhashi, T.; Kagawa, E.; Dai, K. & Aokage, T. (2008). Torsade de pointes associated with bradycardia and takotsubo cardiomyopathy. *Canadian Journal of Cardiology*, Vol.24, No.8, (August 2008), pp.640-642, ISSN 0828-282X
- Larsen, JA. & Kadish, AH. (1998). Effects of gender on cardiac arrhythmias. *Journal of Cardiovascular Electrophysiology*, Vol.9, No.6, (June 1998), pp.655-664, ISSN 1045-3873
- Mahida, S.; Dalageorgou, C. & Behr, ER. (2009). Long-QT syndrome and torsades de pointes in a patient with Takotsubo cardiomyopathy: an unusual case. *Europace*, Vol.11, No.3, (March 2009), pp.376-378, ISSN 1099-5129
- Micallef, T.; Gruppetta, M.; Cassar, A. & Fava, S. (2010). Takotsubo cardiomyopathy in a patient with severe hypothyroidism: a case report. *Journal of cardiovascular medicine (Hagerstown, Md.)*, doi: 10.2459/JCM.0b013e3283403454, ISSN 1558-2027
- Nault, MA.; Baranchuk, A.; Simpson, CS. & Redfearn, DP. (2007). Takotsubo cardiomyopathy: a novel "proarrhythmic" disease. *Anadolu Kardiyoloji Dergisi*, Vol.7, Supp.No.1, (July 2007), pp.101-103, ISSN 1302-8723
- Okada, T.; Miyata, S.; Hashimoto, K.; Maie, K. & Mochizuki, S. (2007). Takotsubo cardiomyopathy associated with torsades de pointes and long QT interval: a case report. *Journal of Cardiology*, Vol.50, No.1, (July 2007), pp.83-88, ISSN 0914-5087

- Pacha, O.; Kadikoy, H.; Amro, M.; Haque, W. & Abdellatif, A. (2010). Torsades de pointes and prolonged QT syndrome in Takotsubo cardiomyopathy. *Journal of cardiovascular medicine (Hagerstown, Md.)*, doi: 10.2459/JCM.0b013e328336b4a6, ISSN 1558-2027
- Patel, HM.; Kantharia, BK.; Morris, DL. & Yazdanfar, S. (2007). Takotsubo syndrome in African-American women with atypical presentations: a single-center experience. *Clinical Cardiology*, Vol.30, No.1, (January 2007), pp.14-18, ISSN 1932-8737
- Peters, S. & Klein, HU. (2011). WCD LifeVest: Risk stratification in a case of tako-tsubo cardiomyopathy with QT interval prolongation. *Herz*, doi: 10.1007/s00059-011-3440-9, ISSN 0946-1299
- Purvis, JA.; Cunningham, EL.; McGlinchey, PG. & Barr, SH. (2009). Drugs, electrolytes and tako-tsubo cardiomyopathy: triple aetiology of acquired long QT syndrome and torsades de pointes. *The Ulster medical journal Ulster*, Vol.78, No.3, (September 2009), pp.188-189, ISSN 0041-6193
- Roden, DM. (2004). Drug-induced prolongation of the QT interval. *The New England Journal of Medicine*, Vol.350, No.10, (March 2004), pp.1013-22, ISSN 0028-4793
- Rotondi, F.; Manganelli, F.; Lanzillo, T.; Candelmo, F.; Lorenzo, ED.; Marino, L. & Stanco, G. (2010). Tako-tsubo cardiomyopathy complicated by recurrent torsade de pointes in a patient with anorexia nervosa. *Internal Medicine*, Vol.49, No. 12, (June 2010), pp.1133-1137, ISSN 1349-7235
- Samuelov-Kinori, L.; Kinori, M.; Kogan, Y.; Swartzon, M.; Shalev, H.; Guy, D.; Ferenidou, F.; Mashav, N.; Sadeh, B.; Atzmony, L.; Kliuk-Ben-Basat, O.; Steinvil, A. & Justo, D. (2009). Takotsubo cardiomyopathy and QT interval prolongation: who are the patients at risk for torsades de pointes? *Journal of electrocardiology*, Vol.42, No.4, (July-August 2009); pp.353-357, ISSN 0022-0736
- Sasaki, O.; Nishioka, T.; Akima, T.; Tabata, H.; Okamoto, Y.; Akanuma, M.; Uehata, A.; Takase, B.; Katsushika, S.; Isojima, K.; Ohtomi, S. & Yoshimoto, N. (2006). Association of takotsubo cardiomyopathy and long QT syndrome. *Circulation Journal*, Vol.70, No.9, (September 2006), pp.1220-1222, ISSN 1346-9843
- Thakar, S.; Chandra, P.; Hollander, G. & Lichstein, E. (2011). Electrocardiographic Changes in Takotsubo Cardiomyopathy. *Pacing and Clinical Electrophysiology*, doi: 10.1111/j.1540-8159.2011.03151, ISSN 1540-8159
- Wedekind, H.; Müller, JG.; Ribbing, M.; Skurzewski, P.; Bozzetti, C.; Meyer-Krahmer, HJ. & Böcker, D. (2009). A fatal combination in an old lady: Tako-Tsubo cardiomyopathy, long QT syndrome, and cardiac hypertrophy. *Europace*, Vol.11, No.6, (June 2009), pp.820-822, ISSN 1099-5129
- Wittstein, IS.; Thiemann, DR.; Lima, JA.; Baughman, KL.; Schulman, SP.; Gerstenblith, G.; Wu, KC.; Rade, JJ.; Bivalacqua, TJ. & Champion, HC. (2005). Neurohumoral features of myocardial stunning due to sudden emotional stress. *The New England Journal of Medicine*, Vol.352, No.6, (February 2005), pp.539-548, ISSN 0028-4793

Yamada, Y.; Tani, T.; Homma, M. & Saito, S. (2011). Two cases of torsades de pointes associated with takotsubo cardiomyopathy as the second insult. *Journal of electrocardiology*, doi.org/10.1016/j.jelectrocard.2011.03.002, ISSN 0022-0736

IntechOpen

IntechOpen



Cardiomyopathies - From Basic Research to Clinical Management

Edited by Prof. Josef Veselka

ISBN 978-953-307-834-2

Hard cover, 800 pages

Publisher InTech

Published online 15, February, 2012

Published in print edition February, 2012

Cardiomyopathy means "heart (cardio) muscle (myo) disease (pathy)". Currently, cardiomyopathies are defined as myocardial disorders in which the heart muscle is structurally and/or functionally abnormal in the absence of a coronary artery disease, hypertension, valvular heart disease or congenital heart disease sufficient to cause the observed myocardial abnormalities. This book provides a comprehensive, state-of-the-art review of the current knowledge of cardiomyopathies. Instead of following the classic interdisciplinary division, the entire cardiovascular system is presented as a functional unity, and the contributors explore pathophysiological mechanisms from different perspectives, including genetics, molecular biology, electrophysiology, invasive and non-invasive cardiology, imaging methods and surgery. In order to provide a balanced medical view, this book was edited by a clinical cardiologist.

How to reference

In order to correctly reference this scholarly work, feel free to copy and paste the following:

Dan Justo, Arie Steinvil and Itzhak Shapira (2012). Torsades de Pointes Associated with Takotsubo Cardiomyopathy: Is It Preventable?, *Cardiomyopathies - From Basic Research to Clinical Management*, Prof. Josef Veselka (Ed.), ISBN: 978-953-307-834-2, InTech, Available from:
<http://www.intechopen.com/books/cardiomyopathies-from-basic-research-to-clinical-management/torsades-de-pointes-associated-with-takotsubo-cardiomyopathy-is-it-preventable->

INTECH
open science | open minds

InTech Europe

University Campus STeP Ri
Slavka Krautzeka 83/A
51000 Rijeka, Croatia
Phone: +385 (51) 770 447
Fax: +385 (51) 686 166
www.intechopen.com

InTech China

Unit 405, Office Block, Hotel Equatorial Shanghai
No.65, Yan An Road (West), Shanghai, 200040, China
中国上海市延安西路65号上海国际贵都大饭店办公楼405单元
Phone: +86-21-62489820
Fax: +86-21-62489821

© 2012 The Author(s). Licensee IntechOpen. This is an open access article distributed under the terms of the [Creative Commons Attribution 3.0 License](#), which permits unrestricted use, distribution, and reproduction in any medium, provided the original work is properly cited.

IntechOpen

IntechOpen