

We are IntechOpen, the world's leading publisher of Open Access books Built by scientists, for scientists

4,800

Open access books available

122,000

International authors and editors

135M

Downloads

Our authors are among the

154

Countries delivered to

TOP 1%

most cited scientists

12.2%

Contributors from top 500 universities



WEB OF SCIENCE™

Selection of our books indexed in the Book Citation Index
in Web of Science™ Core Collection (BKCI)

Interested in publishing with us?
Contact book.department@intechopen.com

Numbers displayed above are based on latest data collected.

For more information visit www.intechopen.com



Oral Rapamycin to Reduce Intimal Hyperplasia After Bare Metal Stent Implantation - A Prospective Randomized Intravascular Ultrasound Study

Carmelo Cernigliaro, Mara Sansa,
Federico Nardi and Eugenio Novelli
*Department of Cardiology, Clinica San Gaudenzio Novara,
Italy*

1. Introduction

Coronary artery disease is a major health problem throughout the world. Important advances in diagnosis and treatment of atherosclerotic disorders have been made over the last five decades. Coronary angiography, introduced by Mason Sones in 1958 has been very effective on expanding the diagnosis and treatment of coronary lesions. The introduction of conventional balloon percutaneous transluminal coronary angioplasty (PTCA) by Andreas Grüntzig in 1977, represented an innovative and quite efficient non surgical treatment of angina pectoris and acute myocardial infarction. This procedure was however frequently complicated by an abrupt vessel closure, coronary dissections and a high incidence of restenosis (up to 40 - 50 % of cases) (Grüntzig et al., 1979). In 1986 the first coronary Wallstent was implanted in Toulouse by Jacques Puel and Ulrich Sigwart (Sigwart et al., 1987) and in 1994 Palmaz-Schatz stents were approved by FDA in the United States. Coronary stents improved the immediate and long-term results of coronary angioplasty, reducing immediate complications of the procedure like coronary dissection and abrupt closure and the incidence of restenosis. However, despite technical advances in stent delivery systems and design the rate of restenosis after stent implantation remained 20-30% especially in the high risk patients subsets (Serruys et al., 1994; Fischman et al., 1994). To overcome the problem of restenosis the drug eluting stents Cypher and Taxus were approved in 2003 and 2004 respectively. The initial studies with these stents demonstrated a marked major advance in reducing restenosis (Bailey, 1997; Serruys et al., 2002). Later studies however confirmed that despite these advances, in the real world, stent thrombosis (acute, subacute and late) and in-stent restenosis still remain a great clinical challenge (Daemen et al., 2007). The process of restenosis is complex. Restenosis may ensue mainly because of: a) patients-related factors (diabetes, restenosis after PTCA, chronic renal insufficiency, high serum PCR etc), b) vessel factors (chronic occlusion, vessel involved e.g. LAD, SVG etc, vessel < 3.0mm diameter, lesion length > 30 mm, bifurcation lesion, ostial lesion), c) procedure factors (post-stent MLD < 3mm, multiple stents, stent underexpansion or malapposition, stent fracture).

2. Cellular mechanism of restenosis

The restenosis process is a combination of inflammatory and reparative reaction at the site of stent implantation that may produce after weeks or months intimal hyperplasia or vascular remodelling.

In the porcine coronary after implantation of a metallic stent, restenotic neointima forms within one month and has a histopathologic appearance similar to human restenosis.

Three distinct stages in the genesis of neointima have been described: thrombosis, cellular recruitment, cellular proliferation.

Thrombosis: the earliest response to arterial injury is the formation of a thrombus, which is pale and platelet-rich microscopically. Erythrocytes and fibrin deposit on platelets and produce a heterogeneous microscopic appearance. By 24 hours the thrombus becomes denser as platelets and erythrocytes lyse and agglutinate. Platelet lysis results in discharge of granules and release of bioactive substances including platelet-derived growth factor (PDGF) (Ross et al., 1986; Williams, 1989).

Cellular recruitment: in this stage the thrombus itself becomes covered by the endothelium. Monocytes and lymphocytes are attracted by the flowing blood to the newly formed endothelial surface and pass through the endothelium into the degenerating fibrin thrombus. The monocytes become macrophages. Both macrophages and lymphocytes release a variety of growth factors and cytokines that are involved in smooth muscle cells migration and proliferation. Macrophages and lymphocytes also elaborate fibrinolytic enzymes. Over time these cells are found at deeper levels within the degenerated thrombus from the luminal (endothelium) direction toward the media of the artery.

Cellular proliferation: in the next stage cells form an intimal cap on the luminal side of the healing mass. The thickness of the cap is proportional to lesion age. Residual thrombus is gradually resorbed and replaced by neointima. An extracellular matrix consisting of collagen and glycosaminoglycans is present presumably secreted by vascular smooth muscle cells.

In early experiments, elimination of smooth muscle cells from media by intraluminal microwave heat energy applied in pig arteries after balloon injury was thought to prevent intimal hyperplasia because no cells would be available to migrate and proliferate. After one month however a large volume of neointima was observed at the burn sites where most of the cells had been killed as if migration of smooth muscle cells into the neointima may still occur from a distant uninjured medial site.

To summarize this interesting information, smooth muscle cells forming neointima do not necessarily originate at the site of medial injury. Endothelialized and degenerating thrombus, colonized by monocytes and lymphocytes, provides a matrix where smooth muscle cells migrate and proliferate and synthesize extracellular matrix. The thrombus burden that accumulates at the arterial injury site determines the volume of eventual neointimal volume (Schwartz et al., 1992).

3. Alternative therapies to prevent stent restenosis

These data would favour a systemic approach with drugs that reduce intracoronary inflammation and neointimal proliferation also at sites distant from that injured by stent implantation. Stents that elute loco-regionally drugs such rapamycin or paclitaxel (DES), even if in multiple large randomized studies, demonstrate superiority over conventional bare metal stents (BMS) with regard to clinical endpoints such as target vessel or target

lesion revascularization are still subjected to failure and restenosis. Interestingly, limited evidence directly comparing DES implantation to vascular brachytherapy (locally applied beta or gamma radiations) in patients with stent restenosis, has shown no direct benefit of one approach to the other (Torguson et al., 2006).

A systemic approach with oral antiproliferative agents like oral sirolimus or newer inhibitors of cytokines could more effectively reduce vascular smooth cell proliferation, migration and invasion process even at a distant site from the injured media (Kuchulakanti & Waksman, 2004). The oral approach has been so far reported in small size studies. The studies suggest that a course of 30 days of oral therapy is both safe and effective and that efficacy is tied to serum blood levels of the drug (Brara et al., 2003; Cernigliaro et al., 2010; Chaves et al., 2005; Fox et al., 2009; Gallo et al., 1999; Guarda et al., 2004; Hausleiter et al., 2004; Munk et al., 2009; Rodriguez et al., 2003; Rodriguez et al., 2005; Rodriguez et al., 2006; Rodriguez, 2009; Rodriguez et al., 2009; Jennings & Kalus 2010; Stojkovic et al., 2010; Waksman et al., 2004; Waksman et al., 2006). Future investigation into the efficacy of oral antiproliferative agents also during the periprocedural period of BMS or DES implantation is still needed.

Recent studies have investigated adjunctive therapies that could potentially reduce stent restenosis. Addition of cilostazol to aspirin and a thienopyridine (triple antiplatelet therapy) demonstrated reduction of angiographic restenosis at 6 months follow-up over patients receiving dual antiplatelet therapy regardless of whether a bare metal stents or a drug-eluting stents was implanted (Jennings & Kalus 2010).

Oral inhibitors of up-regulated chemokines for reduction of restenosis rates following implantation of BMS without increase in late thrombosis are being utilized in clinical trials.

Chemokines have a crucial role in the initiation and progression of neointima formation by controlling the vascular remodelling in response to various noxious stimuli. It has been demonstrated that eliminating the MCP-1 gene or blocking MCP-1 signaling decreases neointimal hyperplasia after balloon and stent induced injury in several animal models.

In addition, elevated circulating levels of MCP-1 are observed in patients with restenosis after coronary angioplasty. The induction of MPC-1 correlates with macrophages accumulation and there is strong evidence for an important role of MPC-1 in vascular smooth muscle cells (VSMC) proliferation and migration. One of these oral inhibitors have demonstrated anti-inflammatory activity in a number of experimental diseases, with no induction of systemic immunosuppression and no effect on arachidonic acid metabolism.

In vitro it reduces rat vascular smooth muscular proliferation migration, and invasion processes. In a porcine model of in-stent restenosis the product inhibits in-stent neointimal restenosis. Treatment of rats at a dose of 200mg/Kg/day significantly reduces balloon injury-induced intima formation by 39% at day 14 without affecting re-endothelization and reduces the number of medial and neointimal proliferating cells at day 7 by 54% and 30% respectively. A human Phase II trial of 120 patients receiving BMS is ongoing.

The toxicological profile of the drug is safe and patients with rheumatoid arthritis and lupus nephritis have shown that the product is well tolerated and that urinary MCP-1 and albumin excretion in kidney disease is reduced.

The drug can be taken in combination with all the drugs taken by cardiological patients. It is administered b.i.d for 6 months after stent implantation and can be used in combination with BMS as an alternative to DES (Fox et al., 2009).

Regular high intensity exercise training is associated with a significant reduction of late luminal loss following BMS or DES implantation. Patients enrolled into the high-intesitive training group also demonstrated a significantly lower cardiac event rate. The hypothesis surrounding

the potential benefit of a high intensity exercise training is that such activity may be beneficial in minimizing endothelial dysfunction after stent implantation (Munk et al., 2009).

4. Current imaging modalities

Coronary angiography objectively assess the long-term outcome after stent implantation. It provides a silhouette of the intravascular space of coronary arteries. Many important features of the lesion that could influence intimal hyperplasia development after intervention may however not be identifiable with coronary arteriography alone.

Angioscopy is an invasive technique that allows an operator to visualize directly the interior of the vessel that can be seen through the fiberoptic eyepiece, or, using electronic chip camera technology. This allows improved understanding of the pathophysiology of coronary arteries. It identifies the presence of morphological features like thrombus or mural haemorrhage and disrupted atheromas that protrude into lumen. Such disruptions may appear angiographically as luminal haziness.

Grayscale intravascular ultrasonography (IVUS) is an invasive, catheter-based imaging procedure that uses sound waves to see inside the vessels within the body. IVUS is most commonly performed in conjunction with conventional coronary angiography for evaluating vessel pathology, atherosclerotic burden, and lesion severity. As compared with angiography, IVUS can provide more detail of the vessel architecture, including the cross-sectional composition of the lumen and wall and the presence and composition of plaque. Atheroma can be interrogated thoroughly to reveal the nature of the lesion (e.g. soft with high lipid content or fibrotic and calcified). Although IVUS is an invasive imaging modality, reports of major clinical complications are rare despite increasing clinical use. When performed by experienced operators, most major and acute procedural complications associated with IVUS imaging occur during interventional cases. The most frequently encountered complication is coronary spasm, which occurs in approximately 2–3% of patients during interventional and diagnostic procedures and usually responds rapidly to the administration of intracoronary nitroglycerin (Figure 1a, Figure 1b).

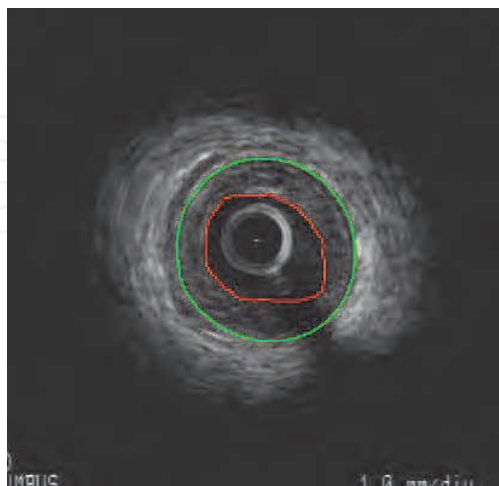


Fig. 1a) Cross sectional IVUS image of a coronary artery with colour coding delineating the lumen (red) the external elastic membrane (green) and the atherosclerotic burden of the media




Fig. 1b) Longitudinal display during monitored pullback of the same artery

Both non invasive and invasive methods have been proposed to aid in visualizing vessel morphology. Noninvasive alternatives to IVUS may include magnetic resonance imaging (MRI), computed tomography (CT) and Doppler ultrasound. Studies support IVUS as the "gold" reference standard when planning, guiding and assessing percutaneous coronary interventions. Multislice CT has moderate to good sensitivities and specificities for the visualization of coronary plaques compared with IVUS as the reference standard. Quantitative 64-channel CT angiography obtained with an effective radiation dose to patients in the range of 3 mSv, can obtain reliable measures in multiple views of reference diameter, minimum lumen diameter, and percent stenosis of coronary arteries before and after intervention (Figure 2a, Figure 2b, Figure 2c, Figure 2d).

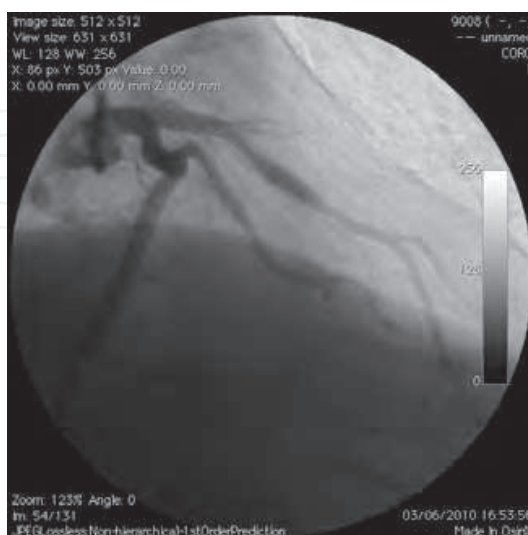


Fig. 2a) Coronary angiography of a Left Anterior Descending Artery with two overlapped DES showing proximal intrastent hyperplasia

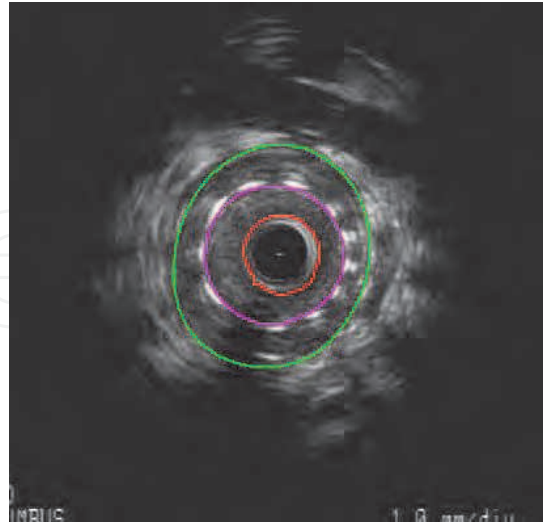


Fig. 2b) Cross sectional IVUS image of the same LAD artery with intrastent intimal hyperplasia




Fig. 2c) Longitudinal IVUS image of the same LAD artery: intimal hyperplasia encroaches the stent (yellow line)

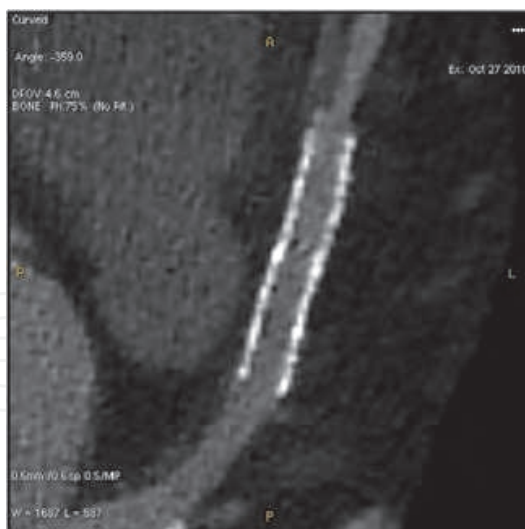

Fig. 2d) 64-CT angiography of the same LAD artery. Intimal hyperplasia encroaches the stent struts as islets of tissue imaged as intraluminal black spots by the struts

Novel invasive imaging technologies include optical coherence tomography (OCT), which measures the intensity of back-reflected light in a similar way to that by which IVUS measures acoustic waves; intracoronary thermography; and spectroscopy (reflected light is collected and launched into a spectrometer.)

Virtual Histology (OCT) analyzes radiofrequency ultrasound signals and provides real-time maps by classifying atherosclerotic plaque into tissue types of fibrous, fibro-fatty, dense calcium, and necrotic-core. VH IVUS is intended to be used in conjunction with imaging catheters during diagnostic ultrasound imaging of the peripheral and coronary vasculature to semi-automatically visualize boundary features and perform spectral analysis of radiofrequency ultrasound signals of vascular features that the user may wish to examine more closely during routine diagnostic ultrasound imaging examinations.

5. Intimal hyperplasia imaging

Coronary arteries architecture consists of an external layer the adventitia, the outer covering of the artery the media, the actual wall of the artery the intima, a layer of endothelial cells that make direct contact with the blood and the lumen. The intima in normal arteries is thin; in diseased arteries is thickened by plaques or other tissue growth often eccentric or asymmetrical. The term intimal hyperplasia applies to any cells that form a multi-layer compartment internally to the elastic membrane of the arterial wall. Standard coronary angiography shows the lumen of the artery and lumen narrowings when present by the injection of contrast dye as well as a dynamic picture of the blood flow. If the intima is thickened by plaques or other tissue growth that are not evenly distributed, coronary angiography will show an eccentric lumen and depending on the angle of the view the artery could show less or more stenosis than it really is. The intima layer is best visualized by the intravascular ultrasound (IVUS) that allows a vision of the coronary artery from the inside-out. The cross-section view obtained by IVUS shows the single circular layers of the artery using shades of gray or colors in real time. In a normal artery the intima will appear thin, in a diseased artery the intima is thickened by plaques as the lumen diameter is reduced. Low-dose quantitative 64-channel CT angiography can be a reasonable alternative to invasive IVUS to evaluate the extent of intimal hyperplasia (Figure 3a, Figure 3b).

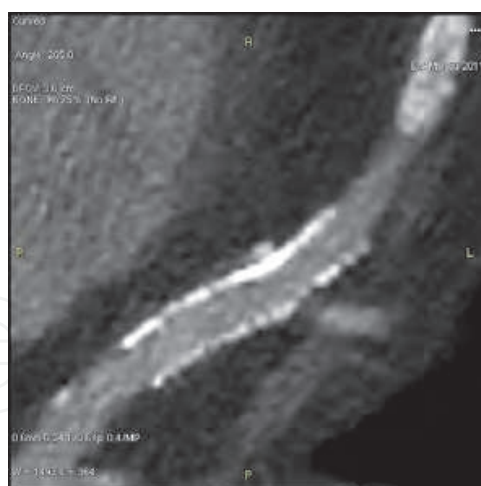


Fig. 3a) 64-CT angiography of a BMS stented Obtuse Margin artery. Intimal hyperplasia is represented as less dense islets of tissue imaged as intraluminal black spots by the struts

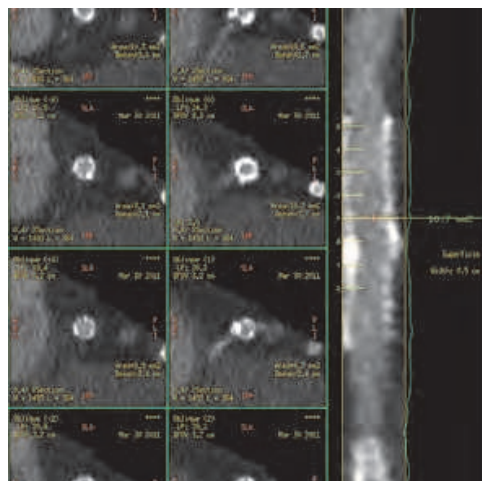


Fig. 3b) 64-CT angiography of the same Obtuse Margin artery in a cross sectional and a longitudinal (right) view

6. The intravascular ultrasound study of oral rapamycin to reduce restenosis after bare metal stent implantation

The aim of our study was to verify if rapamycin, an antiproliferative and anti-inflammatory drug given orally at a dosage of 2 mg/day for one month was capable to reduce intimal hyperplasia in bare metal stents at 6-month after implantation. Intima hyperplasia in the stented segment of the coronary artery was detected and measured using the intravascular ultrasound technique.

6.1 Methods and results

In this placebo-controlled randomized study, 108 consecutive patients (164 lesions) were enrolled in two groups: oral Rapamycin (54 patients, 83 lesions; 4 mg loading dose on the day of the procedure followed by 2 mg daily for 30 days) and Placebo (54 patients, 81 lesions; 2 mg daily of sodium bicarbonate for 30 days). The angiographic in-segment binary restenosis rate

at follow-up angiography was the primary study endpoint. Restenosis was significantly reduced from 36.8% in the Placebo group to 14.3% in the Rapamycin group ($p=0.003$).

6.2 Intravascular ultrasound analysis

Image acquisition was performed in all cases with a 2.6F 40 MHz Atlantis (Boston Scientific, Natick, Ma) mechanical intravascular ultrasound (IVUS) catheter, interfaced to an Insight III ultrasound console (Cardio Vascular Imaging Systems, Boston Scientific, Natick, Ma). The guidewire was threaded through a short monorail close to the probe. The imaging catheter was then advanced beyond the stented segment, as far as possible, after intracoronary injection of 200 μ g nitroglycerin and after administration of heparin 5000 IU. Motorized transducer pullbacks were performed at a speed of 0.5 mm/sec and recorded on S-VHS videotapes for off-line quantitative analysis.

Videotaped recordings of IVUS pullbacks were digitalized by using Echo-CMS (Medis, The Netherlands), a Windows-based 3D image acquisition software. The IVUS pullback and frame-grabbing rates were constant, and each segment obtained thus represented a 200 μ m-thick slice. We used QCU-CMS (Medis, The Netherlands), a contour detection program for automated 2D and 3D IVUS analysis of the digitalized segment. Two-dimensional parameters were measured in all slices of the stented segment, and proximal and distal reference segments, according to the ACC Consensus Document for Intravascular

Ultrasound. Volume data was then calculated as $V = \sum_{i=1}^n A_i \times H$, in which V = volume

(lumen, stent or vessel), A = area in each slice, H = slice thickness, and n = number of analyzed slices.

All IVUS analyses were performed by an independent core lab (Mediolanum Cardio Research, Milan, Italy) blinded to the patients' treatment.

6.3 Study endpoints and definitions

Intravascular ultrasound end-points were the volume of neointimal hyperplasia, minimum residual stent area and percentage in-stent volume obstruction, obtained after IVUS analysis by dividing IH volume by stent volume.

The primary end-point was the rate of binary restenosis (percentage diameter stenosis >50%) at 6-month angiographic follow-up.

Additional end-points were the 18-month rates of target vessel failure: death, myocardial infarction (new onset of Q waves on a 12-lead ECG, or CK enzyme elevation > 2 upper limit of normality, with CK-MB fraction >5%), and repeat target vessel revascularization, including coronary artery bypass graft surgery and percutaneous coronary intervention. Intravascular ultrasound end-points were the volume of neointimal hyperplasia, minimum residual stent area, and percentage in-stent volume obstruction, obtained after IVUS analysis by dividing IH volume by stent volume (Figure 4a and Figure 4b).

6.4 Statistical analysis

All analyses were performed on an intention-to-treat basis. Kolmogorov-Smirnov test was used to assess variables normality. Normally distributed variables were compared by Student's T-test, whereas the Mann-Whitney U-test was utilized for not normally distributed variables.

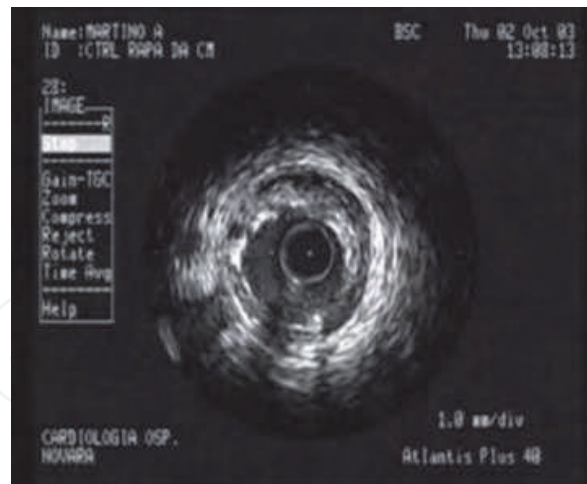


Fig. 4a) Cross sectional IVUS image of a coronary artery of a patient 6 month after BMS implantation and rapamycin medication: no visible intimal hyperplasia across the stent struts

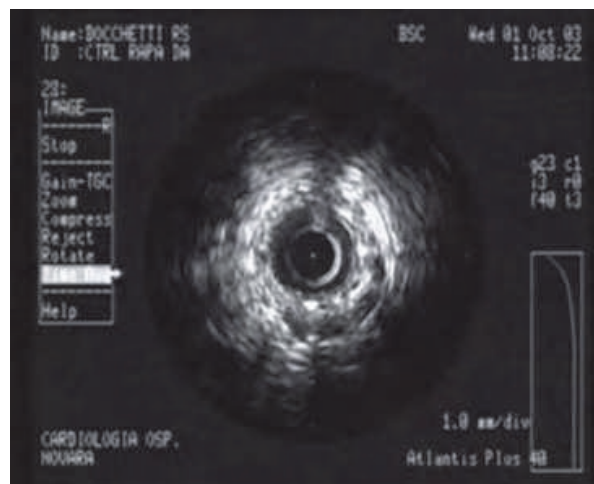


Fig. 4b) Cross sectional IVUS image of a coronary artery of a patient 6 month after BMS implantation and placebo medication: abundant intimal hyperplasia encroaches the stent struts

Discrete baseline characteristics were compared with the use of the chi-square test, Yates corrected when necessary. Statistical significance was accepted for a value of $p < 0.05$. Data analysis were performed by SPSS statistical software (version 12.0; SPSS Inc, Chicago, IL).

6.5 Results

Intravascular ultrasound analysis was performed in a total of 93 lesions, 48 in the Rapamycin group and 45 lesions in the Placebo group. The two groups were similar with regard to all baseline clinical and angiographic characteristics. IVUS was attempted but not performed due to inability to advance the catheter across the restenotic lesion in 6 cases (11.1%) in the Rapamycin group and 4 cases (8.2%) in the Placebo group ($p = ns$). The results for the IVUS analysis at 6-month follow-up are summarized in Table 1.

Serum Rapamycin dosage was performed in a total of 53 patients. Serum Rapamycin levels > 5 ng/ml have been reported to be associated to a lower rate of restenosis. In our series, binary

in-stent restenosis was significantly higher in patients with rapamycin blood concentration < 5 ng/ml than in patients with > 5 ng/ml rapamycin (33.3% vs. 7.7%, p=0.044).

	Rapamycin (n=48 lesions)	Placebo (n=45 lesions)	<i>p</i>
Mean Vessel CSA (mm ²)	18.70 ± 5.71	16.18 ± 4.32	0.043
Mean Stent CSA (mm ²)	8.93 ± 3.13	7.27 ± 2.35	0.007
Minimum Stent CSA (mm ²)	7.59 ± 2.94	6.20 ± 1.94	0.033
Stent Length (mm)	15.2 ± 7.58	14.5 ± 5.38	ns
Stent Volume (mm ³)	139.2 ± 83.1	111.1 ± 62.9	ns
Minimum Lumen CSA (mm ²)	4.76 ± 2.84	3.68 ± 1.79	0.031
Intimal Hyperplasia Volume (mm ³)	28.04 ± 24.9	33.46 ± 32.4	ns
% Volume Obstruction	18.06 ± 10.7	27.06 ± 15.7	0.008

CSA: cross-sectional area.

Table 1. Results for the IVUS analysis at 6-month follow-up.

There were no serious adverse events during the 18-month period of follow-up. Significant changes in the serum creatinine, cholesterol, triglyceride as well as red and white blood cell counts, fibrinogen, ESR, hepatic enzymes at 15, 30 days and 6 month were not observed. Two patients, one in the Rapamycin group and one in the placebo group, respectively 2 weeks and 3 weeks after treatment, stopped the medication because of severe heartburn.

6.6 Discussion

Purpose of our study was to evaluate the anti-restenotic properties of orally administered Rapamycin after bare metal stent placement, assessed by quantitative angiography and intravascular ultrasound analysis performed at 6 month follow-up angiography, and by assessing the clinical event rates at 5-year follow-up. This study demonstrates that oral administration of Rapamycin at the doses tested results in statistically significant inhibition of neo-intimal hyperplasia, with a reduction in binary restenosis from 36.8% to 14.3% at 6-month follow-up. Percentage volume obstruction at follow-up IVUS was reduced from 27% in the Placebo Group to 18% in the Rapamycin Group. This was associated with a reduction in target vessel failure at 18-month clinical follow-up respectively from 38.8% to 24.1%.

Rapamycin is a macrolide analogue that binds to and inhibits mTOR (mammalian Target of Rapamycin), which is a kinase ultimately involved in the phosphorylation of the 40S ribosomal subunit. By inhibiting mTOR, Rapamycin halts cell proliferation by blocking the cell cycle in the G1/S phase. Experimental studies have shown that Rapamycin inhibits vascular smooth muscle cell proliferation, migration, and differentiation, thus leading to an inhibition of intrastent neointimal hyperplasia proliferation, and consequently a reduced restenosis rate.

6.7 Conclusion

Our study shows that oral administration of Rapamycin at the doses tested results in an inhibition of neointimal hyperplasia at 6-month angiographic and IVUS follow-up, after

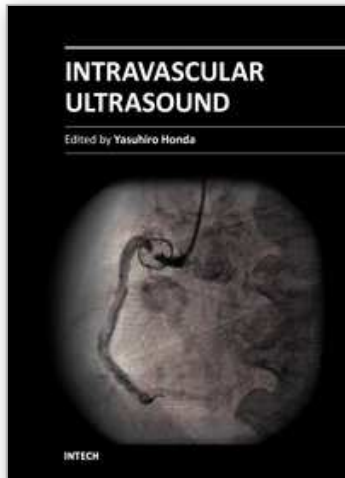
coronary stent placement for de novo native coronary artery lesions. This leads to a reduction in angiographic restenosis, and clinical events, mainly target lesion revascularization, which persists at 5-year follow-up. The degree of inhibition of NIH achieved by orally administered Rapamycin appears inferior to that achieved by locally delivered Rapamycin from drug-eluting stents. An optimization of the dosage regimen is still necessary. However, oral administration of Rapamycin associated to bare metal stent implantation could be a competitive strategy even in the drug-eluting stent era. Randomized clinical trials comparing these strategies are warranted. Another possible direction is combination therapy between orally administered Rapamycin and drug-eluting stents in patient or lesion subsets at particularly high risk of restenosis.

7. References

- Bailey S.R. (1997) Local drug delivery: current applications. *Prog Cardiovasc Dis*, Vol.40, pp. 183-204.
- Brara P.S., Moussavian M., Grise M.A., Fernandez M., Schatz R.A. & Brara P.S. (2003) Pilot trial of oral rapamycin for recalcitrant restenosis. *Circulation*, Vol.107, pp. 1722-4.
- Brito F.S., Rosa W.C., Arruda J.A., Tedesco H., Pestana J.O. & Lima V.C. (2005) Efficacy and safety of oral sirolimus to inhibit in-stent intimal hyperplasia. *Catheter Cardiovasc Interv*, Vol.64, pp. 413-8.
- Cernigliaro C., Sansa M., Vitrella G., Verde A., Bongo A.S., Giuliani L. and Novelli E. (2010) Preventing restenosis after implantation of bare stents with oral rapamycin: a randomized angiographic and intravascular ultrasound study with a 5-year clinical follow-up. *Cardiology*, Vol.115, pp. 77-86.
- Chaves A.J., Sousa A.G., Mattos L.A., Abizaid A., Feres F., Staico R., Centemero M., Tanajura L.F., Abizaid A.C., Rodrigues A., Paes A., Mintz G.S. & Sousa J.E. (2005) Pilot study with an intensified oral sirolimus regimen for the prevention of in-stent restenosis in de novo lesions: a serial intravascular ultrasound study. *Catheter Cardiovasc Interv*, Vol.66, pp. 535-40.
- Daemen J., Wenaweser P., Tsuchida K., Abrecht L., Vaina S., Morger C., Kukreja N., Jüni P., Sianos G., Hellige G., van Domburg R.T., Hess O.M., Boersma E., Meier B., Windecker S. & Serruys P.W. (2007) Early and late coronary stent thrombosis of sirolimus-eluting and paclitaxel-eluting stents in routine clinical practice: data from a large two institutional cohort study. *Lancet*, Vol.369, pp. 667-78.
- Fischman D.L., Leon M.B., Baim D.S., Schatz R.A., Savage M.P., Penn I., Detre K., Veltri L., Ricci D., Nobuyoshi M., et al. (1994) A randomised comparison of coronary stent placement and balloon angioplasty in the treatment of coronary artery disease. *N Engl J Med*, Vol.331, pp. 496-501.
- Fox D.J., Reckless J., Lingard H., Warren S. & Grainger D.J. (2009) Highly potent, orally available anti-inflammatory broad-spectrum chemokine inhibitors. *J Med Chem*, Vol.52, pp. 3591-5.
- Gallo R., Padurean A., Jayaraman T., Marx S., Roque M., Adelman S., Chesebro J., Fallon J., Fuster V., Marks A. & Badimon J.J. (1999) Inhibition of intimal thickening after balloon angioplasty in porcine coronary arteries by targeting regulators of the cell cycle. *Circulation*, Vol.99, pp. 2164-70.

- Grüntzig A.R., Senning A. & Siegenthaler WE. (1979) Non-operative dilatation of coronary artery stenosis: percutaneous transluminal coronary angioplasty. *N Engl J Med*, Vol.301, pp. 61-68.
- Guarda E., Marchant E., Fajuri A., Martínez A., Morán S., Mendez M., Uriarte P., Valenzuela E., Lazen R. (2004) Oral rapamycin to prevent human coronary stent restenosis: a pilot study. *Am Heart J*, Vol.148:e9.
- Hausleiter J., Kastrati A., Mehilli J., Vogeser M., Zohnhöfer D., Schühlen H., Goos C., Pache J., Dotzer F., Pogatsa-Murray G., Dirschinger J., Heemann U. & Schömig A.; OSIRIS Investigators. (2004) Randomized, double-blind, placebo-controlled trial of oral sirolimus for restenosis prevention in patients with in-stent restenosis: the Oral Sirolimus to Inhibit Recurrent In-stent Stenosis (OSIRIS) trial. *Circulation*, Vol.110, pp. 790-5.
- Jennings D.L. & Kalus J.S. (2010) Addition of cilostazol to aspirin and a thienopyridine for prevention of restenosis after coronary artery stenting: a meta-analysis. *J Clin Pharmacol*, Vol.50, pp. 415-21.
- Kuchulakanti P. & Waksman R. (2004) Therapeutic potential of oral antiproliferative agents in the prevention of coronary restenosis. *Drugs*, Vol.64, pp. 2379-88.
- Munk P.S., Staal E.M., Butt N., Isaksen K. & Larsen A.I. (2009) High-intensity interval training may reduce in-stent restenosis following percutaneous coronary intervention with stent implantation A randomized controlled trial evaluating the relationship to endothelial function and inflammation. *Am Heart J*, Vol.158, pp. 734-41.
- Rodríguez A.E., Alemparte M.R., Vigo C.F., Pereira C.F., Llaurodo C., Russo M., Virmani R. & Ambrose J.A. (2003) Pilot study of oral rapamycin to prevent restenosis in patients undergoing coronary stent therapy: Argentina Single-Center Study (ORAR Trial). *J Invasive Cardiol*, Vol.15, pp. 581-4.
- Rodríguez A.E., Rodríguez Alemparte M., Vigo C.F., Fernández Pereira C., Llaurodo C., Vetcher D., Pocovi A. & Ambrose J. (2005) Role of oral rapamycin to prevent restenosis in patients with de novo lesions undergoing coronary stenting: results of the Argentina single centre study (ORAR trial). *Heart*, Vol.91, pp. 1433-7.
- Rodríguez A.E., Granada J.F., Rodríguez-Alemparte M., Vigo C.F., Delgado J., Fernández-Pereira C., Pocovi A., Rodríguez-Granillo A.M., Schulz D., Raizner A.E., Palacios I., O'Neill W., Kaluza G.L. & Stone G.; ORAR II Investigators. (2006) Oral rapamycin after coronary bare metal stent implantation to prevent restenosis: the Prospective, Randomized Oral Rapamycin in Argentina (ORAR II) Study. *J Am Coll Cardiol*, Vol.47, pp. 1522-9.
- Rodríguez A.E. (2009) Emerging drugs for coronary restenosis: the role of systemic oral agents the in stent era. *Expert Opin Emerg Drugs*, Vol.14, pp. 561-76.
- Rodríguez A.E., Maree A., Tarragona S., Fernández-Pereira C., Santaera O., Granillo A.M., Rodríguez-Granillo G.A., Russo-Felssen M., Kukreja N., Antoniucci D., Palacios I.F. & Serruys P.W.; ORAR III Investigators. (2009) Percutaneous coronary intervention with oral sirolimus and bare metal stents has comparable safety and efficacy to treatment with drug eluting stents, but with significant cost saving: long-term follow-up results from the randomised, controlled ORAR III (Oral Rapamycin in ARgentina) study. *EuroIntervention*, Vol.5, pp. 255-264.
- Ross R., Raines E.W. & Bowen-Pope D.F. (1986) The biology of platelet-derived growth factor. *Cell*, Vol.46, pp. 155-69.

- Serruys P.W., Jaegere P., Kiemeneij F., Macaya C, Rutsch W, Heyndrickx G, Emanuelsson H, Marco J, Legrand V, Materne P et al. (1994) A comparison of balloon expandable stent implantation with balloon angioplasty in patients with coronary artery disease. *N Engl J Med*, Vol.331, pp. 489-495.
- Serruys P.W., Degertekin M., Tanabe K., Abizaid A., Sousa J.E., Colombo A., Guagliumi G., Wijns W., Lindeboom W.K., Ligthart J., de Feyter P.J. & Morice M.C.; RAVEL Study Group. (2002) Intravascular ultrasound findings in the multicenter, randomized, double-blind RAVEL (RAndomized study with the sirolimus-eluting VELOCITY balloon-expandable stent in the treatment of patients with de novo native coronary artery Lesions) trial. *Circulation*, Vol.106, pp. 798-803.
- Sigwart U., Puel J., Mirkovitch V., Joffre F. & Kappenberger L. (1987) Intravascular stents to prevent occlusion and restenosis after transluminal angioplasty. *N Engl J Med*, Vol.316, pp. 701-706.
- Stojkovic S., Ostojic M., Nedeljkovic M., Stankovic G., Beleslin B., Vukcevic V., Orlic D., Arandjelovic A., Kostic J., Dikic M. & Tomasevic M. (2010) Systemic rapamycin without loading dose for restenosis prevention after coronary bare metal stent implantation. *Catheter Cardiovasc Interv*, Vol.75, pp. 317-25.
- Schwartz R.S., Huber K.C., Murphy J.G., Edwards W.D., Camrud A.R., Vlietstra R.E. & Holmes D.R. (1992) Restenosis and the proportional neointimal response to coronary artery injury: results in a porcine model. *J Am Coll Cardiol*, Vol.19, pp. 267-74.
- Torguson R., Sabate M., Deible R., Smith K., Chu W.W., Kent K.M., Pichard A.D., Suddath W.O., Satler L.F. & Waksman R. (2006) Intravascular brachytherapy versus drug-eluting stents for the treatment of patients with drug-eluting stent restenosis. *Am J Cardiol*, Vol.98, pp. 1340-4.
- Waksman R., Ajani A.E., Pichard A.D., Torguson R., Pinnow E., Canos D., Satler L.F., Kent K.M., Kuchulakanti P., Pappas C., Gambone L., Weissman N., Abbott M.C. & Lindsay J. (2004) Oral rapamycin to inhibit restenosis after stenting of de novo coronary lesions: the Oral Rapamune to Inhibit Restenosis (ORBIT) study. *J Am Coll Cardiol*, Vol.44, pp. 1386-92.
- Waksman R., Pakala R., Baffour R., Hellings D., Seabron R., Kolodgie F. & Virmani R. (2006) Optimal dosing and duration of oral everolimus to inhibit in-stent neointimal growth in rabbit iliac arteries. *Cardiovasc Revasc Med*, Vol.7, pp. 179-84.
- Williams L.T. (1989) Signal transduction by the platelet-derived growth factor receptor. *Science*, Vol. 243, pp. 1564-70.



Intravascular Ultrasound

Edited by Dr. Yasuhiro Honda

ISBN 978-953-307-900-4

Hard cover, 207 pages

Publisher InTech

Published online 01, February, 2012

Published in print edition February, 2012

Intravascular ultrasound (IVUS) is a cardiovascular imaging technology using a specially designed catheter with a miniaturized ultrasound probe for the assessment of vascular anatomy with detailed visualization of arterial layers. Over the past two decades, this technology has developed into an indispensable tool for research and clinical practice in cardiovascular medicine, offering the opportunity to gather diagnostic information about the process of atherosclerosis in vivo, and to directly observe the effects of various interventions on the plaque and arterial wall. This book aims to give a comprehensive overview of this rapidly evolving technique from basic principles and instrumentation to research and clinical applications with future perspectives.

How to reference

In order to correctly reference this scholarly work, feel free to copy and paste the following:

Carmelo Cernigliaro, Mara Sansa, Federico Nardi and Eugenio Novelli (2012). Oral Rapamycin to Reduce Intimal Hyperplasia After Bare Metal Stent Implantation - A Prospective Randomized Intravascular Ultrasound Study, *Intravascular Ultrasound*, Dr. Yasuhiro Honda (Ed.), ISBN: 978-953-307-900-4, InTech, Available from: <http://www.intechopen.com/books/intravascular-ultrasound/oral-rapamycin-to-reduce-intimal-hyperplasia-after-bare-metal-stent-implantation-a-prospective-rando>

INTECH
open science | open minds

InTech Europe

University Campus STeP Ri
Slavka Krautzeka 83/A
51000 Rijeka, Croatia
Phone: +385 (51) 770 447
Fax: +385 (51) 686 166
www.intechopen.com

InTech China

Unit 405, Office Block, Hotel Equatorial Shanghai
No.65, Yan An Road (West), Shanghai, 200040, China
中国上海市延安西路65号上海国际贵都大饭店办公楼405单元
Phone: +86-21-62489820
Fax: +86-21-62489821

© 2012 The Author(s). Licensee IntechOpen. This is an open access article distributed under the terms of the [Creative Commons Attribution 3.0 License](#), which permits unrestricted use, distribution, and reproduction in any medium, provided the original work is properly cited.

IntechOpen

IntechOpen