

# We are IntechOpen, the world's leading publisher of Open Access books Built by scientists, for scientists

**4,800**

Open access books available

**122,000**

International authors and editors

**135M**

Downloads

Our authors are among the

**154**

Countries delivered to

**TOP 1%**

most cited scientists

**12.2%**

Contributors from top 500 universities



**WEB OF SCIENCE™**

Selection of our books indexed in the Book Citation Index  
in Web of Science™ Core Collection (BKCI)

Interested in publishing with us?  
Contact [book.department@intechopen.com](mailto:book.department@intechopen.com)

Numbers displayed above are based on latest data collected.

For more information visit [www.intechopen.com](http://www.intechopen.com)



# Intravascular Ultrasound (IVUS) and Clinical Applications

T. Ozcan  
*Mersin University, Faculty of Medicine,  
Department of Cardiology, Mersin  
Turkey*

## 1. Introduction

### 1.1 Intravascular ultrasound (IVUS) and clinical applications

Atherosclerosis is a chronic disease potentially involving the whole vascular system that causes a spectrum of clinical manifestations ranging from stable angina to acute myocardial infarction or stroke. The continuous accumulation of lipids, inflammatory and/or fibrous elements in the arterial wall leads to progressive lumen narrowing. Acute coronary syndromes (acute myocardial infarction, unstable angina) have a complex and dynamic pathogenesis with coronary plaque rupture. Some plaques lead to clinical events whereas many others remain asymptomatic for life, different imaging modalities have been applied to define the atherosclerotic burden and the anatomical characteristics of unstable or vulnerable lesions.

The vascular response to endothelial dysfunction is a well-orchestrated inflammatory response triggered by the accumulation of macrophages within the vessel wall. The formation of such vulnerable plaques prone to rupture underlies the majority of cases of acute myocardial infarction. The complex molecular and cellular inflammatory cascade is orchestrated by the recruitment of T lymphocytes and macrophages and their paracrine effects on endothelial and smooth muscle cells (1). Molecular imaging in atherosclerosis has evolved into an important clinical and research tool that allows in vivo visualization of inflammation and other biological processes. Several recent examples demonstrate the ability to detect high-risk plaques in patients, and assess the effects of pharmacotherapeutics in atherosclerosis (2).

Intravascular ultrasound (IVUS) performed with an ultrasound machine that has been especially adapted to intravascular imaging. The machine can be permanently affixed in the catheterization lab or can be portable and moved from one catheterization room to another as needed. The IVUS catheter is attached to the ultrasound machine through an interface that ensures sterility of the catheter. Intravascular ultrasound is an exciting technology that allows in-vivo visualization of vascular anatomy by utilizing a miniature transducer. The IVUS catheter can be advanced into different vascular structures including peripheral arteries, coronary arteries, and intracardiac chambers. Intracoronary ultrasound has become particularly useful in further delineating plaque morphology and distribution, and providing a rationale to guide transcatheter coronary interventions (3). The reflected ultrasound from the intima is displayed as a single concentric echo. All of the ultrasound, however, is not reflected

by the intima; some will penetrate through to the media. Since the media is composed primarily of homogeneous smooth muscle cells, ultrasound passes through with minimal reflection and appears as a dark zone devoid of echoes. The adventitia, is highly reflective because it has numerous collagen fibers laid down in parallel, thereby producing multiple interfaces from which to reflect sound. The adventitia will appear very bright. As a result, the normal coronary anatomy produces alternating bright and dark echoes:

1-A bright echo from the intima, 2-A dark zone from the media, 3-Multiple bright echoes from the adventitia

This pattern is called the normal "three layer appearance" of a coronary artery (4). The three-layer appearance is actually a simplified view since the IVUS resolution (approximately 120 microns) is not sufficient to detect the truly nondiseased intima (one or two cell layers thick or approximately 50 microns). The tomographic cross-sectional view of the artery is ideal to discern concentric from eccentric plaque distribution. This feature makes IVUS far more accurate than angiography for assessing plaque eccentricity (3). Because of the limitations of angiography, hazy angiographic sites could represent an irregular plaque/distorted lumen, a napkin-ring lesion, thrombus, or a dissection. IVUS is particularly useful in this situation because it immediately distinguishes between plaque and lumen irregularities, dissection, or discrete stenosis (5).

IVUS has also demonstrated that apparently normal areas by angiography are often markedly abnormal. One of the areas that IVUS can be useful is Slow coronary flow (SCF). Slow coronary flow is characterized with the late opacification of the epicardial coronary arteries without occlusive disease (6,7). It was first described by Tambe et al. in 1972 (10). In 1973, Kemp et al. suggested it to be a variant of "syndrome X" (11). However, SCF differs in a distinct manner in which is a phenomenon characterized by delayed opacification of epicardial coronary arteries in the absence of epicardial occlusive disease. The exact etiology, pathogenesis and long term outcome of SCF patients is still unknown. Endothelial and vasomotor dysfunction, microvascular dysfunction, and occlusive disease of small coronary arteries were suggested in its etiology (8-17). The carotid artery intima-media thickness (CIMT) is the best known sonographic marker for early atherosclerotic vascular wall lesions (18). Previous cross-sectional studies in different populations have shown that, increase in CIMT is associated with cardiovascular event prevalence (19-25). Additionally, CIMT increase was strongly and significantly correlated with myocardial infarction and stroke incidence (26). Angiography depicts only 2D silhouette of the lumen, whereas IVUS allows tomographic assessment of lumen area, plaque size, distribution, and composition. In young subjects, normal intimal thickness is typical 0.15 mm (27). Intravascular ultrasound (IVUS) can detect intimal thickening of the coronary arteries and is suitable for detection of early atherosclerosis that cannot be detected by conventional angiography (28-30).

In addition Intravascular ultrasound (IVUS) is useful during stent implantation to assess lesion severity, length, and morphology before stent implantation; to optimize stent expansion, extension, and apposition; and to identify and treat possible complications after stent implantation (31). Most of the evidence from the era of bare-metal stents indicates that IVUS guidance offers incremental information leading to lower rates of angiographic restenosis and repeat revascularization (32). In the current era of drug-eluting stents (DES) with ensuing low restenosis rates, the relationship between IVUS-guided DES implantation and clinical outcomes is less well established.

In cases of coronary dissection, IVUS can distinguish atherosclerotic plaques from intramural hematoma and also detect the media dissection, false and true lumen and, if present, the intimal flap. Treatment of spontaneous dissection in particular is often especially challenging, since it commonly affects young individuals with little or no atherosclerotic burden. Therapy has traditionally been guided by clinical and angiographic findings. However, in small series of patients IVUS has been proven useful in the context of interventional treatment (33).

There are some controversies between the results of the studies which compared the CIMT values of SCF patients and normal subject. A previous study shows that patients with SCF have a significantly increased carotid IMT compared with those with normal coronary flow (34). But recent studies do not support this result (35). The investigated these values with comparing the IVUS and TIMI frame counts. Measurements of CIMT using ultrasound assess the extent and the severity of systemic atherosclerosis. Today, CIMT, measured with high-resolution B-mode ultrasound, is the standard for noninvasive surrogate measurements of atherosclerosis. It has been shown that a direct relation exists between CIMT and clinical cardiovascular disease (19-22). Due to these data, CIMT assessment can be used to document regression or progression of atherosclerosis (19-36). Besides, at least two large epidemiologic studies proposed that increased CIMT values are associated prospectively with increased risk of coronary artery disease (24,25,37). Several studies, CIMT was significantly increased in SCF patients. This would mean the increased risk of coronary, cerebral and peripheral vascular diseases in these patients. However these risks are still not studied enough, and are unknown in this special group of patients. It was shown another study diffuse or regional calcification and intimal thickening in coronary arteries in most of the patients with SCF, despite the absence of angiographically detectable coronary focal stenosis or plaques in them. These results suggest that epicardial coronary arteries were affected as a part of diffuse atherosclerotic disease of all arterial system in this specific group of patients. IVUS imaging can detect early intimal thickening, which cannot be detected by conventional angiography (28-30,38). Some previous studies have shown the evidence of diffuse atherosclerosis despite angiographically normal coronary arteries in syndrome-X patients by intravascular ultrasound (28-30). Pekdemir et al. showed that most patients with SCF had longitudinally extended massive calcification throughout the epicardial coronary arteries. Cin et al. demonstrated that the patients with SCF had diffuse intimal thickening, widespread calcification along the coronary vessel wall, and atheroma which did not cause luminal irregularities in the coronary angiography (39,40). In the present study, according to the findings of IVUS, the speculate that SCF may be a form or preliminary phase of diffuse atherosclerotic process that involve epicardial coronary arteries. However, in a previous study, Chilian et al. (41) have observed enhanced vasoconstrictor response in the monkeys with atherosclerosis and they speculated that the early pathophysiological consequences of atherosclerosis might extend into the microcirculation, which may be another mechanism for SCF. Erdogan et al. (42) suggest that coronary flow reserve (CFR) is impaired in patients with SCF. Impairment of endothelial function and reduced CFR, which reflects coronary microvascular function, has been shown to be early manifestation of atherosclerosis. Mangieri et al. (12) and Kurtoglu et al. [11] have observed remarkable progress in restoring coronary flow when they studied dipyridamole in this group of patients. They concluded the theory that the pathophysiology underlying this disorder is closely related to the microvasculature and has a dynamic character. Near these

results, some other studies have shown the evidence of diffuse epicardial atherosclerosis despite angiographically normal coronary arteries (28-30,43). All these data, however, do not clearly delineate the borders of this disorder neither does it imply any interaction between micro and macrovasculature of the heart. In the present study, the correlation of TIMI frame count and the CIMT and coronary intima-media thickness suggest the atherosclerosis would be the pathophysiological mechanism of the disease. However, it is impossible to conclude any suggestion about microvascular pathology. The occurrence of myocardial ischemia was only sporadically demonstrated in these patients. It is concluded that most of these patients continue to experience regular and/or worsening chest pain despite reassurance that they do not have obstructed coronary arteries (44).

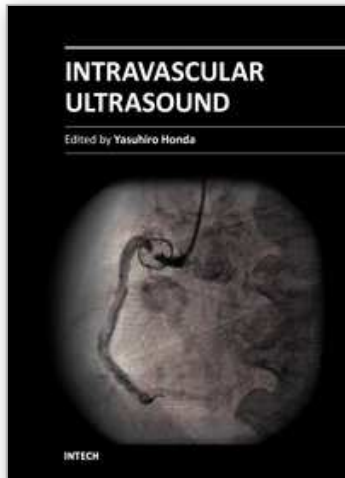
Prior to IVUS, only the lumen of a vessel could be visualized in vivo with angiography or angiography. IVUS extends our capability to visualize and assess the size of the vessel, should it be devoid of atherosclerotic disease. Prior to a discussion of the applications of IVUS, it is important to appreciate the added information provided by this procedure when compared with conventional angiography for the assessment of coronary artery disease. Today intravascular ultrasound (IVUS) offers qualitative details on plaque composition, like hard and soft components, that are helpful to assess unstable lesions. As a result, the appropriate indications and clinical cases provide important information.

## 2. References

- [1] Andersson, J., Libby, P., *et al.* Adaptive immunity and atherosclerosis. *Clin Immunol.* 134 (1), 33-46 (2010).
- [2] Jaffer, F. A., Libby, P. *et al.* Molecular Imaging of Cardiovascular Disease. *Circulation.* 116 (9), 1052-1061 (2007).
- [3] Yock, P, Fitzgerald, P, Popp, R. Intravascular ultrasound. *Sci Am Science Med* 1995; 2:68.
- [4] Fitzgerald, PJ, St Goar, FG, Connolly, AJ, *et al.* Intravascular ultrasound imaging of coronary arteries: is three layers the norm? *Circulation* 1992; 86:154.
- [5] Ziada, KM, Tuzcu, EM, De Franco, AC, *et al.* Intravascular ultrasound assessment of the prevalence and causes of angiographic "haziness" following high-pressure coronary stenting. *Am J Cardiol* 1997; 80:116.
- [6] Lierde JV, Vrolix M, Sionis D, De Geest H, Piessens J. Lack of evidence for small vessel disease in a patient with "slow dye progression" in the coronary arteries. *Cathet Cardiovasc Diagn* 1991;23:117-20
- [7] Yigit F, Sezgin AT, Demircan S, *et al.* Slow coronary flow is associated with carotid artery dilatation. *Tohoku J Exp Med* 2006;209:41-8.
- [8] Tambe AA, Demany MA, Zimmerman HA, Mascarenhas E. Angina pectoris and slow flow velocity of dye in coronary arteries—a new angiographic finding. *Am Heart J* 1972;84:66-71.
- [9] Kemp Jr HG, Vokonas PS, Cohn PF, Gorlin R. The anginal syndrome associated with normal coronary arteriograms. Report of a 6-year experience. *Am J Med* 1973;54:735-42.
- [10] Vrints C, Herman AG. Role of the endothelium in the regulation of coronary artery tone. *Acta Cardiol* 1991;46:399-418.
- [11] Mosseri M, Yarom R, Gotsman MS, Hasin Y. Histologic evidence for small vessel coronary artery disease in patients with angina pectoris and patent large coronary arteries. *Circulation* 1986;74:964-72.

- [12] Mangieri E, Macchiarelli G, Ciavolella M, et al. Slow coronary flow: clinical and histopathological features in patients with otherwise normal epicardial coronary arteries. *Cathet Cardiovasc Diagn* 1996;37:375–81.
- [13] Kurtoglu N, Akcay A, Dindar I. Usefulness of oral dipyridamole therapy for angiographic slow coronary artery flow. *Am J Cardiol* 2001;87:777–9.
- [14] Motz W, Vogt M, Rabenau O, et al. Evidence of endothelial dysfunction in coronary resistance vessels, in patients with angina pectoris and normal coronary angiograms. *Am J Cardiol* 1991;68:996–1003.
- [15] Quyyumi AA, Cannon III RO, Panza JA, Diodati JG, Epstein SE. Endothelial dysfunction in patients with chest pain and normal coronary arteries. *Circulation* 1992;86:1864–71.
- [16] Egashira K, Inou T, Hirooka Y, et al. Evidence of impaired endothelium-dependent coronary vasodilatation in patients with angina pectoris and normal coronary angiograms. *N Engl J Med* 1993;328:1659–64.
- [17] Zeiher AM, Krause T, Schachinger V, Minners J, Moser E. Impaired endothelium-dependent vasodilation of the coronary resistance vessels is associated with exercise-induced myocardial ischaemia. *Circulation* 1995;91:2345–52.
- [18] Kaslival RR, Bansal M, Bhargava K, Gupta H, Tandon S. Carotid intima-media thickness and brachial-ankle pulse wave velocity in patients with and without coronary artery disease. *Indian Heart J* 2004;56(2):117–22.
- [19] For the ARIC Study Group. Arterial wall thickness is associated with prevalent cardiovascular disease in middle-aged adults. *Stroke* 1995;26:386–91.
- [20] Kronmal RA, Smith VE, O'Leary DH, et al. Carotid artery measures are strongly associated with left ventricular mass in older adults (a report from the Cardiovascular Health Study). *Am J Cardiol* 1996;77:628–33.
- [21] Mattace Raso F, Rosato M, Talerico A, Cotronei P, Mattace R. Intimal-medial thickness of the common carotid arteries and lower limbs atherosclerosis in the elderly. *Minerva Cardioangiol* 1999;47:321–7.
- [22] Mannami T, Baba S, Ogata J. Strong and significant relationships between aggregation of major coronary risk factors and the acceleration of carotid atherosclerosis in the general population of a Japanese city. *Arch Intern Med* 2000;160:2297–303.
- [23] Hodis HN, Mack WJ, LaBree L, et al. The role of carotid arterial intima-media thickness in predicting clinical coronary events. *Ann Intern Med* 1998;128:262–9.
- [24] Chambless L, Heiss G, Folsom AR, et al. Association of coronary heart disease incidence with carotid arterial wall thickness and major risk factors: the atherosclerosis risk in communities (ARIC) study. *Am J Epidemiol* 1997;146:483–94.
- [25] Newman AB, Naydeck B, Sutton-Tyrell K, et al. Coronary artery calcification in older adults with minimal clinical or subclinical cardiovascular disease. *J Am Geriatr Soc* 2000;48:256–63.
- [26] For the Cardiovascular Health Study Collaborative Research Group. Carotid artery intima and media thickness as a risk factor for myocardial infarction and stroke in older adults. *N Engl J Med* 1999;340:14–22.
- [27] Steven E. Nissen, Paul Yock. Intravascular ultrasound: novel pathophysiological insight and current clinical applications. *Circulation* 2001;103:604–16.
- [28] Nakatani S, Yamagishi M, Tamai J, et al. Assessment of coronary artery distensibility by intravascular ultrasound application of simultaneous measurements of luminal area and pressure. *Circulation* 1995;91:2904–10.

- [29] Mintz GS, Painter JA, Pichard AD, et al. Atherosclerosis in angiographically “normal” coronary artery reference segments: an intravascular ultrasound study with clinical correlations. *J Am Coll Cardiol* 1995;25:1479-85.
- [30] Tuzcu EM, Kapadia SR, Tutar E, et al. High prevalence of coronary atherosclerosis in asymptomatic teenagers and young adults evidence from intravascular ultrasound. *Circulation* 2001;103:2705-10.
- [31] Mintz GS, Nissen SE, Anderson WD, et al. American College of Cardiology clinical expert consensus document on standards for acquisition, measurement and reporting of intravascular ultrasound studies (IVUS). A report of the American College of Cardiology Task Force on Clinical Expert Consensus Documents. *J Am Coll Cardiol* 2001; 37:1478 -92.
- [32] Parise H, Maehara A, Stone GW, Leon MB, Mintz GS. Metaanalysis of randomized studies comparing intravascular ultrasound versus angiographic guidance of percutaneous coronary intervention in the pre-drug-eluting stent era. *Am J Cardiol* 2011;107:374-82.
- [33] Arnold JR, West NE, van Gaal WJ, Karamitsos TD, Banning AP. The role of intravascular ultrasound in the management of spontaneous coronary artery dissection. *Cardiovasc Ultrasound*.2008; 6: 24.
- [34] Tanriverdi H, Evrengul H. Carotid intima.-media thickness in coronary slow flow: relationship with plasma homocysteine levels. *Coron Artery Dis* 2006;17(4):331-7.
- [35] Yigit F, Sezgin AT, Demircan S, et al. Slow coronary flow is associated with carotid artery dilatation. *Tohoku J Exp Med* 2006;2091:41-8.
- [36] Ishizu T, Ishimitsu T, Kamiya H, et al. The correlation of irregularities in carotid arterial intima-media thickness with coronary artery disease. *Heart Vessels* 2002;17(1):1-6.
- [37] Cerne A, Kranjec I. Atherosclerotic burden in coronary and peripheral arteries in patients with first clinical manifestation of coronary artery disease. *Heart Vessels* 2002;16(6):217-26.
- [38] Kawano S, Yamagishi M, Hao H, Yutani C, Miyatake K. Wall composition in intravascular ultrasound layered appearance of human coronary artery. *Heart Vessels* 1996;11(3):152-9.
- [39] Pekdemir H, Polat G, CinVG, et al. Elevated plasma endothelin-1 levels in coronary sinus during rapid right atrial pacing in patients with slow coronary flow. *Int J Cardiol* 2004;97:35-41.
- [40] Cin VG, Pekdemir H, Camsarı A, et al. Diffuse intimal thickening of coronary arteries in slow coronary flow. *Jpn Heart J* 2003;44:907-19.
- [41] Chillian WM, Dellsperger KC, Layne SM, et al. Effects of atherosclerosis on the coronary microcirculation. *Am J Physiol* 1990;258:529-39.
- [42] Erdogan D, Caliskan M, Gullu H, et al. Coronary flow reserve is impaired in patients with slow coronary flow. *Atherosclerosis* 2007;191:168-74.
- [43] Nissen SE, Gurley JC, Grines CL, et al. Intravascular ultrasound assessment of lumen size and wall morphology in normal subjects and patients with coronary artery disease. *Circulation* 1991;84:1087-99.
- [44] Przybojewski JZ, Becker PH. Angina pectoris and acute myocardial infarction due to “slow-flow phenomenon” in nonatherosclerotic coronary arteries: a case report. *Angiology* 1986;37:751-61.



## **Intravascular Ultrasound**

Edited by Dr. Yasuhiro Honda

ISBN 978-953-307-900-4

Hard cover, 207 pages

**Publisher** InTech

**Published online** 01, February, 2012

**Published in print edition** February, 2012

Intravascular ultrasound (IVUS) is a cardiovascular imaging technology using a specially designed catheter with a miniaturized ultrasound probe for the assessment of vascular anatomy with detailed visualization of arterial layers. Over the past two decades, this technology has developed into an indispensable tool for research and clinical practice in cardiovascular medicine, offering the opportunity to gather diagnostic information about the process of atherosclerosis in vivo, and to directly observe the effects of various interventions on the plaque and arterial wall. This book aims to give a comprehensive overview of this rapidly evolving technique from basic principles and instrumentation to research and clinical applications with future perspectives.

### **How to reference**

In order to correctly reference this scholarly work, feel free to copy and paste the following:

T. Ozcan (2012). Intravascular Ultrasound (IVUS) and Clinical Applications, Intravascular Ultrasound, Dr. Yasuhiro Honda (Ed.), ISBN: 978-953-307-900-4, InTech, Available from:  
<http://www.intechopen.com/books/intravascular-ultrasound/intravascular-ultrasound-ivus-and-clinical-applications>

**INTECH**  
open science | open minds

### **InTech Europe**

University Campus STeP Ri  
Slavka Krautzeka 83/A  
51000 Rijeka, Croatia  
Phone: +385 (51) 770 447  
Fax: +385 (51) 686 166  
[www.intechopen.com](http://www.intechopen.com)

### **InTech China**

Unit 405, Office Block, Hotel Equatorial Shanghai  
No.65, Yan An Road (West), Shanghai, 200040, China  
中国上海市延安西路65号上海国际贵都大饭店办公楼405单元  
Phone: +86-21-62489820  
Fax: +86-21-62489821



© 2012 The Author(s). Licensee IntechOpen. This is an open access article distributed under the terms of the [Creative Commons Attribution 3.0 License](#), which permits unrestricted use, distribution, and reproduction in any medium, provided the original work is properly cited.

IntechOpen

IntechOpen