

# We are IntechOpen, the world's leading publisher of Open Access books Built by scientists, for scientists

4,800

Open access books available

122,000

International authors and editors

135M

Downloads

Our authors are among the

154

Countries delivered to

TOP 1%

most cited scientists

12.2%

Contributors from top 500 universities



WEB OF SCIENCE™

Selection of our books indexed in the Book Citation Index  
in Web of Science™ Core Collection (BKCI)

Interested in publishing with us?  
Contact [book.department@intechopen.com](mailto:book.department@intechopen.com)

Numbers displayed above are based on latest data collected.  
For more information visit [www.intechopen.com](http://www.intechopen.com)



# Hypothermic Cardiac Arrest to Remove Right Atrial Thrombi Due to Abdominal Malignancies

Pier Luigi Stefano, Stefano Romagnoli,  
Donata Villari and Giacomo Batignani  
*Università degli Studi di Firenze,  
Italy*

## 1. Introduction

The first use of hypothermia in cardiac surgery is attributed to Dr. John Lewis who performed an atrial septal defect closure on September 2, 1952 at the University of Minnesota (Gott, 2005).

Cardiopulmonary by-pass (CPB) and hypothermic cardio-circulatory arrest (HCCA) has been introduced for the first time in clinical practice for aortic arc substitution (Pierangeli et al., 1974). More recently the same technique has been proposed to remove atrial thrombi originated from renal carcinomas (Marshall et al., 1984), adrenal carcinomas (Shahinian et al., 1989), hepatocellular carcinoma (Hamazaki et al., 1995) and other abdominal malignancies such as caval leiomyosarcoma, uterine endometrial sarcoma or intravenous leiomyomatosis, ovarian or testicular tumors (Hassan et al., 2010; Vargas-Barron et al., 1990; Ariza et al., 1982; Kanda et al., 1991).

There is still a debate pro and cons the use of hypothermic arrest with some favours the normothermic (Lubahn et al., 2006; Stewart et al., 1991) and some others the hypothermic, because of the operative field appears better exposed and almost completely bloodless so the blood loss resulted much lower. Furthermore they claim a better visualization of some critical areas with an easier removal of the tumoural thrombus, that may invade the hepatic veins or the coronaric sinus, may either remain attached to the tricuspid valve or may have embolized into the pulmonary artery (Chiappini et al., 2002; Kalkat et al., 2008; Leo et al., 2010; Topcuglu et al., 2004). In all these occasions HCCA offers the possibility of a better tumoural cleaning with the possibility of R0 resection. The incomplete removal of this tumoural thrombi in fact is correlated to an early recurrence and a worst postoperative survival (Skinner et al., 1989). Furthermore the hepatic, renal and splenic damage from warm ischemia due to the Pringle's manoeuvre and/or aortic/mesenteric cross-clamping (usually necessary when CPB is used without cardio-circulatory arrest) is reduced when the HCCA is instead used (Chiappini et al., 2002, Davlourous et al., 2005). This permits its use even in the setting of mild hepatic damage (Leo et al., 2010).

## 2. Kidney

Tumour thrombus extension in the inferior vena cava (IVC) occurs in 4 % to 10% of patients with renal cell carcinoma (RCC) (Marshall et al., 1988). The cephalic extension of tumour

thrombus in RCC was first defined in 1987 by Neves and Zincke (Neves & Zincke, 1987) and classified in four levels (level I : thrombus at the level of the renal vein, level II : thrombus extending into the infra-hepatic IVC, level III : thrombus extending into the retro-hepatic IVC, level IV : intra-atrial thrombus (suprahepatic IVC involvement or right atrium thrombus). Libertino classification system (Moinzadeh & Libertino, 2004) distinguishes: renal vein only involvement, level I caval involvement (IVC below the diaphragm), level II caval involvement (IVC above the diaphragm) and level III involvement (when the thrombus reaches the atrium).

Recently an updated staging system by the American Joint Committee on Cancer (AJCC) and the "Union International Contre le Cancer" (UICC) was utilized and the current staging, according to the 2009 UICC/AJCC TNM staging classification system, designates renal vein involvement as pT3a Level III, when the thrombus involves the intra-hepatic portion of the IVC but below the diaphragm is designated as p T3b, while level IV when the thrombus extends above the diaphragm, as T3c. The thrombus may extend as far as the right atrium (IV level) in 1% of patients with RCC. Accurate information about the presence and complete extent of IVC involvement is essential for surgical planning. Routine CT scanning and abdominal ultrasonography are less reliable in delineating the cephalic extent of the thrombus. Contrast inferior venacavography is an accurate, but invasive, diagnostic tool and a single antegrade study may be insufficient in complete caval obstruction. Occasionally has been employed trans oesophageal echocardiography and trans-abdominal colour flow Doppler ultrasonography. MRI has become the preferred, non invasive, diagnostic study though its frequent inability to differentiate actual invasion of the vena cava wall which is generally associate with a poor prognosis. Contrast inferior venography is reserved for patients in whom MRI findings are equivocal or for whom MRI is contraindicated. Another option in this group of patients is multiplanar CT.

Renal arteriography is useful in the preoperative study because it may highlighted a distinct vascularisation of the thrombus (observed in 35% to 40% of the cases) allowing to perform a preoperative embolization of the kidney, causing the shrinkage of the thrombus and its more easily intra-operative removal.

The prognostic significance of venous involvement and tumour thrombus level remains highly controversial. According to the literature in the absence of metastasis, when adjusting for clinical and pathologic features, radical nephrectomy with total tumour thrombus excision in patients with RCC and level I to III vena caval involvement is associated with a cancer specific 5 -year survival rate between 47% and 68% (Staheler & Brkovic, 2000; Belis et al., 2000).

Some authors generally accepted that neoplastic extension in the IVC was not a prognostic determining factor (Libertino et al., 1987; Skinner et al., 1989; Ciancio et al., 2010). Some others, more recently, have shown that tumour thrombus level is an independent predictor of survival (Martínez-Salamanca et al., 2011).

RCC with vascular invasion into the IVC, direct invasion of the vein's wall appears to be an important prognostic factor and should be noted during tumour staging. With no perinephric fat or lymph nodal involvement, patients who undergo tumour excision with radical nephrectomy and IVC thrombectomy have an overall and cancer specific 5-year survival of 30% to 72% with an operative mortality of 2.7% to 13.5 %. When the thrombus locally invades the wall of the vena cava, aggressive resection of the vascular wall with reconstruction along with the attainment of negative surgical margins provides a survival

benefit (Hatcher et al., 1991). Grafting or reconstitution sometimes is required only in those patients with not complete occlusion of IVC and collateral blood flow. In 1913, Berg first described nephrectomy and vena caval thrombectomy as primary surgical treatment of these patients (Berg, 1913). Usually, in level I and II disease the tumour thrombus can safely be excised by means of proximal and distal control of the IVC. In level III and IV disease the exposure and isolation of IVC requires liver mobilization with or without the use of CBP. Several techniques have been used during the years to remove large caval thrombi when distal caval control cannot be achieved below the liver such as cross-clamping of the supraceliac aorta (Cummings et al., 1979), occlusion of the intra pericardial vena cava with simultaneous occlusion of the "porta hepatis" and superior mesenteric artery (Skinner et al., 1989), use of an intraoperative venous (cava-atrial) shunt (Foster et al., 1988), and cardiopulmonary by pass alone (Novick & Cosgrove, 1980). The use of CBP alone is limited to the period during which the liver and the kidneys undergo warm ischemia. Skinner and co-workers reported an average warm ischemia of 14 minutes ranging from 8 to 20 minutes. Post operative complications occurred in 41% to 60% of the patients and included transient hyperbilirubinemia, renal dysfunction and respiratory failure (Skinner et al., 1989). When the thrombus extends above the diaphragm the use of CPB with deep HCCA have been used. Marshall et al., 1984 and Krane et al., 1984 first demonstrated the feasibility of this approach. The most common post operative complications related to this procedure are haemorrhage, coagulopathy, increased transient and/or permanent neurologic risk. Novick et al., 1990 in their experience reported up to 60 minutes of safe ischemia with direct visual inspection of the entire vena caval lumen in a bloodless field reducing risk of sudden massive intra-operative haemorrhage or distal pulmonary tumour Thrombo-embolization. Operative mortality rate reported was 4.7% (Novick et al., 1990). Heart surgery have been used more frequently to treat intra-cardiac extension of infra-diaphragmatic tumours and the safety of this procedure has increased. Chiappini and co-workers in their series of 13 patients reported no in-hospital deaths while 2 patients experienced postoperative complications such as respiratory failure and bleeding (Chiappini et al., 2002). On the other side, Ruel and co-workers in 2001 reported their experience in cavo-atrial thrombus excision in 6 patients affected by RCC without circulatory arrest (Ruel et al., 2001). During the last 10 years the traditional approach using CBP and HCCA was revisited. Deep hypothermic circulatory arrest was therefore not considered imperative and some studies reported that its avoidance may decrease morbidity and mortality. Shinghal et al., in 2003 reported in a single patient a novel technique by placing an aortic occlusive balloon in the abdominal aorta at the level of the diaphragm, limiting flow in the IVC and maintaining both cerebral and spinal cord perfusion during cardiopulmonary bypass (Shingai et al., 2003). In 2005 Ciancio & Soloway described a technique that can be safely used to approach RCC with a tumour thrombus extending into the supra-diaphragmatic IVC and right atrium through a trans-abdominal approach without sternotomy and/or cardiopulmonary bypass utilizing a complete liver mobilization and minimizing the vena caval cross-clamp time. The trans-abdominal incision exposes the intra-pericardial IVC and right atrium trans-diaphragmatically. (Ciancio & Soloway, 2005; Ciancio G, Shirodkar S et al., 2009). Step by step description of this technique based on orthotopic liver transplantation was reported in 2011 by the same author regarding a cohort of 56 patients with retro-hepatic extension of the thrombus and 12 patients with a supra-hepatic/intra atrial localizations. Mean operative time was 5h and 32 min. Five patients required CPB (7.3%). Three patients died

in the immediate post operative period (4.4%) (Ciancio G, Gonzalez J, et al., 2011). In 2007 Chowdhury et al., reported their experience in a cohort of 6 patients with RCC and intra atrial tumour thrombus using mild hypothermic CPB and intermittent cross-clamping of the supra-celiac abdominal aorta (Chowdhury et al., 2007)

RCC with vascular invasion into the IVC remains a crucial challenge to the urologic oncologist. Complete excision of the tumour together with the thrombus and negative margins offers the best chance for patients survival. Surgical resection of these complex tumours requires multidisciplinary approach.

### **2.1 Adrenal**

The use of CPB to remove the tumour thrombus from adrenocortical carcinoma (ACC) was first reported in 1976 (Scully et al., 1976) while the first procedure using HCCA was in 1989 (Shahian et al., 1989) but because of the poor prognosis of this tumour at this stage and the technical difficulties that has to be faced such as the invasion of surrounding organs and vascular control/reconstruction, radical surgical resection remains controversial. A recent review from France (Chiche et al., 2006) collected the outcome of 32 patients reported in literature with cavo-atrial invasion in whom a CPB was used in 26 including 6 under HCCA. Reported peri-operative mortality was 3/26 (11.5%) and took place in patients operated using CPB alone.

In their own series of ACC with tumour thrombi extending into the vena cava or in the right atrium, they reported the outcome of 15 patients treated by a combination of venous control ranging from cross clamping to hepatic vascular exclusion or normo/ipothermic cardiopulmonary by-pass. The extension grade C (above the liver) was in 7 patients, including 4 with atrial thrombi and represents the 7% of the overall series. Of these patients 3 had HCCA and 1 (33.3%) died p.o. from multi-organ failure but the patient was cirrhotic with a portal thrombosis.

They concluded that CPB should always be used for tumours extending to the cavo-atrial junction or into the right atrium and additional HCCA provides a bloodless field that allow a precise dissection of the thrombus while reducing the blood loss.

### **2.2 Liver**

Macroscopic vascular invasion (either portal or supra-hepatic) is a major complication of hepatocellular carcinoma (HCC). Major vascular invasion is the evolution of microscopic vascular invasion over the time so the liver tumour is of the large type at diagnosis and usually require major liver resection.

The natural history of HCC complicated with macroscopic vascular invasion of the portal vein, shows a median survival time of only 9 to 10 weeks (Okada et al., 1992).

Treatments with systemic chemotherapy, intra-arterial chemotherapy or radiofrequency ablation result in a dismal survival at 1 year ranging from 7% to 18% (Raul et al., 1994; Akashi et al., 1991; Poon et al., 2003). Hepatic resection remains the only option for these patients and a recent multicentric study showed that, resected patients lived longer, compared to those not treated surgically, with a five-year survival rate of 10% (Pawlik et al., 2005; Lin et al., 2007).

Liver tumour with extension to the hepatic veins represents instead a controversial issue and its extension in the right atrium (RA) via the inferior vena cava is more uncommon,

with percentage of incidence reported of 2.9% by imaging techniques, 0.7% at operation, and 18.2% at autopsy in Japan (Yogita et al., 2000).

Therapeutics options at this stage are few and debatable because of the high risk for lung metastasis (Masaki et al., 1995) but, on the other hand, the risk of developing a "ball valve syndrome" (Hahne & Climie, 1962) or a pulmonary embolism is very high (Fujisaki et al., 1991). The overall survival time of these patients with cavo-atrial thrombi and who do not undergo operative treatment is reported to be very low: from 3 days to 2 months (Lin et al., 2007).

Liver resection and cavo-atrial thrombectomy remains, in this situation, the only effective therapeutic option with reported survival time ranging from 5 to 56 months (Miyazawa et al., 2005).

The first authors describing the removal of a tumoural thrombus in the RA from HCC on cirrhosis using CPB were Goto et al. in 1986 who removed only the thrombus. Fujisaki et al. in 1991 first removed the thrombus along with the primary tumour using CPB hepatic vascular exclusion while Hamazaki et al. in 1995 added the use of HCCA in a similar situation. Indeed, HCCA was first applied in liver surgery, in a young child to remove atrial thrombi from hepatoblastoma, which usually occurs on a normal liver parenchyma, in 1981 (Ein et al., 1981).

The majority of patients with HCC has a diseased liver because of the presence of hepatitis viruses infection and /or previous alcohol abuse. The presence of hepatic vein, vena cava and atrial thrombosis contraindicate liver transplantation and, liver resection with thrombectomy, is the only real therapeutic option in this setting (Wu et al., 2000). As previously stated, acute pulmonary embolism or congestive heart failure may complicate liver tumours involving hepatic vein with tumours thrombi in the inferior vena cava/right atrium. This latter situation represent an impending life-threatening condition that should be surgically treated as soon as possible (Novick et al., 1990).

Atrial thrombus removal may be achieved under normothermic CPB and total liver vascular exclusion. Tolerance of the cirrhotic liver to normothermic ischemia is reported as safe up to 33 minutes (Huguet et al., 1994) which is quite similar to the safety time reported to avoid neurological complications when using HCCA (McCullough et al., 1999).

Extracorporeal circulation with HCCA has been increasingly used to remove atrial thrombi due to retroperitoneal malignancies (Ogata et al., 2006) but its use in cirrhotic patients has been limited, for many years, because of the fear of post-operative liver failure and poor outcome. However, in more recent time, we have assisted to an increase number of reports where HCCA has been used to remove cavo-atrial thrombi due to HCC with no mortality and low morbidity, probably, lower than expected thus, we can assume that, a short lasting HCCA, has to be considered safe in a well compensated liver cirrhosis (Novick et al., 1990; Yogita et al., 2000; Ohwada et al., 2008; Florman et al., 2009; Leo et al., 2010).

Since the vast majority of patients with HCC and atrial tumour thrombi has large type of HCC, a major liver resection is usually required and the possibility of postoperative liver failure raises accordingly, liver function tests and indocyanin green retention test, should be carried out in these patients in order to demonstrate the presence of a good functional reserve (Kawasaki et al., 1995). Furthermore we think that adding a sequential arterial and portal embolization of a hemi-liver could lessen the possibilities of post-operative liver failure when a major resection is planned (Ogata et al., 2006).

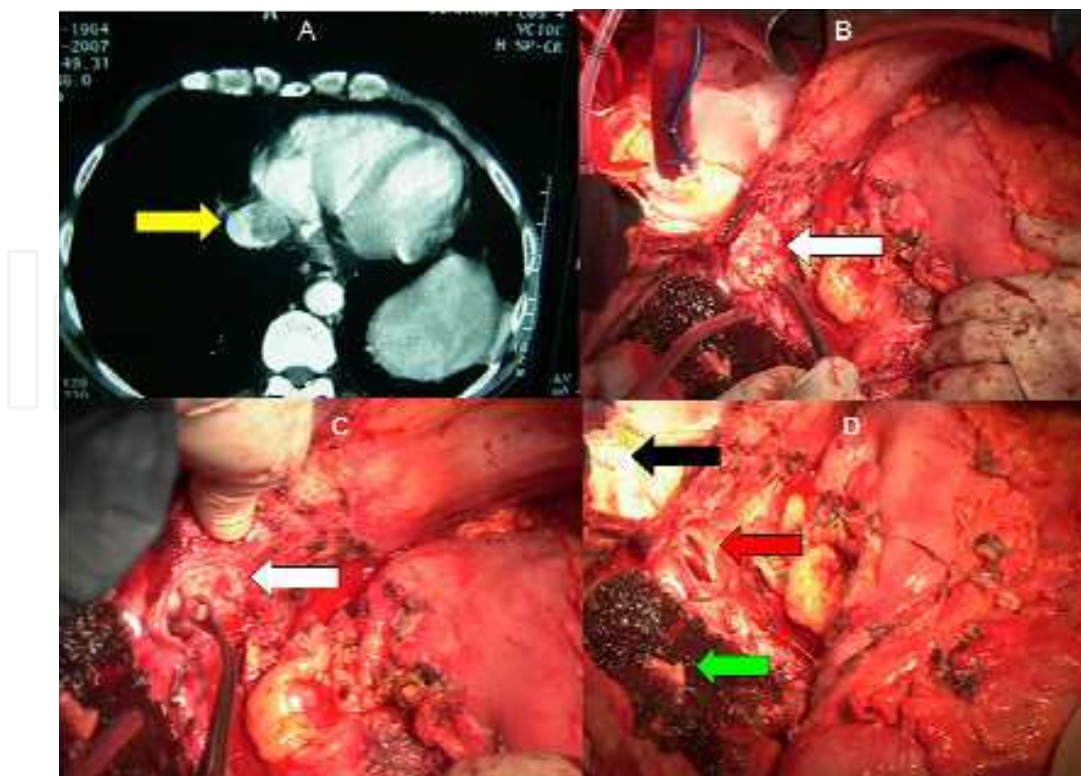


Fig. 1. A: Ct scan of a cavo-atrial tumour thrombus (yellow arrow). B and C: Extraction of the thrombus, after a left hemi-hepatectomy, from the sectioned left and middle hepatic vein ostium (white arrow) using a rings clamps to pull and an index finger, inserted from the atriotomy site, to push the thrombus downward. D: Cleaned ostium (red arrow), closed atriotomy (black arrow) and distal middle hepatic vein stump (green arrow) to be reconstructed. Please note the completely bloodless field of the procedure under hypothermic cardiocirculatory arrest.

### 2.3 Uterus

The uterus is seldom the site of origin of a cavo-atrial thrombi owing to two distinct tumours: the endometrial stromal sarcoma (ESS) and the “benign” intravenous leiomyomatosis (IVL). This latter situation differs from the other types of neoplastic thrombi because the endovascular material is represented mainly by myofibroblastic cells, growing into the vessel, rather than by a neoplastic thrombotic apposition.

#### 2.3.1 Endometrial stromal sarcoma

ESS represents only the 0.2% of all uterine malignancies and it has been described to invade the great vessels rarely. In a recent review only 9 patients had a tumour thrombus reaching the right atrium, ventricle or the pulmonary artery that underwent radical resection by means of total abdominal hysterectomy and thrombectomy. Normothermic CPB was reported in 7 out of the 9 patients with only 1 (14.3%) complication due to renal acute tubular necrosis. No perioperative deaths were reported (Renzulli et al., 2008).

#### 2.3.2 Intravenous leiomyomatosis

IVL is an uncommon “benign” tumour of middle age parous women arising from either the uterine venous wall or uterine leiomyoma (Nam et al., 2002). It is known also as benign

metastatic fibro-leiomyoma because pulmonary nodules (proliferating leiomyocytes) are often present. Although this tumour is usually confined to the pelvis, it sometime extends to the right cardiac cavities through the iliac vein and the vena cava (Wakiyama et al., 2000) by means of intra-vascular proliferation and growth of fibro-myocytes which results in an extension of the fibro-leiomyoma rather than in a thrombus formation conferring a typical consistency and resistance to traction to the endo-vascular proliferation (Galajda et al., 2010). IVL with cardiac extension is an exceedingly rare disease first reported in 1907 in an autopsy series (Durk, 1907). Since then a further 34 cases have been reported involving the right heart (Wakiyama et al., 2000). Patients often have a history of hysterectomy or leiomyoma resection and various lengths of intravascular proliferation up to 29 cm with a diagnosis performed up to 18 yrs after the primary surgery (Galajda et al., 2010). Complete surgical removal of the uterus and IVL is the therapy of choice (Topcoglu et al., 2004) and it has been carried out for the first time in 1974 using CPB and HCCA (Mandelbaum et al., 1974).

We came across a similar case (Fig. 2) in whom we performed a total abdominal hysterectomy and IVL removal through a cavotomy and atriotomy under CPB and HCCA (Fig. 3). Due to the typical consistency of IVL and the usual absence of adhesions the complete heart and retro-hepatic vena cava cleaning was achieved by simple traction from the infra-renal cavotomy site (Fig. 3A) while the iliac portion was stacked and required separate iliac vein incision.

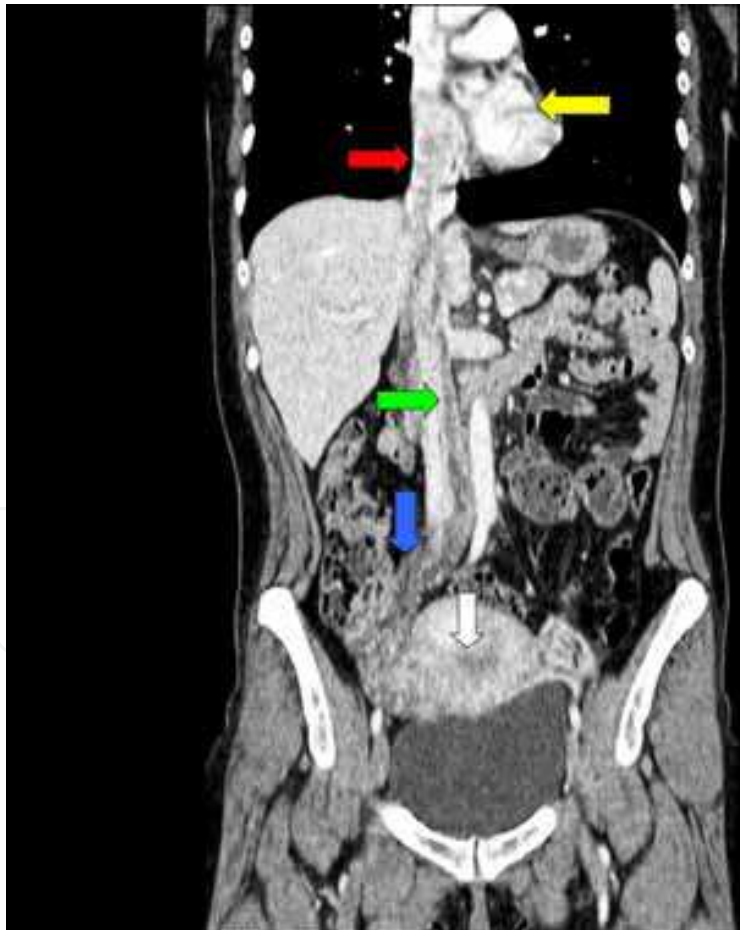

Fig. 2. Preoperative ct scan of intra-vascular leiomyomatosis arising from uterine leiomyoma (white arrow) extending to the right iliac vein (blue arrow), infra and retro-hepatic vena cava (green arrow), right atrium (red arrow) and to the right ventricle (yellow arrow).



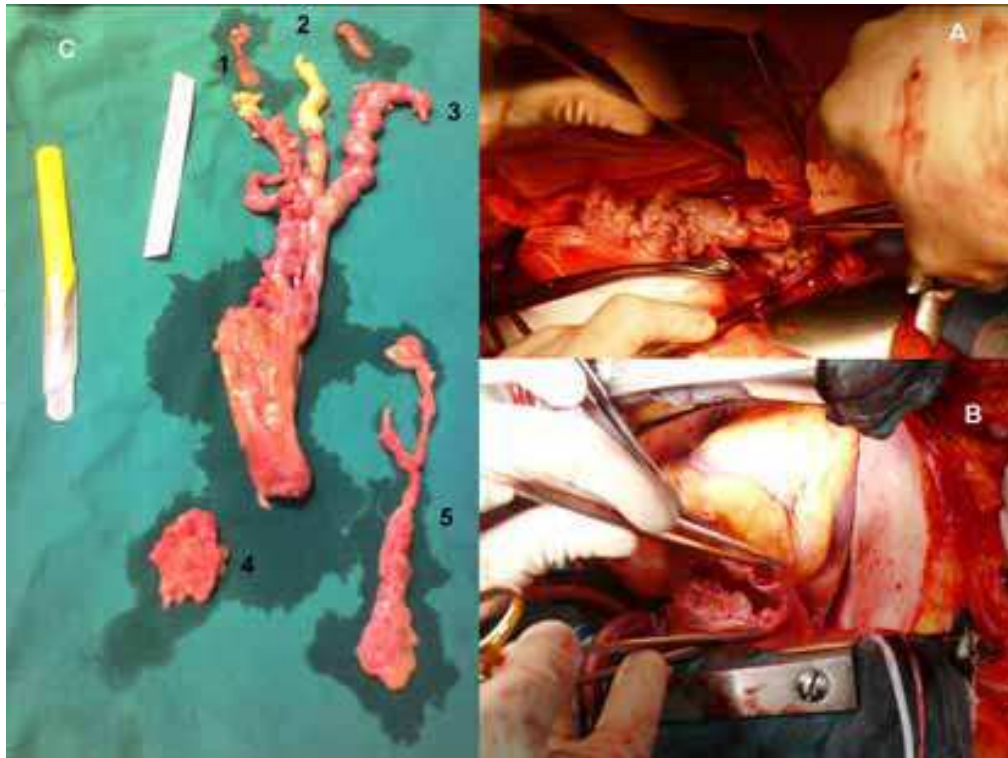


Fig. 3. Same Patient of figure 2. Operative view of the removal, through a cavotomy (A) and atriotomy (B), of intravascular leiomyomatosis. Operative specimen removed is shown in C: 1 and 2 are the right atrial extensions, 3 the right ventricular extension, 4 the caval iliac extensions and 5 right ovarian vein involvement.

#### 2.4 Vena cava

Leiomyosarcomas of the inferior vena cava (IVC) are rare malignant tumours originating from the smooth muscle cells of the media layer that typically show three growth patterns: extra-luminal, intra-luminal and both (Mingoli et al., 1996). They may be classified anatomically according to Chiappini et al., 2002, as for renal tumours, into four types: Type I infra-hepatic, type II retro-hepatic, type III supra-hepatic IVC and type IV the thrombus extends in the right atrium.

Patient with type IV was treated and reported by Hassan et al., 2010, using normothermic CPB and Pringle's manoeuvre to remove the atrial thrombus reporting mild hyperbilirubinemia and normal renal function. They discussed the possible advantages of the technique used, compared to HCCA which they thought to be associated with an extended CPB time, increased postoperative bleeding and coagulopathy, and increased neurological risk. On the other hand HCCA provides a bloodless surgical field with reduced risk of spreading/embolization, and fatal haemorrhage. Furthermore the advantages include reduced liver and kidney warm ischemia, reduced risk of incomplete excision, optimal visualization of the IVC/right atrial lumen minimizing the need for a too extensive retro-peritoneal dissection (Chiappini et al., 2002).

#### 2.5 Others

Scattered case reports of ovarian haemangioma (Tamburino et al., 1992), testicular tumour (Kanda et al., 1991), embryonal carcinoma of the testis (Paule et al., 1991), testicular teratoma (Moon et al., 1992) and even pancreatic cancer (Ozben et al., 2007) have been reported so far.

The problems when dealing with these situations are almost the same of those reported above and at the moment it is impossible to draw any conclusion due the scarcity of the cases.

### 3. Anesthetic management

In the following sections, an overview of the main technical features for the management of anaesthesia, extracorporeal circulation and hypothermic circulatory arrest for cavo-atrial thrombectomy are summarized.

#### 3.1 Monitoring and anesthesia

Any operative procedure involving large vessels entail the risk of developing hemodynamic instability, mainly due to massive bleeding. Moreover, a number of specific conditions have to be taken into consideration, including coexisting multisystemic diseases, non-physiological conditions associated with CPB and deep HCCA. In light of these concerns, patients undergoing cavo-atrial thrombectomy require extensive monitoring to provide early warning of conditions that may lead to potentially life-threatening states.

##### 3.1.1 Monitoring

An intraoperative electrocardiogram, using the five-leads technique, is the standard monitoring procedure always recommended during surgery and anesthesia. In this setting, it is useful for the diagnosis of both myocardial ischemia ( $D_{II} - V_5$  identify 90% of ischemic episodes) and dysrhythmias.

Intravascular pressure measurements represent the standard technique during this type of surgery. Arterial pressure is usually measured by placing a catheter in a peripheral (radial, ulnar, brachial) or central (femoral) artery. Direct arterial pressure measurement allows monitoring during the pre-CPB stage and nonpulsatile ECC. Moreover, during the post-CPB/HCCA period, patients are usually hemodynamically unstable, and close surveillance of arterial blood pressure, other than with blood-gas analysis, is of primary importance.

A central venous line (internal jugular, subclavian) for pressure monitoring (central venous pressure [CVP]) is influenced by circulating blood volume, venous tone and capacitance, and right ventricular function; therefore, a number of pieces of information can be obtained from the CVP. A central venous catheter (3 lumens, 7-8.5 Fr) can be used for both pressure measurement and inotropic-vasoactive drug administration. Central venous lines can also be used for pulmonary artery catheter (PAC) positioning if the patient's comorbidities suggest the monitoring of pulmonary artery pressures, the measurement of cardiac output and mixed venous oxygen saturation. Central venous cannulation should be performed under ultrasound guidance because up to 30% of patients have some abnormalities of the jugular vein anatomy (Carid et al., 1988; Bevilacqua et al., 2005).

Hemodynamic monitoring is completed with transesophageal echocardiography, which has gained widespread use in cardiac operating rooms (where this intervention for cavo-atrial invasion is usually performed) because it provides a great deal of information about the heart's global performance during systole and diastole, the valve function and cardiac volume loads, as well as morphologic details on thrombotic cardiac invasion from the inferior vena cava.

Temperature monitoring. Assessment of accurate central temperature is of primary importance in this setting. The core temperature (vital organ temperature) can be measured by means of a PAC thermistor, nasopharyngeal probe (provides accurate measurement of brain temperature during CPB and HCCA), bladder probe (it may be inaccurate when renal blood flow and urine output are decreased), CPB arterial line (temperature of the heat exchanger), CPB venous line (reflects core temperature well during CPB, when no active cooling or warming is ongoing), or rectal probe (when the tip of the probe rests in stool, the measurement may be imprecise) (FIG. 4 & 5).

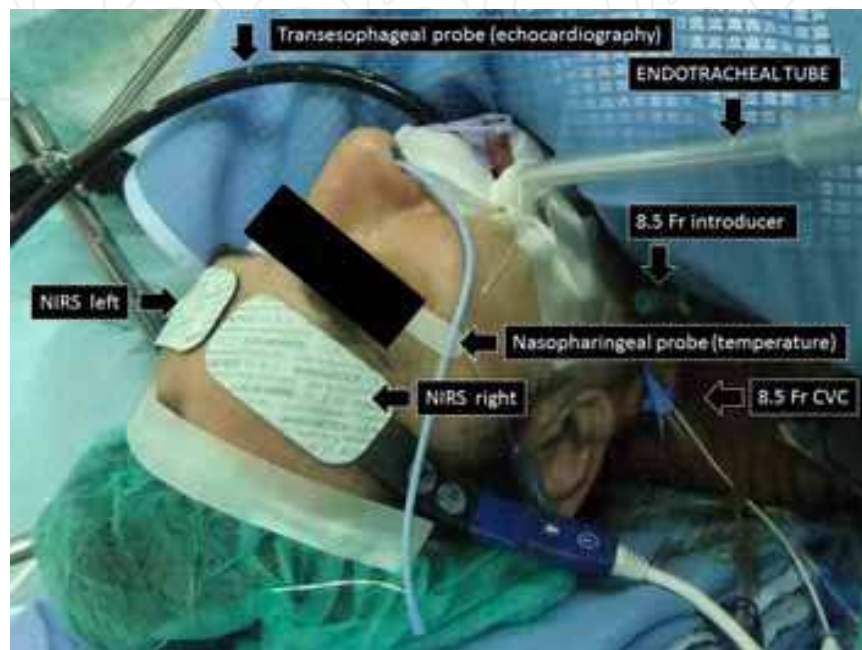

Fig. 4. Monitoring. (NIRS, near infrared spectroscopy; CVC, central venous catheter).

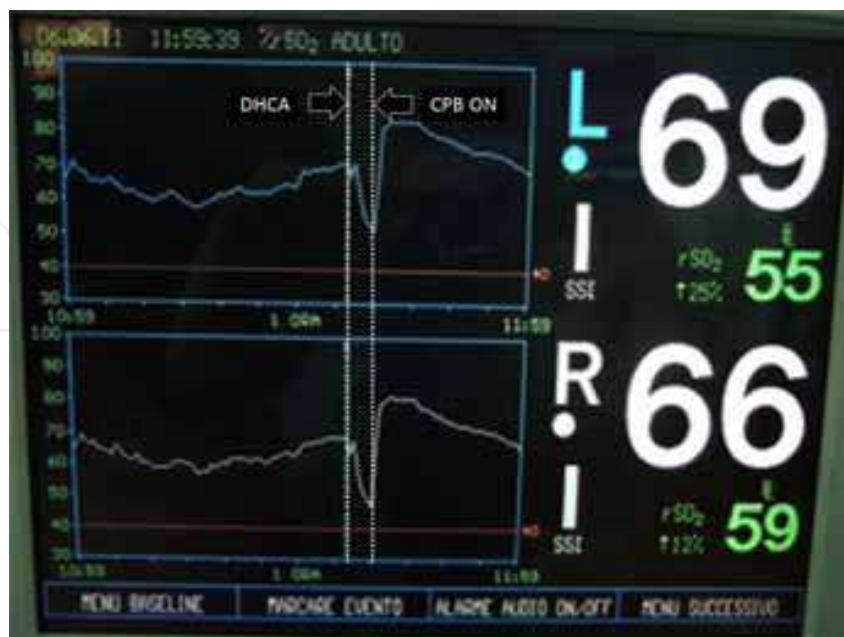

Fig. 5. Near infrared spectroscopy. (DHCA Deep Hypothermic Circulatory Arrest; CPB, cardiopulmonary bypass).

Renal function. Acute kidney injury (AKI) is one of the well-known complications occurring during CPB that has significant implications for both short- and long-term outcomes. The incidence of acute renal failure ranges from 20 to 30% of patients (Kumar & Suneja, 2004). Pre-operative renal function is one of the most important factors related to post-CPB AKI. The major risk factors for AKI after CPB include advanced age, preexisting kidney disease, diabetes mellitus, chronic obstructive pulmonary disease, CPB duration, emergency surgery, female sex, left ventricle ejection fraction <40%, and hemodilution on CPB. Hemolysis always occurs during CPB, and serum hemoglobin levels rise; therefore, urine output should be maintained to avoid tubular damage. Diuretic therapies (mannitol is used routinely in CPB priming) are also useful for eliminating the hemodilution induced with the onset of CPB. As a consequence, urinary catheter positioning and urine output are the best monitoring systems for renal function evaluation.

### 3.1.2 Anesthesia

These patients usually require a smooth induction because wide modifications in vascular tone, myocardial contractility, and reductions in venous returns due to increased intra-thoracic pressures under mechanical ventilation may worsen the organ and tissue perfusion. Midazolam or etomidate, in association with an opioid (remifentanyl, fentanyl), are useful drugs for anesthesia induction; propofol and/or sevoflurane or desflurane can be used for anesthesia maintenance, and a nondepolarizing muscle relaxant should be administered for the duration of the intervention (Table 1).

	<b>Drug</b>	<b>Induction dose</b>
<b>Hypnotics</b>	Propofol	1-1.5 mg/Kg
	Thiopental	3-4 mg/Kg
	Etomidate	0.2-0.3 mg/Kg
	Midazolam	0.1-0.2 mg/Kg
<b>Opioids</b>	Fentanyl	3-10 mcg/Kg
	Sufentanyl	0.5-1 mcg/Kg
	Remifentanyl	0.1-0.75 mcg/Kg/min
<b>Muscle relaxants</b>	Cisatracurium	0.07- 0.1 mg/Kg
	Vecuronium	0.07- 0.1 mg/Kg
	Rocuronium	0.6 mg/Kg

Table 1. Hypnotics, opioids, and muscle relaxants (induction doses)

The choice of drug for anesthesia induction and maintenance depends on the patient's general conditions and, in particular, his/her heart, renal, and liver function. In addition, antibiotic prophylaxis should be administered at least 30 minutes before skin incision.

## 3.2 Cardiopulmonary bypass, deep hypothermic circulatory arrest and neuroprotection

### 3.2.1 Cardiopulmonary bypass

Cardiopulmonary bypass permits blood to bypass the heart and lungs (Fig. 6).

Venous blood is drained by gravity into an oxygenator (artificial lung), and a pump injects it, after oxygenation and removal of CO<sub>2</sub>, into a great artery (aorta, subclavian, femoral artery). Adequate anticoagulation is necessary during the CPB period, and an activated clotting time longer than 420-480 seconds is usually considered safe (the optimal target of

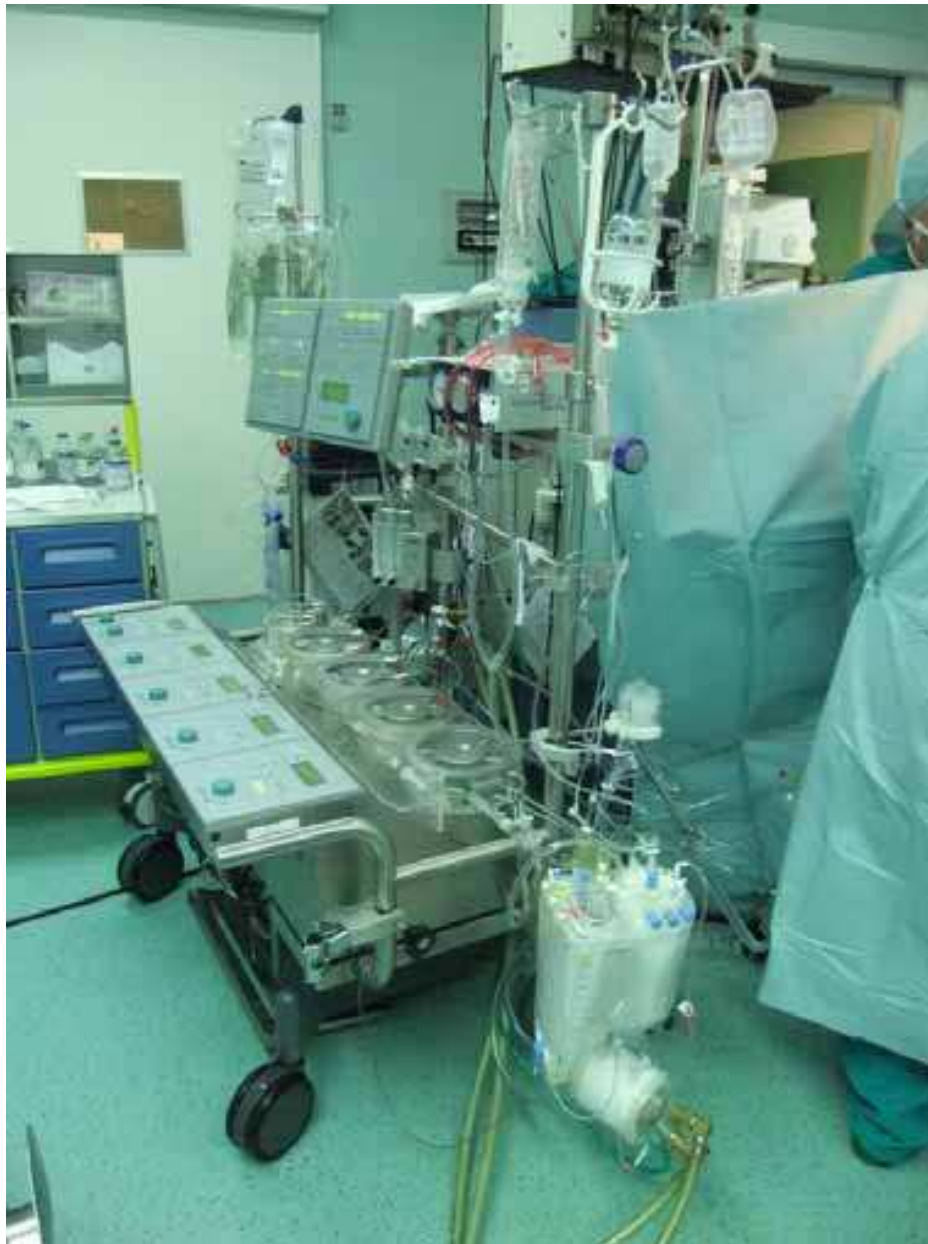

Fig. 6. Cardiopulmonary bypass.

ACT is still debated). Anticoagulation is obtained with heparin 300-400 U/kg, and supplemental doses of 5000 U can be administered if necessary. Use of heparin-coated circuits does not eliminate the need for heparin. The pump flow has to be set at values that guarantee an adequate oxygen delivery. "Normal" pump flow is considered to be 2.4 l/min/m<sup>2</sup>, although recent studies have demonstrated that a redistribution of flow toward organs occurs during CPB in both normothermia and hypothermia (Slater et al., 2001). Muscle flow is significantly reduced during CPB, and if flow is reduced, splenic, renal and cerebral flow decrease as well, in that order. During CPB, blood pressure depends on pump flow, total arterial impedance and haematocrit. During CPB, blood pressure is less important in determining global perfusion if pump flow is adequate, but minimal values of blood pressure may be significant in providing specific regional flows; therefore, during mild to moderate hypothermia (30-34°C), the blood pressure is generally maintained at

approximately 70 mm Hg. During CPB and HCCA, the loss of flow auto regulation (<20°C and for several hours after HCCA) is still debated, but pressure levels as low as 30-40 mm Hg are considered safe values (Croughwell et al., 1992). Despite several techniques for cerebral protection have been developed, central nervous system dysfunction associated with cardiac surgery is very frequent, with an incidence that depends on the type of intervention (up to 65%) (Arrowsmith et al., 2000). Apart from ischemic events, cognitive dysfunction has been observed within the first postoperative week in more than 80% of patients undergoing coronary artery bypass grafting under CPB, and at five years after surgery, some degree of neuropsychological dysfunction can be observed in up to 35% of patients (Arrowsmith et al., 2000). A number of risk factors have been identified, and they can be divided into patient-related and technology-related factors. The patient-related factors are age >70 year old, cerebrovascular disease, aortic atherosclerosis, and diabetes mellitus; the technology-related factors are open chamber procedures, CPB duration >90 minutes, use of bubble rather than membrane oxygenators, and circulatory arrest. Apart from open chamber procedures, all the other risk factors have to be taken into consideration when cavo-atrial thrombectomy with CPB and HCCA is performed.

### 3.2.2 Deep hypothermic circulatory arrest

After CPB has been started, the temporary interruption of cerebral blood flow is a necessary condition to remove the thrombus from the vena cava and, in such cases, from the right atrium. Interruption of cerebral blood flow has been associated with a high incidence of neurologic injury because the brain is susceptible to ischemic injury within minutes of the onset of circulatory arrest as a result of its high metabolic rate and limited reserves (Harrington et al., 2003). The physiologic basis for hypothermia as a neuroprotective strategy is its ability to reduce the cerebral oxygen metabolic rate and the accumulation of toxic metabolites. In adults, a decrease in core temperature leads to a reduction in the cerebral metabolic rate that increases in ischemic tolerance from 2-3 minutes (normothermia) to 20-34 minutes (17°C) (Reich et al., 1999). However, the optimal level of hypothermia is still debated. Studies based on electroencephalographic monitoring have shown that a median nasopharyngeal temperature of 18°C allows electrocortical silence (Stecker et al., 2001). Today, based on the results of several studies, HCCA at 18°C is considered safe for durations of up to 40 minutes (Griep, 2001). It has been also suggested that hypothermia provides neurological protection through mechanisms other than the cerebral metabolic rate. In the face of an incomplete understanding of the involved mechanisms, hypothermia remains the most efficacious intervention for preventing ischemic brain injuries. In addition to systemic hypothermia, topical cooling, obtained by packing the head with ice, can be used to prevent passive warming of the brain during circulatory arrest, but consensus on this adjunctive strategy is still lacking because re-warming during circulatory arrest could be negligible (Reich et al., 1999). After the targeted core temperature has been reached, the pump is turned off, allowing brain protection during surgery performed in a bloodless field. HCCA has several potential adverse consequences. Achieving the target temperature prolongs the duration of the CPB period, thus amplifying problems related to CPB (loss of pulsatile flow, injury to blood elements, risk of embolization, coagulation system derangements, etc.). Re-warming increases the cerebral metabolic rate and has the potential to make the brain vulnerable to ischemic injury. With the aim of limiting brain injuries, a short period (10 minutes) of hypothermic

reperfusion is achieved before re-warming, and maintaining a temperature gradient of less than 10°C in the heat exchanger and avoiding complete re-warming are usually performed. Currently, there is no class of drug representing the standard of practice, but some drugs can be used as adjunctive strategies for cerebral protection. A number of drugs cause EEG burst suppression, resulting in a reduction in the cerebral metabolic rate by approximately 50%, but the most used of these drugs is thiopental at a dose of 5-8 mg/kg. The administration of thiopental results in EEG burst suppression for few minutes at normothermia. Thiopental and/or steroids are administered before circulatory arrest in some centres, without a clear demonstration of beneficial effects.

### 3.2.3 pH management during hypothermia

There is an inverse relationship between gas solubility and blood temperature. When blood temperature decreases, an apparent respiratory alkalosis occurs due to a decrease in PaCO<sub>2</sub> and an increase in pH. To compensate for this PaCO<sub>2</sub> reduction, CO<sub>2</sub> can be added to the oxygenator (pH-stat management) or the CPB gas sweep rate can be reduced. The technique of pH-stat management was commonly used until the mid-1980s, but there is more recent evidence that pH-stat management can increase the incidence of postoperative cognitive dysfunction when CPB lasts longer than 90 minutes (Murkin et al., 1995). It has been suspected that the increase in CO<sub>2</sub> should increase the cerebral blood flow during perfusion phases, uncoupling flow and metabolism. The most used  $\alpha$ -stat (not temperature-correcting) requires that neutrality be maintained at only 37°C, and it permits hypothermic alkaline drift. Thus, additional CO<sub>2</sub> is not needed. Cellular trans-membrane pH gradients, protein functioning, and enzyme activity are more normal when the pH is allowed to drift into the alkaline range, in parallel with the temperature-dependent pKa of protein and the neutral pH of water. Moreover, a relatively alkaline pH is beneficial before the ischemic insult of circulatory arrest. Despite considerable laboratory and animal research into these mechanisms, substantial controversy remains over which strategy produces the best clinical outcomes (Duebener et al., 2002).

### 3.2.4 Coagulation management

Coagulation system management during and after CPB is based on the administration of heparin, followed by neutralization with protamine, and this approach has been unchanged for almost 50 years. Heparin binds to antithrombin-III (AT-III), potentiating the action of AT-III (more than 1000-fold) to inhibit thrombin and factor Xa most importantly (but also factors IXa, XIa, and XIIa). After central venous administration, heparin's effect peaks within 1 minute. The onset of CPB increases the circulating blood volume by approximately 1500 ml, reducing the heparin blood concentration; therefore, 5000 U of heparin are added to the CPB prime. Before CPB, heparin is administered at a dose of 300-400 U/kg to obtain ACT for 420-480 seconds, and successive supplemental doses are guided by monitoring the ACT. Some centres monitor blood heparin concentrations. ACT is prolonged by hypothermia and hemodilution. After CPB weaning is successfully achieved and a satisfactory spontaneous circulation is restored, heparin anticoagulation must be reversed with protamine administration. The most used protamine-heparin ratio is 0.6-1 mg/100 U. Protamine must always be administered slowly to prevent adverse hemodynamic effects. After protamine administration, ACT should return to a value no more than 10% above the basic value. If more prolonged, heparin residual activity is likely, and additional doses of protamine

should be administered. During CPB, antifibrinolytic agents ( $\xi$ -aminocaproic acid or tranexamic acid) have beneficial effects in restoring coagulation equilibrium. Antifibrinolytics act as lysine analogues that bind to the lysine-binding sites of plasmin and plasminogen.  $\xi$ -aminocaproic acid can be administered at a dose of 100-150 mg/kg in bolus form, followed by 10-15 mg/kg/h or a 50 mg/kg bolus followed by 20-25 mg/kg/h. Tranexamic acid can be administered at a dose of 10-20 mg/kg followed by 1-2 mg/kg/h, although some centres prefer a 5 g bolus and repeat bolus to a total of 15 g. Post-bypass bleeding is common after CPB/HCCA. Evaluation of haemostasis and correct intervention are key factors for preventing indiscriminate use of transfusion medicine. After surgical haemostasis has been achieved, the first approach is the confirmation of adequate heparin neutralization (heparinase ACT, protamine titration test, thromboelastography-TEG). In addition, a test of platelet function should be available (TEG maximal amplitude, Platelet-Function-Analyzer-100). Finally, the fibrinolysis pathway must be explored (TEG lysis index). Packed red blood cells must be available at every moment of the intervention, and fresh frozen plasma and platelets should be prepared in case of established coagulation abnormalities (very frequent in this population of patients) to replace coagulation factors and platelets.

#### 4. Conclusions

In conclusion we think that CPB with HCCA should be considered for atrial thrombi removal in patient affected by several abdominal malignancies such as renal, adrenal carcinomas, primary liver tumours also in presence of a well compensated liver cirrhosis, uterine endometrial stromal tumours and intravascular leiomyomatosis, vena cava leiomyosarcoma and others, because it is simpler and safer compared to CPB alone. It permits the careful cleaning of the vena cava, right atrium, ventricle and even of the pulmonary artery in a bloodless field which entails in a lower recurrence rate. Mortality and morbidity seem to be the same when compared to CPB alone but further studies are necessary due to the small number of patients.

#### 5. References

- Akashi Y, Koreeda C, Enomoto S, et al. Prognosis of unresectable hepatocellular carcinoma: an evaluation based on multivariate analysis of 90 cases. *Hepatology* 1991;14:262-8.
- Ariza A, Cerra C, Hahn IS, Shaw RK, Rigney B: Intravascular leiomyomatosis of the uterus. *Conn Med* 1982; 46: 700-3.
- Arrowsmith JE, Grocott H, Reves, et al. Central nervous system complications of cardiac surgery. *Br J Anaesth*; 2000; 84:378-393.
- Belis JA, Livinson ME, Pae WE. Complete radical nephrectomy and vena caval thrombectomy during circulatory arrest. *J Urol* 2000; Feb;163:434-6.
- Berg AA. Malignant hypernephroma of the kidney, its clinical course and diagnosis, with a description of the author's method of radical operative cure. *Surg Gynecol Obstet*.1913;17:463-71.
- Bevilacqua S, Romagnoli S, Ciappi F, et al. Transpharyngeal ultrasonography for cannulation of the internal jugular vein. *Anesthesiology*. 2005;102:873-4.
- Carid JC, Hawkins IF Jr, Weichmann BN, et al. Sonographic guidance when using the right internal jugular vein for central access. *Am J Roentgenol* 1988;171:1259-63.



- Ciancio G, Manhoran M, Katkooi D, et al. Long term survival in patients undergoing radical nephrectomy and inferior vena ca thrombectomy: single centre experience. *Eur Urol* 2010; 57:667-672.
- Ciancio G & Soloway MS :Renal cell carcinoma with tumour thrombus extending above diaphragm :avoiding cardiopulmonary bypass. *Urology* 2005; 66:266-270.
- Ciancio G,Shirodkar S, Soloway MS et al: Techniques for avoidance of sternotomy and cardiopulmonary bypass during resection of extensive renal cell carcinoma with vena caval tumor thrombus extension above the diaphragm. *J Card Surg* 2009;24:657-60.
- Ciancio G, Shiroddkar G, Soloway MS et al. Renal carcinomas with supradiaphragmatic tumor thrombus :avoiding sternotomy and cardiopulmonary bypass. *Ann Thorac Surg* 2010; 89: 505-10.
- Ciancio G ,Gonzalez J, Shirodkar SP, et al.: Liver transplantation technique for the surgical management of RCC with tumour thrombus in the inferior vena cava :step by step description. *Eur Urol* 2011; 59:401-6.
- Chowdhury UK, Mishra A K, Seth A, et al :Novel technique for tumour Thrombectomy for RCC with intra atrial tumour thrombus.*Ann Thorac Surg* 2007; 83:1.
- Chiappini B, Savini C, Marinelli G, et al.: Cavoatrial tumor thrombus: Single-stage surgical approach with profound hypothermia and circulatory arrest, including a review of the literature. *J Thorac Cardiovasc Surg* 2002; 124: 684-8.
- Chiche L, Dousset B, Kieffer E, et al.: Adrenocortical carcinoma extending into the inferior vena cava: Presentation of a 15-patient series and review of the literature. *Surgery* 2005; 139: 15-27.
- Croughwell N, Smith LR, Quill T, et al.: The effect of temperature on cerebral metabolism and blood flow in adults during cardiopulmonary bypass. *J Thorac Cardiovasc Surg.* 1992;103:549-54.
- Cummings KB ,Li WI, Ryan J A, et al.: Intraoperative management of renal cell carcinoma with supradiafragmatic caval extension of renal carcinoma.*JUrol* 1979;122:9.
- Davlouros P, Manolis A, Apostolakis E: Renal tumour with cavoatrioventricular extension. *Heart* 2005; 91: 7-9.
- Duebener LF, Hagino I, Sakamoto T et al.: Effects of pH management during deep hypothermic bypass on cerebral microcirculation:  $\alpha$ -stat versus pH-stat. *Circulation.* 2002; 106(12 Suppl 1):I103-8.
- Durck H: Ein kotinuiertlich durch die untere. Hohlvene in das herz vorwrschendes leiomyom. *Muchen Med Wochnschr* 1907; 54: 1154-5.
- Edmonds HL Jr, Ganzel BL, Austin EH 3rd.: Cerebral oximetry for cardiac and vascular surgery. *Semin Cardiothorac Vasc Anesth.* 2004;8:147-66.
- Ein SH, Shandling B, Williams WG, et al.: Major hepatic tumor resection using profound hypothermia and circulation arrest. *J Pediatr Surg.* 1981;16:339-42.
- Foster RS, Mahomed Y, Bihrlle R, et al.: Use of a caval-atrial shunt for resection of a caval tumour thrombus in renal cell carcinoma. *J Urol* 1988;61:402.
- Florman S, Weaver M, Primeaux P, et al.: Aggressive resection of hepatocellular carcinoma with right atrial involvement. *Am Surg.* 2009;75:1104-8.
- Fujisaki M, Kurihara E, Kikuchi K, et al.: Hepatocellular carcinoma with tumor thrombus extending into the right atrium: report of a successful resection with the use of cardiopulmonary bypass. *Surgery.* 1991;109:214-9.

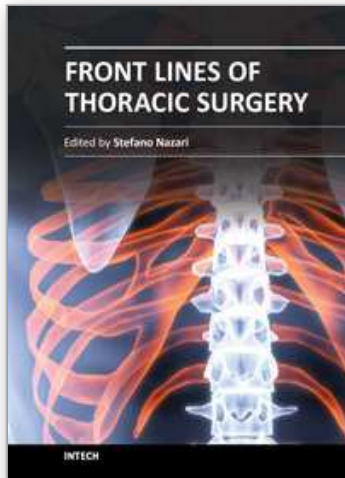
- Galajda Z, Copotoiu C, Suciu H, Tint D, Glasz T, Deac R: The diagnosis, morphological particularities, and surgical technique in a case of intravascular leiomyoma extended to the right heart chambers. *J Vasc Surg* 2010; 51: 1000-2.
- Goto H, Kaneko Y, Utoh J, et al., : Surgery of hepatoma with intracavitary cardiac extension. *Heart and Vessels* 1986; 2: 60-62.
- Gott VL.: Lillehei, Lewis, and Wangenstein: The right mix for giant achievements in cardiac surgery. *Ann Thorac Surg* 2005; 79: S2210-3.
- Griep RB.: Cerebral protection during aortic arch surgery. *J Thorac Cardiovasc Surg.* 2003;125:S36-S38.
- Hahne OH & Climie ARH: Right atria thrombi with ball-valve action. *Am J Med* 1962; 32: 942-6.
- Hamazaki K, Yagi T, Katsuta K, et al., : Extracorporeal circulation and hypothermic perfusion for caval tumor thrombus complicating hepatocellular carcinoma: a case report. *Hepatogastroenterology.* 1995;42:282-5.
- Harrington DH, Bonser M, Moss A, et al. Neuropsychometric outcome following aortic arch surgery: a prospective randomized trial of retrograde cerebral perfusion. *J thorac cardiovasc surg* 2003; 126:638-644.
- Hassan M, Ciancio G, Shirodkar SP, et al.,: Surgical technique of removal of inferior vena cava leiomyosarcoma extending into the right atrium without deep hypothermic circulatory arrest. *J Card Surg* 2010; 25: 277-81.
- Hatcher PA ,Anderson EE, Paulson DF ,et al : Surgical management and prognosis of renal cell carcinoma invading the vena cav,j *Urol* 1991; 145:20-4.
- Huguet C, Gavelli A, Sakai H: Vascular exclusion technique in liver resection for hepatocellular carcinoma. *J Hep Bil Pancr Surg* 1994; 2: 123-127.
- Kalkat MS, Abedin A, Rooney S, et al.,: Renal tumours with cavo-atrial extension: Surgical management and outcome. *Interact Cardiovasc Thorac Surg* 2008; 7: 981-5.
- Kanda T, Miyamoto H, Hayakawa et al.,: A case of tumor thrombus in the right atrium after multimodal treatment of testicular tumor. *Nippon Kyobu Geka Gakkai Zasshi* 1991; 39: 1966-70.
- Kawasaki S, Makuuchi M, Miyagawa S, et al.,: Results of hepatic resection for hepatocellular carcinoma. *World J Surg* 1995; 19: 31-4.
- Krane RJ, White R ,et al :Removal of renal cell carcinoma extending into the right atrium using cardiopulmonary bypass, profound hypothermia and circulatory arrest. *J Urol* 1984; 131:945-7.
- Kumar AB & Suneja M.: Cardiopulmonary Bypass-associated Acute Kidney Injury. *Anesthesiology* 2011; 114: 964-70
- Leo F, Rapisarda F, Sefano PL, et al.,: Cavo-atrial thrombectomy combined with left hemihepatectomy for vascular invasion from hepatocellular carcinoma on diseased liver under hypothermic cardio-circulatory arrest. *Interact Cardiovasc Thorac Surg* 2010; 10: 473-5.
- Libertino JA,Zinman L, Watkins E Jr.: Long term results of resection of renal cell cancer with extension into inferior vena cava.*J Urol* 1987;137;21-4.
- Lin HH, Hsieh CB, Chu HC, et al., : Acute pulmonary embolism as the first manifestation of hepatocellular carcinoma complicated with tumor thrombi in the inferior vena cava: surgery or not? *Dig Dis Sci.* 2007;52:1554-7.

- Lubahn J, Sagalowsky A, Rosenbaum D et al.: Contemporary techniques and safety of cardiovascular procedures in the surgical management of renal cell carcinoma with tumor thrombus. *Thorac Cardiovasc Surg* 2006; 131: 1289-95.
- Mandelbaum I, Pauletto FJ, Nasser WK: Resection of a leiomyoma of the inferior vena cava that produced tricuspid valvular obstruction. *J Thorac Cardiovasc Surg* 1974; 67: 561-7.
- McCullough JN, Zhang N, Reich DL, et al. Cerebral metabolic suppression during hypothermic circulatory arrest in humans. *Ann Thorac Surg.* 1999;67:1895-9.
- Marshall FF, Reitz BA, Diamond DA: A new technique for the management of renal cell carcinoma involving the right atrium: Hypothermia and cardiac arrest. *J Urol* 1984; 131: 103-9.
- Marshall FF, Dietrich DD, Baumgartner WA, et al. Surgical management of renal cell carcinoma with intracaval neoplastic extension above the hepatic veins. *J Urol* 1988;139:1166-72.
- Martínez-Salamanca JI, Huang WC, et al., : Prognostic impact of the 2009 UICC/AJCC TNM staging system for renal cell carcinoma with venous extension. *International Renal Cell Carcinoma-Venous Thrombus Consortium.* *Eur Urol* 2011; 59:120-7.
- Masaki N, Hayashi S, Maruyama T, et al.: Marked clinical improvement in patients with hepatocellular carcinoma by surgical removal of extended tumor mass in right atrium and pulmonary arteries. *Cancer Chemother Pharmacol.* 1994; 33 Suppl:S7-11.
- Mingoli A, Cavallaro A, Sapienza P et al: International registry of inferior vena cava leiomyosarcoma: Analysis of a world series on 218 patients. *Anticancer Res* 1996; 16: 3201-5.
- Miyazawa M, Torii T, Asano H, et al.: Does a surgery for hepatocellular carcinoma with tumor thrombus highly occupying in the right atrium have significance? A case report and review of the literature. *Hepatogastroenterology.* 2005; 52: 212-6.
- Moinzadeh A, Liberto JA: Prognostic significance of tumour thrombus level in patients with renal cell carcinoma and venous thrombus extension. Is all T3b the same? *J Urol* 2004;171:598-601.
- Moon TD, Fox LS; Varma DG: Testicular teratocarcinoma with intracaval metastases to the heart. *Urology* 1992; 40: 368-70.
- Murkin JM, Martzke JS, Buchan AM, et al. A randomized study of the influence of perfusion technique and pH management strategy in 316 patients undergoing coronary artery bypass surgery. II. Neurologic and cognitive outcomes. *J Thorac Cardiovasc Surg.* 1995;110:349-62.
- Nam MS, Jeon MJ, Kim YT, Kim JW, Park KH, Hong YS: Pelvic leiomyomatosis with intracaval and intracardiac extension: a case report and review of the literature. *Gynecologic Oncology* 2003; 89: 175-80.
- Neves RJ & Zincke H. Surgical treatment of renal cancer with vena cava extension. *Br J Urol* 1987;59:168:205-9
- Novick AC, Cosgrove DM. Surgical approach for removal of renal cell carcinoma extending into the vena cava and the right atrium. *J Urol* 1980; 123: 947-50.
- Novick AC, Kaye MC, Cosgrove DM, et al.: Experience with cardiopulmonary bypass and deep hypothermic circulatory arrest in the management of retroperitoneal tumors with large vena cava thrombi. *Ann Surg.* 1990; 212:472-7.

- Ogata S, Belghiti J, Farges O, et al.: Sequential arterial and portal vein embolizations before right hepatectomy in patients with cirrhosis and hepatocellular carcinoma. *Br J Surg* 2006;93:1091-8.
- Ohwada S, Takahashi T, Tsutsumi H, et al.: Hepatocellular carcinoma with a tumour thrombus extending to the tricuspid valve: report of a successful en bloc resection. *Hepatogastroenterology*. 2008; 55:903-6.
- Okada S, Okazaki N, Nose H, et al.: Prognostic factors in patients with hepatocellular carcinoma receiving systemic chemotherapy. *Hepatology* 1992; 16:112-7.
- Ozben B, Papila N, Tannikulu MA, et al.: Inferior vena cava tumor thrombus extending into the right atrium in a patient with pancreatic cancer. *J Thromb Thrombolysis* 2007; 24: 317-21.
- Paule B, Brion N, Grunenwald D, et al.: Right atrial extension of an embryonal carcinoma of the testis. *Cancer* 1991; 66: 198-201.
- Pawarode A, Voravud N, Sriuranpong V, et al.: Natural history of untreated primary hepatocellular carcinoma: a retrospective study of 157 patients. *Am J Clin Oncol* 1998; 21:386-91.
- Pawlik TM, Poon RT, Abdalla EK, et al.: Hepatectomy for hepatocellular carcinoma with major portal or hepatic vein invasion: results of a multicenter study. *Surgery*. 2005;137:403-10.
- Pierangeli A, Coli G, Mikus PM: Sostituzione dell'arco aortico in ipotermia profonda. *Bull Scienze Med* 1974; 2: 1-16.
- Poon RT, Fan ST. Evaluation of the new AJCC/UICC staging system for hepatocellular carcinoma after hepatic resection in Chinese patients. *Surg Oncol Clin N Am* 2003;12:35-50
- Renzulli P, Weimann R, Barras JP, et al: Low-grade endometrial stromal sarcoma with inferior vena cava tumor thrombus and intracardiac extension: radical resection may improve recurrence free survival. *Surg Oncol* 2009; 18: 57-64.
- Scully RE, Galbadini JJ, McNeely BU: Case records of the Massachusetts general hospital. Case 40-1976. *N Eng J Med* 1976; 295: 774-82.
- Shahinian DM, Nieh PT, Libertino JA: Resection of cavo-atrial carcinoma using hypothermic circulatory arrest. *Ann Thorac Surg* 1989; 48: 421-2.
- Slater JM, Orszulak TA, Cook DJ. Distribution and hierarchy of regional blood flow during hypothermic cardiopulmonary bypass. *Ann Thorac Surg* 2001; 72:532-547.
- Stecker MM, Cheung AT, Pochettino A, et al. Deep hypothermic circulatory arrest: II. Changes in electroencephalogram and evoked potentials during rewarming. *Ann Thorac Surg*. 2001; 71(1):22-8.
- Stewart JR, Carey JA, McDougal S et al.: Cavoatrial tumor thrombectomy using cardiopulmonary bypass without circulatory arrest. *Ann Thorac Surg* 1991; 51: 717-22.
- Sripathi V, Muralidharan KV, Ramesh S, Muralinath S: Wilms' tumor with vena cava, atrial and middle hepatic vein tumor thrombus. *Pediatr Surg Int* 2000; 16: 447-8.
- Yogita S, Tashiro S, Harada M, et al.: Hepatocellular carcinoma with extension into the right atrium: report of a successful liver resection by hepatic vascular exclusion using cardiopulmonary bypass, *J Med Invest*. 2000; 47:155-60.

- Yao FS, Tseng CC, Ho CY, et al. Cerebral oxygen desaturation is associated with early postoperative neuropsychological dysfunction in patients undergoing cardiac surgery. *J Cardiothorac Vasc Anesth.* 2004;18:552-8.
- Reich DL, Uysal S, Sliwinski M, Ergin MA, et al. Neuropsychologic outcome after deep hypothermic circulatory arrest in adults. *J Thorac Cardiovasc Surg.* 1999;117:156-163.
- Raoul JL, Guyader D, Bretagne JF, et al. : Randomized controlled trial for hepatocellular carcinoma with portal vein thrombosis: intra-arterial iodine-131-iodized oil versus medical support. *J Nucl Med* 1994; 35:1782-7
- Ruel M ,Bedard P, Morash CG et al : Resection of right atrial tumour thrombi without circulatory arrest. *Ann Thorac Surg* 71:733-734, 2001.
- Shingai R, Vricella L et al: Cavoatrial tumour thrombus excision without circulatory arrest. *Urology* 62:138-140, 2003.
- Staheler G & Brkovic D: The role of radical surgery for renal cell carcinoma with extension into the vena cava. *J Urol* 2000;163:1671-75
- Skinner DG, Pritchett TR, Lieskovsky G, et al.: Vena caval involvement by renal cell carcinoma. Surgical resection provides meaningful long-term survival. *Ann Surg* 1989; 210: 387-92.
- Tamburino C, Russo G, Incognito G, et al.: Intracardiac extension of a calcified ovarian hemangioma: a case report. *Angiology* 1992; 43: 249-52.
- Topcuoglu MS, Yaliniz H, Poyrazoglu H, et al.: Intravenous leiomyomatosis extending into the right ventricle after subtotal hysterectomy. *Ann Thorac Surg* 2004; 78: 330-2.
- Wakiyama H, Sugimoto T, Ataka K, et al.: Intravenous leiomyomatosis extending into the right ventricular cavity : one-stage radical operation using cardiopulmonary bypass-a case report. *Angiology* 2000; 51: 505-9.
- Wu CC, Hseih S, Ho WM, et al.: Surgical treatment for recurrent hepatocellular carcinoma with tumour thrombi in right atrium: using cardiopulmonary bypass and deep hypothermic circulatory arrest. *J Surg Oncol.* 2000;74:227-31.
- Vargas-Barron J, Keirns C, Barragan-Garcia R, et al.: Intracardiac extension of malignant uterine tumor. Echocardiographic detection and successful surgical resection. *J Thorac Cardiovasc Surg* 1990; 99: 1099-103.

IntechOpen



## **Front Lines of Thoracic Surgery**

Edited by Dr. Stefano Nazari

ISBN 978-953-307-915-8

Hard cover, 412 pages

**Publisher** InTech

**Published online** 03, February, 2012

**Published in print edition** February, 2012

Front Lines of Thoracic Surgery collects up-to-date contributions on some of the most debated topics in today's clinical practice of cardiac, aortic, and general thoracic surgery, and anesthesia as viewed by authors personally involved in their evolution. The strong and genuine enthusiasm of the authors was clearly perceptible in all their contributions and I'm sure that will further stimulate the reader to understand their messages. Moreover, the strict adhesion of the authors' original observations and findings to the evidence base proves that facts are the best guarantee of scientific value. This is not a standard textbook where the whole discipline is organically presented, but authors' contributions are simply listed in their pertaining subclasses of Thoracic Surgery. I'm sure that this original and very promising editorial format which has and free availability at its core further increases this book's value and it will be of interest to healthcare professionals and scientists dedicated to this field.

### **How to reference**

In order to correctly reference this scholarly work, feel free to copy and paste the following:

Pier Luigi Stefano, Stefano Romagnoli, Donata Villari and Giacomo Batignani (2012). Hypothermic Cardiac Arrest to Remove Right Atrial Thrombi Due to Abdominal Malignancies, Front Lines of Thoracic Surgery, Dr. Stefano Nazari (Ed.), ISBN: 978-953-307-915-8, InTech, Available from:  
<http://www.intechopen.com/books/front-lines-of-thoracic-surgery/hypothermic-cardiac-arrest-to-remove-right-atrial-thrombi-due-to-abdominal-malignancies->

**INTECH**  
open science | open minds

### **InTech Europe**

University Campus STeP Ri  
Slavka Krautzeka 83/A  
51000 Rijeka, Croatia  
Phone: +385 (51) 770 447  
Fax: +385 (51) 686 166  
[www.intechopen.com](http://www.intechopen.com)

### **InTech China**

Unit 405, Office Block, Hotel Equatorial Shanghai  
No.65, Yan An Road (West), Shanghai, 200040, China  
中国上海市延安西路65号上海国际贵都大饭店办公楼405单元  
Phone: +86-21-62489820  
Fax: +86-21-62489821

© 2012 The Author(s). Licensee IntechOpen. This is an open access article distributed under the terms of the [Creative Commons Attribution 3.0 License](#), which permits unrestricted use, distribution, and reproduction in any medium, provided the original work is properly cited.

IntechOpen

IntechOpen