

# We are IntechOpen, the world's leading publisher of Open Access books Built by scientists, for scientists

**4,800**

Open access books available

**122,000**

International authors and editors

**135M**

Downloads

Our authors are among the

**154**

Countries delivered to

**TOP 1%**

most cited scientists

**12.2%**

Contributors from top 500 universities



**WEB OF SCIENCE™**

Selection of our books indexed in the Book Citation Index  
in Web of Science™ Core Collection (BKCI)

Interested in publishing with us?  
Contact [book.department@intechopen.com](mailto:book.department@intechopen.com)

Numbers displayed above are based on latest data collected.

For more information visit [www.intechopen.com](http://www.intechopen.com)



# Strategies to Improve the Function, Kinematic and Implants' Positioning of a TKA with Minimally Invasive Computer-Assisted Navigation

Nicola Biasca<sup>1</sup> and Matthias Bungartz<sup>2</sup>

<sup>1</sup>*Orthopedic Clinic Luzern AG, Hirslanden Clinic St. Anna, Luzern*

<sup>2</sup>*Klinik für Orthopädie und Unfallchirurgie, Lehrstuhl für Orthopädie der Friedrich-Schiller-Universität Jena, Waldkrankenhaus*

*„Rudolf Elle“ Eisenberg*

<sup>1</sup>*Switzerland*

<sup>2</sup>*Germany*

## 1. Introduction

Total Knee Arthroplasty (TKA) is a well established, highly successful procedure, with numerous long-term follow-up studies reporting clinical success rates of 72-100% at 10-20 years in terms of pain reduction, functional improvement and overall patient satisfaction [1-5]. Although TKA is generally successful, and despite the advances in surgical techniques, instrumentation and implant designs, between 5 to 8% of all patients still develop complications such as anterior knee pain, loosening, instability, malpositioning, infection or fractures [6-8]. Imperfection in the coronar, sagittal and axial alignments of the femoral and/or of tibial components, improper ligament balancing and incorrect joint line restoration can lead to soft tissue imbalance and inability to re-establish optimal kinematics and the overall biomechanics of the joint, with persistent anterior knee pain, patellar maltracking, instability or limitation of movement [9-14, 15].

Several investigators have demonstrated on the basis of conventional radiography and computer-tomography that TKA, implanted with computer-assisted navigation and conventional approach, has more accurate component alignment than TKA implanted conventionally [9, 15-29].

The introduction of minimally invasive surgery (MIS) has gained in importance in orthopedics and especially in TKA. Patient's demand for high activity level after TKA, concerns about postoperative pain, fast rehabilitation process, possible reduction in duration of hospitalization and costs in connection with the necessity of health care savings have led to the rapid advancement of less invasive surgical approaches and techniques as well as the development of new instrumentation by the orthopedic implant industry.

Regardless of the numerous advantages of minimal-invasive TKA, concern is driven about loss of accuracy for implant placement and increased complications related to skin slough and infection when a minimally invasive approach is used [30, 31]. Furthermore reduced operative visualization, a steep learning curve, an increased risk of complications, excessive

skin trauma and compromised implant fixation and alignment are topic of objection. In addition few surgeons have expressed concern about minimally invasive surgery and its relevance to TKA as well as the safety of operations performed "through a keyhole" and are convinced that at present there is no credible evidence that smaller incisions significantly benefit the patient receiving MIS TKA. By contrast, proponents of MIS TKA report that MIS patients, compared to patients undergoing conventional TKA, Experience shortened hospital stay, less pain-control medications, faster recovery of knee range of motion and decreased blood loss all without compromise of accuracy or short-term outcome [32-34].

## 2. Computer-assisted navigated orthopedic surgery

The principle of computer-assisted surgery in orthopedics is based on the creation of a digital map for the different steps during operation. Using this map, the surgeon is guided through the operating process. The development of the digital image is based on three different basic ideas.

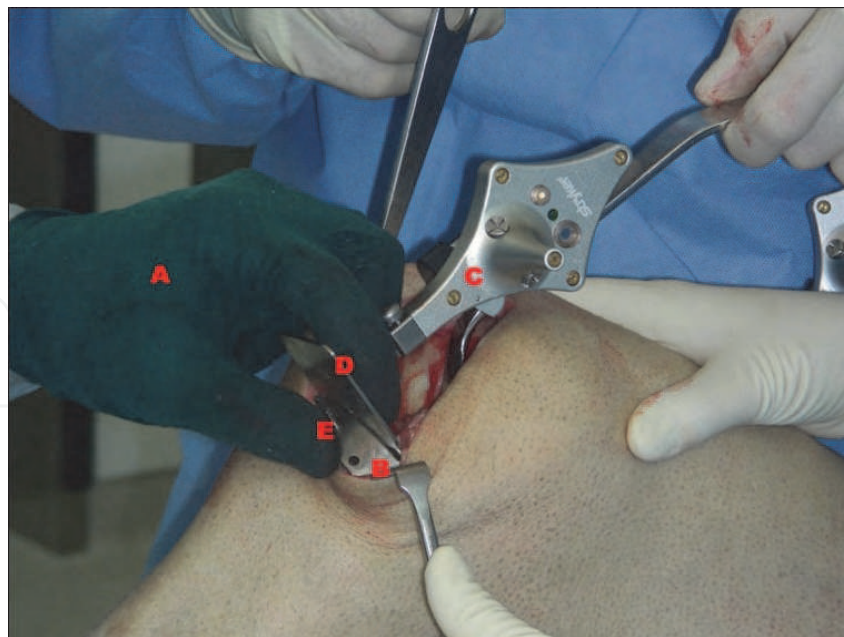
One system uses anatomical information which is achieved from pre-operatively performed CT- or MRI-scans, the second system is "peri-operatively-imaged" in which anatomical imaging occurs in the operating suite at the time of surgery. This requires a specially modified fluoroscopy unit, which entails the presence of a relatively bulky and expensive apparatus during surgery. These two systems display the "image-based systems". The third group on the contrary is "image-free" and relies on information acquired during surgery. This "image-free" navigation allows the surgeon to quantify data, receive real-time dynamic intra-operative maneuvering feedback and to obtain more reproducible results.

A very important feature of this navigation system is its ability to provide instant feedback regarding *in vivo* kinematics of the joint at different stages of the operation. Alignment and ligament stability can be assessed with the trials in place to ensure proper function. Furthermore, this system allows the surgeon to measure the coronal, sagittal and axial deformities, the alignments and the stability of the joint before, during and after the implantation of a TKA. These characteristics of the navigation system provide the unique opportunity to assess *in vivo* the kinematics of the knee during surgery and implement beneficial changes of the components or alteration in components selection.

We were using at the Orthopedic Clinic at the Hospital Oberengadin in Samedan an "image-free" navigation system (Stryker® Leibinger Knee Navigation System, Stryker® Leibinger, precisioN Knee Navigation Software V 4.0). This system is available in an active wireless PC-based guidance system, which is based on an image-free navigation method, and thus does not require pre-operative computer tomography or intra-operative fluoroscopy. It comprises a module for analyzing the alignment of the leg, the alignment of the resection planes and thus of the prosthetic components. The system also allows the surgeon to quantify the kinematics of the knee and the balancing of the soft tissue (Further details on the Stryker® Knee Navigation System are available on <http://www.europe.stryker.com/>).

### 2.1.1 Surgical procedure

The patient is placed supine on a standard operating table. A tourniquet is applied after exsanguination of the limb, and standard skin preparation and draping are undertaken. To obtain best exposition of all structures during the procedure, two distally positioned leg holders are fixed on the operating table to allow full flexion and extension of the leg. Flexing the knee thereby exposes the posterior structures whereas extension facilitates access to the anterior anatomy of the knee.

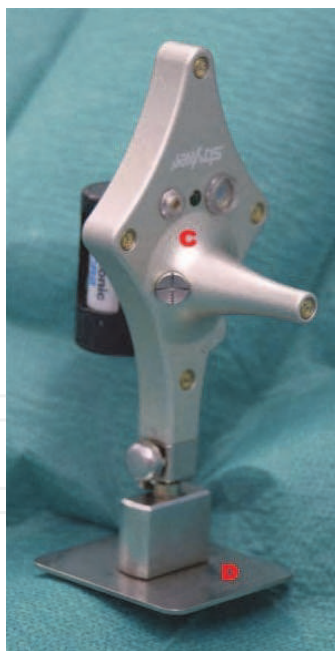

1A

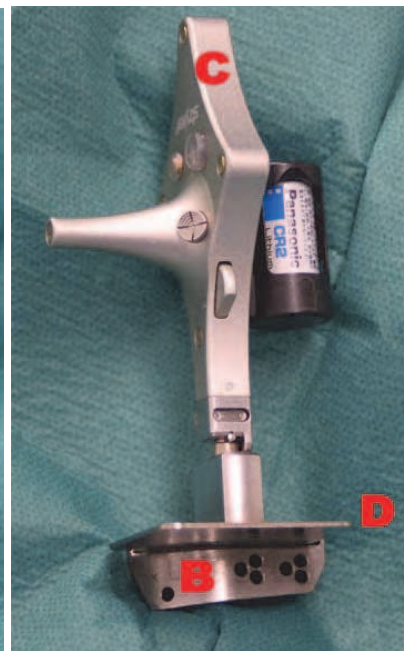Fig. 1A. The proximal tibial resection requires the surgeon to position the MIS Cutting Guide in relation to the three axes of freedom controlling the varus/ valgus, the depth and the posterior slope, with a freehand technique (A). The cutting guide block/ tracker construct (B-C-D) is then hold by the surgeon with a “tripod grip” (A). The universal tracker (C) is attached to the resection plane probe (D), which in turn is placed into the captured slot of the cutting guide block (B). The cutting guide block (B) is pinned into place with three pins (E).



1B



1C



1D

Fig. 1B-D. MIS TKA must be performed with accurate instruments:

Fig. 1B. The cutting guide block (B).

Fig. 1C. The universal tracker (C) is attached to the resection plane probe (D).

Fig. 1D. The universal tracker (C) is attached to the resection plane probe (D), which in turn is placed into the captured slot of the cutting guide block (B).

Fig. 1A-D. Proximal tibial resection

As standard approach we used a mid-vastus approach [35-38]. To enable a better exposure and visibility of the lateral compartment the patella was osteotomized freehand to 12-14 mm bone thickness for later resurfacing in order to reconstruct preoperative thickness. All interventions were performed by a single surgeon (NB), who is a high volume arthroplasty surgeon and uses computer-navigation routinely for over six years.

Two pin trackers need to be fixed rigidly at the beginning of the operation on the lateral distal femur and on the ventral proximal tibia, both within the surgical access zone (For further details information's please see the references 24 and 25).

The digitizing pointer is now used to mark the key anatomical landmarks. After that procedure the surgeon is able to reproduce the correct joint kinematics at any time of the operation in any position of the leg with the Knee Navigation System software. After analyzing the kinematics curves and axis, bone cuts are performed using the information obtained from the navigation system.

We usually prefer starting with tibial cut first. The proximal tibial cut is made in a one-step procedure, controlling the desired posterior slope, varus/ valgus and depth. The degree of posterior slope of the tibial cut is aimed to match the original posterior slope of the tibial plateau as measured in the pre-operative lateral x-ray [16]. Using freehand technique, the position of the probe is adjusted according to the image and data shown on the computer. MIS TKA must be performed with accurate instruments that are coordinated with the procedure. The guide is held with a "tripod grip" technique (Figures 1A-D), and the visual movements of the guide can be monitored in real time on the screen (Figure 2).

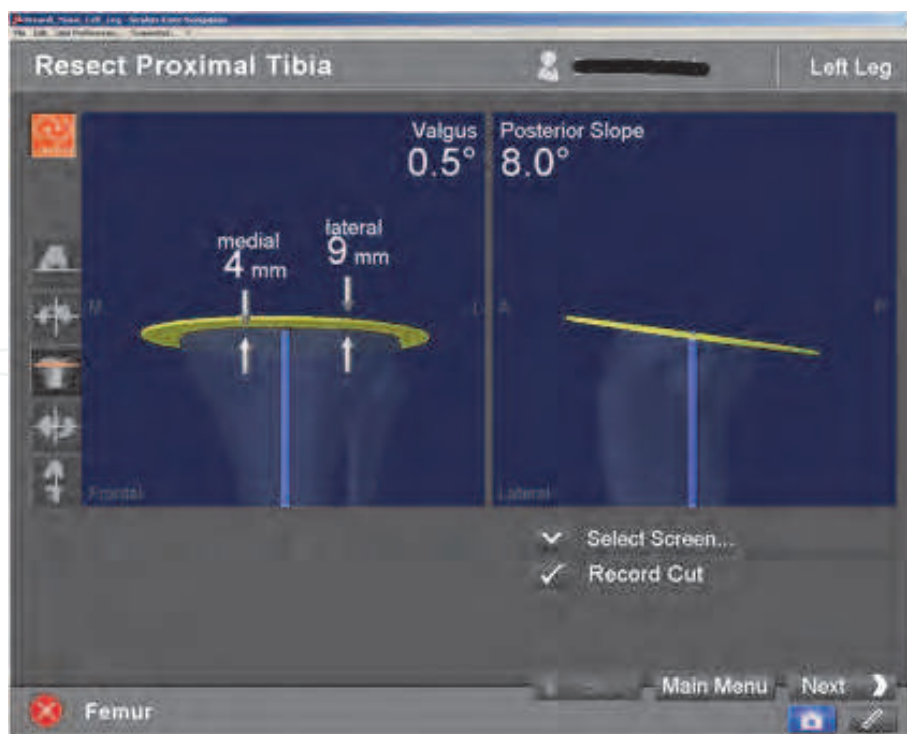
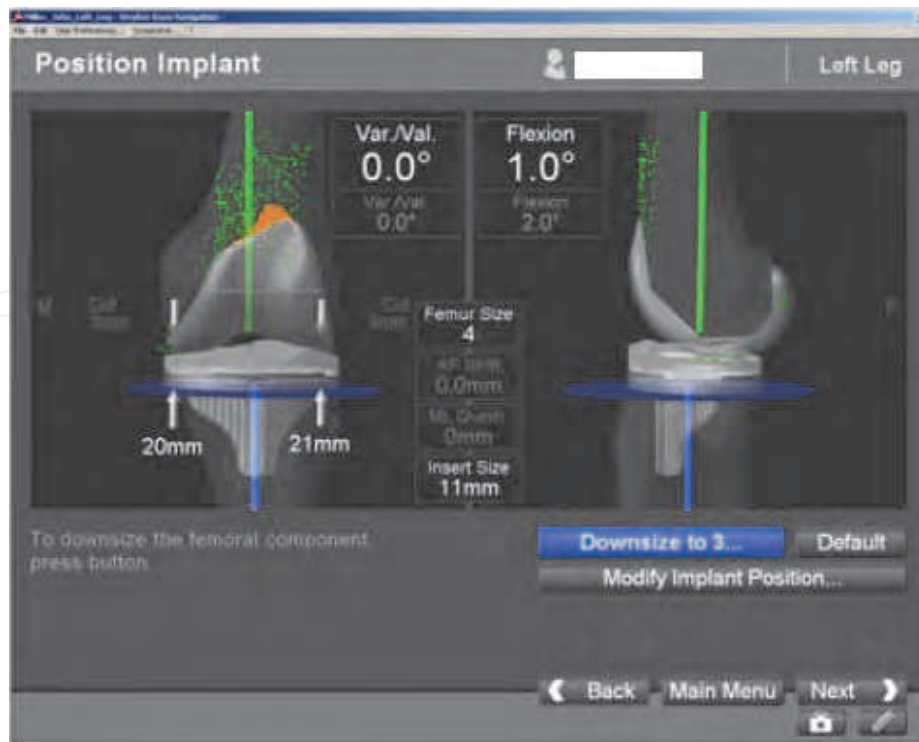
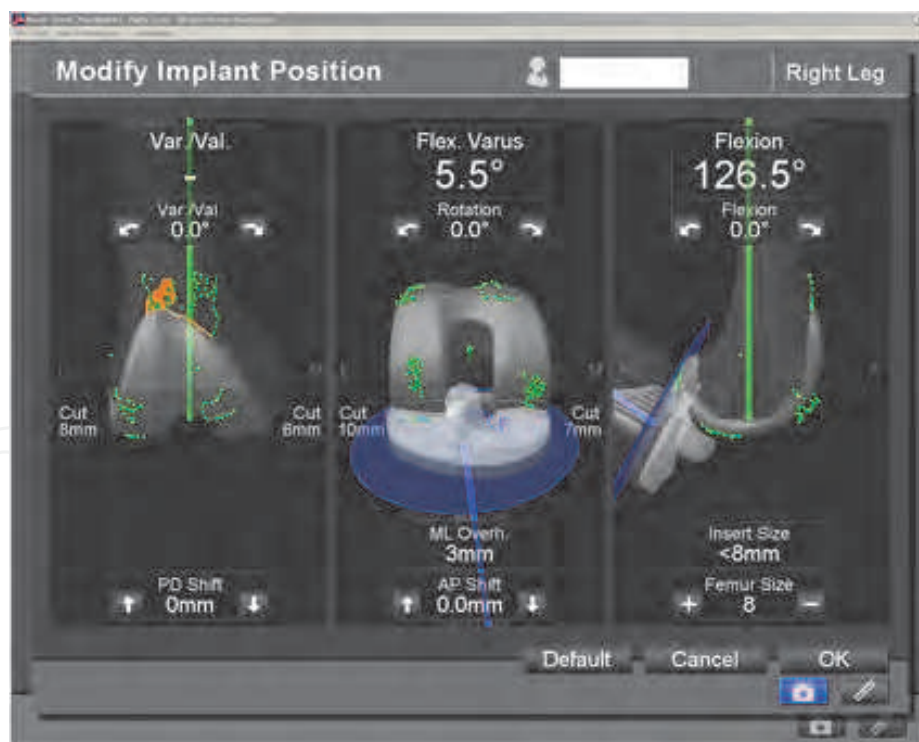


Fig. 2. The virtual position of cutting guide/ tracker construct is now an active tool, which can be monitored (i.e. the varus/ valgus angle, the slope angel and the depth) on the computer navigation screen.



3A

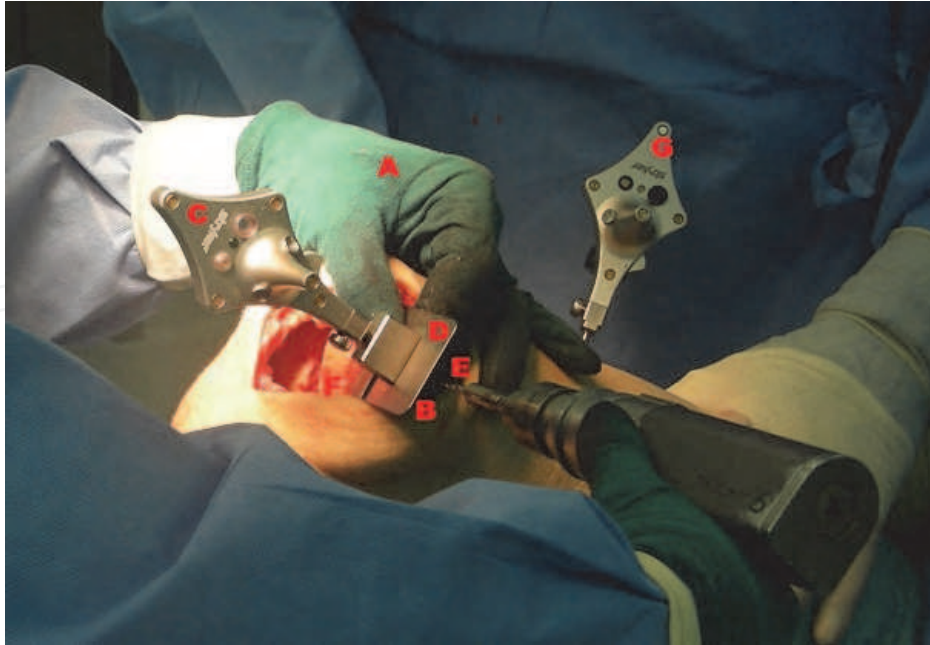
Fig. 3A. "Implant Position": The system allows the surgeon to check the position of the implant.



3B

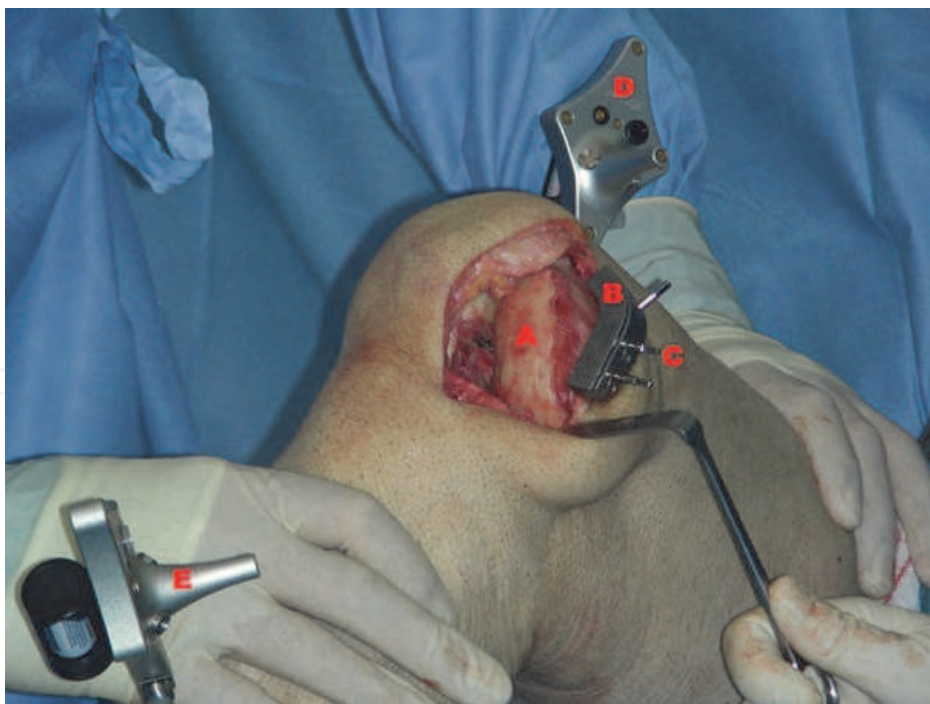Fig. 3B. "Modify Implant Position": This system allows the surgeon to modify the flexion/ extension, varus/ valgus, internal/ external rotation, anterior/ posterior shift, proximal/ distal shift of the femoral implant and to adjust its implant size relative to femur.

Fig. 3A. and 3B. Implant Position and Modify Implant Position:



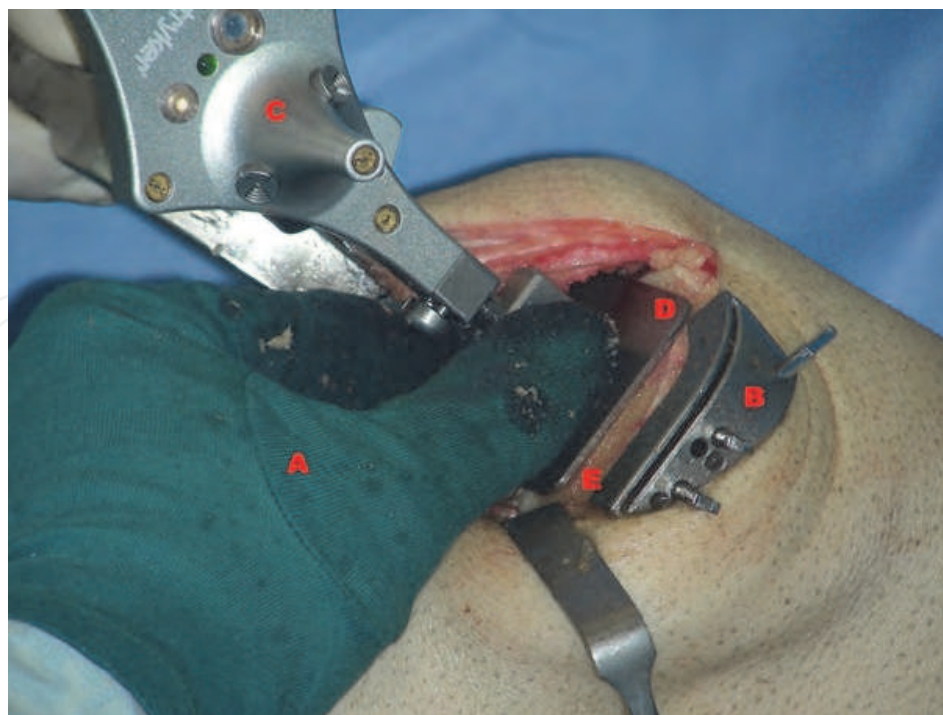
4A

Fig. 4A. With the freehand technique (A) the same cutting guide block (B) is used with the universal tracker (C) and with the resection plane probe (D) in the captured slot (E) and placed on the external border of the medial distal femur condyle (F). Similar to tibial cutting, a freehand technique with the cutting guide block (B-C-D) is used for the distal femoral resection. The block is pinned into place with three pins (E). The femoral tracker (G) is visible in this picture.



4B

Fig. 4B. The distal femoral resection (A) is done with the cutting guide block (B), which is fixed with three pins (C) and the surgeon can now use a saw blade to cut the desired distal femoral (A) resection. The femoral tracker (D) and tibial trackers (E) are visible in this picture. Now the distal femoral bone resection can be done with the saw through the cutting guide block.



4C

Fig. 4C. Control of the corrected resection of the distal femoral bone with the freehand technique (A): After resection with the cutting guide block (B), the universal tracker (C) in connection with the resection plane probe (D) can verify the accuracy of the cut of the distal femoral bone surface (E), re-correct the resection if it is necessary and finally record the distal femoral cut on the screen. In this picture the resection plane probe (D) is hold on the distal femoral bone cut surface (E) to record the resection result.

Fig. 4A-C. Distal femoral resection

Afterwards, the surgeon has the possibility to continue with the bone resection of the distal femur. In a two-step process, using two femoral cutting blocks, the cutting guide and the femoral alignment guide and the resection plane probe, the cuts are performed. Distal femoral resection requires control of the flexion/extension, varus/ valgus and depth of bone resection, based on our decision of the implant positioning and sizing (Figures 4A-C).

The rotational alignment is subsequently established with the femoral alignment guide and resection plane probe. The femoral component rotation is aimed to be  $0^{\circ}$  in relation to the special algorithm of surgical transepicondylar axis and the Whiteside line as provided by the computer software. Care is taken to avoid notching the ventral femoral cortex. We finally finish the femur preparation with the femoral resection guide and the femoral trochlea with the corresponding resection guide. Hereby care is taken to release any flexion contracture and to remove all the posterior femoral osteophytes. The femoral component is then inserted and, once correctly seated, the fixation lugholes are drilled.

Subsequently the tibial bone resection is finalized: The appropriately sized tibial baseplate is inserted and its rotation is determined through self-adjustment by flexing and extending the knee with the trial femoral and inlay components implanted. The tibial component rotation is marked, and later the component is implanted with the desired rotation [39, 40].

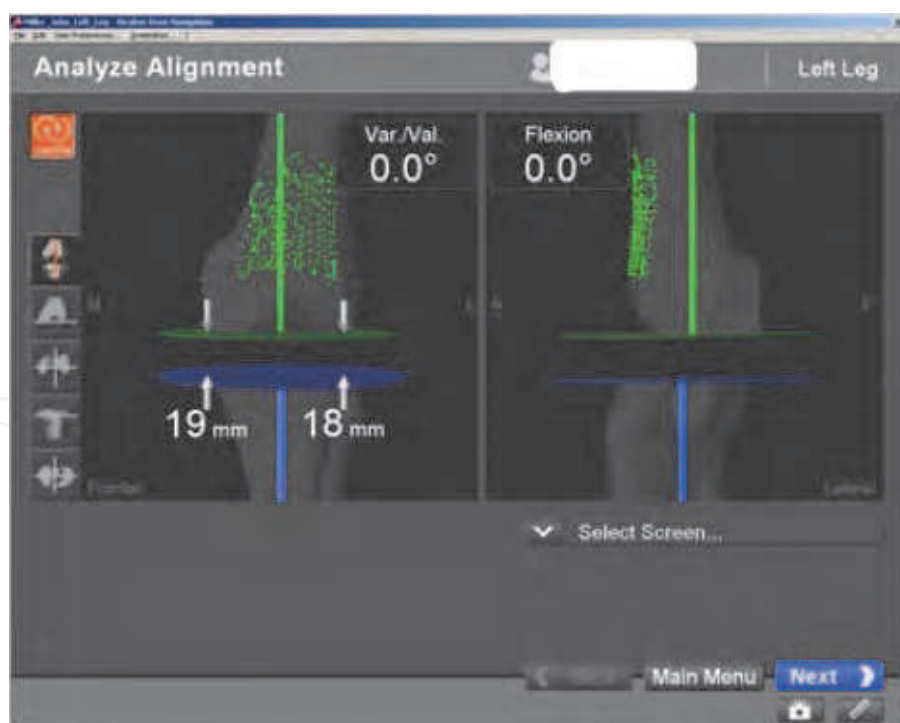


### 2.1.2 Trial component insertion

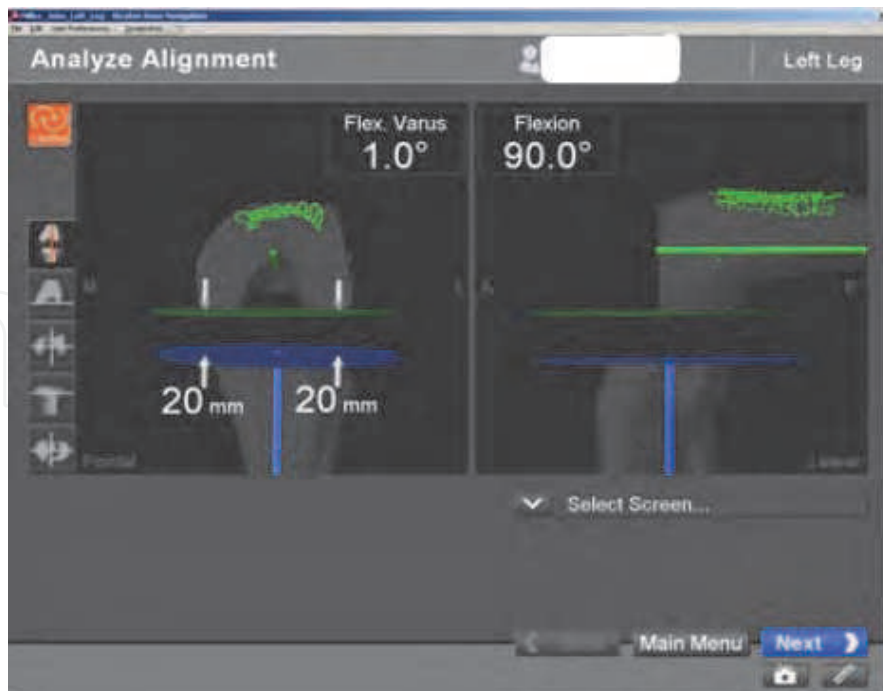
Before the insertion of the trial components, the tibial and femoral bone cuts are again verified with a small resection plane probe, which is directly applied on the resection planes of the affected bone. Every cut is recorded and stored by the system, and can be used for post-operative evaluation and quality control. After completion and digital check of the tibial, femoral and soft tissue preparation, the trial components are inserted and once again the correct position of the trial components is checked with a small resection plane probe for position. Subsequently, the patella preparation is finished and patellar tracking is checked with the implant trials in place.

### 2.1.3 Trial components soft tissue assessment

After the insertion of the trial components, limb alignment and soft tissue balancing are assessed with the intra-operative kinematics by moving the limb from extension to full flexion under neutral, varus and valgus stress, manually applied through the heel of the foot, carefully keeping the same rotation. Using this information, the surgeon can simulate changes of polyethylene insert and soft tissue release by repeating the assessment. In this way one can obtain a constant dynamic feedback in the process of balancing the knee (Figures 5A and B).

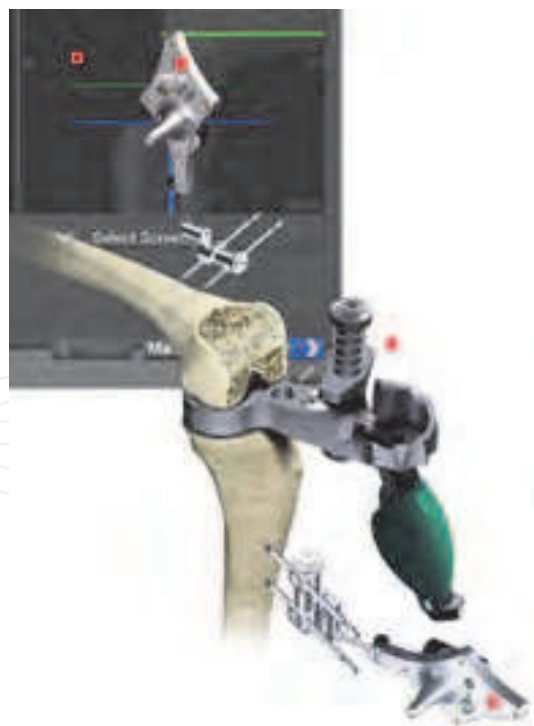

5A



5B

Fig. 5A. and B. The Gap monitoring enables the surgeon to analyze varus/valgus, extension/flexion as well as the gap in extension (A) and flexion (B) upon performance of all cuts with a mechanical tensioner to ensure equal medial and lateral tension in both flexion and extension. This maneuver can also be done through the all ROM under neutral, varus and valgus stress.



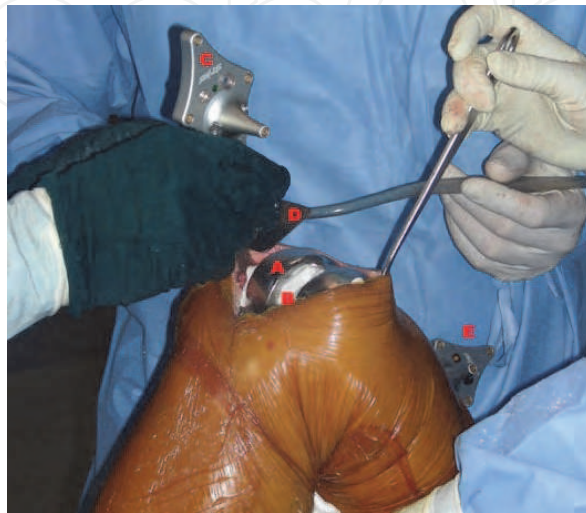
5C

Fig. 5C. Schematic view of the gap monitoring in flexion with a mechanical tensioner (A). The femoral tracker (B), the tibial tracker (C) and the screen (D) are visible in this picture.

Fig. 5A-C. Gap monitoring

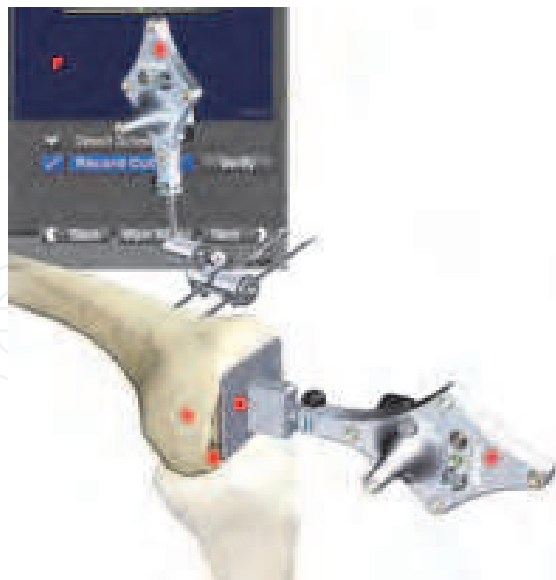### 2.1.4 Definite component insertion

All our patients received a posterior-stabilized “Scorpio” total knee prosthesis (Stryker® Howmedica Osteonics, Freiburg, Germany). After jet-lavage (approx. 3 L of Ringer Solution) of the resection planes the femoral and tibial components are cemented with the Stryker® Compact Vacuum Cement Mixing System. It is still possible to control the position of the tibial and femoral components with the resection plane probe and, if necessary, improve (Figures 6A and B). Then again the definitive position is documented with the navigation system.



6A

Fig. 6A. After insertion of the femoral component (A) with cement (B), the surgeon has the possibility to check the position of the femoral component with the universal tracker (C) and the resection plane probe (D) and if necessary to improve its position before the cement is fully polymerized. The femoral tracker (E) is visible in this picture.



6B

Fig. 6B. Schematic view to check the position of the femoral component with the universal tracker (C) and the resection plane probe (D). In this schematic view, without a Prosthetic component, the distal femoral condyle (A), the distal femoral cut surface (B), the femoral tracker (E) and the screen (F) are visible.

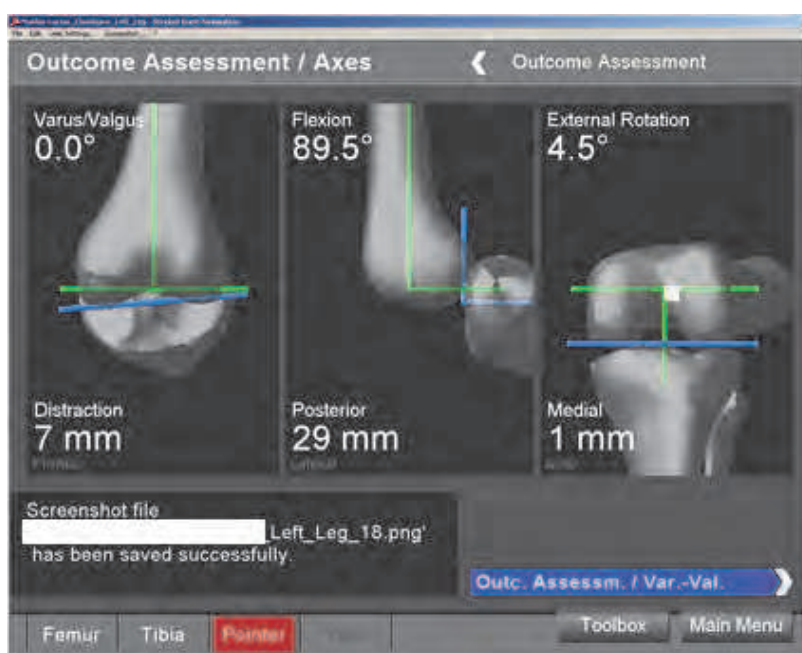Fig. 6A. and B. Final control of the position the femoral component

Any excessive cement is removed under direct vision. In the same way the femoral component is cemented, a polyethylene inlay trial is then inserted and thereafter the patellar component is embedded with cement. After the cement is fully polymerized, the tourniquet is released and subtle hemostasis performed. Before the final choice of the inlay size is made, it is still possible to assess the joint and soft tissue balance using different size of polyethylene inlay trials and to show the resulting kinematics analysis on screen.

**2.1.5 Wound closure**

The joint is accurately irrigated and an intraarticular drain is inserted. The arthrotomy is closed with interrupted absorbable sutures (Vicryl 2.0) with the knee at 90° of flexion. After putting a second, subcutaneous drain, the subcutaneous layer is closed with Vicryl 2.0, and the skin is closed with Ethycriin 4.0.

Subsequently the final outcome and the kinematics are documented, recorded and compared to the initial data to assess the success of any correction (Figures 7A and 7B).



7A

Actual	min					+96°	max
+ Flexion - Hyperextension	-0.5°	+0.0°	+30.0°	+45.0°	+60.0°	+90.0°	+129.0°
+ Valgus - Varus	-1.5°	-1.0°	+0.5°	+0.5°	+1.0°	+0.0°	-0.5°
+ Internal - External	-8.0°	-8.0°	-5.0°	-5.0°	-5.0°	-3.0°	+4.0°
+ Compression - Distraction	-10	-10	-13	-11	-7	+0	+12
+ Medial - Lateral	+6	+6	+5	+5	+6	+7	+8
+ Anterior - Posterior	+10	+10	-8	-15	-22	-30	-38

7B

Fig. 7A. and B. The final outcome of the 3-dimensional axis (A) is documented on the screen as a value with a chart (B).

## 2.2 Postoperative treatment

For post-operative pain control, our patients first receive a “one-off sciatic nerve block (SB)” and then a continuous femoral nerve block (FB) [41, 42], combined with oral analgesics for both groups. Physical therapy is started as early as 4 to 6 hours post-operatively (continuous passive motion) and consequently intensified under supervision of an experienced physiotherapist (i.e. continuous passive motion 3 times a day, early ambulation, walking exercises, active bending and extending exercises, active knee stretching exercises, walking up and down stairs, leg press, ergometer-bike riding, coordination exercises, getting up from a seated position, strengthen exercises, etc.). Patients are allowed to full weight bearing as tolerated. Patients are discharged from the hospital once they are able to flex the knee joint to 120°, to perform an unassisted straight-leg raise, to walk independently with or without crutches, to rise from a chair to standing and sit from standing without support, and to ascend and descend a full flight of stairs. All patients receive Low Molecular Weight Heparin (LMWH, i.e. Fraxiparine®, Nadroparin) or a direct oral Factor Xa inhibitor (i.e. Xarelto®, Rivaroxaban) for deep venous thrombosis prophylaxis for 6 weeks. Outpatient physical therapy is started immediately after discharge. The Patients are evaluated clinically and radiographically in the office at 6 weeks, 3 months and 6 months.

## 2.3 Radiographic follow-up

All patients received full-length standing antero-posterior radiographs pre-operatively, at 6 weeks as well as 6 and 12 months post-operatively (“Philips® Multidiagnost 3”). Pre- and post-operative mechanical axes (i.e. the coronal mechanical axis of the limb, the Hip-Knee-Angle) were determined from radiographs. A mechanical axis of more than 3° varus/valgus was determined as outlier as defined previously [17, 18]. Conventional radiographic assessment involved short-leg-length weight-bearing antero-posterior (AP) radiographs, as well as non-rotated short-leg-length lateral radiographs at 30° of knee flexion and patella axial radiographs. The alignment of the prosthetic components was evaluated on the short-length standard radiographs. Radiographic parameters, including the coronal femoral component angle, the sagittal femoral component angle, the coronal tibial component angle and the sagittal tibial component angle (i.e. tibial slope angle) were evaluated to determine the correct position of the femoral and tibial components [43, 44]. The coronal alignment of the femoral component was measured in relation to the anatomical femoral axis (ideal value = 96°) and of the tibial component in relation to the anatomical tibial axis (ideal value = 90°). To determine the sagittal angle of the femoral and tibial components, a perpendicular line, drawn from the midline of the femoral respectively tibial components, was compared with the midline of the distal segment of the femur and of the proximal segment of the tibia using the Knee Score reference lines [45]. Although little consensus on the ideal reference for defining the slope of the tibia on the lateral radiograph is reached, we used the technique described by Catani et al. and Yoo et al., measuring the slope of the tibial component on conventional short-length sagittal view radiographs with reference to the proximal anatomic axis [16, 46]. Pre- and post-operative sagittal tibial component angles (i.e. tibial slope angle) were compared on conventional short-length lateral radiographs in 30° of knee flexion. All patients also received standardized CT-scans of both knees 6 weeks postoperatively to evaluate rotational alignment of the components according to the technique described by Berger et al. for our follow-up study [47].

### 3. Results and discussion

#### 3.1 CN TKA versus MIS CN TKA

In a previous study we compared two groups of patients either with a standard medial parapatellar approach (CN-TKA group) or with a minimal invasive mid-vastus approach (MIS CN-TKA group) [For further detailed information please see the references 48]. No inaccuracies of the Knee Navigation System (i.e. dirty reflectors, camera or rounding errors), or of the references pin itself (i.e. loosening of the reference pin intraoperatively and consequent inaccuracies in reference readings) were found. No switch to the conventional implantation method was necessary. Postoperative recovery of the patients was uneventful, there were no infections or wound healing disorders in both groups. No patients were lost to follow-up.

##### 3.1.1 Clinical outcome

The mean postoperative range of motion (ROM) after 3 months was significantly higher in MIS CN-TKA (125° MIS CN-TKA group vs. 118° CN-TKA group) ( $p = 0.037$ ). However, 6 months after operation there was no statistical relevant difference in range of motion between the two groups (125° vs. 122°) to be found. The Knee Society Clinical Rating Score (i.e. the knee and function scores) had improved in both groups to almost identical values 6 months after the operation. The mean length of hospital stay was significantly reduced in the MIS CN-TKA group ( $p < 0.0005$ ) resulting in a total duration of 8 days (range 6 - 9 days) versus 17 days (range: 8 - 31 days) in the CN-TKA group. We found no statistically difference between operation time and blood loss in the computer-assisted MIS TKA compared to the conventional CN-TKA group [For further detailed information please see the reference 48].

##### 3.1.2 Radiological outcome

The radiographic coronal mechanical axis of the limb (i.e. the Hip-Knee-Angle) improved to an orthograde level in both groups (CN TKA 0.5° versus MIS CN-TKA 0.7°). We found no outliers in both groups regarding alignment .

The tibial slope was significantly reconstructed to match the preoperative value not only in the conventional CN-TKA group (CN-TKA: mean value 1.6°) but also in the minimally invasive CN-TKA group (MIS CN-TKA: mean value 1.4°). The same accuracy was found for the implantation of the tibial component in the coronal alignment with no statistically significant difference between the conventional CN-TKA group (CN-TKA: mean value 91.3°) and the minimally invasive CN-TKA group (MIS CN-TKA: mean value 91.4°).

With regard to the accuracy of the coronal alignment of the femoral component we found a correct implantation of the femoral component in all cases and there was no statistically significant difference between both groups (CN-TKA (96.2°) vs. MIS CN-TK (95.2°)). The post-operative radiological analysis of the sagittal alignment of the femoral component in relation to the anatomical femoral axis revealed slight more flexion of the femoral components in both groups than planned pre-operatively (CN-TKA: mean value 6.9° versus MIS CN-TKA: mean value 7.8°). However, the intra-operative alignment of the sagittal femoral cut showed an accurate value closed to 1° of flexion not only in the conventional CN-TKA group (CN-TKA Group: mean value of 0.58°, standard deviation

0.44°, Range 0.00 - 1.50), but also in minimally invasive CN-TKA group (MIS CN-TKA Group: mean value of 1.03°, standard deviation 0.40°, Range 0.50 - 2.00). Moreover, the anterior flange of the femoral component was parallel to the dorsal femoral cortex in every patient of both groups.

### 3.1.3 Computed tomography outcome

The Analysis of the postoperative CT scans revealed a statistically significant reconstruction of the desired rotational alignment of the femoral component parallel to the transepicondylar axis not only in the conventional CN-TKA group (CN-TKA: mean value 0.7°) but also in the minimally invasive CN-TKA group (MIS CN-TKA: mean value 1.3°) ( $p = 0.018$ ). No outliers in the rotational alignment of the femoral prosthesis could be documented [For further detailed information please see the reference 48].

### 3.2 Discussion

It is well known by now that malposition of TKA affects implant fixation and leads to an increased risk of loosening, instability and decreased survival of the prosthesis. Computer-assisted navigation systems have been designed to increase the precision of implantation of TKA allowing the surgeon to reproduce the mechanical axes measured on full-length standing radiographs of the lower limb and reduces the number of outliers in the alignment of the limb compared to traditional mechanical instrumented TKA [9, 15-19, 21, 22, 48-54]. Two recent meta-analysis comparing alignment outcomes for computer-assisted navigated versus conventional TKA indicate a significant improvement in component orientation and mechanical axis, when computer-assisted navigation is used [55, 56]. Our analysis demonstrated that it is possible to achieve straight mechanical axes not only in the conventional but also in the minimally invasive approaches by using a computer-assisted navigation. Additionally intra-operative alignment of the femoral and tibial bone resection was accurate in all three planes not only in the conventional but also in the minimally invasive computer navigated TKA group. Similar intra-operative results have been published and our results showed the same accuracy of the intra-operative bone resections with the navigation system as the above mentioned [9, 16-18, 22].

However, the solely measurement of mechanical axis alone appears too basic as an indicator of correct limb alignment and long-term outcome. Accurate angles of the individual components in the coronal and sagittal planes, correct axial alignment and proper ligament and soft tissue balancing contribute to the success of knee replacement surgery and should be taken in consideration as well. The results of these data were also accurate in both groups using the computer-assisted navigation technique.

Different studies have compared computer-assisted systems with traditional implantation for improvement of component orientation. Most authors showed that the coronal alignment (i.e. the varus/ valgus alignment) of the femoral component was improved with the use of navigation [9, 16-18, 57-59]. Only few studies did not report an improvement in component alignment between patients in who navigation was used [60, 61]. Despite the fact that in these studies the senior authors have more experience with conventional than navigated TKA, the reduction of outliers was greater in the navigation group. However, all these studies investigated TKA implanted using conventional approach.

We were also able to demonstrate that, by using a computer-assisted navigation system, it is possible to implant the femoral and tibial components in the desired coronal and sagittal planes not only with the conventional but also with a minimally invasive approach. The post-operative radiographic analyses of the coronal alignment of the femoral and tibial components showed reliable results in both groups without any outliers in either group [For further detailed information please see the references 48].

Few further studies found the same accurate reconstruction of the sagittal alignment of the femoral component by using the navigation system, however with a standard conventional approach [9, 16, 19, 24, 25, 49, 57, 58, 62].

Literature documents that the influence of computer-assisted navigation on the alignment of the tibial component remains unclear. Several authors confirmed that the coronal alignment of the tibial component (i.e. the varus/ valgus alignment) is improved with the use of navigation [9, 24, 62], whereas other authors did not find evidence for improvement in coronal alignment [19, 49]. We found the same preciseness for the implantation of the tibial component in the coronal plane in the conventional as well as in the minimally invasive approach. Furthermore, we could demonstrate that the sagittal tibial component angle (i.e. the tibial slope angle) can be accurately and reproducibly reconstructed to match the original value of the tibial plateau in both computer-assisted approaches. Although some studies disagree that the alignment in the sagittal plane of the tibial component can be improved with navigation, our result confirmed, as it has been reported by other authors, that the surgeon can use, in practical terms, computer-assisted navigation to accurately restore the tibial slope during TKA using minimally invasive approaches as well [19, 24, 25, 28, 48, 49, 58, 63-68].

Even small abnormalities of rotational alignment of the components have a considerable influence on patellar tracking, varus/ valgus stability and on the overall biomechanics of the joint. The accuracy to adjust the rotational alignment of the femoral component is a prerequisite to avoid malfunctioning TKAs. Debate still exists whether a navigation system does improve the rotational alignment of the femoral component or not [67]. Several reference axes have been proposed to establish proper rotational alignment of the femoral components [63]. Of these axes, the transepicondylar axis approximates the flexion-extension axis of the knee. Furthermore, although there is no consensus about the best landmarks to gauge femoral rotation, alignment according to the surgical epicondylar axis seems to come closest to allowing physiological biomechanics [7, 8, 10, 67]. Debate continues with regard to how accurately and easily the transepicondylar axis can be located intra-operatively. Siston et al. found high variability in rotational alignment of the femoral component in a cadaver study [63]. This variability may be explained by the higher or lower ability of the surgeon to identify intra-operatively the medial epicondyle with its bone ridge and sulcus and the attachment of the deep and superficial fibers of the medial ligament, by the learning curve of the surgeon associated with the use of navigation and finally by the individual surgeon's skills. The algorithm of the Knee Navigation Software to establish the proper femoral rotational alignment by averaging the angle subtended by the Whiteside's line and the transepicondylar axis, gives the surgeon the possibility to improve the accuracy of the femoral rotational alignment without excessively increasing operative time. The analysis of our post-operative rotational alignment of the femoral component by CT-scans revealed a statistically



significant reconstruction of the desired rotational alignment of the prosthesis parallel to the transepicondylar axis not only in the conventional but also in the minimally invasive computer-assisted navigated approaches. These results are in agreement with other studies using standard approaches, computer-assisted navigation and an improved computer tomography protocol [16, 17, 24, 68].

Although it has been reported that the rotational mismatch between the femoral and tibial components is decreased with navigation, controversy still exists as to whether navigation systems do improve the rotational alignment of the tibial component in the axial plane [24, 68, 69]. We used the technique describe by Dalury and Eckhoff et al., whereby the orientation of the tibial tray was determined by allowing it to float into position with respect to the femoral component while the knee was placed through a full arc of flexion and extension [39, 40]. We were able to document an accurate alignment of the tibial component in the CT scan postoperatively in both computer-assisted navigated groups as well. However, we do believe that a navigation system that relies only on digitization of landmarks to establish the rotational alignment of the tibial component is not reliable enough. Further research is therefore necessary.

In addition to component malpositioning, tibiofemoral instability is another very important factor that might lead to implant failure and chronic pain. Some studies point out that 30% to 35% of the revision TKA were due to an uncorrected joint stability [20-21]. Tibiofemoral instability often represents a failure to correct the soft tissues balancing throughout the full range of motion and to adjust the flexion and extension gaps at the time of the primary arthroplasty. Furthermore, it is important to take the different behavior of involved ligaments on the medial and lateral aspects into consideration as well. This instability can be in extension, midflexion and/ or in flexion. Stability and function of TKA are strictly related to the interplay among the prosthetic component alignment, the articular surface geometry (flat or congruent polyethylene insert), the type and designs of prosthesis (cruciate-retaining versus cruciate-substituting prosthesis), as well as the balancing of the soft tissue and muscle action. Of all these factors, implant component alignments, joint line restoration and soft tissue balancing "can and must be" assessed and restored by the surgeon during the intervention. Calculation of the joint line height both at the femur and tibia is usually performed by measurements on pre- and post-operative radiographs using standard anatomical indices, which are very inaccurate and not reproducible. The computer assisted navigation system allows the surgeon to measure and restore accurately the alignments of the prosthetic components in all three geometrical planes, femoral joint height and the tibial joint line, as well as the desired soft tissue balancing [54].

An established concept is the preparation of a rectangular joint gap in TKA. With a posterior stabilized TKA, flexion and extension gaps can be different. This has been regarded as an important goal achieving good joint function. However, the lateral tibiofemoral joint is physiologically lax, and as consequence the flexion gap may not be rectangular. Van Damme et al. reported in a cadaveric study on normal non-arthritic knee joint an increased laxity lateral compared to medial in full extension, and an increased lateral laxity from 0° to 90° flexion [70]. Because of technical difficulties, only few data are available on the physiological laxity of the joint. Such analysis can only be performed if the flexed knee is imaged three-dimensionally both in neutral position and under a varus/ valgus stress. Tokuhara et al. analyzed quantitatively the stability of the medial

and lateral tibiofemoral joint for normal knees in an open MRI [71]. Their results indicate that the flexion gap in a normal knee is not rectangular and that the lateral joint gap is significantly lax. Recent biomechanical studies have further shown that flexion of the knee is associated with a significant medial-pivot internal rotation of the tibia [72-75]. Thus, in rotation the medial condyle is immobile and the lateral condyle is mobile on the tibial surface.

Since 1977, several studies have investigated the relationship between soft tissue release and the resulting changes in the tibiofemoral gaps in TKA using optical encoders, pressure-sensitive film, fluoroscopy or knee analysis system [76-79]. Computer-assisted surgical technology enables the surgeon to measure and assess knee behavior during operation, allowing real-time monitoring of knee's behavior from extension to flexion and soft tissue balance. In a previous study, we measured the mechanical axis and the varus/ valgus stability of the joint at different time points with the computer-assisted navigation and we documented a similar increased lateral joint laxity before and after implantation of the components at 45° and 90° of knee flexion. We even found that the overall laxity was decreasing beyond 45°/ 60° of flexion to maximal flexion [80]. Therefore, knee navigation allows the surgeon to objectively quantify and monitor kinematics and stability of the TKA through the full ROM pre-, intra- and post-operatively. Leaving the knee too lax after TKA may theoretically lead to tibiofemoral instability and excessive tightness of the joint in different position may cause stiffness. However, differently from TKA alignment, no data are available to define what is a well-balanced knee intra- and/or post-operatively. We suggested as ideal laxity for TKA a varus/ valgus laxity of an approximately total joint-line opening between 1.5° to 2° to be achieved from maximal extension to 45°/ 60° flexion and decreasing to 0.5° to 1.0° by further increasing flexion [80]. These findings serve as a benchmark for future soft tissue laxity measurements and additional work should be performed to validate these proposed values. The computer navigation will help to correlate the collected data and clinical outcomes more objectively than in the past and enable the setting of more accurate limits for soft tissue management.

Despite some motivating factors, including a potential reduction in duration of hospitalization and costs, one should not discount that the patient-driven desires include their concerns about postoperative pain, prolonged rehabilitation, and less than- ideal functional outcomes associated with conventional TKA. Various authors have also reported superior clinical results and decreased cost using minimally invasive techniques for TKA [24, 32, 43, 51, 52]. Obtaining these results with standard approaches and conventional instruments seem to cause much more soft tissue damages leading to an arduous recovery period for the patients. Although the length of the skin incision is shorter in the MIS approach, MIS knee surgery should not be defined by the size of the skin incision, but rather by the method of soft tissue handling once the skin is incised. Therefore, we should better substitute the misnomer "minimally invasive surgery" (MIS) for "soft-tissue sparing" surgery. We believe that minimal trauma of the soft tissue and bone results in better post-operative function and accelerated rehabilitation.

In a previous study, we were able to demonstrate that minimally invasive computer-assisted navigated TKA is able to achieve these objectives. With the minimally invasive approach patients were mobilized more aggressively reaching full weight bearing and profit by earlier discharge. Postoperative ROM after 3 months was significantly higher in MIS CN-TKA, but

after 6 months differences were minimal. Clinical scores were identical for both groups six months after surgery. However, these clinical scores have turned out not to be ideal for the evaluation of patient satisfaction immediately after a computer-assisted navigated TKA with a conventional or MIS approach [81-83]. It would have been more appropriate to use patients' self-reported measures of outcome, such as the WOMAC and the SF-36 score systems. In addition, a recent prospective randomized controlled study demonstrated a positive correlation between accurate mechanical alignment after TKA and functional and quality-of-life patients' outcomes [84]. At all post-operative follow-up intervals from 6 weeks to 12 months the total IKSS score were significantly better in patients with a mechanical axis within 3° of neutral compared to those greater than 3°. Moreover, the SF-12 physical scores at all intervals from 3 months were also significantly better for patients with a mechanical axis within 3° of neutral, and at 12 months these patients demonstrated better SF-12 mental-scores as well. Furthermore, another recent study showed, that TKA with good alignment lead to better function with quicker rehabilitation and earlier hospital discharge as well [85]. Therefore, the use of a computer-assisted navigation not only leads to reproducible accuracy of implant positioning in all three planes, but also to better functional outcomes with quicker rehabilitation and earlier hospital discharge due to the advantages of minimally invasive techniques.

### 3.3 Conclusion

Modern computerized knee navigation systems, appropriately used, aid surgeons to accurately optimize mechanical and axial alignments of the components in all three planes to avoid any malrotation and/ or any errors in coronal, sagittal and axial alignments. These advantages can be achieved not only in the conventional but also in minimally invasive approach without loss of accuracy. There is an increasing statistical evidence of a positive correlation between accurate mechanical alignment after TKA and a better functional as well as quality-of-life patient outcomes. Nevertheless the surgeon has to keep potential pitfalls in association with the computer-assisted procedures in mind. If used correctly, the system is very sophisticated and will improve accuracy. Therefore it will enhance the surgeon's perspective, but should never replace it.

The use of a computer-assisted navigation leads to reproducible accuracy of implant positioning in all three planes not only in the conventional but also in minimally invasive approaches. In contrast to even the most elaborate mechanical instrumentation system, which relies on visual inspection to confirm the accuracy of the alignment and stability of the TKA, computer-assisted navigation allows the surgeon to objectify every operative osteotomy, the position of trials and finally of the implants. It is well known that there is a definite relationship between the accuracy of implant positioning and longevity and therefore it is imperative to reproduce the implant positioning after a TKA.

Despite the above mentioned advantages and excellent results that may be achieved with computer-assisted navigation, certain factors still cause concern and need to be optimized. As only the cutting guides are navigated, the surgeons may make less than optimal bone resections by bending the saw blade, especially when attempting to cut through sclerotic areas of bone. Differences in cement thickness may also potentially lead to malalignment, even though bone resection was accurate. These latter two problems, which can occur with conventional instrumentation as well, can be obviated only by using the verification

plate of the navigation system to verify the correct level and direction of the performed osteotomy.

Computer-assisted technology assists the surgeon to reliably measure kinematics of TKA alignment and stability of the TKA on a screen. Furthermore, surgeons have the opportunity to improve their surgical performance with a direct intra-operative documentation of alignment and orientation of instruments, trials and implants. Additionally computer-assisted navigation allows to verify the final alignment of the implants after component implantation and before the cement hardens to avoid or probably correct considerable error in alignment.

Incorrect positioning of the components may only be a co-factor together with tibiofemoral instability and soft tissue trauma with MIS approach, leading to suboptimal implant loading with early loosening and increased wear. The use of computer-assisted navigation alone will not empower the surgeon to accurately and reproducibly implant a TKA. This might be especially true for the minimally invasive technique. Much technical expertise in the conventional TKA, the skill of the surgeon and their familiarity with the instruments may also be necessary to obtain good results.

#### **4. Competing interests**

The authors declare that they have no competing interest.

#### **5. Authors' contributions**

We thank Prof. Fabio Catani, Dr. Andrea Ensini, and their collaborator of the Istituti Ortopedici Rizzoli of Bologna, Italy, for their great personal commitment and help with the statistical analysis.

#### **6. Acknowledgements**

We appreciate the contribution of Dr. M. Brouwer, Dr. F. Tichler and Dr. M. Stephan, chairmen of the Anesthesiology Department at the Hospital Oberengadin in Samedan, who have contributed to the anesthesiology part of this article, as well. We also acknowledge the great support of the operating room personnel for their cooperation and the Swiss Stryker Company for their permanent remarkable supervision.

No funding or external support was received by any of the authors in support of or in any relationship to the study.

#### **7. References**

- [1] Callaghan JJ, O'Rourke MR, Iossi MF, Liu SS, Goetz DD, Vittetoe DA, et al. Cemented rotating-platform total knee replacement. A concise follow-up at a minimum of fifteen years. *J Bone Joint Surg Am* 2005; 87: 1995-1998.
- [2] Gill GS, Joshi AB. Long-term results of kinematic condylar knee replacement: An analysis of 404 knees. *J Bone Joint Surg Br* 2001; 83: 335-358.
- [3] Pavone V, Boettner F, Fickert S, Sculco TP. Total condylar knee arthroplasty: A long term follow-up. *Clin Orthop Relat Res* 2001; 388: 18-25.

- [4] Ritter MA, Berend ME, Meding JB, Keating EM, Faris PM, Crites BM. Long-term follow-up of anatomic graduated components posterior cruciate-retaining total knee replacement. *Clin Orthop Relat Res* 2001; 388: 51-57.
- [5] Rodrigues JA, Bhende H, Ranawat CS. Total condylar knee replacement: A 20-year follow-up study. *Clin Orthop Relat Res* 2001; 388: 10-17.
- [6] Insall JN, Binazzi R, Soudry M, Mestriner L. Total knee arthroplasty. *Clin Orthop Relat Res* 1985; 192: 13-22.
- [7] Insall JN, Scuderi GR, Komistek RD, Math K, Dennis D, Anderson DT. Correlation between condylar lift-off and femoral component alignment. *Clin Orthop Relat Res* 2002; 403: 143-152.
- [8] Barrack RL, Schrader T, Bertot AJ, Wolfe MW, Myers L. Component rotation and anterior knee pain after total knee arthroplasty. *Clin Orthop Relat Res* 2001; 392: 46-55.
- [9] Sparmann M, Wolke B, Czupalla H, Banzer D, Zink A. Positioning of total knee arthroplasty with and without navigation support. *J Bone Joint Surg Br* 2003; 85: 830-835.
- [10] Miller MC, Berger RA, Petrella AJ, Karmas A, Rubash HE. Optimizing femoral component rotation in total knee arthroplasty. *Clin Orthop Relat Res* 2001; 392: 38-45.
- [11] Nagamine R, White SE, McCarthy DS, Whiteside LA. Effect of rotational malposition of the femoral component on knee stability kinematics after total knee arthroplasty. *J Arthroplasty* 1995; 10: 265-270.
- [12] Romero J, Duronio JF, Sohrabi A, Alexander N, MacWilliams BC, Jones L, Hungerford D. Varus and valgus flexion laxity of total knee alignment methods in loaded cadaveric knees. *Clin Orthop Relat Res* 2002; 394: 243-253.
- [13] Figgie HE, Goldberg VM, Heiple KG, Moller HS, Gordon NH. The influence of tibial-patellofemoral location on function of the knee in patients with posterior stabilized condylar knee prosthesis. *J Bone Joint Surg Am* 1986; 68: 1035-40.
- [14] Piazza SJ, Delp SL, Stulberg SD, Stern SH. Posterior tilting of the tibial component decreases femoral rollback in posterior-substituting knee replacement: a computer simulation study. *J Orthop Res* 1998; 16: 264-70.
- [15] Ritter MA, Faris PM, Keating EM, Meding JB. Postoperative alignment of total knee replacement. Its effect on survival. *Clin Orthop Relat Res* 1994; 299: 153-156.
- [16] Catani F, Leardini A, Ensini A, Cucca G, Bragonzoni L, Toksvig-Larsen S, Giannini S. The stability of cemented tibial component of total knee arthroplasty: Posterior cruciate-retaining versus posterior-stabilized design. *J Arthroplasty* 2004; 19(6): 775-782.
- [17] Jeffery RS, Morris RW, Denham RA. Coronal alignment after total knee replacement. *J Bone Joint Surg Br* 1991; 73: 709-714.
- [18] Rand JA, Coventry MB. Ten-year evaluation of geometric total knee arthroplasty. *Clin Orthop Relat Res* 1988; 232: 168-173.
- [19] Matziolis G, Krocher D, Weiss U, Tohtz S, Perka C. A prospective, randomized study of computer-assisted and conventional total knee arthroplasty. *J Bone Joint Surg Am* 2007; 89:236-243.
- [20] Lotke PA, Ecker ML. Influence of positioning of prosthesis in total knee replacement. *J Bone Joint Surg Am* 1977; 59: 77-79.

- [21] Nabeyama R, Matsuda S, Miura H, Mawatari T, Kawano T, Iwamoto Y. The accuracy of image-guided knee replacement based on computed tomography. *J Bone Joint Surg Br* 2004; 86: 366-371.
- [22] Sharkey PF, Hozack WJ, Rothman RH, Shastri S, Jacoby S. Insall Award paper: why are total knee arthroplasties failing today? *Clin Orthop Relat Res* 2002; 404: 7-13.
- [23] Stulberg S, Loan P, Sarin V. Computer-assisted navigation in total knee replacement: Results of an initial experience in thirty-five patients. *J Bone Joint Surg Am* 2002; 84: 90-98.
- [24] Chauhan SK, Scott RG, Breidahl W, Beaver RJ. Computer-assisted knee arthroplasty versus a conventional jig-based technique. A randomized, prospective trial. *J Bone Joint Surg Br* 2004 Apr; 86(3): 372-7.
- [25] Stöckl B, Nogler M, Rosiek R, Fischer M, Kriesmer, Kessler O. Navigation improved accuracy of rotational alignment in total knee arthroplasty. *Clin Orthop Relat Res* 2004; 426: 180-186.
- [26] Bächis H, Perlick L, Tingart M, Luring C, Zurakowski D, Grifka J. Alignment in total knee arthroplasty: A comparison of computer-assisted surgery with conventional technique. *J Bone Joint Surg Br* 2004; 86: 682-687.
- [27] Martin A, Wohlgenannt O, Prenn M, Oelsch C, Stempel A. Imageless navigation for TKA increased implant accuracy. *Clin Orthop Relat Res* 2007; 460: 178-184.
- [28] Ensini A, Catani F, Leardini A, Romagnoli M, Giannini S. Alignments and clinical results in conventional and navigated total knee arthroplasty. *Clin Orthop Relat Res* 2007; 457:156-162.
- [29] Mielke RK, Clemens U, Jens JH, Kershally S. Navigation in knee endoprosthesis implantation: Preliminary experience and prospective comparative study with conventional implantation technique. *Z Orthop Ihre Grenzgeb* 2001; 139: 109-116.
- [30] Dalury DF and Dennis DA. Mini-incision total knee arthroplasty can increase risk of component malalignment. *Clin Orthop Relat Res* 2005; 440:77-81.
- [31] Insall JN. Choices and compromises in total knee arthroplasty. *Clin Orthop Relat Res* 1988; 226:43-48.
- [32] Bonutti PM, Mont MA, McMahon M, Ragland PS, Kester M. Minimally invasive total knee arthroplasty. *J Bone Joint Surg Am* 2004; 86: 26-32.
- [33] Repicci JA. Mini-invasive knee unicompartmental arthroplasty: bone-sparing technique. *Surg Technol Int*. 2003; 11: 282-286.
- [34] Tria AJ, Coon TM. Minimal incision total knee arthroplasty. *Clin Orthop Relat Res* 2003; 416: 185-190.
- [35] Scuderi GR, Tenholder M, Capeci C. Surgical approaches in mini-incision Total Knee Arthroplasty. *Clin Orthop Relat Res* 2004; 428:61-67.
- [36] Hofmann AA, Plaster RL, Murdock LE. Subvastus (southern) approach for primary total knee arthroplasty. *Clin Orthop Relat Res* 1991; 269:70-77.
- [37] Engh GA, Holt BT, Parks NL. A midvastus muscle-splitting approach for the total knee arthroplasty. *J Arthroplasty* 1997; 12: 322.
- [38] Berger TO, Aglietti P, Mondanelli N, Sensi L. Mini-subvastus versus parapatellar approach in total knee arthroplasty. *Clin Orthop Relat Res* 2005; 440: 82-87.
- [39] Dalury DF. Observations of the proximal tibia in total knee arthroplasty. *Clin Orthop Relat Res* 2001; 389:150-155.

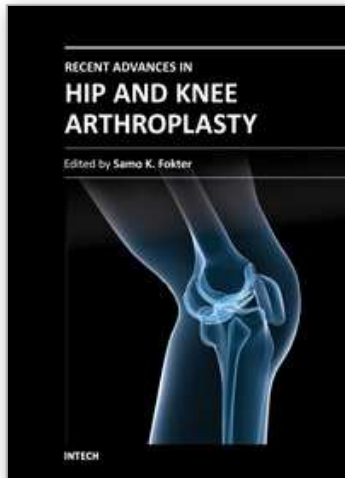
- [40] Eckhoff DG, Metzger RG, Vandewalle MV. Malrotation associated with implant alignment technique in total knee arthroplasty. *Clin Orthop Relat Res* 1995; 3211: 28-31.
- [41] Labat G. Its Technique and clinical applications: Regional Anesthesia. 2nd edition. Philadelphia, W.B. Saunders, 1924: 45-55.
- [42] Winnie AP, Ramamurthy S, Durrani Z. The inguinal paravascular technic of lumbar plexus anesthesia: the '3-in-1 block'. *Anesthesia and Analgesia* 1973; 52: 989-96.
- [43] Biasca N, Wirth S, Bungartz M. Mechanical accuracy of navigated minimally invasive total knee arthroplasty (MIS TKA). *The Knee* 2009;16 (1): 22-29.
- [44] Chin PL, Yang KY, Yeo SJ, Lo NN. Randomized control trial comparing radiographic total knee arthroplasty implant placement using computer navigation versus conventional technique. *J Arthroplasty* 2005; 20:618-626.
- [45] Ewald FC. The Knee Society Total Knee Arthroplasty roentgenographic evaluation and scoring system. *Clin Orthop Relat Res* 1989; 248: 9-12.
- [46] Yoo JH, Chang CB, Shin KS, Seong SC, Kim TK. Anatomical references to assess the posterior tibial slope in total knee arthroplasty: A comparison of 5 anatomical axes. *J Arthroplasty* 2008; 23(4): 586-592.
- [47] Berger RA, Rubash HE, Seel MJ, Thompson WH. Determining the rotational alignment of the femoral component in total knee arthroplasty using the epicondylar axis. *Clin Orthop Relat Res* 1993; 286: 40-47.
- [48] Biasca, N., Bungartz, M.: New on Minimally invasive computer-assisted navigated Total Knee Arthroplasty (MIS TKA). *Minerva Orthop Traumat* 2010; 1:1-10.
- [49] Jenny JY, Boeri C. Navigated implantation of total knee endoprosthesis: A comparative study with conventional instruments. *Z Orthop Ihre Grenzgeb* 2001; 139: 117-119.
- [50] Laskin RS. New techniques and concepts in total knee replacement. *Clin Orthop Relat Res* 2003; 416:151-153.
- [51] Bonutti PM, Neal DJ, Kestler MA. Minimal incision total knee arthroplasty using the suspended leg technique. *Orthopedics* 2003; 26: 899-903.
- [52] Laskin RS. Minimally invasive total knee arthroplasty: The results justify its use. *Clin Orthop Relat Res* 2005; 440: 54-59.
- [53] Karpman RR, Smith HL. Comparison of the early results of minimally invasive vs standard approaches to total knee arthroplasty: A prospective, randomized study. *J Arthroplasty* 2008, 24(5):681-8.
- [54] Catani F, Biasca N, Ensini A, Leardini A, Belvedere C, Giannini S. Tibial and femoral joint line restoration after navigated total knee arthroplasty. *J Bone Joint Surg Am* 2010, in Review.
- [55] Bauwens K, Matthes G, Wich M, Gebhard F, Hanson B, Ekkernkamp A, et al. Navigated total knee replacement: A meta-analysis. *J Bone Joint Surg Am* 2007; 89:261-269.
- [56] Mason JB, Fehring TK, Estok R, Banel D, Fahrback K. Meta-analysis of alignment outcomes in computer-assisted total knee arthroplasty surgery. *J Arthroplasty* 2007; 22(8): 1097-1106.
- [57] Jenny JY, Clemens U, Kohler S, Kiefer H, Konermann W, Miehle RK. Consistency of implantation of a total knee arthroplasty with a non-image-based navigation system. *J Arthroplasty* 2005; 20(7): 832-839.

- [58] Haaker RG, Stockheim M, Kamp M, Proff G, Breitenfelder J, Ottersbach A. Computer-assisted navigation increased precision of component placement in total knee arthroplasty. *Clin Orthop Relat Res* 2005; 433: 152-159.
- [59] Molfetta L, Caldo D. Computer navigation versus conventional implantation for varus knee total arthroplasty: A case-control study at 5 years follow-up. *The Knee* 2008; 15: 75-79.
- [60] Kim YH, Kim JS, Yoon SH. Alignment and orientation of the components in total knee replacement with and without navigation support. *J Bone Joint Surg Br* 2007; 89(4): 471-476.
- [61] Malik MH, Wadia F, Porter ML. Preliminary radiological evaluation of the Vector Vision CT-free knee module for implantation of the LCS knee prosthesis. *The Knee* 2007; 14(1): 19-21.
- [62] Decking R, Markmann Y, Fuchs J, Puhl W, Scharf HP. Leg axis after computer-navigated total knee arthroplasty: A randomized trial comparing computer-navigated and manual implantation. *J Arthroplasty* 2005; 20(3): 282-288.
- [63] Siston RA, Patel JJ, Goodman SB, Delp SL, Giori NJ. The variability of femoral rotational alignment in total knee arthroplasty. *J Bone Joint Surg Am* 2005; 87: 2276-2280.
- [64] Catani F, Biasca N, Ensini A, Leardini A, Bianchi L, Digennari V, et al. Alignment deviation between bone resection and final implant positioning in computer-navigated total knee arthroplasty. *J Bone Joint Surg Am* 2008; 90: 765-771.
- [65] Hart R, Janecek M, Chaker A, Bucek P. Total knee arthroplasty implanted with and without kinematic navigation. *Int Orthop* 2003; 27: 366-369.
- [66] Oberst M, Bertsch C, Wurstlin S, Holz U. CT analysis of leg alignment after conventional versus navigated knee prosthesis implantation. *Unfallchirurg* 2003; 106:941-948.
- [67] Olcott CW, Scott RD. The Ranawat Award. Femoral component rotation during total knee arthroplasty. *Clin Orthop Relat Res* 1999; 367: 39-42.
- [68] Chauhan SK, Clark GW, Lloyd S, Scott RG, Breidahl W, Sikorski JM. Computer-assisted total knee replacement: A controlled cadaver study using a multi-parameter quantitative ct assessment of alignment (the Perth CT Protocol). *J Bone Joint Surg Br* 2004; 86-B: 818-23.
- [69] Siston RA, Giori NJ, Goodman SB, Delp SL. Surgical navigation for total knee arthroplasty: A perspective. *J Biomech* 2007; 40: 728-735.
- [70] Van Damme G, Defoort K, Ducoulombier Y, Van Glabbeek F, Bellemans J, Victor J. What should the surgeon aim for when performing computer-assisted total knee arthroplasty? *J Bone Joint Surg Am* 2005; 87(Suppl 2): 52-58
- [71] Tokuhara Y, Kadoya Y, Nakagawa S, et al. The flexion gap in normal knees: An MRI Study. *J Bone Joint Surg [Br]* 2004; 86B1: 1133-6
- [72] Todo S, Kadoya Y, Moilanen T, et al. Anteroposterior and rotational movement of the femur during knee flexion. *Clin Orthop* 1999;362: 162-70.
- [73] Hill PF, Vedi V, Williams A, et al. Tibiofemoral movement 2: the loaded and unloaded living knee studied by MRI. *J Bone Joint Surg* 2000;82-B: 1196-8.
- [74] Iwaki H, Pinskerova V, Freeman MAR. Tibiofemoral movement 1: the shapes and relative movement of the femur and tibia in the unloaded cadaver knee. *J Bone Joint Surg* 2000;82-B: 1189-95.



- [75] Nakagawa S, Kadoya Y, Todo S, et al. Tibiofemoral movement 3: full flexion in the living knee studied by MRI. *J Bone Joint Surg [Br]* 2000;82-B: 1199-200.
- [76] Moore TH, Meyer MH. Apparatus to position knees for varus-valgus stress roentgenograms. *J Bone J Surg Am* 1977;59: 984.
- [77] Takahashi T, Wada Y, Yamamoto H. Soft tissue balancing with pressure distribution during total knee arthroplasty. *J Bone J Surg Br* 1997;79: 235-239.
- [78] Stahelin T, Kessler O, Pfirmann C, Jacob HAC, Romero J. Fluoroscopy assisted stress radiography for varus-valgus stability assessment in flexion after total knee arthroplasty. *J Arthroplasty* 2003;18: 513-515.
- [79] Oliver JH, Coughlin LP. Objective knee evaluation using the Genucum knee analysis system: Clinical implications. *Am J Sports Medicine* 1987;15: 571-578.
- [80] Wirth S, Biasca N. Joint laxity in navigated total knee arthroplasty. Presented at the 2006 CAOS Annual Meeting, Helsinki, 2006.
- [81] Ranawat CS, Insall J, Shine J. Duo-Condylar knee arthroplasty: Hospital for Special Surgery design. *Clin Orthop Relat Res* 1976; 120: 76-82
- [82] Insall JN, Dorr LD, Scott RD, Scott WN. Rationale of the Knee Society Clinical Rating System. *Clin Orthop Relat Res* 1989; 248: 13-14.
- [83] Lingard EA, Katz JN, Wright RJ, Wright EA, Sledge CB. Validity and responsiveness of the Knee Society Clinical Rating System in comparison with the SF-36 and WOMAC. *J Bone Joint Surg Am* 2001; 83(12): 1856-1864.
- [84] Choong PF, Dowsey MM, Stoney JD. Does accurate anatomical alignment result in better function and quality of life? A prospective randomized controlled trial comparing conventional and computer-assisted total knee arthroplasty. *J Arthroplasty* 2008, 24(4):560-9.
- [85] Longstaff LM, Sloan K, Stamp N, Scaddan M, Beaver R. Good alignment after Total Knee Arthroplasty leads to faster rehabilitation and better function. *J Arthroplasty* 2008, 24(4):570-8.

IntechOpen



## **Recent Advances in Hip and Knee Arthroplasty**

Edited by Dr. Samo Fokter

ISBN 978-953-307-841-0

Hard cover, 452 pages

**Publisher** InTech

**Published online** 27, January, 2012

**Published in print edition** January, 2012

The purpose of this book is to offer an exhaustive overview of the recent insights into the state-of-the-art in most performed arthroplasties of large joints of lower extremities. The treatment options in degenerative joint disease have evolved very quickly. Many surgical procedures are quite different today than they were only five years ago. In an effort to be comprehensive, this book addresses hip arthroplasty with special emphasis on evolving minimally invasive surgical techniques. Some challenging topics in hip arthroplasty are covered in an additional section. Particular attention is given to different designs of knee endoprotheses and soft tissue balance. Special situations in knee arthroplasty are covered in a special section. Recent advances in computer technology created the possibility for the routine use of navigation in knee arthroplasty and this remarkable success is covered in depth as well. Each chapter includes current philosophies, techniques, and an extensive review of the literature.

### **How to reference**

In order to correctly reference this scholarly work, feel free to copy and paste the following:

Nicola Biasca and Matthias Bungartz (2012). Strategies to Improve the Function, Kinematic and Implants' Positioning of a TKA with Minimally Invasive Computer-Assisted Navigation, Recent Advances in Hip and Knee Arthroplasty, Dr. Samo Fokter (Ed.), ISBN: 978-953-307-841-0, InTech, Available from: <http://www.intechopen.com/books/recent-advances-in-hip-and-knee-arthroplasty/strategies-to-improve-the-function-kinematic-and-implants-positioning-of-a-tka-with-minimally-invasi>

**INTECH**  
open science | open minds

### **InTech Europe**

University Campus STeP Ri  
Slavka Krautzeka 83/A  
51000 Rijeka, Croatia  
Phone: +385 (51) 770 447  
Fax: +385 (51) 686 166  
[www.intechopen.com](http://www.intechopen.com)

### **InTech China**

Unit 405, Office Block, Hotel Equatorial Shanghai  
No.65, Yan An Road (West), Shanghai, 200040, China  
中国上海市延安西路65号上海国际贵都大饭店办公楼405单元  
Phone: +86-21-62489820  
Fax: +86-21-62489821

© 2012 The Author(s). Licensee IntechOpen. This is an open access article distributed under the terms of the [Creative Commons Attribution 3.0 License](#), which permits unrestricted use, distribution, and reproduction in any medium, provided the original work is properly cited.

IntechOpen

IntechOpen