

# We are IntechOpen, the world's leading publisher of Open Access books Built by scientists, for scientists

## 4,800

Open access books available

## 122,000

International authors and editors

## 135M

Downloads

Our authors are among the

## 154

Countries delivered to

## TOP 1%

most cited scientists

## 12.2%

Contributors from top 500 universities

**WEB OF SCIENCE™**Selection of our books indexed in the Book Citation Index  
in Web of Science™ Core Collection (BKCI)

Interested in publishing with us?  
Contact [book.department@intechopen.com](mailto:book.department@intechopen.com)

Numbers displayed above are based on latest data collected.

For more information visit [www.intechopen.com](http://www.intechopen.com)

# Fixation of Periprosthetic Supracondylar Femur Fractures Above Total Knee Arthroplasty – The Indirect Reduction Technique with the Condylar Blade Plate and the Minimally Invasive Technique with the LISS

K. Kolb<sup>1</sup>, P.A. Grützner<sup>2</sup>, F. Marx<sup>3</sup> and W. Kolb<sup>4</sup>

<sup>1</sup>Department of Trauma Surgery Klinikum am Steinenberg, Reutlingen

<sup>2</sup>Department of Trauma Surgery Unfallklinik Ludwigshafen

<sup>3</sup>Department of Trauma Surgery, Friedrich-Schiller-University, Jena

<sup>4</sup>Department of Trauma and Orthopaedic Surgery, Bethesda Hospital, Stuttgart  
Germany

## 1. Introduction

Supracondylar fractures of the femur after total knee arthroplasty are an uncommon but highly challenging injury (Streubel et al., 2010). The management of distal femoral fractures following a total knee replacement can be complex and requires the equipment, perioperative support and surgical skills of both trauma and revision arthroplasty services (Johnston et al., 2011, Nauth et al., 2011). The incidence of periprosthetic supracondylar femur fractures after total knee arthroplasties ranges from 0.3% to 2.5%. A patient with revision total knee arthroplasty has a significantly higher risk of supracondylar fracture above the prosthesis (2-4%) (Merkel & Johnson, 1986; Berry, 1999). Interprosthetic femoral fractures tend to occur more frequently in the supracondylar region above total knee arthroplasty components (Mamczak et al., 2010). Predisposing factors are female gender, poor bone stock, rotationally constrained implants, stress risers such as screw holes around the knee, malalignment of the prosthesis, endosteal ischaemia (bone cement, spongiosa preparation), anterior femoral notching, arthrofibrosis, chronic steroid use, rheumatoid arthritis, revision total knee arthroplasties, poliomyelitis and Parkinson's disease (Table 1, Aaron & Scott, 1987; Ayers, 1997; Berry, 1999; Bogoch et al., 1987; Cain et al., 1986; Cordeiro et al., 1990; Culp et al., 1987; Diehl et al., 2006; DiGioia et al., 1991; Figgie et al., 1990; Haddad et al., 1999; Hirsh et al., 1981; Lesh et al., 2000; Merkel et al., 1986; Moran et al., 1996; Ritter et al., 1988; Roscoe et al., 1989; Shawen et al., 2003; Short et al., 1981; Sisto et al., 1985; Wick et al., 2004; Zehntner & Ganz, 1993). A biomechanical study has shown that notching of the anterior cortex significantly lessens the load to failure by decreasing the bending strength by 18% and the torsional strength by approximately 40% (Lesh et al., 2000). In a retrospective study, the clinical results of 1089 consecutive total knee replacements demonstrated no difference in knees managed with or without anterior femoral notching (Ritter et al., 2005). This finding emphasises the potential for osseous remodelling to decrease the risk of

fracture should an anterior notch occur (Dennis, 2001). Additionally, should an anterior notch of the distal part of the femur occur, the surgeon should consider implantation of a femoral component with an attached diaphysis-engaging stem to support the weakened distal part of the femur (Dennis, 2001).

Motions of stiff knees under anaesthesia have a high risk of periprosthetic supracondylar femur fractures (Diehl et al., 2006).

| <b>General</b>                      | <b>Femur</b>                   |
|-------------------------------------|--------------------------------|
| Patient depending factors           |                                |
| Osteoporosis                        | Female gender                  |
| Bone disease (M. Paget)             |                                |
| Rheumatoid arthritis                | Arthrofibrosis                 |
| Steroid abuse                       |                                |
| Neurologic abnormalities            |                                |
| Malalignment                        |                                |
| Infections                          |                                |
| <b>Surgery dependant factors</b>    |                                |
| Revision total knee arthroplasty    | Malalignment of the prosthesis |
| Removal of cement                   | Implantation error             |
| Screw holes around the knee         | Anterior femoral notching      |
| Osteolysis due to wear              |                                |
| Stress shielding                    |                                |
| Motion under anaesthesia            | Endosteal ischemia             |
| <b>Prosthesis dependant factors</b> |                                |
|                                     | Intramedullary stems           |
|                                     | Constrained prosthesis         |

Table 1. Risk factors for periprosthetic supracondylar femur fractures above total knee arthroplasty modified according to (Diehl et al., 2006 ; Nauth et al., 2011)

Most periprosthetic femur fractures occur between two and four years after a total knee arthroplasty (Ehrhardt & Kuster, 2010). The number of these cases may rise quickly, given the projection that, by the year 2030, the implantation of total knee arthroplasties will increase to 3.48 million in the United States, an increase of 673% compared with 2005. The most frequent mechanism of injury is a low-velocity fall onto the knee in combination with torsion or axial compression, with a smaller proportion resulting from high-energy trauma (e.g., motor vehicle accidents) (Su et al., 2004)

The complication rate of these fractures is between 25% and 75%. Conservative treatment of displaced fractures with casting results in malalignment (25-100%), non-union (20-35%), loss of motion of the knee, and inability to maintain reduction of the fracture (Kolb et al., 2009). Surgical treatment provides the best restoration of mechanical alignment to the limb, permits early mobilisation to avoid the complications of prolonged bed rest, and may maximise healing potential in a region where blood supply is already compromised by providing stable fixation (Rorabeck & Taylor, 1999). In 1970, the AO (Arbeitsgemeinschaft für Osteosynthesefragen) published the first results of 112 supracondylar femoral fractures treated according to their principles using a condylar plate, a fixed angle device, with 74% good or excellent results (Wenzl et al., 1970).

The reported complications of operative treatment included deep infection (3%), fixation failure (4%), non-union (9%), and revision surgery (13%) (Herrera et al., 2008). The treatment of periprosthetic fractures around the knee can be challenging for a number of reasons (Healy et al., 1993; Kim et al., 2006; Rhinelander, 1972): (1) these fractures occur in patients with poor bone stock that can compromise potential fixation; (2) the majority of these patients are elderly and, because of their age may have retarded fracture healing; (3) the epiphyseal and frequently the intramedullary blood supplies of the distal femur are interrupted after total knee arthroplasty; (4) after a fracture of the distal part of the femur immediate reduction of total bone blood flow by nearly 50% through the physiological vasoconstriction in both the periosteal and intramedullary vessels further impairs blood supply; (5) the attachment of the ligamentous structures to the fracture fragment may predispose these knees to potential instability, necessitating the use of a constrained prosthesis with all their potential problems. The wide metaphyseal and diaphyseal spaces, osteopenia, and distal extension of the fracture often associated with these elderly patients can result in suboptimal internal fixation (Ricci et al., 2006). Fractures with stable prostheses are best treated with some means of internal fixation and without stem revision (Dennis, 2001).

Ideally, the treatment of a supracondylar femoral fracture above a total knee arthroplasty would be characterised as follows (Kregor et al., 2001):

- The ability of the patient to return to pre-accident function,
- A surgical technique that is minimally invasive,
- Capability of immediate motion,
- No need for bone-grafting,
- Low risk of infection, and
- Adaptability to various total knee designs.

In practice, flexible intramedullary nails, rigid retrograde IM nails, angled blade plates, cobra plates, dynamic condylar screws and Ilizarov external fixators have been used (Althausen et al., 2003; Beris et al., 2010; Chettiar et al., 2009; Gliatis et al., 2005; Maniar et al., 1996; McLaren et al., 1994; Rorabeck & Taylor, 1999; Zehntner & Ganz, 1993).

Fixation with conventional compression plates, though for the most part successful, has its limitations (Kubiak et al., 2006). Conventional plate osteosynthesis (CPO) with rigid fixation has shown a high complication rate that includes delayed or non-union, infection, hardware failure and re-fracture after plate removal (Bostman, 1983; Claes et al., 1999; Finsen & Benum, 1986; Hidaka & Gustilo, 1984; Kenwright & Goodship, 1989; Kessler et al., 1992; Mulier et al., 1997; Noorda & Wuisman, 2002; Riemer et al., 1992; Stoffel et al., 2003).

(Mast et al., 1989) pioneered the indirect reduction technique without disturbance of the soft tissue envelope around the fracture itself.

The concept of the indirect reduction technique is to provide reduction of the fracture through traction across the intact soft tissues and decreased surgical dissection of the fracture site (Mast et al., 1989). Minimally invasive plate osteosynthesis (MIPO) have been introduced to go one step further (Krettek et al., 1997). Locked plate fixators improved the stability of plate osteosynthesis significantly (Streubel et al., 2010; Kolb et al., 2010). The combination of locked plate fixators and the MIPO technique allows for plate osteosynthesis without bone grafts (Streubel et al., 2010; Kolb et al., 2010).

The aim of this report is to describe new planning methods and new techniques of internal fixation for supracondylar femur fractures above total knee arthroplasty.

## 2. Preoperative assessment

Preoperative clinical evaluation involves questions related to general factors that include smoking, peripheral vascular and neurological status, nutritional status, comorbidities such as diabetes, alignment of the injured leg, pre-injury range of motion of the knee, knee extensor mechanism, signs of loosening of the prosthesis (weight dependant pain, knee instability, reduced walking distance), infection and activity level. Radiographic assessment includes anterior posterior (a.p.), lateral and oblique radiographs of the knee and femur including the hip and former radiographs if available (Diehl et al. 2006; Ehrhardt & Kuster, 2010). Specifically, the lateral radiograph is used to assess (Kregor et al., 2001) the following: 1. the integrity of the femoral component-bone interface to assess potential loosening, 2. the bone block attached to the femoral component, and 3. the position of the cement mantle and flange for the femoral component. Modern CT scans provide more information concerning the integrity of the femoral-bone interface to assess potential loosening of the prosthesis (Kregor et al., 2001; Ehrhardt & Kuster, 2010). Both the type and classification of fractures and the type of prosthesis should be known preoperatively because this information is very important for choosing the right treatment option (Ehrhardt & Kuster 2010). The operative report should be available whenever possible (Ehrhardt & Kuster, 2010).

### 2.1 Classification

The classification system that is the most valuable to management was created by Rorabeck & Young (Fig. 1, Rorabeck & Taylor, 1999; Dennis, 2001). Their classification system takes

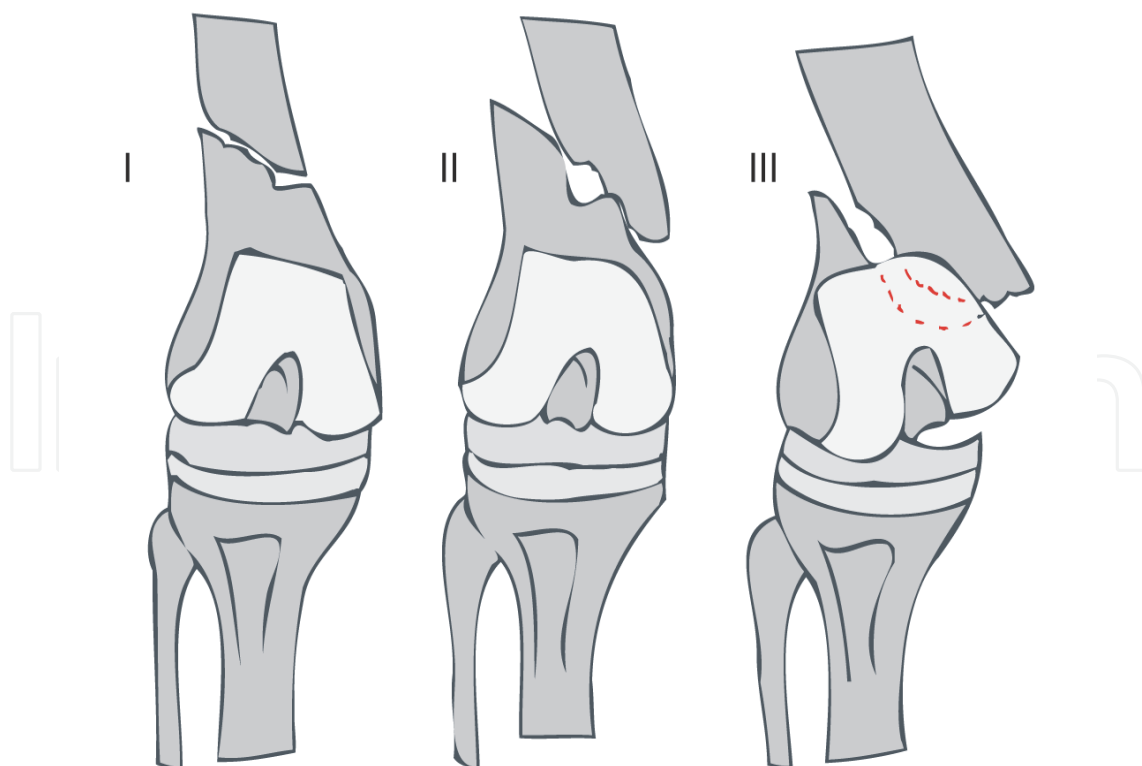


Fig. 1. The Classification system of supracondylar femoral fractures above total knee arthroplasties created by (Rorabeck & Young, 1999)

into account both the status of the prosthesis (that is, whether it is intact or failing) and the displacement of the fracture (Dennis, 2001).

(Su et al., 2004) developed their classification system because patients are increasingly being treated operatively and the bone stock of the distal segment continues to be considered a key limiting factor to obtaining adequate fixation (Herrera et al., 2008). Their classification system takes into account the height of the fractures (Table 2, Su et al., 2004).

| Fracture Type | Fracture Height  |
|---------------|--|
| I             | Fracture above the femoral component   |
| II            | Fracture above the femoral component, fracture reaching the tip of the femoral component |
| III           | Fractures below the tip of the femoral component   |

Table 2. Classification system of supracondylar femoral fractures above total knee arthroplasties created by (Su et al., 2004)

### 3. Treatment options

The goals of treating supracondylar femoral fractures above total knee arthroplasties are to obtain and maintain good postfracture alignment and stability to allow an early range of motion and bone healing (Culp et al., 1987; Rorabeck & Taylor, 1999; Dennis, 1998; Ehrhardt & Kuster, 2010). Acceptable alignments exhibit translations that are less than 5 mm, angulations that are less than 5°-10°, minimal rotations, less than 1 cm of femoral shortening, and proper tibiofemoral prosthetic joint alignments (DiGioia & Rubash, 1991). High malunion rates are common in association with varus, flexion, and internal rotation deformities typically seen as a result of forces exerted by the adductor and gastrocnemius muscle groups (Figgie et al., 1990; Dennis, 2001).

#### 3.1 Non-operative treatment

The non-operative options include skeletal traction, application of a cast, pins and plaster, and cast bracing (Dennis et al., 2001). Traction has a high complication rate and is no longer an option. According to Rorabeck & Young, only fracture type I can be treated conservatively, 4-6 weeks with a cast and 6 weeks of mobilisation with a brace (Chen et al., 1994). However, this treatment may be associated with difficulty in maintaining the reduction, a prolonged period of immobilisation, reduced knee functions, malunion and non-union (McGraw, P.; & Kumar, A., 2010). Conservative treatment was followed by non-union in 20% and mal-union in 23% of the cases evaluated (Culp et al., 1987). Casting resulted in an average loss of motion of 26° (Culp et al., 1987). Of these fractures, 29% eventually required operative care (Harlow & Hofmann, 1994; Dennis, 2001).

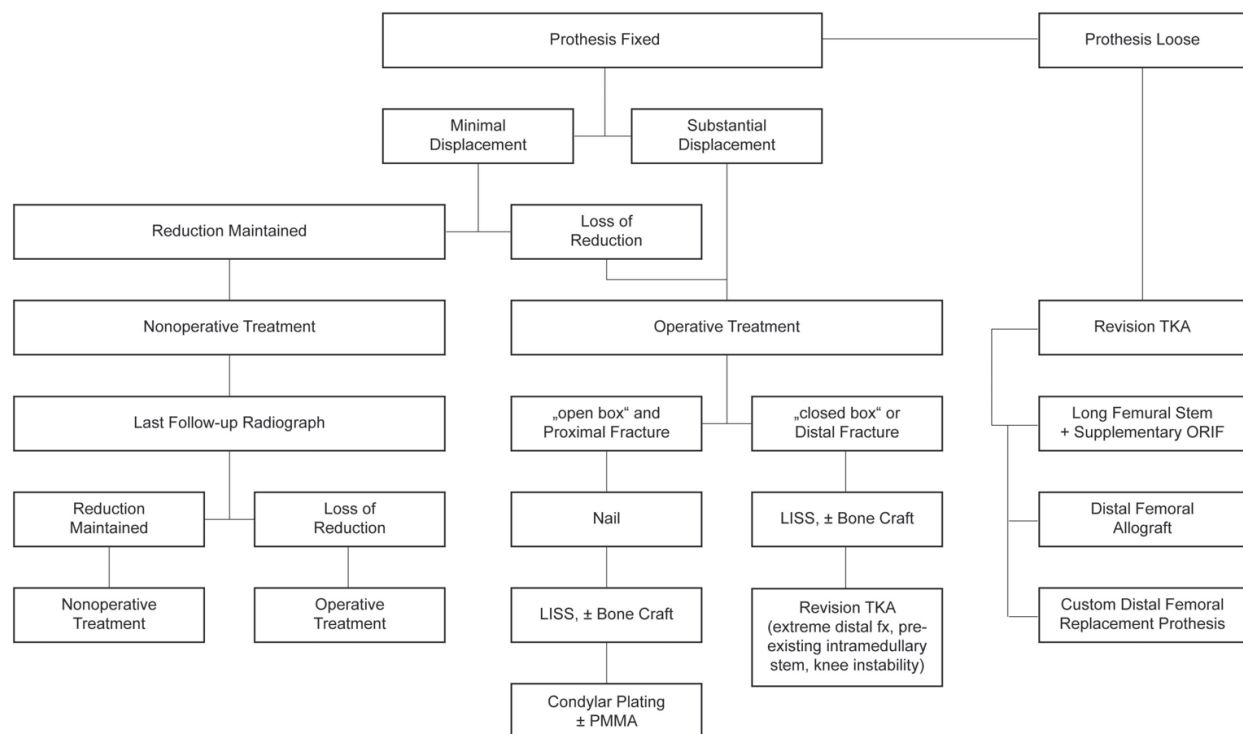


Fig. 2. Schematic of treatment options for supracondylar femoral fractures above total knee arthroplasties. TKA=total knee arthroplasty, PMMA=polymethylmethacrylate

### 3.2 Operative treatment

Several options are available to provide secure internal fixation of supracondylar fractures of the distal femur (Fig. 2, Ayers, 1997; Kolb et al., 2009). Many factors must be considered in choosing the most appropriate management method for these fractures including the patients general health, prefracture ambulatory status, fracture pattern, location, displacement, and type of implant (Su et al., 2004). Periprosthetic fractures above total knee arthroplasties have particular risks for failure, including wide metaphyseal and diaphyseal spaces, osteoporosis, small distal femoral fragments, and prosthetic anchorage pegs reducing the sites for fixation (Kolb et al., 2010). Surgical options include intramedullary devices, condylar buttress plates and, - more recently, - locking plates (internal fixators) that are typically placed in a submuscular manner (Herrera et al., 2008).

### 3.3 Conventional plate osteosynthesis

The two basic types of fixed angle devices are the condylar screw plate and the 95° condylar blade plate. They work best for more proximal fractures and when there is minimal comminution of the distal fragments (Ayers, 1997; Su et al., 2004). The advantages of the 95° condylar plate are that no bone has to be removed from the distal fragment when this device is inserted and that the blade is relatively thin (Healy et al., 1993). The blade can therefore, be placed close to the lugs of the femoral component and close to the anterior femoral flange (Healy et al., 1993). Usually, the entry site for the blade chisel is at a height of 2.5-3 cm above the prosthetic joint line, depending on the configuration of the fracture and the prosthetic design (Moran et al., 1996). However, the angled 95° condylar blade plates do not provide sufficient stability in osteoporotic bone and might interfere with the fixation lugs of

the femoral component, and the polymethylmethacrylate (Zehntner & Ganz 1993, Chen et al. 1994). Of the total numbers of conventional plate osteosynthesis an average of 32% (range, 0-75%) primary bone grafts were used. A mean of 10% (range, 0-50%) of those with conventional plate osteosynthesis (CPO) had an implant failure and developed a non-union (Table 3, Kolb et al., 2009).

| Authors, year of publication | Bone graft (n, % early/late) | Infection | Implant failure | Non-union (n, %) | Results of fixation   |
|------------------------------|------------------------------|-----------|-----------------|------------------|---|
| Sisto et al., 1985           | 0                            | 0         | 0               | 0                | Valgus 3° 1 (33%)<br>Valgus 5° 2 (66%)                          |
| Merkel et al., 1986          | 2 (40%)                      | 1 (20%)   | 0               | 0                | Normal alignment  |
| Figgie et al., 1990          | 4 (40%)                      | 0         | 5 (50%)         | 5 (50%)          | Varus 7° 5 (23%)?   |
| Healy et al., 1993           | 15/3 (75%/15%)               | 0         | 0               | 0                | Normal alignment  |
| Zehntner et al., 1993        | 2 (30%)                      | 0         | 0               | 0                | Valgus 5° (range, 0-10°)  |
| Moran et al., 1996           | 6/2 (40%/13%)                | 0         | 3 (20%)         | 3 (20%)          | Shortening 2 cm 3 (20%)<br>Valgus 17° 1 (7%)<br>Varus 2° 1 (7%) |
| Ochsner et al., 1999         | 0                            | 0         | 0               | 0                | Varus   |

Table 3. Complications of conventional plate osteosynthesis (CPO) of fractures above fixed total knee arthroplasties (from Kolb et al., 2009).

The indirect reduction technique allows for the use of longer plates with less pullout force acting on the screws due to improvement of the working leverage and significant stress reduction in the plate (50%-85%) (Kolb et al., 2009; Gautier & Sommer, 2003; Stoffel et al., 2003). Various methods have been used to enhance fixation using internal fixation (McGraw, P.; & Kumar, A., 2010). In severely osteoporotic bone, polymethylmethacrylate can be used to enhance screw fixation (Zehentner & Ganz, 1993). An intramedullary autograft is another option to help restore bone stock and achieve quadric-cortical fixation of the screws (Tani et al., 1998). However, this technique has not been widely used because of donor-site morbidity, particularly in elderly patients (McGraw, P.; & Kumar, A., 2010).

Combining medial strut allografts with compression plates allows for fixation of severe osteoporotic fractures and failures of initial open reduction and internal fixation (Wang & Wang, 2002). Three patients with very low and comminuted fractures exhibited good results using intramedullary fibular strut allografts without donor-site morbidities (Kumar et al., 2008).

The epiphyseal and frequently the intramedullary blood supplies of the distal femur are interrupted after total knee arthroplasty (Healy et al., 1993). Immediate reduction of total bone blood flow after a fracture of the distal part of the femur through physiological



vasoconstriction in both the periosteal and intramedullary vessels by nearly 50% further impairs blood supply (Rhineland, 1972). Fractures above total knee arthroplasties may have greater tendencies to non-unions than do distal femoral fractures not associated with arthroplasties (Moran et al., 1996). Microangiographic studies have demonstrated that much of the vascular supply to the callus area derives from the surrounding soft tissue (Rhineland, 1972). Conventional plate osteosynthesis produces compression between the implant and the bone and probably further impairs the blood supply (Fig 3 Healy et al., 1993; Wagner, 2003). Plates interfere significantly with the periosteal blood supply, resulting in bone necrosis (Perren et al., 1988). Direct manipulation of bone fragments in conventional plate osteosynthesis is a major cause of devitalisation of the bone fragments (Leunig et al., 2000). Medial dissection of soft tissue can disrupt this important blood supply and is, thus, to be avoided (Mast et al., 1989).

The extreme difference in healing time between conservative treatment (3 months) and compression fixation (15 months) indicates that the circumstances can be improved (Perren, 2003). Bone union depends on respecting the capacity of the soft tissues to maintain vascular supply to the bone, on the reduction of the fracture, and on applying the technique that best provides the necessary stability for union to occur (Wagner & Frigg, 2006). Surgical treatment should take biological, biomechanical and surgical aspects into account (Table 4, Korner et al., 2003).

| AO principles THEN (Müller et al., 1970) | Influences through clinical experiences and experimental investigations  | AO principles NOW (Wagner & Frigg, 2006)  |
|--|--|---|
| 1. Anatomical precise reduction          | <p>Applied science concerning:</p> <ul style="list-style-type: none"> <li>- bone healings,</li> <li>- blood supply through soft tissues and bone,</li> <li>- biological shortcomings of ORIF in multifragmentary shaft fractures lead to a new way of thinking.</li> </ul> <p>As a consequence, indirect reduction techniques were developed</p> | <p>Fracture reduction and fixation to restore anatomical relationships. Reductions need not be anatomical but only axially aligned in the diaphysis and the metaphysis. Anatomical reduction is required for intra-articular reductions. The principles of articular fracture care:</p> <ul style="list-style-type: none"> <li>- atraumatic anatomical reduction of the articular surfaces,</li> <li>stable fixation of the articular fragments, and</li> <li>- metaphyseal reconstruction with bone grafting and buttressing apply as they did at the beginning</li> </ul> |

|   |   |  |
|---|---|--|
| <p>2. Rigid fixation, absolute stability</p>  | <p>The most notable change in the treatment of diaphyseal fractures has been the shift from the mechanical to the biological aspects of internal fixation. The preservation of the viability and integrity of the soft tissue envelope of the metaphysis has been recognized as the key to success. Today the dominant theme in the fixation of fractures of the diaphysis is the biology of bone and the preservation of the blood supply to bony fragments, and no longer the quest for absolute stability. Major changes have occurred in the timing of the different steps of metaphyseal reconstruction, as well as in the fixation methods and techniques. The comprehensive classification of long bones has helped predict treatment and outcome.</p> | <p>Stabilisation with different grades of stability, from high (absolute stability) to low (relative stability). Appropriate construct stability. Stability by compression or splinting, as the fracture pattern and the injury require. The joint surfaces require anatomical reduction with absolute stability. The majority of diaphyseal fractures are treated with relative stability methods (eg. intramedullary or extramedullary splinting).</p> |
| <p>3. Preserving blood supply</p>   | <p>The present concept still emphasises that the blood supply through the soft tissues and bone is the most important aspect in fracture care.<br/>- atraumatic soft tissue technique through the appropriate surgical approaches,<br/>- atraumatic reduction and fixation techniques are mandatory,<br/>- implants with new bone-implant interface</p>   | <p>Preservation of the blood supply to soft tissues and bone by careful handling and gentle reduction techniques and a newly designed bone-implant interface</p>   |
| <p>4. Early protective motion for rehabilitation because pain was abolished and union assured</p> |   | <p>Early and safe mobilisation of the part and the patient. Early active motion can also be carried out because splint fixation is stable enough to allow postoperative functional care</p>  |

Table 4. Comparison of AO principles from 1970 and 2006 (from Wagner and Frigg, 2006).

### **3.4 Plate osteosynthesis with the indirect reduction technique**

The concept of biological internal fixation entails preserving the biologic reactivity of the tissue as much as possible (Rozbruch et al., 1998). This process includes careful tissue dissection, epiperiosteal bone dissection, and indirect reduction of the fracture to avoid the stripping and de-vascularisation of bone fragments (Rozbruch et al., 1998). (Mast et al., 1989) pioneered the indirect reduction of fractures without disturbance of the soft tissue envelope around the fracture and reduced blood loss. One example of an indirect reduction method is the distraction of fragments using a distractor, an external fixator, a plate or traction applied to a limb (Wagner & Frigg, 2006). The fragments are reduced using ligamentotaxis, minimising the extent to which they are manipulated and preserving their blood supply (Babst et al., 2001; Rüedi et al., 1998; Wagner & Frigg, 2006; Vidal et al., 1979). Primary grafting, which is often used in CPO is not necessary (Kolb et al., 2009; Ricci et al., 2005; Ricci et al., 2006). Minimally invasive techniques (i.e., MIPO) go one step further (Krettek et al., 1997). The bridging plate is one of the early developments of an internal fixator (Brunner & Weber, 1982). Recent developments are the Schuhli nut developed by Mast (Kolodziej et al., 1998), the Zespol plate (Ramotowski & Granowski, 1991), the point contact fixator (PC-Fix) (Tepic et al., 1997), the less invasive stabilisation system (LISS) (Frigg et al., 2001), and the locking compression plate (LCP) (Frigg, 2003). Healing has been accelerated with the PC-Fix, so that its removal is possible after only 3 months (Wagner & Frigg, 2006). Local infection resistance has been improved, such that 750 times more *Staphylococcus aureus* were required to produce the same incidence of infection with the PC-Fix as with the dynamic compression plate (Arens et al., 1999).

### **3.5 Minimally invasive osteosynthesis with internal fixators and retrograde nails**

Internal fixators and retrograde nails have advantages in minimally invasive osteosynthesis (MIO) compared to the condylar plate (Ehrhardt & Kuster, 2010). Numerous studies (Chettiar et al., 2009; Gliatis et al., 2005; Henry, 1995; Mittlmeier et al., 2005; Murrell & Nunley, 1995; Platzer et al., 2010; Rolston et al., 1995; Smith et al., 1996) recommend nailing in the posterior cruciate ligament retaining femoral component with an open box. The supracondylar nail preserves the fracture haematoma, does not require extensive soft-tissue stripping, and provides fair stability to the fracture (Figgie et al., 1990; Gardner et al., 2004; Gliatis et al., 2005; Kolb et al., 2008; Mittlmeier & Beck 2005; Stedtfeld et al., 2004). Problems associated with the use of a retrograde nail include malalignment due to a poor starting point, flexion malalignment as a result of the knee flexion required for access to the joint during reaming and nail placement, and insufficient distal stability (Horwitz & Kubiak, 2010). The intercondylar distance must be at least 11mm or 12 mm to accommodate the nail, and the knee flexion must be at least 60° (Diehl et al., 2006; Kolb et al., 2010; Rolston et al., 1995). Small distal fragments should have enough space for at least two screws (Diehl et al., 2006, Kolb et al., 2010; Mittlmeier et al., 2005). Many systems include an interference screw that can be placed in the most distal screw hole to convert the nail to a fixed-angle device (Horwitz & Kubiak, 2010). However, these systems still fail because the osteoporotic cancellous bone is inadequate, and it is not uncommon for a distal femoral fracture to drift into valgus at the site of the nail fixation (Horwitz & Kubiak, 2010). Angular correction and additional stability can be achieved by placing blocking screws in the distal fragment (Stedtfeld et al., 2004). In a retrospective study, 14 supracondylar periprosthetic fractures obtained good functional outcomes, a low complication rate and 100% fracture unions (Chettiar et al., 2009).

### **3.6 Minimally invasive osteosynthesis with the Less Invasive Stabilisation System (LISS)**

The LISS has theoretical advantages for the treatment of supracondylar femoral fractures above well-fixed total knee arthroplasties (Kolb et al., 2010). Broadly, the advantages of the LISS fixator are attributable to three factors (Kregor et al., 2001):

1. The ability to place multiple fixed-angled locked screws, offering improved stability of the distal fragment,
2. the ability to place percutaneous screws in the proximal femur without dissection of the metaphyseal/diaphyseal component of the fracture,
3. the ability to place 3 or 4 screws even in small distal fragments.

The bridge-plating technique produces minimal biological damage with locked flexible fixation (Ehinger et al., 2011; Thielemann et al., 1988; Rozbruch et al., 1998; Perren, 2002; Gautier & Jakob, 2004). The minimally invasive plate-osteosynthesis technique leaves the blood supply largely intact and reduces blood loss compared with the conventional plate osteosynthesis using a standard approach (Mast et al., 1989; Krettek et al., 1997; Grützner et al., 1997; Farouk et al., 1998; Krettek et al., 2001; Althausen et al., 2003; Kolb et al., 2003). It avoids the need for precise reduction and exposure of the bone, thus reducing surgical trauma (Thielemann et al., 1988; Gerber et al., 1990; Ganz et al., 1991; Rozbruch et al., 1998; Perren, 2002). The locked plates provided significantly greater fixation stability than the standard plate, blade plate, condylar buttress plate, dynamic condylar screws, or the retrograde nail in biomechanical studies involving axial loading with mild to moderate osteoporotic femurs (Egol et al., 2004; Ganz et al., 1991; Koval et al., 1997; Marti et al., 2001; Salas et al., 2011; Zlowodzki et al., 2004). The probability of periprosthetic fracture of the locking plate compared to the retrograde IM nail (in a deterministic finite element model of each construct type) was higher under the applied loading conditions (locking plate 21.8% versus IM nail 0.019%) (Salas et al., 2011). By using an internal fixator with locked screw heads, the screw loading is primarily bending and not pullout (Gautier & Sommer, 2003; Wagner & Frigg, 2006). Locked screws provide improved anchorage and safety and they cannot be stripped during their insertion because they limit the torque applied to the screw thread (Perren, 2003, Fig 3a and 3b). The pull out resistance of the LISS is increased with convergent screws in the femoral condyle. These plates are particularly useful in the presence of a proximal femur implant as they allow unicortical screw fixation that overlap the distal part of the proximal implant, thereby avoiding a stress riser between the two implants (McGraw & Kumar, 2010). Blood supply to the bone is preserved, and no contact between the fixator and the bone required (Kolb et al., 2010).

### **3.7 Osteosynthesis with the locking compression plate (LCP) and polyaxial locking plates**

In September 1998, Professor Michael Wagner (of the Wilhelminen Hospital in Vienna) questioned whether it was possible to make the LISS screw-head hole compatible with conventional bone screws (Frigg, 2003). As a result the locking compression plate (LCP) was developed. It has a combined plate hole, which allows for the use of conventional bone screws or locked screws. The possibility of using the LCP as a compression plate (> primary fracture healing), an internal fixator (> secondary fracture healing) or in a specific combination (hybrid fixation) allows for ideal plate anchorage that is adapted to the bone (Frigg, 2003; Wagner, 2003).

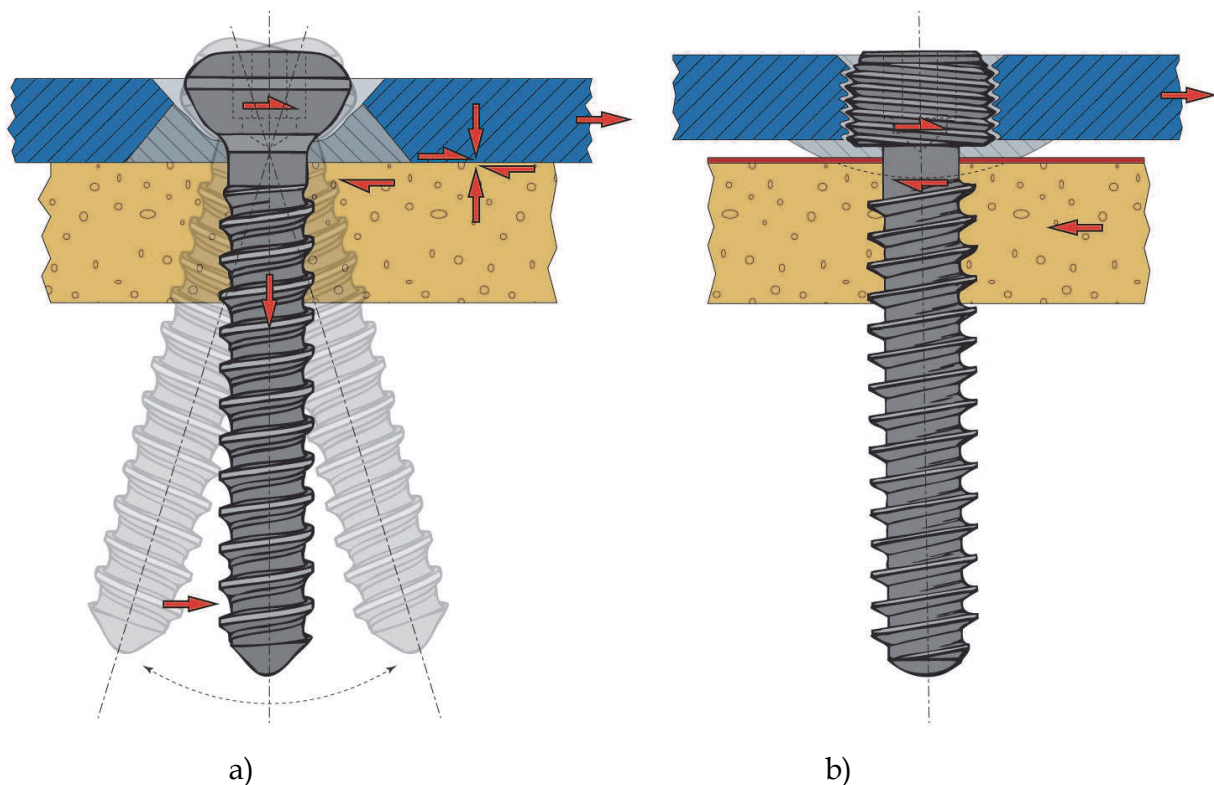


Fig. 3. a left - Longitudinal section through the screw hole of a conventional plate screw. The inclination of the screw is not locked. The screw is tightened with an axial traction of 2000 to 3000 N, the plate is compressed onto the bone producing friction which resists a tangential load of 1000 N (friction =  $0.4 \times 2500 = 1000$  N). Fig. 3. b right - Longitudinal section through the locked screw of an internal fixator. Because of the steep conical surfaces ("Morse cone") the screw locks upon application of minimal torque. Therefore absence of compression between the plate and bone allows either point contact or no contact thus enabling reduction of the contact damage to the blood supply. This type of force transmission does not depend on axial preloading of the screw (from Perren, 2002).

Polyaxial locking plates (POLYAX Locked Plating Systemt, DePuy, Warsaw, IN, USA), which allow screw angulation within a maximum 40-degree cone, are now available (Haydukewych et al., 2007). As the conical threaded head engages the bushing, the bushing expands, placing hoop stresses on the surrounding hole and effectively locking the screw (Haydukewych et al., 2007). Polyaxial locking plates offer more fixation versatility without an apparent increase in mechanical complications related to loss of reduction (Haydukewych et al., 2007). The non-contact bridging plate for distal femurs (NCB DF, Zimmer, Warsaw, IN, USA) combines conventional plating techniques with polyaxial screw placement and angular stability (Ehrhardt et al., 2008). Results of this combination technique show promise with regard to union and malunion rates in periprosthetic fractures in elderly and osteoporotic patients (Ehrhardt et al., 2008; El-Zayat et al., 2010). In a biomechanical study, the POLYAX supported smaller loads compared with the LISS and NCB while under axial loading (Otto et al., 2009). In addition, the mode of failure of the NCB plate, creating an intra-articular fracture propagating from the distal posterior screw hole, may be of some concern (Otto et al., 2009).

#### 4. Preoperative planning

Indirect reduction and closed fixation techniques are technically much more demanding than an open procedure; thus, accurate preoperative planning is needed to choose the appropriate implant size and length, shape of the plate and the number, position and order of insertion of the screws (Mast et al., 1989). The common issues related to the use of locked supracondylar plates for extraarticular distal femoral fractures are appropriate plate length, malalignment, and interference with total knee arthroplasty pegs (Horwitz & Kubiak, 2010). Plate length is important in patients with osteoporosis, both for fixation of the condylar fragment and to avoid creation of stress risers in the femoral shaft (Horwitz & Kubiak, 2010). Use of a long plate, while leaving some screw holes without screws, provides better fixation with less chance of failure at the proximal part of the diaphysis due to either pullout of the screws or a fracture at the tip of the plate (Sanders et al., 2002). The newer techniques

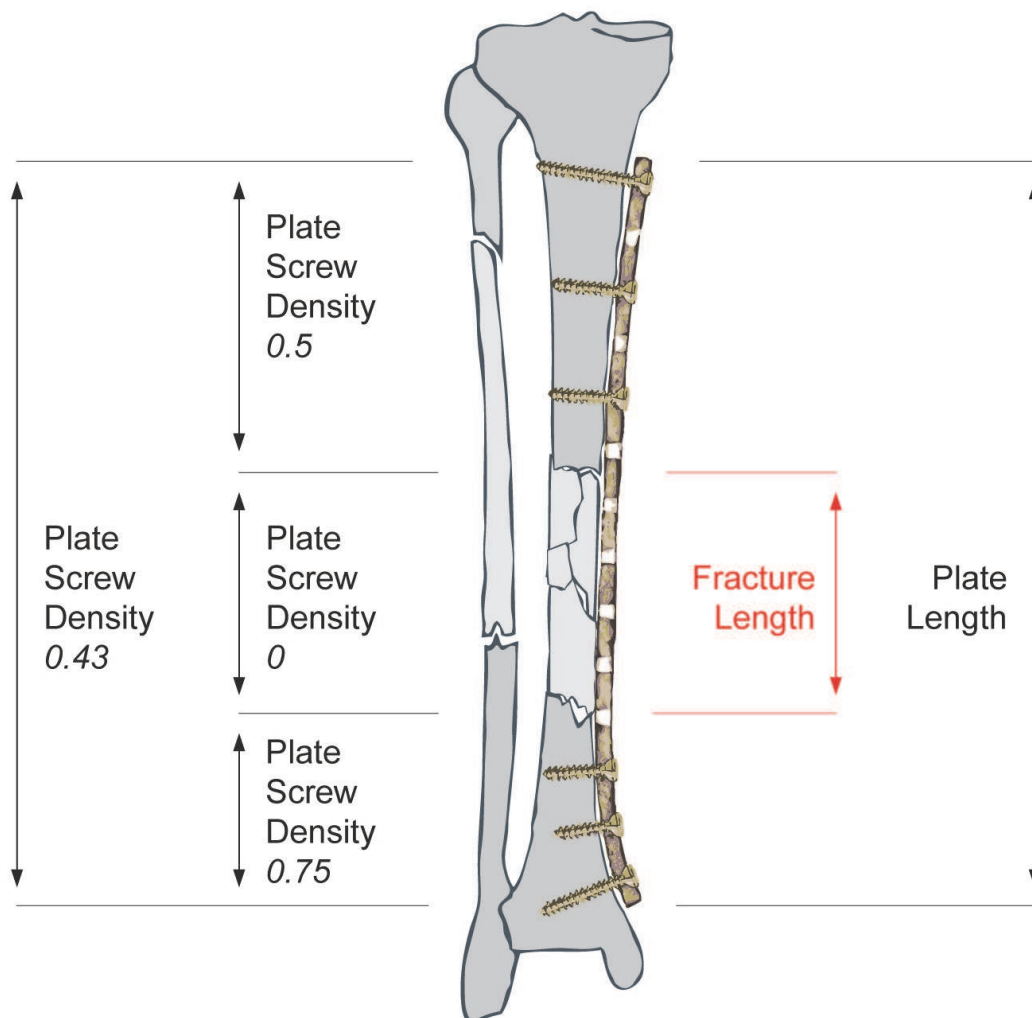


Fig. 4. The importance of plate-span ratio and plate-screw density in the bridge-plating technique. The schematic drawing shows a mechanically sound fixation of a comminuted diaphyseal fracture of the lower leg. The plate-span ratio is approximately 3, indicating that the plate is three times longer than the overall fracture area. The overall plate-screw density of the construct in this example is 0.43 & screws for a 14-hole plate (from Gautier and Sommer, 2003).

of indirect reduction and subcutaneous or submuscular implant insertion allow for increasing the plate length without additional soft tissue dissection (Gautier & Sommer, 2003). The plate length can be chosen according to the pure mechanical demands of the specific fracture that requires stabilisation (Gautier & Sommer, 2003). The working length has been shown to be the most important factor affecting axial stiffness and torsional rigidity (Stoffel et al., 2003). Increasing the working and plate lengths reduces considerably the von Mises stress in the LISS plate (Duda et al., 2002). In osteoporotic femurs, the use of self-tapping bicortical locking head screws with at least four or five screws in each fragment is recommended (Frigg & Wagner, 2006; Kregor et al., 2001).

As has been shown in total hip replacement, the LISS can be combined with periprosthetic screws, a locking attachment plate, or a cable system. The omission of one screw hole near the fracture site has been shown to significantly decrease, axial stiffness and torsional rigidity (by 64% and 36%, respectively (Stoffel et al., 2003). The number of screws has greater influence over shorter versus longer working lengths (Stoffel et al., 2003). Further more, more than three screws on either side of the fracture did little to increase axial stiffness; likewise, four screws did not increase torsional rigidity (Stoffel et al., 2003). In a biomechanical study locked and hybrid (combining of locked and unlocked) constructs demonstrated similar behaviour in osteoporotic bone; no differences between the locked and hybrid specimens were found at any cyclic interval (Gardner et al., 2006).

The plate-span ratio and the plate-screw density determine the ideal length of the internal fixator (Gautier & Sommer, 2003; Rozbruch et al., 1998). The plate-span ratio is the quotient of plate-length and fracture-length, while the plate-screw density is the quotient of the number of screws inserted into the plate and the number of plate holes (Rozbruch et al., 1998). The plate-span ratio should be higher than 2-3 in comminuted fractures and higher than 8-10 in simple fractures (Gautier & Sommer, 2003). The plate-screw density should be below 0.5-0.4 (Fig. 4, Gautier & Sommer, 2003).

## 5. Surgical technique

The length of the 95° condylar blade plate and the LISS, positioning, and length of the screws are selected using the Association for Osteosynthesis/ASIF templates (Synthes Corporation). Leg length and axial alignment of the contralateral extremity are determined as described by (Kolb et al., 2009). Surgical procedures involved the tool preOp plan, developed by Siemens, to support osteosynthesis planning with regard to the 95° condylar blade plate and the LISS (Less Invasive Stabilisation System) (Synthes, West Chester, Pennsylvania) (Koudela et al., 2010).

### 5.1 Indirect reduction technique with the condylar blade plate

The indirect reduction technique is performed with the 95° condylar blade plate (Kolb et al., 2009; Müller et al., 1979; Ostrum & Geel, 1995). The surgical technique includes a standard lateral approach to the distal femur with the patient in a supine position. Hyperextension of the distal femoral fragment is corrected with the knee flexed to 60° over a supracondylar towel bump. After opening the fascia lata, the vastus lateralis muscle is elevated from the linea aspera, and the perforating vessels are preserved when possible. The lateral and anterior aspects of the femur are exposed. The posterior and medial soft tissues are not violated. The blade of the 95° condylar blade plate is inserted along the track previously made by the seating chisel parallel to a k-wire that marks the joint line. The window of the seating chisel is in the middle third of the anterior half of the distal femur, 2.5 cm above the

prosthetic joint line and, if possible, anterior to the anchorage pegs of the prosthesis (Mast et al., 1989). Indirect reduction is obtained through manual traction or a compression-distraction device to obtain the appropriate axis, rotation and length of the femur. The plate is then attached to the proximal shaft with a Verbrugge clamp and fixed with screws. At least four divergent plate screws are used for proximal plate fixation. In three patients with severely osteoporotic bone, fractures were stabilised in combination with bone cement to enhance screw fixation. The screws are fully inserted into the cement while it is still soft after the plate is provisionally fixed to the femur, and the screws are tightened after the cement has set. Only one knee had a plate-bone interface failure after 4 weeks. Bone graft was required in only four patients with severely osteoporotic bone with comminution and in three in combination with bone cement.

### **5.1.1 Postoperative considerations**

Postoperatively, patients are allowed toe-touch weight bearing for 6-8 weeks, except for one patient who has an associated tibial fracture. Two patients are mobilised with a glider cane. After removal of the suction drains on the second postoperative day, continuous passive motion is initiated.

## **6. Minimally invasive technique with the LISS**

The standard anterolateral approach to the distal femur is performed on a radiolucent table with the patient in a supine position (Kolb et al., 2010). Hyperextension of the distal femoral fragment is corrected with the knee flexed over a supracondylar towel bump. Closed indirect reduction through manual traction with control of the axis, rotation and length, and temporary retention of the articular block on the shaft are attained. A 4 cm to 5 cm lateral incision is made over the distal femur. After sharp dissection through the skin and subcutaneous tissue, the iliotibial band is divided in line with its fibres. Atraumatic entry into the area between the vastus lateralis and the lateral femoral condyle (without visualising the metaphyseal part of the fracture) is performed. The perforating vessels are kept intact. The plate is placed slightly more distally than the recommended 1.0-1.5 cm, often directly adjacent to the femoral component to achieve maximal screw purchase (Kregor et al., 2001). The plate is used as an internal fixator and not as a reduction aid. The LISS was temporarily fixated using the aiming device with two 2.0 mm Kirschner wires (Fig. 5). At least four self-drilling monocortical locked screws are used for the articular block, and at least four self-tapping bicortical locked screws are used for the shaft. When interference occurs with an intercondylar box of the femoral component (in four patients), we use shorter self-tapping or periprosthetic screws. In two patients with interference from total hip replacements, periprosthetic locked screws were used in the proximal femoral fragment when the LISS overlapped a hip prosthesis. After a proximal screw pull-out due to malpositioning of the fixator, we obtain a true lateral view of the proximal shaft to ensure that the plate is centred on the bone in the lateral view before inserting the proximal screws, and we perform a mini-open approach over the proximal three holes of the fixator, facilitating the exact positioning of the fixator.

We require no intraoperative blood transfusion and no bone graft or soft tissue procedure.

### **6.1 Postoperative considerations**

Active physiotherapy and continuous passive motion are initiated on day 2 after removal of the drains. Patients are allowed to partially bear weight (up to 20 kg) for 6 to 8 weeks.



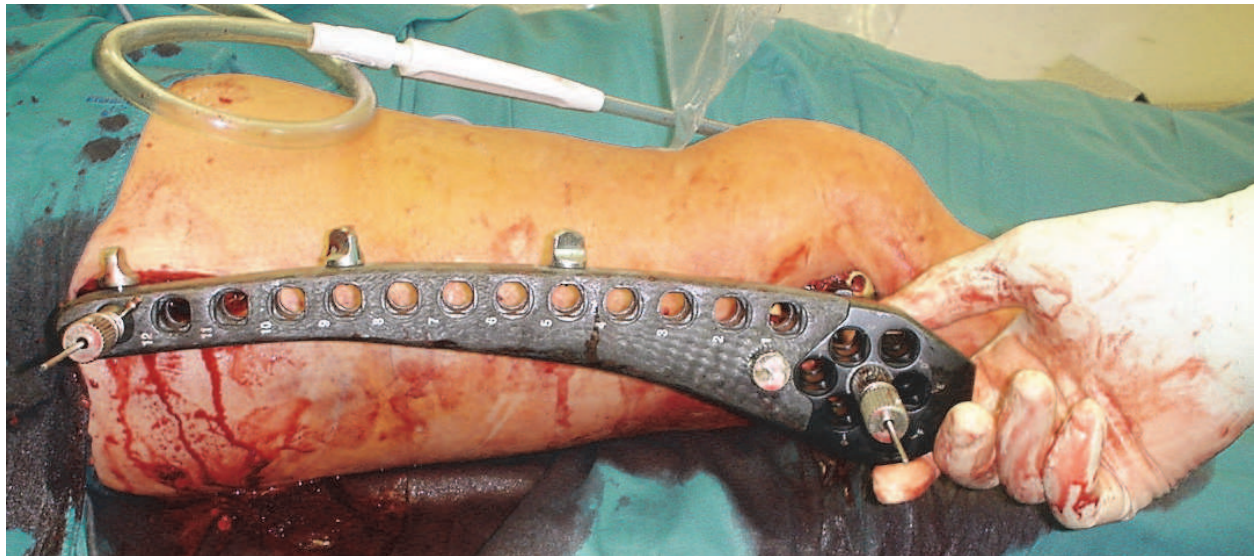


Fig. 5. Temporary fixation of the LISS with the aiming device with two 2.0 mm Kirschner wires.

## 7. Results and conclusions

The incidence of periprosthetic fractures is increasing as ageing populations throughout the world live longer (Kolb et al., 2010). Despite the increased risk of many of our patients all knees treated with the angled 95° condylar blade plate in indirect reduction technique healed without complications (Kolb et al., 2009). The angled 95° condylar plate in indirect reduction technique is still a good implant with good long-term results (Kolb et al., 2009). It works best in proximal fractures when there is minimal comminution of the distal fragment in the hands of a surgeon experienced with this device (Kolb et al., 2009). A minimally invasive, locked plating system permits stable fixation, early knee motion with good short- to mid-term results, and minimal complications (Kolb et al., 2010, Tables 5 and 6).

| Authors Year of publication | Patients (n) for Follow-up (n, %) | Internal Fixation CPO/MIPO Nailing   | Fracture Healing (weeks)        | Mean Follow-up (years) | Good/Excellent Results (%) Scoring System |
|-----------------------------|-----------------------------------|--|---------------------------------|------------------------|---|
| Sisto et al., 1985          | 3/3 (100%)                        | CPO (CP)   | 16 (12-20)                      | 1.1                    | 86 HSS knee score                         |
| Merkel et al., 1986         | 5/3 (60%)                         | CPO 4 (80%)<br>Screws 1 (20%)  | ND                              | 3.0                    | 76.3 KSS score                            |
| Cain et al., 1986           | 4/4                               | CPO 1 (25%) Rush pins 3 (75%)  | Non-union 2 (50%)               | 2.5                    | 25 Own rating system                      |
| Culp et al., 1987           | 30/22 (73%)                       | CPO (67%) Rush pins 2 (7%)   | Non-union 1 (3%)                | 3.7                    | ND  |
| Figgie et al., 1990         | 22/12                             | CPO 10 (45%) CP 5 (23%), Dual plating 2 (9%), CPB 2 (9%), Barr bolt and AO screws 1 (4%) | 32 (16-64)<br>Non-union 5 (23%) | ND                     | 64 University knee score                  |
| Healy et al., 1993          | 20                                | CPO (CP/DCS 7/7, 35%, CBP 6, 30%)  | 16 (6-40)                       | 2.2                    | 84 KSS score                              |

|                        |  |   |   |                       |                       |
|------------------------|--|---|---|-----------------------|-----------------------|
| Zehntner et al., 1993  | 7/6 (86%)  | CPO (CPB 6, 86%)  | 14 (12-16)  | 1.4                   | 50 Cain rating system |
| McLaren et al., 1994   | 7/7 (100%)                                       | Intramedullary supracondylar rod 7 (100%)                                 | 12  | 1.3                   | ND                    |
| Moran et al., 1996     | 15/15 (100%)                                     | CPO (CP 9 60%, CBP 3 20% (2 with double plating)                          | 12 (4-16), non-union 3 (20%)  | 2.5                   | KSS score             |
| Ochsner et al., 1999   | 6/5 (83%)  | CPO (Fork Plate) 6 (100%)   | 9   | ND                    | ND                    |
| Wick et al., 2001)     | 6/6 (100%)                                       | GSH nail 8 (100%)   | 12.4  | 1.4                   | 69 Freeman score      |
| Kregor et al., 2001    | 13   | LISS 13/13 (100%)   | ND  | ND                    | ND                    |
| Althausen et al., 2003 | 11   | LISS 5 (45%) Rush rod 4 (36%) CPO 2 (18%) Retrograde nail 1 (9%)          | ND  | ND                    | ND                    |
| Wick et al., 2004      | 18/18 (100%)                                     | DFN (44%), GSH nail 1 (6%), LISS 9 (50%)                                  |   | 2.5                   | ND                    |
| Gliatis et al., 2005   | 10/10 (100%)                                     | GSH 10 (100%)   | 12  | 2.9                   | 59 WOMAC score        |
| Ricci et al., 2006     | 24/22 (92%)                                      | LCP 24 (100%)   | 12 (8-20), Non-union 3 (13%)  | 1.0                   | ND                    |
| O'Toole et al., 2006   | 14/11 (79%)                                      | LISS 14 (100%)  | ND  | 1.0                   | 71 own score          |
| Fulkerson et al., 2007 | 18   | LISS 18   | 6.2 (3-19) months Delayed union 2 (11%) Non-union 3 (17%)   | 2.3                   | ND                    |
| Kolb et al., 2009      | 21/15 (71%)                                      | CP  | 14 (12-16)  | 9 (712)               | 77 KSS score          |
| Streubel et al., 2010  | 89/61 (69%)<br>Group A (n=28),<br>Group B (n=33) | Peri-Loc Distal Lateral Femur locking plate, Locking Condylar Plate, LISS | Delayed union 5 (18%), non-union 3 (11%) group A, delayed union 2 (6%), non-union 5 (15%) group B | Minimum follow-up 0.5 | ND                    |
| Kolb et al., 2010      | 23/19 (83%)                                      | LISS 23 (100%)  | 14 (9-21) Delayed union 2 (11%)   | 3.8 (2.2-5.6)         | 81 KSS score          |

Table 5. Results of surgically treated periprosthetic femur fractures above total knee arthroplasties

| Authors<br>Year           | Malalignment  | Bone graft (n,<br>% early/late) | Infection<br>(n, %) | Implant<br>Failure        | Secondary<br>Surgical<br>Procedure  |
|---------------------------|---|---------------------------------|---------------------|---------------------------|---|
| Sisto et al.,<br>1985     | Valgus 3/5° ½<br>(33/66%)   | 0                               | 0                   | 0                         | 0   |
| Merkel et<br>al., 1986    | 0   | 2 (40%), 1<br>(20%)             | 0                   | Intraoperative<br>1 Death | 1 Above knee<br>amputation  |
| Cain et al.,<br>1986      | Valgus 10° 2<br>(25%)   | 0                               | 0                   | 0                         | 0   |
| Culp et al.,<br>1987      | 3 (10%)   | 0                               | 2 (7%)              | 0                         | 2 Above knee<br>amputations   |
| Figgie et al.,<br>1990    | Varus 7°<br>5 (23%)   | 4 (18%)                         | 0                   | 5 (23%)                   | 4 Revision<br>osteosynthesis<br>with bone<br>grafting, 1<br>Revision TKA, |
| Healy et al.,<br>1993     | 0   | 15/3<br>(75%)/(15%)             | 0                   | 0                         | 3 Revision<br>osteosynthesis  |
| Zehntner et<br>al., 1993  | Valgus 5° (0-<br>10°)   | 2 (30%)                         | 0                   | 0                         | 0   |
| McLaren et<br>al., 1994   | 0   | 0                               | 0                   | 0                         | 1 Stress fracture<br>at the proximal<br>locking screw                     |
| Moran et al.,<br>1996     | Shortening 2<br>cm 3 (20%),<br>Valgus 17° 1<br>(7%), Varus 2°<br>1 (7%) | 6/2<br>(40%)/(13%)              | 0                   | 3 (20%)                   | 3 Revision<br>osteosynthesis,<br>2 with bone<br>graft                     |
| Ochsner et<br>al., 1999   | Varus 1 (17%)   | 0                               | 0                   | 0                         | 1 Valgus<br>osteotomy   |
| Wick et al.,<br>2001      | Valgus 10° 1<br>(17%),<br>Shortening 1<br>(17%)                         | 0                               | 0                   | 0                         | 0   |
| Althausen et<br>al., 2003 | Rush rod<br>valgus 13° 2<br>(50%), 10° 1<br>(25%),                      | 0                               | 0                   | 0                         | ND  |

|                        |   |                                 |                                |                                |  |
|------------------------|---|---------------------------------|--------------------------------|--------------------------------|--|
|                        | Retrograde Nail varus 3° 1 (100%), Shortening >2 cm 1 (25%), CPO varus 4° 1 (50%) |                                 |                                |                                |  |
| Kregor et al., 2001    | 0   | 0/1 (8%)                        | 0                              | 0                              | 1 Revision osteosynthesis  |
| Wick et al., 2004      | Valgus 18° retrograde   | 0                               | 1 (6%)                         | 1 (6%) retrograde nail         | 1 Revision osteosynthesis<br>1 Hematoma                                    |
| Gliatis et al., 2005   | Valgus 35° 1 (11%)  | 0                               | 0                              | 0                              | ND   |
| Ricci et al., 2006     | Varus 6° 1 (4%), Valgus 7°/9°/13° 1/1/1 (4%)                                      | 0                               | 2 (8%)                         | 4 (17%) proximal screw failure | 1 Above knee amputation<br>1 Debridement                                   |
| O'Toole et al., 2006   | 0   | 0                               | 0                              | 0                              | 0  |
| Fulkerson et al., 2007 | <5° Varus/Valgus angulation   | 0/1 (6%)                        | 1 (6%)                         | 1 (6%)                         | 1 Revision to DCS and Dall-Miles cables, 2 Revision TKA, 1 Excision plasty |
| Kolb et al., 2009      | Varus 5° 1 (5%)   | 4/1 (19%)/(5%)                  | 0                              | 1 (5%)                         | 1 Revision osteosynthesis with bone graft and bone cement, 2 Hematomas     |
| Streubel et al., 2010  |   | 2 (7%) Group A, 4 (12%) Group B | 1 (4%) Group A, 1 (3%) Group B | 0                              | 8 Debridments, 6 Revision osteosynthesis                                   |
| Kolb et al., 2010      | Varus 7 1 (5%)  | 0                               | 0                              | 1 (5%)                         | 1 Revision osteosynthesis  |

Table 6. Complications of surgically treated periprosthetic femur fractures above total knee arthroplasties

## 8. References

- Aaron, R.K.; & Scott, R. (1987) Supracondylar fracture of the femur after total knee arthroplasty, *Clin Orthop Relat Res*, Vol.219, (June 1987), pp.136-139.
- Althausen, P.L.; Lee, M.A.; Finkemeier, C.G.; Meehan, J.P.; & Rodrigo, J.J. (2003). Operative stabilization of supracondylar femur fractures above total knee arthroplasty: a comparison of four treatment methods, *J Arthroplasty*, Vol.18, No.7, (October 2003), pp.834-839.
- Arens, S.; Eijer, H.; Schlegel, U.; Printzen, G.; Perren, S.M.; & Hansis, M. (1999). Influence of the design for fixation implants on local infection: experimental study of dynamic compression plates versus contact fixateurs in rabbits, *J Orthop Trauma*, Vol.13, No.7, (September-October 1999), pp.470-476.
- Ayers, D.C. (1997). Supracondylar fracture of the distal femur proximal to a total knee replacement, *Instruct Course Lect*, Vol.46, pp.197-203.
- Babst, R.; Hehli, M.; & Regazzoni, P. (2001). [LISS tractor. Combination of the "less invasive stabilization system" (LISS) with the AO distractor for the distal femur and proximal tibial fractures], *Unfallchirurg*, Vol.104, No.6, (June 2001), pp.530-535. German.
- Beris AE, Lykissas MG, Sioros V, Mavrodonitis AN, Korompilias AV. (2010). Femoral periprosthetic fracture in osteoporotic bone after total knee replacement: treatment with external Ilizarov fixation, *J Arthroplasty*, Vol.25, No.7, (October 2010), pp.1168.e9-12.
- Berry, D.J. (1999) Epidemiology: hip and knee, *Orthop Clin North Am*, Vol.30, No.2, (April 1999), pp.183-190. Review.
- Böstman, O.M. (1983). Rotational refracture of the shaft of the adult tibia, *Injury*, Vol.15, No.2, (September 1983), pp.93-98.
- Bogoch, E.; Hastings, D.; Gross, A.; & Gschwend, N. (1988). Supracondylar fractures of the femur adjacent to resurfacing and MacIntosh arthroplasties of the knee in patients with rheumatoid arthritis, *Clin Orthop Relat Res*, (April 1988), Vol.229, pp.213-220.
- Brunner, C.; & Weber, B.G. (1982). *Special Techniques in Internal Fixation*, Springer, Berlin, Germany.
- Cain, P.R.; Rubash, H.E.; Wissinger, H.A.; & McClain, E.J. (1986). Periprosthetic femoral fractures following total knee arthroplasty, *Clin Orthop Relat Res*, Vol.208, (July 1986), pp.205-214.
- Chen, F.; Mont, M.A.; & Bachner, R.S. (1994). Management of ipsilateral supracondylar femur fractures following total knee arthroplasty, *J Arthroplasty*, Vol.9, No.5, (October 1994), pp.521-526.
- Chettiar, K.; Jackson, M.P.; Brewin, J.; Dass, D.; & Butler-Manuel, P.A. (2009). Supracondylar periprosthetic femoral fractures following total knee arthroplasty: treatment with a retrograde intramedullary nail, *Int Orthop*, Vol.33, No.4, (August 2009), pp.981-985.
- Claes, L.; Heitemeyer, U.; Krischak, G.; Braun, H.; & Hierholzer, G. (1999). Fixation technique influences osteogenesis of comminuted fractures, *Clin Orthop Relat Res*, Vol.365, (August 1999), pp.221-229.
- Cordeiro, E.N.; Costa, R.C.; Carazzato, J.G.; & Silva Jdos, S. (1990). Periprosthetic fractures in patients with total knee arthroplasties, *Clin Orthop Relat Res*, Vol.252, (March 1990), pp.182-189.

- Culp, R.W.; Schmidt, R.G.; Hanks, G.; Mak, A.; Esterhai, J.L.; & Heppenstall, R.B. (1987). Supracondylar fracture of the femur following prosthetic knee arthroplasty. *Clin Orthop Relat Res*, Vol.222, (September 1987), pp.212-222.
- Dennis, D.A. (1998). Periprosthetic fractures following total knee arthroplasty: the good, bad, & ugly, *Orthopedics*, Vol.21, No.9, (September, 1998), pp.1048-1050. Review.
- Dennis D.A. Periprosthetic fractures following total knee arthroplasty. (2001). *J Bone Joint Surg Am*, Vol.83, pp.120-130.
- Diehl, P.; Burgkart, R.; Klier, T.; Glowalla, C.; & Gollwitzer, H. (2006) [Periprosthetic fractures after total knee arthroplasty, *Orthopäde*, Vol.35, No.9, (September 2006), pp.972-974. Review. German.
- DiGioia, A.M.<sup>3rd</sup>; & Rubash, H.E. (1991) Periprosthetic fractures of the femur after total knee arthroplasty. A literature review and treatment algorithm, *Clin Orthop Relat Res*, Vol.271, (October 1991), pp.135-142.
- Duda, G.N.; Mandruzzato, F.; Heller, M.; Kassi, J.P.; Khodadadyan, C.; & Hass, N.P. (2002). Mechanical conditions in the internal stabilization of proximal tibial defects, *Clin Biomech (Bristol, Avon)*, Vol.17, No.1, (January 2002), pp.64-72.
- Egol, K.A.; Kubiak, E.N.; Fulkerson, E.; Kummer, F.J.; & Koval, K.J. (2004). Biomechanics of locked plates and screws, *J Orthop Trauma*, Vol.18, No.8, (September 2004), pp.488-493.
- Ehinger, M.; Adam, P.; Abane, L.; Rahme, M.; Moor, B.K.; Arlettaz, Y.; & Bonnormet, F. (2011). Treatment of periprosthetic femoral fractures of the knee, *Knee Surg Sports Traumatol Arthrosc*, Mar 23. [Epub ahead of print].
- Erhardt, J.B.; Grob, K.; Roderer, G.; Hoffmann, A.; Forster, T.N.; & Kuster, M.S. (2008). Treatment of periprosthetic femur fractures with the non-contact bridging plate: a new angular stable implant, *Arch Orthop Trauma Surg*, Vol.128, No.4, (April 2008), pp.409-416.
- Erhardt JB, Kuster MS. (2010). [Periprosthetic fractures of the knee joint]. *Orthopäde* 2010;39:97-108.
- El-Zayat, B.F.; Zettl, R.; Efe, T.; Krüger, A.; Eisenberg, F.; & Ruchholtz, S. (2010) [Minimally invasive treatment of geriatric and osteoporotic femur fractures with polyaxial locking implants (NCB-DF).], *Unfallchirurg*, (November 18, 2010), [Epub ahead of print].
- Farouk, O.; Krettek, C.; Miclau, T.; Schandelmaier, P.; & Tscherne, H. (1998). Effects of percutaneous and conventional plating techniques on the blood supply to the femur, *Arch Orthop Trauma Surg*, Vol.117, No.8, pp.438-441.
- Figgie, M.P.; Goldberg, V.M.; Figgie, H.E. <sup>3rd</sup>; & Sobel, M. (1990) The results of treatment of supracondylar fracture above total knee arthroplasty, *J Arthroplasty*, Vol.5, No.3, (September 1990), pp.267-276.
- Finsen, V.; & Benum, P. (1986). Refracture of the hip rare after removal of fixation device, *Acta Orthop Scand*, Vol.57, No.5, (October 1986), pp.434-435.
- Frigg, R.; Appenzeller, A.; Christensen, R.; Frenk, A.; Gilbert, S.; & Schavan, R. (2001). The development of the distal femur Less Invasive Stabilization System (LISS), *Injury*, Vol.32, Suppl 3, (December 2001), pp.SC24-31. Review.
- Frigg, R. (2003). Development of the Locking Compression Plate, *Injury*, Vo.34, Suppl 2, pp.B6-10. Review.

- Fulkerson, E.; Tejwani, N.; Stuchin, S.; & Egol, K. (2007). Management of periprosthetic femur fractures with a first generation locking plate, *Injury*, Vol.38, No.8, (August 2007), pp.965-972.
- Ganz, R.; Mast, J.; Weber, B.; & Perren, S.M. (1991). Clinical aspects of „bio-logical“ plating, *Injury*, Vol.22, pp.4-5.
- Gardner, M.J.; Helfet, D.L.; & Lorich D.G. (2004). Has locked plating completely replaced conventional plating, *Am J Orthop*, Vol.33, No. 9, (September 2004), pp.439-446. Review.
- Gardner, M.J.; Griffith, M.H.; Demetrakopoulos, D.; Brophy, R.H.; Grose, A.; Helfet, D.L.; Lorich, D.G. (2006). Hybrid locked plating of osteoporotic fractures of the humerus, *J Bone Joint Surg Am*, Vol.88, No.9, (September 2006), pp.1962-1967.
- Gautier, E.; & Sommer, C. (2003) Guidelines for the clinical application of the LCP, *Injury*, Vol.34, Suppl 2, pp.B63-76. Review.
- Gautier, E.; & Jakob, R.P. (2004). Biomechanics of osteosynthesis by screwed plates. In *Biomechanics and biomaterials in orthopedics*, D.G. Poitout (Ed.), pp.330-350, Springer, New York, USA.
- Gerber, C.; Mast, J.; & Ganz, R. (1990). Biological internal fixation of fractures. *Arch Orthop Trauma Surg*, Vol.109, No.6, pp.295-303.
- Gliatis, J.; Megas, P.; Panagiotopoulos, E.; & Lambiris, E. (2005). Midterm results of treatment with a retrograde nail for supracondylar periprosthetic fractures of the femur following total knee arthroplasty, *J Orthop Trauma*, Vol.19, No.3, (March 2005), pp.164-170.
- Grützner, P.; Winkler, H.; & Wentzensen, A. (1997). [New aspects and developments of plate osteosynthesis. Point Contact Fixateur-PC Fix-Indication-technology-experiences, *OPJ*, Vol.3, pp.332-338.
- Haddad, F.S.; Masri, B.A.; Garbuz, D.S.; & Duncan, C.P. (1999). The prevention of periprosthetic fractures in total hip and knee arthroplasty, *Orthop Clin North Am*, Vol.30, No.2, (April 1999), pp.191-207. Review.
- Haidukewych, G.; Sems, S.A.; Huebner, D.; Horwitz, D.; & Levy, B. (2007). Results of polyaxial locked-plate fixation of periarticular fractures of the knee, *J Bone Joint Surg Am*, Vol.89, No.3, (March 2007), pp.614-620.
- Harlow, M.L.; & Hofmann, A.A. (1994). Periprosthetic fractures. In *The knee*, W.N. Scott (Ed.), pp.1405-1417, CV Mosby, St. Louis, USA.
- Healy, W.L.; Siliski, J.M.; & Incavo, S.J. (1993). Operative treatment of distal femoral fractures proximal to total knee replacements, *J Bone Joint Surg Am*, Vol.75, No.1, pp.27-34.
- Henry, S.L. (1995). Management of supracondylar fractures proximal to total knee arthroplasty with the GSH supracondylar nail, *Contemp Orthop*, Vol.31, No.4, (October 1995), pp.231-238.
- Herrera, D.A.; Kregor, P.J.; Cole, P.A.; Levy, B.A.; Jönsson, A.; & Zlowodzki, M. (2008). Treatment of acute distal femur fractures above total knee arthroplasty: a systematic review of 415 cases (1981-2006), *Acta Orthop*, Vol.79, No.1, (February 2006), pp.22-27.
- Hidaka, S.; & Gustilo, R.B. (1984). Refracture of bones of the forearm after plate removal, *J Bone Joint Surg Am*, Vol.66, No.8, (October 1984), pp.1241-1243.

- Hirsh, D.M.; Bhalla, S.; & Roffman, M. (1981) Supracondylar fracture of the femur following total knee replacement. Report of four cases, *J Bone Joint Surg Am*, Vol.63, No.1, (January 1981), pp.162-163.
- Horwitz, D.S. & Kubiak, E.N. (2010). Surgical treatment of osteoporotic fractures about the knee, *Instr Course Lect*, Vol.59, pp.511-523. Review.
- Johnston, A.T.; Tsiridis, E.; Eyres, K.S.; & Toms, A.D. (2011). Periprosthetic fractures in the distal femur following total knee replacement: A review and guide to management, *Knee*, Jul 7. [Epub ahead of print].
- Kenwright, J.; & Goodship, A.E. (1989). Controlled mechanical stimulation in the treatment of tibial fractures, *Clin Orthop Relat Res*, Vol.241, (April 1989), pp.36-47.
- Kim, K.I.; Egol, K.A.; Hozak, W.J.; & Parvizi J. (2006). Periprosthetic fractures after total knee arthroplasties, *Clin Orthop Relat Res*, Vol.446, (May 2006), pp.167-175.
- Kessler, S.B.; Deiler, S.; Schiffl.Deiler, M.; Uthoff, H.K.; & Schweiberer, L. (1992). Refractures: a consequence of impaired local bone viability, *Arch Orthop Trauma Surg*, Vol.111, No.2, pp.96-101.
- Kolb, K.; Koller, H.; Lorenz, I.; Holz, U.; Marx, F.; Grützner, P.; & Kolb, W. (2009). Operative treatment of distal femoral fractures above total knee arthroplasty with the indirect reduction technique: a long-term follow-up study, *Injury*, Vol.40, No.4, (April 2009), pp.433-439.
- Kolb, K.; Grützner, P.; Koller, H.; Windisch, C.; Marx, F.; & Kolb, W. (2009). The condylar plate for treatment of distal femoral fractures: a long-term follow-up study, *Injury*, Vol.40, No.4, (April 2009), pp.440-448.
- Kolb, W.; Guhlmann, H.; Friedel, R.; & Nestmann, H. (2003). [Fixation of periprosthetic femur fractures with the less invasive stabilization system (LISS)-a new minimally invasive treatment with locked fixed-angle screws], *Zentralbl Chir*, Vol.218, No.1, (January 2003), pp.53-59. German.
- Kolb, W.; Guhlmann, H.; Windisch, C.; Marx, F.; kolb, K.; & Koller, H. (2008). Fixation of distal femoral fractures with the Less Invasive Stabilization Systems: a minimally invasive treatment with locked fixed-angled screws, *J Trauma*, Vol.65, No.6, (December 2008), pp.1425-1434.
- Kolb, W.; Guhlmann, H.; Windisch, C.; Marx, F.; Koller, H.; & Kolb, K. (2010). Fixation of periprosthetic femur fracture above total knee arthroplasty with the less invasive stabilization system: a midterm follow-up study, *J Trauma*, Vol.69, No.3, (September 2010), pp.670-676.
- Kolodziej, P.; Lee, F.S.; Patel, A.; Kassab, S.S.; Shen, K.L.; Yang, K.H.; & Mast, J.W. (1998). Biomechanical evaluation of the schuhli nut, *Clin Orthop Relat Res*, Vol.347, (February 1998), pp.79-85.
- Korner, J.; Lill, H.; Müller, L.P.; Rommens, P.M.; Schneider, E. & Linke, B. (2003). The LCP-concept in the operative treatment of distal humerus fractures – biological, biomechanical and surgical aspects, *Injury*, Vol.34, Suppl 2, (November 2003), pp.B20-30. Review.
- Koudela, K. Jr.; Koudelová, J.; Koudela, K. Sr.; Kunesova. M.; Kren, J.; & Pokorny, J. (2010). [Radiographic measurements in total knee arthroplasty and their role in clinical practice], *Acta Chir Orthop Traumatol Cech*, Vol.77, Vol.4, (August 2010), pp.304-311.



- Koval, K.J.; Hoehl, J.J.; Kummer, F.J.; & Simon, J.A. (1997). Distal femoral fixation: a biomechanical comparison of the standard condylar buttress plate, a locked buttress plate, and the 95-degree blade plate, *J Orthop Trauma*, Vol.11, No.7, (October 1997), pp.521-524.
- Kregor, P.J.; Hughes, J.L.; & Cole, P.A. (2001). Fixation of distal femoral fractures above total knee arthroplasty utilizing the Less Invasive Stabilizations System (L.I.S.S.), *Injury*, Vol.32, Suppl 3, pp.SC64-75:
- Krettek, C.; Schandelmaier, P.; Miclau, T.; & Tscherne, H. (1997). Minimally invasive percutaneous plate osteosynthesis (MIPPO) using DCS in proximal and distal femoral fractures, *Injury*, Vol.28, (Suppl 1), pp.S-A20-30.
- Krettek, C.; Müller, M.; & Miclau, T. (2001). Evolution of minimally invasive plate osteosynthesis (MIPO) in the femur, *Injury*, Vol.32, Suppl 3, pp.S-C14-S-C23.
- Kubiak, E.N.; Fulkerson, E.; Strauss, E.; & Egol, K.A. (2006). The evolution of locked plates, *J Bone Joint Surg Am*, Vol.88, Suppl 4, (December 2006), pp.189-200. Review.
- Kumar, A.; & Chambers, I. (2008). Management of periprosthetic fracture above total knee arthroplasty using intramedullary fibular allograft and plate fixation, *J Arthroplasty*, Vol.23, No.4, (June 2008), pp.554-558.
- Lesh, M.L.; Schneider, D.J.; Deol, G.; Davis, B.; Jacobs, C.R.; & Pellegrini, V.D. Jr. (2000). The consequence of anterior femoral notching in total knee arthroplasty. A biomechanical study, *J Bone Joint Surg Am*, Vol.82, No.8, (August 2000), pp.1096-1101.
- Leunig, M.; Hertel, R.; Siebenrock, K.A.; Ballmer, F.T.; Mast, J.W.; & Ganz, R. (2000). The evolution of indirect reduction techniques for the treatment of fractures, *Clin Orthop Relat Res*, Vol.375; (June 2000), pp.7-14. Review.
- Mamczak, C.N.; Gardner, M.J.; Bolhofner, B.; Borelli, J. Jr.; Streubel, P.N.; & Ricci, W.M. (2010). Interprosthetic femoral fractures, *J Orthop Trauma*, Vol.24, No.12, (December 2010), pp.740-744.
- Maniar, R.N.; Umlas, M.E.; Rodriguez, J.A.; & Ranawat, C.S. (1996). Supracondylar femoral fracture above a PFC posterior cruciate-substituting total knee arthroplasty treated with supracondylar nailing. A unique technical problem, *J Arthroplasty*, Vol.11, No.5, (August 1996), pp.637-639.
- Marti, A.; Fankhauser, C.; Frenk, A.; Cordey, J.; & Gasser, B. (2001). Biomechanical evaluation of the less invasive stabilization system for the internal fixation of distal femur fractures, *J Orthop Trauma*, Vol.15, No.7, (September-October 2001), pp.482-487.
- Mast, J.; Jacob, R.; & Ganz, R. (1989). *Planning and reduction techniques in fracture surgery*, Springer, New York, USA. .
- [http://www.medical.siemens.com/webapp/wcs/stores/servlet/ProductDisplay~q\\_catalogId~e\\_-3~a\\_catTree~e\\_100010,1007665,12760,1032265~a\\_langId~e\\_-3~a\\_productId~e\\_202741~a\\_storeId~e\\_10001.htm](http://www.medical.siemens.com/webapp/wcs/stores/servlet/ProductDisplay~q_catalogId~e_-3~a_catTree~e_100010,1007665,12760,1032265~a_langId~e_-3~a_productId~e_202741~a_storeId~e_10001.htm)
- McGraw, P.; & Kumar, A. (2010). Periprosthetic fractures of the femur after total knee arthroplasty, *J Orthop Traumatol*, Vol.11, No.3, (September 2010), pp.135-141. Review.
- McLaren, A.C.; Dupont, J.A.; & Schroeber, D.C. (1994). Open reduction internal fixation of supracondylar fractures above total knee arthroplasties using the intramedullary rod, *Clin Orthop Relat Res*, Vol.302, (May 1994), pp.194-198.

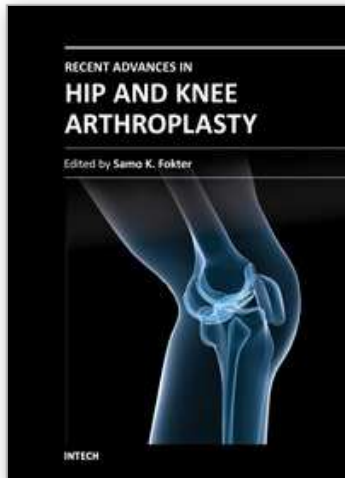
- Merkel, K.D.; & Johnson E.W.jr. (1986). Supracondylar fracture of the femur after total knee arthroplasty, *J Bone Joint Surg Am*, Vol.68, No.1, (January 1986), pp.29-43.
- Stedtfeld, H.W.; Mittlmeier, T.; Landgraf, P.; & Ewert, A. (2004). The logic and clinical applications of blocking screws, *J Bone Joint Surg Am*, Vol.86, Suppl 2, pp.17-25.
- Mittlmeier, T.; Stöckle, U.; Perka, C.; & Schaser, K.D. (2005). [Periprosthetic fractures after total knee joint arthroplasty, *Unfallchirurg*, Vol.108, No.6, (June 2005), pp.481-495; quiz 496. Review. German.
- Mittlmeier, T.; & Beck, M. (2005). [Retrograde medullary locking in periprosthetic distal femoral fracture after condylar knee joint replacement], *Unfallchirurg*, Vol.108, No.6, (June 2005), pp.497-501. Review. German.
- Moran, M.C.; Brick, G.W.; Sledge, C.B.; Dysart, S.H.; & Chien, E.P. (1996). Supracondylar femoral fracture following total knee arthroplasty, *Clin Orthop Relat Res*, Vol.324, (March 1996), pp.196-209.
- Mulier, T.; Seligson, D.; Sioen, W.; van den Bergh, J.; & Reynaert, P. (1997). Operative treatment of humeral shaft fractures, *Acta Orthop Belg*, Vol.63, No.3, pp.170-177.
- Müller, M.E.; Allgöwer, M.; & Willenegger, H. (1970). *Manual of Internal Fixation*, first ed., Springer, New York, USA.
- Müller, M.E.; Allgöwer, M.; Schneider, R.; & Willenegger, H. (1979). *Manual of Internal Fixation*, 2<sup>nd</sup> ed., Springer, New York, USA.
- Murrell, G.A.; & Nunley, J.A. (1995). Interlocked supracondylar intramedullary nails for supracondylar fractures after total knee arthroplasty. A new treatment method, *J Arthroplasty*, Vol.10, No.1, (February 1995), pp.37-42.
- Nauth, A.; Ristevski, B.; Begué, T.; & Schemitsch, E.H. (2011). Periprosthetic distal femur fractures: current concepts, *J Orthop Trauma*, Vol.25, Suppl 1, (June 2011), pp.S82-85.
- Noorda, R.J.; & Wuisman, P.I. (2002). Mennen plate fixation for the treatment of periprosthetic femoral fracture: a multicenter study of thirty-six fractures, *J Bone Joint Surg Am*, Vol.84, No.12, (December 2002), pp.2211-2215.
- Ochsner, P.E.; & Pfister, A. (1999). Use of the fork plate for internal fixation of periprosthetic fractures and osteotomies in connection with total knee replacement, *Orthopedics*, Vol.22, No.5, (May 1999), pp.517-521.
- Ostrum, R.F.; & Geel, C. (1995). Indirect reduction and internal fixation of supracondylar femur fractures without bone graft, *J Orthop Trauma*, Vol.9, No.4, pp.278-284.
- O'Toole, R.V.; Gobeze, R.; Hwang, R.; Chandler, A.R.; Smith, R.M.; Estok, D.M.2<sup>nd</sup>; & Vrahas, M.S. (2006). Low complication rate of LISS for femur fractures adjacent to stable hip or knee arthroplasty, *Clin Orthop Relat Res*, Vol.450, (September 2006), pp.203-210.
- Otto, R.J.; Moed, B.R.; & Bledsoe, J.G. (2009). Biomechanical comparison of polyaxial locking plates and a fixed-angle locking plate for internal fixation of distal femurs, *J Orthop Trauma*, Vol.23, No.9, (October 2009), pp.645-652.
- Perren, S.M.; Coredy, J.; Rahn, B.A.; Gautier, E.; & Schneider, E. (1988). Early temporary porosis of bone induced by internal fixation implants. A reaction to necrosis, not to stress protection? *Clin Orthop Relat Res*, Vol.232, (July 1988), pp.139-151. Review.
- Perren, S.M. (2002). Evolution of the internal fixation of long bone fractures, *J Bone Joint Surg Br*, Vol.84, No.8, (November 2002), pp.1093-1110. Review.

- Perren, S.M. (2003) Backgrounds of the technology of internal fixators, *Injury*, Vol.34, Suppl 2, pp.B1-3.
- Platzer, P.; Schuster, R.; Aldrian, S.; Prosquill, S.; Krumboeck, A.; Zehetgruber, I.; Kovar, F.; Schwarmeis, K.; & Vecsei, V. (2010). Management and outcome of periprosthetic fractures after total knee arthroplasty, *J Trauma*, Vol.68, No.6, (June 2010), pp.1464-1470.
- Ramotowski, W.; & Granowski, R. (1991). Zespol. An original method of stable osteosynthesis, *Clin Orthop Relat Res*, Vol.272, (November 1991), pp.67-75.
- Rhineland, F.W. (1972). Circulation in bone. In: Bourne GH, editor. 2<sup>nd</sup> ed., *The biochemistry and physiology of bone*, vol 2, 2<sup>nd</sup> ed. New York: Academic Press, p. 1-77.
- Ricci, W.M.; Bolhofner, B.R.; Loftus, T.; Cox, C.; Mitchell, S.; & Borelli, J. Jr. (2005). Indirect reduction and plate fixation, without grafting, for periprosthetic femoral shaft fractures about a stable intramedullary implant, *J Bone Joint Surg Am*, Vol.87, No.10, (October 2005), pp.2240-2245.
- Ricci, W.M. ; Loftus, T.; Cox, C.; & Borelli, J. (2006). Locked plates with minimally invasive insertion techniques for the treatment of periprosthetic supracondylar femur fractures above total knee arthroplasty *J Orthop Trauma*, Vol.20, No.3, (March 2006), pp.190-196.
- Ricci, W.M.; Bolnhofner, B.R.; Loftus, T.; Cox, C.; Mitchell, S.; & Borrelli, J. Jr. (2006). Indirect reduction and plate fixation without grafting, for periprosthetic femoral shaft fractures about a stable intramedullary implant. Surgical technique, *J Bone Joint Surg Am*, Vol.88, Suppl 1 Pt2, (September 2006), pp.275-282.
- Riemer, B.L.; Butterfield, S.L.; Burke, C.J 3rd.; & Mathews, D. (1992). Immediate plate fixation of highly comminuted femoral diaphyseal fractures in blunt polytrauma patients, *Orthopedics*, Vol.15, No.8, (August 1992), pp.907-916.
- Ritter, M.A.; Faris, P.M.; & Keating, E.M. (1988) Anterior femoral notching and ipsilateral supracondylar femur fracture in total knee arthroplasty, *J Arthroplasty*, Vol.3, No.2, pp.185-187.
- Ritter, M.A.; Thong, A.E.; Keating, E.M.; Faris, P.M.; Meding, J.B.; Berend, M.E.; Pierson, J.L.; & Davis, K.E. (2005). The effect of femoral notching during total knee arthroplasty on the prevalence of postoperative femoral fractures and on clinical outcome, *J Bone Joint Surg Am*, Vol.87, No.11, (November 2005), pp.2411-2414.
- Rolston, L.R.; Christ, D.J.; Halpern, A.; O'Connor, P.L.; Ryan, T.G.; & Uggen, W.M. (1995). Treatment of supracondylar fractures of the femur proximal to a total knee arthroplasty, *J Bone Joint Surg Am*, Vol.77, No.6, (June 1995), pp.924-931.
- Rorabeck CH, Taylor JW. Periprosthetic fractures of the femur complicating total knee arthroplasty. *Orthop Clin North Am* 1999;30:265-277.
- Roscoe, M.W.; Goodman, S.B.; & Schatzker, J. (1989) Supracondylar fracture of the femur after GUERPAR total knee arthroplasty, *Clin Orthop Relat Res*, Vol.241, (April 1989), pp.221-223.
- Rozbruch, S.R.; Müller, U.; Gautier, E.; & Ganz, R. (1998). The evolution of femoral shaft plating technique, *Clin Orthop Relat Res*, Vol.354, (September 1998), pp.195-208.
- Rüedi, T.P.; Sommer, C.; & Leutenegger, A. (1998). New techniques in indirect reduction of long bone fractures, *Clin Orthop Relat Res*, Vol.347, (February 1998), pp.27-34. Review.

- Salas, C.; Mercer, D.; DeCoster, T.A.; & Reda Taha, M.M. (2011) Experimental and probahilistic analysis of distal femoral periprosthetic fracture: a comparison of locking plate and intramedullary nail fixation. Part A: experimental investigation, *Comput Methods Biomech Biomed Engin*, Vol.12, No.2, (February 2011), pp.157-164.
- Sanders, R.; Haidukewych, G.J.; Milne, T.; Dennis, J.; & Latta, L.L. (2002). Minimal versus maximal plate fixation techniques of the ulna: the biomechanical effect of number of screws and plate length, *J Orthop Trauma*, Vol.16, No.3, (March 2002), pp.166-171.
- Shawen, S.B.; Belmont, P.J.Jr.; Klemme, W.R.; Topoleski, L.D.; Xenos, J.S.; & Orchowski, J.R. (2003) Osteoporosis and anterior femoral notching in periprosthetic supracondylar femoral fractures: a biomechanical analysis, *J Bone Joint Surg Am*, Vol.85, No.1, (January 2003), pp.115-121.
- Short, W.H.; Hootnick, D.R.; & Murray, D.G. (1981). Ipsilateral supracondylar femur fractures following knee arthroplasty, *Clin Orthop Relat Res*, Vol.158, (July-August 1981), pp.111-116.
- Sisto, D.J.; Lachiewicz, P.F.; & Insall, J.N. (1985). Treatment of supracondylar fractures following prosthetic arthroplasty of the knee, *Clin Orthop Relat Res*, Vol.196, (June 1985), pp.265-272.
- Smith, W.J.; Martin, S.L.; & Mabrey, J.D. (1996). Use of supracondylar nail for treatment of a supracondylar fracture of the femur following total knee arthroplasty, *J Arthroplasty*, Vol.11, No.2, (February 1996), pp.210-213.
- Streubel, P.N.; Gardner, M.J.; Morshed, S.; Collinge, C.A.; Gallagher, B.; & Ricci, W.M. (2010). Are extreme distal periprosthetic supracondylar fractures of the femur too distal to fix using a lateral locked plate? *J Bone Joint Surg Br*, Vol.92, Vol.4, (April 2010), pp.527-534.
- Stoffel, K.; Dieter, U.; Stachowiak, G.; Gächter, A.; & Kuster, M.S. (2003) Biomechanical testing of the LCP – how can stability in locked internal fixators be controlled? *Injury*, Vol.34, Suppl 2, pp.B11-19.
- Su, E.T.; Dewal, H.; & Di Cesare, P.E. (2004) Periprosthetic femoral fractures above total knee replacements, *Am J Acad Orthop Surg*, Vol.12, No.1, (January-February 2004), pp.12-20. Review.
- Tani, Y.; Inoue, K.; Kanecko, H.; Nishioka, J.; & Hukuda, S. (1998). Intramedullary fibular graft for supracondylar fracture of the femur following total knee arthroplasty, *Arch Orthop Trauma Surg*, Vol.117, No.1-2, pp.103-104.
- Tepic, S.; Remiger, A.R.; Morikawa, K.; Predieri, M.; & Perren, S.M. (1997). Strength recovery in fractured sheep tibia treated with a plate or an internal fixator: an experimental study with a two-year follow-up, *J Orthop Trauma*, Vol.11, No.1, (January 1997), pp.14-23.
- Thielemann, F.W.; Blerch, E.; & Holz, U. (1988). [Plate osteosynthesis of femoral shaft fracture with reference to biological aspects], *Unfallchirurg*, Vol.91, No.9, (September 1988), pp.389-394. German.
- Vidal, J.; Buscayret, C.; Fischbach, C.; Brahin, B.; Paran, M.; & Escare, P. (1977). [New method of treatment of comminuted fractures of the lower end of the radius: „ligamentary taxis“], *Acta Orthop Belg*, Vol.43, No.6, pp.781-789. French.

- Wagner, M. (2003). General principles for the clinical use of the LCP, *Injury*, Vol.34, Suppl 2, (November 2003), pp.B31-42. Review.
- Wagner, M. & Frigg, R. (2006). *Manual of Fracture Management, Internal Fixators, Concepts and Cases using LCP and LISS*, Thieme, New York, USA.
- Wang, J.W.; & Wang, C.J. (2002). Supracondylar fractures of the femur above total knee arthroplasties with cortical allograft struts, *J Arthroplasty*, Vol.17, No.3, (April 2002), pp.365-372.
- Wenzl, H.; Casey, P.A.; Hérbert, P.; & Bellin, J. (1970). Die operative Behandlung der distalen Femurfraktur. *AO Bulletin*, Chur AO: Arbeitsgemeinschaft für Osteosynthesefragen.
- Wick, M, Müller, E.J.; & Muhr, G. (2001). [Supracondylar femoral fractures in knee endoprosthesis. Stabilizing with retrograde interlocking nail], *Unfallchirurg*, Vol.104, No.5, (May 2001), pp.410-413. German.
- Wick, M.; Müller, E.J.; Kutscha-Lissberg, F.; Hopf, F.; & Muhr, G. (2004). [Periprosthetic supracondylar femoral fractures: LISS or retrograde intramedullary nailing? Problems with use of minimally invasive technique], *Unfallchirurg*, Vol.107, No.3, (March 2004), pp.181-188. German.
- Zehntner, M.K.; & Ganz, R. (1993). Internal fixation of supracondylar fractures after condylar total knee arthroplasty. *Clin Orthop Relat Res*, Vol.293, (August 1993), pp.219-224.
- Zlowodzki, M.; Williamson, S.; Cole, P.A.; Zardiackas, L.D.; & Kregor, P.J. (2004). Biomechanical evaluation of the less invasive stabilization system, angled blade plate, and retrograde intramedullary nail for the internal fixation of distal femur fractures, *J Orthop Trauma*, Vol.18, No.8, (September 2004), pp.494-502.

IntechOpen



## **Recent Advances in Hip and Knee Arthroplasty**

Edited by Dr. Samo Fokter

ISBN 978-953-307-841-0

Hard cover, 452 pages

**Publisher** InTech

**Published online** 27, January, 2012

**Published in print edition** January, 2012

The purpose of this book is to offer an exhaustive overview of the recent insights into the state-of-the-art in most performed arthroplasties of large joints of lower extremities. The treatment options in degenerative joint disease have evolved very quickly. Many surgical procedures are quite different today than they were only five years ago. In an effort to be comprehensive, this book addresses hip arthroplasty with special emphasis on evolving minimally invasive surgical techniques. Some challenging topics in hip arthroplasty are covered in an additional section. Particular attention is given to different designs of knee endoprotheses and soft tissue balance. Special situations in knee arthroplasty are covered in a special section. Recent advances in computer technology created the possibility for the routine use of navigation in knee arthroplasty and this remarkable success is covered in depth as well. Each chapter includes current philosophies, techniques, and an extensive review of the literature.

### **How to reference**

In order to correctly reference this scholarly work, feel free to copy and paste the following:

K. Kolb, P.A. Grützner, F. Marx and W. Kolb (2012). Fixation of Periprosthetic Supracondylar Femur Fractures Above Total Knee Arthroplasty – The Indirect Reduction Technique with the Condylar Blade Plate and the Minimally Invasive Technique with the LISS, Recent Advances in Hip and Knee Arthroplasty, Dr. Samo Fokter (Ed.), ISBN: 978-953-307-841-0, InTech, Available from: <http://www.intechopen.com/books/recent-advances-in-hip-and-knee-arthroplasty/fixation-of-periprosthetic-supracondylar-femur-fractures-above-total-knee-arthroplasty-the-indirect->

**INTECH**  
open science | open minds

### **InTech Europe**

University Campus STeP Ri  
Slavka Krautzeka 83/A  
51000 Rijeka, Croatia  
Phone: +385 (51) 770 447  
Fax: +385 (51) 686 166  
[www.intechopen.com](http://www.intechopen.com)

### **InTech China**

Unit 405, Office Block, Hotel Equatorial Shanghai  
No.65, Yan An Road (West), Shanghai, 200040, China  
中国上海市延安西路65号上海国际贵都大饭店办公楼405单元  
Phone: +86-21-62489820  
Fax: +86-21-62489821

© 2012 The Author(s). Licensee IntechOpen. This is an open access article distributed under the terms of the [Creative Commons Attribution 3.0 License](#), which permits unrestricted use, distribution, and reproduction in any medium, provided the original work is properly cited.

IntechOpen

IntechOpen