

We are IntechOpen, the world's leading publisher of Open Access books Built by scientists, for scientists

4,800

Open access books available

122,000

International authors and editors

135M

Downloads

Our authors are among the

154

Countries delivered to

TOP 1%

most cited scientists

12.2%

Contributors from top 500 universities



WEB OF SCIENCE™

Selection of our books indexed in the Book Citation Index
in Web of Science™ Core Collection (BKCI)

Interested in publishing with us?
Contact book.department@intechopen.com

Numbers displayed above are based on latest data collected.

For more information visit www.intechopen.com



Hip Fracture in the Elderly: Partial or Total Arthroplasty?

Samo K. Fokter¹ and Nina Fokter²

¹Celje General and Teaching Hospital

²Maribor University Clinical Centre
Slovenia

1. Introduction

The growing number of femoral neck fractures will have a large impact on health economics of developed countries in the coming decades. Great numbers of patients are already hospitalised yearly due to femoral neck fractures. These numbers are expected to augment importantly in the future years as the life expectancy and osteoporosis incidence increase in the ageing population. In the past, conservation of femoral head was supposed to be the ideal treatment for dislocated femoral neck fractures. However, conservation of femoral head with internal fixation has shown a high incidence of aseptic necrosis and non-union. Therefore, this treatment is now mostly applied to younger patients without osteoporosis and arthritis. In this chapter we review the topic of management of displaced femoral neck fractures in the elderly from a historical, surgical, and economical perspective. The emphasis is placed on the treatment rationale, surgical technique, and long-term clinical results. The authors' preferred choice of treatment of these sometimes difficult cases is also presented and illustrated.

2. Internal fixation or arthroplasty?

Therapeutic approaches for treatment of elderly patients with dislocated femoral neck fractures (Garden III-IV) include internal fixation of bone fragments, hemiarthroplasty or total hip arthroplasty (THA), and there is still no consensus about the optimal treatment. In a large multicentre prospective randomised study Rogmark et al. compared the results of internal fixation and hip arthroplasty in patients older than 70 years with a 2-year follow-up (Rogmark et al., 2002). They found 43% of treatment failures in the internal fixation group and only 6% of treatment failures in the arthroplasty group.

Bhandari et al. performed a meta-analysis of 14 prospective randomised studies comparing internal fixation with arthroplasty and discovered that 17% of patients could have been spared a revision surgery had they been treated with arthroplasty instead of internal fixation (Bhandari et al., 2003). Similar findings were described by Keating et al. in a study of patients older than 60 years with femoral neck fracture (Keating et al., 2006). At 2-year follow-up, 39% of the patients treated with internal fixation needed a secondary surgical procedure, whereas secondary surgery was required only in 5% of the patients treated with hemiarthroplasty and in 9% of the patients treated with THA. The complication rate can

certainly be lowered by fast diagnostic procedures and a shorter time in bed waiting for the surgery. Internal fixation with femoral head preservation should be performed in the first 6 hours after the injury or only exceptionally in the first 24 hours. In older injuries hip arthroplasty should be performed (Sendtner et al., 2010). The bone healing potential is especially low in older patients (Figure 1).

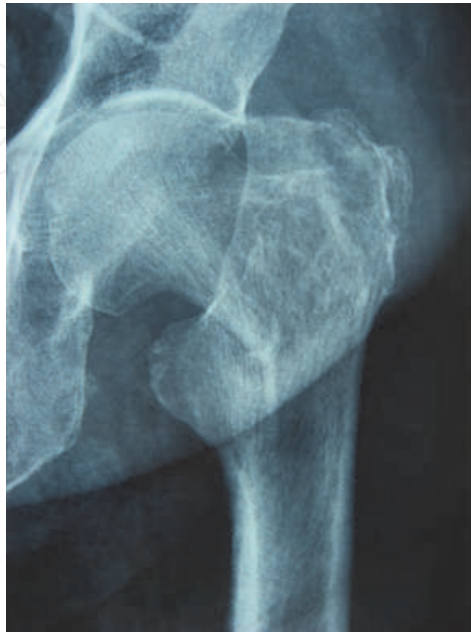

Fig. 1A. Proximal femoral fracture in a 74-year old female osteoporotic patient.

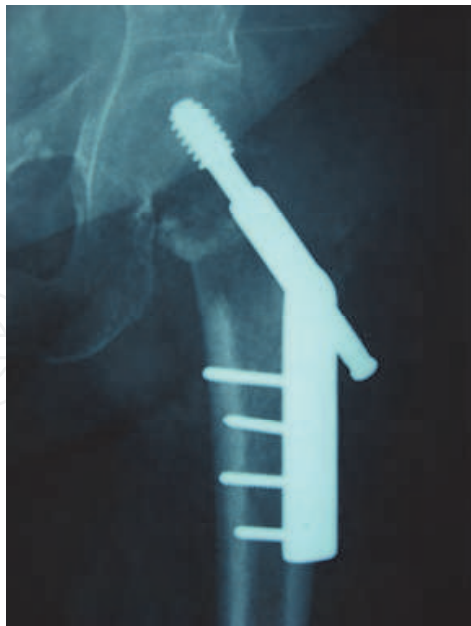

Fig. 1B. No signs of bony healing 6 months after open reduction and internal fixation with a dynamic hip screw (DHS) device. The patient is unable to walk.

In case we do not decide for preservation of the femoral head the remaining treatment options are unipolar hemiarthroplasty, bipolar hemiarthroplasty and THA.

3. Hemiarthroplasty

While hemiarthroplasty avoids the known risks of internal fixation, it brings other risks of its own: infection, stem loosening, dislocation, and groin pain as an effect of acetabular protrusion (Figure 2) or cartilage erosion (the so-called endoprosthetic arthritis).

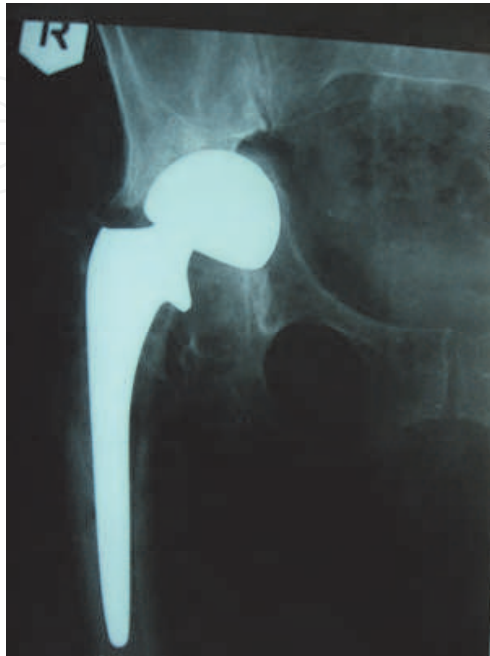

Fig. 2A. Acetabular fracture in a 64-year old patient 5 years after bipolar hemiarthroplasty for right femoral neck fracture.

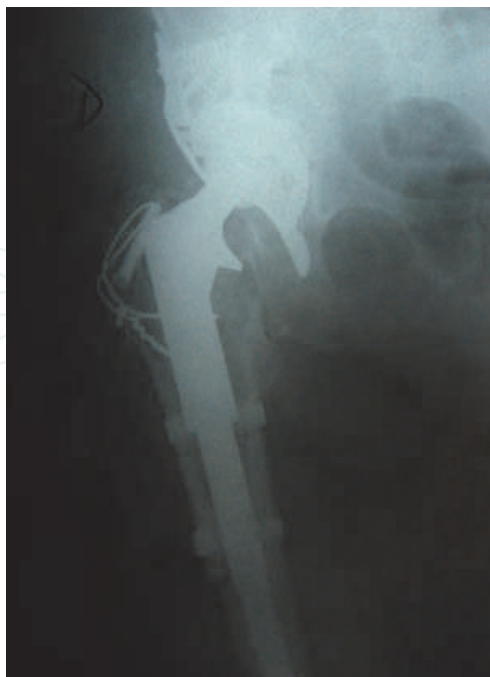

Fig. 2B. The same patient after revision total hip arthroplasty with insertion of a Burch-Schneider acetabular supportive ring.

Unipolar hemiarthroplasty has been in use for more than half a century. The short-term results of this treatment are usually good, with rare infections and dislocations. However, the rates of mid- and long-term complications (5 to >20 years postoperatively) are high due to acetabular cartilage erosion. The cartilage defect causes pain and is the main reason for conversion to THA. Kofoed and Kofod found that as much as 55% of patients living alone needed conversion to THA two years after unipolar arthroplasty for femoral neck fracture (Kofoed & Kofod, 1983). The factors accelerating acetabular cartilage erosion are young age, high activity level and the length of follow-up (Macaulay et al., 2006).

The aim of introducing bipolar hemiarthroplasty in the 1970s was to prevent the development of endoprosthetic arthritis. Some motion is carried out among the components of the prosthesis, which theoretically diminishes acetabular wear. However, the functional importance of the prosthesis-prosthesis motion remains unclear. In a prospective randomised study of 115 patients over the age of 65 years with dislocated femoral neck fracture treated with either unipolar or bipolar hemiarthroplasty, Raija et al. found no statistical difference between the groups in quality of life and functional outcome at one year follow-up (Raija et al., 2003). Cornell et al. compared the results of treatment of 47 patients with an average age of 77 years. They noted better hip rotation and abduction and higher walking speed in the group treated with bipolar hemiarthroplasty compared to the group treated with unipolar hemiarthroplasty. On the other hand, they found no statistical difference in postoperative complication rates, lengths of hospitalisation and functional outcomes between the two groups (Cornell et al., 1998). Similar conclusions were reached by Parker and Gurusamy who compared the results of prospective randomised trials including a total of 857 patients (Parker & Gurusamy, 2004). The research showed an absence of significant differences between unipolar and bipolar hemiarthroplasty concerning hip dislocation, acetabular cartilage erosion, infection, reoperation rate and deep vein thrombosis at an average follow-up of 2 years.

Unipolar hemiarthroplasty is generally recommended for elderly, less active patients with a shorter life expectancy. These are the patients with the least benefit from the potential advantages of the more expensive bipolar hemiarthroplasty. Some authors advise against bipolar hemiarthroplasty in the elderly because of its higher price, long-term complications due to polyethylene wear, and higher rates of hip dislocations requiring an open reposition (Giliberty, 1983).

4. Total hip arthroplasty

In the past, THA was used in elderly patients with femoral neck fractures only in cases of coexisting acetabular disease. In 2004 Healy and Iorio proved that elderly patients treated with THA for displaced femoral neck fractures achieved a more independent living, a longer interval to reoperation or death, and better cost effectiveness than patients treated with internal fixation or hemiarthroplasty (Healy & Iorio, 2004).

Older studies have reported a higher incidence of hip dislocations after THA for femoral neck fractures compared to elective THA for acetabular cartilage disease. The reason for the higher dislocation rate was supposed to be the greater range of motion in patients with a fractured femoral neck. However, more recent studies have not confirmed the supposed differences concerning perioperative morbidity, functional outcome, and radiological signs

of loosening (Abboud et al., 2004). Enocson et al. nevertheless recommended a careful choice of surgical approach in order to minimise the risk of dislocation (Enocson et al., 2009). In a prospective cohort study including 698 patients treated with THA for displaced femoral neck fracture or its complications, the least dislocations were noted in the anterolateral approach group (2%), while the dislocation rate in the posterolateral approach group was six times higher (13%). An additional reduction of dislocation risk in THA inserted via posterior approach can be achieved with the use of cemented dual articulation acetabular component (Tarasevicius et al., 2010).

Longer-term results of THA for femoral neck fracture were published by Lee et al. (Lee et al., 1998). They reported on treatment of 126 patients with an average age of 75 years and a 9-year follow-up. 10% of the patients had one or more postoperative dislocations, but 99% had mild or no pain and 69% reached their preoperative level of function or better. The study showed a higher complication rate in THA than is usual for hemiarthroplasty, but on the other hand revealed good clinical results and long-term prosthesis survival.

Total hip arthroplasty is a durable treatment option for femoral neck fractures in the elderly and gives a good functional outcome, but comes with the price of a higher complication rate, such as dislocation or postoperative delirium (Gallo et al., 2010). Surgical technique adapted to osteoporotic bone and careful implant selection regarding fixation influence the success of treatment for femoral neck fractures (Figure 3). The risk of dislocation depends on the surgical approach, the reconstruction of hip biomechanics, the head size and offset, the quality of capsular closure, and the experience of the surgeon (Ames et al., 2010; Leighton et al., 2007; Rutz et al., 2010).

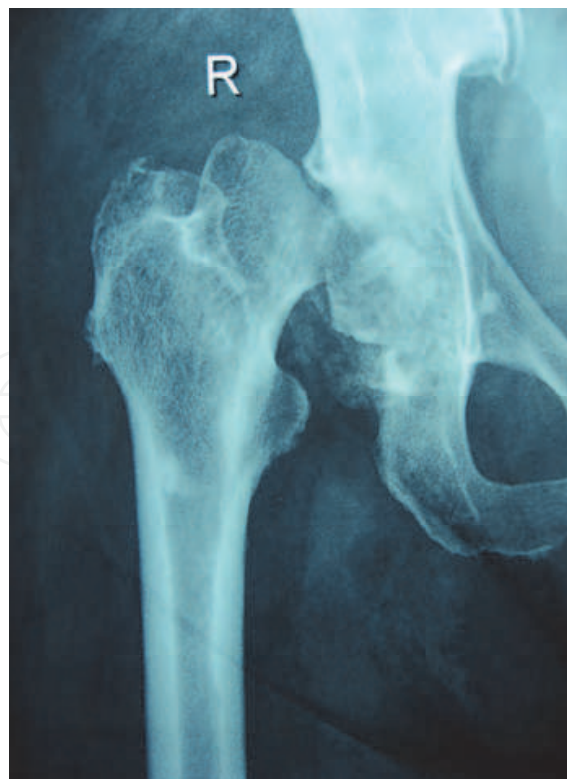

Fig. 3A. Subcapital fracture in a 71-year old female patient with osteoporosis.

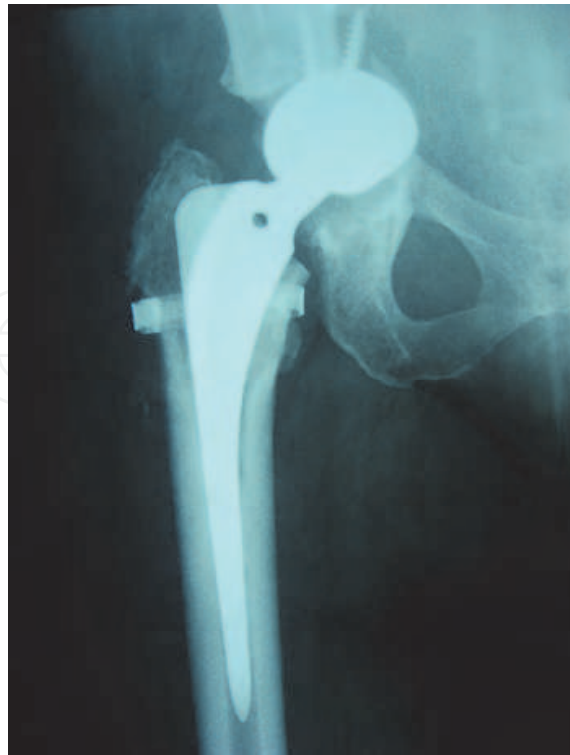

Fig. 3B. Acetabular fracture and intrapelvic cup (press-fit type) migration noted 6 weeks after primary uncemented THA in the same patient. Note that intraoperative femoral shaft fracture also occurred and was treated with a cerclage belt.

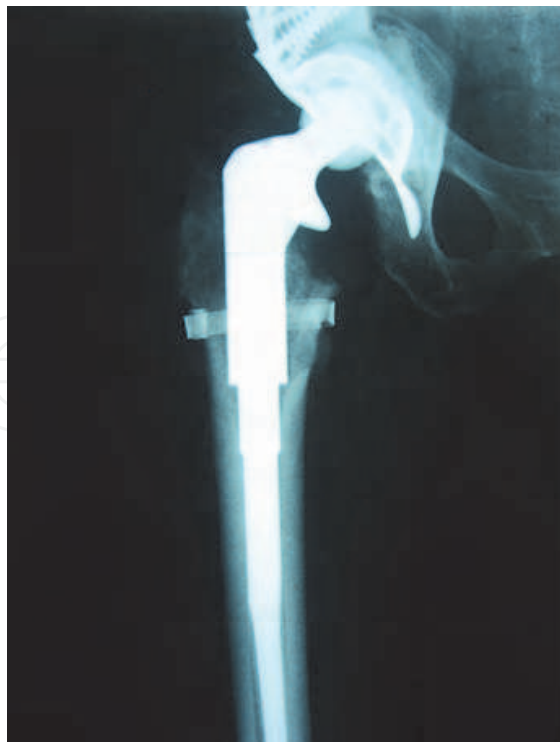

Fig. 3C. The same patient after revision THA with modular femoral stem and a Bursch-Schneider acetabular supportive ring.

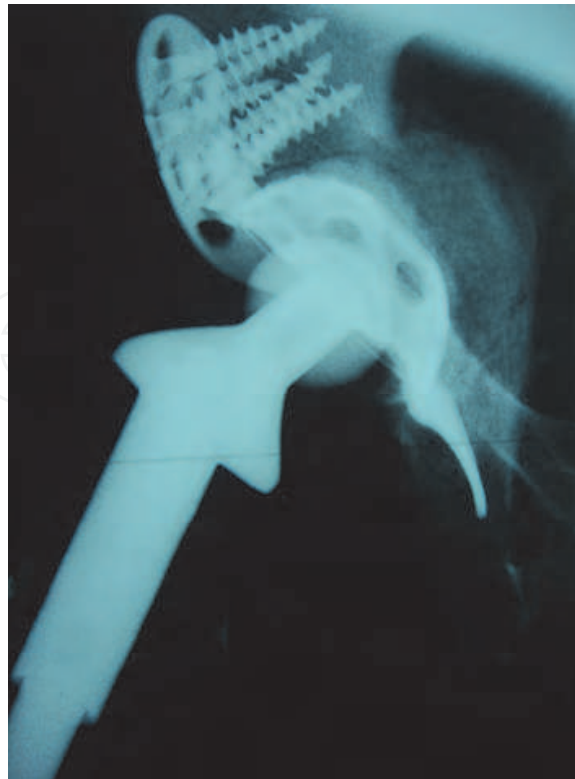

Fig. 3D. The same patient after revision THA on lateral radiograph. Note massive autologous bone grafts under the Bursch-Schneider ring.

5. Cemented or cementless hip arthroplasty?

There is still a lively ongoing debate in the orthopaedic community as to which method of fixation of the implant is superior to the other. Although the development of total hip replacement began with cementless THA in the late fifties, cemented THA has been more popular after Charnley's systematic promotion of low friction arthroplasty, which included fixation with bone cement (Charnley, 1961). Nevertheless, cementless THA rapidly gained acceptance during the 1980s when materials that allowed bone ingrowth became available. A meta-analysis comparing the survival rate of cemented and cementless THA reported that cemented THA was slightly superior (Morsched et al., 2007). However, the difference between the groups was no longer significant when revision surgery of the cup or the stem was regarded as treatment failure. At present, it is not possible to ascertain the superiority of any of the two options. In the authors' institutions, cemented type of fixation is used in the majority of fracture cases.

Figved et al. recently raised the question whether a specific type of fixation should be used for the treatment of displaced femoral neck fractures (Figved et al., 2009). In the randomized, controlled trial in patients 70 years and older comparing a cemented implant with hydroxyapatite-coated uncemented implant, both with a bipolar head, the mean Harris hip score showed equivalence between the groups after 3 months and 12 months. The complication and mortality rates were similar in both groups. However, the duration of surgery was 12.4 minutes shorter and the mean intraoperative blood loss was 89 mL less in the cementless group.

6. Hemiarthroplasty or total hip arthroplasty?

Rogmark et al. tried to evaluate which patients to treat with THA and which with hemiarthroplasty in the course of surgical treatment of femoral neck fractures (Rogmark et al., 2002). In the multicentre prospective randomised trial comparing internal fixation to arthroplasty, they divided the arthroplasty group to hemiarthroplasty and THA according to the scoring system for patients with femoral neck fracture (Table 1). Patients with a score of 15 or more were treated with THA and the others with hemiarthroplasty. The scoring system favoured THA in younger (age 70-80 years), alert patients who were capable of independent walking before the injury. The authors noted no significant difference between the THA and hemiarthroplasty groups. The overall dislocation rate was 8%. They concluded that the good functional outcome and the relatively low incidence of dislocations proved the value of their scoring system for choosing the appropriate patients for each treatment option.

Patient Variables	Points*
Age	
70 to 80 years	5
> 80 years	2
Habitat	
Own home	5
Sheltered home	2
Walking aids	
One cane or none	5
Canes, walking frame	2
Mental status	
Alert	5
Slight confusion	2

*A total score ≥ 15 points indicates treatment required with total hip arthroplasty.

Table 1. Rogmark preoperative scoring system for patients with femoral neck fractures (Rogmark et al., 2002).

Hopley et al. recently published a systematic review comparing THA with hemiarthroplasty considering reoperation rates, mortality, complications, functional outcome and quality of life (Hopley et al., 2010). They identified 3821 references, inspected 202 papers and included 15 papers with a total of 1890 patients. The meta-analysis showed that THA carried a lower risk of reoperation than hemiarthroplasty. THA also showed better ratings in the Harris hip score than hemiarthroplasty. However, the rates of dislocation (relative risk 1.48; 95% confidence interval 0.89 to 2.46) and general complications (relative risk 1.14, 95% confidence interval 0.87 to 1.48) were slightly higher for THA.

Arthroplasty is thus indicated in most patients over the age of 65 years with femoral neck fractures. Hemiarthroplasty is indicated in institutionalised patients and patients with comorbidities who are not expected to live longer than 6 or 7 years. Studies show a high reoperation rate in patients living longer than 6 to 7 years after hemiarthroplasty. THA is indicated in active patients with little or no comorbidities as it represents the most successful treatment in terms of pain relief and is also cost effective (Kyle, 2010). Recent

advances in the materials and technology of THA components allowing the use of larger femoral heads, as well as better surgical techniques have made THA safer and less prone to dislocation and other mechanical complications. Economical analyses demonstrate that due to the costs of complications THA is more cost effective than internal fixation or hemiarthroplasty in patients surviving 2 years or longer after their initial femoral neck fracture. An increasing number of authors therefore believe that THA should be granted a larger role in the treatment of displaced femoral neck fractures than it has had in the past (Schmidt et al., 2009).

7. Cost

We live in a time of global recession and information about the cost of treatment is unfortunately not unimportant. Iorio et al. calculated the costs of treatment of femoral neck fractures in the elderly during a 2-year postoperative period (Iorio et al., 2001). Surgical treatment methods included reduction with internal fixation, unipolar hemiarthroplasty, bipolar hemiarthroplasty, and THA. The analysis included the costs of hospitalisation, rehabilitation, and probability-adjusted costs of revision. The calculated total cost of cemented THA was 20,670 US dollars, hybrid THA 21,066 US dollars, bipolar hemiarthroplasty 22,043 US dollars, unipolar hemiarthroplasty 21,597 US dollars, and internal fixation 24,606 US dollars. The authors concluded that taking into account complication rates, mortality, revision surgeries and functional outcome, THA is the most cost effective treatment option for femoral neck fractures in the elderly.

The current costs of treatment for femoral neck fractures in the elderly in Northern Europe have been analysed by Frihagen et al. (Frihagen et al., 2010). They randomised 222 patients with an average age of 83 years to internal fixation or hemiarthroplasty. The patients were followed for 2 years. The analysis included costs of hospitalisation, rehabilitation, community-based care, and nursing home use. Primary hospital treatment was less expensive in the group treated with internal fixation (9,044 euros) than in the hemiarthroplasty group (11,887 euros). The relation changed when they included all hospital costs (rehabilitation, revision surgeries, formal and informal contact with the hospital): 21,709 euros for internal fixation and 19,976 euros for hemiarthroplasty. When all costs of the 2-year treatment were included (with community-based care and nursing home), internal fixation was much more expensive (47,186 euros) than hemiarthroplasty (38,615 euros).

8. Summary

Strong evidence exists in favour of primary arthroplasty over internal fixation for displaced femoral neck fractures in the elderly. Hemiarthroplasty is indicated for institutionalised patients, and patients with comorbidities who are not expected to live longer than a few years. THA is definitely indicated for patients with concurrent degenerative or rheumatic arthritis. Besides, evidence is accumulating that THA may be more effective than hemiarthroplasty in terms of pain relief and functional outcome in younger, more active patients with intact acetabulum and longer life expectancy. Regarding costs to the society, hemiarthroplasty is more favourable than internal fixation on the short term, and THA is more favourable than hemiarthroplasty on the medium term. Considering the growing life

expectancy, primary THA should be chosen more often for the treatment of displaced femoral neck fractures even in the elderly.

9. References

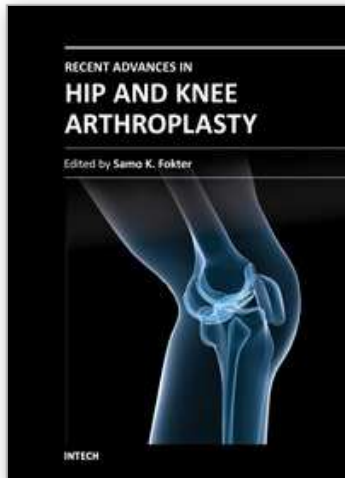
- Abboud, J. A., Patel, R. V., Booth Jr, R. E. & Nasarian, D. G. (2004). Outcomes of total hip arthroplasty are similar for patients with displaced femoral neck fractures and osteoarthritis. *Clinical Orthopaedics and Related Research*, Vol.421, No.4, (April 2004), pp. 151-154
- Ames, J. B., Lurie, J. D., Tomek, I. M., Zhou, W. & Koval, K. J. (2010) Does surgeon volume for total hip arthroplasty affect outcomes after hemiarthroplasty for femoral neck fracture? *The American Journal of Orthopedics (Belle Mead)*, Vol.39, No.8, (August 2010), pp. E84-89
- Bhandari, M., Devereaux, P. J., Swiontkowski, M. F., Tornetta 3rd, P., Obrebsky, W., Koval, K. J., Nork, S., Sprague, S., Schemitsch, E. H. & Guyatt, G. H. (2003) Internal fixation compared with arthroplasty for displaced fractures of the femoral neck: A meta-analysis. *Journal of Bone and Joint Surgery, American Volume*, Vol.85, No.9, (September 2003), pp. 1673-1681
- Charnley, J. (1961) Arthroplasty of the hip: A new operation. *Lancet*, Vol.277, No.7187, (May 1961), pp. 1129-1132
- Cornell, C. N., Levine, D., O'Doherty, J. & Lyden, J. (1998) Unipolar versus bipolar hemiarthroplasty for the treatment of femoral neck fractures in the elderly. *Clinical Orthopaedics and Related Research*, Vol.348, No.3, (March 1998), pp. 67-71
- Enocson, A., Hedbeck, C. J., Tidermark, J., Pettersson, H., Ponzer, S. & Lapidus, L. J. (2009) Dislocation of total hip replacement in patients with fractures of the femoral neck: A prospective cohort study of 713 consecutive hips. *Acta Orthopaedica*, Vol.80, No.2, (April 2009), pp. 184-189, ISSN 1745-3674
- Figved, W., Opland, V., Frihagen, F., Jervidal, T., Madsen, J. E. & Nordsletten, L. (2009) Cemented versus uncemented hemiarthroplasty for displaced femoral neck fractures. *Clinical Orthopaedics and Related Research*, Vol.467, No.9, (September 2009), pp. 2426-2435
- Frihagen, F., Waaler, G. M., Madsen, J. E., Nordsletten, L., Aspaas, S. & Aas, E. (2010) The cost of hemiarthroplasty to that of internal fixation for femoral neck fractures. *Acta Orthopaedica*, Vol.81, No.4, (August 2010), pp. 446-452
- Gallo, J., Cechova, I. & Zapletalova, J. (2010) Early complications associated with total hip arthroplasty due to femoral neck fracture. *Acta Chirurgiae Orthopaedicae et Traumatologiae Cechoslovaca*, Vol.77, No.5, (October 2010), pp. 389-394
- Giliberty, R. P. (1983) Hemiarthroplasty of the hip using low-friction bipolar endoprosthesis. *Clinical Orthopaedics and Related Research*, Vol.175, No.5, (May 1983), pp. 86-92
- Healy, W. L. & Iorio, R. (2004) Total hip arthroplasty: Optimal treatment for displaced femoral neck fractures in elderly patients. *Clinical Orthopaedics and Related Research*, Vol.429, No.12, (December 2004), pp. 43-48
- Hopley, C., Stengel, D., Ekkernkamp, A. & Wich, M. (2010) Primary total hip arthroplasty versus hemiarthroplasty for displaced intracapsular hip fractures in older patients: Systematic review. *British Medical Journal*, No.340, (June 2010), c2332

- Iorio, R., Healy, W. L., Lemos, D. W., Appleby, D., Luzzhesi, C. A. & Saleh, K. J. (2001) Displaced femoral neck fractures in the elderly: Outcomes and cost effectiveness. *Clinical Orthopaedics and Related Research*, Vol.383, No.2, (February 2001), pp. 229-242
- Keating, J. F., Grant, A., Masson, M., Scott, N. W. & Forbes, J. F. (2006) Randomized comparison of reduction and fixation, bipolar hemiarthroplasty, and total hip arthroplasty: Treatment of displaced intracapsular hip fractures in healthy older patients. *Journal of Bone and Joint Surgery, American Volume*, Vol.88, No.2, (February 2006), pp. 249-60
- Kofoed, H. & Kofod, J. (1983) Moore prosthesis in the treatment of fresh femoral neck fractures: A critical review with special attention to secondary acetabular degeneration. *Injury*, Vol.14, No.6, (May 1983), pp. 531-540
- Kyle, R. F. (2010) Subcapital fractures: In the bucket or on top of the neck? *Orthopedics*, Vol.33, No.9, (September 2010), p.644
- Lee, B. P., Berry, D. J., Harmsen, W. S. & Sim, F. H. (1998) Total hip arthroplasty for the treatment of an acute fracture of the femoral neck: Long-term results. *Journal of Bone and Joint Surgery, American Volume*, Vol.80, No.1, (January 1998), pp. 70-75
- Leighton, R. K., Schmidt, A. H., Collier, P. & Trask, K. (2007) Advances in the treatment of intracapsular hip fractures in the elderly. *Injury*, Vol.38, No.5, (September 2007), pp.S24-S34
- Macaulay, W., Pagnotto, M. R., Iorio, R., Mont, M. A. & Saleh, K. J. (2006) Displaced femoral neck fractures in the elderly: hemiarthroplasty versus total hip arthroplasty. *Journal of the American Academy of Orthopaedic Surgeons*, Vol.14, No.5, (May 2006), pp. 287-293
- Morsched, S., Bozic, K. J., Ries, M. D., Malchau, H. & Colford Jr., J. M. (2007) Comparison of cemented and uncemented fixation in total hip replacement: a meta-analysis. *Acta Orthopaedica*, Vol.78, No.3, (June 2007), pp. 315-326
- Parker, M. J. & Gurusamy, K. (2004) Arthroplasties (with and without bone cement) for proximal femoral fractures in adults. *Cochrane Database of Systematic Reviews*, Vol.2, CD001706
- Raia, F. J., Chapman, C. B., Herrera, M., Schweppe, M. W., Michelsen, C. B. & Rosenwasser, M. P. (2003) Unipolar or bipolar hemiarthroplasty for femoral neck fractures in the elderly? *Clinical Orthopaedics and Related Research*, Vol.414, No.9, (September 2003), pp. 259-265
- Rogmark, C., Carlsson, A., Johnell, O. & Sernbo, I. (2002) A prospective randomised trial of internal fixation versus arthroplasty for displaced fractures of the neck of the femur: Functional outcomes for 450 patients at two years. *Journal of Bone and Joint Surgery, British Volume*, Vol.84, No.2, (March 2002), pp. 183-188
- Rutz, E., Leumann, A., Rutz, D., Schaefer, D. & Walderrabano, W. (2010) Total hip arthroplasty for fractures of the proximal femur in older patients. *Hip International*, Vol.20, No.2, (April-June 2010), pp. 215-220
- Schmidt, A. H., Leighton, R., Parvizi, J., Sems, A. & Berry, D. J. (2009) Optimal arthroplasty for femoral neck fractures: Is total hip arthroplasty the answer? *Journal of Orthopaedic Trauma*, Vol.23, No.6, (July 2009), pp. 428-433

- Sendtner, E., Renkawitz, T., Kramny, P., Wenzl, M. & Grifka, J. (2010) Fractured neck of femur - internal fixation versus arthroplasty. *Deutsches Aerzteblatt International*, Vol.107, No.23, (June 2010), pp.401-407
- Tarasevicius, S., Busevicius, M., Robertson, O. & Wingstrand, H. (2010) Dual mobility cup reduces dislocation rate after arthroplasty for femoral neck fracture. *BMC Musculoskeletal Disorders*, Vol.6, No.11, (August 2010), pp. 175-178

IntechOpen

IntechOpen



Recent Advances in Hip and Knee Arthroplasty

Edited by Dr. Samo Fokter

ISBN 978-953-307-841-0

Hard cover, 452 pages

Publisher InTech

Published online 27, January, 2012

Published in print edition January, 2012

The purpose of this book is to offer an exhaustive overview of the recent insights into the state-of-the-art in most performed arthroplasties of large joints of lower extremities. The treatment options in degenerative joint disease have evolved very quickly. Many surgical procedures are quite different today than they were only five years ago. In an effort to be comprehensive, this book addresses hip arthroplasty with special emphasis on evolving minimally invasive surgical techniques. Some challenging topics in hip arthroplasty are covered in an additional section. Particular attention is given to different designs of knee endoprotheses and soft tissue balance. Special situations in knee arthroplasty are covered in a special section. Recent advances in computer technology created the possibility for the routine use of navigation in knee arthroplasty and this remarkable success is covered in depth as well. Each chapter includes current philosophies, techniques, and an extensive review of the literature.

How to reference

In order to correctly reference this scholarly work, feel free to copy and paste the following:

Samo K. Fokter and Nina Fokter (2012). Hip Fracture in the Elderly: Partial or Total Arthroplasty?, Recent Advances in Hip and Knee Arthroplasty, Dr. Samo Fokter (Ed.), ISBN: 978-953-307-841-0, InTech, Available from: <http://www.intechopen.com/books/recent-advances-in-hip-and-knee-arthroplasty/hip-fracture-in-the-elderly-partial-or-total-arthroplasty->

INTECH
open science | open minds

InTech Europe

University Campus STeP Ri
Slavka Krautzeka 83/A
51000 Rijeka, Croatia
Phone: +385 (51) 770 447
Fax: +385 (51) 686 166
www.intechopen.com

InTech China

Unit 405, Office Block, Hotel Equatorial Shanghai
No.65, Yan An Road (West), Shanghai, 200040, China
中国上海市延安西路65号上海国际贵都大饭店办公楼405单元
Phone: +86-21-62489820
Fax: +86-21-62489821

© 2012 The Author(s). Licensee IntechOpen. This is an open access article distributed under the terms of the [Creative Commons Attribution 3.0 License](#), which permits unrestricted use, distribution, and reproduction in any medium, provided the original work is properly cited.

IntechOpen

IntechOpen