

We are IntechOpen, the world's leading publisher of Open Access books Built by scientists, for scientists

4,800

Open access books available

122,000

International authors and editors

135M

Downloads

Our authors are among the

154

Countries delivered to

TOP 1%

most cited scientists

12.2%

Contributors from top 500 universities



WEB OF SCIENCE™

Selection of our books indexed in the Book Citation Index
in Web of Science™ Core Collection (BKCI)

Interested in publishing with us?
Contact book.department@intechopen.com

Numbers displayed above are based on latest data collected.
For more information visit www.intechopen.com



Shoulder Hemiarthroplasty in Proximal Humerus Fractures

José Hernández Enríquez, Xavier A. Duralde and Antonio J. Pérez Caballer

¹*Orthopaedics Department, Hospital Infanta Elena, Valdemoro*

²*Orthopaedics Department, Peachtree Orthopaedic Clinic, Atlanta GA*

³*Orthopaedics Department, Hospital Infanta Elena, Valdemoro*

^{1,3}*Spain*

²*USA*

1. Introduction

We present a review of the most recent published articles related to shoulder hemiarthroplasty in proximal humerus fractures. Four-part proximal humerus fractures represent between 2% and 10% of all proximal fractures where displacement occurs as a result of the muscular deforming force.

Hemiarthroplasty is indicated in patients with four-part fractures and in elderly patients with osteoporotic bone who have fracture-dislocations. In both groups of patients, obtaining a secure stable reduction using internal fixation techniques is difficult, and the rate of osteonecrosis can range from 13% to 35% in four-part fractures. Hemiarthroplasty can also be considered in patients with three-part fractures and fracture-dislocations when bone quality is poor and the degree of comminution precludes satisfactory reduction and internal fixation. Headsplitting proximal humerus fractures in elderly patients also should be treated with hemiarthroplasty. Primary replacement can be considered in younger patients with four-part proximal fractures if acceptable reduction cannot be obtained.

The important surgical principles when performing a hemiarthroplasty for four-part proximal humeral fractures include the following: the use of a deltopectoral approach, allowing preservation of the deltoid origin and insertion; restoration of humeral length and retroversion; and secure fixation of the tuberosities to the prosthesis, to the shaft and to one another.

Results of hemiarthroplasty for four-part proximal humerus fractures are somewhat difficult to interpret, specifically because other proximal humerus fracture patterns often are included in published series. Wide variation in outcomes measurements also makes comparisons between studies difficult. Despite these limitations, hemiarthroplasty offers reliable pain relief and reasonable levels of patient satisfaction, but only modest functional results. Limited use with activities of daily living below shoulder level may be reliably obtained but overhead use is not typical following this surgery.

Significant residual pain generally tends to be associated with moderate activity: minimal pain occurs at rest. Even when motion and functional results are limited, pain relief is reported to be consistent.

Reports of patient satisfaction vary widely, in part because of the numerous scales used to measure outcomes and satisfaction. High satisfaction rates seem to correlate more with pain relief than with range of motion or functional outcomes. Even studies with poor functional results report high patient satisfaction if pain relief is acceptable.

The prognostic factors have been shown to be the age, the delay between injury and surgery, preoperative neurologic deficit, history of cigarette smoking, excessive alcohol consumption and female sex. Tuberosity position and healing may be the most important factors in determining outcome.

Recently the use of the Reverse Total Shoulder Replacement has been recommended in selected cases of proximal humeral fracture. Although the indications and results of this technique are not well known yet, this may offer an advantage in selected cases over traditional Humeral Head Replacement. Any possible advantages of this technique must be weighed against increased risks and the known results of humeral head replacement.

Humeral head replacement is indicated for a select group of proximal humeral fractures depending on the severity and pattern of the fracture as well as bone quality and cuff integrity (Compito et al 1994). The results of this surgery are dependent on patient factors, timing of surgery, and technical factors associated with the performance of the operation. The majority of fractures of the proximal humerus can be treated nonoperatively but a full 15% of cases will require some type of operative intervention (Young et al 1985, Zuckerman et al 2007). Neer's fracture classification has generally served as a reliable guide to fracture management (Neer et al 1970, 1970). The more severe the injury, the higher the risk of avascular necrosis of the humeral head, malunion, or nonunion of the fracture. When indicated, early surgical intervention leads to superior results and avoids many complications associated with delayed management (Demirhan et al 2003, Duralde & Leedy 2010).

Operative treatment options for proximal humeral fractures include various forms of open or closed reduction and fixation versus prosthetic replacement. The introduction of the proximal humeral locking plate has expanded the indications for ORIF as patients with osteoporotic bone can now be better managed utilizing this plate for fixation (Duralde & Leedy 2010). Even cases of late avascular necrosis following ORIF can be managed effectively with hardware removal and prosthetic replacement as long as the tuberosities have healed in a relatively anatomic position (Boileau et al 2001). Similarly advances in the technique of closed reduction and percutaneous pinning have increased the indications for this modality (Jaberg et al 1992). ORIF remains a good option for displaced 2-part fractures, 3-part fractures (even in the face of osteoporosis), and impacted valgus 4-part fractures of the proximal humerus (Bastian & Hertel 2009, Duralde & Leedy 2010). Four-part fractures in young patients are preferably treated with a locking plate but if stable fixation cannot be attained, humeral head replacement is indicated. A group of fractures remain, however, that are not amenable to this modality and require prosthetic replacement for adequate management.

Prosthetic replacement for proximal humeral fractures remains the treatment of choice for 4-part fracture dislocations, head-split fractures, and head impaction fractures of >40%. These fractures represent between 2 and 10% of proximal humeral fractures (Zuckerman & Sajadi 2007). It remains a good option in comminuted 3-part fractures especially in elderly patients with poor bone quality or a high degree of comminution (Bigliani 1990). Humeral head replacement is contraindicated in cases of active infection, severe nerve palsy to the deltoid and rotator cuff, and in patients unable to comply with the postoperative rehabilitation

program. In patients with known chronic large rotator cuff tears, the results of humeral head replacement for fracture are poor (Compito et al 1994) and this may be an indication for the use of a Reverse Total Shoulder Arthroplasty (RTSA). Indications and technical recommendations for the use of the RTSA in this setting are not clearly defined but this represents an area of exciting new research (Franke et al 2002, Wall & Walch 2007).

Prosthetic replacement for proximal humerus fractures is a challenging operation with variable results reported in the orthopaedic literature especially in terms of patient function (Robinson et al 2003). This procedure is performed uncommonly even by shoulder specialists. Anatomic landmarks are lost due to fracture of the tuberosities away from the humeral shaft making proper placement of prosthesis in terms of height and version a challenge. Tuberosities may be comminuted and the deforming pull of the rotator cuff tendons represents a challenge to fracture healing. Excellent results following humeral head replacement for fracture are associated with proper implant selection and insertion, anatomic tuberosity healing, and early rehabilitation to restore motion and strength³. Conversely, poor results are most commonly associated with tuberosity malunion or nonunion and improper humeral stem positioning (Bolileau et al 2002, Demirhan et al 2003, Esen et al 2009, Frankle et al 2001, Robinson et al 2003). Other important factors include the timing of surgery, patient age, tobacco and alcohol use, and female sex. Despite intensive study and improvements in patient selection, prosthetic design, and surgical technique, functional results remain variable. Wide variation in outcomes measurements also makes comparisons between studies difficult. Despite these limitations, hemiarthroplasty offers reliable pain relief and reasonable levels of patient satisfaction, but only modest functional results. Limited use with activities of daily living below shoulder level may be reliably obtained but overhead use is not typical following this surgery. Good to excellent results remain between 75-85% despite these challenges (Bigliani 1990, Goldman et al 1995, Green et al 1993, Kontakis et al 2008, Moeckel et al 1992, Robinson et al 2003, Tanner & Cofield 1983). High satisfaction rates seem to correlate more with pain relief than with range of motion or functional outcomes. Even studies with poor functional results report high patient satisfaction if pain relief is acceptable. Certainly, the more prepared the surgeon finds him or herself in the management of the patient with a severely displaced proximal humeral fracture, the better the chance of success. The purpose of this article is to review the preoperative evaluation, describe the surgical technique required for successful placement of the prosthesis and fixation of the tuberosities, and outline a safe postoperative rehabilitation program. We will review current results and complications associated with the technique of humeral head replacement and Reverse total shoulder arthroplasty for proximal humeral fractures.

2. Shoulder arthroplasty for proximal humerus fractures

2.1 Preoperative evaluation

Adequate preoperative evaluation is critical in the management of patients with displaced proximal humerus fractures. The surgeon must have a good working knowledge as to the mechanism of injury and level of energy associated as this will give an indication of possible neurovascular injuries. The surgeon should attempt to determine whether the injury represents a fracture or a fracture/dislocation and evaluation of all available radiographic studies is beneficial. Previous history of osteoporosis will give an indication as to the quality of bone available for fixation. Past history of rotator cuff disease is helpful as a large rotator

cuff tear will be associated with poor results with a humeral head replacement and may be an indication for reverse ball and socket prosthesis.

Physical examination may be limited in the acute fracture setting because of pain and swelling. The area of bruising is most commonly seen in the chest as well as the arm distal to the deltoid muscle. Bruising in the area of the deltoid itself is indicative of either direct trauma to this area or perforation of the deltoid by one of the fracture fragments. Neurovascular examination is typically limited because of pain and the status of the axillary nerve often cannot be determined prior to surgery. Distal pulses should be evaluated and compared to the contralateral side. Differences in distal pulses may be an indication for arteriogram. Displacement of the shaft medially in the area of the brachial plexus is also an indication to obtain an arteriogram prior to open reduction internal fixation. Range of motion testing is of no benefit in the acute fracture setting.

Radiographic examination should be limited to a trauma series which does not require the patient to move the arm. Three orthogonal views as described by Neer can adequately evaluate the fracture in the majority of cases (Neer 1990). (Figure 1) These include an AP view in the scapular plane, a transthoracic lateral view, and a Valpeau axillary view. All of these X-rays can be taken without removal of the arm from the sling. CT scan has been shown to improve the accuracy of fracture classification and is very beneficial in preoperative planning (Shrader et al 2005). (Figure 2)

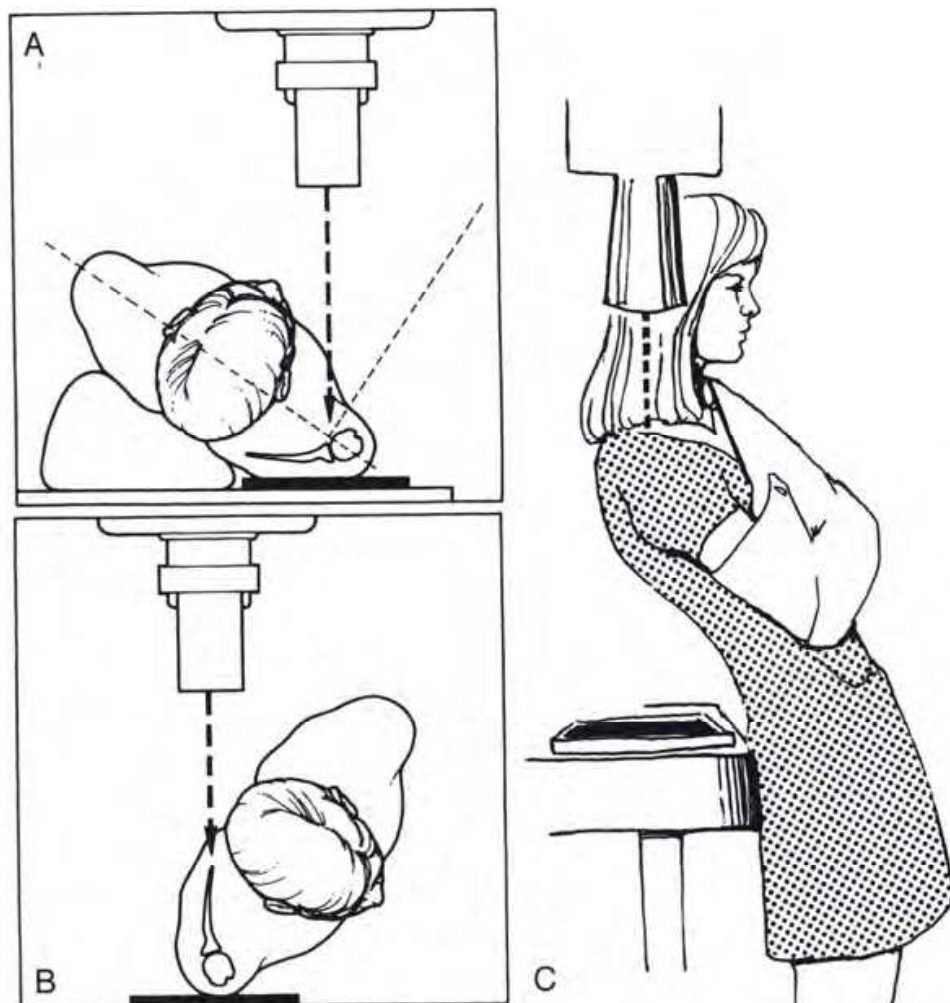


Fig. 1.

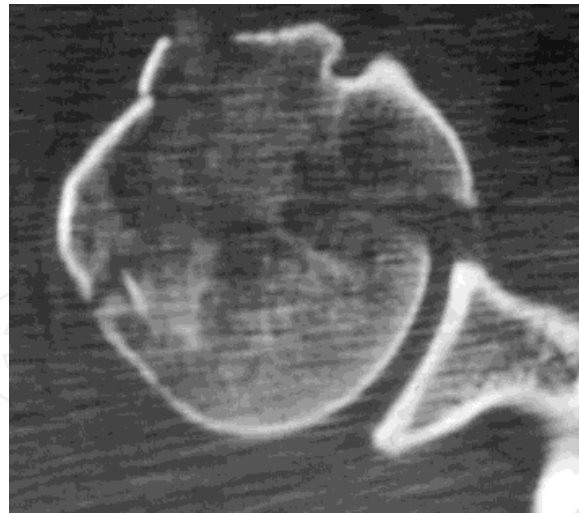


Fig. 2.

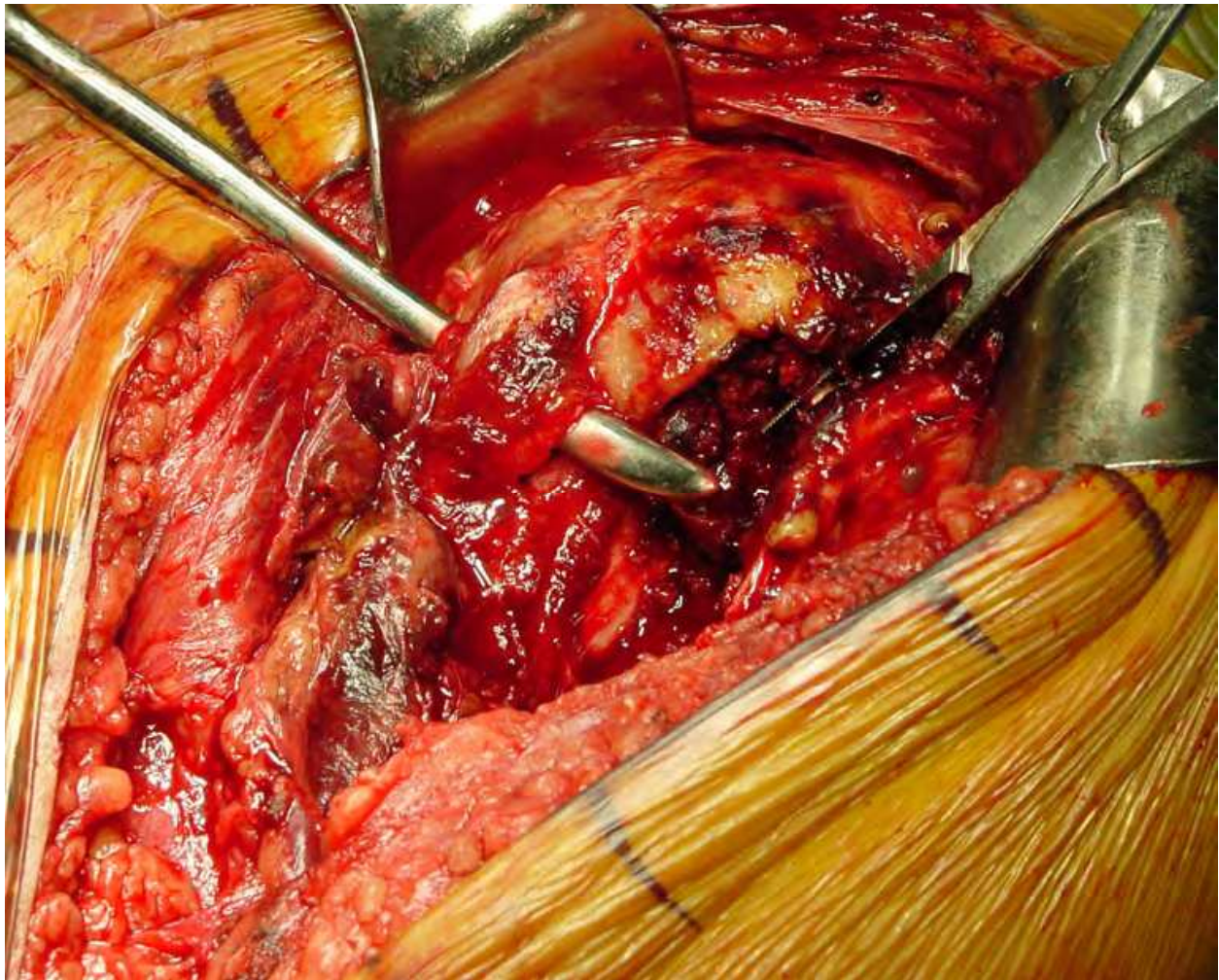


Fig. 3.

Arthroplasty for proximal humerus fractures is typically indicated for head split and head indentation fractures >40% fractures, displaced 4-part fractures of the proximal humerus,

and 4-part fracture/dislocations. In these cases, the proximal humerus does fracture in a very characteristic pattern. The fracture line between the greater and lesser tuberosity typically lies directly posterior to the bicipital groove so that the lesser tuberosity fracture typically also contains the bicipital groove and a small portion of the greater tuberosity. (Figure 3) The remainder of the greater tuberosity often fractures away from the shaft and lesser tuberosity with a characteristic "V" shaped pattern of bone leaving a distinctive defect in the proximal shaft which can be used in realigning the fracture fragments anatomically. (Figure 4) Variable amounts of head fragment may still be attached to a tuberosities. A small portion of the calcar typically stays attached to the humeral head fragment. (Figure 5)

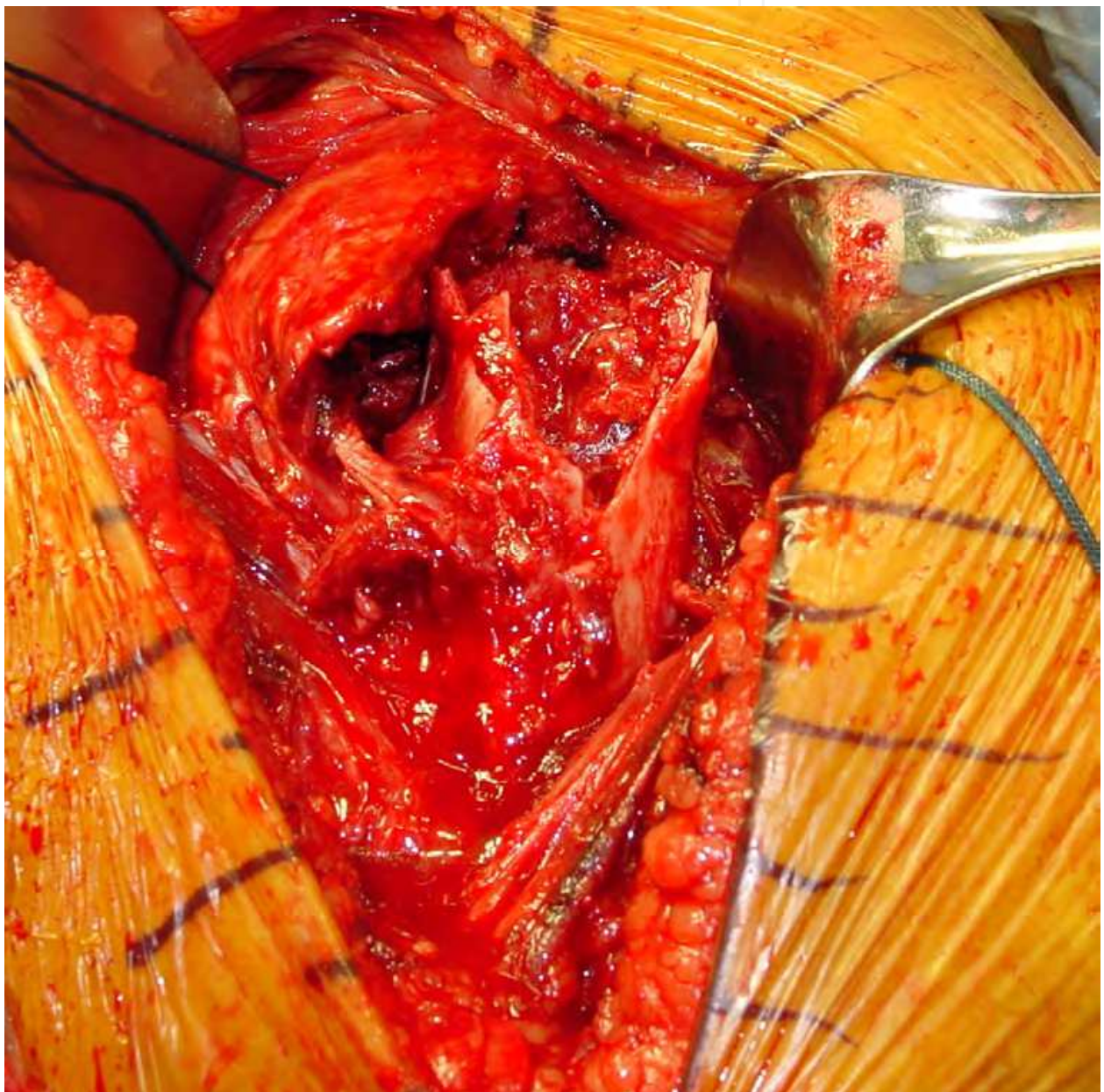


Fig. 4.

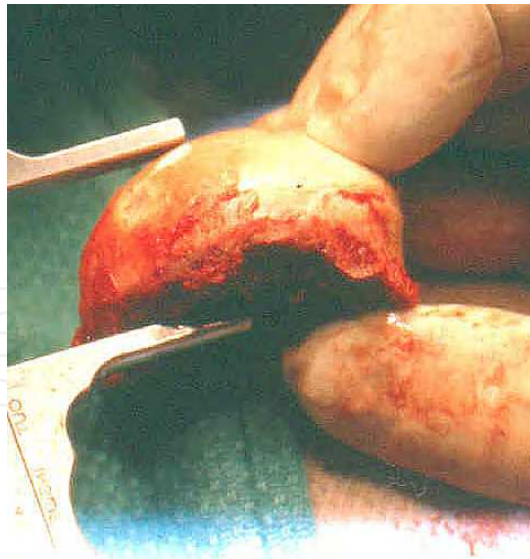

Fig. 5.

2.2 Operative technique

Key goals in prosthetic replacement for proximal humerus fractures include atraumatic exposure of the fracture site with protection of the deltoid origin and insertion while avoiding further devascularization of the fracture fragments, proper positioning of the prosthesis both in terms of height and version, and secure anatomic fixation of the tuberosities. The exact indications for the use of reverse prosthesis in the management of proximal humerus fractures is not well understood currently and is undergoing a period of development and research. Surgery is recommended within 7-10 days after the patient is cleared medically. Delay beyond this time makes dissection more challenging due to early fibrosis. Surgery must be followed by a safe physical therapy program which allows adequate healing of the tuberosities while avoiding excessive stiffness.

This surgery is typically performed under interscalene block anesthesia and general anesthesia. Relaxation during surgery decreases the pull of the pectoralis major and improves exposure. Interscalene block is contraindicated in the face of documented neurologic injury. This block results in excellent postoperative pain relief when indicated. The patient is placed in the beach chair position with the back of the table elevated approximately 30°. The patient is placed at the edge of the operating table with a bolster along the medial border of the scapula to stabilize this structure during surgery. Lateral placement of the arm allows extension off of the table for exposure and access to the humeral shaft. A well-padded neurosurgical head rest allows increased exposure and access to the superior shoulder and a short arm board supports the elbow without blocking access to the arm. All bony prominences are well-padded. A fluoroscan is utilized from above to allow evaluation of the fracture itself and tuberosity positioning. (Figure 6) Broad-spectrum antibiotics are routinely used. Surgical approach is planned to contribute minimal additional trauma to the soft tissues and vascular structures in the area of the proximal humerus. In situations in which the humeral head is displaced into the axilla in the area of the brachial plexus, caution must be exercised in its removal as this can result in hemorrhage. Assistance from a vascular surgeon may be required in such cases.

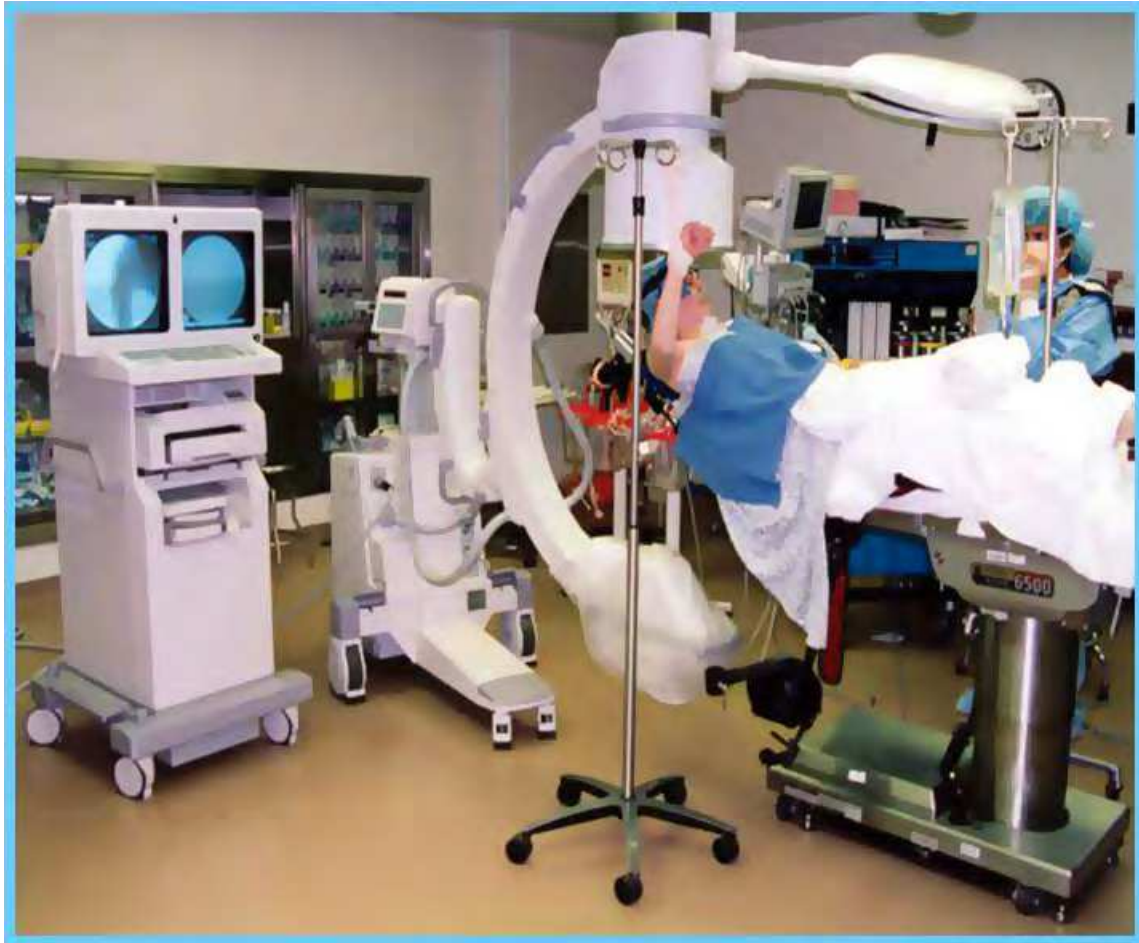

Fig. 6.

2.3 Surgical exposure

A deltopectoral incision is made beginning at the level superior to the coracoid and passing to a point directly anterior to the deltoid insertion. (Figure 7) The fat stripe over the cephalic vein is identified and carefully incised avoiding injury to the vein. With the edema encountered in acute fractures, blunt dissection can be carried through the deltopectoral interval dissecting the cephalic vein laterally with the deltoid down to the level of the fracture site itself. Fracture hematoma is evacuated and the anatomy of the fracture is now examined. The conjoint tendon is retracted medially and the deltoid is retracted laterally. The deltoid origin and insertion are preserved. Landmarks which assist in identification of critical structures include the coracoid which has been named “the lighthouse of the glenoid” and the biceps tendon which has been called “the highway to the glenoid”. The coracoacromial ligament is identified at the lateral edge of the coracoid and can be followed to the subacromial space. The base of the coracoid can be palpated and helps guide the surgeon to the glenoid. The biceps tendon can be identified in the pectoralis insertion on the humeral shaft and followed into the fracture site. The fracture line between the lesser and greater tuberosities is typically immediately posterior to this tendon. The axillary nerve must be identified and protected throughout the procedure. The nerve is palpated anteriorly along the inferior border of the subscapularis and laterally along the undersurface of the deltoid muscle. Continuity of this nerve can be verified using the Tug Test (Flatow & Bigliani 1992) and is reassuring that the nerve has not been lacerated by fracture fragments.

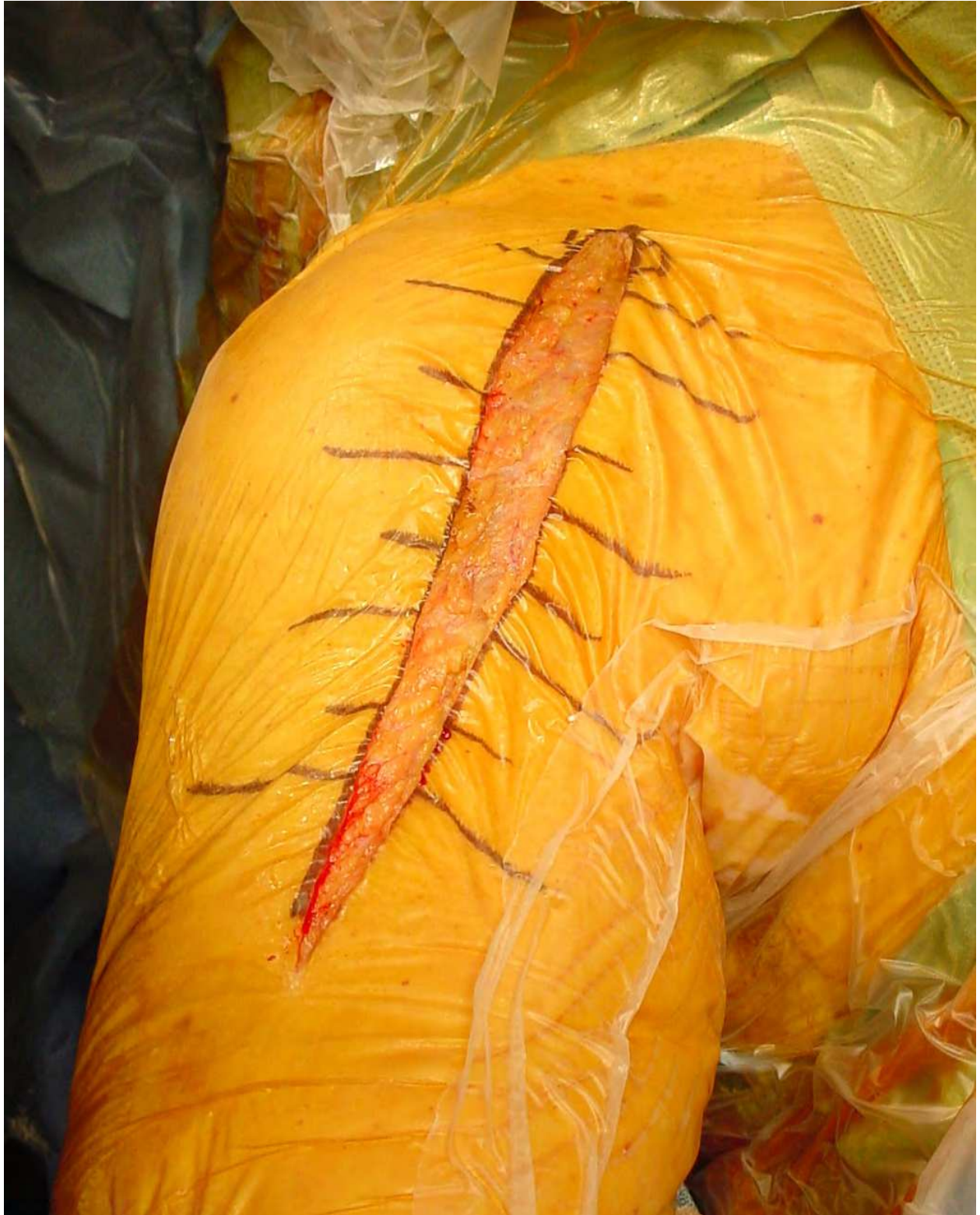

Fig. 7.

2.4 Control of fracture

The first step in controlling the 4-part proximal humerus fracture is to control the tuberosities. The lesser tuberosity is displaced medially by the pull of the subscapularis

while the greater tuberosity is displaced posterosuperiorly by the pull of the infraspinatus and teres minor muscles. Heavy nonabsorbable sutures are passed through the subscapularis tendon to control the lesser tuberosity and through the infraspinatus tendon to control the greater tuberosity. (Figure 8) A bone hook or clamp may be necessary to reduce the greater tuberosity so that a suture can be passed through the cuff tendon. Abduction of the humerus relaxes the deltoid and assists with exposure of the greater tuberosity. Sutures are not placed through the greater tuberosity itself as bone quality may be poor and this will lead to further comminution. The rotator cuff tendon is often stronger than the bone itself and should be utilized for both mobilization and later fixation. The fracture line between the tuberosities is followed up to the rotator cuff. The rotator cuff can then be split in line with its fibers in continuity with this fracture line. This will leave a small strip of supraspinatus tendon attached to the anterior fragment. This fragment includes the lesser tuberosity, bicipital groove, and a small portion of the greater tuberosity. Attached to it are the subscapularis tendon, the rotator interval, and a small strip of the

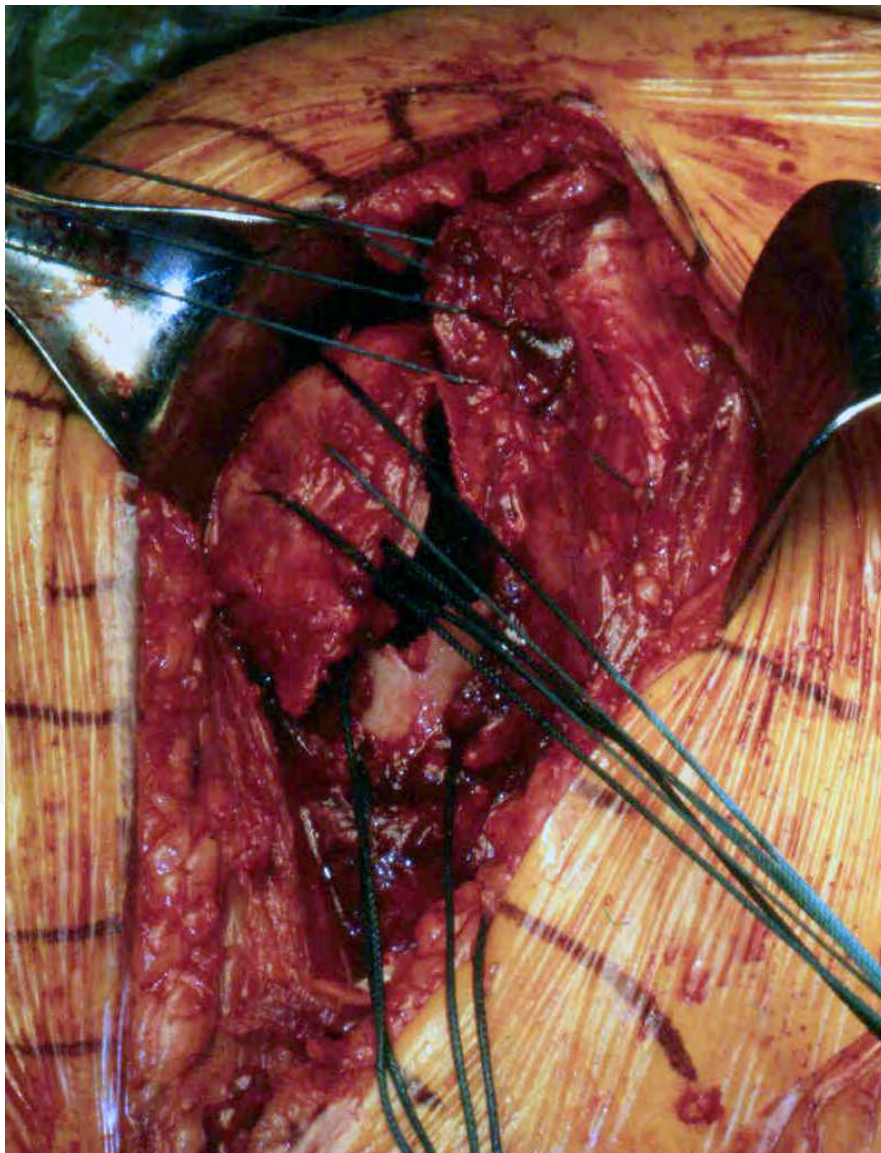


Fig. 8.

supraspinatus tendon. The remainder of the supraspinatus as well as the entire infraspinatus and teres minor tendons will be attached to the posterior fragment. Splitting the supraspinatus in line with its fibers to the level of the glenoid now allows exposure of the glenoid as well as the humeral head.

The humeral head is now removed and placed on the back table where it can be measured in terms of height and diameter. (Figure 9) Any missing fragments from the humeral head are typically still connected to the tuberosities and must be removed to allow adequate reduction of these tuberosities under the prosthetic humeral head. Removal of these portions of the humeral head is necessary but debulking of the tuberosity fragments is contraindicated as this may compromise tuberosity healing and positioning. The humeral head is also carefully inspected to determine the amount of calcar attached medially. The size of this fragment is indicative of the amount of missing shaft medially and will help determine the exact positioning of the prosthesis. The prosthetic humeral head should be positioned superior to the shaft a distance equal to the amount of the calcar bone left attached to the humeral head. Placement of the humeral head directly onto the humeral shaft ignoring the size of this calcar fragment will result in positioning of the head too low relative to the shaft. All cancellous bone in the humeral head can now be harvested and used for bone grafting of the tuberosities prior to fixation.

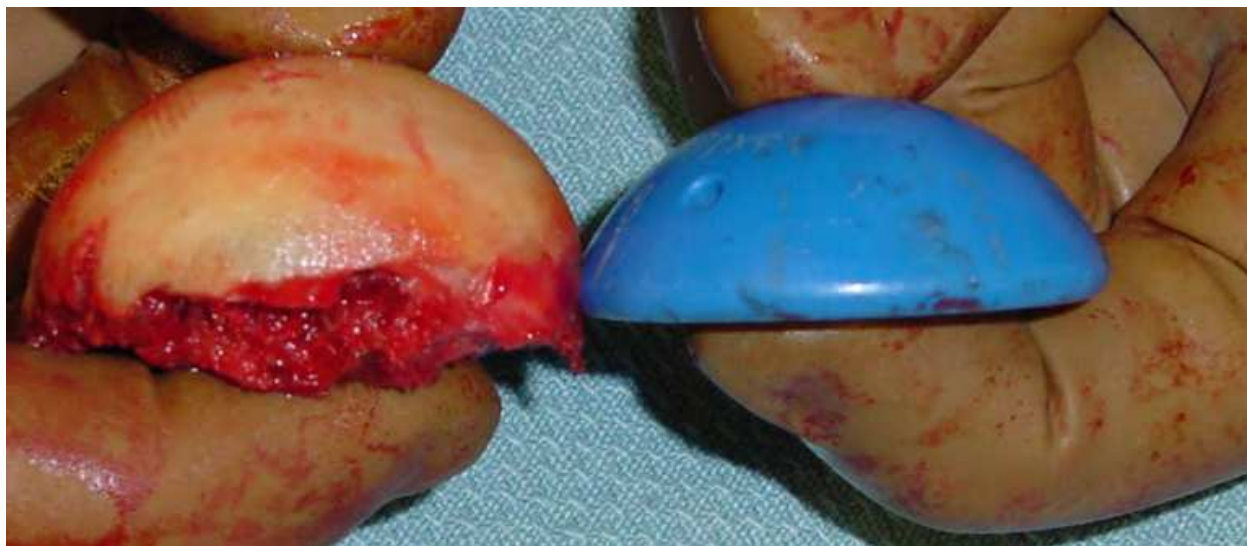

Fig. 9.

2.5 Prosthetic selection

Adequate prosthetic selection is determined by measuring the humeral head and canal. The proximal humeral shaft can be delivered into the operative site by extension, adduction and external rotation of the arm and placement of the elbow onto the short arm board. This allows access to the proximal humeral canal which can be measured with reamers. Minimal reaming is required. If there is no significant shaft comminution associated with the fracture, a standard length prosthetic stem on the order of 130 mm is adequate and a long stem prosthesis is not required. A prosthetic system which allows use of a narrow stem is preferred as this will allow room for bone grafting and tuberosity reduction and healing. Prostheses with a broad proximal collar often do not allow

enough room for tuberosity reduction without debulking and compromises the healing ability of these tuberosities. Ingrowth material on the proximal stem may be beneficial to tuberosity healing. The prosthetic stem must be narrow enough to allow adequate insertion into the humerus and avoid proud placement of the prosthesis. Prosthetic humeral head size is determined by measuring the patient's humeral head at the time of surgery both in terms of height and diameter. In prosthetic systems with an offset humeral head, placement of the maximum offset is recommended posteriorly or posterosuperiorly to allow placement of the greater tuberosity under the humeral head in this location. Appropriate head sizing will help reestablish anatomic tension on the rotator cuff tendons after tuberosity repair.

2.6 Prosthetic positioning

Adequate positioning of the prosthesis both in terms of height and version is critical towards the success of this procedure and in reestablishing relatively normal anatomy for the patient postoperatively. Distortion of the normal proximal humeral anatomy by displacement of the tuberosities represents a challenge for determination of proper stem and head height. This positioning is important to reestablish the normal resting length of the deltoid muscle. There are multiple options for determining adequate height for the prosthesis. The superior margin of the pectoralis insertion typically is 56 mm from the superior aspect of the greater tuberosity and is a fairly standard measurement in patients of varying sizes (Murachovsky et al 2006). This measurement will allow the surgeon to determine whether he is in the generally correct range for prosthetic height. As mentioned previously, the size of the fragment of calcar on the humeral head will indicate the height of the prosthetic head relative to the shaft. In cases in which the greater tuberosity does not have significant comminution, the greater tuberosity fragment can be interdigitated back in the "V" shaped defect just posterior to the bicipital groove. The humeral head must be placed just superior to the greater tuberosity in this location and by reducing the greater tuberosity to the shaft, the surgeon can determine proper head height. (Figure 10^a and 10^b) Tension on the biceps tendon has been recommended as a guide for the prosthetic height but is less exact. The biceps can be tenodesed at this time and removed from the joint. Finally, some prosthetic systems do allow preoperative templating relative to the contralateral arm with jigs which can be utilized for determining height. These systems are often unwieldy and difficult to use. Placement of the prosthesis too low will result in inferior subluxation of the humeral head relative to the glenoid and cause weakness in elevation. Proud placement of the prosthesis will lead to overstuffing of the joint, superior subluxation, pain, and stiffness. Anatomic version of the humeral head has been generally reported between 20 and 40° of retroversion. Placing the prosthesis in less retroversion places less tension on the greater tuberosity fragment during internal rotation and may benefit healing. Version of approximately 20° is recommended for this reason and can be determined relative to the patients' forearm. In prosthetic systems with a posterior fin of the prosthesis positioned 180° from the medial calcar portion of the stem, this posterior fin should generally be located just posterior to the bicipital groove. The humeral stem is generally cemented in place to avoid subsidence and malrotation because the stabilizing effect typically afforded by the tuberosities has been lost due to the fracture.

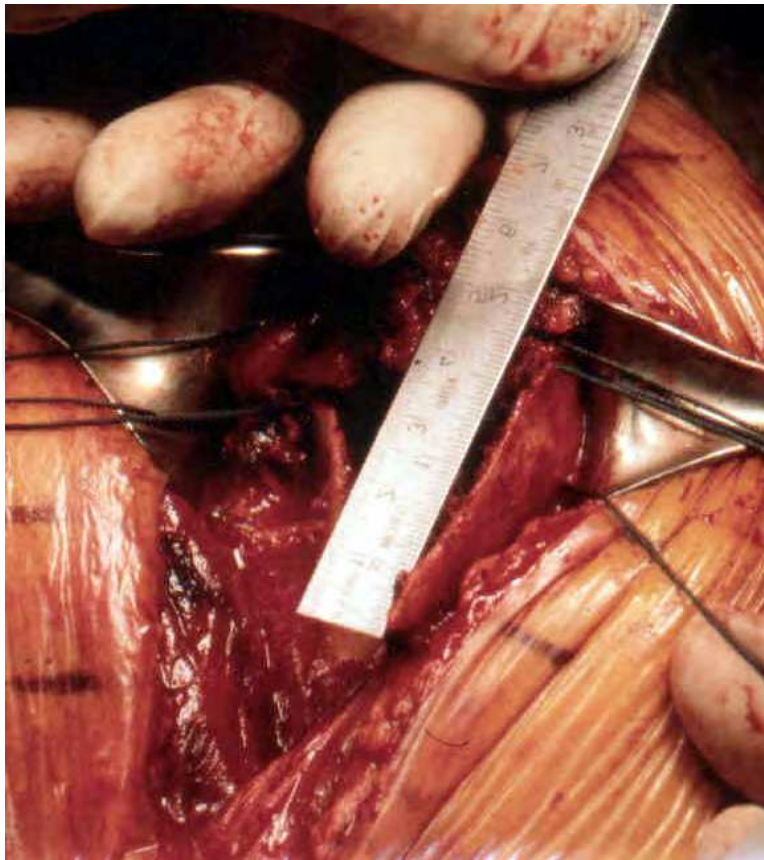


Fig. 10a.



Fig. 10b.

2.7 Tuberosity fixation

Postoperative function is most closely tied to anatomic healing of the tuberosities. The success of tuberosity healing is directly related to the adequacy of reduction and fixation of the tuberosities at the time of surgery. Tuberosity healing is a major challenge and greater tuberosity pull off remains the most common complication of this surgery (Boileau et al 2002). The tuberosities must heal to each other and to the shaft as well as to the ingrowth material of the humeral prosthesis. A variety of fixation techniques have been reported but techniques recommended by both Frankle and Boileau have demonstrated superior biomechanical resistance to deforming forces (Boileau et al 2000, Frankle et al 2002). The tuberosities are repaired utilizing a suture technique which fixes these tuberosities to each other, to the prosthesis, and to the shaft of the humerus. The placement of these sutures and drill holes for their placement is necessary prior to cementing the humeral stem in place. Drill holes in the shaft include the one drill hole anterior to the bicipital groove, two drill holes straddling the bicipital groove, and one drill hole posterior to the bicipital groove. (Figure 11) In cases in which the "V" shaped fragment of the greater tuberosity is of adequate size, small drill holes between this fragment and the humeral shaft just posterior to the bicipital groove can be utilized for a figure of 8 reduction suture. (Figure 12) This suture does not resist deforming forces but is used for anatomic reduction of the tuberosity. #5 polyester nonabsorbable sutures are placed through the anterior drill hole and through the posterior drill hole respectively. One #5 polyester suture is passed through the holes straddling the bicipital groove in such a way that both ends of this suture pass out from the canal with a small loop of suture inside the canal. While the cement for stem fixation is curing, morcelized bone graft is packed into the proximal canal just above the cement. (Figure 13) These small fragments are fixed to the cement while the cement is setting. This creates a bony surface for healing to the tuberosities. The greater tuberosity is repaired first. One or two cerclage sutures of #5 polyester suture are placed through the rotator cuff at the bone tendon junction and around the anterior stem of the prosthesis. The #5 polyester suture from the anterior drill hole in the shaft is then passed diagonally across the prosthesis and through the rotator cuff tendon at the bone-tendon interface to fix the greater tuberosity to the shaft and to resist vertically directed deforming forces against the tuberosity. (Figure 14) The greater tuberosity is fixed to the posterior aspect of the fin on the stem just inferior to the humeral head utilizing the cerclage sutures passed around the prosthesis. The bone graft is inserted between the prosthesis and the greater tuberosity to restore bulk to the tuberosity and to assist with healing. The posterior shaft suture is then passed diagonally across the prosthesis and passed through the subscapularis tendon at the bone-tendon junction. One to two cerclage sutures between the greater tuberosity and lesser tuberosity are then used to reduce the lesser tuberosity to the stem just underneath the humeral head anterior to the prosthetic fin. Again bone graft is used as needed and the cerclage sutures are tied. The suture from the posterior shaft to the lesser tuberosity is then tied. The rotator cuff split made previously during exposure is closed using nonabsorbable figure of 8 sutures. By making that split through the supraspinatus tendon, good tissue is available for repair anteriorly and posteriorly to help resist greater tuberosity pull-off. Finally, the two suture limbs at the bicipital groove distally are passed in a figure of 8 fashion over the rotator interval and rotator cuff split to firmly repair these to each other and to the shaft. (Figure 15) The stability and strength of the repair is then tested by taking the arm through gentle range

of motion. (Figure 16) Adequacy of reduction of the tuberosity fragments can be verified fluoroscopically. The continuity of the axillary nerve can be verified using the Tug test. Suction drains are placed deep to the deltoid and a layered closure is performed.

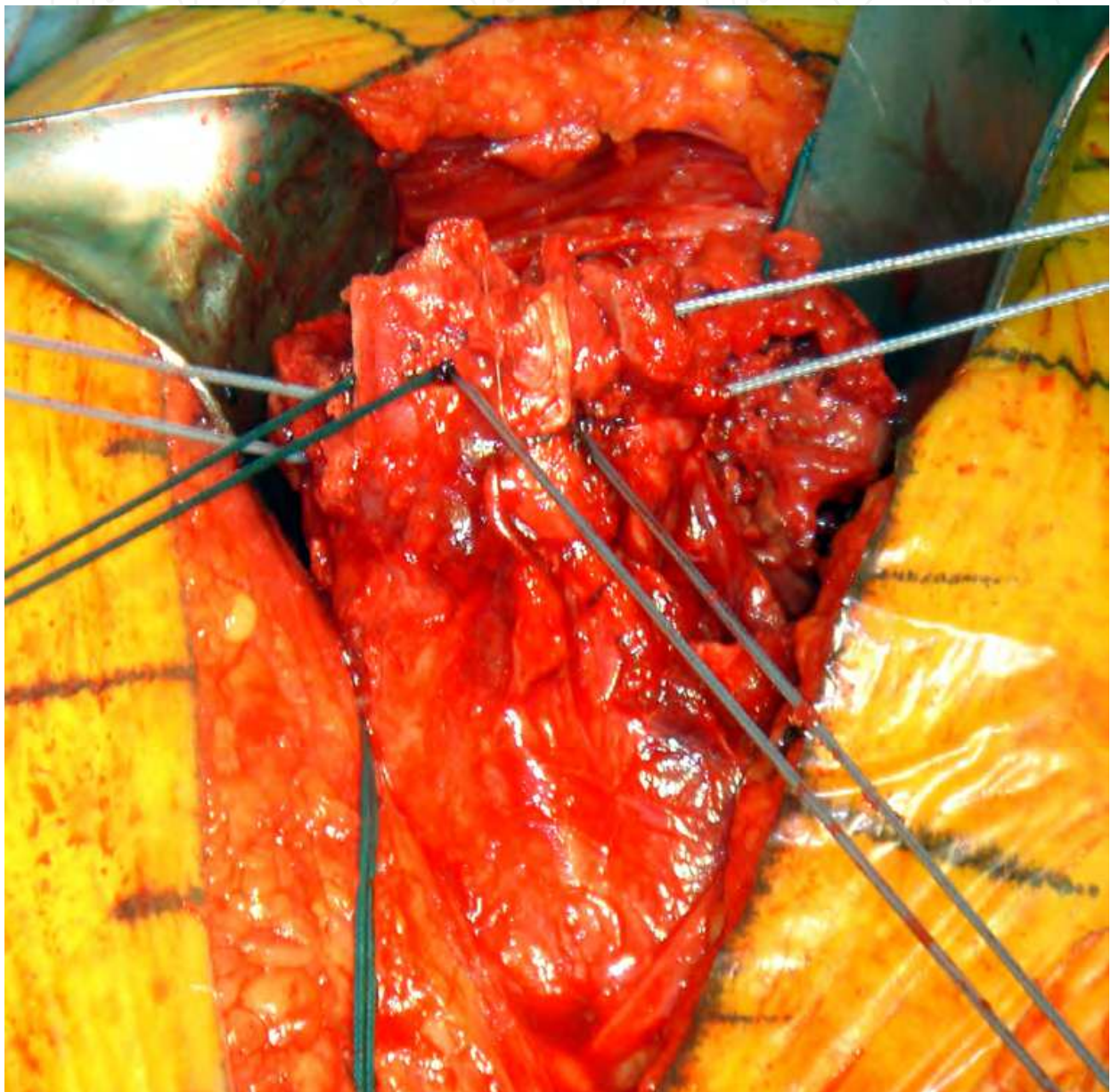


Fig. 11.

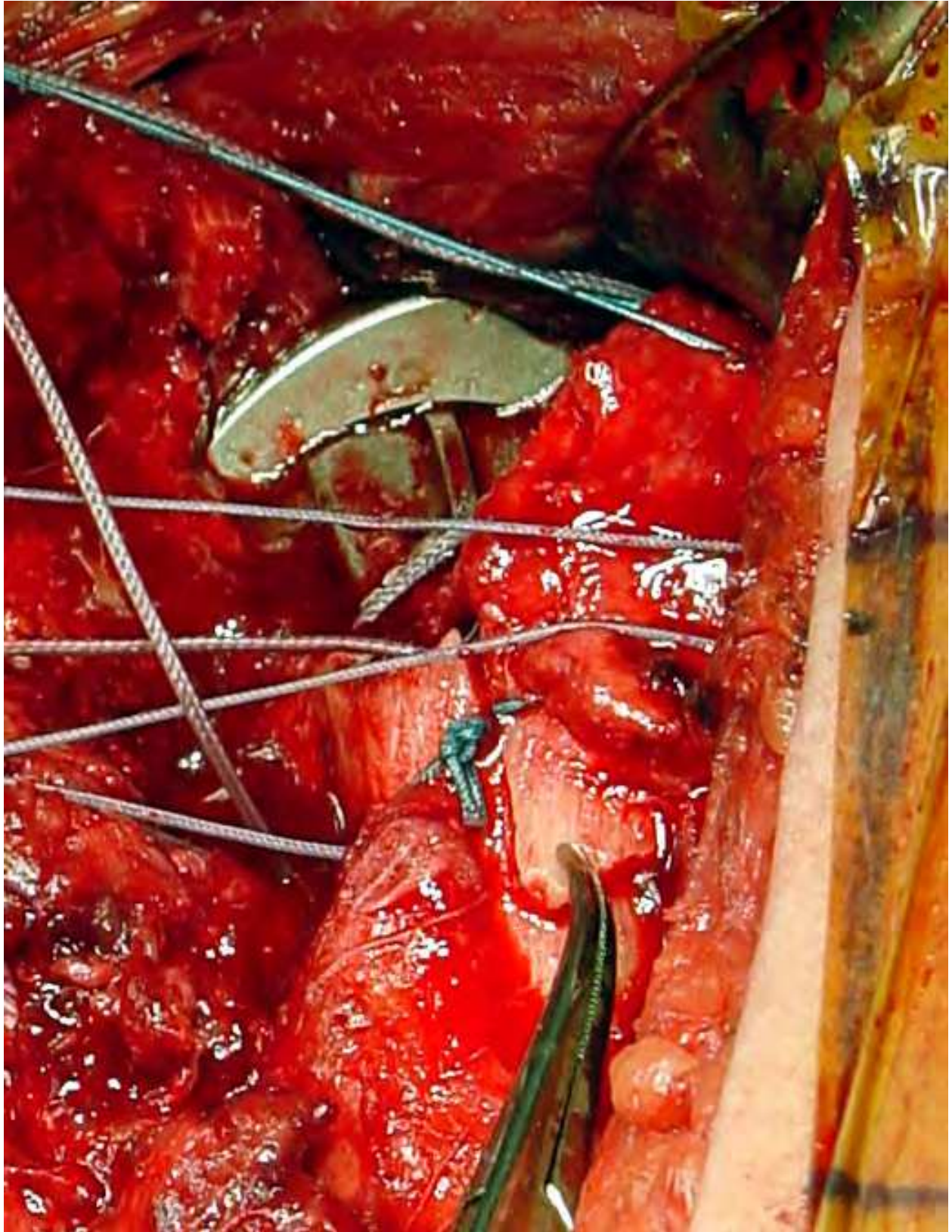


Fig. 12.

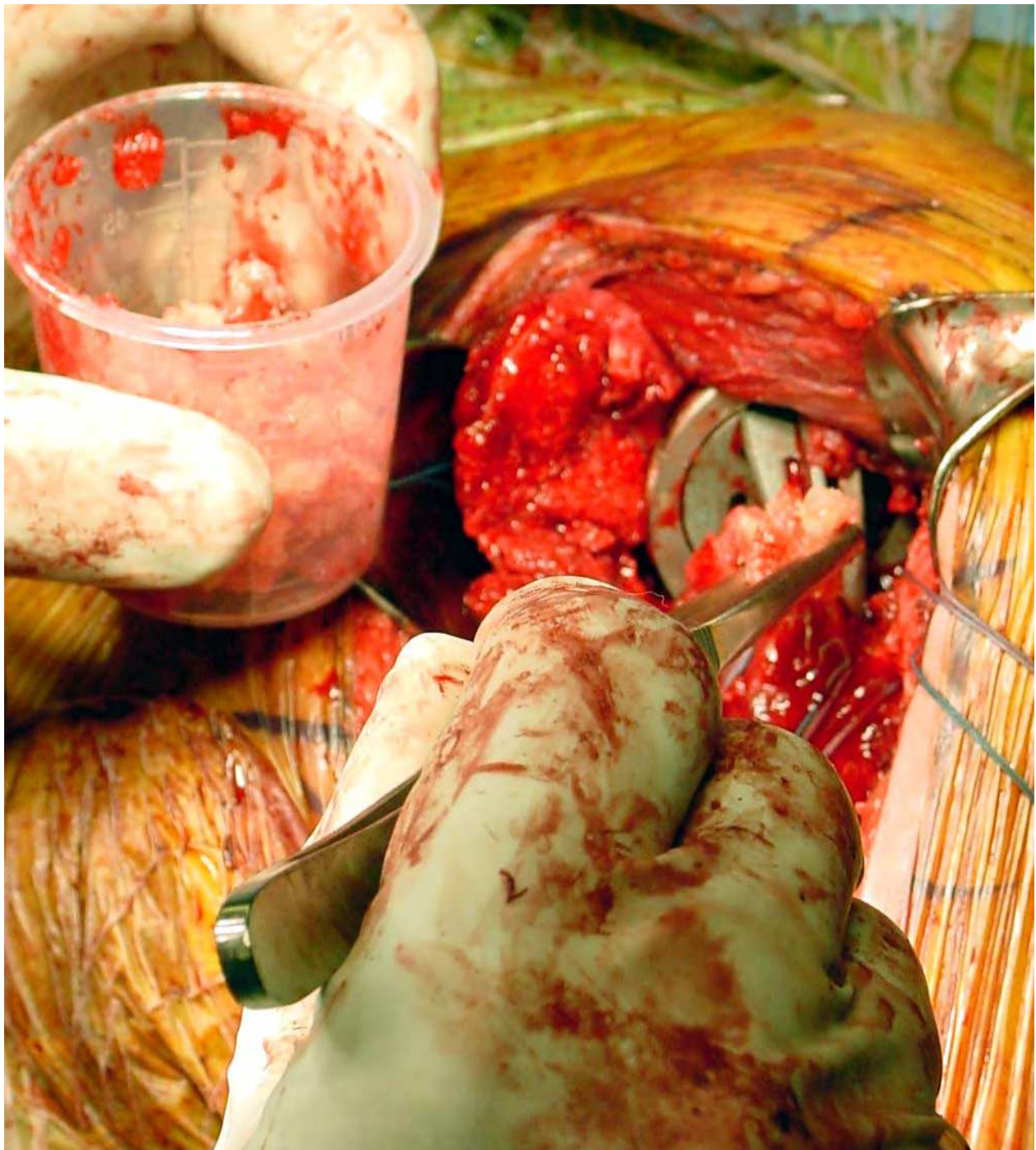

Fig. 13.

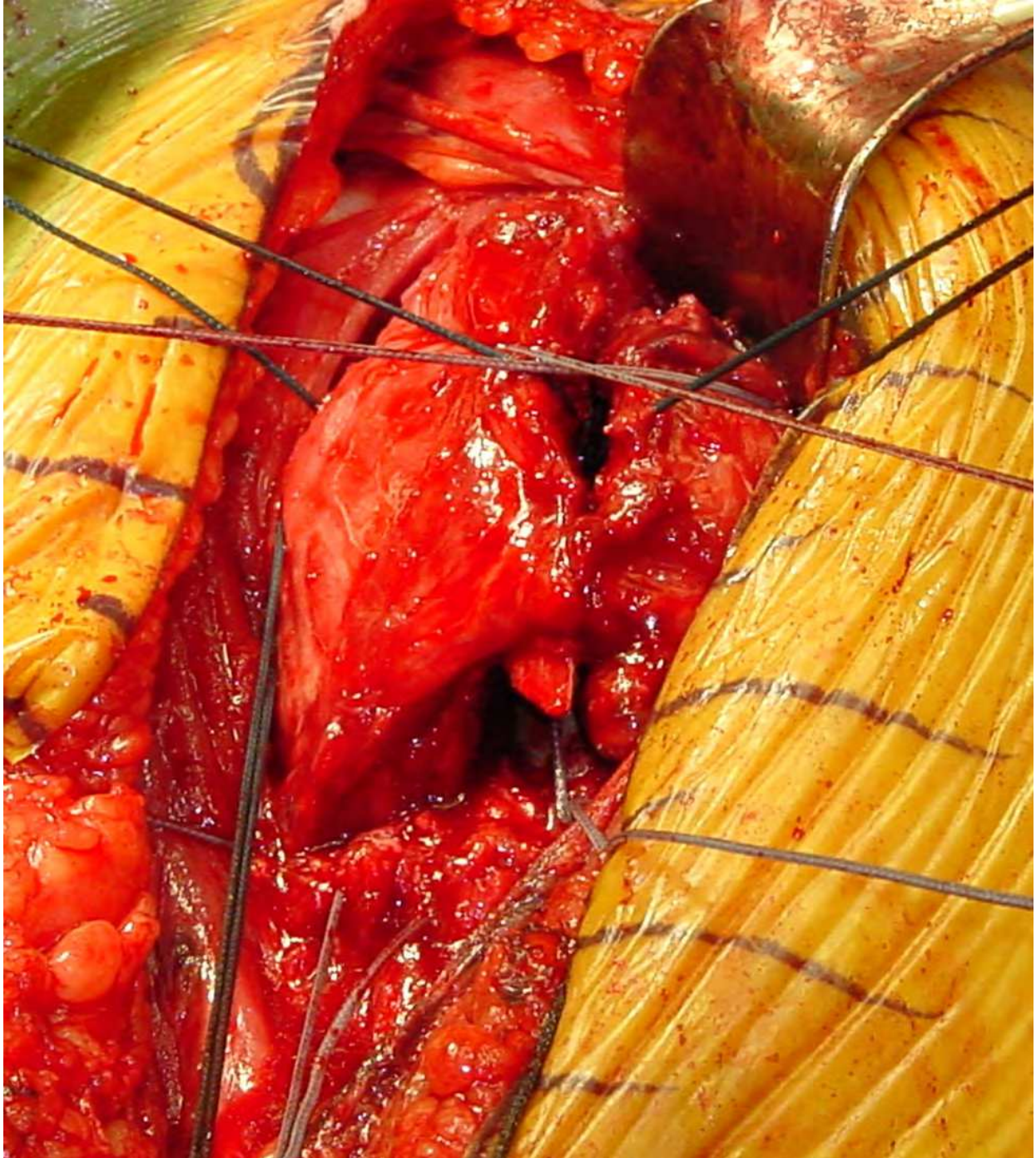


Fig. 14.

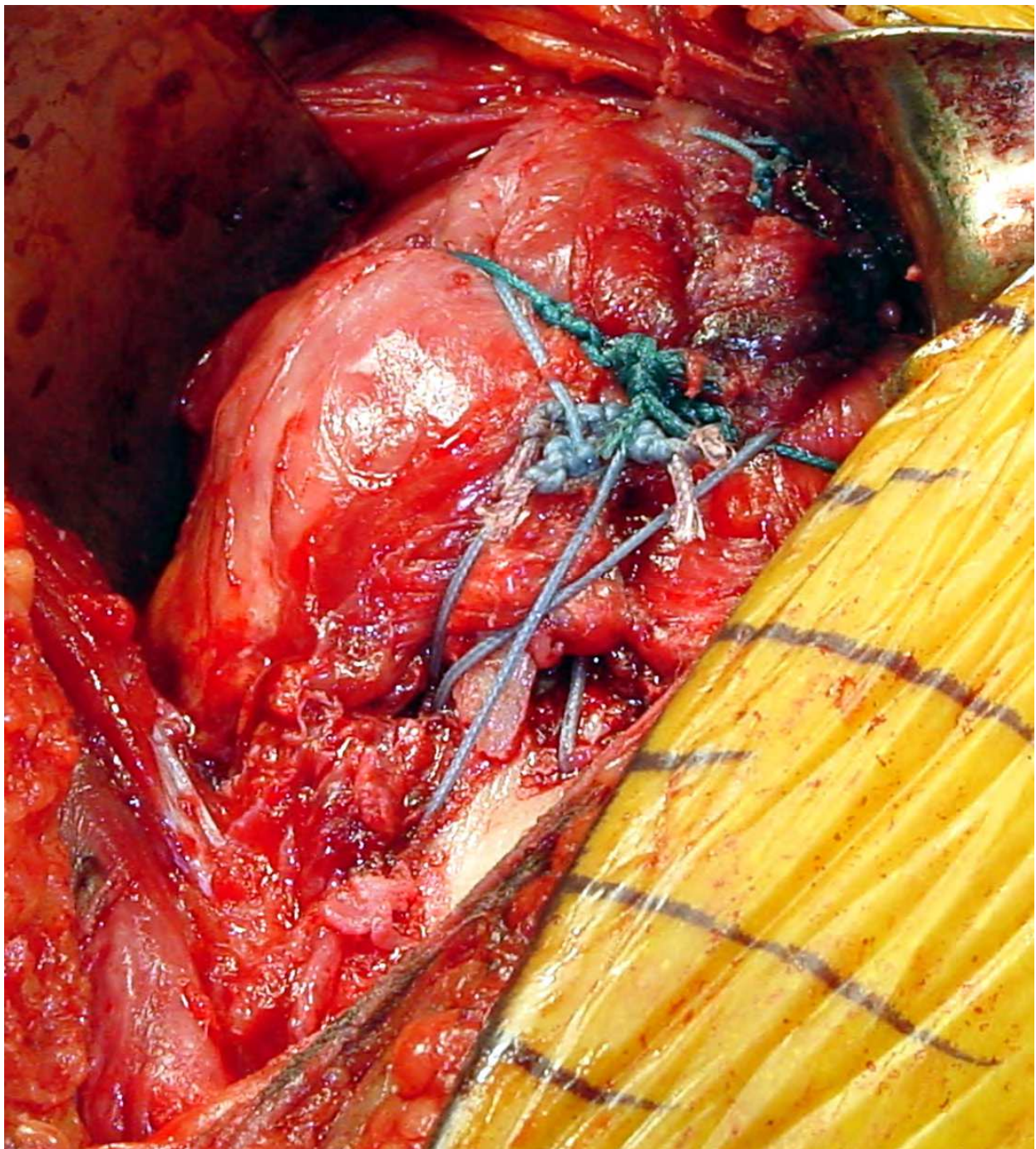


Fig. 15.

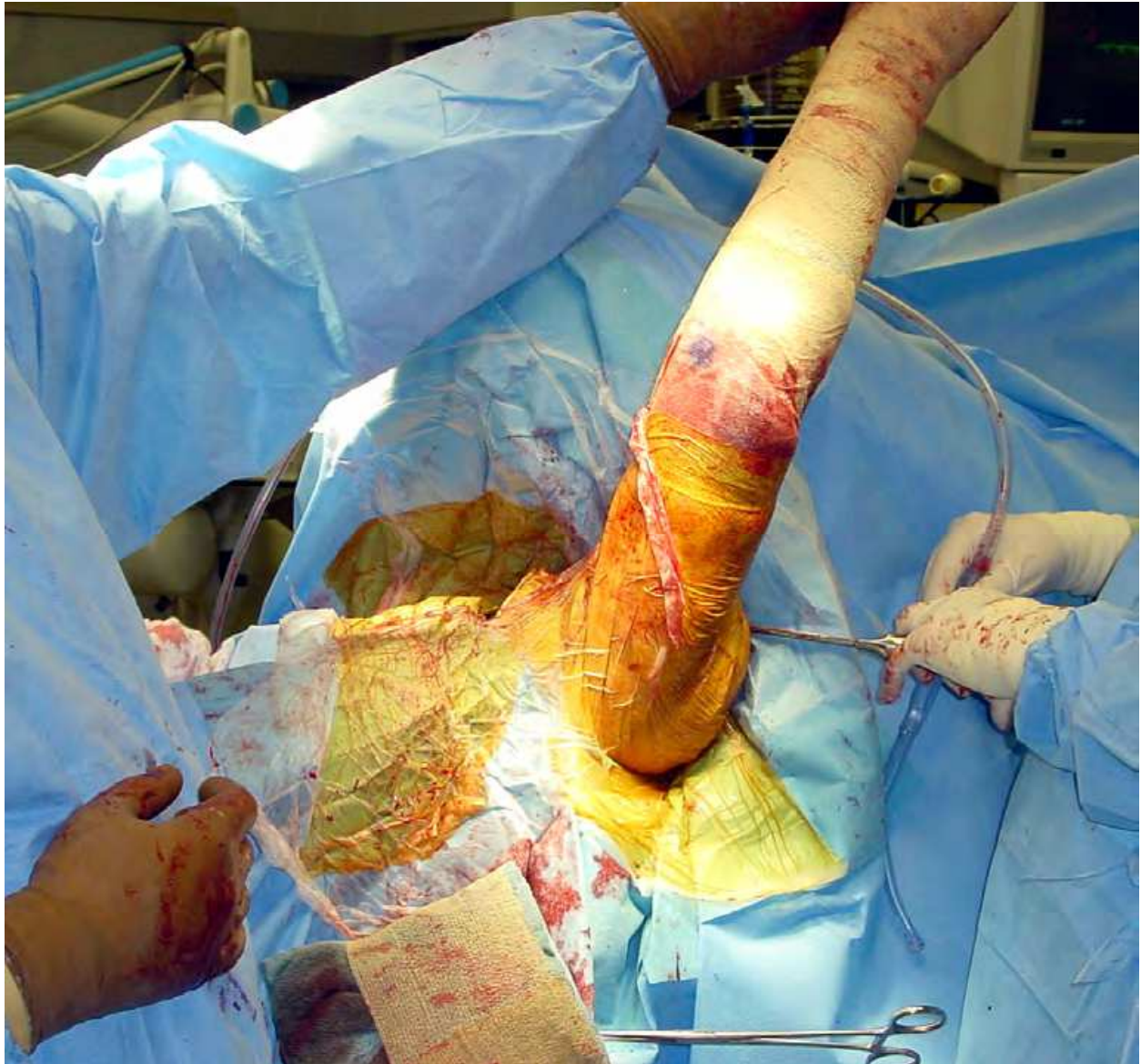

Fig. 16.

2.8 Reverse prosthesis for fracture

Indications for the use of the reverse total shoulder arthroplasty in the management of displaced proximal humerus fractures is in evolution. This prosthesis is generally not recommended in younger patients and its use has most often been reported in patients around the age of 70. It should be considered in cases with a relatively poor prognosis with use of the humeral head replacement including elderly patients (>75), patients with pre-existing large rotator cuff tears, and patients whose fracture care has been delayed. These patients are at particular risk for poor tuberosity healing (Boileau et al 2002). Use has been spurred by variability in functional results of the humeral head replacement in

the management of these complex fractures. The technique of reverse prosthesis in this situation is relatively straightforward (Wall & Walch 2007). The dissection up to removal of the humeral head is identical to that described previously for standard humeral head replacement. The deltopectoral approach is preferred over the superior approach for this indication as it permits easier rehabilitation and allows the surgeon to address any distal humeral shaft comminution that may be present. The exposure of the glenoid is easier than usual as the tuberosities are displaced away from the shaft and the glenoid can be clearly visualized at the time of surgery. The capsule and labrum are released from the glenoid to allow clear exposure of the glenoid rim. The glenoid is reamed according to the specifications of the particular prosthesis. The glenoid baseplate is placed slightly inferiorly and inclined caudally to help avoid notching of the lateral scapular border. Standard placement of the glenosphere is indicated. Humeral stem placement is dictated by soft tissue tension as in standard cases. Minimal or no pistoning of the stem relative to glenosphere should be present with adequate tension across the deltoid. Tension on the tuberosities will also influence the determination of stem height. Version is generally recommended at 0-20° of retroversion but can be altered to allow for optimal tuberosity reduction. In cases in which the supraspinatus is still attached to the greater tuberosity, the tendon insertion may require release in order to mobilize the tuberosity distally enough to reach the shaft and prosthesis. Similar suture fixation is recommended with cerclage sutures between the tuberosities and the prosthesis as well as the vertically aligned sutures diagonally between the shaft and the greater and lesser tuberosities. (Figure 17^a and 17^b) Prostheses with proximal ingrowth may help tuberosity union. Tuberosity repair should decrease incidence of prosthetic instability and allow improved external rotation postoperatively. Currently limited information as to the benefits of tuberosity healing is available in this setting (Bufquin et al 2007). Following tuberosity fixation with either the reverse prosthesis or standard humeral head replacement, suction drainage is indicated to avoid hematoma formation. The deltopectoral interval is closed and the skin is closed in a layered fashion.

Postoperative rehabilitation is geared toward allowing adequate tuberosity healing while helping the patient to regain flexibility in a reasonable and safe fashion. During the first six weeks following surgery the tuberosities are vulnerable to avulsion from active use or extreme range of motion with passive stretching. A protective ultrasling is indicated for the first six weeks following surgery holding the arm in neutral rotation to limit tension on the greater tuberosity fragment. The patient is allowed to perform gentle pendulum exercises with passive external rotation exercises utilizing a stick. Range of motion exercises of the elbow, wrist, and fingers are encouraged with gentle active use of these joints.

Once tuberosity healing can be verified radiographically, active use of the arm can be instituted. This typically occurs at approximately six weeks following surgery. Active-assisted exercises are begun in the supine position along with passive stretching under the supervision of a physical therapist. Light activities of daily living are allowed with the elbow at the side with progression of this as active function increases. Between weeks 6 and 12, exercises are characterized by gentle stretching with isometric strengthening for muscle reeducation. Beginning at 12 weeks, a resistive exercise program can be started below shoulder level with advancement to above shoulder exercises once the patient's strength increases.

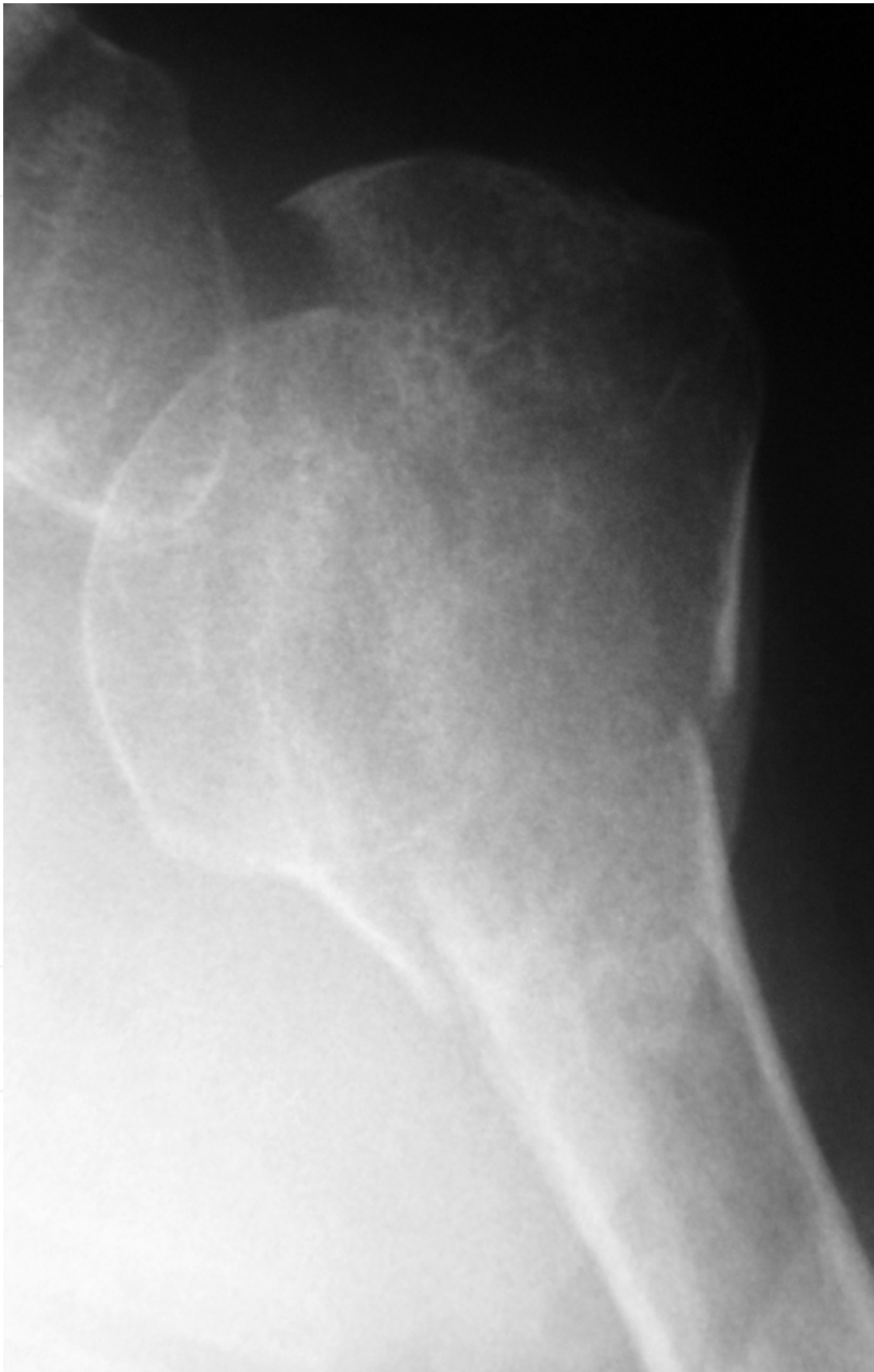

Fig. 17a.

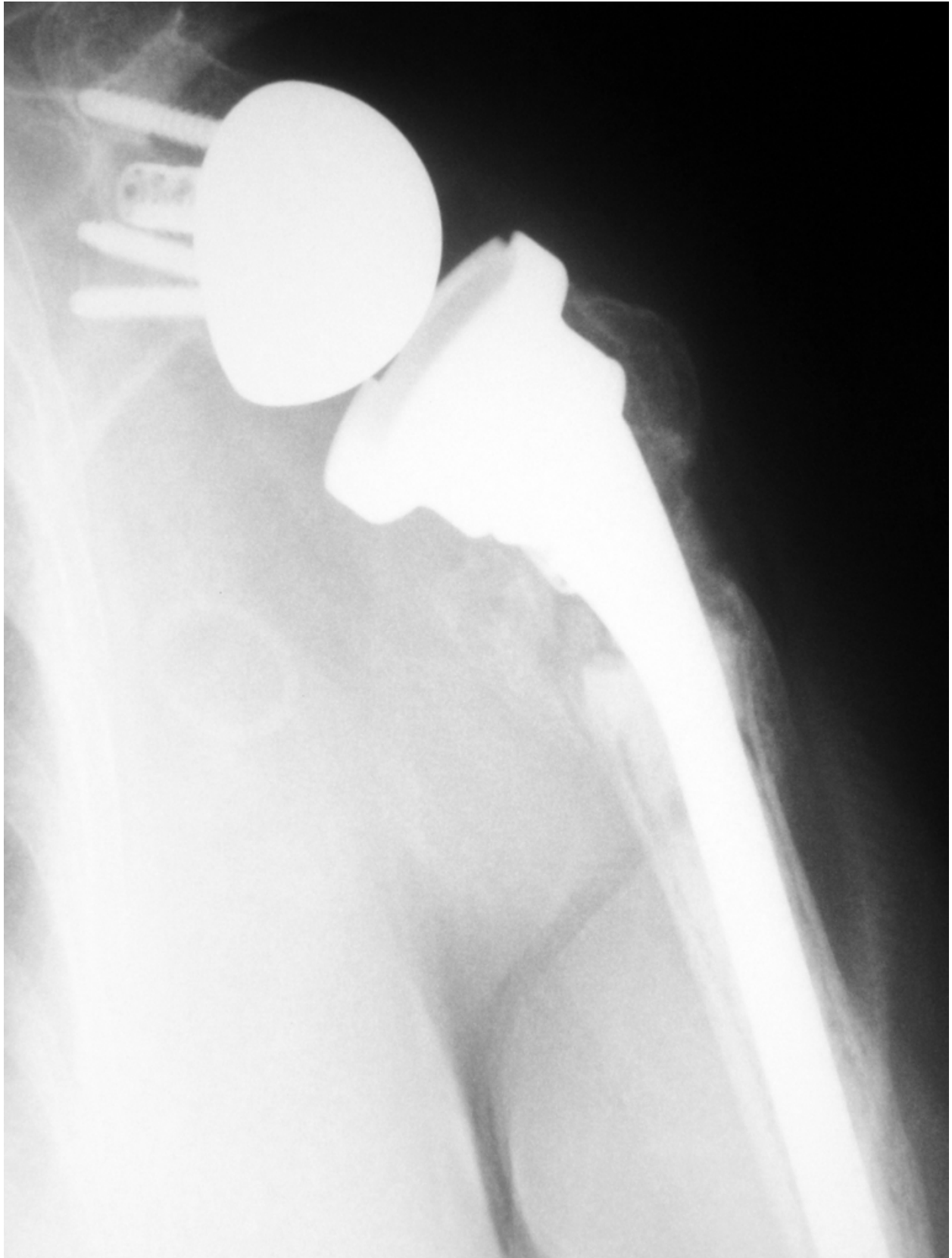


Fig. 17b.

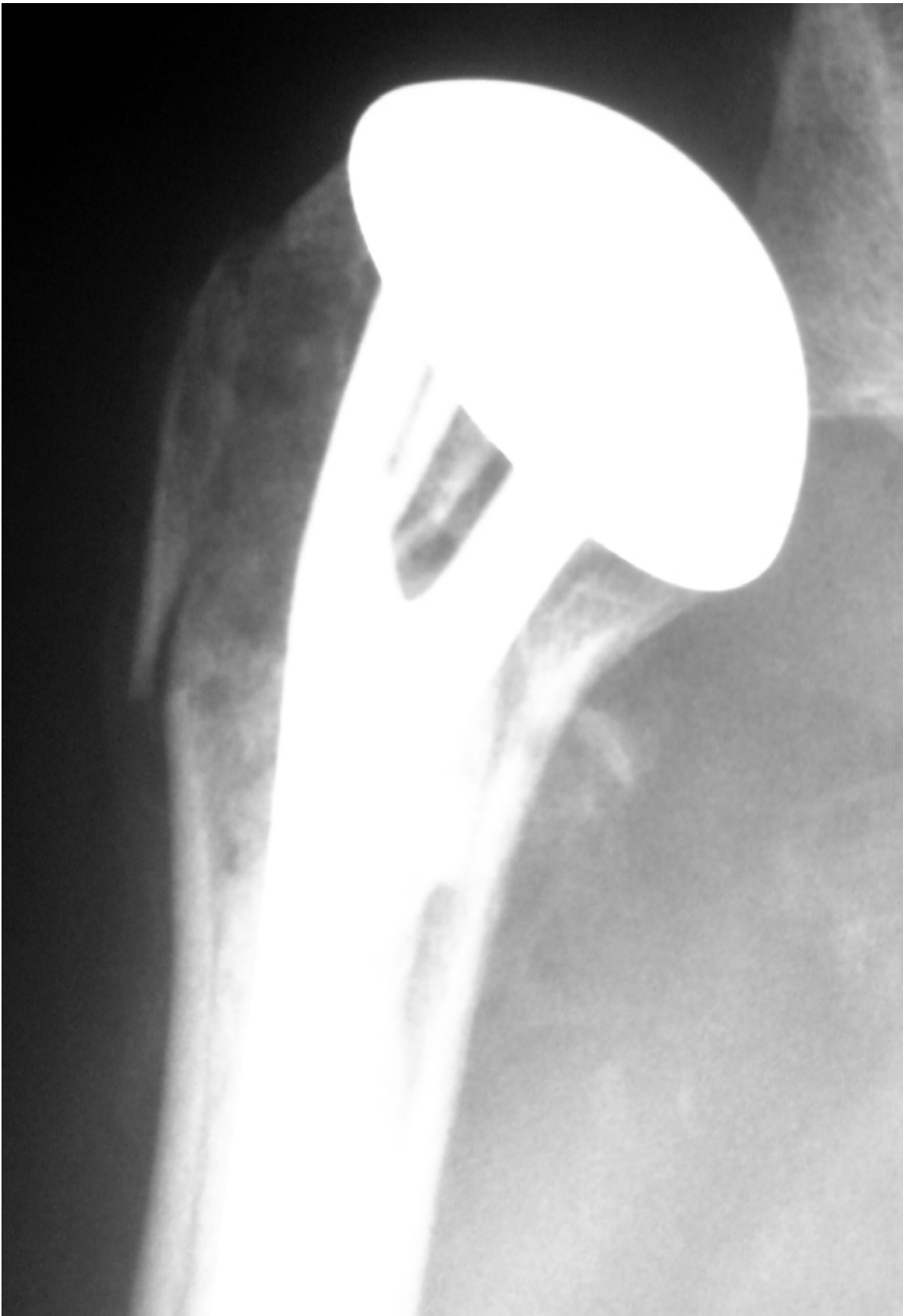

Fig. 18.

3. Results

Complex displaced three and four-part fractures, fracture-dislocations, and fractures with a humeral head split are at risk for the development of malunion and osteonecrosis, especially after internal fixation. Shoulder hemiarthroplasty or, recently, reverse total shoulder arthroplasty is indicated for the treatment of some of these complex fractures (Voos et al 2010).

In spite of advanced patient age, tuberosity healing can be achieved by reattachment and bone grafting around specific Reverse Fracture prosthesis, according to Boileau et al. Successful peri-prosthetic tuberosity healing is associated with restoration of both active elevation and external rotation (Boileau et al 2010). (Figure 18)

3.1 Pain relief

Pain relief is the most predictable outcome following hemiarthroplasty for four-part proximal humerus fractures. Many authors have supported this finding, with 61% to 97% of patients reporting complete pain relief. Significant residual pain generally tends to be associated with moderate activity; minimal pain occurs at rest. Even when motion and functional results are limited, pain relief is reported to be consistent (Young et al 2010).

3.2 Patient satisfaction

Reports of patient satisfaction vary widely, from 58% to 92%, in part because of the numerous scales used to measure outcome and satisfaction. High satisfaction rates seem to correlate more with pain relief than with range of motion or functional outcomes. Even studies with poor functional results report high patient satisfaction if pain relief is acceptable (Young et al 2010).

3.3 Prognostic factors

Patient age has been shown to be predictive of outcome. Younger patients have improved results, gaining more range of motion and a higher level of functional return. These improved results are attributed, in part, to motivation and compliance with postoperative rehabilitation and a more structurally intact rotator cuff.

Another prognostic factor is the delay between injury and surgery. A long delay between the time of injury and surgery has been shown to result in poorer postoperative range of motion and decreased functional outcomes. Although the time frames vary across studies, surgery within 1 week of injury seems to be associated with improved outcomes.

Other preoperative factors that correlate with a poor result are preoperative neurologic deficit, a history of cigarette smoking, excessive alcohol consumption, and female sex. Poorer results associated with the latter are somewhat controversial because in the studies that identified this finding, women were significantly older than men, which is a significant confounding variable.

Tuberosity position and healing may be the most important factors in determining outcome. Greater tuberosity malunion is the most common complication associated with hemiarthroplasty for four-part proximal humerus fractures. Final tuberosity position of more than 5 mm above or more than 10 mm below the prosthetic head is associated with poor results. A final position of more than 2 cm below the prosthetic humeral head also

has been associated with a poor functional result. The best range of motion has been reported to occur if the tuberosity is between 10 and 16 mm below the humeral head. Although these results differ somewhat, a nonanatomic final position of the tuberosity generally is believed to interfere with rotator cuff function and compromise range of motion and function. Lesser tuberosity malunion has received much less attention as a factor affecting outcome and does not appear to be as significant as greater tuberosity position (Zuckerman & Sajadi 2007).

Studying the clinical and radiologic parameters that can explain unsatisfactory results, final tuberosity malposition correlates with unsatisfactory results as well as superior migration of the prosthesis, poor position of the greater tuberosity and women over age 75 years (likely with osteopenic bone) (Boileau et al 2002).

At least five compelling reasons exist to reattach the tuberosities and obtain bone healing when performing a reverse shoulder prosthesis: 1) humeral length is restored and thus the deltoid is tensioned optimally; 2) joint stability is improved as a function of the restored humeral length and reconstructed anterior and posterior soft tissue walls; 3) the risk of infection is reduced as the subacromial dead-space is minimised and the surrounding soft-tissues are better vascularised. 4) better primary implant stability reduces the probability of humeral implant loosening and 5) active (specifically external) rotation is restored, crucial for activities of daily living in elderly patients (Boileau et al 2010).

3.4 Avoiding pitfalls and complications

Complications following hemiarthroplasty for acute proximal humerus fractures include infection, neurologic injury, preprosthetic fracture, instability, tuberosity malunion and nonunion, rotator cuff tear, heterotopic ossification, glenoid erosion, and stiffness. Although the incidence of any specific complication is relatively low, the cumulative incidence represents at least 15%.

The incidence of infection and wound healing problems is about 4% and includes acute postoperative infections and subacute delayed presentations within 6 months of the procedure. Factors that increase the risk of infection include the need for a second operation performed within a short period of time and a compromise immune system. Preventing infection requires meticulous attention to surgical preparation and draping, particularly because of the potential contamination from the axilla. Perioperative antibiotics are indicated. Meticulous handling of soft tissues also is important. The fact that these injuries occur more commonly in elderly patients whose tissues are more sensitive to injury and surgery further emphasizes its importance. If wound problems develop early in the postoperative course, treatment should be aggressive, including additional antibiotics and surgical debridement, if necessary (Young et al 2010).

Instability following hemiarthroplasty also can be a significant problem. The definition of instability varies widely, which affects the reported incidence of this problem. Several factors predispose patients to the development of instability, including component malposition, rotator cuff compromise, and tuberosity problems. Of these, component malposition is a critically important predisposing factor. Instability may result if the humeral component is placed too high or too low, resulting in secondary impingement or poor soft-tissue tension, respectively. Improper placement of the component in excessive anteversion or retroversion may lead to dislocation and tuberosity failure (Voos et al 2010).

If the component is placed in an incorrect amount of version or if humeral length is not properly restored, the risk of instability is greater. Careful attention to positioning the component intraoperatively and managing that position during cementing is essential. Inserting the component in proper version requires the use of consistent landmarks. Obtaining proper version and length during cementing can be difficult; therefore, we find the use of intraoperative fracture jigs to be beneficial. Component malposition can be prevented if a reliable method to obtain and maintain malposition during insertion is used. We believe that cemented fixation of these components is mandatory to maintain position, particularly in the absence of metaphyseal bony support (Young et al 2010).

The so-called “unhappy triad,” involves prosthesis with excessive height and retroversion and the greater tuberosity is positioned too low. This combination was frequently associated with poor functional results and persistent pain and stiffness. Studies have also demonstrated that acute reconstruction (less than four weeks after the injury) results in better functional outcomes because of the ease of tuberosity reconstruction (Boileau et al 2000).

Rotator cuff compromise also causes instability and usually develops as a result of tuberosity compromise. Preventing this problem requires secure fixation and proper positioning of the tuberosity. If the tuberosity becomes detached, particularly in the early postoperative period, instability often can result. Detachment of the lesser tuberosity compromises anterior support and can result in anterior instability (Young et al 2010).

Detachment of the greater tuberosity can result in significant superior and anterior instability. Although posterior instability can occur, it is less common. Factors that predispose patients to tuberosity detachment are inadequate tuberosity fixation and noncompliance with the postoperative rehabilitation. Secure tuberosity fixation and reattachment using the principles (transverse, longitudinal, and cerclage fixation) will decrease the risk of fixation failure. A supervised, structured rehabilitation program also can limit the potential for patient noncompliance. The treatment of instability following tuberosity failure can be difficult. If detachment is identified early, reattachment should be considered. Tuberosity detachment identified more than 6 months after surgery is more problematic. Mobilization and attachment of tuberosities can be quite difficult at this time. If the patient reports significant pain and demonstrates instability, the revision surgery, possibly to a reverse shoulder arthroplasty, may be necessary.

Tuberosity nonunion is another significant complication following hemiarthroplasty. The factors that predispose patients to nonunion are related to the method of reattachment, particularly the ability to obtain proper reduction and secure fixation. The quality of bone and soft tissue also affect fixation. The significance of tuberosity nonunion can vary, but generally relates to the degree of migration and displacement. Limited amounts of migration and displacement frequently result in weakness and limited motion but not instability. With significant displacement, the patient will demonstrate weakness and limited motion, as well as instability and pain. The best approach to prevent tuberosity nonunion is use of an optimal method of reattachment.

Malunion of the greater or lesser tuberosity can occur, although probably with less frequency than nonunion. Malunion usually occurs as a result of either inadequate reduction at the time of surgery or inadequate fixation, which allows migration of the fragment with healing into a malunited position. Thus, proper positioning of the tuberosity

intraoperatively is mandatory to avoid these problems. If necessary, intraoperative radiographs should be obtained to confirm the position. Radiographs also should be obtained early in the postoperative period to ensure that migration has not occurred. Malunion of the greater tuberosity is a much more significant problem than that of the lesser tuberosity. Posterior or superior displacement of the greater tuberosity restricts motion and can be a source of pain. Treatment of tuberosity malunion depends on functional significance. If significant pain and limited motion can be attributed to tuberosity malunion, surgical management consisting of osteotomy, mobilization, and reattachment to a more anatomic position can be considered. If the component is not in an optimal position, the component revision may be necessary. These procedures tend to be difficult and, clearly, the most effective treatment of tuberosity malunion is prevention.

Heterotopic ossification following hemiarthroplasty for acute fractures is relatively common, although it generally is not clinically significant. Small areas of heterotopic ossification and reactive bone can develop, but these generally do not interfere with function or compromise outcomes. However, more extensive ossification, particularly in the subacromial space, or bone bridging from the acromion to the proximal humerus can be significant. The factors that predispose to clinically heterotopic ossification include high-energy injuries (fracture-dislocations) and delays in surgery longer than 10 to 14 days after the acute injury. Heterotopic ossification also can develop when the procedure is performed after an early failure of internal fixation. The second procedure, particularly when it is performed 2 to 4 weeks after the initial procedure, carries a significant increased risk of heterotopic ossification. Whenever possible, it is important to take measures to prevent the formation of heterotopic bone. At the time of the initial surgery, meticulous technique to minimize soft-tissue trauma is important. The timing of surgery also is important. Whenever possible, the "at risk" period should be avoided. For those patients who are felt to be at high risk for heterotopic bone development, prophylactic measures can be considered, including anti-inflammatory medications postoperatively and/or the use of single-dose radiation therapy. The use of preventive measures has to be balanced with the potential to interfere with tuberosity healing and should be individualized for each patient (Young et al 2010).

Plausinis et al reported the complications that took place after humeral head replacement and included infection, neurologic injury, intraoperative fracture, instability, tuberosity malunion and nonunion, rotator cuff tear, heterotopic ossification, glenoid erosion, and stiffness. When technical factors such as tuberosity malunion or component malpositioning are considered as postoperative complications, the incidence of complications is relatively high (Plausinis et al 2005).

Cazeneuve et al described the clinical and radiological outcome of 36 fractures at a mean of 6.6 years (1 to 16) in which the mean Constant score was 58.5 and was reduced to 53 points with the further follow-up. A total of 23 patients (63%) had radiological evidence of loosening of the glenoid component. Nevertheless, only one patient had aseptic loosening of the baseplate at 12 years' follow-up (Cazeneuve et al 2010).

Wall et al reported a series of 186 with 191 retained reverse total shoulder arthroplasty prostheses who were followed for an average of 39.9 months. Overall, the average Constant score improved from 23 points before surgery to 60 points at the time of follow-up and 173 of the 186 patients were satisfied or very satisfied with the result. Dislocation (fifteen cases)

and infection (eight cases) were the most common complications among the 199 shoulders that were followed for two years or were revised prior to the minimum two-year follow-up. Patients who received the reverse prosthesis at the time of a revision arthroplasty had a higher complication rate than did those who received the reverse prosthesis at the time of a primary arthroplasty. The most common complications were dislocation (fifteen cases; prevalence, 7.5%) and infection (eight cases; prevalence, 4.0%). Glenoid fractures, postoperative humeral fractures, symptomatic hardware, musculocutaneous nerve palsy, radial nerve palsy, glenoid sphere loosening, and glenoid base loosening also occurred in five or fewer cases each (Wall & Walch 2007).

To evaluate functional outcome after hemiarthroplasty for displaced proximal humeral fractures and to review whether prosthesis type, intraoperative technique or previous ipsilateral shoulder surgery could affect the outcome, Fallatah et al reviewed the medical records and radiographs of patients who had undergone hemiarthroplasty for proximal humeral fractures between 1992 and 2000. They concluded that soft tissue status and operative technique played an important role in late postoperative pain and range of motion. Hemiarthroplasty after failed open reduction and internal fixation is associated with inferior results (Fallatah et al 2008).

In the retrospective study of Gallinet D et al, forty patients were treated by shoulder replacement for three- or four-part displaced fractures of the proximal humerus between 1996 and 2004. Twenty-one had a hemiarthroplasty and 19 were treated by reverse prosthesis. The reverse prosthesis group showed better results in terms of abduction, anterior elevation and Constant score. Rotation was better in the hemiarthroplasty group. They concluded that in three- or four-part displaced proximal humerus fracture, arthroplasty did not ensure recovery of pretrauma shoulder function. Management is therefore to be decided in terms of outcome predictability and rapid recovery of daily comfort for elderly patients (Gallinet et al 2009).

Hemiarthroplasty can provide good functional results, but depends on tuberosity union quality and this often necessitates a prolonged immobilization. Reverse prostheses provide reliable, rapid and predictable results in terms of abduction, anterior elevation and pain relief, but impaired rotation; this impacts quality of life and long-term implant durability (glenoid notching).

Reverse prostheses should thus prove advantageous in the treatment of complex fractures of the proximal humerus if these two drawbacks can be resolved and at present seem indicated on condition that the patient is no younger than 70 years of age (Gallinet et al 2009).

Compito et al reviewed the important factors for a successful outcome, including gentle soft tissue technique, secure placement of the prosthesis with proper version and height, secure tuberosity reconstruction, meticulous rotator cuff repair, and a motivated patient who is able to understand and perform the rigorous postoperative rehabilitation. Unsatisfactory results are associated with tuberosity detachment, prosthetic loosening, inadequate or noncompliant rehabilitation, preoperative nerve injury, humeral malposition, dislocation, deep infection, and ectopic bone formation (Compito et al 1994).

On the basis of the current literature, Voos et al list arthroplasties for the treatment of complex proximal humeral fractures in descending order with regard to their clinical success as follows: (1) hemiarthroplasty in a patient with reconstructible tuberosities, (2) reverse total shoulder arthroplasty in a patient with reconstructible tuberosities, (3) reverse

total shoulder arthroplasty in a patient without reconstructible tuberosities, and (4) hemiarthroplasty in a patient without reconstructible tuberosities (Voos et al 2010).

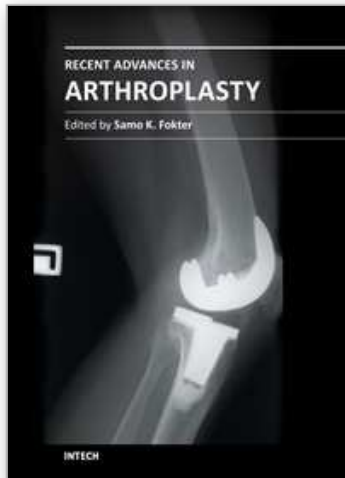
This review covers the indications, technique, results, and complications associated with the use of prostheses for proximal humeral fractures. Meticulous technique, especially in regards to tuberosity fixation, is necessary for successful reconstruction. The use of the Reverse Total Shoulder prosthesis is in evolution but does offer exciting options in the management of these difficult patients (Voos et al 2010).

4. References

- [1] Antuña SA, Sperling JW, Cofield RH. Shoulder hemiarthroplasty for acute fractures of the proximal humerus: a minimum five-year follow-up. *J Shoulder Elbow Surg.* 2008;17(2):202-9.
- [2] Bastian JD, Hertel R. Osteosynthesis and hemiarthroplasty of fractures of the proximal humerus: Outcomes in a consecutive case series. *J Shoulder Elbow Surg* 2009;19:216-219.
- [3] Bigliani LU. Fractures of the proximal humerus. In: Rockwood CA, Green DP, eds. *Fractures in Adults.* 3rd ed. Philadelphia, Pa: JB Lippincott Completed/mh; 1990:871-927.
- [4] Boileau P, Krishnan SG, Tinsi L, et al. Tuberosity malposition and migration: Reasons for poor outcomes after hemiarthroplasty for displaced fractures of the proximal humerus. *J Shoulder Elbow Surg* 2002;11(5): 401-412.
- [5] Boileau P, Trojani C, Walch G, Krishnan SG, Romeo A, Sinnerton R. Shoulder arthroplasty for the treatment of the sequelae of fractures of the proximal humerus. *J Shoulder Elbow Surg* 2001;10:299-308.
- [6] Boileau P, Walch G, Krishnan SG. Tuberosity osteosynthesis and hemiarthroplasty for four-part fractures of the proximal humerus. *Tech Shoulder Elbow Surg* 2000;1:96-109.
- [7] Boileau P, Moineau N, Brassart, Clavert, Favard L, Sirveaux F, O'Shea K. Reverse Shoulder Fracture-Prosthesis for the treatment of proximal humeral fractures in elderly patients. *Shoulder Concepts* 2010:231-43.
- [8] Bufquin T, Hersan A, Hubert L, Massin P. Reverse shoulder arthroplasty for the treatment of three- and four-part fractures of the proximal humerus in the elderly: a prospective review of 43 cases with a short-term follow-up. *J Bone Joint Surg.* 2007 Apr;89(4):516-20.
- [9] Cazeneuve JF, Cristofari DJ. The reverse shoulder prosthesis in the treatment of fractures of the proximal humerus in the elderly. *J Bone Joint Surg.* 2010;92(4):535-9.
- [10] Compito CA, Self EB, Bigliani LU. Arthroplasty and acute shoulder trauma. Reasons for success and failure. *Clin Orthop* 1994;307:27-36.
- [11] Demirhan M, Kilicoglu O, Altinel L, Eralp L, Akalin Y. Prognostic factors in prosthetic replacement for acute proximal humerus fractures. *J Orthop Trauma* 2003;17(3):181-189.
- [12] Duralde XA, Leddy LR. The results of ORIF of displaced unstable proximal humeral fractures using a locking plate. *J Shoulder Elbow Surg* 2010;19:480-488.

- [13] Esen E, Dogramaci Y, Gultekin S, Deveci MA, et al. Factors affecting results of patients with humeral proximal end fractures undergoing primary hemiarthroplasty: A retrospective study in 42 patients. *Injury* 2009;40:1336-1341.
- [14] Fallatah S, Dervin GF, Brunet JA, Conway AF, Hrushowy H. Functional outcome after proximal humeral fractures treated with hemiarthroplasty. *Can J Surg.* 2008;51(5):361-5.
- [15] Flatow EL, Bigliani LU. Locating and protecting the axillary nerve in the shoulder surgery; the Tug Test. *Orthop Rev.* 1992;21:503-505.
- [16] Frankle M, Siegal S, Pupello D, et al. The reverse shoulder prosthesis for glenohumeral arthritis associated with severe rotator cuff deficiency. A minimum two-year follow-up study of sixty patients. *J Bone Joint Surg Am* 2005;87(8):1697-1705.
- [17] Frankle MA, Ondrovic LE, Markee BA, Harris ML, Lee WE 3rd. Stability of tuberosity reattachment in proximal humeral hemiarthroplasty. *J Shoulder Elbow Surg* 2002;11(5):413-420.
- [18] Frankle MA, Greenwald DP, Markee BA, Ondrovic LE, Lee WE 3rd. Biomechanical effects of malposition of tuberosity fragments on the humeral prosthetic reconstruction for four-part proximal humerus fractures. *J Shoulder Elbow Surg* 2001;10(4):321-326.
- [19] Gallinet D, Clappaz P, Garbuio P, Tropet Y, Obert L. Three or four parts complex proximal humerus fractures: hemiarthroplasty versus reverse prosthesis: a comparative study of 40 cases. *Orthop Traumatol Surg Res.* 2009 Feb;95(1):48-55.
- [20] Goldman RT, Koval KJ, Cuomo F, et al. Functional outcomes after humeral head replacement for acute three and four-part proximal humerus fractures. *J Shoulder Elbow Surg* 1995;4:81-86.
- [21] Green A, Bamard L, Limbrid RS. Humeral head replacement for acute, four-part proximal humerus fractures. *J Shoulder Elbow Surg* 1993;2:249-254.
- [22] Hawkins RJ, Switlyk P. Acute prosthetic replacement for severe fractures of the proximal humerus. *Clin Orthop* 1993;289:156-160.
- [23] Huffman GR, Itamura JM, McGarry MH, Duong L, et al. Neer Award 2006: Biomechanical assessment of inferior tuberosity placement during hemiarthroplasty for four-part proximal humeral fractures. *J Shoulder Elbow Surg* 2008;17(2):189-196.
- [24] Jaberg H, Warner JJ, Jakob RP. Percutaneous stabilization of unstable fractures of the humerus. *J Bone Joint Surg Am* 1992;74:508-515.
- [25] Kontakis G, Koutras C, Tosounidis T, Giannoudis P. Early management of proximal humeral fractures with hemiarthroplasty. *J Bone Joint Surg (Br)* 2008;90B(11):1407-1413.
- [26] Lervick GN, Carroll RM, Levine WN. Complications after hemiarthroplasty for fractures of the proximal humerus. *Instr Course Lect.* 2003;52:3-12.
- [27] Levine WN, Connor PM, Yamaguchi K, Self EB, et al. Humeral head replacement for proximal humeral fractures. *Orthopedics* 1998;21(1):68-73.
- [28] Martin TG, Iannotti JP. Reverse total shoulder arthroplasty for acute fractures and failed management after proximal humeral fractures. *Orthop Clin North Am.* 2008;39(4):451-7.
- [29] Mighell MA, Kolm GP, Colinge CA, Frankle MA. Outcomes of hemiarthroplasty for fractures of the proximal humerus. *J Shoulder Elbow Surg* 2003;12:569-577.

- [30] Moeckel BH, Dines DM, Warren RF, Altchek DW. Modular hemiarthroplasty for fractures of the proximal part of the humerus. *J Bone Joint Surg Am* 1992;74:884-889.
- [31] Murachovsky J, Ikemoto RY, Nascimento LG, Milani C, Warner JJ. Pectoralis major tendon reference (PMT): A new method for accurate restoration of humeral length with hemiarthroplasty for fracture. *J Shoulder Elbow Surg* 2006;15(6):675-678.
- [32] Neer CS. Fractures. In: *Shoulder Reconstruction*. Philadelphia, PA: WB Saunders Co. 1990:363-420.
- [33] Neer CS. Displaced proximal humeral fractures, I: classification and evaluation. *J Bone Joint Surg Am* 1970;52:1077-1089.
- [34] Neer CS. Displaced proximal humeral fractures, II: treatment of three-part and four-part displacement. *J Bone Joint Surg Am* 1970;52:1090-1103.
- [35] Pijls BGCW, Werner PH, Eggen PJ. Alternative humeral tubercle fixation in shoulder hemiarthroplasty for fractures of the proximal humerus. *J Shoulder Elbow Surg* 2010;19:282-289.
- [36] Plausins D, Kwon YW, Zuckerman JD. Complications of humeral head replacement for proximal humeral fractures. *AAOS Instruc Course* 2005;54:371-380.
- [37] Reuther F, Mühlhäusler B, Wahl D, Nijs S. Functional outcome of shoulder hemiarthroplasty for fractures: A multicentre analysis. *Injury*. 2010;41(6):606-12.
- [38] Robinson CM, Page RS, Hill RMF, Sanders DL, et al. Primary hemiarthroplasty for treatment of proximal humeral fractures. *J Bone Joint Surg* 2003;85A (7):1215-1223.
- [39] Shrader MW, Sanchez-Sotelo J, Sperling JW, et al. Understanding proximal humerus fractures: image analysis, classification, and treatment. *J Shoulder Elbow Surg* 2005; 14(5): 497-505.
- [40] Tanner MW, Cofield RH. Prosthetic arthroplasty for fractures and fracture-dislocations of the proximal humerus. *Clin Orthop* 1983;179:116-128.
- [41] Voos JE, Dines JS, Dines DM. Arthroplasty for fractures of the proximal part of the humerus. *J Bone Joint Surg Am*. 2010 Jun;92(6):1560-7.
- [42] Wall B, Walch G. Reverse Shoulder Arthroplasty for the Treatment of Proximal Humeral Fractures. *Hand Clin* 23,2007:425-430.
- [43] Young TB, Wallace WA. Conservative treatment of fractures and fracture-dislocations of the upper end of the humerus. *J Bone Joint Surg Br* 1985;67:373-377.
- [44] Zyto K. Non-operative treatment of comminuted fractures of the proximal humerus in elderly patients. *Injury* 1998;29(5):349-352.
- [45] Young SW, Segal BS, Turner PC, Poon PC. Comparison of functional outcomes of reverse shoulder arthroplasty versus hemiarthroplasty in the primary treatment of acute proximal humerus fracture. *ANZ J Surg*. 2010;80(11):789-93.
- [46] Zuckerman JD, Sajadi KR. Proximal Humerus Fractures: Hemiarthroplasty for Four-Part Fractures. *Advanced Reconstruction Shoulder*. AAOS 2007:30:283-98.



Recent Advances in Arthroplasty

Edited by Dr. Samo Fokter

ISBN 978-953-307-990-5

Hard cover, 614 pages

Publisher InTech

Published online 27, January, 2012

Published in print edition January, 2012

The purpose of this book was to offer an overview of recent insights into the current state of arthroplasty. The tremendous long term success of Sir Charnley's total hip arthroplasty has encouraged many researchers to treat pain, improve function and create solutions for higher quality of life. Indeed and as described in a special chapter of this book, arthroplasty is an emerging field in the joints of upper extremity and spine. However, there are inborn complications in any foreign design brought to the human body. First, in the chapter on infections we endeavor to provide a comprehensive, up-to-date analysis and description of the management of this difficult problem. Second, the immune system is faced with a strange material coming in huge amounts of micro-particles from the tribology code. Therefore, great attention to the problem of aseptic loosening has been addressed in special chapters on loosening and on materials currently available for arthroplasty.

How to reference

In order to correctly reference this scholarly work, feel free to copy and paste the following:

José Hernández Enríquez, Xavier A. Duralde and Antonio J. Pérez Caballer (2012). Shoulder Hemiarthroplasty in Proximal Humerus Fractures, Recent Advances in Arthroplasty, Dr. Samo Fokter (Ed.), ISBN: 978-953-307-990-5, InTech, Available from: <http://www.intechopen.com/books/recent-advances-in-arthroplasty/shoulder-hemiarthroplasty-in-proximal-humerus-fractures>

INTECH
open science | open minds

InTech Europe

University Campus STeP Ri
Slavka Krautzeka 83/A
51000 Rijeka, Croatia
Phone: +385 (51) 770 447
Fax: +385 (51) 686 166
www.intechopen.com

InTech China

Unit 405, Office Block, Hotel Equatorial Shanghai
No.65, Yan An Road (West), Shanghai, 200040, China
中国上海市延安西路65号上海国际贵都大饭店办公楼405单元
Phone: +86-21-62489820
Fax: +86-21-62489821

© 2012 The Author(s). Licensee IntechOpen. This is an open access article distributed under the terms of the [Creative Commons Attribution 3.0 License](#), which permits unrestricted use, distribution, and reproduction in any medium, provided the original work is properly cited.

IntechOpen

IntechOpen