

# We are IntechOpen, the world's leading publisher of Open Access books Built by scientists, for scientists

**4,800**

Open access books available

**122,000**

International authors and editors

**135M**

Downloads

Our authors are among the

**154**

Countries delivered to

**TOP 1%**

most cited scientists

**12.2%**

Contributors from top 500 universities



**WEB OF SCIENCE™**

Selection of our books indexed in the Book Citation Index  
in Web of Science™ Core Collection (BKCI)

Interested in publishing with us?  
Contact [book.department@intechopen.com](mailto:book.department@intechopen.com)

Numbers displayed above are based on latest data collected.

For more information visit [www.intechopen.com](http://www.intechopen.com)



## Toxic and Drug-Induced Changes of the Electrocardiogram

Catalina Lionte, Cristina Bologa and Laurentiu Sorodoc  
*"Gr.T.Popa" University of Medicine and Pharmacy, Iasi,  
Romania*

### 1. Introduction

There are numerous toxins and drugs that can cause, in overdose, electrocardiogram (ECG) changes, even in patients without history of cardiac pathology. The diagnosis and management of patients with an abnormal ECG encountered in a specific toxicity can challenge experienced physicians. One must have serious knowledge of basic cardiac physiology, in order to understand the ECG changes associated with various drugs and toxins.

The main mechanisms involved include membrane - depressant action (sodium channel blockers, slow calcium channel blockers, outward potassium ( $K^+$ ) channel blockers, and sodium-potassium adenosine-triphosphatase blockers), and action on autonomic nervous system and its sites of cardiovascular action (beta-adrenergic blockers and other sympathetic-inhibitors, sympathomimetic, anticholinergic and cholinomimetic substances). Many toxins and medications have actions that involve more than one of these mechanisms, including hypoxia, electrolyte and metabolic imbalances, and thus may result in a combination of electrocardiographic changes.

In resting state, the myocardial cell membrane is impermeable to positively charged sodium ions ( $Na^+$ ). The  $Na^+/K^+$  ATPase maintains a negative electric potential of approximately 90 mV in the myocyte. The rapid opening of  $Na^+$  channels and massive  $Na^+$  influx (phase 0 of action potential) explains depolarization of the cardiac cell membrane (fig.1), causing the rapid upstroke of the cardiac action potential, which is conducted through the ventricles and is expressed as the QRS complex of the ECG. The closure of  $Na^+$  channels and the transient opening of  $I_{to}$   $K^+$  efflux channels (phase 1) mark the peak of the action potential. Then, phase 2 of the action potential occurs when the opening of slow calcium ( $Ca^{2+}$ ) channels produces an influx of positive ions with a steady maintenance of the membrane potential and myocardial contraction continues. The end of the cardiac cycle is marked by the closure of the  $Ca^{2+}$  channels and the activation of the  $K^+$  efflux channels, which allow the action potential to return to its resting potential of - 90 mV (phase 3). This  $K^+$  efflux from the myocardial cell is directly responsible for the QT interval on the ECG (Holstege et al., 2006). During phase 4 of the cardiac cell action potential, some cardiac fibers allow sodium ions to enter the cell, increasing the resting membrane potential, known as spontaneous diastolic depolarization. When the threshold in membrane potential is reached, the  $Na^+$  channels open and another action potential is generated.

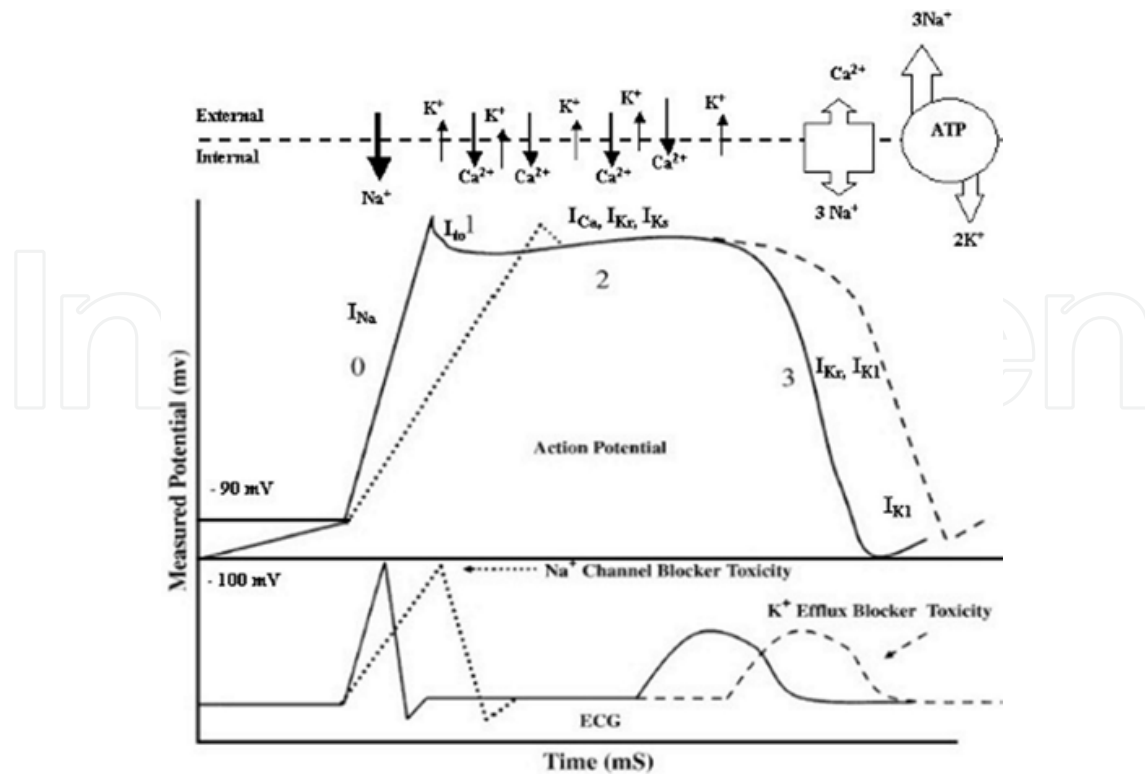


Fig. 1. Cardiac cycle action potential with corresponding ion changes across the membrane and electrocardiographic tracing. Dotted line indicates the changes associated with  $\text{Na}^+$  channel blocker toxicity. Dashed line indicates the changes associated with  $\text{K}^+$  efflux blocker toxicity.  $I_{\text{to}}$  = transient outward  $\text{K}^+$  current;  $I_{\text{Ca}}$  = L-type  $\text{Ca}^{2+}$  current;  $I_{\text{Na}}$  = late sodium channel current;  $I_{\text{Kr}}$  = rapidly activating delayed-rectifier  $\text{K}^+$  current;  $I_{\text{Ks}}$  = slowly activating delayed rectifier  $\text{K}^+$  current;  $I_{\text{K1}}$  = inward rectifier  $\text{K}^+$  current (adapted from Holstege et al., 2005).

The atrial and ventricular myocardium contraction, and the conduction in the His-Purkinje system depend on sodium entry via the fast sodium channels in phase 0 of the action potential, while the conduction in sinoatrial node and atrioventricular (AV) node depend on  $\text{Ca}^{2+}$  entry during phase 0 via the slow  $\text{Ca}^{2+}$  channels (Patel & Benowitz, 2005).

Cardiac activity is controlled, among other mechanisms, by the autonomic nervous system. Sympathetic fibers increase the heart rate, the rate of AV nodal conduction and the contractility of the myocardium. The norepinephrine released by postganglionic fibers leads to an interaction with beta 1-adrenergic cardiac receptors, and increasing cells' permeability to  $\text{Na}^+$  and  $\text{Ca}^{2+}$ , with an increase of contractility, excitability, and conduction. The parasympathetic postganglionic fibers innervate the sinus node and AV node. Stimulation of muscarinic receptors via releasing of acetylcholine decreases atrial excitability and slows the conduction of impulses to the ventricles (Patel & Benowitz, 2005).

In the setting of drug overdose or of a toxic exposure, ECG abnormalities, especially arrhythmias, are produced by direct or indirect sympathomimetic effects, anticholinergic effects, the effects of altered central nervous system (CNS) regulation of peripheral autonomic system, and myocardial membrane depression. Genesis of arrhythmias in the poisoned patient is based on the same three mechanisms as in an ischemic patient: abnormal impulse formation, abnormal impulse conduction, and triggered activity. Contributing factors to ECG changes are hypotension, hypoxia, acid-base and electrolyte imbalances.

## 2. Membrane – depressant drugs and toxins

Cardiotoxins are responsible of ECG changes through a combination of membrane depressant effects, autonomic disturbances and metabolic changes. The severity of a toxic-induced conduction block varies depending on the toxin involved and its site of action.

### 2.1 Sodium channel blockers

Inhibition of the fast Na<sup>+</sup> channels, in the phase 0 of the action potential (AP), decreases the rate of rise and amplitude of the AP in Purkinje fibers, and in atrial and ventricular myocardial cells. As a result, the upslope of depolarization is slowed and the QRS complex becomes wide. In a toxicological situation, QRS complex widening likely results directly from Na<sup>+</sup> channel blockage or indirectly from toxin-induced hyperkalemia (Holstege et al.,

Inhibitors of fast Na <sup>+</sup> channels	<ol style="list-style-type: none"> <li>1. Cardiovascular drugs: <ul style="list-style-type: none"> <li>- Type Ia antiarrhythmics (Quinidine, Disopyramide, Procainamide)</li> <li>- Type Ic antiarrhythmics (Flecainide, Encainide, Propafenone, Moricizine)</li> <li>- Propranolol and other membrane depressant beta-blockers*</li> <li>- Verapamil, Diltiazem</li> </ul> </li> <li>2. Psychiatric drugs: <ul style="list-style-type: none"> <li>- Carbamazepine</li> <li>- Cyclic antidepressants (Amitriptyline, Amoxapine, Desipramine, Doxepin, Imipramine, Nortriptyline, Maprotiline)</li> <li>- Neuroleptics (Thioridazine, Mesoridazine)</li> <li>- Other antidepressants (Citalopram)</li> <li>- Antipsychotics (Loxapine)</li> </ul> </li> <li>3. Other drugs: <ul style="list-style-type: none"> <li>- Amantadine</li> <li>- Antihistamines (Diphenhydramine)</li> <li>- Chloroquine, Hydroxychloroquine</li> <li>- Orphenadrine</li> <li>- Narcotic pain relievers (Propoxyphene)</li> </ul> </li> <li>4. Illicit drugs: Cocaine</li> <li>5. Toxins: Quinine, Saxitoxin, Tetrodotoxin</li> </ol>
ECG changes	<p>QRS widening  Right bundle branch pattern  R wave elevation in aVR lead  Rightward deviation of QRS axis  Ventricular tachycardia (VT) and ventricular fibrillation (VF)  Bradycardia with wide QRS complex  Asystole  ST/T changes consistent with ischemia (cocaine toxicity)</p>

\*mechanism not involving the beta-receptor.

Table 1. Na<sup>+</sup> channel blockers and the resulting ECG changes.

2005). Direct toxin-induced blockade of cardiac  $\text{Na}^+$  channels will cause QRS complex widening, and it has been described as a membrane stabilizing effect, a local anesthetic effect, or a quinidine-like effect. Some drugs in this category (Table 1) may also affect other myocardial ion transfers, such as the  $\text{Ca}^{2+}$  influx and  $\text{K}^+$  efflux (Holstege et al., 2006). Other abnormal QRS complex configurations are also possible. In the most severe cases, the QRS complex widening becomes so profound that the ultimate origin of the rhythm disturbance is impossible (fig. 2).

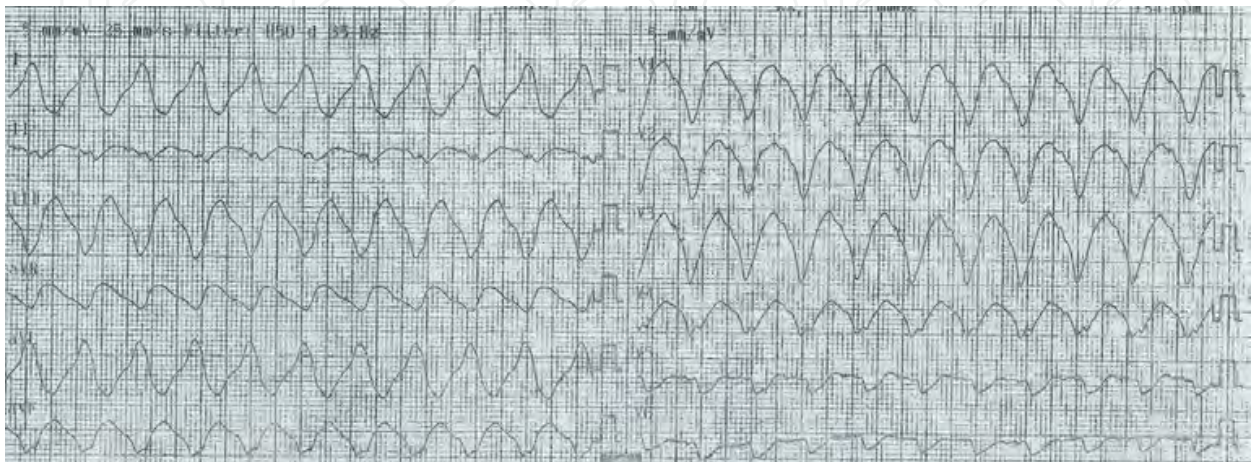


Fig. 2.  $\text{Na}^+$  channel blocker toxicity (patient with acute Propafenone overdose). Note the wide QRS complex, at a rate of 134/min, which suggests, at a first view, monomorphic VT.

R wave elevation in  $\text{aVR} \geq 3 \text{ mm}$  (fig.3) is the only ECG variable that significantly indicates the risk of seizures and arrhythmias in acute tricyclic antidepressant poisoning (Liebelt et al., 1995). In addition, QT interval prolongation can occur with tricyclic antidepressant poisoning, as well as rightward axis deviation of the terminal 40 msec of the frontal plane QRS axis, which is unknown in other  $\text{Na}^+$  channel blocking agents (Wolfe et al. 1989; Berkovitch et al, 1995). Continued prolongation of the QRS complex may result in a sine wave pattern and eventual asystole.

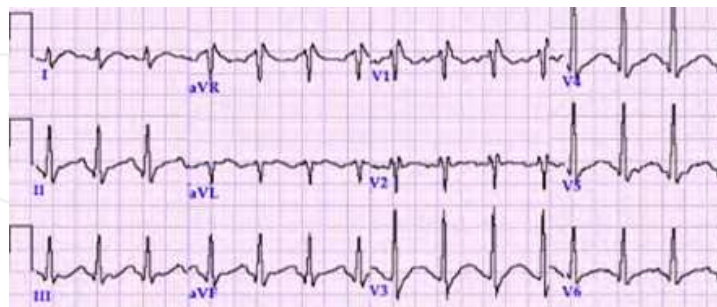


Fig. 3. Acute poisoning with Amitriptyline. ECG reveals sinus tachycardia 148/min, RBBB pattern, QRS complex  $\geq 120 \text{ ms}$ , as well as R wave elevation in  $\text{aVR} \geq 3 \text{ mm}$ .

$\text{Na}^+$  channel blockers may determine slowed intraventricular conduction, unidirectional block, the development of a reentrant circuit, and a resulting VT as well as VF. Because many of the  $\text{Na}^+$  channel blocking agents have also anticholinergic or sympathomimetic effects, bradydysrhythmias are rare. In  $\text{Na}^+$  channel blocker poisoning by anticholinergic and sympathomimetic drugs, the combination of a wide QRS complex and bradycardia is a



sign of severe poisoning, indicating that the Na<sup>+</sup> channel blockade is so profound that tachycardia does not occur, despite the clinical muscarinic antagonism or adrenergic agonism (Holstege et al., 2006). Nevertheless, bradycardia may occur because of slowed depolarization of pacemaker cells that depend on entry of Na<sup>+</sup> ions.

## 2.2 Slow Calcium Channel Blockers (CCB)

All CCBs (Table 2) inhibit the voltage sensitive L-type Ca<sup>2+</sup> channel within the cell membrane. In the pacemaker cells of the sinoatrial node and AV node, the primary ion channel, which controls depolarization, is the slow Ca<sup>2+</sup> channel. When inhibited, there is a slowing or an inhibition of the specialized tissue to conduct a cardiac impulse (Patel & Benowitz, 2005).

Inhibitors of slow Ca <sup>2+</sup> channels	<ol style="list-style-type: none"> <li>1. Dihydropyridines: <ul style="list-style-type: none"> <li>- 1<sup>st</sup> generation: Nicardipine, Nifedipine</li> <li>- 2<sup>nd</sup> generation: Felodipine, Isradipine, Nimodipine</li> <li>- 3<sup>rd</sup> generation: Amlodipine, Nitrendipine</li> <li>- 4<sup>th</sup> generation: Lercanidipine, Lacidipine</li> </ul> </li> <li>2. Phenylalkylamine: <ul style="list-style-type: none"> <li>- Verapamil</li> <li>- Gallopamil</li> </ul> </li> <li>3. Benzothiazepine: <ul style="list-style-type: none"> <li>- Diltiazem</li> </ul> </li> <li>4. Non-selective: <ul style="list-style-type: none"> <li>- Bepridil</li> <li>- Mibefradil</li> <li>- Fluspirilene</li> </ul> </li> </ol>
ECG changes	Sinus bradycardia Reflex tachycardia (ex. Nifedipine) Varying degrees of AV block Sinus arrest with AV junctional rhythm Asystole Wide QRS complex ST/T changes

Table 2. Calcium channel blockers and the resulting ECG changes.

In CCB toxicity initially occurs a sinus bradycardia, followed by various degrees of AV block (fig.4), and junctional and ventricular bradydysrhythmias on ECG. Depending on the agent involved, other dysrhythmias may be seen (Gordon, 2006): sinus tachycardia (specifically Nifedipine), atrial arrhythmias, and junctional rhythms (fig. 5, 6,7). A wide QRS complex may appear, caused by ventricular escape rhythms or by CCB-induced Na<sup>+</sup> channel blockade which delays of phase 0 of depolarization. Sudden shifts from bradydysrhythmias to cardiac arrest have been reported.

In addition, ECG changes associated with cardiac ischemia (fig.8) may occur as a result of the hypotension and changes in the cardiovascular status, especially in patients with pre-existing cardiac disease (Patel & Benowitz, 2005; Holstege et al., 2006).

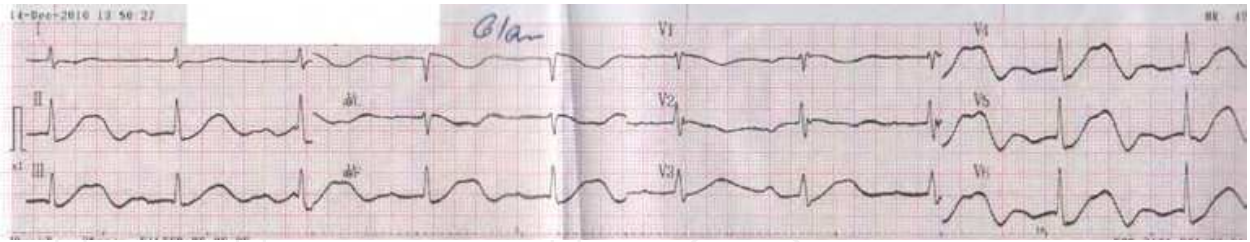


Fig. 4. Acute poisoning with Verapamil in a 61-years old female. ECG reveals sinus bradycardia 41/min, minor right bundle branch block (RBBB), first-degree AV block (PR 0.32 sec) and long QT interval (0.64 sec).

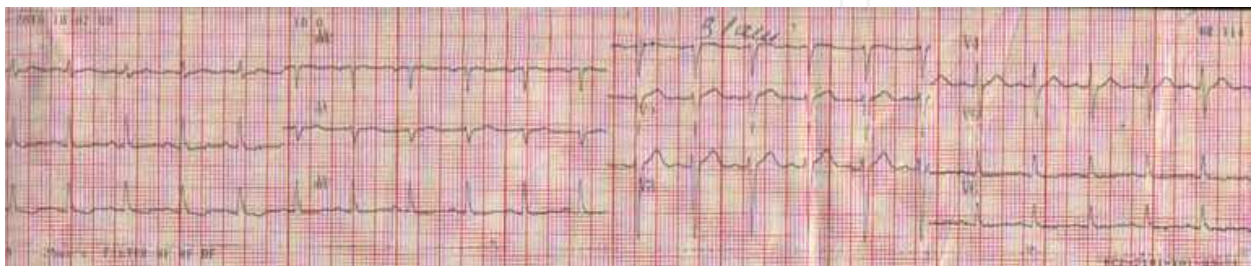


Fig. 5. Acute poisoning with Norvasc 300 mg in a 31-years old female. ECG reveals sinus tachycardia 114/min, signs of ischemia in infero-lateral leads, 14 hours after ingestion (systolic blood pressure 70 mmHg).

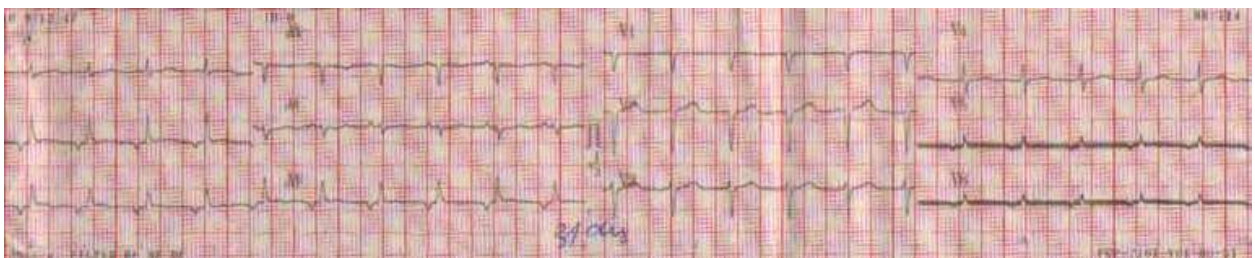


Fig. 6. Same patient, two days after ingestion. ECG reveals accelerated junctional rhythm (sinus coronary rhythm, or Zahn rhythm) 114/min, with negative P waves in leads DII, DIII, aVF, and disappearance of ischemic changes present at admission.

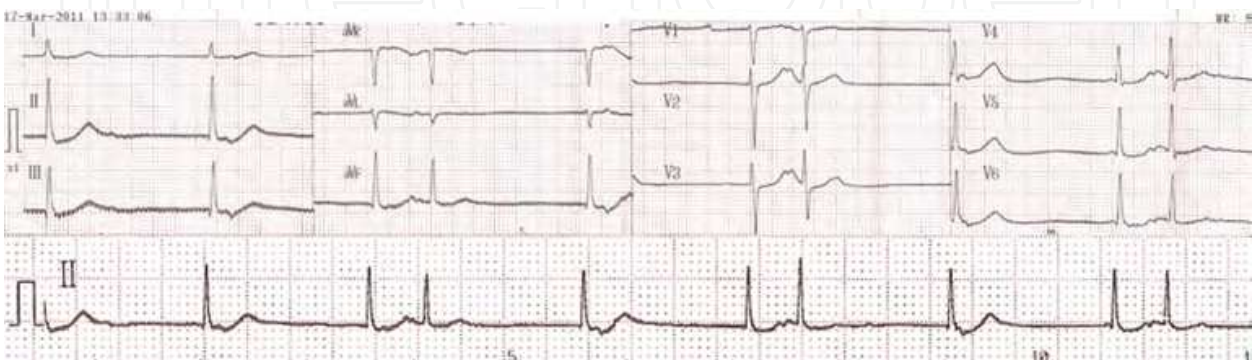


Fig. 7. Acute Diltiazem poisoning at admission. ECG reveals accelerated junctional rhythm 75/min, retrograde atrial conduction (negative P waves after QRS), and atrial premature beats.



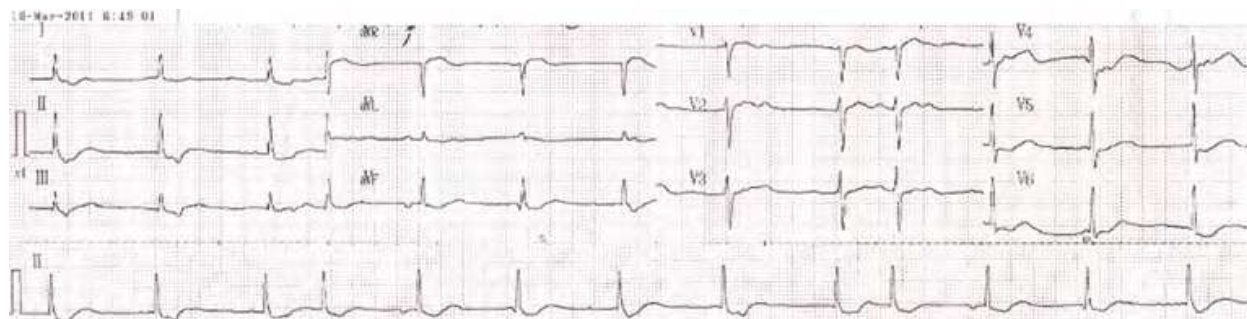


Fig. 8. Same patient (Diltiazem poisoning), second day of evolution. ECG reveals atrio-ventricular dissociation, with escape junctional rhythm and some ventricular captures, and signs of ischemia (in inferior and lateral leads).

### 2.3 Outward potassium channel blockers

Medications in the  $K^+$  efflux blocker category block the outward flow of  $K^+$  from intracellular to extracellular spaces. Blockade of the outward  $K^+$  currents may prolong the cardiac cycle action potential (Fig. 1). The primary electrocardiographic manifestation is QT interval prolongation (QTc interval greater than 0.45 seconds in men and 0.47 seconds in women). Delay of repolarization causes the myocardial cell to have less charge difference across its membrane, and result in the activation of the inward depolarization current (early after-depolarization), which is seen on ECG as prominent U waves (Murphy et al., 2007). This may promote triggered activity, which potentially can progress to re-entry and subsequent polymorphic VT. Toxin-induced blockade of  $K^+$  efflux channels during phase 3 of the action potential corresponding with repolarization and QT interval prolongation may place the patient at risk for polymorphic VT or torsades de pointes (Holstege et al., 2005; Holstege et al., 2006). The drugs and toxins reported to have this effect are listed in table 3.

Risk factors for torsades de pointes (TdP) among patients treated with medications that prolong QT interval include, among others, female gender, hypokalemia, hypomagnesemia, bradycardia, overdose, drug interactions (fig.9), digitalis therapy, and background of the patient (preexisting cardiac disease, long QT interval or family history of long QT). (Murphy et al., 2007; Roden, 2004)

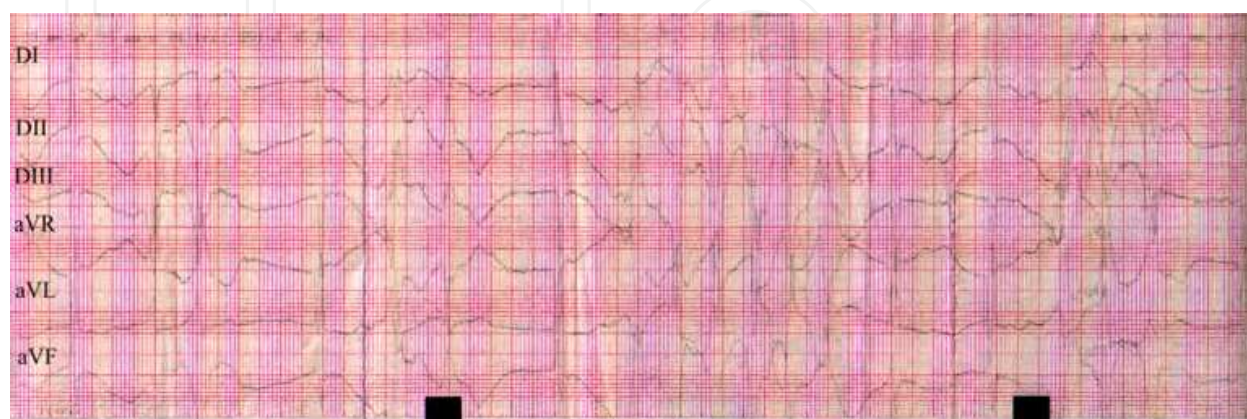


Fig. 9. Drug-induced long QT interval, following interaction between Bisoprolol and Amiodarone. ECG shows long QT interval (0.80 sec), couples of PVB with R/T phenomenon preceding a short episode of polymorphic VT.



Inhibitors of outward K <sup>+</sup> channel	<ol style="list-style-type: none"> <li>1. Cardiovascular drugs: <ul style="list-style-type: none"> <li>- Class IA antidysrhythmics** (Disopyramide, Quinidine, Procainamide)</li> <li>- Class IC antidysrhythmics (Encainide, Flecainide, Moricizine, Propafenone)</li> <li>- Class III antidysrhythmics** (e.g. Amiodarone, Dronedarone, Dofetilide, Ibutilide, Sotalol, Vernakalant)</li> <li>- Anti-anginal/vasodilators** (Bepridil, Prenylamine, Terodiline)</li> <li>- Antihypertensives (Ketanserin*)</li> </ul> </li> <li>2. Psychiatric drugs: <ul style="list-style-type: none"> <li>- Antipsychotics (Chlorpromazine, Droperidol, Haloperidol, Mesoridazine, Pimozide, Quetiapine, Risperidone, Thioridazine, Ziprasidone)</li> <li>- Cyclic antidepressants (Amitriptyline, Amoxapine, Desipramine, Doxepin, Imipramine, Nortriptyline, Maprotiline)</li> <li>- Other antidepressants (Citalopram, Venlafaxine)</li> <li>- Phenothiazines</li> </ul> </li> <li>3. Other drugs: <ul style="list-style-type: none"> <li>- Antihistamines (Astemizole, Diphenhydramine, Loratidine, Terfenadine*, Hydroxyzine)</li> <li>- Serotonin 5-HT<sub>4</sub> receptor agonist (Cisaprid***)</li> <li>- Antimicrobials and antimalarics (Ciprofloxacin, Gatifloxacin, Levofloxacin, Moxifloxacin, Sparfloxacin, Clarithromycin**, Erythromycin**, Pentamidine**, Chloroquine**, Halofantrine, Hydroxychloroquine, etc.)</li> <li>- Arsenic trioxide</li> <li>- Probucol*</li> </ul> </li> <li>4. Synthetic opioids: Levomethadyl</li> <li>5. Opium alkaloids: Papaverine**</li> <li>6. Toxins: Quinine, Organophosphates (fig.10)</li> </ol>
ECG changes	QT interval prolongation T- or U-wave abnormalities Premature ventricular beats (PVB) followed by TdP Sinus tachycardia

\*removed from the market; \*\* TdP reported.

Table 3. K<sup>+</sup> efflux channel blockers, and the resulting ECG changes.

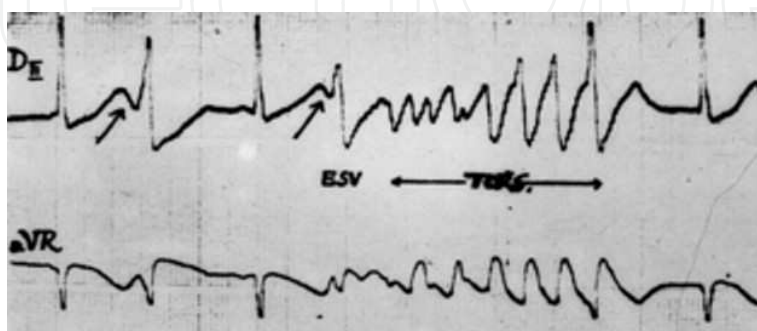


Fig. 10. Acute organophosphate poisoning, five days after ingestion. ECG shows long QT interval (0.60 sec), PVB with R/T phenomenon (arrows) preceding a short episode of TdP (TORS).

Many of these drugs have other effects that can result in significant electrocardiographic changes, such as antipsychotics, that can cause muscarinic acetylcholine receptor and alpha-adrenergic receptor blockade and cardiac cell  $K^+$ ,  $Na^+$ , and  $Ca^{2+}$  channel blockade (Holstege et al., 2006). These effects lead to sinus tachycardia (secondary to anticholinergic effect) or reflex tachycardia (secondary to alpha-adrenergic blockade).

#### 2.4 Sodium–potassium ATPase blockers

Cardiac glycosides (table 4) inhibit the  $Na^+/K^+$  adenosine triphosphatase ( $Na^+/K^+$ ATPase) pump. As a result, there is an inhibition of the active transport of  $Na^+$  and  $K^+$  across cell membrane, intracellular  $Na^+$  increases and the  $Na^+/Ca^{2+}$  exchanger is secondary activated. The intracellular  $Ca^{2+}$  level increases, and augments myofibril activity in cardiac myocytes, which results in a positive inotropic effect, and increased automaticity. The cardiac glycosides also increase vagal tone that may lead to a direct atrioventricular (AV) nodal depression (Holstege et al., 2006). Digitalis derivatives in therapeutic doses are used to increase myocardial contractility or slow AV conduction. They modify ECG, changes known as “digitalis effect”, expressed by abnormal inverted or flattened T waves coupled with ST segment depression (most pronounced in leads with tall R waves), QT interval shortening (as a result of decreased ventricular repolarization time), PR interval lengthening (increased vagal activity), and prominent U-waves. Sagging ST segments, inverted T waves, and normal or shortened QT intervals are sometimes identified by their similar appearance to “Salvador Dali’s mustache” (Clancy, 2007). These ECG changes are seen with therapeutic Digoxin levels and do not represent toxicity (Chung, 1981).

$Na^+/K^+$ ATPase blockers	<ol style="list-style-type: none"> <li>1. Drugs:             <ul style="list-style-type: none"> <li>- Digoxin (Lanoxin)</li> <li>- Digitoxin</li> </ul> </li> <li>2. Plants producing cardiac glycosides:             <ul style="list-style-type: none"> <li>- Cardenolide type: <i>Strophanthus</i> - ouabain g/k/e-strophanthin, <i>Digitalis lanata</i> and <i>Digitalis purpurea</i> (foxglove) - digoxin, digitoxin, <i>Nerium oleander</i> (oleander) - oleandrin, <i>Convallaria majalis</i> (Lily of the valley), <i>Apocynum cannabinum</i> (Dogbane), <i>Asclepias species</i>.</li> <li>- Bufadienolide type: <i>Urginea maritima</i> (Red squill)</li> </ul> </li> <li>3. Animals producing cardiac glycosides:             <ul style="list-style-type: none"> <li>- Bufadienolide type: <i>Bufo marinus</i> toads</li> </ul> </li> </ol>
ECG changes	<ul style="list-style-type: none"> <li>- Excitant activity: atrial and junctional premature beats, atrial tachycardia, atrial flutter (rare), AF (rare), accelerated junctional rhythms, PVB, bigeminy and multifocal, VT, bi-directional VT, VF.</li> <li>- Suppressant activity: sinus bradycardia, sinoatrial block, type I second degree AV block (Wenckebach), bundle branch blocks, complete AV block, type II second degree AV block (rare).</li> <li>- Combination of these: atrial tachycardia with AV block, sinus bradycardia with junctional tachycardia, Wenckebach with junctional premature beats, regularization of ventricular rhythm with AF.</li> </ul>

Table 4.  $Na^+/K^+$  ATPase blocking agents and ECG changes in intoxication (adapted from Gordon, 2006; Lapostolle & Borron, 2007).

Electrocardiographic abnormalities with cardiac glycoside toxicity are the result of increased automaticity (from increased intracellular  $Ca^{2+}$ ) accompanied by slowed conduction through the AV node. In 10% to 15% of cases, ectopic rhythms will be the first sign of intoxication. AV block or an increase in ventricular automaticity are the most common manifestations of Digoxin toxicity and have been shown to occur in 30% to 40% of verified cases of toxicity. The nonspecific dysrhythmias consist of premature ventricular contractions (especially bigeminal and multiform), first-, second-, and third degree AV block, sinus bradycardia (fig.11), sinus tachycardia, sino-atrial block or arrest, atrial fibrillation (AF) with slow ventricular response (fig.12), atrial tachycardia, junctional escape rhythm, AV dissociation, ventricular bigeminy and trigeminy, VT (fig.13), TdP, and VF. The more specific dysrhythmias are AF with slow, regular ventricular rate (AV dissociation), nonparoxysmal junctional tachycardia (rate 70-130), atrial tachycardia with block (atrial rate is usually 150-200), and bi-directional VT. Bi-directional VT is particularly characteristic of severe toxicity and is the result of alterations of intraventricular conduction, junctional tachycardia with aberrant intraventricular conduction, or, on rare occasions, alternating ventricular pacemakers. Typically, in the young, slow rhythms and conduction defects predominate over ventricular ectopy, which is more prominent in older Digoxin-toxic patients. (Litonjua et al., 2005)

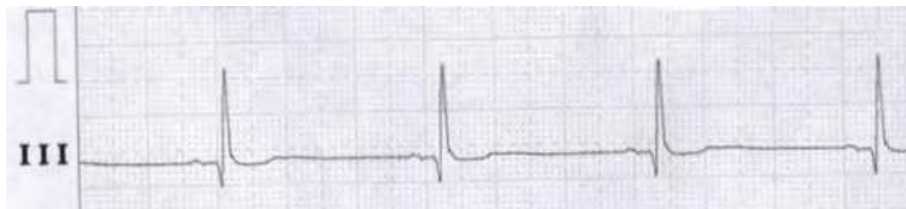

Fig. 11. Sinus bradycardia 47/min, with ST/T changes, 20 hours after attempted suicide with 10 mg Digoxin, in an 18 years old man.

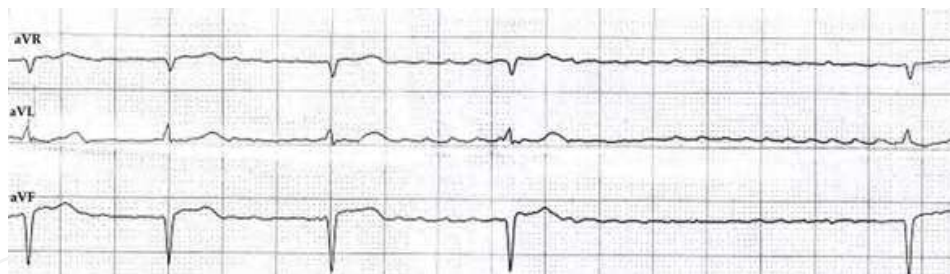


Fig. 12. AF 56/min, with a pause of 2.96 sec, 15 hours after attempted suicide with Digoxin, in a 68 years old woman.

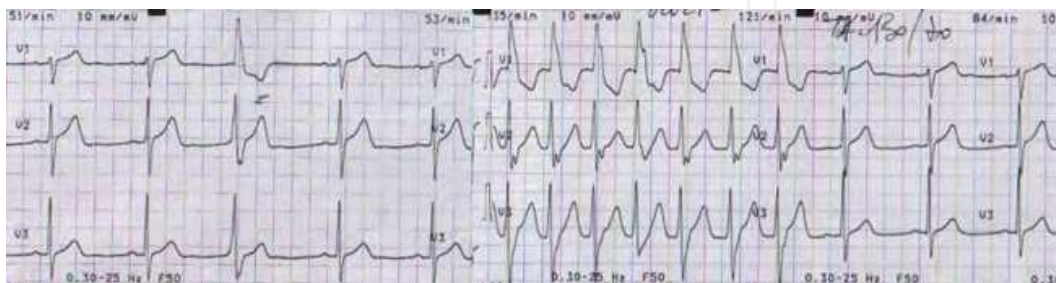


Fig. 13. PVB and a short episode of non-sustained VT 135/min, in a 56 years old male with Digoxin overdose in attempted suicide.



### 3. Drugs and toxins acting on autonomic nervous system

In an acute poisoning, ECG changes, especially arrhythmias, can be explained by direct or indirect sympathomimetic effects, anticholinergic effects, and the effects of altered central nervous system (CNS) regulation of peripheral autonomic activity. Sympathetic fibers innervate most parts of the heart. Postganglionic fibers release norepinephrine, which interacts with the beta 1- adrenergic cardiac receptors, to increase permeability to Na<sup>+</sup> and Ca<sup>2+</sup>, thus leading to increased excitability, conduction and contractility. The vagal postganglionic parasympathetic fibers locally release acetylcholine. Vagal stimulation of the muscarinic receptors primarily decreases excitability of the atria, and slows the conduction of impulse into the ventricles, to a complete blockade of transmission in the AV node, with modest direct effects on contractility (Patel & Benowitz, 2005).

Beta-adrenergic blockers	<p>1<sup>st</sup> generation</p> <ul style="list-style-type: none"> <li>- Oxprenolol (membrane stabilizing effect, intrinsic sympathomimetic activity)</li> <li>- Propranolol (membrane stabilizing effect)</li> <li>- Alprenolol, Nadolol</li> <li>- Pindolol (intrinsic sympathomimetic activity)</li> <li>- Sotalol (K<sup>+</sup> channel blockade)</li> <li>- Timolol</li> </ul> <p>2<sup>nd</sup> generation</p> <ul style="list-style-type: none"> <li>- Acebutolol (membrane stabilizing effect, intrinsic sympathomimetic activity)</li> <li>- Practolol, Atenolol, Metoprolol</li> <li>- Betaxolol (membrane stabilizing effect, vasodilation secondary to calcium channel blocking properties)</li> <li>- Bisoprolol</li> <li>- Esmolol</li> </ul> <p>3<sup>rd</sup> generation</p> <ul style="list-style-type: none"> <li>- Labetalol (vasodilation, alpha-adrenergic antagonist activity)</li> <li>- Carvedilol (vasodilation, alpha-adrenergic antagonist activity)</li> <li>- Nebivolol (vasodilation by release of nitric oxide)</li> <li>- Carteolol (vasodilation by release of nitric oxide)</li> <li>- Celiprolol (vasodilation, alpha 2-adrenergic antagonism activity)</li> </ul>
ECG changes	<p>Sinus or nodal bradycardia  AV blocks (first-degree AV block is common)  Prolonged PR, and QTc intervals  Prolonged QRS complex (membrane stabilizing agents)  Ventricular tachydysrhythmias (membrane stabilizing agents) - fig.14  Multifocal ventricular extrasystoles, VT, VF (Sotalol)  Asystole (in severe poisoning)  Mild tachycardia (Pindolol overdose)</p>

Table 5. Beta-blockers and ECG changes in intoxication (adapted from Gordon, 2006; Holstege et al., 2006; Brubacher, 2007)

### 3.1 Beta-adrenergic blockers (BB)

BBs competitively inhibit various  $\beta$ -adrenergic receptors, and are listed in table 5.

They cause in most cases sinus bradycardia. Serious arrhythmias result from purely anticholinergic compound poisoning, especially in patients with underlying ischemic heart disease (e.g. atrial tachycardia and PVB). In acute BB overdose, the most pronounced effects are bradycardia (from decreased sinoatrial node function), varying degrees of AV block, and hypotension. Beta-adrenergic antagonists competitively antagonize the effects of catecholamines at the beta-adrenergic receptor and blunt the chronotropic and inotropic response to catecholamines (Bird, 2007).

Inhibition of the conducting system most commonly causes first-degree AV block, but higher levels of toxicity can promote second- and third-degree AV block (fig.15), junctional rhythms, and intraventricular conduction delays (Anderson, 2008).

Three beta-blockers are known to prolong QTc intervals: Sotalol (fig.16), Propranolol, and Acebutolol. Sotalol blocks  $K^+$  channels, thereby prolonging the action potential and the repolarization duration. The prolongation of the QTc interval predisposes the patient to ventricular tachyarrhythmias and TdP, which have been described after both Sotalol overdose and therapeutic administration. Propranolol overdose has caused QTc prolongation and torsades on rare occasion (Delk et al., 2006).

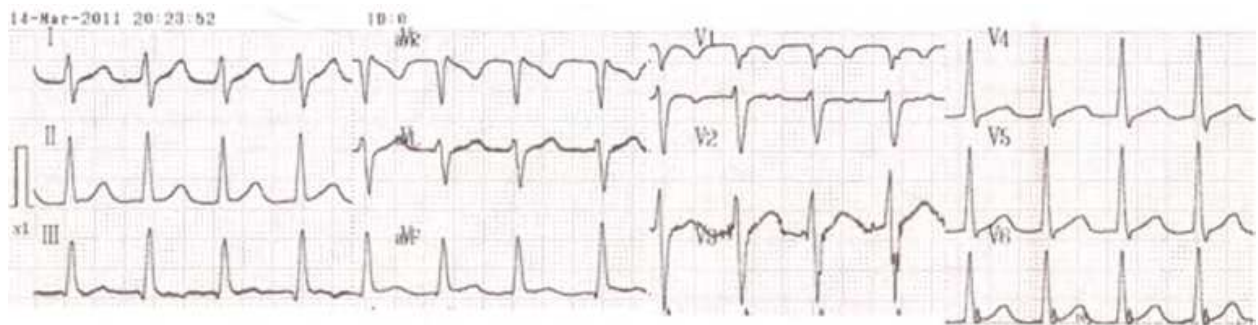


Fig. 14. Acute poisoning 3 hours after ingestion of 2 grams of Propranolol, presenting with accelerated idioventricular rhythm 115/min, in a young female. Note the absence of P waves, wide QRS complex (0.12 msec).

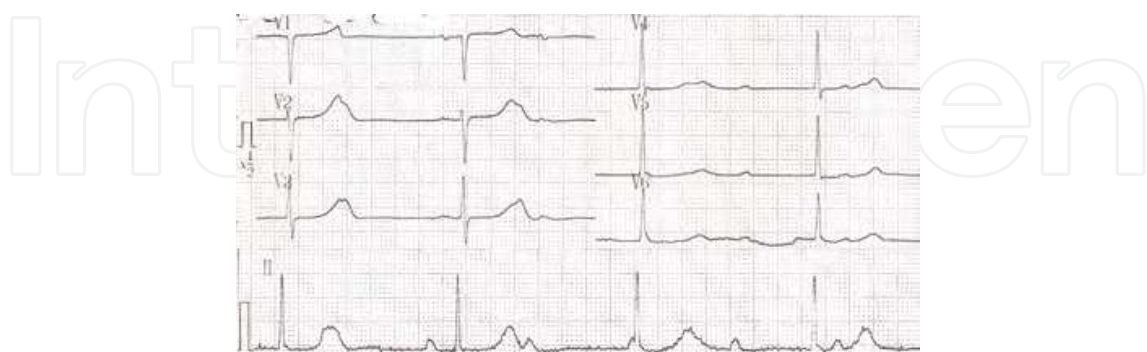


Fig. 15. Acute Metoprolol poisoning presenting with third degree AV block, with narrow QRS complex at a rate of 35/min. Atrial activity is represented by P waves, 80/min.

Beta-adrenergic antagonists also cause myocardial depression, at least in part, by an action independent of either catecholamine antagonism or membrane-depressant activity (Brubacher, 2007).

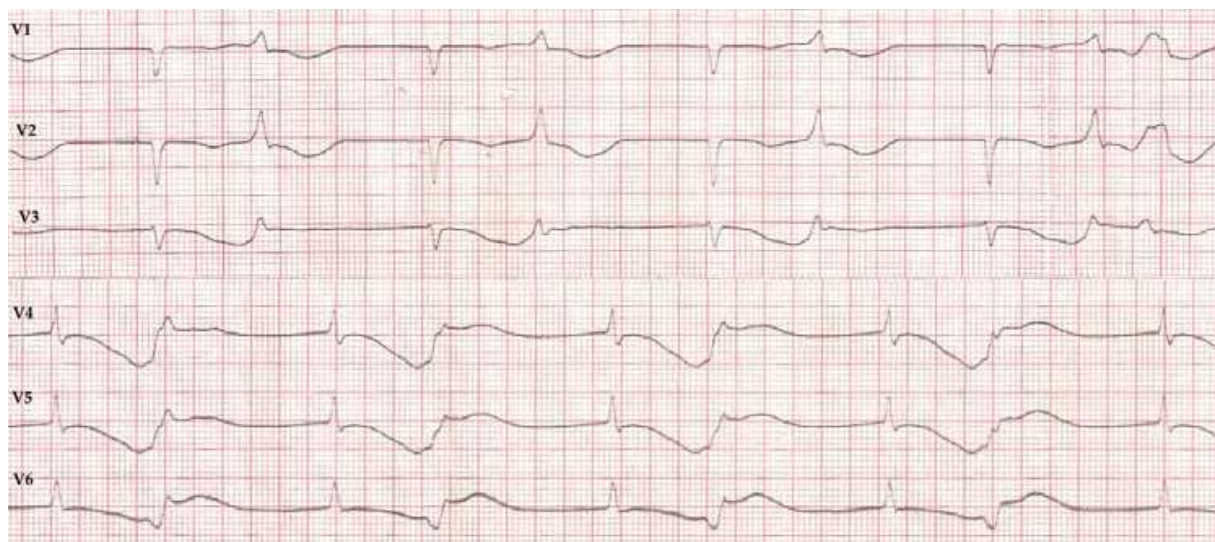


Fig. 16. Acute Sotalol poisoning presenting with bradyarrhythmias, with severe QT prolongation, and monomorphic PVB, R/T phenomenon, and a couple of polymorphic PVB (leads V1-V3).

**3.2 Other sympathetic – inhibitors (other than BB)**

Cardiac disturbances caused by sympathetic-inhibiting drugs are listed in table 6.

Sympathetic-inhibiting agents	Methyldopa Clonidine and other imidazoline derivatives Reserpine, Guanethidine Prazosin and other alpha-blockers
ECG changes	Sinus, atrial, junctional and ventricular bradyarrhythmias First degree AV block Ventricular tachyarrhythmias

Table 6. Sympathetic-inhibitors and the resulting ECG changes.

These drugs are used for their antihypertensive action, explained by central and peripheral alpha 2-adrenergic agonist effects. In acute overdose they cause ECG changes, along with hypotension, and cardiac failure. Cardiac arrests have been described in adults with Clonidine poisoning. Over-the-counter topical decongestants commonly contain imidazoline derivatives (naphzoline, tetrahydrozoline, oxymetazoline, and xylometazoline), and can cause systemic toxicity after topical exposure, or ingestion, with sympatholytic effects, such as bradyarrhythmias and hypotension, related to central alpha 2-adrenergic and imidazoline receptor stimulation (Murphy et al., 2007; Wiley II, 2007).

**3.3 Sympathomimetic toxicity**

Sympathetic overactivity can be caused by a number of drugs and toxins (table 7), such as illicit drugs, and hydrocarbon solvents, but also by sedative drug withdrawal syndromes. The typical ECG changes are sinus and atrial tachycardia, and occasionally ventricular dysrrhythmias (in massive exposures). Sinus tachycardia may be the first manifestation of exposure to a sympathomimetic.



Sympathomimetic drugs and toxins	<ol style="list-style-type: none"> <li>1. Drugs: <ul style="list-style-type: none"> <li>- Monoamine oxidase inhibitors</li> <li>- Phenylpropanolamine and other over-the-counter sympathomimetics (decongestants containing phenylephrine, pseudoephedrine, ephedrine)</li> <li>- Theophylline</li> <li>- Ergot alkaloids</li> <li>- Beta-adrenoreceptor agonists (Albuterol, Dobutamine, Epinephrine, Isoproterenol, Norepinephrine, Ritodrine, Terbutaline)</li> <li>- Caffeine</li> <li>- Chloral hydrate (sedative and hypnotic drug)</li> </ul> </li> <li>2. Illicit drugs: <ul style="list-style-type: none"> <li>- Amphetamines</li> <li>- Cocaine</li> <li>- Phencyclidine</li> <li>- Delta-tetrahydrocannabinol (cannabis) - fig.17</li> <li>- Lysergic acid diethylamide</li> <li>- Psilocybin and other hallucinogens</li> </ul> </li> <li>3. Toxins: <ul style="list-style-type: none"> <li>- Ethanol</li> <li>- Hydrocarbon solvents (e.g. toluene, benzene, chloroform, etc.)</li> <li>- Freon (and other fluorocarbon aerosols)</li> </ul> </li> </ol>
ECG abnormalities	<p>Sinus tachycardia</p> <p>Sinoatrial slowing with escape junctional or ventricular rhythms (solvent inhalation)</p> <p>Atrial tachycardia - fig. 18</p> <p>Ventricular premature beats</p> <p>VT, VF</p> <p>Myocardial ischemia or infarction (cocaine, amphetamines, or hydrocarbons ingestion)</p>

Table 7. Sympathomimetic drugs and toxins and the resulting ECG changes.

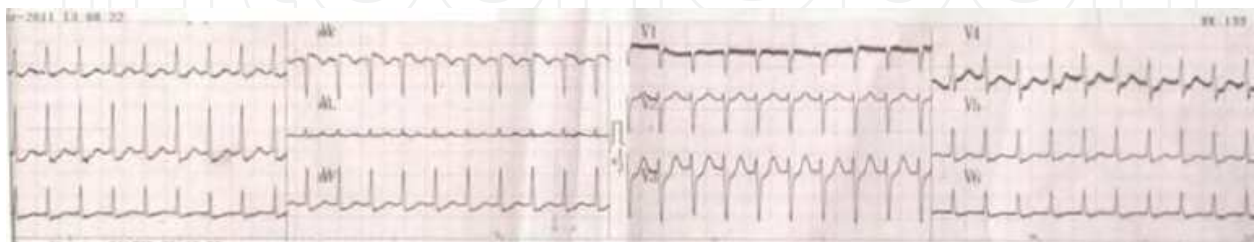


Fig. 17. Paroxysmal supraventricular tachycardia 169/min, in a young female with acute cannabis and ethanol poisoning.

However, other supraventricular or ventricular dysrhythmias may develop if an abnormal rhythm is generated in another part of the heart.

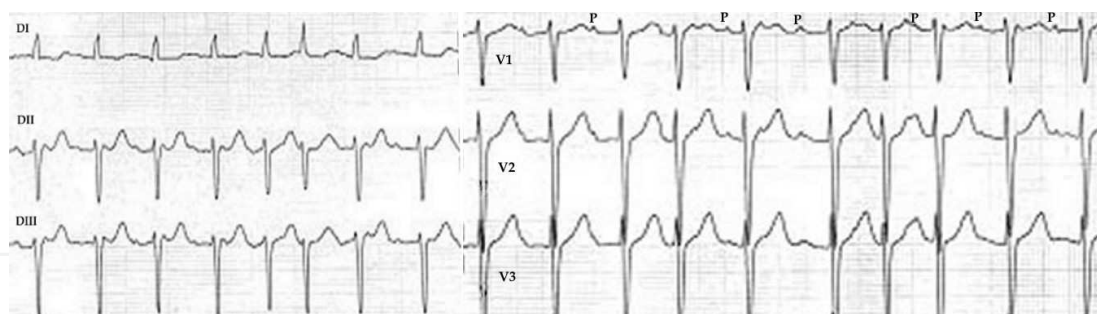


Fig. 18. Atrial tachycardia 150/min, with variable AV block, in a female with a chronic respiratory disease and Theophylline overdose.

Either as a result of excessive circulating catecholamines observed with cocaine and sympathomimetics, or myocardial sensitization secondary to halogenated hydrocarbons or thyroid hormone, or increased second-messenger activity secondary to theophylline, the extreme inotropic and chronotropic effects cause dysrhythmias. Altered repolarization, increased intracellular  $Ca^{2+}$  concentrations, or myocardial ischemia may cause the dysrhythmia. Additionally, cocaine that produce focal myocardial ischemia, can lead to malignant ventricular dysrhythmias (Clancy, 2007). In high dose, along with its potent sympathomimetic action, cocaine blocks fast  $Na^{+}$  channels in the myocardium, with a depression of depolarization, and slowing of conduction velocity, manifested on ECG with prolonged PR, QRS, and QT intervals (Murphy et al., 2007).

### 3.4 Anticholinergic toxicity

There are numerous and various anticholinergic drugs and toxins that may be ingested (table 8) and produce ECG abnormalities.

Anticholinergic drugs and toxins	<ol style="list-style-type: none"> <li>1. Drugs: <ul style="list-style-type: none"> <li>- Antihistamines</li> <li>- Atropine, scopolamine</li> <li>- Tricyclic antidepressants</li> <li>- Antipsychotics (e.g. Phenothiazines, Clozapine, Olanzapine)</li> </ul> </li> <li>2. Toxins: <ul style="list-style-type: none"> <li>- Toxic plants from Solanaceae family containing belladonna alkaloids: Belladonna (<i>Atropa belladonna</i>), Henbane (<i>Hyoscyamus niger</i>), Jimson Weed (<i>Datura stramonium</i>), Mandrake (<i>Mandragora officinarum</i>)</li> <li>- Toxic mushrooms: <i>Amanita muscaria</i></li> </ul> </li> </ol>
ECG changes	Sinus and atrial tachycardia Premature ventricular beats

Table 8. Drugs and toxins with anticholinergic effect, with induced ECG abnormalities.

They cause in most cases sinus tachycardia. Serious arrhythmias result from purely anticholinergic compound poisoning, especially in patients with underlying ischemic heart disease (e.g. atrial tachycardia and ventricular premature beats). Atropine, for example, increases myocardial oxygen demand secondary to tachycardia, and can lead to VT and fibrillation in patients after myocardial infarction. Patients presenting with anticholinergic

toxidrome (mydriasis, diminished bowel sounds, urinary retention, dry mouth, flushed skin, tachycardia, and agitation) may have ingested antihistamine-sympathomimetic combinations, or tricyclic antidepressants and neuroleptics, having both anticholinergic and membrane-depressant effects, which can explain the presence of serious cardiovascular disturbances (such as widening of the QRS complex, and a rightward deflection of the terminal 40 msec of the QRS complex, with prolongation of the QTc, which creates a substrate for the development of TdP). (Murphy et al., 2007; Juurlink, 2007)

### 3.5 Cholinomimetic toxicity

Poisoning by cholinomimetic drugs and toxins (table 9) lead to different ECG aspects. The most common type of cholinomimetic toxicity is poisoning with organophosphate and carbamate pesticides, resulting in the excessive inhibition of the cholinesterase. The ECG changes are unpredictable and often change over the time course of the poisoning.

Cholinomimetic drugs and toxins	<ol style="list-style-type: none"> <li>1. Drugs: <ul style="list-style-type: none"> <li>- Causing acetylcholine release (Alpha 2-adrenergic antagonists, Aminopyridines, Carbachol, Guanidine)</li> <li>- Direct muscarinic agonists (Pilocarpine, Bethanechol, Methacholine)</li> <li>- Direct nicotinic agonists (Carbachol, Succinylcholine)</li> <li>- Indirect neuronal nicotinic agonists (Chlorpromazine, local and volatile anesthetics, Ketamine)</li> <li>- Anticholinesterases (Pyridostigmine, Neostigmine, Physostigmine)</li> <li>- Central cholinesterase inhibitors (Rivastigmine, Galantamine, Donepezil)</li> </ul> </li> <li>2. Toxins: <ul style="list-style-type: none"> <li>- Organophosphate and carbamate pesticides</li> <li>- Nicotine</li> <li>- Muscarine</li> <li>- Black widow spider venom</li> <li>- Coniine (alkaloid found in poison hemlock and the yellow pitcher plant)</li> </ul> </li> </ol>
ECG abnormalities	<p>Sinus bradycardia  Atrial, junctional, or ventricular bradycardia  AV block  Sinus tachycardia (seen in early stages of cholinesterase inhibition and nicotine poisoning due to ganglionic stimulation)  VT associated with QT interval prolongation  Asystole</p>

Table 9. Cholinomimetic drugs and toxins, and ECG changes induced in acute exposure.

Early in the course, tachycardia is present, due to acetylcholine stimulation of nicotinic receptors, followed by bradycardia, secondary to muscarinic receptor stimulation. In severe poisonings, advanced AV block, bradydysrhythmias and asystole may occur (Murphy et al., 2007). Up to 5 days after exposure, QTc interval prolongation is followed by ventricular tachyarrhythmias (fig.19), including TdP (fig.10), due to persistent imbalance between sympathetic and parasympathetic influences on the heart, as well as dyselectrolytemias. A



rare feature is acute myocardial infarction (fig.20), with a complex mechanism (fig.21) explaining its presence (coronary spasm induced by parasympathetic hyperactivity, direct toxic effect of pesticide on myocardium).

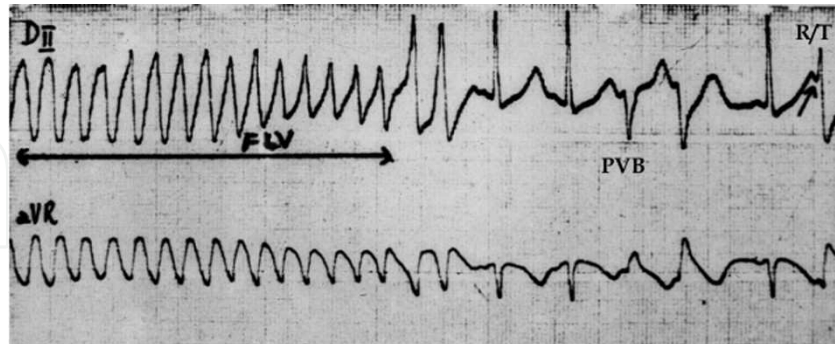


Fig. 19. Acute organophosphate poisoning, five days after exposure. ECG shows QT interval prolongation (0.60 sec), short episode of ventricular flutter (FLV), a couple of PVB, and one PVB with R on T phenomenon (R/T).

Patients with clinical signs of cholinesterase inhibition and abnormal ECG (including long QT interval) should be monitored continuously, because of the risk of developing ventricular arrhythmias (Lionte et al., 2007). Reversible acetylcholinesterase inhibitors, such as Donepezil, have a high selectivity for neuronal acetylcholinesterase, and in accidental overdose were reported to produce sinus bradycardia (Murphy et al., 2007).

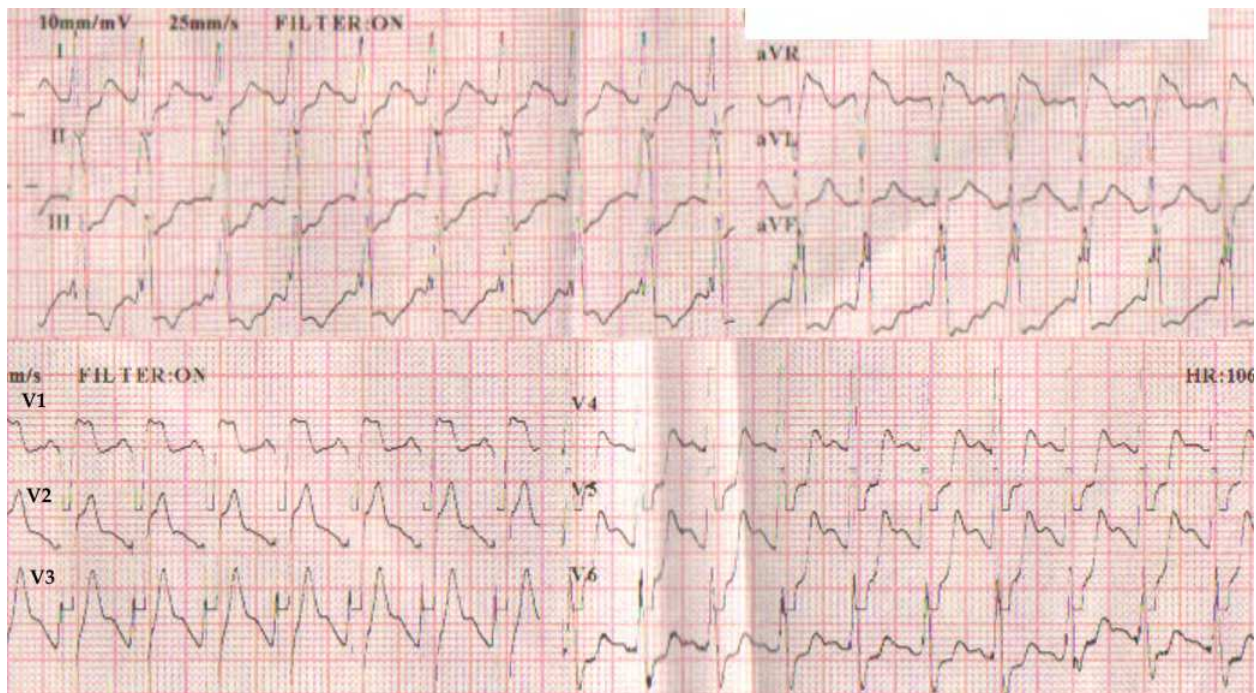


Fig. 20. Acute organophosphate poisoning, four days after exposure, serum cholinesterase normalized with antidote. ECG shows acute ST segment elevation anterior myocardial infarction (with increased cardiac enzymes), sinus tachycardia 106/min, QT interval 0.32 sec.

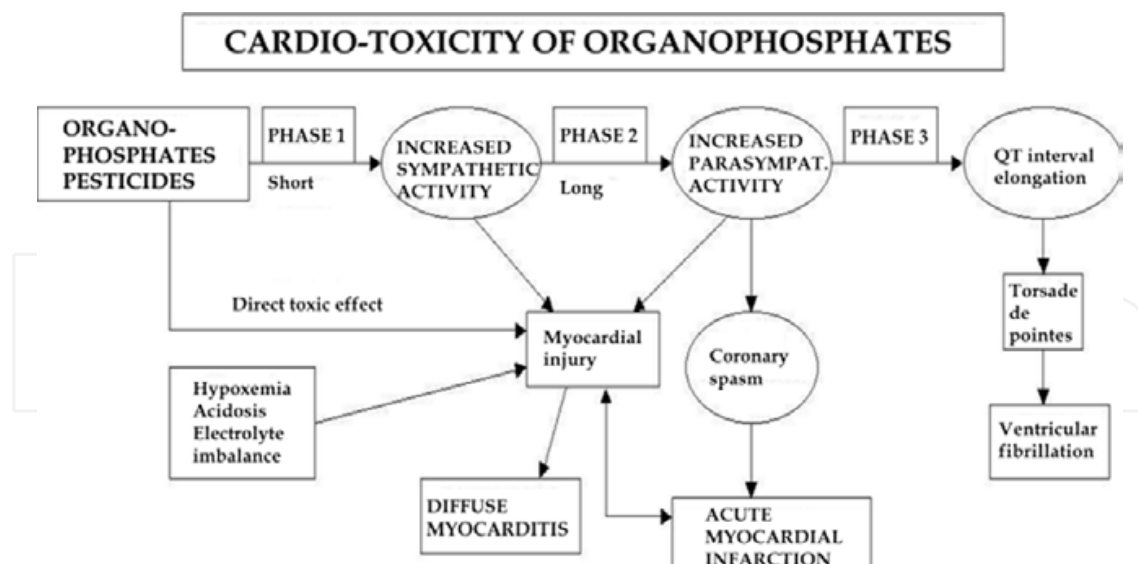


Fig. 21. Cardiac manifestations of organophosphate poisoning and mechanisms involved.

## 4. Other substances inducing ECG changes

### 4.1 Chemical asphyxiants

Chemical asphyxiants act in one of two ways. Some prevent the uptake of oxygen in the blood. Carbon monoxide interferes with the transport of oxygen to the tissues by strongly binding with hemoglobin to form carboxyhemoglobin, which leaves inadequate hemoglobin available for oxygen transport. Hydrogen cyanide does not permit the normal oxygen transfer either from the blood to the tissues or within the cell itself, resulting in tissue hypoxia. Acute exposure to these agents leads to coma and metabolic acidosis, the last explaining in part ECG abnormalities (table 10) recorded in such poisoning.

Chemical asphyxiants	ECG changes
Carbon monoxide (CO)	T wave flattening or inversion ST segment depression or elevation Conduction disturbance Myocardial infarction (fig.22, 23, 24) Arrhythmias occasionally (PVB, atrial fibrillation)
Hydrogen cyanide	Tachycardia (early) Bradycardia, heart block (late) Shortening of the ST segment with eventual fusion of the T wave into the QRS complex. Erratic supraventricular and ventricular arrhythmias Ischemic changes Asystole
Zinc phosphide	Atrial extrasystoles Ventricular arrhythmias ST/T changes (fig.25)

Table 10. Major chemical asphyxiants and their effect on ECG in acute poisoning (adapted from Hall, 2007; Murphy et al., 2007; Schraga et al., 2008)



Myocardial injury from CO poisoning results from tissue hypoxia, and as damage at the cellular level. The affinity of hemoglobin for CO is 200 to 250 times greater than its affinity for oxygen. This results in competitive inhibition of oxygen release due to a shift in the oxygen-hemoglobin dissociation curve, reduced oxygen delivery, and subsequent tissue hypoxia. In CO poisoning, magnitude of ST/T changes doesn't correlate with the severity of the myocardial impairment, other tests, such as echocardiography, being necessary. All cardiovascular changes are more prominent in patients with underlying cardiac pathology (Murphy et al., 2007; Satran et al., 2005).

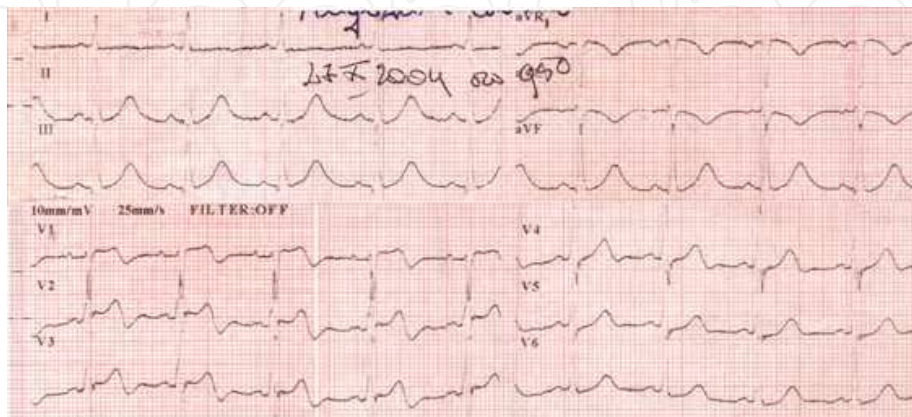


Fig. 22. ECG in acute CO poisoning, 24 hours after exposure (flattened T wave in DI, negative T wave in aVL, ST segment elevation and T wave changes in V1-V3).

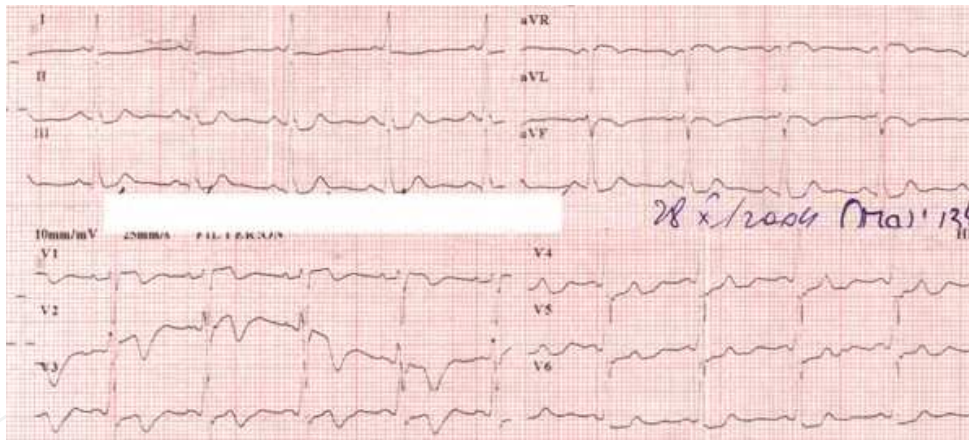


Fig. 23. ECG in acute CO poisoning, same patient, 52 hours after exposure. Note the evolution of ST/T changes in precordial leads.

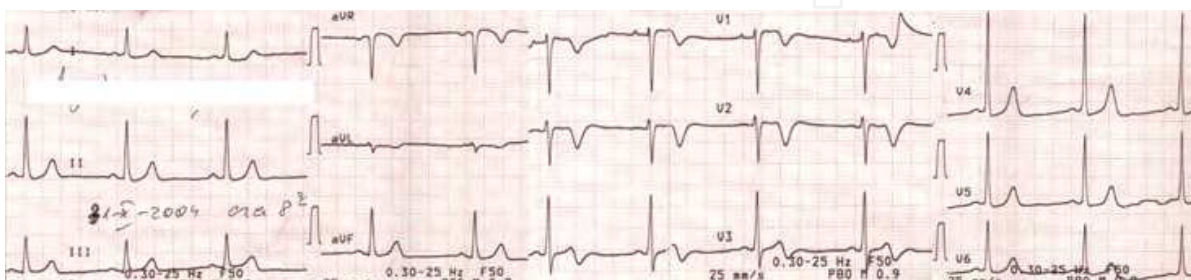


Fig. 24. Same patient, 4 days after exposure. Note the evolution of ST/T changes in precordial and lateral leads.



In humans, cyanide produces histotoxic hypoxia by combining with the ferric ion in mitochondrial cytochrome oxidase, preventing electron transport in the cytochrome system and bringing oxidative phosphorylation and ATP production to a halt. The inhibition of oxidative metabolism puts increased demands on anaerobic glycolysis, which results in lactic acid production and may produce severe acid-base imbalance. Myocardial depression with decreased cardiac output produces stagnation hypoxia. Abnormal heartbeat can occur in cases of severe poisoning. Bradycardia, intractable low blood pressure, and death may result (Hall, 2007).

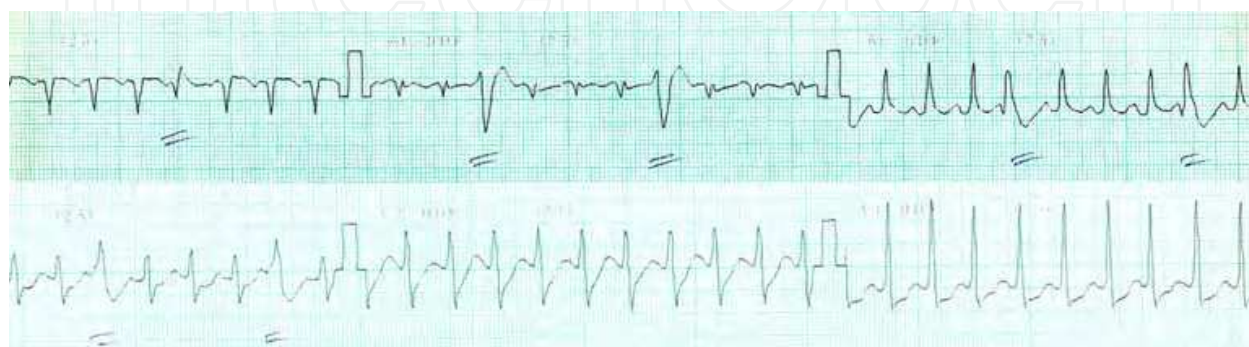


Fig. 25. Attempted suicide with zinc phosphide ingestion in a 19 years old female, presenting circulatory collapse and dyspnea. ECG (leads aVR, aVL, aVF, V1-V3) reveals tachycardia 160 /min with wide QRS complex, multiple PVC (trigeminy), some with R/T phenomenon, and ST/T changes.

Zinc phosphide is a highly effective insecticide and rodenticide. It is mediated by phosphine, which inhibits cytochrome C oxidase. It has been shown recently in nematodes that phosphine rapidly perturbs mitochondrial morphology, inhibits oxidative respiration by 70%, and causes a severe drop in mitochondrial membrane potential. This failure of cellular respiration is likely to be due to a mechanism other than inhibition of cytochrome C oxidase. In addition, phosphine and hydrogen peroxide can interact to form the highly reactive hydroxyl radical and phosphine also inhibits catalase and peroxidase; both mechanisms result in hydroxyl radical associated damage such as lipid peroxidation. The major lethal consequence of zinc phosphide ingestion, profound circulatory collapse, is secondary to factors including direct effects on cardiac myocytes, fluid loss, and adrenal gland damage. There is usually only a short interval between ingestion and the appearance of systemic toxicity. Phosphine-induced impairment of myocardial contractility and fluid loss leads to circulatory failure, and pulmonary edema. Metabolic acidosis, or mixed metabolic acidosis and respiratory alkalosis, are frequent, and contribute to ECG changes (Lionte et al., 2004; Proudfoot, 2009).

#### 4.2 Natural products

Many natural products and toxins have cardiovascular effects, leading to ECG changes (table 11). The clinical and myocardial histological manifestations of scorpion sting resemble those of catecholamine infusion. Myocardial infarction has been documented in scorpion envenomation with a pathophysiological mechanism involving transient myocardial “stunning” (Thomas et al., 2007).

Poisonous animals and plants	ECG abnormalities
Poisonous scorpion stings (venom)	Sinus tachycardia, conduction abnormalities, ST/T changes with peaked T waves, QT prolongation, atrial and ventricular arrhythmias, myocardial infarction
Black widow spider bites (venom)	Tachycardia Atrial arrhythmias
<i>Hymenoptera</i> (bees and wasps) stings (venom)	Tachycardia, dysrhythmias, myocardial infarction
Ciguatera fish (ciguatoxin)	Bradycardia, arrhythmias
Puffer fish (tetrodotoxin)	Bradycardia, arrhythmias
Scombroid fish (scombrototoxin)	Bradycardia, sinus tachycardia, ventricular arrhythmias, acute myocardial infarction (fig.26)
Aconite poisoning (Chinese herbs or teas that contain <i>Aconitum carmichaelii</i> or <i>A. kusnezoffii</i> )	Bradycardia VT (monomorphic or polymorphic) VF

Table 11. ECG changes induced by natural products poisoning (adapted from Hahn, 2007; Lionte, 2010; Murphy et al., 2007; Wandersee, 2006).

In the pathogenesis of clinical syndrome produced by black widow spider bites was suggested to be also involved an excess of catecholamines, while in patients affected by *Hymenoptera* stings, histamine plays a role in pathogenesis.

Fish-borne poisoning has multiple pathogenic mechanisms, depending on the toxin involved. Some of these toxins are heat stable, therefore unaffected by cooking, and gastric acid, while others produce the poisoning because of improper fish handling.

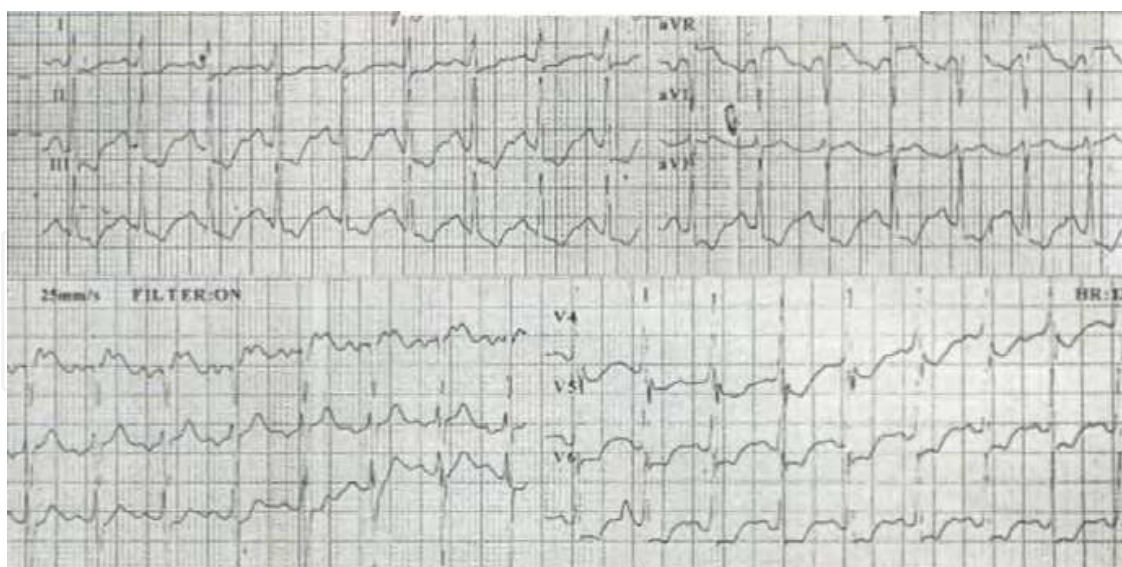


Fig. 26. Scombroid fish poisoning, 1 hour after ingestion, in a young female, presenting chest pain and hypotension (BP 70/45 mmHg). ECG reveals signs of subendocardial myocardial infarction (sustained by enzymatic evidence), and sinus tachycardia 139/min.

Aconite poisoning results from alkaloids contained in teas and herbs, which are not boiled enough before ingestion, such as aconitine and mesaconitine (Murphy et al., 2007).

Aconitine has Na<sup>+</sup> channel-binding properties (maintaining them in an open position), which explain, in part, its neurological and cardiovascular toxicity (cardiodepressant effects). Vagal stimulation is also involved in pathogenesis of aconitine poisoning. Aconitine has a propensity to cause early and delayed after-depolarizations in ventricular myocytes that may be due to increased intracellular Ca<sup>2+</sup> and Na<sup>+</sup>. This explains the presence of biventricular tachycardia and TdP on ECG (Smolinske et al., 2007).

#### 4.3 Drugs of abuse

Some of the most commonly abused drugs are alcohol, nicotine, marijuana, amphetamines, cocaine, opium alkaloids and synthetic opioids, gamma-hydroxybutyrate, 3,4-methylenedioxymethamphetamine (MDMA, ecstasy), and phencyclidine. Drug abuse may lead to organ damage, addiction, and disturbed patterns of behavior. Some illicit drugs, such as heroin, lysergic acid diethylamide, and phencyclidine hydrochloride, have no recognized therapeutic effect in humans. Cardiovascular toxicity of illicit drugs relies on multiple pathophysiological mechanisms. Table 12 presents major categories of drugs, and the ECG abnormalities reported in acute setting.

Illicit drug	ECG
Amphetamines and derivatives (including "ecstasy")	Sinus tachycardia and supraventricular tachyarrhythmias Myocardial ischemia, and infarction PVB and ventricular tachydysrhythmias
Cannabis (marijuana)	Tachycardia (fig. 17) Non-specific ST/T changes PVC (occasional) and AF
Cocaine	Sinus bradycardia, complete heart block, bundle branch block Prolonged QTc, and QRS Supraventricular tachyarrhythmias VT or fibrillation Myocardial infarction
Gamma-hydroxybutyrate (GHB)	Bradycardia Transient P wave inversion in DII, right bundle branch block, ST-segment elevation (pediatric) U waves (in adults) First degree AV block, transient AF (rare)
Hallucinogens	Tachycardia
Opiates and opioids	Bradycardia (opioids) Cardiac conduction abnormalities and dysrhythmias (heroin) Prolonged QT interval and TdP (methadone) QRS prolongation, dysrhythmias (Propoxyphene) Tachycardia (Tramadol)

Table 12. Drugs of abuse and consequent ECG changes in acute poisoning (adapted from Albertson, 2004; Albertson et al., 2007, a; Delgado, 2007; Quang, 2007; Traub, 2007; Yip et al., 2007).

Amphetamine and related drugs activate the sympathetic nervous system via central nervous system stimulation, peripheral release of catecholamines, inhibition of neuronal reuptake of catecholamines, and inhibition of monoamine oxidase. Fenfluramine and dexfenfluramine cause serotonin release and block neuronal serotonin uptake. Methamphetamine (crank, speed), 3,4-methylenedioxyamphetamine (MDMA, ecstasy), and several other amphetamine derivatives (Lysergic Acid Diethylamide), as well as a number of prescription drugs, are used orally and intravenously as illicit stimulants. "Ice" is a smokable form of methamphetamine (Albertson, 2004). Direct catecholamine effects, and ischemic effects, after coronary vasospasm explain arrhythmias, in amphetamine use. The last is involved in the pathogenesis of myocardial infarction after amphetamine use, together with direct cardiac toxicity (myocarditis), and thrombus formation (Albertson et al., 2007, b).

Most of the hallucinogens are indoleamine or phenylethylamine derivatives, structurally similar to the neurotransmitter serotonin. Commonly used hallucinogens include lysergic acid diethylamide (LSD), mescaline, 5-methoxy-N,N-diisopropyltryptamine, and psilocybin ("magic mushrooms"). They produce a variety of autonomic effects, both parasympathetic and sympathetic (Traub, 2007).

Cocaine is one of the most popular drugs of abuse. Rapidly after smoking or intravenous injection (mediated by sympathetic overactivity) appear cardiovascular signs of toxicity. Coronary artery spasm and/or thrombosis may result in myocardial infarction, even in patients with no coronary disease. Chest pain with electrocardiographic evidence of ischemia or infarction in a young, otherwise healthy person suggests cocaine use (Benowitz, 2004). At low doses, occur sinus bradycardia and ectopic rhythms, based on cocaine's local anesthetic properties and its effects on catecholamines. At high doses, cocaine produces direct Na<sup>+</sup> and K<sup>+</sup> channel blockade (see section 3.3). Enhanced sympathetic stimulation will increase intracellular Ca<sup>2+</sup> within myocardial cells, and will enhance automaticity, leading to afterdepolarizations, and ectopic rhythms (Albertson et al., 2007, a).

The cannabinoid delta 9-tetrahydrocannabinol (THC) is the principal psychoactive constituent of *Cannabis sativa* (marijuana consists of the leaves and flowering parts of the plant). Cardiovascular toxicity is dose-related, and is explained by stimulation of the autonomic nervous system, involving both parasympathetic and sympathetic pathways. The effects tend to be more serious in patients with preexisting cardiovascular pathology (for example, an increased risk of myocardial infarction was reported in the hour following marijuana use), but in young, healthy patients, these effects have no serious consequences (Delgado, 2007).

Opiates are a group of naturally occurring compounds derived from the juice of the poppy *Papaver somniferum*. The term opioid refers to these and other derivatives of naturally occurring opium (e.g., morphine, heroin, codeine, and hydrocodone) as well as new, totally synthetic opiate analogs (e.g., fentanyl, butorphanol, meperidine, methadone, and propoxyphene). In general, opioids share the ability to stimulate a number of specific opiate receptors in the CNS. With mild or moderate overdose, pulse rate is decreased. Cardiotoxicity similar to that seen with tricyclic antidepressants and quinidine can occur in patients with severe propoxyphene intoxication. Heroin and propoxyphene toxicity is associated with ECG changes, such as non-specific ST/T wave abnormalities, first-degree AV block, AF, prolonged QTc intervals, and ventricular dysrhythmias. In the pathogenesis of these cardiovascular findings contribute electrolyte, and metabolic derangements, hypoxia, or adulterants (e.g. quinine) found in street drugs (Yip et al., 2007).



## 5. Conclusions


ECG is a valuable source of information in poisoned patients and has the potential to enhance and direct their care. Although it seems obvious that an ECG is required following exposure to a drug used for cardiovascular indications, many drugs with no overt cardiovascular effects from therapeutic dosing become cardiotoxic in overdose. An ECG should be examined extremely early in the initial evaluation of most poisoned patients.

## 6. References

- Albertson, T.E. (2004). Amphetamines, In: *Poisoning & Drug Overdose, 4<sup>th</sup> Ed.*, Olson, K.R. et al. (Eds.), pp. 72-74, Lange Medical Books/McGraw-Hill, ISBN 0-8385-8172-2, New York, USA.
- Albertson, T.E.; Chan, A. & Tharratt, R.S. (2007). Cocaine, In: *Haddad and Winchester's Clinical Management of Poisoning and Drug Overdose (4<sup>th</sup> Ed.)*, Shannon, M.W. et al. (Eds.), pp. 755-772, Saunders Elsevier, ISBN 978-0-7216-0693-4, Philadelphia, USA.
- Albertson, T.E.; Kenyon, N.J. & Morrissey, B. (2007). Amphetamines and derivatives, In: *Haddad and Winchester's Clinical Management of Poisoning and Drug Overdose (4<sup>th</sup> Ed.)*, Shannon, M.W. et al. (Eds.), pp. 781-792, Saunders Elsevier, ISBN 978-0-7216-0693-4, Philadelphia, USA.
- Anderson, A.C. (2008). Management of Beta-Adrenergic Blocker Poisoning. *Clinical Pediatric Emergency Medicine*, Vol. 9, No. 1, (March, 2008), pp.4-16, ISSN 1522-8401.
- Benowitz, N.L. (2004). Cocaine, In: *Poisoning & Drug Overdose, 4<sup>th</sup> Ed.*, Olson, K.R. et al. (Eds.), pp. 171-173, Lange Medical Books/McGraw-Hill, ISBN 0-8385-8172-2, New York, USA.
- Berkovitch, M., et al. (1995). Assessment of the terminal 40-millisecond QRS vector in children with a history of tricyclic antidepressant ingestion. *Pediatric Emergency Care*, Vol.11, No.2, (Apr 1995), pp.75-77, ISSN 0749-5161.
- Bird, S.B.(2007). Beta-Adrenergic antagonists, In: *Haddad and Winchester's Clinical Management of Poisoning and Drug Overdose (4<sup>th</sup> Ed.)*, Shannon, M.W. et al. (Eds.), pp. 975-982, Saunders Elsevier, ISBN 978-0-7216-0693-4, Philadelphia, USA.
- Brubacher, J.R. (2007). Beta-adrenergic antagonists, In: *Goldfrank's Manual of Toxicologic Emergencies*, Hoffman R.S. et al. (Eds.), pp. 518-529, The McGraw-Hill Companies, Inc., <http://www.mhprofessional.com/product.php?cat=116&isbn=007144310X>.
- Chung, D.C. (1981). Anaesthetic problems associated with the treatment of cardiovascular disease: I. Digitalis toxicity. *Can Anaesth Soc J.*, Vol. 28, No.1, (Jan 1981), pp.6-16, ISSN 0008-2856.
- Clancy, C. (2007). Electrocardiographic principles, In: *Goldfrank's Manual of Toxicologic Emergencies*, Hoffman R.S. et al. (Eds.), pp. 29-40, The McGraw-Hill Companies, Inc., <http://www.mhprofessional.com/product.php?cat=116&isbn=007144310X>.
- Delgado, J. (2007). Marijuana, In: *Haddad and Winchester's Clinical Management of Poisoning and Drug Overdose (4<sup>th</sup> Ed.)*, Shannon, M.W. et al. (Eds.), pp. 747-754, Saunders Elsevier, ISBN 978-0-7216-0693-4, Philadelphia, USA.
- Delk, C.; Holstege, C.P. & Brady, W.J. (2007). Electrocardiographic abnormalities associated with poisoning. *American Journal of Emergency Medicine*, Vol.25, No. 6, (July 2007), pp. 672-687, ISSN 0735-6757.

- Gordon, B. (2006). Cardiovascular drugs, In: *The Toxicology Handbook for Clinicians*, Harris, C.R. (Ed.), pp. 61-75, Mosby Elsevier, ISBN 1-56053-711-6, Philadelphia, USA.
- Hahn, I-H. (2007). Arthropods, In: *Goldfrank's Manual of Toxicologic Emergencies*, Hoffman R.S. et al. (Eds.), pp. 901-911, The McGraw-Hill Companies, Inc., <http://www.mhprofessional.com/product.php?cat=116&isbn=007144310X>.
- Hall, A.H. (2007). Cyanide and related compounds - sodium azide, In: *Haddad and Winchester's Clinical Management of Poisoning and Drug Overdose* (4<sup>th</sup> Ed.), Shannon, M.W. et al. (Eds.), pp. 1309-1316, Saunders Elsevier, ISBN 978-0-7216-0693-4, Philadelphia, USA.
- Holstege, C.; Baer, A. & Brady, W.J. (2005). The electrocardiographic toxidrome: the ECG presentation of hydrofluoric acid ingestion. *American Journal of Emergency Medicine*, Vol. 23, No.2, (March 2005), pp.171-176. ISSN 0735-6757.
- Holstege, C.P.; Eldridge, D.L. & Rowden, A.K. (2006). ECG manifestations: the poisoned patient. *Emergency Medicine Clinics of North America*, Vol.24, No.1, (Feb 2006), pp.159-177, ISSN 0733-8627.
- Juurink, D.N. (2007). Antipsychotics, In: *Goldfrank's Manual of Toxicologic Emergencies*, Hoffman R.S. et al. (Eds.), pp. 583-590, The McGraw-Hill Companies, Inc., <http://www.mhprofessional.com/product.php?cat=116&isbn=007144310X>.
- Lapostolle, F. & Borron, S.W. (2007). Digitalis, In: *Haddad and Winchester's Clinical Management of Poisoning and Drug Overdose* (4<sup>th</sup> Ed.), Shannon, M.W. et al. (Eds.), pp. 949-962, Saunders Elsevier, ISBN 978-0-7216-0693-4, Philadelphia, USA.
- Liebelt, E.L.; Francis, P.D & Woolf, A.D. (1995). ECG Lead aVR versus QRS interval in predicting seizures and arrhythmias in acute tricyclic antidepressant toxicity. *Annals of Emergency Medicine*, Vol. 26, No.2, (Aug 1995), pp. 195-201, ISSN 0196-0644.
- Lionte, C. (2010). An unusual cause of hypotension and abnormal electrocardiogram (ECG) – scombroid poisoning. *Central European Journal of Medicine*, Vol. 5, No. 3, (June 2010), pp. 292-297, ISSN 1895-1058.
- Lionte, C., et al. (2007). Electrocardiographic changes in acute organophosphate poisoning. *Revista Medico-Chirurgicala a Societatii de Medici si Naturalisti Iasi*, Vol.111, No.4, (Oct-Dec, 2007), pp. 906-911, ISSN 0048-7848.
- Lionte, C.; Sorodoc, L. & Laba, V. (2004). Zinc phosphide poisoning - diagnosis, complications, management. *Terapeutica, Farmacologie si Toxicologie Clinica*, Vol. VIII, No. 4, (Dec 2004), pp. 87-91, ISSN 1583-0012.
- Litonjua, R.M., et al. (2005). Digoxin: The Monarch of Cardiac Toxicities. *Journal of Pharmacy Practice*, Vol. 18, No. 3, (June 2005), pp.157-168, ISSN 0897-1900.
- Murphy, N.G; Benowitz, N.L. & Goldschlager, N. (2007). Cardiovascular toxicology, In: *Haddad and Winchester's Clinical Management of Poisoning and Drug Overdose* (4<sup>th</sup> Ed.), Shannon, M.W. et al. (Eds.), pp. 133-165, Saunders Elsevier, ISBN 978-0-7216-0693-4, Philadelphia, USA.
- Patel, M.M. & Benowitz, N. (2005). Cardiac conduction and rate disturbances, In: *Critical care toxicology: diagnosis and management of the critically poisoned patient*, Brent, J. et al. (Eds.), pp. 241-260, Elsevier Mosby, ISBN 0-8151-4387-7, Philadelphia, USA.
- Proudfoot, A.T. (2009). Aluminium and zinc phosphide poisoning. *Clin Toxicol (Phila)*. Vol. 47, No.2, (Feb 2009), pp. 89-100, ISSN 1556-3650.

- Quang, L.S. (2007). GHB and related compounds, In: *Haddad and Winchester's Clinical Management of Poisoning and Drug Overdose* (4<sup>th</sup> Ed.), Shannon, M.W. et al. (Eds.), pp. 803-823, Saunders Elsevier, ISBN 978-0-7216-0693-4, Philadelphia, USA.
- Roden, D.M. (2004). Drug-induced prolongation of the QT interval. *New England Journal of Medicine*, Vol. 350, No.10, (March, 2004), pp.1013-1022, ISSN 0028-4793.
- Satran, D. et al. (2005). Cardiovascular Manifestations of Moderate to Severe Carbon Monoxide Poisoning. *Journal of the American College of Cardiology*, Vol. 45, No. 9, (June 2005), pp. 1513–1516, ISSN 0735-1097.
- Schraga, E.D. et al. (Updated: Mar 11, 2008). Hydrogen Cyanide Poisoning, In: *Medscape Reference*, accessed 16 April, 2011, <http://emedicine.medscape.com/article/832840-overview>.
- Smolinske, S.C.; Daubert, G.P. & Spoerke, D.G. (2007). Poisonous plants, In: *Haddad and Winchester's Clinical Management of Poisoning and Drug Overdose* (4<sup>th</sup> Ed.), Shannon, M.W. et al. (Eds.), pp. 473-506, Saunders Elsevier, ISBN 978-0-7216-0693-4, Philadelphia, USA.
- Thomas, J.D.; Thomas, K.E. & Kazzi, Z.N. (2007). Scorpion and stinging insects, In: *Haddad and Winchester's Clinical Management of Poisoning and Drug Overdose* (4<sup>th</sup> Ed.), Shannon, M.W. et al. (Eds.), pp. 440-454, Saunders Elsevier, ISBN 978-0-7216-0693-4, Philadelphia, USA.
- Traub, S.J. (2007). Hallucinogens, In: *Haddad and Winchester's Clinical Management of Poisoning and Drug Overdose* (4<sup>th</sup> Ed.), Shannon, M.W. et al. (Eds.), pp. 793-802, Saunders Elsevier, ISBN 978-0-7216-0693-4, Philadelphia, USA.
- Wandersee, S. (2006). Toxic foods, In: *The Toxicology Handbook for Clinicians*, Harris, C.R. (Ed.), pp. 194-204, Mosby Elsevier, ISBN 1-56053-711-6, Philadelphia, USA.
- Wiley II, J.F. (2007). Clonidine and related imidazoline derivatives, In: *Haddad and Winchester's Clinical Management of Poisoning and Drug Overdose* (4<sup>th</sup> Ed.), Shannon, M.W. et al. (Eds.), pp. 1001-1008, Saunders Elsevier, ISBN 978-0-7216-0693-4, Philadelphia, USA.
- Wolfe, T.R.; Caravati, E.M. & Rollins, D.E. (1989). Terminal 40-ms frontal plane QRS axis as a marker for tricyclic antidepressant overdose. *Annals of Emergency Medicine*, Vol.18, No.4, (Apr 1989), pp.348–351, ISSN 0196-0644.
- Yip, L.; Mégarbane, B. & Borron, S.W. (2007). Opioids, In: *Haddad and Winchester's Clinical Management of Poisoning and Drug Overdose* (4<sup>th</sup> Ed.), Shannon, M.W. et al. (Eds.), pp. 635-658, Saunders Elsevier, ISBN 978-0-7216-0693-4, Philadelphia, USA.



## **Advances in Electrocardiograms - Clinical Applications**

Edited by PhD. Richard Millis

ISBN 978-953-307-902-8

Hard cover, 328 pages

**Publisher** InTech

**Published online** 25, January, 2012

**Published in print edition** January, 2012

Electrocardiograms have become one of the most important, and widely used medical tools for diagnosing diseases such as cardiac arrhythmias, conduction disorders, electrolyte imbalances, hypertension, coronary artery disease and myocardial infarction. This book reviews recent advancements in electrocardiography. The four sections of this volume, Cardiac Arrhythmias, Myocardial Infarction, Autonomic Dysregulation and Cardiotoxicology, provide comprehensive reviews of advancements in the clinical applications of electrocardiograms. This book is replete with diagrams, recordings, flow diagrams and algorithms which demonstrate the possible future direction for applying electrocardiography to evaluating the development and progression of cardiac diseases. The chapters in this book describe a number of unique features of electrocardiograms in adult and pediatric patient populations with predilections for cardiac arrhythmias and other electrical abnormalities associated with hypertension, coronary artery disease, myocardial infarction, sleep apnea syndromes, pericarditides, cardiomyopathies and cardiotoxicities, as well as innovative interpretations of electrocardiograms during exercise testing and electrical pacing.

### **How to reference**

In order to correctly reference this scholarly work, feel free to copy and paste the following:

Catalina Lionte, Cristina Bologna and Laurentiu Sorodoc (2012). Toxic and Drug-Induced Changes of the Electrocardiogram, *Advances in Electrocardiograms - Clinical Applications*, PhD. Richard Millis (Ed.), ISBN: 978-953-307-902-8, InTech, Available from: <http://www.intechopen.com/books/advances-in-electrocardiograms-clinical-applications/toxic-and-drug-induced-changes-of-electrocardiogram>

**INTECH**  
open science | open minds

### **InTech Europe**

University Campus STeP Ri  
Slavka Krautzeka 83/A  
51000 Rijeka, Croatia  
Phone: +385 (51) 770 447  
Fax: +385 (51) 686 166  
[www.intechopen.com](http://www.intechopen.com)

### **InTech China**

Unit 405, Office Block, Hotel Equatorial Shanghai  
No.65, Yan An Road (West), Shanghai, 200040, China  
中国上海市延安西路65号上海国际贵都大饭店办公楼405单元  
Phone: +86-21-62489820  
Fax: +86-21-62489821



© 2012 The Author(s). Licensee IntechOpen. This is an open access article distributed under the terms of the [Creative Commons Attribution 3.0 License](#), which permits unrestricted use, distribution, and reproduction in any medium, provided the original work is properly cited.

IntechOpen

IntechOpen