

We are IntechOpen, the world's leading publisher of Open Access books Built by scientists, for scientists

4,800

Open access books available

122,000

International authors and editors

135M

Downloads

Our authors are among the

154

Countries delivered to

TOP 1%

most cited scientists

12.2%

Contributors from top 500 universities



WEB OF SCIENCE™

Selection of our books indexed in the Book Citation Index
in Web of Science™ Core Collection (BKCI)

Interested in publishing with us?
Contact book.department@intechopen.com

Numbers displayed above are based on latest data collected.

For more information visit www.intechopen.com



Titanium and Yellow Nail Syndrome

Fredrik Berglund
*Swedish Society of Dental Amalgam Patients, Trollhättan,
 Sweden*

1. Introduction

Yellow nail syndrome was defined in 1964 as a combination of slow growing, discoloured nails and edema (Samman & White, 1964). The rate of growth of finger nails was less than 0.2 mm per week compared with the normal 0.5-1.2 mm per week. The nails were thickened and the cuticles were deficient. The color varied from pale yellow to slightly greenish. Onycholysis (separation of the nail from its bed) and shedding of one or more nails was mentioned. - Of the 13 patients with yellow nails 10 presented with edema, mainly in the ankles.

Subsequently, several symptoms were described and included. *Sinusitis* was reported by Wells (Wells,1966), although clearly he did not recognize it as part of the syndrome. Chronic intermittent *cough* with sputum production was reported by Zerfas (Zerfas, 1966), and in combination with *sinusitis* and *bronchitis* by Dilley et al (Dilley et al.,1968). Hiller et al. (1972) emphasized that chronic cough was a persistent finding in all their patients.

Pleural effusion in combination with lymphedema was reported in three patients by Emerson (Emerson,1966). The pleural fluid was clear, with a protein content of 4-9 mg/100 ml. The predominant cell was the lymphocyte. The effusion always re-accumulated after drainage.

Pericardial effusion in addition to pleural effusions and lymphedema was reported by Wakasa et al. (1987).

1.1 Symptom frequency in published papers

In 78 papers listed in PubMed from 1964 to 2009 there were 185 patients diagnosed with yellow nail syndrome: 18 % with yellow nails only, 42 % together with lymphedema, 21 % together with pleural effusion, and 19 % with the complete triad yellow nails-lymphedema-pleural effusion. Thus lymphedema was diagnosed totally in 61 %. Cough and sinusitis were diagnosed in 32 %.

Among several authors reporting sinusitis, some mention radiography revealing mucoid thickening of one or more sinuses (Nakielna et al, 1976, Hassard et al,1984, Camilleri, 1990, Varney et al, 1994, Cebeci et al, 2009). Varney et al. – at a Nose Clinic in London – reported that 14 out of 17 patients with yellow nail syndrome suffered severe rhinosinusitis, which predated nail changes in four, coincided with yellow nails in six, and occurred later in the remaining seven patients.

Among my patients, sinusitis and cough were the most common symptoms (Berglund & Carlmark, 2011). Several patients spontaneously mention postnasal drip and a “strange cough” as a main feature, often starting half a year after a titanium implant or start of medication with drugs containing titanium dioxide.

2. Etiology: Titanium and titanium dioxide

Since 1997 I have seen 35 patients with one or more of the symptoms or signs mentioned above. Twenty-seven patients had titanium implants, whereas eight were exposed to titanium dioxide.

Titanium in nail clippings or shed nails from the patients was analyzed by energy dispersive x-ray fluorescence (Forsell et al., 1997). It was present in the nails in concentrations varying between 1 and 170 $\mu\text{g/g}$, with a median level of 5 $\mu\text{g/g}$ (Berglund & Carlmark, 2011). Shed nails had high levels (46, 41, 22 and 6 $\mu\text{g/g}$), but some nail clippings had even higher levels (170, 120 and 111 $\mu\text{g/g}$). Titanium levels do not seem to correlate with yellowness or thickness of nails. Titanium was not found in nails from healthy subjects, not even if exposed to titanium + gold (one subject) or to drugs with titanium dioxide.

In two patients titanium was analyzed in separate nail clippings of the left hand. The thumbnail had higher level (5.6 and 4.1 $\mu\text{g/g}$) than the other nails (2.8 - 3.2 and 3.1 - 4.1 $\mu\text{g/g}$, respectively). In two patients the levels in clippings from thumb and big toe were identical (1.7 $\mu\text{g/g}$) or nearly identical (1.7 versus 1.6 $\mu\text{g/g}$). In one patient the titanium level was 48 $\mu\text{g/g}$ in a shed nail, but only 6.7 $\mu\text{g/g}$ in fresh clippings. Nowadays I ask for clippings from the left thumbnail, except when shed nails are available.

2.1 Titanium metal

Titanium (Ti): atomic weight 47.9, atomic number 22, specific gravity 4.54. When pure, titanium is a lustrous, white metal. It is 60 % heavier than aluminum, but twice as strong. Titanium is a much harder metal than aluminum and approaches the high hardness possessed by some of the heat-treated steels, which causes some difficulties in dentistry. Its modulus of rigidity falls between that of aluminum and that of steel. The high ductility enables the use of titanium in cochlear implant electrodes. Since it is non-ferromagnetic, patients with titanium implants can be safely examined with magnetic resonance imaging.

Titanium is quite sensitive to galvanic corrosion, e.g. by other metals and fluorine. This is to be expected when comparing their reduction potentials.

2.2 Reduction potentials (Hunsburger, 1976)

Our body shows high electrical conductivity. This enables our recording of the electrocardiogram through electrodes applied to the skin. The higher resistance in the skin is abolished by perspiration (hypotonic saline). The presence of metals with different reduction potentials may give rise to galvanic phenomena within the body or across the skin. (A young man with a gold ring in one ear experienced a buzzing

sensation in the ear while holding a coca-cola can for a while in his hand). Ions of different sorts can be introduced through the skin by means of electric current, so-called iontophoresis.

Reaction	Potential (Volts)
$\text{Ti}^{+2} + 2\text{e}^- \rightleftharpoons \text{Ti}$	-1.63
$\text{TiO}_2 + 4\text{H}^+ + 4\text{e}^- \rightleftharpoons \text{Ti} + 2\text{H}_2\text{O}$	-0.86
$\text{Ag}^+ + \text{e}^- \rightleftharpoons \text{Ag}$	+0.80
$\text{Hg}^{+2} + 2\text{e}^- \rightleftharpoons \text{Hg}$	+0.85
$\text{Au}^+ + \text{e}^- \rightleftharpoons \text{Au}$	+1.69
$\text{F}_2 + 2\text{e}^- \rightleftharpoons 2\text{F}^-$	+2.87

2.3 Titanium implant patients

My first patient got a titanium and a cobalt-chromium implant in her right knee. Half a year later she developed a persistent cough. Later her nails became thick and yellow, and a few nails were shed. She had gold in many of her teeth. Analysis for metals in nail clippings revealed high levels of titanium (Berglund & Carlmark, 2011). Three years later she had normal nails and no cough, but her knee implant had loosened. She got a new implant, and a year later she had her cough and yellow nails again.

The dominant cause of yellow nail syndrome in my patients was the galvanic interaction between titanium implants and gold. There were 23 females and 4 males, aged 15-86 years at onset of symptoms. Most titanium implants were in the teeth (pins or crowns) or in the jaw bones, but also in the knees and hips, or in the abdomen (clips and staples) after laparoscopic surgery. In one patient there was iontophoresis of titanium ions from titanium spectacles to gold in the teeth.

The gold electrodes were present mostly as dental inlays and crowns, but in two patients as wedding or engagement rings. Some patients reported intolerance to gold jewelry. Patch tests with gold cannot be done in titanium implant patients. In three patients amalgam, which contains silver and mercury, formed the electric circuit with titanium. I always advise patients with amalgam or titanium not to wear metal jewelry. In three patients the local application of fluoride gel caused release of titanium from titanium inlays in the teeth. In vitro, the oxidative release of titanium ions from titanium increases sharply in the presence of fluoride (Reclaru & Meyer, 1998, Strietzel et al., 1998, Schiff et al., 2002).

Most patients with titanium implants suspected metal involvement and contacted me through the Swedish Society of Dental Amalgam Patients. However, in published papers most patients were probably exposed to titanium dioxide.

2.4 Titanium dioxide: Uses and intestinal uptake

Titanium dioxide, TiO_2 , is insoluble in water and acid but soluble in alkali. Because of its brightness and high refractive index it is the most widely used white pigment. Titanium dioxide is widely used in the food and drug industry as a whitening agent and is given the European food additive number E171.

After oral administration of titanium dioxide to rats, particles of titanium dioxide were present in the gut associated lymphoid tissue, but also in the liver, spleen, lungs and peritoneal tissues, but were not detected in the heart or the kidney (Jani et al., 1994).

Titanium, together with aluminum, has consistently been found in lymphoid tissue of the ileum and in mesenteric lymph glands in patients with intestinal disease and in postmortem cases with no evidence of gastrointestinal disease (Shepherd et al., 1987). After administration of gelatin capsules with 23 mg titanium dioxide (mean particle size 0.16 μm) to five male subjects, blood levels of titanium rose from 12 $\mu\text{g/L}$ to 43 $\mu\text{g/L}$ at 4-12 hours (Böckmann et al., 2000). The concentration/time curves were considered to be characteristic for a persorption mechanism (absorption in pores only slightly wider than the diameter of absorbed molecules).

2.5 Titanium dioxide patients

Several papers mention the exposure to drugs preceding the development of yellow nails and also return to normal conditions after withdrawal of the drugs (David-Vaudey et al., 2004). It turns out that that all the drug tablets mentioned contain titanium dioxide.

I had eight patients (4 male, 4 female, age 15-79 years at onset of symptoms) exposed to titanium dioxide, six via drug tablets, one via confectionary, and one via chewing gum. Seven had more than ten amalgam restorations in their teeth and had gastrointestinal symptoms, mostly diarrhea, that may have facilitated the absorption of titanium dioxide. A lactulose test in one patient showed increased intestinal permeability. This might explain why relatively few patients develop the syndrome. Also, some patients told me that their strange cough started only after 6 months medication. Most patients don't take their medicines (e.g. antibiotics) that long.

3. Pathogenesis

3.1 Nail changes

Samman and White (1964) suggested that nail changes and defective lymph drainage are related. Emerson (1966) even considered that "nail changes are believed to be the result of defective lymph drainage". Since titanium is always present in the nails of these patients, it is more tempting to consider the nail changes as a toxic reaction to titanium.

3.2 Lymphedema, pleural effusions and ascites; defective lymph drainage or increased vascular leakage?

Lymphangiograms, as performed in four patients with lymphedema in the legs, were interpreted as showing defective lymph drainage (Samman & White, 1964) Similar findings have been reported later (Müller et al., 1979). More recently Danielsson et al. (2006), using lymphoscintigraphy in a patient with edema, pleural effusions, hypoalbuminemia and yellow nails, found normal lymph flow and no signs of lymphatic obstruction in the lower extremities!

Emerson (1966) noted high protein content (40-90 g/L) in pleural effusion, but still considered the primary event to be defective lymph drainage, which could not handle

increased lymph formation, e.g. after some infection. Protein-losing enteropathy in patients with pleural effusions, in some cases together with ascites, has also been reported (Duhra et al., 1985, Battaglia et al., 1985, Malek et al., 1996). In a patient with edema, plural effusion, hypoalbuminaemia and yellow nails, D'Allessandro et al. (2001) found a 10-fold increase in normal albumin enteric loss. Since in most cases of yellow nail syndrome the pleural fluid has a very high protein content, this reflects increased protein permeability of systemic capillaries. D'Allessandro et al claimed that "the theory of pure lymphatic block is not sufficient to explain all the clinical manifestations of yellow nail syndrome", and suggested that microangiopathy and increased microvascular filtration at different sites (pleura, liver, limbs, intestine) due to an alteration in the interstitial matrix, could play a role in addition to lymphatic abnormality.

These reports indicate that increased vascular permeability rather than lymphatic abnormality is a key factor in yellow nail syndrome.

3.3 Prenatal and neonatal manifestations

There are two reports on pregnancy in women with yellow nails and bronchitis or productive cough (Govaert et al., 1992, Slee et al., 2000). Ultrasonography demonstrated polyhydramnios and bilateral pleural effusion in the fetuses at 23 and 29 weeks of gestation, respectively. At delivery both infants were hydropic and had bilateral pleural effusions, which were treated by thoracic drainage. Following initial recovery, pleural effusion recurred 2 days after starting enteral feeding at 4 weeks of age in the first infant, but not in the second. Our interpretation is that both mothers were exposed to titanium or titanium dioxide, and that titanium was transferred across the placenta, and possibly also via maternal milk.

There are a few reports of familiar occurrence of yellow nail syndrome (Lambert et al., 2006). They might be explained by several family members consuming drugs or chewing gum containing titanium.

4. Diagnosis

Yellow discoloration of the nails is often a late sign of the syndrome and therefore not necessary for the diagnosis of yellow nail syndrome; sinusitis and cough, lymphedema and pleural effusion occurring alone or in combination may represent the same syndrome (Varney et al., 1994, Cebecchi et al., 2009). The diagnosis is supported by history or evidence of exposure to titanium implants or to titanium dioxide, and can be confirmed (if necessary) by the presence of titanium in nail clippings ($>1 \mu\text{g/g}$).

5. Treatment

5.1 Titanium implants

Most often it is impossible or extremely difficult to remove titanium implants. It is usually much easier to remove the gold (in teeth, jewelry or rings). In a few patients gold removal (Berglund & Carlmark, 2011) has led to recovery after a period of several months. Because of the hardness of titanium, drilling of dental inlays should not be attempted! Even if removed, titanium may have migrated into gold inlays and will slowly be released over months or

years. I know of two instances where titanium inlays were successfully removed by the use of ultrasonic sound.

Removal of dental amalgam fillings has as yet not been encouraging. Some mercury will remain in the surrounding dental tissue and in various organs in the body. Mercury enters the enterohepatic circulation, often maintaining diarrhea or constipation.

Pleural effusions may require serial thoracentesis. Pleurodesis relieves pleural effusion but may exacerbate lymphedema of the lower limbs (Kawano et al., 2003). In other patients a pleuroperitoneal (Brofman et al., 1990) or a pleurovenous shunt has been applied (Tanaka et al., 2005).

5.2 Titanium dioxide

Patients taking drugs containing titanium dioxide may have difficulties finding titanium-free replacements. They may have to resort to fluid preparations designed for children, or have titanium-free capsules made. Almost all chewing gums contain titanium dioxide, but not Stimorol senses (except the one with peppermint taste).

6. Summary

Yellow nail syndrome was defined in 1964 to include thick yellow nails and lymphedema. A number of symptoms have later been included, most importantly perhaps sinusitis and chronic cough, because they are easily overlooked by the doctor. Most serious are pleural effusions and protein-losing enteritis. The syndrome is caused by titanium or titanium dioxide.

7. Acknowledgement

All costs for this study were defrayed by the Swedish Society of Dental Amalgam Patients, Trollhättan, Sweden.

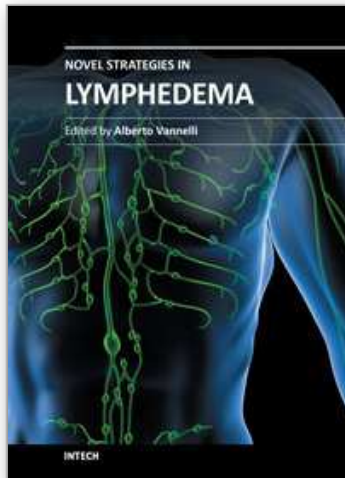
8. References

- Battaglia A, Di Ricco G, Mariani G & Giuntini C (1985). Pleural effusion and recurrent bronchopneumonia with lymphedema, yellow nails and protein losing enteropathy. *Eur J Respir Dis* 66: 65-69.
- Berglund F & Carlmark B (2011). Titanium, sinusitis, and the yellow nail syndrome *Biol Trace Elem Res* 143:1-7.
- Böckmann J, Lahl H, Eckert T & Unterhalt B (2000). Titan-Blutspiegel vor und nach Belastungsversuchen mit Titandioxid. *Pharmazie* 55:140-143.
- Brofman JD, Hall JB, Scott W & Little AG (1990). Yellow nails, lymphedema and pleural effusion. Treatment of chronic pleural effusion with pleuroperitoneal shunting. 97:743-5
- Camilleri AE (1990). Chronic sinusitis and the yellow nail syndrome. *J Laryngol Otol* 104:811-813
- Cebeci F, Celebi M & Onsun N (2009). Nonclassical yellow nail syndrome in six-year-old girl: a case report. *Cases J* 2:165-169

- D'Allessandro A, Muzi G, Monaco A, Filiberto S, Barboni A & Abbritti G (2001). Yellow nail syndrome: does protein leakage play a role? *Eur Respir J* 17: 149-152.
- Danielsson Å, Toth E & Thorlaciuss H (2006). Capsule endoscopy in the management of a patient with a rare syndrome. *Gut* 55: 196
- David-Vaudey E, Jamard B, Hermant C & Cantagrel A (2004). Yellow nail syndrome in rheumatoid arthritis: a drug-induced disease? *Clin Rheumatol* 23: 376-378.
- Dilley JJ, Kierland RR, Randall RV & Shick RM (1968). Primary lymphedema associated with yellow nails and pleural effusions. *JAMA* 204:122-125
- Duhra PM, Quigley EMM & Marsh MN (1985). Chylous ascites, intestinal lymphoangiectasia and the yellow nail syndrome. *Gut* 26:1266-1269
- Emerson PA (1966). Yellow nails, lymphoedema, and pleural effusions. *Thorax* 21: 247-253.
- Forsell M, Marcusson JA, Carlmark B & Johansson O (1997). Analysis of the metal content of in vivo fixed dental alloys by means of a simple office procedure. *Swed Dent J* 21: 161-168
- Govaert P, Leroy JG, Pauwels R, Vanhaesebrouck P, De Praeter C, Van Kets H & Goeteyn M (1992). Perinatal manifestations of maternal yellow nail syndrome. *Pediatrics* 89:1016-1018
- Hassard AD, Martin J & Ross JB (1984). Yellow nail syndrome and chronic sinusitis. *J Otolaryngol* 13:318-320
- Hiller E, Rosenow III EC & Olsen AM (1972). Pulmonary manifestations of the yellow nail syndrome. *Chest* 61:452-458.
- Hunsberger JF (1976). Electrochemical series Table I. In: Weast RC (ed) *Handbook of chemistry and physics*; 57th edn. CRC Press, Boca Raton, pp D141-D143
- Jani PU, McCarthy DE & Florence AT (1994). Titanium dioxide (rutile) particle uptake from the rat GI tract and translocation to systemic organs after oral administration. *Int J Pharm* 105: 157-168.
- Kawano T, Matsuse H, Shigematsu K, Miyazaki M, Taguchi T & Kohno S (2003). Chemical pleurodesis could exacerbate lymphedema of yellow nail syndrome. *Acta Med Nagasaki* 48:71-72
- Malek NP, Ocran K, Tietge UJ, Maschek H, Gratz KF, Trautwein C, Wagner S & Manns MP (1996). A case of the yellow nail syndrome associated with massive chylous ascites, pleural and pericardial effusions. *Z Gastroenterol* 34:763-766.
- Müller R-P, Peters PE, Echernacht-Happle K & Happle R (1979). Roentgenographic and clinical signs in yellow nail syndrome. *Lymphology* 12:257-261
- Nakielna EM, Wilson J & Ballon HS (1976). Yellow nail syndrome: report of three cases. *Can Med Assoc J* 115:46-48
- Reclaru L & Meyer J-M (1998). Effects of fluoride on titanium and other dental alloys in dentistry. *Biomaterials* 19: 85-92
- Samman PD & White WF (1964). The "yellow nail" syndrome. *Br J Dermatol* 76:153-157
- Schiff N, Grosogeat B, Lissac M & Dalard F (2002). Influence of fluoride content and pH on the corrosion resistance of titanium and its alloys. *Biomaterials* 23: 1995-2002
- Shepherd NA, Crocker PR, Smith AP & Levison DA (1987). Exogenous pigment in Peyer's patches. *Hum Pathol* 18: 50-54.
- Slee J, Nelson J, Dickinson J, Kendall P & Halbert A (2000). Yellow nail syndrome presenting as non-immune hydrops: Second case report. *Am J Med Genet* 93:1-4

- Strietzel R, Hösch A, Kalbfleisch H, Buch D (1998). In vitro corrosion of titanium. *Biomaterials* 19: 1495-1499.
- Tanaka E, Matsumoto K, Shindo T & Taguchi Y (2005). Implantation of a pleurovenous shunt for massive chylothorax in a patient with yellow nail syndrome. *Thorax* 60:254-255.
- Varney VA, Cumberworth V, Sudderick R, Durham SR & Mackay IS (1994). Rhinitis, sinusitis and the yellow nail syndrome: a review of symptoms and response to treatment in 17 patients. *Clin Otolaryngol Allied Sci* 19:237-240
- Wakasa M, Imaizumi T, Suyama A, Takeshita A & Nakamura M (1987) Yellow nail syndrome associated with chronic pericardial effusion. *Chest* 92:366-7.
- Wells GC (1966). Yellow nail syndrome with familial primary hypoplasia of lymphatics, manifest late in life. *Proc Royal Soc Med* 59:447
- Zerfas AJ (for HJ Wallace). Yellow nail syndrome with bilateral bronchiectasis. *Proc Royal Soc Med* 59: 448.

IntechOpen



Novel Strategies in Lymphedema

Edited by Dr. Alberto Vannelli

ISBN 978-953-307-929-5

Hard cover, 108 pages

Publisher InTech

Published online 25, January, 2012

Published in print edition January, 2012

Lymphedema is a swelling caused by the abnormal accumulation of lymphatic fluid in the skin. Lymphedema can be caused by burns, injury, surgery, radiation therapy or cancer treatment that cancer survivors undergo. Risk of developing lymphedema is high especially in those with breast or prostate cancer. It is hereditary and can appear without warning at any time of life and is related to obesity and circulatory problems. If not treated, lymphedema can be painful and lead to life-threatening infections. This book will help physicians who deal with lymphedema. It will help you understand how the lymphatic system works, how lymphedema is diagnosed, how to cope with the challenges of lymphedema, how to find treatment, and how to deal with insurance issues. Novel Strategies in Lymphedema is for those with, or at risk of, developing lymphedema, and the healthcare professionals who care for them.

How to reference

In order to correctly reference this scholarly work, feel free to copy and paste the following:

Fredrik Berglund (2012). Titanium and Yellow Nail Syndrome, Novel Strategies in Lymphedema, Dr. Alberto Vannelli (Ed.), ISBN: 978-953-307-929-5, InTech, Available from: <http://www.intechopen.com/books/novel-strategies-in-lymphedema/titanium-and-the-yellow-nail-syndrome>

INTECH
open science | open minds

InTech Europe

University Campus STeP Ri
Slavka Krautzeka 83/A
51000 Rijeka, Croatia
Phone: +385 (51) 770 447
Fax: +385 (51) 686 166
www.intechopen.com

InTech China

Unit 405, Office Block, Hotel Equatorial Shanghai
No.65, Yan An Road (West), Shanghai, 200040, China
中国上海市延安西路65号上海国际贵都大饭店办公楼405单元
Phone: +86-21-62489820
Fax: +86-21-62489821

© 2012 The Author(s). Licensee IntechOpen. This is an open access article distributed under the terms of the [Creative Commons Attribution 3.0 License](#), which permits unrestricted use, distribution, and reproduction in any medium, provided the original work is properly cited.

IntechOpen

IntechOpen