

We are IntechOpen, the world's leading publisher of Open Access books Built by scientists, for scientists

4,800

Open access books available

122,000

International authors and editors

135M

Downloads

Our authors are among the

154

Countries delivered to

TOP 1%

most cited scientists

12.2%

Contributors from top 500 universities



WEB OF SCIENCE™

Selection of our books indexed in the Book Citation Index
in Web of Science™ Core Collection (BKCI)

Interested in publishing with us?
Contact book.department@intechopen.com

Numbers displayed above are based on latest data collected.

For more information visit www.intechopen.com



Advanced 3-D Biomodelling Technology for Complex Mandibular Reconstruction

Horácio Zenha, Maria da Luz Barroso and Horácio Costa
Plastic, Reconstructive & Maxillofacial Surgery Department
Centro Hospitalar V.N.Gaia/Espinho
Portugal

1. Introduction

Reconstructive surgery of the head and neck is a demanding field. The specific anatomical complexity of the region, and its almost inevitable exposure to the public, demand for highly refined and careful reconstructive procedures. In fact, in the last decades, the trend in reconstructive surgery, as for the general medical field, is to put the standard of care in an extremely high level and this adds an extra perfectionist input in treatment goals.

In the classical principles of treatment in plastic surgery, restoration of function is always regarded as first objective. Regular mastication, swallowing, respiration and speech are the goals to reach when planning facial reconstructive procedures. In the modern principles, this first priority has been caught up by a new priority goal – the aesthetic result. In head and neck reconstruction, this new goal is even more important because of the prime social role this anatomical region sustains. So, it is not enough to restore functions, but we should also seek for facial harmony and the most perfect symmetry.

Facial structure is complex and unique among individuals. The challenge of recreating its 3-dimensional (3-D) morphology is enormous and traditionally a very artistic endeavour. Hard, time-consuming and “eye-match” manual techniques were normally used in order to obtain satisfactory results. This is particularly valid when we focus on severe defects of the head and neck.

Reconstruction with local or regional tissues is normally preferred in general plastic surgery, especially because of the similarity of neighbouring tissues regarding the final result. This concept changes in the facial region due to 2 fundamental reasons: the face is in the cephalic extremity of the human body and there is a relative lack of possible neighbour donor sites; and that option would imply the sacrifice of other areas that are also important to overall function and aesthetic adding unnecessary morbidity to the solution. So, distant free flaps are very often used as the first choice for complex reconstruction of the head and neck. This technique allows us to bring to our “reconstruction site” a much less limited amount of tissue and restore severe compound defects (skin, bone, mucosa...). As counterpart, it has considerable technical, logistic and time-consuming difficulties. The dissection and transfer of free flaps requires specific training and capabilities. Vessels anastomosis are done under microscope and, apart from the surgical team, all the operating room personnel should be

used the routines on its manipulation so the time this phase of the surgery lasts can be minimized. Two surgical teams should work together: one at the recipient site, where the extirpation of the tumour or recreation of the previous defect and dissection of recipient vessels is done; while the other dissects the free flap selected, and so time can be spared. Nonetheless, it is not easy to complete these procedures in less than 5-6 hours. The management of osteocutaneous/osteomucosal compound defects and extensive mandibular defects is particularly troublesome, especially the correct modelling of the anatomically "curved" mandibular bone which is unique in the human body. The surgeon, apart from the technical skills, has to apply all his inspiration and art into the cases. Manual measurements and calculations and "eye-match" techniques to evaluate symmetries are often applied in the operating theatre. (Zenha et al., 2011)

2. Biomodelling technology

The advances in medical imaging in recent years have been overwhelming with the possibility of obtaining increasing volumes of complex and extremely precise data from the patient. To explore their full potential is sometimes hard for the surgeon, specially when he is forced to mentally transform 2-D images into a 3-D scenery as the one he is faced within the surgical field (Zenha et al., 2011). Three-dimensional (3-D) imaging has been developed to narrow the communication gap between radiologist and surgeon. It represents a big development for data display, diagnosis and surgical planning and is nowadays ready accessible in most centers but it is not a true 3-D technology, as it is displayed on a flat screen or radiological film only in 2 dimensions (D'Urso et al., 1999a).

Biomodelling is the generic term describing the ability to replicate the morphology of a biological structure in a solid substance (Oliveira et al., 2008). Specifically, biomodelling uses radiant energy to capture morphological data on a biological structure and processes such data by a computer to generate the code required to manufacture the structure by rapid prototyping (RP) (Oliveira et al., 2008). It represents the physical 3-D expression of 3-D imaging technology data. Stereolithography (SL) is a RP process. As almost all RP processes, it is based on layered manufacturing methodology in which objects are built as series of horizontal cross sections, each one being formed individually from the relevant raw materials and bonded to preceding layers until it is completed. Technically, the model-fabrication is by polymerisation of liquid UV-sensitive resin using a UV-laser beam on a horizontal plane, with vertical construction by submerging the model stepwise (Bill et al., 1995). Accuracy of SL has been shown in the range of +/-1mm.

Biomodelling technology with SL is a long established method in industry for the construction of prototypes and cast moulds, namely in the space and aeronautic field. Mankovich *et al.* in 1990 reported the 1st SL anatomical models and Stoker *et al.* in 1992 described the use of SL biomodelling for retrospective assessment of a clinical case. However, it was Arvier *et al.* in 1994, which described the 1st real clinical use of SL biomodelling techniques, with application in cases of mandibular reconstruction and orthognathic surgery. Since then, the development in the technique has been facilitated by improvements in medical imaging, computer hardware, 3D image processing software and the technology transfer of engineering methods into the field of surgery. Colour SL for planning of maxillofacial tumour surgery was described by Kermer *et al.* in 1998. In the same year, Peckitt (1998) opened the field of prosthesis manufacturing through SL biomodelling

with its accuracy, flexibility and limitations. Kernan & Wimsatt in 2000 described the use of SL biomodels for accurate preoperative adaptation of a reconstruction plate. The concurrent evolution of other technologies like stereophotogrammetry (Xia et al., 2000) has enriched SL biomodelling techniques enabling the diagnosis, simulation and planning of the soft tissues component of the reconstructive procedure. Surgical navigation technology (Schramm et al., 2000 & Gelrich et al., 2002) is another growing field that augmented, and in some instances substituted (Hohlweg-Majert, 2005), the role of SL in maxillofacial surgery.

In craniomaxillofacial surgery, biomodelling technology with SL has been applied in craniofacial, tumour, orthognathic, trauma and implantology and has been considered a valuable tool in several studies (D'Urso et al., 1999a, 2000a; Bill et al., 1995; Sailer et al., 1998; Xia et al., 2006). Application of biomodeling technology has also been reported in neurosurgery (D'Urso & Redmond, 1999b, 1999c & 2000b; Sinn et al., 2006; Westendorf et al., 2007; Staffa et al., 2007; Wurm et al., 2004), orthopedic surgery (Fukui et al., 2003; Brown et al., 2002 & Gutierrez et al., 2007), cardiology and cardio-thoracic surgery (Sodian et al., 2002 & Greil et al., 2007), vascular surgery (Lermusiaux et al., 2001), facial aging (Pessa, 2000 & 2001), alloplasty (Coward et al., 1999), forensic medicine (Dolz et al., 2000 & Vanezi et al., 2000) and fetal medicine (D'Urso & Thompson, 1998).

In fact, biomodelling technology associated with rapid prototyping has become an important tool in reconstructive surgery, especially in head and neck complex cases involving mandible reconstruction. The possibility of creating an highly accurate physical model of the patient's anatomy enables better overall evaluation and a careful and detailed surgical planning with significative surgery-time sparing. Also, virtual simulation of the surgical procedure with the generation of surgical templates has been integrated in the process. This virtual simulation step presents an enormous potential in the field of surgical planning and optimisation.

We developed two new stereolithographic biomodel tools to be used intra-operatively that should optimise the reconstructive procedure: surgical cutting guides that preoperatively define the exact defect to be reconstructed and a template that simultaneously guides the osseous free flap osteotomies and enables reconstruction plate modelling.

2.1 Materials & methods

Between 2008 and 2010, 19 patients, of which 10 male and 9 female, were submitted to complex and compound mandibular reconstruction procedures. Age ranged from 9 to 66 years old (mean - 36,5). The ethiology was neoplastic in the majority - 16 cases, 84% - with 12 tumours origin from the mandible and the remaining 4 from the oral mucosa. Histological analysis of the mandibular tumours revealed 8 ameloblastomas, 1 sarcoma, 1 osteoclastoma, 1 giant cell tumour and 1 odontogenic queratocyst. The histological characterization of the oral mucosa tumours treated was oral squamous cell carcinoma (3 cases) and minor salivary gland adenocarcinoma (1 case). Other ethiologies were osteoradionecrosis following radiotherapy (RT) adjuvant treatment for oral squamous cell carcinoma (2 cases) and congenital (1 case of Goldenhar syndrome with severe unilateral mandibular hipoplasia). In approximately $\frac{3}{4}$ of the patients (14 cases) reconstruction was immediate after surgical extirpation. In the remaining (5 cases), there had been previous surgery or congenital malformation that originated the defect to be reconstructed.

The free flaps selected for reconstruction of the mandibular defects were the iliac crest flap (13 cases) and the fibula flap (6 cases, in association with a radial forearm flap in 3 cases). These flaps were selected because of: their “bone stock” availability; the similarity of contour with the mandible; the relatively good and long vascular pedicle and the possibility to reconstruct oral mucosa and/or facial and cervical skin with a thin and pliable flap (Costa et al., 2011). The iliac crest free flaps were always transferred as osteomuscular flaps. The fibula flaps were all transferred as osteoseptocutaneous flaps with the skin paddle used for cervico-facial skin reconstruction in 3 cases, intra and extra-oral reconstruction in 2 cases and as a facial volume enhancer in a buried flap (after deepithelization) in the case of congenital hemifacial microsomia. In 3 of the fibula flap patients, due to magnitude of the defect, it was necessary to perform a second free flap – radial forearm fasciocutaneous – to be used in a sequentially linked flow-through technique and to which the fibula flap vessels were anastomosed.

2.2 The process

Surgical planning using biomodelling technology starts with a CT scan of the head and neck of the patient (Figure 1). A specialized scanning protocol is required with image slices in the range of 0,5-1mm in order to obtain isotropic data. This 2-D DICOM data is then converted in 3-D data through a specific software, *AnatomicsPro*®, that automatically generates surface-based STL (Standard Tessellation Language) files and contour-based SLC (Stereolithography) files proper for solid modelling via rapid prototyping. Further image processing is required to identify and separate (segmentation) the anatomy to be modelled.

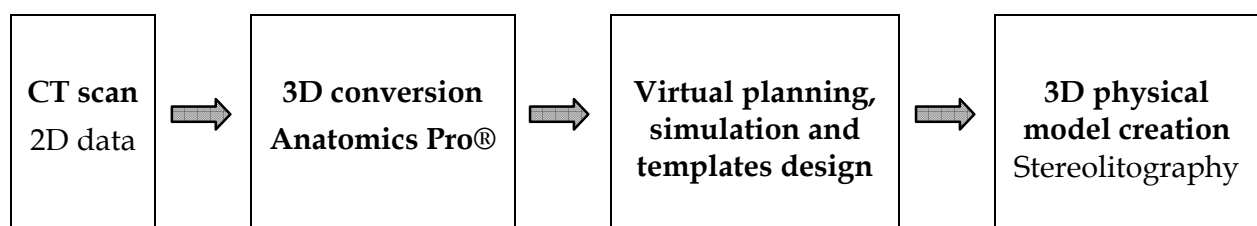


Fig. 1. The dynamic process of biomodelling technology application in complex mandibular reconstruction. The stereolithography models are generated for “hands-on” surgical planning and intra-operative use.

Virtual simulation and rehearsal of the surgical procedure is done through another software, *Freeform Modelling*®, where, advanced mathematical techniques, enable the exact calculation of the contours, angles, length and morphology of the reconstructive procedure and also the generation of surgical templates to be used intra-operatively. We can plan and simulate with high accuracy all the “osseous phase of the surgery”. In immediate reconstructions we define exactly where we want to cut the mandible and design a surgical guide that fits in that area in the original mandible. In secondary reconstructions, we calculate the bone defect with several instrumental techniques like virtual manipulation of the remaining mandible, mirror-imaging and standardized cephalometric mandible measurements (Figure 2). We are able to create different templates that guide: donor-bone harvesting; bone-modelling osteotomies and titanium plate modelling. It is also possible to generate pre-modelled titanium plates by stereolithography but due to the logistics needed and the costs involved it wouldn’t be worthwhile. The 3-D physical models are then

fabricated by RP and used to optimise planning, with “hands-on” evaluation and training, and are ready to be sterilized for surgical utilization (Figure 3).

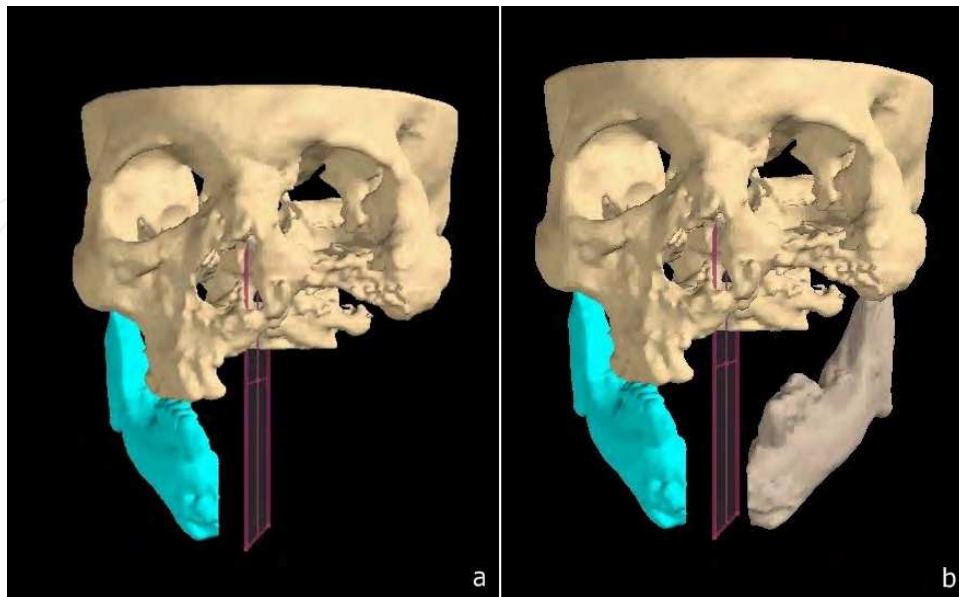


Fig. 2. Virtual manipulation and surgical planning are done through a specific software (Freeform Modelling®). It enables the mobilization of remaining anatomical structures (blue hemimandible) to the correct position and the calculation of the defect to restore through techniques like mirror-imaging (grey left hemimandible).




Fig. 3. Fabrication of the acrylic biomodels by stereolithography. The skull and templates are used for detailed surgical planning and intra-operative use.

Intra-operatively the surgical cutting guides are used directly in the mandible and define the exact osteotomies sites. Another SL tool is used for planning the osteotomies of the free flap (fibula or iliac crest) and simultaneously guide the reconstruction titanium plate modelling for the necessary osteosynthesis. The final surgical steps are the microsurgical vascular anastomosis that, in this way, are done without further more “aggressive” osseous manoeuvres that could eventually cause damage.

2.3 Results

Free flaps modelling based on the SL 3-D biomodelling tools accomplished an almost anatomical reconstruction in all the cases (Table 1). The innovative surgical templates were easily used intra-operatively and found to be very efficient. Apart from the flap modelling, where they guided the osteotomies needed in order to mimic the original angulated mandible, they were simultaneously used to mould the reconstruction plate. This surgical step was found to be much easier and quicker than in the regular way. Preoperative planning with virtual simulation of the surgical procedure facilitates a two-team approach from the beginning of the surgical procedure accelerating it. The intra-operative availability of the Surgical Guides enables a more straightforward modelling of the free flap along with much less drawbacks. The operative time is diminished in about 45 minutes, according to surgeons estimation, in comparison to similar cases performed without 3-D biomodels, namely due to optimisation of the flap and reconstruction plate modelling phase.

There were two partial flap necrosis (cases 13 and 18) that needed further surgical revisions with local/regional soft-tissue flaps. Delayed wound healing occurred in 4 cases mainly due to RT-damaged skin.

End-results were evaluated according to functional and aesthetic criteria in 4 different categories: unsatisfactory, satisfactory, good and very good. Restoration of swallowing was considered the first priority, followed by mastication along with the possibility of oral rehabilitation and finally the aesthetic result and facial symmetry (Figs. 4, 5 & 6).

Sex	Age	Ethiology	Mandibular defect	Timing	Free Flap	Bone (cm)	OST	Surgery Time (h)	Result
♀	65	Oral adenocarcinoma	Anterior arch	Primary	Fibula OFC + RFF	15	2	11	Good
♀	15	Ameloblastoma	Hemimandible sparing condyle	Primary	Iliac crest OM	10	0	7	Good
♂	46	Oral SCC	Hemimandible sparing condyle	Secondary	Iliac crest OM	12	1	9	Very Good
♂	11	Goldenhar sdr	Hemimandible	Primary	Fibula OFC	9	1	9	Good
♂	66	ORN	Anterior arch	Primary	Fibula OFC	15	2	10	Good
♀	20	Ameloblastoma	Hemimandible sparing condyle	Primary	Iliac crest OM	9	0	10	Very Good
♀	31	Osteoclastoma	Hemimandible sparing condyle	Primary	Iliac crest OM	10	0	8	Very Good

Sex	Age	Ethiology	Mandibular defect	Timing	Free Flap	Bone (cm)	OST	Surgery Time (h)	Result
♀	35	Ameloblastoma	Anterior arch	Primary	Iliac crest OM	11	1	8	Very Good
♂	41	ORN	Hemimandible sparing condyle	Primary	Fibula OFC	8	0	9	Very Good
♀	26	Sarcoma	Hemimandible sparing condyle	Primary	Iliac crest OM	12	1	8	Very Good
♀	34	Ameloblastoma	Hemimandible sparing condyle	Primary	Iliac crest OM	10	0	5	Very Good
♂	46	Ameloblastoma	Hemimandible sparing condyle	Primary	Iliac crest OM	8,5	0	8	Very Good
♂	54	Oral SCC	Anterior arch	Secondary	Fibula OFC + RFF	15	2	11	Satisfactory
♀	53	Queratocyst	Hemimandible	Primary	Iliac crest OM	12	0	7	Very Good
♂	41	Ameloblastoma	Hemimandible sparing condyle	Primary	Iliac crest OM	8	0	7	Very Good
♂	10	Giant cell granuloma	Anterior arch	Primary	Iliac crest OM	10,5	1	8	Very Good
♂	9	Ameloblastoma	Hemimandible	Primary	Iliac crest OM	10,5	2	5	Very Good
♂	45	Oral SCC	Anterior arch	Secondary	Fibula OFC + RFF	16	2	12	Good
♀	46	Ameloblastoma	Anterior arch	Secondary	Iliac crest OM	12	2	6	Very Good

Table 1. Clinical cases of complex oromandibular reconstruction using advanced 3-D biomodelling technology. (OFC- osteofasciocutaneous; OM- osteomuscular; ORN- osteoradionecrosis; OST- osteotomies; RFF- radial forearm flap; SCC- squamous cell carcinoma)

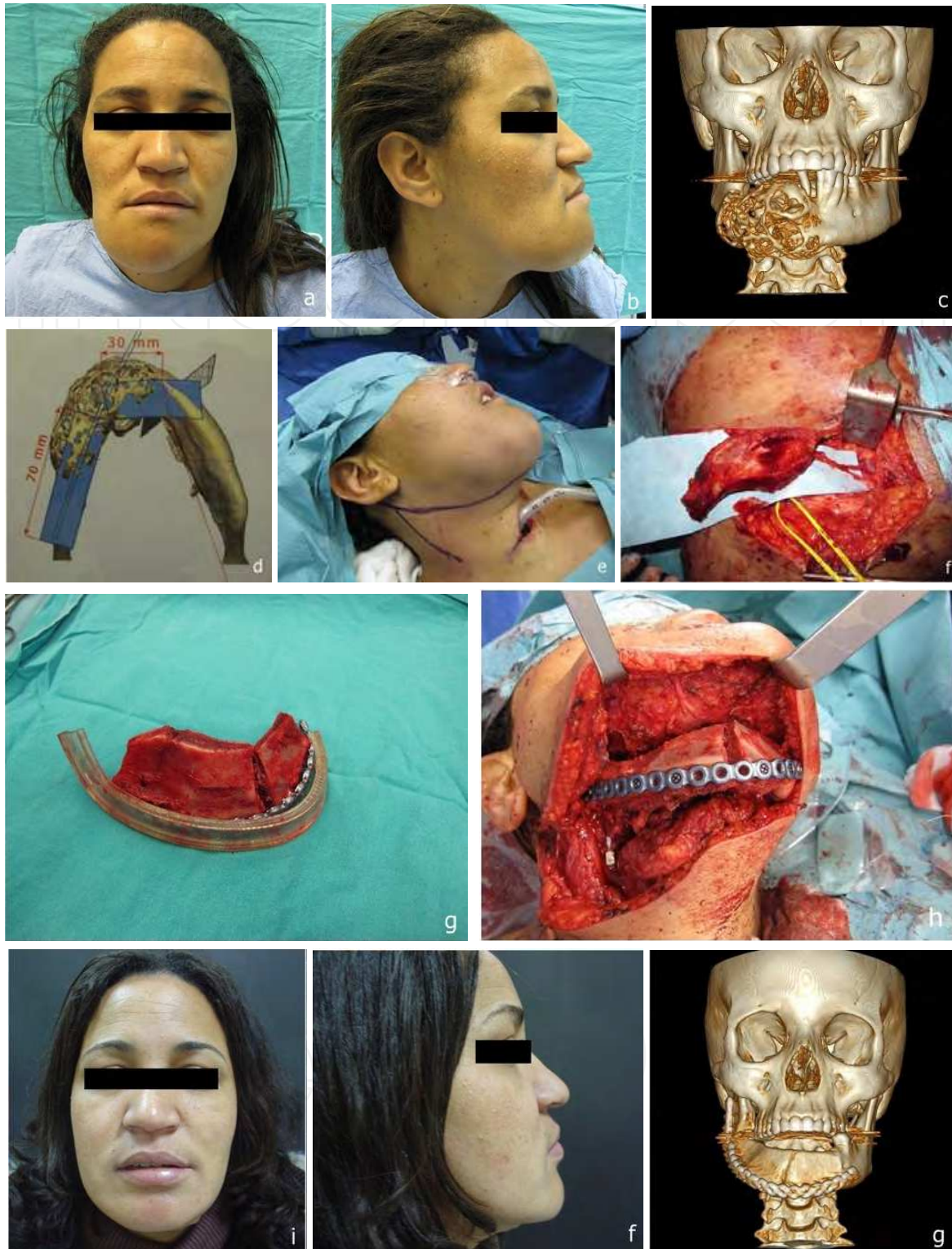

Fig. 4. Female, 35 years old, with a neglected ameloblastoma of the mandible involving the right body and symphysis (a, b & c); Preoperative planning with 3-D biomodelling technology (d); Preoperative markings showing the cervical approach (e); reconstruction with a vascularised iliac crest osteomuscular flap modelled with a 3-D template generated by mirror-imaging and segmentation techniques (f, g & h); 9-month post-operative result showing very good facial contour and bone symmetry (i, f & g).

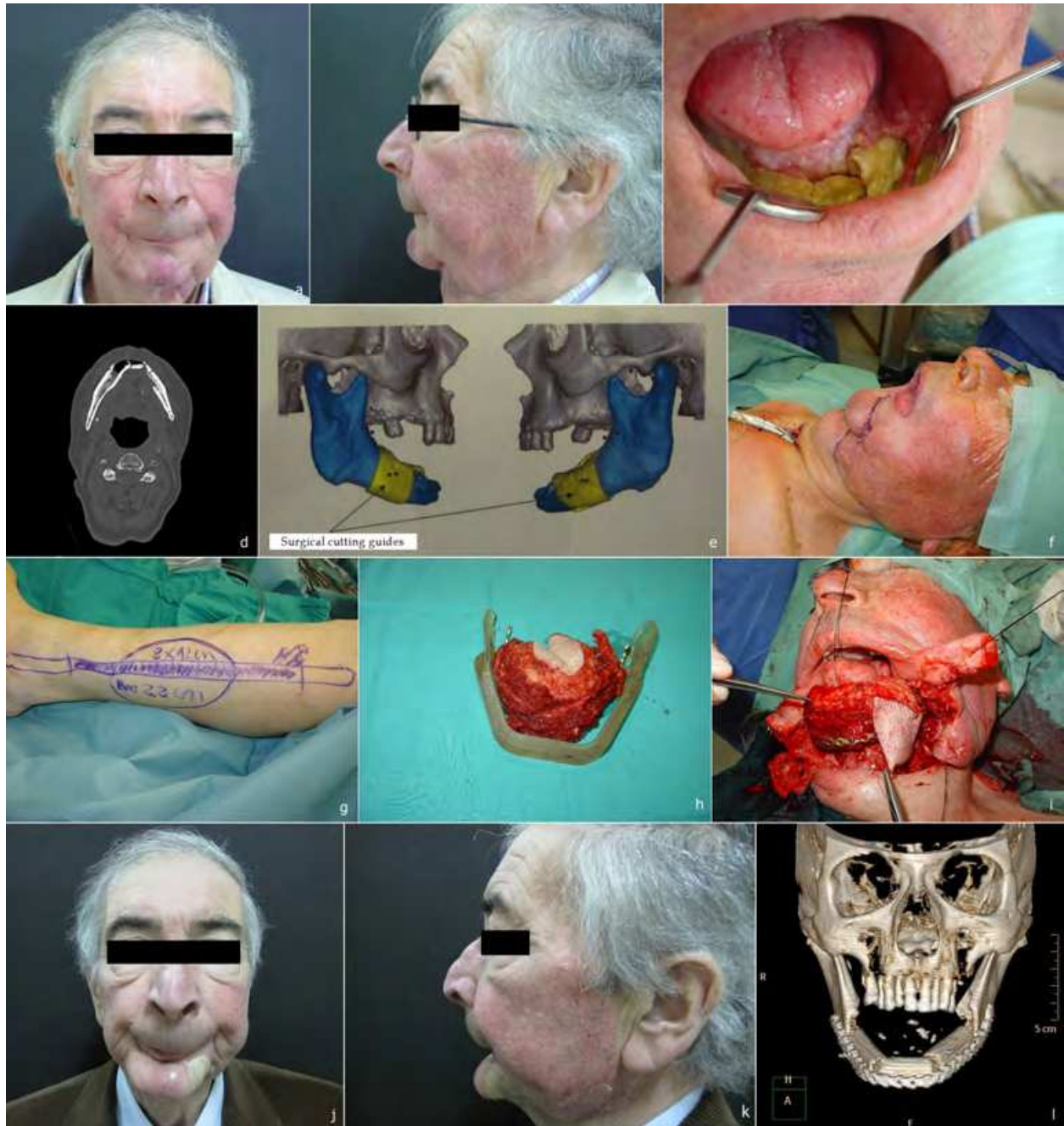


Fig. 5. Male, 66 years old, with osteoradionecrosis of the mandible involving the anterior arch and with orocervical fistulization (a, b, c & d) following radical surgery and RT for an oral squamous cell carcinoma; pre-operative planning with 3-D biomodelling technology showing the surgical cutting guides for bone resection (e); preoperative markings for reconstruction with a osteoseptocutaneous fibula flap (f & g); osteoseptocutaneous fibula flap modelled according to the 3D template that simultaneously guided the titanium plate modelling (h); flap *in situ* (i); Postoperative result at 9 months revealing a good mandibular contour and symmetry. The lack of lower lip projection is due to the temporary removal of the dental plate (j, k & l). Oral rehabilitation with dental implants is in course.

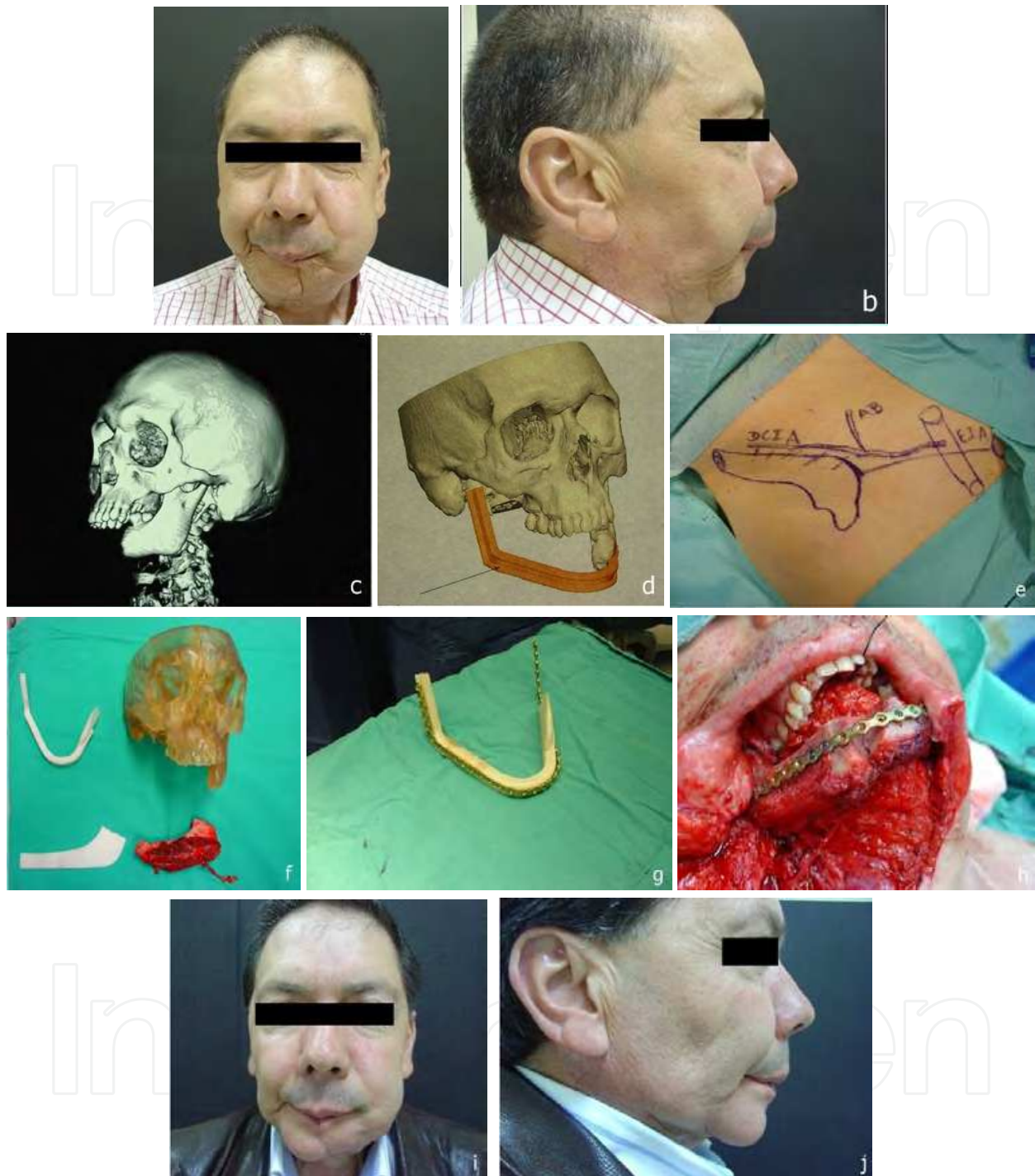

Fig. 6. Male, 46 years old, with an history of oral squamous cell carcinoma submitted to radical excision with left hemimandibulectomy sparing the condyle and RT (a, b & c); pre-operative planning with 3-D biomodelling technology showing the reconstruction plate modelling template generated with mirror-imaging and virtual simulation techniques (d); pre-operative markings for reconstruction with a vascularised iliac crest osteomuscular flap (e); Bone and reconstruction plate modelling based on the surgical 3-D SL templates (f & g); Intra-operative result after osteosynthesis (g); post-operative result at 9 months.

2.4 Advantages

Complex mandible reconstruction cases pose a real challenge. Long and technically demanding procedures are needed and 3-D anatomical reconstruction is very difficult to obtain. Over the last 20 years, Biomodelling technology associated with rapid prototyping has become an important tool in reconstructive surgery (Arvier et al., 1994; Bill et al., 1995 & Sailer et al., 1998). It enables virtual planning and simulation of surgical procedures and the production of very accurate physical models of the patient's anatomy (Winder & Bibb, 2005 & Robiony et al., 2007). It has been applied successfully in several medical fields (Zenha et al., 2011) with particularly interesting results in craniomaxillofacial surgery. We have a 8-year experience in using this technology in complex craniomaxillofacial defects (primary and secondary), with the great majority of the cases involving extensive mandibular defects. We have also applied this technology in craniofacial and maxillary defects. Since the mid-90's, 3-D biomodelling technology is regarded as a valuable tool in congenital malformations (including craniofacial surgery), tumour surgery, traumatology, orthognathic surgery and implantology (Bill et al., 1995). Sailer et al. (1998), indicate its use for craniofacial surgery in cases of hypertelorism, severe asymmetries of the neuro- and viscerocranium, complex cranial synostoses and large skull defects and of less value in cases of consolidated fractures of the periorbital and nasoethmoidal complex. The several studies and clinical applications of this technology by the group of D'Urso et al. (1998a, 1998b, 1999a, 1999b, 1999c, 2000a & 2000b), concluded that biomodelling significantly improved operative planning and diagnosis; reduced operative time and risk, facilitates team communication and also provides patients with a clearer understanding of their pathology and treatment strategy. In a multicentric european study of 466 cases, Wulf et al. (2003) concluded that medical modelling has utility in surgical specialities, especially in the craniofacial and maxillofacial area.

Biomodelling technology represents a whole new era in craniomaxillofacial surgery. The potential that computer surgical simulation of the procedure offers is still to be revealed. After patient image data acquisition by CT, we can pre-operatively and without time-pressure, better define the tumour to extirpate or the defect to reconstruct. We can simulate and rehearse the surgical steps and, with the specific software used, calculate the exact contours, angles, length and morphology of the reconstructive procedure. Finally, it enables the generation of surgical templates to be used intra-operatively. These templates guide the surgical procedure and are used to guide bone harvesting and modelling and also reconstruction plate moulding. This reduces effectively the operative time with major benefits for the patient including lesser wound exposure, decreased anaesthesia time and decreased blood loss (Kernan & Wimsatt, 2000). Team communication is also enhanced and treatment strategies can be discussed in a more detailed and "physical" way.

Patient's original anatomy is more accurately restored by this technology leading to better functional and aesthetic results (Fig 4i,f,g). The final anatomical result is more accurate leading to better functional and aesthetic results. All the patients were found to have at least a satisfactory result, with 94,8% (18 patients) ended with a good and very good end-result. Case 13 was the only considered to have a satisfactory result. This was mainly due to two reasons: the major defect to be reconstructed that needed a combined sequentially

linked radial forearm fasciocutaneous flap plus a fibula osteoseptocutaneous flap; and to partial flap necrosis that occurred in the fibula flap that forced surgical revision. It is important to point that none of these reasons is directly dependent on the use of biomodelling technology. More than 2/3 of the patients (68,4%, 13 patients) were judged to have very good results. The differences between patients in the good and in the very good classification are mostly related to external scar appearance and are directly dependent on the pre-operative patient status. This evaluation was parallel to the patient's satisfaction.

2.5 Limitations

Apart from the several advantages that this technology ensures, there are some limitations to consider. The main limitation is the significant economical additional cost to the use of this technology. The virtual planning and manufacturing of the SL surgical templates costs around 1000-1500 €. Cost-effectiveness of this technology has been studied in the literature and is considered worthwhile (Bill et al., 1995; Sailer et al., 1998; D'Urso et al., 1998b & 1999a; Xia et al., 2006) due to the reduction of the operative time (with parallel reduction of potential complications) and to the better anatomical and functional end-results. Also, experience has led us to simplify and refine some steps in the procedure, making it more practical and less time-consuming. Nowadays, we invest more on the virtual planning and simulation phase, and we only generate the surgical guides to be used intra-operatively while at the beginning, we always created the patient's anatomical model. In this way, we define more objectively what is going to be done in the operating room and we spare the extra cost of manufacturing the whole craniofacial skeleton. Another drawback is the higher radiation dosage to which the patient has to be exposed due to the specific CT-scanning protocol that is needed. We consider it to be a minor problem when compared to the extra benefits that this technology warrants. More important is the necessary planning and manufacturing time that takes a medium of 2 weeks and can be a troublesome when we are dealing with more urgent cases (oncology and acute trauma). We often still reconstruct the primary oral squamous cell carcinoma with mandibular involvement without the use of this technology.

2.6 Indications

A careful and judicious selection of the patients based on the expected surgical utility is very important. In our opinion, in complex mandible reconstruction, 3-D biomodelling technology is particularly useful in: major secondary defects (oncological, osteoradionecrosis, trauma) with important distortion of craniofacial structure; congenital malformations and primary tumour surgery when the dimensions of the tumour have altered normal anatomy considerably or the resection involves an angled region (genius or angle of the mandible) (Zenha et al., 2011).

3. Conclusion

Complex oromandibular reconstruction is one of the more challenging areas to deal with. The surgical procedures are necessarily long, complex and technically demanding and a

satisfactory 3-D anatomical reconstruction is very difficult to obtain. 3-D Biomodelling technology designing of free flaps enables a better pre-operative planning, reduces operative time and significantly improves the aesthetic and biofunctional outcome. These new stereolithographic biomodel tools that exactly define the defect to be reconstructed and guide the osseous free flap osteotomies and also the reconstruction plate modelling are a step forward in the optimisation of the treatment of these cases.

4. Acknowledgments

The authors would like to thank Eng. José Domingos and Eng. Bruno Sá for their technical and scientific support on the conception and development of this technology. The authors would also like to thank all the remaining members of the Plastic, Reconstructive and Maxillofacial Surgery Department of the Centro Hospitalar Vila Nova Gaia/Espinho (medical doctors, nursing staff and secretaries) for their support in the treatment of these patients.

5. References

- Arvier JF, Barker TM, Yau YY et al (1994). Maxillofacial biomodelling. *Br J Oral Maxillofac Surg* 1994;32;276-283. ISSN 0266-4356
- Bill JS, Reuther JF, Dittmann, W et al (1995). Stereolithography in oral and maxillofacial operation planning. *Int J Oral Maxillofac Surg* 1995; 24;98-103. ISSN 0901-5027.
- Brown GA, Milner B & Firoozbakhsh K (2002). Application of computer generated stereolithography and interpositioning template in acetabular fractures: a report of eight cases. *J Orthop Trauma* 2002;16;347-52. ISSN 0890-5339.
- Costa H, Zenha H, Azevedo L, Rios L, Luz Barroso M & Cunha C (2011). Flow-through sequentially linked free flaps in head and neck reconstruction *Eur J Plast Surg*, Online first, (May 2011). ISSN 1435-0130.
- Coward TJ, Watson RM & Wilkinson IC (1999). Fabrication of a wax ear by rapid-process modelling using stereolithography. *Int J Prosthodont* 1999;12;20-7. ISSN 0893-2174.
- Dolz MS, Cina SJ & Smith R (2000). Stereolithography: a potential new tool in forensic medicine. *Am J Forensic Med Pathol* 2000;21;119-23. ISSN 0195-7910.
- D'Urso PS & Thompson RG (1998). Fetal biomodelling. *Aust N Z J Obstet Gynaecol* 1998;38;205-7. ISSN 0004-8666.
- D'Urso PS, Atkinson RL, Lanigan MW et al (1998b). Stereolithographic (SL) biomodelling in craniofacial surgery. *Br J Plast Surg* 1998;51;522-30. ISSN 0007-1226.
- D'Urso PS, Barker TM, Earwaker WJ et al (1999a). Stereolithographic biomodelling in craniomaxillofacial surgery: a prospective trial. *J Craniomaxillofac Surg* 1999; 27; 30-37. ISSN 1010-5182.
- D'Urso PS, Thompson RG, Atkinson RL et al (1999b). Cerebrovascular biomodelling: a technical note. *Surg Neurol* 1999;52;490-500. ISSN 0090-3019.
- D'Urso PS, Hall BI, Atkinson RL, Weidmann MJ & Redmond MJ (1999c). Biomodel-guided stereotaxy. *Neurosurgery* 1999;44;1084-93. ISSN 0022-3069.

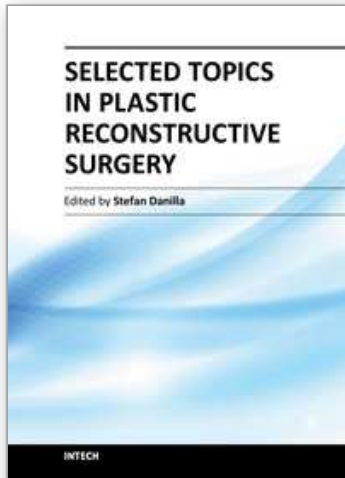- D'Urso PS, Barker TM, Earwaker WJ et al (2000a). Custom cranioplasty using stereolithography and acrylic. *Br J Plast Surg* 2000;53;200-4. ISSN 0007-1226.
- D'Urso PS & Redmond MJ (2000b). A method for the resection of cranial tumours and skull reconstruction. *Br J Neurosurg* 2000;14;555-9. ISSN 0268-8697.
- Fukui N, Ueno T, Fukuda A & Nakamura K (2003). The use of stereolithography for an unusual patellofemoral disorder. *Clin Orthop Relat Res* 2003;409;169-74. ISSN 0009-921X.
- Gellrich NC, Schramm A, Hammer B et al (2002). Computer-assisted secondary reconstruction of unilateral posttraumatic orbital deformity. *Plast Reconstr Surg* 2002 Nov;110;1417-29. ISSN 1529-4242.
- Greil GF, Wolf I, Kuettner A et al (2007). Stereolithographic reproduction of complex cardiac morphology based on high spatial resolution imaging. *Clin Res Cardiol* 2007;96;176-85. ISSN 1861-0684.
- Gutierrez M, Dias AG & Lopes MA (2007). Opening wedge high tibial osteotomy using 3D biomodelling Bonelike macroporous structures: case report. *J Mater Sci Mater Med* 2007;18;2377-82. ISSN 0957-4530.
- Hohlweg-Majert B, Schön R, Schmelzeisen R, Gellrich NC & Schramm A (2005). Navigational Maxillofacial surgery using virtual models. *World J Surg* 2005;29;1530-8. ISSN 0364-2313.
- Kermer C, Rasse M, Lagogiannis G et al (1998). Colour Stereolithography for planning complex maxillofacial tumour surgery. *J Craniomaxillofac Surg* 1998;26;360-2. ISSN 1010-5182.
- Kernan BT & Wimsatt JA (2000). Use of Stereolithography Model for Accurate, Preoperative Adaptation of a Reconstruction Plate. *J Oral Maxillofac Surg* 2000;58;349-51. ISSN 0278-2391.
- Lermusiaux P, Leroux C, Tasse JC, Castellani L & Martinez R (2001). Aortic aneurism: construction of a life-sized model by rapid prototyping. *Ann Vasc Surg* 2001;15;131-5. ISSN 0890-5096.
- Mankovich NJ, Cheeseman AM & Stoker NG (1990). The display of three-dimensional anatomy with stereolithographic models. *J Digit Imag* 1990;3;200-3. ISSN 0897-1889.
- Oliveira M, Hussain NS, Dias AG, Lopes MA, Azevedo L, Zenha H, Costa H & Santos JD (2008). 3-D biomodelling technology for maxillofacial reconstruction. *Materials Science and Engineering C* 28 (2008) 1347-1351, ISSN 0921-5093.
- Peckitt NS (1998). Stereolithography and the manufacture of customized implants in facial reconstruction: a flapless surgical technique. *Br J Oral Maxillofac Surg* 1998;36;481. ISSN 0266-4356.
- Pessa JE (2000). An algorithm of facial aging: verification of Lambros's theory by three-dimensional stereolithography, with reference to the pathogenesis of midfacial aging, scleral show, and the lateral suborbital trough deformity. *Plast Reconstr Surg* 2000;106;479-88. ISSN 1529-4242.
- Pessa JE (2001). The potential role of stereolithography in the study of facial aging. *Am J Orthod Dentofacial Orthop* 2001;119;117-20. ISSN 0889-5406.

- Sailer HF, Haers PE, Zollikofer CPE et al (1998). The value of stereolithographic models for preoperative diagnosis of craniofacial deformities and planning of surgical corrections. *Int J Oral Maxillofac Surg* 1998;27:327-333. ISSN 0901-5027.
- Schramm A, Gellrich NC, Gutwald R et al (2000). Indications for computer-assisted treatment of cranio-maxillofacial tumours. *Comput Aided Surg* 2000;5(5):342-52. ISSN 1092-9088.
- Sinn DP, Cillo JE & Miles BA (2006). Stereolithography for craniofacial surgery. *J Craniofac Surg* 2006;17:869-75. ISSN 1049-2275.
- Sodian R, Loebe M, Hein A et al (2002). Application of stereolithography for scaffold fabrication for tissue engineered heart valves. *ASAIO J* 2002;48:12-6. ISSN 1058-2916.
- Staffa G, Nataloni A, Compagnone C & Servadei F (2007). Custom made cranioplasty prostheses in porous hydroxy-apatite using 3D design techniques: 7 years experience in 25 patients. *Acta Neurochir* 2007;149:161-70. ISSN 0001-6268.
- Stoker NG, Mankovich NJ & Valentino D (1992). Stereolithographic models for surgical planning: a preliminary report. *J Oral Maxillofac Surg* 1992;50:466-71. ISSN 0278-2391.
- Robiony M, Salvo I, Costa F et al (2007). Virtual Reality Surgical Planning for Maxillofacial Distraction Osteogenesis: The Role of Reverse Engineering Rapid Prototyping and Cooperative Work. *J Oral Maxillofac Surg* 2007;65:1198-208. ISSN 0278-2391.
- Vanezi P, Vanezis M, McCombe G & Niblett T (2000). Facial reconstruction using 3-D computer graphics. *Forensic Sci Int* 2000;108:81-95. ISSN 0379-0738.
- Westendorff C, Kaminsky J, Ernemann U, Reinert S & Hoffmann J (2007). Image-guided sphenoid wing meningioma resection and simultaneous computer-assisted cranio-orbital reconstruction: technical case report. *Neurosurgery* 2007;60:173-4. ISSN 0022-3069.
- Winder J & Bibb R (2005). Medical Rapid Prototyping Technologies: State of the Art and Current Limitations for Application in Oral and Maxillofacial Surgery. *J Oral Maxillofac Surg* 2005;63:1006-15. ISSN 0278-2391.
- Wulf J, Vitt KD, Erben CM, Bill JS & Busch LC (2003). Medical biomodelling in surgical applications: results of a multicentric European validation of 466 cases. *Stud Health Technol Inform*. 2003;94:404-6. ISSN 0926-9630.
- Wurm G, Tomancok B, Pogady P, Holl K & Trenkler J (2004). Cerebrovascular stereolithographic biomodeling for aneurism surgery. Technical note. *J Neurosurg* 2004;100:139-45. ISSN 0022-3085.
- Xia J, Wang D, Samman N, Yeung RWK & Tideman H (2000). Computer-assisted three-dimensional surgical planning and simulation: 3D color facial model generation. *Int J Oral Maxillofac Surg* 2000;29:2-10. ISSN 0901-5027.
- Xia JJ, Phillips CV, Gateno J et al (2006). Cost-effectiveness analysis for computer-aided surgical simulation in complex cranio-maxillofacial surgery. *J Oral Maxillofac Surg* 2006;64:1780-4. ISSN 0278-2391.

Zenha H, Azevedo L, Rios L, Pinto A, Luz Barroso M, Cunha C & Costa H (2011). The application of 3-D biomodelling technology in complex mandibular reconstruction - experience of 47 clinical cases. *Eur J Plast Surg*, Vol. 34, No. 4, (August 2011), pp. 257-265, ISSN 0930-343X.

IntechOpen

IntechOpen



Selected Topics in Plastic Reconstructive Surgery

Edited by Dr Stefan Danilla

ISBN 978-953-307-836-6

Hard cover, 242 pages

Publisher InTech

Published online 20, January, 2012

Published in print edition January, 2012

Plastic Surgery is a fast evolving surgical specialty. Although best known for cosmetic procedures, plastic surgery also involves reconstructive and aesthetic procedures, which very often overlap, aiming to restore functionality and normal appearance of organs damaged due to trauma, neoplasm, ageing tissue or iatrogenesis. First reconstructive procedures were described more than 3000 years ago by Indian surgeons that reconstructed nasal deformities caused by nose amputation as a form of punishment. Nowadays, many ancient procedures are still used like the Indian forehead flap for nasal reconstruction, but as with all fields of medicine, the advances in technology and research have dramatically affected reconstructive surgery.

How to reference

In order to correctly reference this scholarly work, feel free to copy and paste the following:

Horácio Zenha, Maria da Luz Barroso and Horácio Costa (2012). Advanced 3-D Biomodelling Technology for Complex Mandibular Reconstruction, Selected Topics in Plastic Reconstructive Surgery, Dr Stefan Danilla (Ed.), ISBN: 978-953-307-836-6, InTech, Available from: <http://www.intechopen.com/books/selected-topics-in-plastic-reconstructive-surgery/advanced-3-d-biomodelling-technology-for-complex-mandibular-reconstruction>

INTECH
open science | open minds

InTech Europe

University Campus STeP Ri
Slavka Krautzeka 83/A
51000 Rijeka, Croatia
Phone: +385 (51) 770 447
Fax: +385 (51) 686 166
www.intechopen.com

InTech China

Unit 405, Office Block, Hotel Equatorial Shanghai
No.65, Yan An Road (West), Shanghai, 200040, China
中国上海市延安西路65号上海国际贵都大饭店办公楼405单元
Phone: +86-21-62489820
Fax: +86-21-62489821

© 2012 The Author(s). Licensee IntechOpen. This is an open access article distributed under the terms of the [Creative Commons Attribution 3.0 License](#), which permits unrestricted use, distribution, and reproduction in any medium, provided the original work is properly cited.

IntechOpen

IntechOpen