

# We are IntechOpen, the world's leading publisher of Open Access books Built by scientists, for scientists

**4,800**

Open access books available

**122,000**

International authors and editors

**135M**

Downloads

Our authors are among the

**154**

Countries delivered to

**TOP 1%**

most cited scientists

**12.2%**

Contributors from top 500 universities



**WEB OF SCIENCE™**

Selection of our books indexed in the Book Citation Index  
in Web of Science™ Core Collection (BKCI)

Interested in publishing with us?  
Contact [book.department@intechopen.com](mailto:book.department@intechopen.com)

Numbers displayed above are based on latest data collected.

For more information visit [www.intechopen.com](http://www.intechopen.com)



## Models of Perspective on Various Kinds of Complex Congenital Heart Defects

Huai-Min Chen

*Department Cardiovascular Surgery,  
Kaohsiung Medical University Hospital, Kaohsiung,  
Assistant Professor of Surgery, School of Medicine,  
Kaohsiung Medical University, Kaohsiung  
Taiwan*

### 1. Introduction

Understanding normal and abnormal cardiac structures is best achieved through pathological specimens. Some cardiologists or cardiac surgeons are fortunate enough to work at centers where hearts from autopsies are preserved and catalogued for teaching purposes, but most practitioners still need to form a mental picture of the cardiac pathology and morphology. Actually, specific anatomic and diagnostic issues often remain in question after cautious preoperative and serial studies, and some physicians frequently fail to perform this mental exercise consistently. If we have a model which presents the cardiac anatomy and segmental relationship in a perspective view with a simple hand-drawn three-dimensional model to improve the understanding of the complex heart, it will be accessible to inexperienced staff and medical students and also to patients' families, and it will also save the considerable cost of image reconstruction. Some cardiac defects such as ASD, VSD, PDA, or TAPVR are easily visualized after echocardiographic examinations, but others remain challenges, especially hearts with misaligned cardiac segments and hearts with a double outlet right ventricle. In order to classify and clearly understand the variants of congenital cardiac defects, Dr. Van Praagh introduced three cardiac segments to establish a cardiac set. He used the coding system of the atrium, ventricle and great vessel to describe the hemodynamics and relationships of cardiac anatomy. The first code represents the atrium status including situs solitus or inversus. The second code represents the ventricular status including ventricular D-loop and L-loop. The third code represents the relationships of the great arteries including the aorta located anteriorly to the pulmonary trunk (D-malposition or L-malposition), and the aorta located posteriorly to the pulmonary trunk (solitus or inversus position). The system clearly categorizes complex cardiac defects, but different cardiac anomalies can be present under the same coding conditions and the hemodynamics of the codes and the connections between ventricular-arterial segments are still not easily understood by inexperienced personnel because the system lacks stereotactic structures. This is why we wished to develop a simple three-dimensional model to depict complex hearts. Before creating the models of variant congenital cardiac defects, we needed to determine the stereography of anomaly heart. We found the transverse cross-section of

heart at the atrio-ventricular junction offers the best reconstructive level for stereo-images because of its coverage of most cardiac structures and defects. From the picture, we can clearly visualize the heart with its specific relationships at the atrio-ventricular and ventricular-arterial segments. For the atrium, we used a broad-base triangular appendage to indicate the morphological right atrium; a finger and tube-like structure indicates the morphological left atrium. For the atrio-ventricular valves, we used the oval annulus with tri-leaflets, which indicates the atrio-ventricular valve of the morphological right ventricle; the bean-like structure with bi-leaflets indicates the atrio-ventricular valve of the morphological left ventricle; the aorta is indicated by the two coronary ostia. The tricuspid valves and pulmonary valves are separated by the ventricular infundibular fold (VIF) and infundibulum septum (crista supraventricularis).

## **2. The differentiation of great artery and aortic arch**

The embryonic courses of the cardiovascular system from the beginning of the cardiac tube to differentiation into the atriums, the ventricles, and the great arteries, and the setup of the complete circulation are very complicated and delicate. We will discuss mainly the changes among the ventricles and the great arteries including the migration, septation and absorption of the truncus; the following development of aorta and pulmonary artery; and finally, the possible variants of connection between ventricle and corresponding great artery. Understanding such embryonic defects and anomalies are very helpful to interpret the hemodynamic and treatment of complex congenital cardiac defects, especially in the part of mal-connections of cardiac segments.

## **3. The setup of circulation**

The initial circulation system is achieved by the almost simultaneous formation of the heart and three networks: intraembryonic, vitelline, and umbilico-allantoic. From the third week to the beginning of the second month of embryonic age, the embryo lives on its small reserves of yolk sac (the vitelline circulation); the primitive intraembryonic circulation and allantoic circulation are forming. At the end of the second month, the vitelline circulation disappears and the allantoic circulation becomes the placenta stage by connecting the umbilical vessels and placenta.

## **4. The transformation of aorta**

The primitive arterial system undergoes numerous modifications in its development, which are quite complex in the anterior region where aortic arches are formed. The ventral arteries, the first aortic arches, and the dorsal aortas are continuous. In each branchial arch, 5 pairs of aortic arches are formed successively and join the ventral to the dorsal aortas. The dorsal aortas extend from the cranial region to the caudal region and develop paired segmental arteries to the somites. The left and right primitive ventral aortas and aortic arches arise from the dilated terminal region of truncus, known as aortic sac, and terminate in the primitive dorsal aorta of the corresponding side. The two dorsal aortas approach each other and fuse at about week 4 to form the adult descending aorta. During weeks 6 to 8, the primitive aortic arch pattern is transformed into the basic adult arterial arrangement. The details of differentiations of five paired arches are discussed as below:

## 5. Regression of aortic arch

In Fig.1 we demonstrate the regression of aortic arch. Six pairs of aortic arches in pharyngeal arches are theoretically formed; however, the fifth pair is essentially only a temporary doubling of the fourth pair, and the aortic arches are never all present at the same time. When the third and fourth arches appear, the first and second arches have disappeared (before 31 days of embryo age).

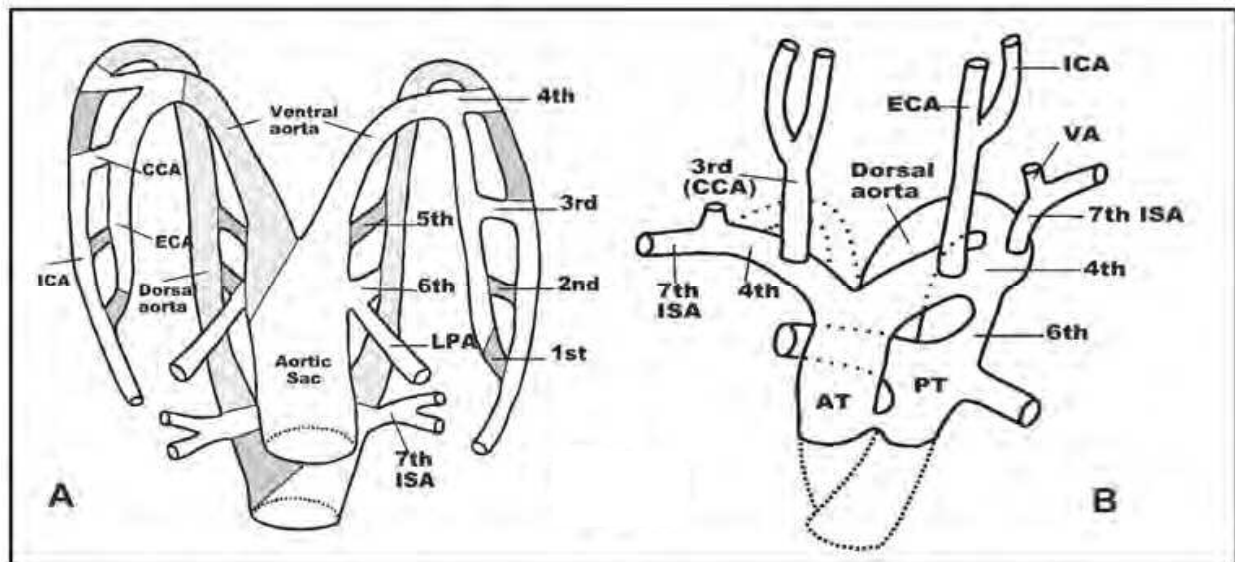


Fig. 1. The developments and regression of aortic arches from embryonic pharyngeal arches to adult aorta. Fig.1.A presents the primitive aorta in embryo stage, and the gray-colored area marks the regions will undergo regression and absorption. Fig.1-B presents the basic adult aorta. AT: aortic trunk; CCA: common carotid artery; ECA: external carotid artery; ICA: internal carotid artery; ISA: intersegmental artery; LPA: left pulmonary artery; PT:pulmonary trunk; VA: vertebral artery.

The first and second paired aortic arches are nearly completely regressed in the main except for the small part that develops into capillary structures of the maxillary artery; the dorsal aorta between the third and fourth paired aortic arches will be totally absorbed, making the bilateral third aortic arches form common carotid arteries and proximal part of internal carotid arteries (ICAs) on both sides, and its distal part of the primitive ventral aorta will form the external carotid artery (ECA) as well as the distal part of the primitive dorsal aortic forms the internal carotid artery (ICA); the fourth arch on the left forms the aortic arch which is located between the left common carotid artery (LCCA) and the left subclavian artery (LSCA), and the right one forms the right innominate artery and the proximal part of the right subclavian artery (RSCA); the fifth arch almost completely regresses before developing; the sixth arch appears during the middle period of the 5th week of embryo, the bilateral proximal parts (close to aortic sac) will form the left pulmonary artery (LPA) and the right pulmonary artery (RPA), but the distal part of the left side will form the ductal arteriosus, and the distal part of the right one will completely regress. The distal part of the pulmonary artery is derived by buds of the sixth arch and develops into the pulmonary system. Once the partitioning of the truncus finishes, the pulmonary arteries will arise from

the pulmonary trunk. After the pulmonary vascularization completes, the primitive right dorsal aorta will totally and completely regress from the site of bifurcation.

Concerning the seventh intersegmental artery (ISA), its left part forms the LSCA, and the right part forms the distal RSCA, so the primitive dorsal aorta between the 4th arch and 7th ISA will totally disappear. The left dorsal aorta goes on remodeling by a wide margin making the left 7th ISA, while the ductus arteriosus and the left fourth arch link together in a very short distance.

## 6. Developments of Cono-Truncus-Aortic sac (aortic-pulmonary septum)

The vascular developments and changes we will state as follows:

From ventricular outflow tract to aortic sac, the truncus can be divided into three regions by the level. The proximal part of the conus is linked with the ventricle, followed successively by the truncus, and the distal part of the aortic sac. Finally the truncus will differentiate into the aorta and pulmonary artery by complex procedures. Firstly, the conus will undergo three stages of development including septation, migration and absorption. During conus septation, the conus will present 2 masses: Dextro-Dorsal Conal Crest (DDCC) and Sinistra-Ventral Conal Crest (SVCC). The DDCC extends to ventricular outflow tract and fuses with the Superior Endocardial Cushion (SEC) and the Right Lateral Endocardial Cushion (RLEC) to form crista supraventricularis which will be a septum among the Tricuspid valve and pulmonary valve; SVCC extends to ventricular outflow tract and forms the left part of the outlet septum (conal septum) with some SEC, which becomes a part of the primitive interventricular septum (Fig.2).

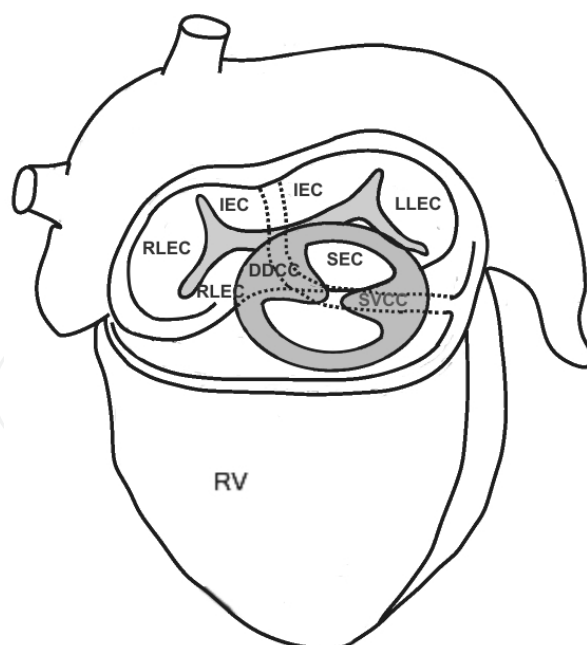


Fig. 2. The anatomic and structural relationships of endocardial cushion and conus-truncus at the level of atrio-ventricular and ventricular-arterial junctions. DDCC: dextro-dorsal conal crest; IEC: inferior endocardial cushion;; LLEC: lateral endocardial cushion ; RLEC: right lateral endocardial cushion ; SEC: superior endocardial cushion; SVCC: sinistra-ventral conal crest.



Two masses will present in truncal level, too. It is Dextro-Superior Truncal Swelling (DSTS) and Sinistra-Inferior Truncal Swelling (SITS) respectively. The DDCC will extend superiorly and fuse with the DSTS, and the SVCC also extends superiorly and fuses with SITS (Fig.3.1). During the fusion processes procession, two masses of right intercalated truncal swelling (RITS) and left intercalated truncal swelling (LITS) in the pulmonary conus and aortic conus will present between the conal and truncal levels, which will fuse with DSTS and SITS and form the future semilunar valves of the great arteries. From the above-mentioned discussion, we can observe the vascularities which form the pulmonary system are developed from the sixth paired arches and their buds. The arches are closed to the aortic sac and extended from ventral aorta to dorsal aorta, so the posterior cavity of the aortic sac will differentiate into the pulmonary trunk and fuse with the primitive pulmonary artery to become the pulmonary system (Fig.1). So after septation of the truncus, the pulmonary trunk, no matter whether right-sided or left-sided, will be at the rear of the aortic trunk at the level of terminal aortic sac (aortic-pulmonary septum). This concept is very important for us to realize the various types of ventricular-artery mal-connection and to judge the possible truncal positions.

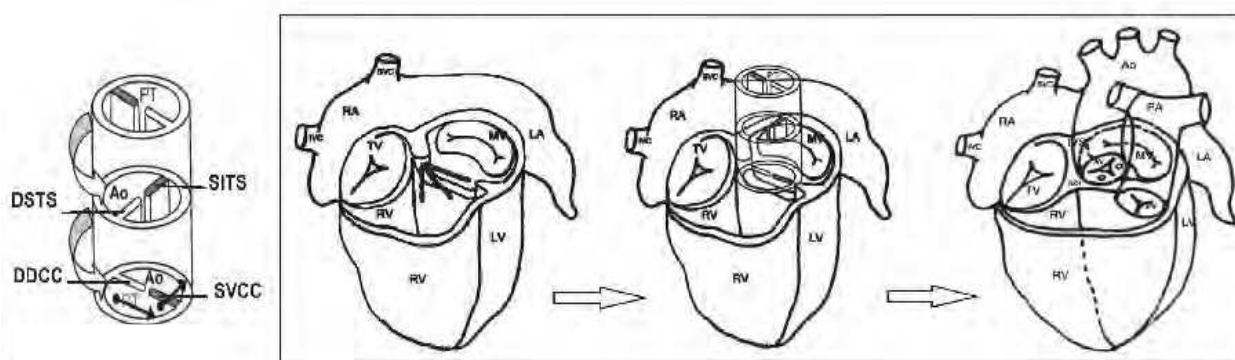


Fig. 3.1. The creation of cardiac perspective model step by step with the combination of truncus and heart with atrio-ventricular structures. There are three possibilities in direction of conal septum above the primitive interventricular septum. The conal septum is parallel to the IVS in this figure. The extension and spiral rotation of conal septum (DDCC-SVCC) to truncal septum (DSTS-SITS) and more extension to aorto-pulmonary septum result in the pulmonary artery rotates from right to left and from anterior to posterior. DDCC: dextro-dorsal conal crest ; DSTS: Dextro-Superior Truncal Swelling ; SITS: Sinistra-Inferior Truncal Swelling ; SVCC: Sinistra-Ventral Conal Crest.

## 7. Development of endocardial cushion

Before we study the field of ventricular-arterial connection and the atrioventricular septal defect (endocardial cushion defect), we should know the development and composites of the endocardial cushion (Fig.2). The endocardial cushion is fused by the inferior endocardial cushion (IEC), superior endocardial cushion (SEC), right lateral endocardial cushion (RLEC),

left lateral endocardial cushion (LLEC), interatrial septum (IAS), primitive interventricular septum (IVS), dextrodorsal conal crest (DDCC), and sinistroventrol conal crest (SVCC). The DDCC and SVCC in Conal trunk (cavity) will fuse with the primitive interventricular septum and form the conal septum. The DDCC will extend to SEC and RLEC, which changes to the cristal supraventricularis. The cristal supraventricularis can be separated into the septal portion and parietal portion (ventricular infundibular fold, i.e., free wall between inferior vena cava and RV). The ventricular infundibular fold (VIF) is the main part to separate the tricuspid valve and the pulmonary valve. The SEC will develop into the free portion of anterior mitral leaflet, the left surface portion of the infundibular septum, the external wall of the left ventricular outlet tract (LVOT), and the left side surface of the outlet septum.

The IEC will develop into the septal portion of the anterior mitral leaflet, the septal leaflet of the tricuspid valve, and the inlet septum of the IVS. The IEC will fuse with the septum primum and close the foramen primum. The LLEC develops into the posterior mitral leaflet, and the RLEC develops into the posterior leaflet and the lateral portion of the anterior-lateral leaflet of the tricuspid valve. The DDCC differentiates into the median portion of anterior leaflet of the tricuspid valve, the right side surface of cristal supraventricularis and outlet septum. The secondary inter-ventricular foramen is closed by the fusion of the IEC, primitive IVS, DDCC, and SVCC (Fig.2). The fusion of DDCC and SVCC will become the conal septum, i.e. the parietal band of septal marginal trabecularis (SMT). It can extend anteriorly to form the anterior limb of SMT, and extend posteriorly to form the posterior limb of SMT. The portion above the two limbs is the septal portion of crista supraventricularis which is formed by the regression of DDCC and SEC, it also can be called as infundibular septum or outlet septum. The other part is the parietal portion of crista supraventricularis which is formed by the regression of DDCC and RLEC; it is located between the posterior limb of SMT, primitive IVS, and the free wall of right ventricle. It is also called as the ventricular infundibular fold (VIF). The parietal band (anterior limb and posterior limb) and the septal band of right ventricle we can group as the septal marginal trabecularis (Fig.3.2). That is to say, the conal crest of DDCC and SVCC inserts itself from the posterior limb of septal marginal trabecularis (SMT) to the anterior limb of SMT, and the conal septum is formed. The conal septum and the crista supraventricularis will separate the right and left ventricle. But before the conal septum does not completely fuse, the ventricle and truncus still link through the primitive interventricular foramen, so the free border of the primitive IVS and the endocardial cushion will be the margins of the primitive interventricular foramen. After the fusion processes of DDCC and SVCC are completed in upward and downward directions, the primitive interventricular foramen is then closed. The ventricle will link with its own trunk at this moment, and only the secondary interventricular foramen is left to communicate between two ventricles (Fig.6). If the secondary interventricular foramen is still open after birth, then it would be the so-called ventricular septal defect (VSD). Finally, the membrane septum will close the secondary interventricular foramen and the primitive IVS, and the course of ventricular septation is completed. The margins of the secondary interventricular foramen are as below: the posterior inferior margin is made up by the free border of IEC; the anterior margin is made up by the free border of primitive IVS; and the floor is supported by the conal septum.

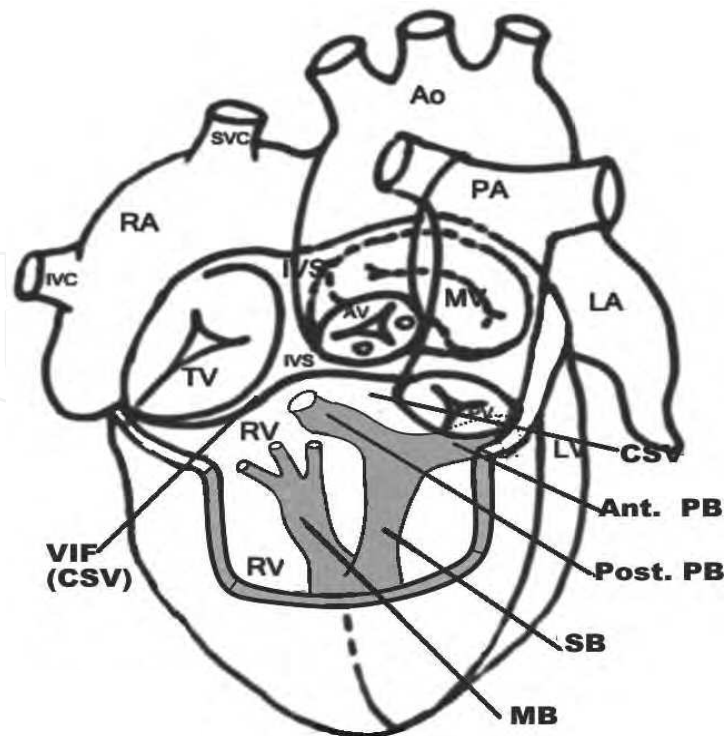


Fig. 3.2. The longitudinal cross-section of right ventricle to demonstrate the anatomies of right surface of inter-ventricular septum. CSV: cristal supra-ventricularis; MB: moderate band; PB: parietal band; SB: septal band; VIF: ventricular infundibular fold.

## 8. The spiral rotation of truncus and arrangement of great arteries

Most of the developmental defects of ventricular outflow tract are related with cardiac neural crest. During the course of embryonic development, neural crest provides the cells to differentiate into a septum to separate the aortic trunk and pulmonary trunk. In animal models, we can find the outflow tract defects in neural crest-resected embryos. These anomalies involve aorta, pulmonary artery, and mal-alignment or mal-connection of ventricles. From the outflow tract to the terminal of cardiac tube (Aortic sac) during the time of normal development, its endocardial jelly inside will form a pair of cushions arranged in opposite directions, and these cushions will be twined spirally together in the course of extending, and run through the whole tract. The cells come from neural crest infiltration and migration to outflow tract and distal endocardial cushion at the same time, and the next is the integration of endocardial cushion. This course will begin from the distal part of truncus; the terminal outflow tract will be divided into aortic trunk and pulmonary trunk, and merge with mesenchymal cells of the posterior wall of aortic sac. The aortic trunk connects with the left 4th paired arch, and pulmonary trunk connects with the left 6th paired arch.

From these models, we observe the septum will extend from ventricular outflow tract to conal and truncal septum, if posterior aspect of conal cavity can extend to anterior aspect of truncal cavity after spiral rotation, it will present a relative longer outflow tract. That is to say, there will be fibrous discontinuity (muscle band) between ventricle and great artery. But if it is anterior aspect of conal cavity extending to be the posterior aspect of truncal cavity during the septal rotation (such as the pulmonary artery in {S.L.D}-IAI), then it will



have relatively short outflow tract, and may present fibrous continuity in ventricular-arterial connection. On the contrary, if it is the posterior aspect of conal cavity rotating to posterior aspect of truncal cavity, it will be the same situation with a relatively short outflow tract and fibrous continuity in ventricular-arterial connection (the aorta in {S.D.S}-normal heart). In the vertical conal septum, the direction of interventricular septum (ventricular looping status) and spiral rotation of truncal septum will be the key points, but the median cavity is the usual one with the fibrous continuity. The left one in D-looping status and the right one in L-looping status stands for the median conus respectively.

## 9. Built-up the perspective model

In Fig.3.1, we have reconstructed the perspective model with the combination of heart with atrio-ventricular structures and truncus step by step to exhibit the A-V and V-A relationships. Really, any model can be built by such a method. The first step is to define the ventricular looping status and the direction of IVS, which is right-posterior to left-anterior in D-looping ventricle and left-posterior to right-anterior in L-looping ventricle. The conal septum may be parallel to the IVS or not depending on the conal position and direction. There are three even four (horizontal) possibilities of different conal directions that could be considered. The second step is to determine the position and rotation of truncal cavity in individual great artery. Such a rotation can be counterclockwise or clockwise in direction or even with no rotation. I believe the counterclockwise rotation of the conal-truncal septum more easily happens in D-looping heart and the clockwise rotation of the conal-truncal septum more easily happens in L-looping heart. The final step is to put the pulmonary trunk in posterior position with the decision of aorta in rightward or leftward, and the descending aorta is located on the same side with the main pulmonary artery. In this figure we use the {S.D.S}-normal heart to demonstrate the procedures of how to build the perspective cardiac models.

## 10. Hypothesis of cardiac segmental connections

The heart is differentiated from a cardial tube into two atriums, two ventricles, and two trunks; how to guarantee its connection's exactness is very important for the survival of the organism after birth. How to keep its correct relationship after serial migration, septation, spiral rotation and absorption between the distinct ventricle and related trunk is the field that we still fail to understand in depth. Actually, among them, every step finishes under rigorous genetic regulation and control. Even so, the principle of hydromechanics must be followed in blood flow. So we put forward the following assumptions to explain the possible developments and variations from ventricle to conus, conus to truncus and to the aorto-pulmonary septum:

1. Just as in the previous discussion, the pulmonary trunk which arises from aortic sac, no matter whether left-sided or right-sided, will be in the posterior aspect.
2. From conal septum to truncal septum and truncal septum to aorto-pulmonary septum, the angle of spiral rotation between them should not be too wide.
3. From conal septum to truncal septum, and truncal septum to aorto-pulmonary septum, its direction of extension (i.e. spiral rotation) will be identical, and the pulmonary trunk after complete septation will be the location in posterior aspect.

4. The rotational direction of truncal septum will change the blood flow from ventricular outflow tract (ventricle-conus) and result in different hemodynamics (such as {S.D.L} which can be the anatomically corrected malposition (ACM), and can be the complete TGA (cTGA), which is decided by the rotational direction of truncal septum).
5. The conal septum and truncal septum are similar to water diversion boards which drain the blood flow from ventricle to its own circulation.

## 11. Variants of the septation and spiral rotation of Cono-Truncal septum

In Figs. 4.1 ~ 4.3, we have listed the different possible abnormalities of the truncus regarding the septal septation and spiral rotation. Discussed in aortic sac level as above, only the two kinds of right-posterior pulmonary trunk and left-posterior pulmonary trunk are possible; the DSTS and SITS also determine the truncal septum in the direction of left-posterior to right-anterior in truncal level, but sometimes may present Dextro-Inferior Truncal Swelling (DITS) and Sinistra-Superior Truncal Swelling (SSTS), then the truncal septum will be turned into right-posterior to left-anterior oblique direction.

So we can sort the relationships of the two great arteries as four groups by the position of aortic trunk in the truncal level according to the classification and coding system of Dr. Van Praagh, they are {---.S} (Ao is right posterior to PA), {---.I} (Ao is left posterior to PA), {---.D} (Ao is right anterior to PA), and {---.L} (Ao is left anterior to PA).

As for the direction of conal septum which is decided by DDCC and SVCC, the direction of conal septum is right-posterior to left anterior oblique direction and is identical to the interventricular septum in the normal D-looping ventricle. But this may present the abnormal conal septums with Dextro-Ventro Conal Crest (DVCC) and Sinistra-Dorsal Conal Crest (SDCC) and cause the direction of conal septum to become left-posterior to right-anterior oblique direction (alike as the direction of interventricular septum in L-looping ventricle). In addition, we also discuss the condition of side-by-side conal cavities, i.e. the situation of vertical conal septum.

The direction extended from conal septum to truncal septum may be a clockwise rotation, may be counterclockwise too, and may continue the same direction to extend to aorta-pulmonary septum. The course of such spiral rotation may stop, and cause conal septum, truncal septum or aorta-pulmonary septum to be all in the same direction (such as {S.D.D}-cTGA). But the location of the pulmonary trunk is posterior to the aortic trunk in the level of aortic sac, so aortic trunk and pulmonary trunk in conal level will be decided by the whirling direction of septums (conal and truncal septums), instead of deciding from its connected ventricle.

### 11.1 Direction of right-posterior to left-anterior conal septum

In Fig. 4.1 we list all possible relationships of two great arteries based on the direction of right-posterior to left-anterior conal septum. In accordance with the direction of truncal septum, we divide this group into three subgroups: no change in direction, counterclockwise rotation, and clockwise rotation in direction respectively. Each truncal subgroup can still be divided into two to three groups according to the direction of aorto-pulmonary septum: no change in direction, counterclockwise rotation, and clockwise rotation in direction, too.

Right-posterior to Left-anterior Conal septum		Same direction of A-P septum	Counter clockwise rotation of A-P septum	Clockwise rotation of A-P septum	
Same direction of Truncal septum				{S.D.D}-cTGA	{S.D.I}-IIAI
				{S.L.D}-IAI-M	{S.L.I}-ccTGA (?)
Counter clockwise rotation of Truncal septum				{S.D.L}-cTGA	{S.D.S}-normal
				{S.L.L}-IAI (?)	{S.L.S}-ccTGA
Clockwise rotation of Truncal septum				{S.D.L}-ACM	{S.D.L}-ACM
				{S.L.L}-ccTGA	{S.L.L}-ccTGA

Fig. 4.1. All possibilities of different directions of conal -truncal - aortopulmonary Septum in the group of right-posterior to left-anterior conal septum. Three subgroups of same direction of truncal septum, counter clockwise rotation and clockwise rotation of truncal septums are listed. Two to three subtypes are included in each subgroup according to the direction of aortopulmonary septum. The anatomies and hemodynamic status are different between D-looping and L-looping ventricle in the same subtype. Arrow head presents the direction of spiral rotation from the lower truncus to the upper truncus. ACM: anatomically corrected malposition; cTGA: complete Transposition of Great Artery; ccTGA: congenital corrected TGA; IAI-M: isolated atrial inversion with malposition; IIAI: isolated infundibulo-arterial inversion.

Actually the hemodynamics are not really decided by the directions of the three septums, the atrio-visceral status and ventricular looping status play the most important parts. For example, if a heart possess the same direction of right-posterior to left-anterior in conal, truncal, and aorto-pulmonary septums, it can be the type of {S.D.D}-cTGA in D-looping status or the type of {S.L.D}-IAI-M (IAI with mal-position of great artery and we will discuss later) in L-looping status; but if we consider the more complex anomaly such as DORV, such a situation we have another section to discuss. This group can be classified into several subgroups such as {S.D.D}-cTGA, {S.D.I}-IIAI, {S.D.L}-cTGA, {S.D.S}-normal heart, and {S.D.L}-ACM in D-looping status; {S.L.D}-IAI-M, and {S.L.L}-ccTGA in L-looping status. Besides, there is the presence of two questionable arrangements as {S.L.I}-ccTGA, {S.L.L}-IAI, and we have marked them with question marks in Fig. 4.1. The hollow big arrow point means the direction of spiral rotation from lower (proximal) septum to upper (distal) septum, and the solid small arrow point means the direction of blood flow under the guide of conal septum and truncal septum. All types of perspective cardiac models we list in Figs .5.1~Fig.5.4, and the all cardiac models are discussed and set in situs solitus of atrial status ({S. --.--}).

### 11.2 Direction of left-posterior to right-anterior conal septum

Similarly we list all possibilities based on the direction of left-posterior to right-anterior conal septum in Fig. 4.2 and this group can be classified into several subgroups such as {S.D.L}-ACM, {S.D.S}-posterior TGA, {S.D.D}-cTGA, and {S.D.I}-posterior TGA in D-looping status; {S.L.L}-ccTGA, {S.L.S}-IVI, {S.L.D}-IAI-M, {S.L.D}-ccTGA, and {S.L.I}-IAI in L-looping status. There is a questionable arrangement in this group which is {S.D.D}-ACM.



Left-posterior to Right-anterior Conal septum		Same direction of A-P septum		Counter clockwise rotation of A-P septum		Clockwise rotation of A-P septum	
Same direction of Truncal septum			{S.D.L}-ACM		{S.D.S}-Posterior TGA		{S.D.L}-ACM
			{S.L.L}-ccTGA		{S.L.S}-IVI		{S.L.L}-ccTGA
Counter clockwise rotation of Truncal septum			{S.D.D}-cTGA		{S.D.D}-cTGA		
			{S.L.D}-IAI-M		{S.L.D}-IAI-M		
clockwise rotation of Truncal septum			{S.D.D}-ACM (?)				{S.D.I}-Posterior TGA
			{S.L.D}-ccTGA				{S.L.I}-IAI

Fig. 4.2. Group of left-posterior to right-anterior conal septum. The detailed description is the same as in Fig. 4.1. ACM: anatomically corrected malposition; cTGA: complete transposition of great artery; ccTGA: congenital corrected TGA; IAI: isolated atrial inversion; IVI: isolated ventricular inversion.

### 11.3 Vertical truncal septum

In Fig. 4.3, we exclude the possibilities of vertical truncal septum because it is not addressed by Dr. Van Praagh. Two subgroups are listed with all types of {S.D.D}-cTGA and {S.D.L}-ACM in D-looping status; {S.L.D}-IAI-M and {S.L.L}-ccTGA in L-looping status. We also exclude the possibilities of horizontal conal septum because it more easily occurs in the conal-truncal malformations such as DORV, so we discuss such condition in the section of DORV.



Vertical Conal septum		Same direction of A-P septum	Counter clockwise rotation of A-P septum	clockwise rotation of A-P septum
Counter clockwise rotation of Truncal septum		 {S.D.D}- cTGA {S.L.D}- IAI-M	 {S.D.D}- cTGA {S.L.D}- IAI-M	
clockwise rotation of Truncal septum		 {S.D.L}- ACM {S.L.L}- ccTGA		 {S.D.L}- ACM {S.L.L}- ccTGA

Fig. 4.3. Group of vertical conal septum. The detailed description is as in the Fig. 4.1. ACM: anatomically corrected malposition; cTGA: complete transposition of great artery; ccTGA: congenital corrected TGA; IAI-M: isolated atrial inversion with malposition.

## 12. Classification by ventricular looping

If we categorize the segmental mal-connections of the heart according to the ventricular looping status and the four relationships of truncal cavity, we can put several following groups in order.

In D-looping group there are the following possibilities:

1. [S.D.S]--- normal heart or posterior TGA
2. [S.D.L] --- cTGA or ACM (with six variants)
3. [S.D.D] --- cTGA (with six variants)
4. [S.D.I] --- Posterior TGA or IIAI

In L-looping group there also are the following possibilities:

1. [S.L.S] --- IAI
2. [S.L.I] --- IAI
3. [S.L.D] --- IAI-M (with six variants) or ccTGA
4. [S.L.L] --- ccTGA (with six variants)

The corresponding relationships of conal septum, truncal septum, and AP septum can refer to the Fig.4.1~Fig.4.3.

## 13. Atrio-Ventricular and Ventricular-Arterial relationship

According to the corresponding relations of their Atrial-Ventricular and Ventricular-Arterial connection again, we can divide segmental mal-connection of the heart into four groups as well. We also depict their unusual mechanisms and figure the perspective models in the following.



### 13.1 Atrio-Ventricular concordance with Ventricular-Arterial concordance

In the group of atrio-ventricular (A-V) concordance with ventricular-arterial (V-A) concordance (Fig.5.1), three subgroups of {S.D.S}-normal, {S.D.I}-IIAI, and {S.D.L}-ACM are included. In (S.D.S) the tricuspid valves and pulmonary valves are separated by the ventricular infundibular fold (VIF) and infundibulum septum (crista supraventricularis). The aorta is posterior and to the right of the main pulmonary artery at the level of the valves and it rotates 90 to 110 degrees in a counter clockwise direction which results in the aorta lying anteriorly to the pulmonary arteries at the level of the aorto-pulmonary trunk.

The {S.D.I} is characterized by the two great arteries normally related with inversion, with the result that there is no hemodynamic derangement in patients with IIAI. However, significant associated malformations often coexist including dextrocardia, criss-cross heart, large VSD, and conotruncal malformation of the inverted TOF. The aortic-mitral continuity excludes the other diagnostic possibility of an anatomically corrected malposition of the great arteries ({S.D.L}-ACM). ACM means that the great arteries are abnormally related to each other and to the ventricles, but they arise above anatomically corrected ventricles. The aorta arises anteriorly and to the left of the main pulmonary artery and the muscular subaortic conus separates the aortic and mitral valves, which may result in hypoplasia of the aorta. Both the aorta and subaortic conus are above the left ventricle. Twisting of the conus-truncus in one direction and of the ventricular loop in the opposite direction appears to be of central importance in the morphogenesis of ACM. The external morphology may be misdiagnosed as {S.L.L}-TGA, but from the epicardial course of coronary arteries and ventricular trabeculation, a differential diagnosis can be made between {S.L.L}-TGA and {S.D.L}-ACM. However, in a rare condition the {S.D.L}/{I.L.D} may present an anatomy other than ACM with the characteristics of TGA. That is to say, the {S.D.L}/{I.L.D} may have the anatomy of ACM or TGA. The conditions also happen in the type of {S.L.D} groups.

We will discuss why the two different hemodynamics can be present in {S.D.L} and {S.L.D}. In the six variants of {S.D.L}-ACM they can be divided into two groups based on the location of pulmonary trunk at the level of AP septum, one is right-posterior and the other is left-posterior respectively. Each group consists of three subtypes and they are different in the directions of conal septum which one is right-posterior to left-anterior conal septum, another is left-posterior to right-anterior conal septum, and the other is vertical conal septum. Although the conal septums are different in directions, the perspective cardiac models would be similar. In spite of the differences between their conal directions, they are consistent in the spiral rotation from conal septum to truncal septum and truncal septum to the AP septum (clockwise direction) respectively, and this is different from the {S.D.L}-cTGA which is in counterclockwise rotation from conal septum to truncal septum. Either left-posterior or right-posterior aspect of pulmonary trunk, the three subtypes of {S.D.L}-ACM we demonstrate with the similar cardiac model because we find the direction of truncal septum plays the role of guiding the blood flow by extension with the conal septum when the blood is pumped from ventricular outflow tract and conal cavity, and the site of conal cavity and the direction of conal septum will determine the constructions between the ventricle and the corresponding great artery such as mitral-aortic/ mitral-pulmonary/ tricuspid-aortic/ tricuspid-pulmonary fibrous continuity or discontinuity. The difference in the two subgroups of {S.D.L}-ACM is the further rotation between the truncal septum and the AP septum, and it leads the aortic conus and aortic trunk (level of AP septum) occupies on the opposite site which causes more degrees of spiral rotation on the external appearance of great arteries.

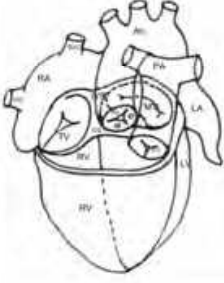
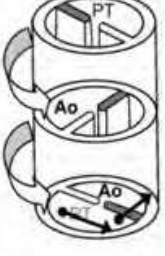
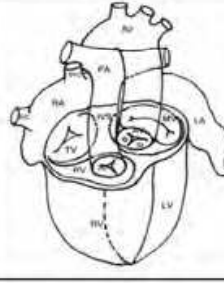
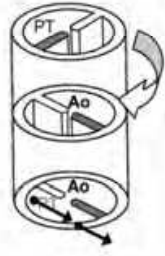
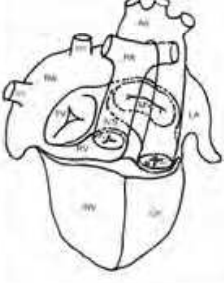
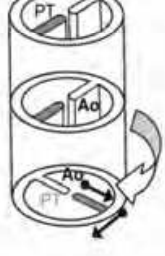
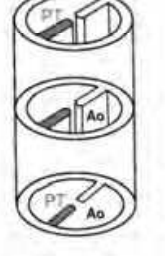
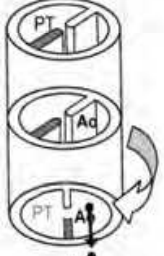
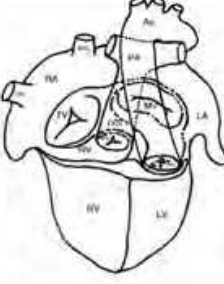
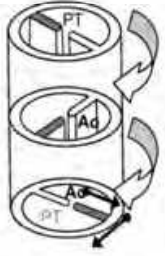
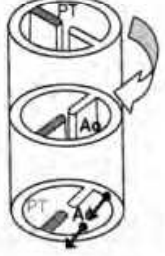
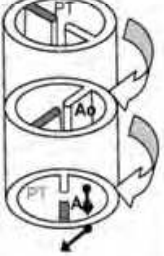
<b>A-V concordance V-A concordance</b>		<b>Rt-posterior to Lt-anterior conus</b>	<b>Lt-posterior to Rt-anterior conus</b>	<b>Vertical conus</b>
<b>{S.D.S)- Normal</b>				
<b>{S.D.I)-IIAI</b>				
<b>{S.D.L)-ACM Pulmonary trunk over right-posterior</b>				
<b>Pulmonary trunk over left-posterior</b>				

Fig. 5.1. The perspective cardiac models and corresponding truncus with the hemodynamic of atrio-ventricular concordance and ventricular-arterial concordance. Three subgroups, {S.D.S)-normal, {S.D.I)-IIAI, and {S.D.L)-ACM, are included. In the six variants of {S.D.L)-ACM they can be divided into two groups based on the location of pulmonary trunk at the level of AP septum. Each group consists of three subtypes and they are different in the directions of conal septum. Although the conal septums are different in directions, the perspective cardiac models would be similar. ACM: anatomically corrected malposition; IIAI: isolated infundibulo-arterial inversion.

### 13.2 A-V discordance with V-A concordance

In the group of A-V discordance with V-A concordance (Fig.5.2), three subgroups of {S.L.S}-IVI, {S.L.I}-IAI, and {S.L.D}-IAI-M are included. In {S.L.S}-IVI this rare cardiac malformation is characterized by atrio-ventricular discordance, ventricular-arterial concordance, and normally related great arteries in a spiral fashion, but the ventricles are inverted in relation to the normal heart. The conal crest develops abnormally with an abnormal direction of conal and inter-ventricular septum from right to left and anterior to posterior. The main pulmonary artery originates from the left-sided morphological right ventricle with a sub-pulmonary conus. The systemic venous return drains into a right-sided morphological left ventricle and also pumps the blood directly into the aorta in the same way as with {S.L.I}-IAI. The patient will suffer from cyanosis and could be treated with an atrial switch operation. The difference between {S.L.I}-IAI and {S.L.S}-IVI is the relationship of the great arteries and the orientation of the truncal septum (spiral rotation between conal-truncal level in {S.L.I}-IAI and the rotational direction between truncal -AP septum level).

The mirror image of {S.L.I} is {I.D.S} and it enables us to more clearly understand the hemodynamics of {S.L.I}/{I.D.S} present the characteristics of isolated atrial inversion. In this subgroup of {S.L.D} there also exist six variants with three of right-posterior aspect of pulmonary trunk and the other three of left-posterior aspect of pulmonary trunk. The hemodynamics in these six variants possess the same characteristics of systemic venous flow returns to right-sided left ventricle with pumping into aorta; the pulmonary venous flow returns to left-sided right ventricle with pumping into pulmonary artery. The aorta is located on right anterior to pulmonary artery which looks like anatomically corrected malposition (ACM) or transposition of great artery (TGA) but is not, because their hemodynamics are not the ACM's A-V and V-A concordance nor the TGA's A-V concordance with V-A discordance, so they should be coded as the name of "isolated atrial concordance (IAC)" or the "IAI with mal-position of great artery (IAI-M)" instead of the ACM malformation. We favor the term of {S.L.D}/{I.D.L}-IAI-M. The differences between the {S.L.D}-ccTGA and {S.L.D}-IAI-M are the opposite spiral rotation of truncal septum (the direction of truncal extension), and the ventricle of subaortic conus connected (mitral-aortic discontinuity in {S.L.D}-IAI-M and tricuspid-aortic discontinuity in {S.L.D}-ccTGA). Without the intracardiac evaluation, the two external morphologies look alike especially the one of {S.L.D}-IAI-M with pulmonary trunk over left-posterior. Just the same as in {S.D.L}-ACM, the further rotation of truncal septum to AP septum cause the aortic conus and aortic trunk to be located on the opposite side. We also use the same perspective cardiac model to stand for each of the three variants in the two subgroups of {S.L.D}-IAI-M because they are just different in the directions of conal septum. Patients in this group will suffer from cyanosis due to the A-V discordance and V-A concordance, so the atrial switch operation is the option of treatment. Of course, the associated cardiac anomalies should be evaluated before intervention.

### 13.3 A-V concordance and V-A discordance

In the third group of A-V concordance and V-A discordance (Fig. 5.3), four subgroups of {S.D.S}-posterior TGA, {S.D.I}-posterior TGA, {S.D.L}-cTGA, and {S.D.D}-cTGA are included.


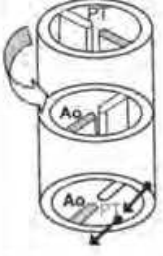
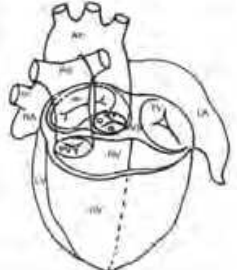
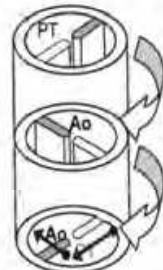
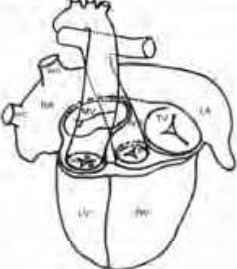
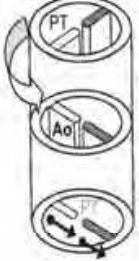
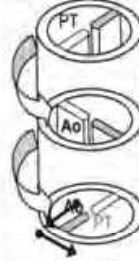

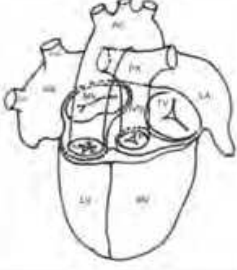
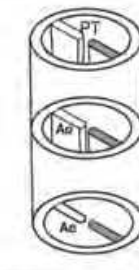


<b>A-V discordance</b> <b>V-A concordance</b>		<b>Rt-posterior to Lt-anterior conus</b>	<b>Lt-posterior to Rt-anterior conus</b>	<b>Vertical conus</b>
<b>{S.L.S}-IVI</b>				
<b>{S.L.I}-IAI / {I.D.S}</b>				
<b>{S.L.D}-IAI-M</b>  <b>Pulmonary trunk over right-posterior</b>				
<b>Pulmonary trunk over left-posterior</b>				

Fig. 5.2. The perspective cardiac models and corresponding truncus with the hemodynamic of atrio-ventricular discordance and ventricular-arterial concordance. Three subgroups, {S.L.S}-IVI, {S.L.I}-IAI, and {S.L.D}-IAI-M, are included. In the six variants of {S.L.D}-IAI-M they can be divided into two groups based on the location of pulmonary trunk at the level of AP septum. Each group consists of three subtypes and they are different in the directions of conal septum. Although the conal septums are different in directions, the perspective cardiac models would be similar. IAI-M: isolated atrial inversion with malposition. IVI: isolated ventricular inversion.

The patients will suffer from cyanosis but they should be treated with arterial switch operation. In {S.D.S}-posterior TGA the conal septum is reversed as compared with the {S.D.S}-normal heart and the other difference is the lack of the spiral rotation between the conal-truncal septum In {S.D.S}-posterior TGA. The external morphologies are similar regardless of atrial-ventricular appearance and the relationship between the great artery, nonetheless we can differentiate from the mitral-aortic fibrous continuity and tricuspid-pulmonary discontinuity in {S.D.S}-normal heart, but in {S.D.S}-posterior TGA the aortic valve is located right-posterior-inferior to the pulmonary valve and aortic-mitral fibrous continuity may persist through a high VSD or some present with aortic-tricuspid fibrous continuity because of the deficiency of the subaortic muscular conus. The greater part of the aortic orifice is above the right ventricle and the pulmonary artery arises to the left of the conal septum and is completely above the left ventricle. The two great vessels are in a spiral relationship rather than straight and parallel as in (S.D.D)-TGA or (S.L.L)-TGA. The flow of circulation is atrio-ventricular concordant and ventricular-arterial discordant in the same manner as in TGA. In {S.D.I}-posterior TGA, the aortic conus is located on the right-posterior aspect but the spiral rotation of the truncal septum results in the pulmonary trunk being more anterior and rightward, so the pulmonary valve is right-anterior to the aortic valve with the further extension of pulmonary trunk. The ventricular-arterial connections are mitral-pulmonary fibrous discontinuity and tricuspid-aortic fibrous continuity.

The type of {S.D.L}-cTGA possesses the same directions of truncal septum and AP septum and sometimes the conal septum as the type of {S.D.L}-ACM but the hemodynamic is really different just because the direction of spiral rotation is quite contrary. The two types are almost the same in the external morphology, besides, the subaortic conus is also present in the two types. So the major differences are the direction of the conal-truncal extension and the connections between ventricles and great arteries, which are the tricuspid-aortic discontinuity with subaortic conus in {S.D.L}-cTGA and mitral-aortic discontinuity with subaortic conus in {S.D.L}-ACM.

The fourth subgroup of {S.D.D}-cTGA can be classified into two groups by the location of pulmonary trunk as well. In each subgroup, the directions of conal septum in three variants may be different but the truncal septums have the same direction and the aortic trunk is right-anterior to the pulmonary trunk; the further rotation in level of truncal-AP septum makes the aorta rotate to the opposite side. The direction of the inter-ventricular septum is the same as that of the normal heart, running from right-posterior to left-anterior. Such a segmental arrangement causes the aorta to be located right-anteriorly (D-malposition) to the main pulmonary artery and to originate from the morphological right ventricle. Fibrous continuity exists between the mitral valve and the pulmonary valve, and the subaortic conus arises between the tricuspid and aortic valves.

In summary, besides the understanding of the hemodynamics traced by the models, the surgeons can delineate the course of the epicardial coronary arteries in spite of the possible variants of coronary anomalies and plan the surgery without difficulty, because patients in this group will suffer from cyanosis and the treatment is the arterial switch operation, of which the epicardial coronary arteries re-implantation is the most important and difficult procedure.



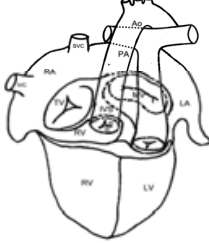
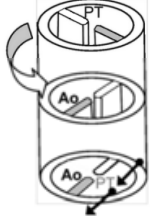
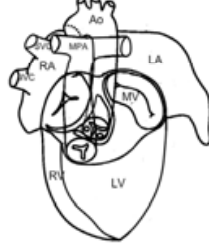
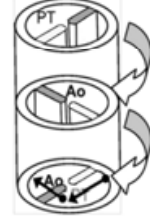
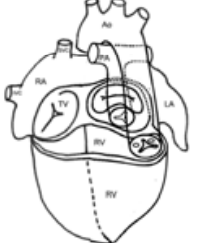
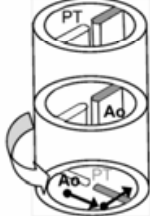
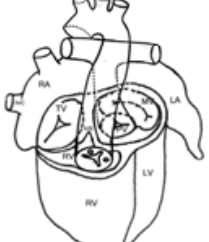
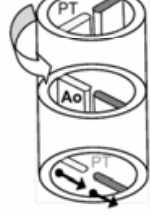
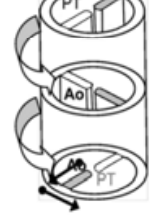
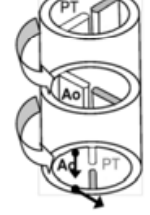
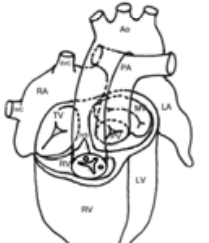
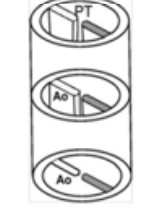
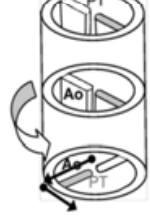
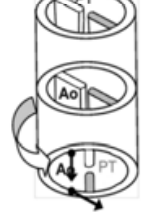
<b>A-V concordance V-A discordance</b>		<b>Rt-posterior to Lt-anterior conus</b>	<b>Lt-posterior to Rt-anterior conus</b>	<b>Vertical conus</b>
<b>{S.D.S}- posterior TGA</b>				
<b>{S.D.I}- posterior TGA</b>				
<b>{S.D.L}-cTGA</b>				
<b>{S.D.D)-cTGA Pulmonary trunk over right-posterior</b>				
<b>Pulmonary trunk over left-posterior</b>				

Fig. 5.3. The perspective cardiac models and corresponding truncus with the hemodynamic of atrio-ventricular concordance and ventricular-arterial discordance. Four subgroups, {S.D.S)-posterior TGA, {S.D.I)- posterior TGA, {S.D.L)-cTGA, and {S.D.D)-cTGA are

included. In the six variants of {S.D.D}-cTGA they can be divided into two groups based on the location of pulmonary trunk at the level of AP septum. Each group consists of three subtypes and they are different in the directions of conal septum. Although the conal septums are different in directions, the perspective cardiac models would be similar. cTGA: complete transposition of great artery.

#### 13.4 A-V discordance and V-A discordance

Three subgroups are included in this category, one is {S.L.D}-ccTGA, another is {S.L.L}-ccTGA, and the other is {S.L.S}-ccTGA (Fig.5.4). In {S.L.D}-ccTGA the way of conal septum is the same as the inter-ventricular septum (L-looping). The truncal rotation is clockwise and makes the left-anterior aortic conus moving rightward and more anteriorly. The mitral valve is connected to the pulmonary valve with fibrous continuity and the aortic valve is disconnected from the tricuspid valve with the subaortic conus. If the spiral rotation extends to the level of AP septum, the type of {S.L.D}-ccTGA may shift to the {S.L.I}-IAI.

In (S.L.L)-ccTGA the inter-ventricular septum is directed from left-posterior to right-anterior as a mirror image of the normal heart. The main pulmonary artery is right-posterior to the aorta without a spiral relationship and it originates from right-sided morphological left ventricle with mitral-pulmonary fibrous continuity. Subaortic conus exists and causes discontinuity of the tricuspid-aortic valves. Some patients may have mal-alignment of the conal septum toward the right-sided left ventricle and this may cause subpulmonary stenosis which causes the effect of physiological pulmonary artery banding, so we can explain why some patients of (S.L.L)-ccTGA can tolerate such a cardiac anomaly over the longer term.

According to the location of pulmonary trunk, two subgroups are divided and three variants are included in each subgroup, and we still use the same perspective cardiac model to present the three variants. The trunk septums in the six variants are the same in the direction of left-posterior to right-anterior. The spiral rotation also proceeds in common with the clockwise direction but the further extension of rotation at the level of truncal-AP septum makes the left-lower aortic conus extending to right-upper aorta and the external relationship of great arteries shifts from the parallel shape to the crossing form. In {S.L.S}-ccTGA the truncal septum extends more left and anteriorly, which causes the left ventricle connects with the pulmonary artery with the conus formation and right ventricle connects with aorta in tricuspid-aortic fibrous continuity. The aorta locates posteriorly to the pulmonary artery, which is the same as posterior TGA but the hemodynamic is as congenitally corrected TGA, so we list the {S.L.S} in this group. The hemodynamic in this group is double discordance, so the picture of cyanosis is not the main symptom unless another cardiac anomaly exists such as pulmonary stenosis or TAPVR, unfortunately, cardiac anomalies usually occur. The patients require receiving operative correction because future miseries of right ventricular failure and pulmonary hypertension will happen. The definitive operation for the type of A-V discordance and V-A discordance is double switch operation (atrial switch and arterial switch), and any single switch procedure will make the patient more worse in cyanosis.

The Congenital Heart Surgery Nomenclature and Database Project published in the *Annals of Thoracic Surgery* in April 2000 classified six main anatomic types of TGA including

{S.D.D/A/L}, {S.L.L/D}, {I.L.L/D}, {I.D.D}, {A.D.D}, and {A.L.L}. Actually the {S.D.D} and {I.L.L}, {S.D.L} and {I.L.D}, {S.L.L},and {I.D.D} could be considered as mirror images of each other.

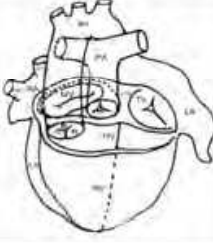
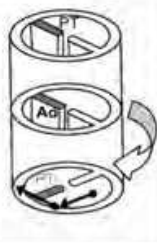
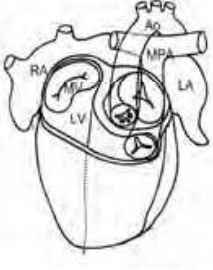
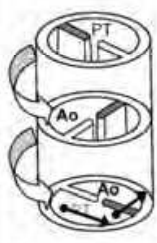
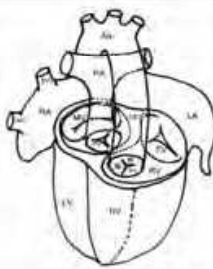
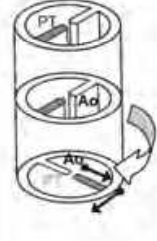
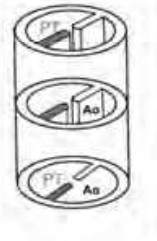
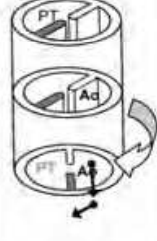
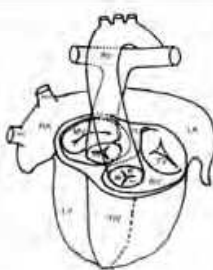
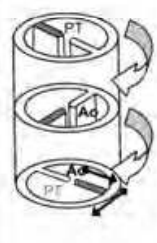
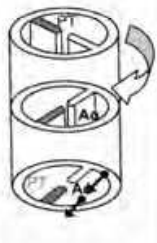
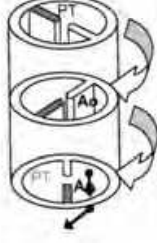
<b>A-V discordance V-A discordance</b>		<b>Rt-posterior to Lt-anterior conus</b>	<b>Lt-posterior to Rt-anterior conus</b>	<b>Vertical conus</b>
<b>{S.L.D}-ccTGA</b>				
<b>{S.L.S}-ccTGA</b>				
<b>{S.L.L}-ccTGA Pulmonary trunk over right-posterior</b>				
<b>Pulmonary trunk over left-posterior</b>				

Fig. 5.4. The perspective cardiac models and corresponding truncus with the hemodynamic of atrio-ventricular discordance and ventricular-arterial discordance. Three subgroups, {S.L.D}-ccTGA, {S.L.S}- ccTGA, and {S.L.L}-ccTGA, are included. In the six variants of {S.L.L}-ccTGA they can be divided into two groups based on the location of pulmonary trunk at the level of AP septum. Each group consists of three subtypes and they are different in the directions of conal septum. Although the conal septums are different in directions, the perspective cardiac models would be similar. ccTGA: congenital corrected TGA.

All the types we discuss above are restricted to the atrial-visceral status in the situs solitus (morphologic right atrium, i.e. systemic venous atrium locates on the right-handed side; morphologic left atrium is on the left-handed side), the situs inversus can be considered as the mirror image of the corresponding type such as the {S.D.D} and {I.L.L} are mirror images, etc. According to the principles of such model, three kinds of situations would have conflicts with existing concepts, so we are not sure the three questionable types exist or not. One is {S.L.I} with right-posterior to left-anterior direction of conal and truncal septums and clockwise rotation of AP septum which is coded as ccTGA (Fig.4.1), another is {S.L.L} with right-posterior to left-anterior direction of conal septum and counter clockwise rotation of truncal septum with the same direction of AP septum which is coded as IAI-M (Fig.4.1), and the other is {S.D.D} with left-posterior to right-anterior conal septum and clockwise rotation of truncal septum with the same direction of AP septum which is coded as {S.D.D}-ACM (Fig.4.2). Further study is necessary to confirm the three models and their hemodynamic status.

#### 14. Double outlet right ventricle

The meaning of DORV is the two great arteries completely or almost completely originating from the right ventricle, actually an infundibular malformation. During the development of embryo in DORV, its infundibular septum (outlet septum) was not going to participate in the formation of outlet portion of IVS, with instead positioning on morphologic RV and forming this anomaly. DORV includes a spectrum of cono-truncal malformation, may present from Tetralogy of Fallot to TGA, but there are still many assumptions that are proposed in the embryo evolution also. The assumptions include these below:

1. Failure of conal insertion.
2. Failure of absorption of bulbo-ventricular flange (BVF) or VIF.
3. Failure of absorption of posterior conus.
4. Mal-alignment between the conal septum and interventricular septum.
5. Failure of incorporation of anterior conus.
6. Anomalous development of conal-truncal and aorta-pulmonary septum.

But still no theory can explain all abnormal possibilities completely. Because of the variety of the complexities and associated anomalies, each case should also focus on the spatial relationship of great artery, inter-infundibular relationship, the location of VSD, and the stenosis of outflow tract; others such as visceral-atrial status, ventricular looping status, the cono-truncal relationship and the septation of aorta-pulmonary septum, etc. should be evaluated carefully. Fortunately, most DORV is situs solitus in visceral-atrial status, and atrial-ventricular concordance with D-looping ventricle ({S.D.X}) or atrial-ventricular discordance with L-looping ventricle ({S.L.X}), so the degrees of difficulties are decreased while we make diagnoses.

the development of IVS is incomplete, which causes the non-differentiation of membranous, inlet and trabecular portions, thus the infundibular septum (outlet septum) will separate the two ventricular outflow tracts. We use the hypothesis of Dr. Lilliam Valdes-Cruz to explain the mechanisms of DORV.

##### 14.1 Classification of DORV

In Fig.6 we demonstrate the normal cardiac development in the level of atrio-ventricular-arterial junction (i.e. endocardial cushion). In Fig.6.A, we can notice the truncus migrates

from right to left, and the DDCC and SVCC present in the conal cavity, which divides the conus into two coni, one antero-lateral and one postero-medial. Eventually the postero-medial conus will incorporate into the left ventricle and become the left ventricular outflow tract (LVOT). Before incorporation, the medial conus communicates with the left ventricle via the primitive interventricular foramen (blank asterisk). The DDCC and SVCC merge gradually with each other to be the conal septum, which moves leftward and downward close to the primitive IVS due to the absorption of the mid-portion of bulboventricular flange (BVF). This draws the aorta over the primitive left ventricle and finally completely locates above the left ventricle and becomes the aorta. In an approximately 32-day-old embryo, the bulboventricular flange (bulboventricular fold synonymous of cono-ventricular flange or bulbo-atrio-ventricular ledge) moves toward the superior endocardial cushion. Near the end of the fifth week, the posterior extremity of the flange terminates almost midway along the base of the superior endocardial cushion and is much less prominent than before (Fig.6.B,C). Finally the flange between the medial conus and the atrioventricular valve will disappear and result in the mitral-aortic fibrous continuity. Some authors consider that the persistence of BVF with the failure incorporation of medial conus into left ventricle are the mechanisms of DORV, and the good development of bulboventricular flange may be due to ineffective conal absorption.

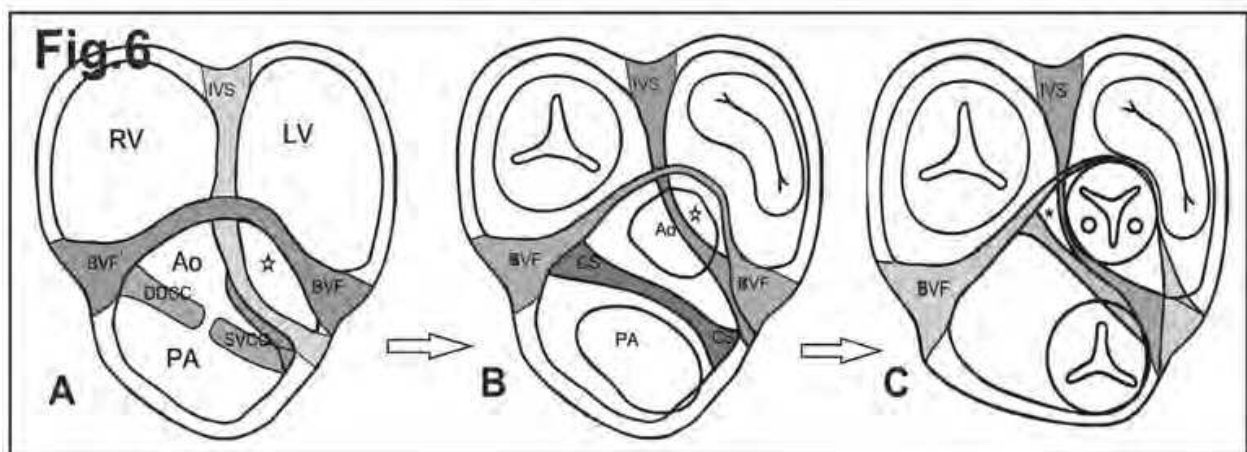


Fig. 6. Processes of Migration, septation, and absorption in atrio-ventricle-arterial junction. The conus cavity is divided into two coni by DDCC and SVCC, and the truncus and ventricles are separated by BVF in the level of endocardial cushion. Conal septum moves leftward and downward to close to the primitive IVS due to absorption of the mid-portion of BVF. This draws the aorta over the primitive left ventricle and finally completely locates above the left ventricle and becomes the aorta. BVF: bulboventricular flange; CS: conal septum; DDCC: dextro-dorsal conal crest; SVCC: sinistra-ventral conal crest. The blank asterisk indicates the primitive interventricular foramen, and the black one indicates the secondary interventricular foramen (VSD).

#### 14.2 Modes of variant DORV

Based on this model, we can determine the spatial relationships of infundibular cavities (the conal cavities) according to the insertion and direction of its outlet septum:



1. Outlet septum insertion to anterior limb of SMT.
2. Insertion to the fusion point of posterior limb of SMT with VIF.
3. Insertion at region between posterior and anterior limbs of SMT.
4. Insertion to VIF itself.

And the relationship of its infundibular cavity, because of the difference of its septal direction, there are the following aspects:

1. Right-posterior to left-anterior outlet septum (antero-lateral with postero-medial infundibulum).
2. Horizontal outlet septum (strict anterior and posterior infundibulum).
3. Left-posterior to right-anterior outlet septum (antero-medial with postero-lateral infundibulum).
4. Vertical outlet septum (side-by-side relationship).

In each relationship of infundibulum, there are several variants could be listed. The two main subgroups are classified by the directions of truncal septum: one is right-posterior to left-anterior truncal septum and the other is left-posterior to right-anterior truncal septum as per the previous classification. There can be two different directions (clockwise and counterclockwise) of spiral rotation in the truncal septum and in the AP septum, so many variants can be found, and we list all in Fig. 7. In accordance with the insertion of outlet septum, we classify the anomalies of DORV into four groups as in the previous description.

	Right-postero to left-antero truncal septum	Left-postero to right-antero truncal septum
<b>Left-posterior to right-anterior Conal septum (DORV-1)</b>		
<b>Vertical conal septum (DORV-2)</b>		
<b>Right-posterior to left-anterior Conal septum (DORV-3)</b>		
<b>Horizontal conal septum (DORV-4)</b>		

Fig. 7. All possibilities of arrangements of conal-truncal-AP septums in double outlet right ventricle. Four groups are categorized by different directions of conal septums. DORV-1: left-posterior to right-anterior conal septum; DORV-2: vertical conal septum; DORV-3: right-posterior to left-anterior conal septum; DORV-4: horizontal conal septum. Two subgroups are divided by the direction of truncal septum which are right-posterior to left-anterior truncal septum and left-posterior to right-anterior truncal septum.

### 14.2.1 Outlet septum insertion to anterior limb of SMT

The first one is outlet septum insertion to anterior limb of SMT (Fig.8.1). The direction of conal septum will greatly determine the degrees of outflow tract stenosis such as the conal septum extending from left-posterior to right-anterior would cause the compromise of lateral conal cavity and a larger connection between VSD and the medial conal cavity; but if the conal septum is in the direction of right-posterior to left-anterior, the compromised one would be the posteromedial conus. Although the direction of conal septum is important, the key points of hemodynamic decision are the size and the location of VSD (primitive interventricular foramen) and the VSD-related conal cavity. If the VSD is larger enough or is closer to the orifice of outflow tract, the corresponding great artery would develop more normally; if the VSD related artery is pulmonary artery rather than the aorta, the degrees of cyanosis and the operative procedures would be more complicated. In this group the VSD-related great artery is the one which locates on the posteromedial conal cavity. Three subgroups are divided by the conal direction, and several variants are included in each group which are DORV-3, DORV-4, and DORV-1 individually. The subgroups of DORV-1, 2, 3, and 4 are listed in Fig. 7.

Generally speaking, if the VSD appears as a muscular defect, we can think this is a DORV with noncommitted VSD; if the infundibular septum is hypoplastic or absent, we can think it is like a DORV with doubly committed VSD. Besides, the other associated anomalies, the size of VSD, and the degrees of ventricular hypoplasia are all required to be known before surgical intervention, not only because the decision of the two ventricular or single ventricular repairs is very important for the surgical outcomes, but because accurate decisions are dependent on detailed structural evaluation. Indeed, most of the DORV are repaired as single ventricle because of valvular dysfunction, ventricular hypoplasia, and great artery anomalies. Furthermore, the type of horizontal conal septum is included in DORV compares with the CHD of non-DORV with lack of the horizontal one.

### 14.2.2 Insertion to the fusion point of posterior limb of SMT

The second group (Fig. 8.2) is the type of conal septal insertion to the posterior limb of SMT. Three subgroups, the left-posterior to right-anterior direction of conal septum, the vertical conal septum, and the right-posterior to left-anterior conal septum, are included. The corresponding subgroups with variants of different truncal and AP septum are DORV-1, DORV-2, and DORV-3 respectively. In this group, the VSD-related great artery is the medial conal cavity, and the direction of conal septum can influence the stenotic degree of outflow tract. In the left-posterior to right-anterior direction and the vertical direction of conal septum, the lateral conal cavity will be compromised by the conal septum; on the contrary, the right-posterior to left-anterior conal direction will compromise the medial conal cavity. Actually the development and hypoplasia of great arteries are not entirely decided by the conal septum, the size and location of VSD, the degrees of valvular dysfunction, and the balance between two ventricles, etc. - all are decisive factors.

### 14.2.3 Insertion at region between posterior and anterior limbs of SMT

The third group (Fig. 8.3) has the type of conal septum insertion in the SMT (between SMT). Three subgroups can be noticed based on the direction of conal septum, too. One is right-

posterior to left-anterior conal direction and its possible Truncal-AP septum variants are listed in DORV-3; another one is horizontal conal septum with the possible variants listed in DORV-4; and the other is left-posterior to right-anterior conal septum with the possible variants in DORV-1. The VSD may be more remote in this type because of the space occupied by the conal septum resulting in the non-committed type VSD, but if there is absence or hypoplasia of the conal septum, the VSD may present as the doubly committed type. In the first one, the postero-medial conus may be more restricted, but in the third one, the antero-lateral conus is more restricted.

#### 14.2.4 Insertion to VIF itself

The fourth group (Fig. 8.4) is the type of conal septum insertion to VIF itself; there are three subgroups based on the direction of conal septum, too. First one is left-posterior to right-anterior conal direction and its possible Truncal-AP septum variants are listed in DORV-1; the second one is vertical conal septum with the possible variants listed in DORV-2; and the third one is right-posterior to left-anterior conal septum with the possible variants in DORV-3. The VSD related great artery is the one which locates on the medial conal cavity, and the restricted one is the lateral conal cavity.

No matter what the type is, the clinical importance of DORV is determined on the size and location of VSD, the position of VSD-related great artery, the balance between ventricles, the competence of valves, and other associated anomalies, etc..

In the clinical aspects, the most possibly confused cardiac anomalies with DORV are the Fallot type DORV, TOF, and TGA ({S.D.D}). They may look alike in external appearance but the internal structures possess some differences. Before talking about the Fallot type DORV, we need to know the basic concept of TOF:

### 15. Tetralogy of Fallot and related topics

According to Dr. Van Praagh's theory, the Tetralogy of Fallot results from a maldevelopment of the subpulmonary conus whereby the aortic valve comes to lie more anteriorly, superiorly and leftwards relative to the pulmonary valve than is normal. That is to say, the conal septum is shifted more anteriorly, superiorly and leftwards, causing right ventricular outflow tract (RVOT) obstruction, hypoplasia of the pulmonary artery and right ventricular hypertrophy. It is difficult to depict the anterior, superior, and leftward deviation of the conus without a three-dimensional representation. Using this figure, drawn in perspective, we can understand the impact of conus deviation on the development of the pulmonary artery and right ventricle, and see why an anterior malalignment of the VSD will cause RVOT obstruction, pulmonary hypoplasia and how the posterior malalignment of VSD will cause left ventricular outflow tract obstruction and hypoplasia of the left cardiac structures. With this depiction, the condition of TOF and the surgical methods can also be clearly represented to patients' families. In TOF, the aorta is located more anteriorly in position because of hypoplasia of pulmonary artery and anterior overriding of aorta (Fig.9.A). Such an appearance also can be seen in the type of {S.D.D}-TGA with pulmonary stenosis (Fig.9.B) or in the type of {S.D.D}-DORV with subpulmonary VSD (Fig.9.C).

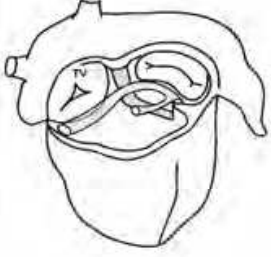
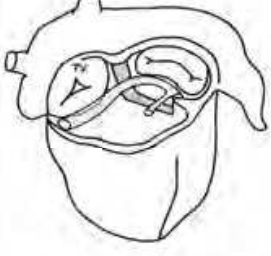
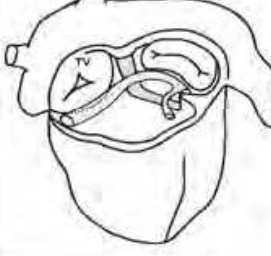
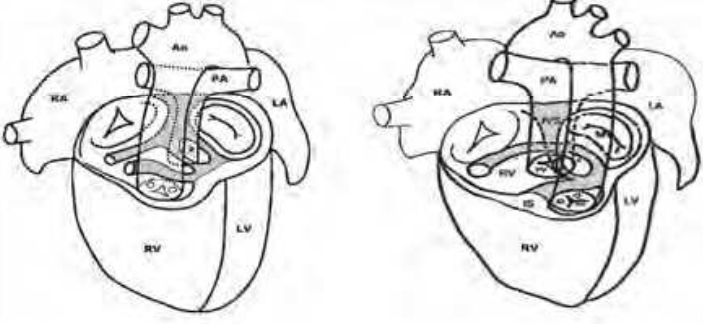
<b>Conal septum insertion to anterior limb</b>		
<b>Right-posterior to Left-anterior Conal septum</b>		Variant types of Right-posterior to Left-anterior oblique direction of conal septum (Fig.7-DORV-3)
<b>Horizontal conal septum</b>		Variant types of horizontal conal septum (Fig.7-DORV-4)
<b>Left-posterior to Right-anterior Conal septum</b>		Variant types of Left-posterior to Right-anterior oblique direction of conal septum (Fig.7-DORV-1)
<b>Model: VSD is related with posteromedian conal cavity</b>		

Fig. 8.1. The group of DORV with conal septum inserts to anterior limb of SMT. Three subgroups are listed including the right-posterior to left-anterior conal septum, horizontal conal septum, and left-posterior to right-anterior conal septum. The corresponding variants of arrangements of conal-truncal-AP septum are Fig.7-DORV-3, Fig.7-DORV-4, and Fig.7-DORV-1 respectively. In the group the VSD is related with posteromedian conal cavity, such as {S.D.D}-DORV is a type of subpulmonary VSD.



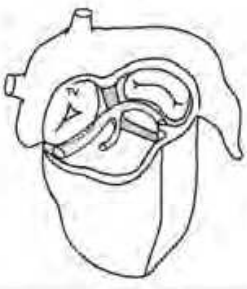
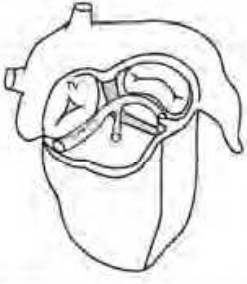
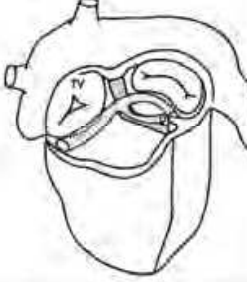
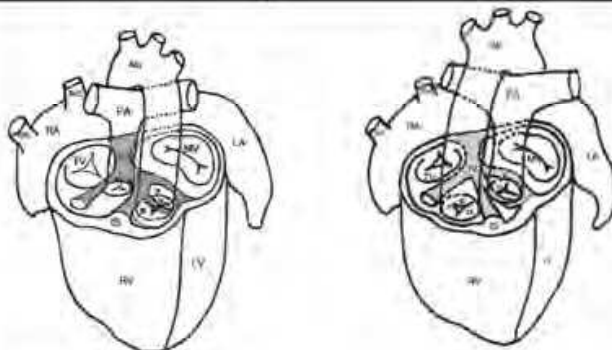
<b>Conal septum insertion to posterior limb</b>		
<b>Left-posterior to Right-anterior Conal septum</b>		Variant types of Left-posterior to Right-anterior oblique direction of conal septum (Fig.7-DORV-1)
<b>Vertical direction Conal septum</b>		Variant types of vertical direction of conal septum (Fig.7-DORV-2)
<b>Right-posterior to Left-anterior Conal septum</b>		Variant types of Right-posterior to Left-anterior oblique direction of conal septum (Fig.7-DORV-3)
<b>Models: VSD is related with median conal cavity</b>		

Fig. 8.2. The group of DORV with conal septum inserts to posterior limb of SMT. Three subgroups are listed including the left-posterior to right-anterior conal septum, vertical conal septum, and right-posterior to left-anterior conal septum. The corresponding variants of arrangements of conal-truncal-AP septum are Fig.7-DORV-1, Fig.7-DORV-2, and Fig.7-DORV-3 respectively. In the group the VSD is related with median conal cavity, such as {S.D.D}-DORV is a type of subpulmonary VSD.



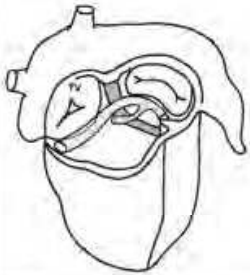
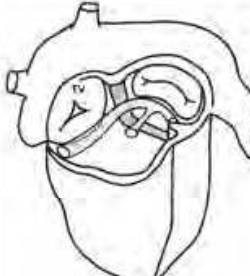
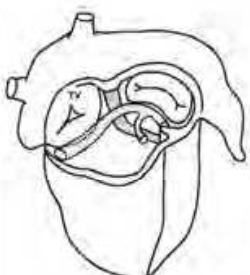
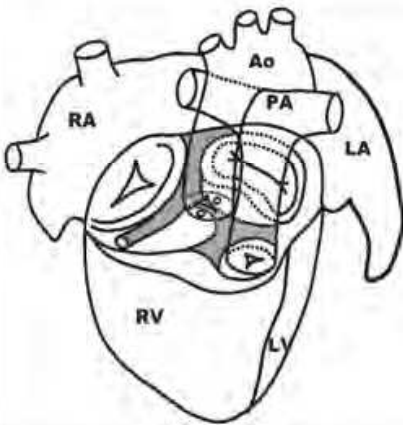
<b>Conal septum insertion between SMT</b>		
<b>Right-posterior to Left-anterior Conal septum</b>		Variant types of Right-posterior to Left-anterior oblique direction of conal septum (Fig.7-DORV-3)
<b>Horizontal conal septum</b>		Variant types of horizontal conal septum (Fig.7-DORV-4)
<b>Left-posterior to Right-anterior Conal septum</b>		Variant types of Left-posterior to Right-anterior oblique direction of conal septum (Fig.7-DORV-1)
<b>Model: Non-committed or Doubly committed VSD</b>		

Fig. 8.3. The group of DORV with conal septum inserts between SMT. Three subgroups are listed including the right-posterior to left-anterior conal septum, horizontal conal septum, and left-posterior to right-anterior conal septum. The corresponding variants of arrangements of conal-truncal-AP septum are Fig.7-DORV-3, Fig.7-DORV-4, and Fig.7-DORV-1 respectively. The VSD may be more remote in this type because of the space occupied by the conal septum and results in the non-committed type VSD, but if absence or hypoplasia of the conal septum, the VSD may present as the doubly committed type.

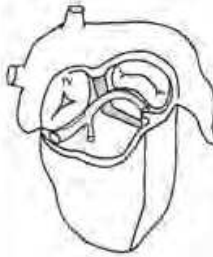
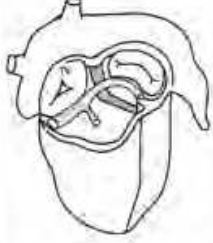

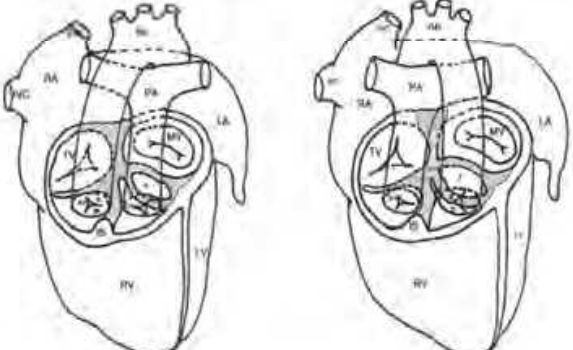
<b>Conal septum insertion to VIF itself</b>		
<b>Left-posterior to Right-anterior Conal septum</b>		Variant types of Left-posterior To Right-anterior oblique direction of conal septum (Fig.7-DORV-1)
<b>Vertical direction Conal septum</b>		Variant types of vertical direction of conal septum (Fig.7-DORV-2)
<b>Right-posterior to Left-anterior Conal septum</b>		Variant types of Right-posterior To Left-anterior oblique direction of conal septum (Fig.7-DORV-3)
<b>Models: VSD is related with median conal cavity</b>		

Fig. 8.4. The group of DORV with conal septum inserts to VIF itself. Three subgroups are listed including the leftt-posterior to right-anterior conal septum, vertical conal septum, and right-posterior to left-anterior conal septum. The corresponding variants of arrangements of conal-truncal-AP septum are Fig.7-DORV-1, Fig.7-DORV-2, and Fig.7-DORV-3, respectively. The VSD is related with median conal cavity,too.

### 15.1 Fallot type v.s. TGA type DORV

Because external appearances cannot offer us a definitive diagnosis, echocardiographic evaluations become the gold standard of diagnosis. Establishing difference between the TOF and DORV has been disputed for a long time. The general concept is the 50 % rule of the aortic overriding over right ventricle in spite of the mitral-aortic continuity or discontinuity, that is to say the subaortic conus is not essential for the diagnosis of DORV. It means in TOF that the aorta overrides less than 50% above right ventricle, and in DORV the aorta overrides more than 50% above right ventricle. The Fallot type DORV (Fig. 9.D) means the two great arteries both originate from right ventricle with an anterior-positioned and hypoplastic pulmonary artery, and the TGA type DORV means the two great arteries both originate from right ventricle, too, but with a posterior-positioned pulmonary artery with a subpulmonary VSD ({S.D.D})-DORV).

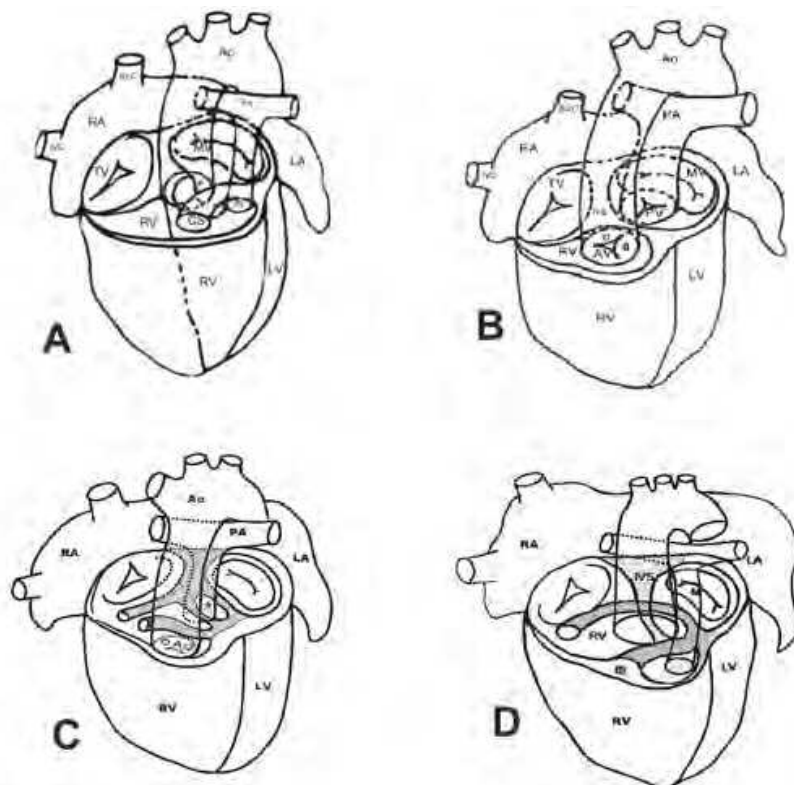


Fig. 9. Collections of DORV variants including the Fallot type DORV (Fig.9.D), the TGA type DORV (Fig.9.C) and the distinct similar models, TOF (Fig.9.A) and {S.D.D}-TGA (Fig.9.B).

### 15.2 TOF with AVSD

In the Finally, we wish to discuss the issue of TOF with AVSD because this type of CHD is more complicated and is poorly understood in morphology and surgical anatomy. In Fig. 10, we draw the pictures of preoperative (Fig. 10-A), postoperative (Fig. 10-B) models, and the bizarre patch we surgeons use to repair the VSD and to reroute the overriding aorta into left ventricle. The patch looks like a teardrop with a semicircle in one part and a tapering oval in another part. In the past, we didn't have the perspective model of AVSD with TOF, and this really was a concern for a long time as to understand why the patch would be such a shape.

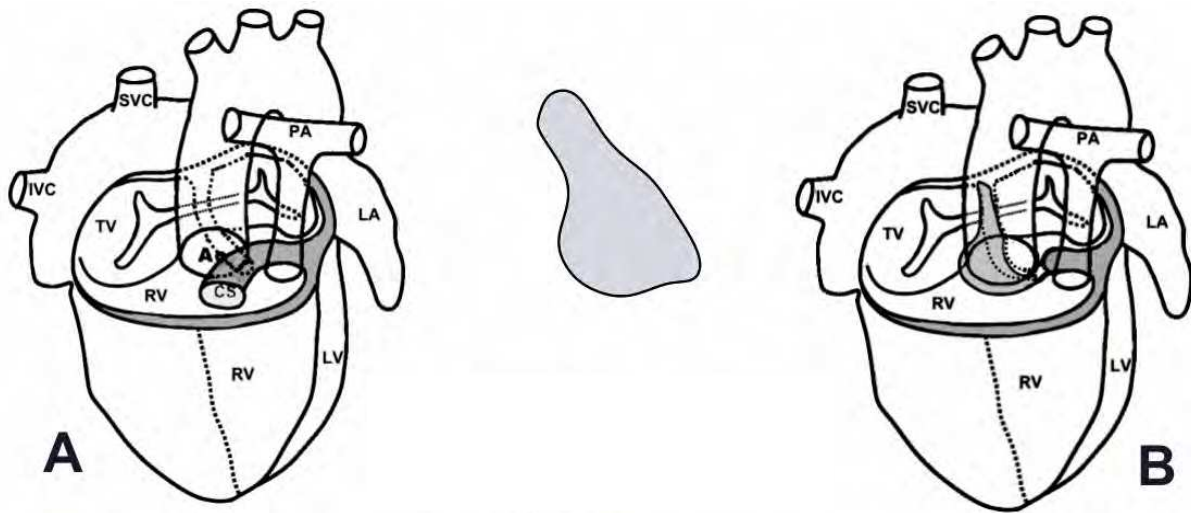


Fig. 10. Fallot type AVSD is delineated by the cardiac model to demonstrate how to repair the VSD and reroute the overriding aorta into left ventricle with the bizarre patch. The narrow part of patch is to repair the VSD and the wider part is for the subaortic rerouting. The patch repair follows conal septal resection. CS: conal septum.

**16. Revised and summary of A-V & V-A segmental connections**

The table has been modified in comparing with the one on earlier paper. We recode the type of {S.L.D}-ACM as {S.L.D}-IAI-M, we also add extra two types of {S.D.S}-posterior TGA and {S.D.I}-posterior TGA in the group of Atrio-Ventricular concordance with Ventricular-Arterial discordance, and {S.L.S}-ccTGA in the group of Atrio-Ventricular discordance with Ventricular-Arterial discordance.

	Ventricular-Arterial Concordance	Ventricular-Arterial Discordance
Atrio-Ventricular Concordance	{S.D.S} / {I.L.I} {S.D.L}-ACM / {I.L.D} {S.D.I}-IIAI / {I.L.S}	{S.D.D}-cTGA / {I.L.L} {S.D.L}-cTGA / {I.L.D} {S.D.S}-posterior TGA {S.D.I}-posterior TGA
Atrio-Ventricular Discordance	{S.L.S}-IVI / {I.D.I} {S.L.I}-IAI / {I.D.S} {S.L.D}-IAI-M / {I.D.L}	{S.L.L}-ccTGA / {I.D.D} {S.L.D}-ccTGA / {I.D.L} {S.L.S}-ccTGA

Table 1. The summary of atrio-ventricular concordance/discordance and ventricular-arterial concordance/discordance. The table has been modified in comparing with the one published on earlier paper. ACM: anatomically corrected malposition; cTGA: complete transposition of great artery; ccTGA: congenital corrected TGA; IAI: isolated atrial inversion; IAI-M: isolated atrial inversion with arterial malposition; IVI: isolated ventricular inversion.



## 17. References

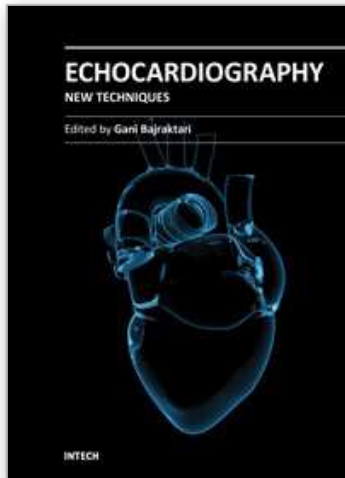
- Anderson RH, Wilkinson JL, Arnold R, Becker AE. Morphogenesis of bulboventricular malformations II. Observations on malformed hearts. *Brit Heart J* 1974; 36: 948-970.
- Anderson RH, Becker AE, Van Mierop LHS. What should we call the Crista? *Br Heart J* 1977; 39:856-859.
- Anderson RH, Becker AE, Wilcox BR, Macartney FJ, Wilkinson JL. Surgical anatomy of double-outlet right ventricle- a reappraisal. *Am J Cardiol* 1983; 52:555-559.
- Angelini P, Leachman RD. The spectrum of double-outlet right ventricle: an embryologic interpretation. *Cardiovasc Dis* 1976; 3:127-149.
- Arista-Salado Martinez O, Arango Casado J, De la Cruz MV, Diaz F, Cubero O. Double outlet right ventricle-an echocardiographic study. *Cardiol Young* 1993; 3: 124-131.
- Arteaga M, De la Cruz MV, Sanchez C, Diaz GF. Double outlet right ventricle: experimental morphogenesis in the chick embryo heart. *Pediatr Cardiol* 1982; 3:219-227.
- Clarkson PM, Brandt PWT, Barratt-Boyes BG, et al. Isolated atrial inversion. *Am J Cardiol* 1972;29:877-81.
- De la Cruz MV, Arteaga M, Espino-Vela J, Quen-Jiménez M. Complete transposition of the great arteries: types and morphogenesis of ventriculo-arterial discordance. *Am Heart J* 1981; 271-281.
- De la Cruz MV, Cayre R, Arista-Salado Martinez O, Sadowinski S. The infundibular interrelationships and the ventriculoarterial connection in double outlet right ventricle, Clinical and surgical implications. *Int J Cardiol* 1992; 35: 153-164.
- Foran RB, Becourt C, Nanton MA, et al. Isolated infundibulo-arterial inversion {S,D,I}: a newly recognized form of congenital heart disease. *Am Heart J* 1988;116:1337-50.
- Goor DA, Dische R, Lillehei CW. The conotruncus. Its normal inversion and conus absorption. *Circulation* 1972; 46: 375-385.
- Goor DA, Edward JE. The spectrum of transposition of the great arteries with specific reference to developmental anatomy of the conus. *Circulation* 1973; 48:406-415.
- Howell CE, Ho SY, Anderson RH, Elliott MJ. Fibrous skeleton and ventricular outflow tracts in double-outlet right ventricle. *Ann Thorac Surg* 1991; 51:394-400.
- Huai-Min Chen , Chau-Chi Chiu , Jin-Ren Wu, Ying-Fu Chen\*. A Simple Model for Variant Congenital Cardiac Anomalies. *Thoracic CardioVasc Surgeon* 2007, 55:433-7.
- Huai-Min Chen, Po-Chih Chang, Meng-Shin Lee, Jin-Ren Wu, Chaw-Chi Chiu\*. Easy Category for Complex Congenital Cardiac Segmental Connections. *Kaohsiung J Med Sci*, 2007,23(1):30-3.
- Lev M, Bharati S, Meng CCL, Libberthson RR, Paul MH, Idriss F. A concept of double-outlet right ventricle. *J Thorac Cardiovasc Surg* 1972; 64:271-281.
- Lincoln C, Anderson RH, Shinebourne EA, English TAH, Wilkinson JL. Double outlet right ventricle with l-malposition of the aorta. *Br Heart J* 1975; 37:453-463.
- Pasquini L, Sander SP, Parness I, et al. Echocardiographic and anatomic findings in atrio-ventricular discordance with ventricular-arterial concordance. *Am J Cardiol* 1988;62:1256-61.
- Piccoli G, Pacifico AD, Kirklin JW, Blackstone EH, Kirklin JK. Changing results and concepts in the surgical treatment of double-outlet right ventricle: analysis of 137 operations in 126 patients. *Am J Cardiol* 1983; 52:549-554.
- Quero-Jiménez M, Raposo-Sonnenfeld I. Isolated ventricular inversion with situs solitus. *Br Heart J* 1975; 37: 293-304.



- Rosenquist GC, Sweeney LJ. Anomalous semilunar valve relationships in transposition of the great arteries. *Ped Cardiol* 1982; 2:195-202.
- Snider AR, Enderlein MA, Feitel DF, et al. Isolated ventricular inversion: two-dimensional echocardiographic findings and a review of the literature. *Pediatr Cardiol* 1984;5:27-33.
- Sridaromont S, Feldt RH, Ritter DG, Davis GD, Edwards JE. Double outlet right ventricle: hemodynamic and anatomic correlations. *Am J Cardiol* 1976; 38:85-94.
- Stellin G, Zuberbuhler JR, Anderson RH, Siewers RD. The surgical anatomy of the Taussig-Bing malformation. *J Thorac Cardiovasc Surg* 1987; 93:560-569.
- Tynan MJ, Becker AE, Macartney FJ, Anderson RH. Nomenclature and classification of congenital heart disease. *Br Heart J* 1979; 41:544-553.
- Van Praagh R, Van Praagh S. Isolated ventricular inversion. A consideration of the morphogenesis, definition and diagnosis of nontransposed and transposed great arteries. *Am J Cardiology* 1966; 17: 395-406.
- Van Praagh R, Perez-Trevino C, Lopez-Cuellar M, Baker FW. Transposition of the great arteries with posterior aorta, anterior pulmonary artery, subpulmonary conus and fibrous continuity between aortic and atrioventricular valves. *Am J of Cardiology* 1971; 28: 621-631.
- Van Praagh R. The segmental approach to diagnosis in congenital heart disease. *Birth Defects (Original Article Series)* 1972; 4-22.
- Van Praagh R. The segmental approach to diagnosis in congenital heart disease. *Birth Defects: Original Article Series* 1972; Vol III, 5:4-22.
- Van Praagh R, Durnin RE, Jockin H, et al. Anatomically corrected malposition of great arteries {S,D,L}. *Circulation* 1975;51:20-31.
- Van Praagh R, Durnin RE, Jockin H, Wagner HR. Anatomically corrected malposition of the great arteries (S,D,L). *Circulation* 1975; 51: 20-31.
- Van Praagh R. Transposition of the great arteries: history, pathologic anatomy, embryology, etiology, and surgical consideration. *Cardiac Surgery: State of the Art Reviews*. 1991; 5: 7-83.
- Wilcox BR, Ho SY, Macartney FJ, Becker AE, Gerlis LM, Anderson RH. Surgical anatomy of double-outlet right ventricle with situs solitus and atrioventricular concordance. *J Thorac Cardiovasc Surg* 1981; 82: 405-417.
- Witham AC. Double outlet right ventricle: a partial transposition complex. *Am Heart J* 1957; 53: 929-939.
- Print Books
- Antoon F.M. Moorman. (2010). Embryology of the Heart, In: *Pediatric Cardiology*, Robert H. Anderson, Edward J. Baker, Daniel J. Penny, et al. pp. 37-56, Churchill Livingstone, 978-0-7020-3064-2, Philadelphia, New York.
- Deepak Srivastava, Scott Baldwin. (2001). Molecular Determinants of Cardiac Development, In: *Moss and Adams' Heart Disease in Infants, Children, and Adolescents*, Hugh D. Allen, Howard P. Gutgesell, et al, pp. 3-23, Lippincott Williams & Wilkins, 0-683-30742-8, Philadelphia, PA.
- Jonas RA. (2004). Tetralogy of Fallot with Pulmonary Stenosis, In: *Comprehensive Surgical Management of Congenital Heart Disease*, Richard A Jonas, James DiNardo, pp. 279-293, Arnold, 0-340-80807-1, London.

- Jonas RA. (2004). Double outlet right ventricle, In: *Comprehensive Surgical Management of Congenital Heart Disease*, Richard A Jonas, James DiNardo, pp. 413-428, Arnold, 0-340-80807-1, London.
- Lee N. Benson. (2010). The Arterial Duct: Its Persistence and its Patency, In: *Pediatric Cardiology*, Robert H. Anderson, Edward J. Baker, Daniel J. Penny, et al. pp. 875-893, Churchill Livingstone, 978-0-7020-3064-2, Philadelphia, PA.
- Lilliam M. Valdes-Cruz. (1999). Double-outlet ventricle, In: *Echocardiographic Diagnosis of Congenital Heart Disease*, Lilliam M. Valdes-Cruz, Paul O. Cayre, pp. 409-422, Lippincott-Raven, 0-7817-1433-8, Philadelphia, New York.
- Lilliam M. Valdes-Cruz. (1999). Embryological Development of the Heart and Great Vessels, In: *Echocardiographic Diagnosis of Congenital Heart Disease*, Lilliam M. Valdes-Cruz, Paul O. Cayre, pp. 3-18, Lippincott-Raven, 0-7817-1433-8, Philadelphia, New York.
- Van Praagh R, Geva T, Van Praagh S. (1990). Segmental situs in congenital heart disease: recent rare findings. In: *Development Cardiology: Morphogenesis and Function*. Clark EB, Takao A, Future Publishing Co, NY.
- Van Praagh R. (1991). Transposition of the great arteries: history, pathologic anatomy, embryology, and surgical considerations, In: *Cardiac Surgery: State of the Art Reviews*. Pp. 7-82, Hanley & Belfus, Philadelphia.
- Van Praagh R. (1998). Cardiac anatomy, In: *Pediatric Cardiac Intensive Care*, Anthony C. Chang, Frank L. Hanley, Gil Wernovsky, David L. Wessel, pp. 1-15, Williams & Wilkins, 0-683-01508-7, Baltimore, Maryland.

IntechOpen



## **Echocardiography - New Techniques**

Edited by Prof. Gani Bajraktari

ISBN 978-953-307-762-8

Hard cover, 218 pages

**Publisher** InTech

**Published online** 18, January, 2012

**Published in print edition** January, 2012

The book "Echocardiography - New Techniques" brings worldwide contributions from highly acclaimed clinical and imaging science investigators, and representatives from academic medical centers. Each chapter is designed and written to be accessible to those with a basic knowledge of echocardiography. Additionally, the chapters are meant to be stimulating and educational to the experts and investigators in the field of echocardiography. This book is aimed primarily at cardiology fellows on their basic echocardiography rotation, fellows in general internal medicine, radiology and emergency medicine, and experts in the arena of echocardiography. Over the last few decades, the rate of technological advancements has developed dramatically, resulting in new techniques and improved echocardiographic imaging. The authors of this book focused on presenting the most advanced techniques useful in today's research and in daily clinical practice. These advanced techniques are utilized in the detection of different cardiac pathologies in patients, in contributing to their clinical decision, as well as follow-up and outcome predictions. In addition to the advanced techniques covered, this book expounds upon several special pathologies with respect to the functions of echocardiography.

### **How to reference**

In order to correctly reference this scholarly work, feel free to copy and paste the following:

Huai-Min Chen (2012). Models of Perspective on Various Kinds of Complex Congenital Heart Defects, Echocardiography - New Techniques, Prof. Gani Bajraktari (Ed.), ISBN: 978-953-307-762-8, InTech, Available from: <http://www.intechopen.com/books/echocardiography-new-techniques/models-of-perspective-on-various-kinds-of-complex-congenital-heart-defects>

**INTECH**  
open science | open minds

### **InTech Europe**

University Campus STeP Ri  
Slavka Krautzeka 83/A  
51000 Rijeka, Croatia  
Phone: +385 (51) 770 447  
Fax: +385 (51) 686 166  
[www.intechopen.com](http://www.intechopen.com)

### **InTech China**

Unit 405, Office Block, Hotel Equatorial Shanghai  
No.65, Yan An Road (West), Shanghai, 200040, China  
中国上海市延安西路65号上海国际贵都大饭店办公楼405单元  
Phone: +86-21-62489820  
Fax: +86-21-62489821

© 2012 The Author(s). Licensee IntechOpen. This is an open access article distributed under the terms of the [Creative Commons Attribution 3.0 License](#), which permits unrestricted use, distribution, and reproduction in any medium, provided the original work is properly cited.

IntechOpen

IntechOpen