

We are IntechOpen, the world's leading publisher of Open Access books Built by scientists, for scientists

4,800

Open access books available

122,000

International authors and editors

135M

Downloads

Our authors are among the

154

Countries delivered to

TOP 1%

most cited scientists

12.2%

Contributors from top 500 universities



WEB OF SCIENCE™

Selection of our books indexed in the Book Citation Index
in Web of Science™ Core Collection (BKCI)

Interested in publishing with us?
Contact book.department@intechopen.com

Numbers displayed above are based on latest data collected.
For more information visit www.intechopen.com



Radiation Mucositis

P. S. Satheesh Kumar

*Department of Oral Medicine and Radiology,
Government Dental College, Trivandrum, Kerala
India*

1. Introduction

Mucosal injury remains an undesirable, painful, and expensive side effect of cytotoxic cancer therapy and is disheartening for patients and frustrating for caregivers.^[1,2] Mucositis and associated outcomes in patients receiving radiotherapy (RT) for head and neck cancer shows that the mean incidence was 80%.^[3] Rates of hospitalization due to mucositis are reported to be 16% overall and 32% for RT-AF (altered fraction radio therapy) patients.^[3] Patients in the high risk of developing oral mucositis group fall into the head and neck cancer population where the incidence of mucositis is high in this group.^[3]

Oral mucositis is a distressing toxic effect of chemotherapy and radiotherapy. It can increase the need for total parenteral nutrition and opioids analgesics, prolong hospital stays, increase the risk of infection, and greatly affect the patient's quality of life ^[4]. All patients treated with high-dose chemotherapy requiring hematopoietic stem cell or bone marrow transplantation develop oral mucositis of varying severity. In addition, up to 80% of patients receiving radiotherapy for head or neck tumours and almost 90% of pediatric patients treated for cancer also develop oral mucositis^[5,6]

2. Mechanism of development

Radiation induced mucositis is initiated by direct injury to basal epithelial cells and cells in the underlying tissue. DNA-strand breaks can result in cell death or injury. Non-DNA injury is initiated through a variety of mechanisms, some of which are mediated by the generation of reactive oxygen species. Radiation and chemotherapy are effective activators of several injury-producing pathways in endothelia, fibroblasts, and epithelia. In these cells, the activation of transcription factors such as nuclear factor- κ B (NF- κ B) and NRF-2 leads to the upregulation of genes that modulate the damage response. Immune cells (macrophages) produce pro-inflammatory cytokines, such as tumor-necrosis factor- α (TNF- α) and interleukin-6, which causes further tissue injury.^[7] These signaling molecules also participate in a positive-feedback loop that amplifies the original effects of radiation and chemotherapy. For example, TNF- α activates NF- κ B and sphingomyelinase activity in the mucosa, leading to more cell death. In addition, direct and indirect damages to epithelial stem cells result in a loss of renewal capacity. As a result, the epithelium begins to thin and patients start to experience the early symptoms of mucositis.^[8]

An oropharyngeal epithelial surface has a rapid rate of cell turnover and appears to be at high risk of injury from ionizing radiation. A healthy oral mucosa serves to clear microorganism and provides a chemical barrier that limits penetration of many compounds into the epithelium. A damaged mucosal surface increases the risk of a secondary infection. Acute mucositis results from the loss of squamous epithelial cells owing to the sterilization of mucosal stem cells and the inhibition of transit cell proliferation. This leads to a gradual linear decrease in epithelial cell numbers. Normally, cells of the mouth undergo rapid renewal over a 7-14 day cycle. Radiation therapy interferes with cellular mitosis and reduces the ability of the oral mucosa to regenerate.^[9]

As radiation therapy continues, a steady state between mucosal cell death and regeneration may occur because of an increased cell production rate from the surviving cells. Usually, however, cell regeneration cannot keep up with cell death, and therefore, partial or complete denudation develops. This presents as patchy or confluent mucositis. As the mucositis becomes more severe, pseudomembranes and ulceration develops. Poor nutritional status further interferes with mucosal regeneration by decreasing cellular migration and renewal. The loss of the epithelial barrier enhances insults from physical, chemical, and microbial agents.

Stages of mode I^[10] for the pathogenesis of mucositis are based on the evidence available to date:

1. **Initiation of tissue injury:** Radiation and/or chemotherapy induce cellular damage resulting in death of the basal epithelial cells. The generation of reactive oxygen species (free radicals) by radiation or chemotherapy is also believed to exert a role in the initiation of mucosal injury. These small highly reactive molecules are by-products of oxygen metabolism and can cause significant cellular damage.
2. **Up-regulation of inflammation via generation of messenger signals:** In addition to causing direct cell death, free radicals activate second messengers that transmit signals from receptors on the cellular surface to the inside of cell. This leads to up-regulation of pro-inflammatory cytokines, tissue injury, and cell death.
3. **Signaling and amplification:** Up-regulation of pro-inflammatory cytokines, such as TNF- α , produced mainly by macrophages, causes injury to mucosal cells, and also activates molecular pathways that amplify mucosal injury.
4. **Ulceration and inflammation:** There is a significant inflammatory cell infiltrate associated with the mucosal ulcerations, based in part on metabolic by-products of the colonizing oral microflora. Production of pro-inflammatory cytokines is also further up-regulated as a result of this secondary infection.^[10]
5. **Healing:** This phase is characterized by epithelial proliferation, as well as, cellular and tissue differentiation,^[11] restoring the integrity of the epithelium.

A number of authors have reported that the oropharyngeal flora may contribute to radiation-induced mucositis. In health, the oral mucosa has a number of distinct habitats which are colonized by micro-organism that are able to establish a homeostatic community.^[12] These homeostatic microbial communities are protective for the host by preventing or interfering with the colonization of exogenous pathogens; this potent defense mechanism is called "colonization resistance". When the oral tissues are irradiated, the colonization resistance is practically abolished. Irradiation mucositis is caused by a combination of alteration of the normal oral microflora with concomitant changes in the tissues. However, healing eventually occurs when cells regenerate from the surviving mucosal stem cells.

3. Clinical presentation

Clinically, mucositis presents with multiple complex symptoms. It begins with a symptomatic redness and erythema and progresses through solitary white elevated desquamative patches that are slightly painful to contact pressure. Following this, large, painful contiguous pseudo membranous lesions develop with associated dysphagia and decreased oral intake. The nonkeratinized mucosa is the most affected one. The most common sites include the labial, buccal, and soft palate mucosa, as well as, the floor of the mouth and the ventral surface of the tongue. Oral lesions usually heal within two to three weeks [Figure 1].

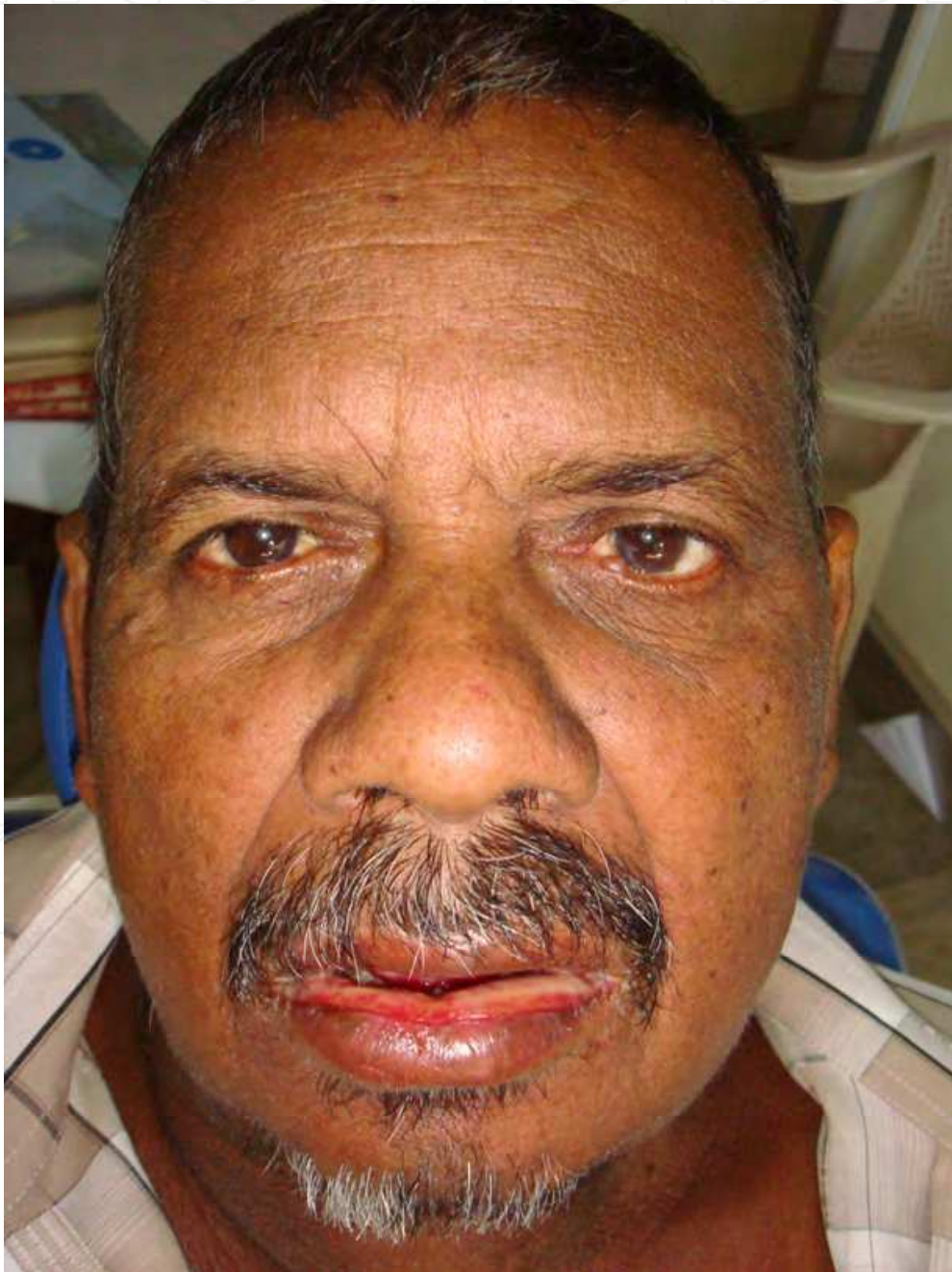


Fig. 1. Oral mucositis in a patient.

Mucositis is an inevitable side effect of radiation. Its severity is dependent on the type of ionizing radiation, the volume of irradiated tissue, the dose per day, and cumulative dose. It has been noted in a considerable number of clinical trials that the severity of acute normal tissue responses, particularly oral mucositis, is significantly increased when the overall treatment time is shortened.^[12,13] The clinical course of oral mucositis may sometimes be complicated by local infection, particularly in immunosuppressed patients. Viral infections such as herpes simplex virus (HSV), and fungal infections such as candidiasis can sometimes be superimposed on oral mucositis. Although HSV infections do not cause oral mucositis, they can complicate its diagnosis and management.

Histopathologically, edema of the rete pegs is noted, along with vascular changes that demonstrate a thickening of the tunica intima with concomitant reduction in the lumen size and destruction of the elastic and muscle fibers of the vessel walls. The loss of the epithelial cells to the basement membrane exposes the underlying connective tissue stroma with its associated innervations, which, as the mucosal lesions enlarge, contributes to increasing pain. If the patient develops both severe mucositis and thrombocytopenia, oral bleeding may occur, which is very difficult to treat.

4. Clinical management of oral mucositis

Management of oral mucositis can be divided into the following sections: pain control, nutritional support, oral decontamination, palliation of dry mouth, management of oral bleeding, and therapeutic interventions for oral mucositis.

4.1 Pain control

The most common symptom of oral mucositis is pain. Pain significantly affects the nutritional intake, the mouth care, and the quality of life. Thus, management of mucositis pain is a primary component of any mucositis management strategy. Many centers use saline mouth rinses, ice chips, and topical mouth rinses containing an anesthetic, such as 2% viscous lidocaine, which may be mixed with equal volumes of diphenhydramine and a soothing covering agent in equal volumes. Such topical anesthetic agents may provide short-term relief. Sucralfate is the most commonly used and widely studied, even though there is no significant decrease in the pain control.^[14,15] In addition to the use of topical agents, most patients with severe mucositis require systemic analgesics, often including opioids, for satisfactory pain relief. Though, the so called '*magic mouthwash*' (lidocaine, diphenhydramine, magnesium aluminum hydroxide) has been observed to be beneficial, morphine mouth washes are preferable.^[16,17] It was significantly better at reducing intensity and duration of pain and functional impairment, with fewer adverse effects.

4.1.1 Sucralfate

Sucralfate also has been tested in patients receiving radiation therapy. One study compared 21 patients who received standard oral care to the head and neck with 24 patients who received sucralfate suspension four times daily. Results revealed a significant difference in mucosal edema, pain, dysphagia, and weight loss in patients receiving sucralfate [18]. In a pilot study done by Pfeiffer et al. [19], sequential patients who received radiation therapy to the head and neck received sucralfate at the onset of mucositis. Most patients had a decrease in pain following the use of sucralfate. A double-blind, placebo-controlled study with sucralfate in 33 patients who received irradiation to the head and neck reported no

statistically significant differences in mucositis; however, the sucralfate group reported less oral pain, and other topical and systemic analgesics were started later in the course of radiation [20]. A prospective double-blind study compared the effectiveness of sucralfate suspension versus diphenhydramine syrup plus kaolin-pectin on radiotherapy-induced mucositis. Data were collected daily, including perceived pain, helpfulness of mouth rinses, weekly mucositis grade, weight change, and interruption of therapy. Analysis of the two groups revealed no statistically significant differences between the two groups. In a retrospective review, 15 patients who had not used daily oral rinses were compared with the two groups, and the results suggested that the use of a daily oral rinse with a mouth-coating agent may result in less pain, reduce weight loss, and help prevent interruption of radiation because of severe mucositis[21].

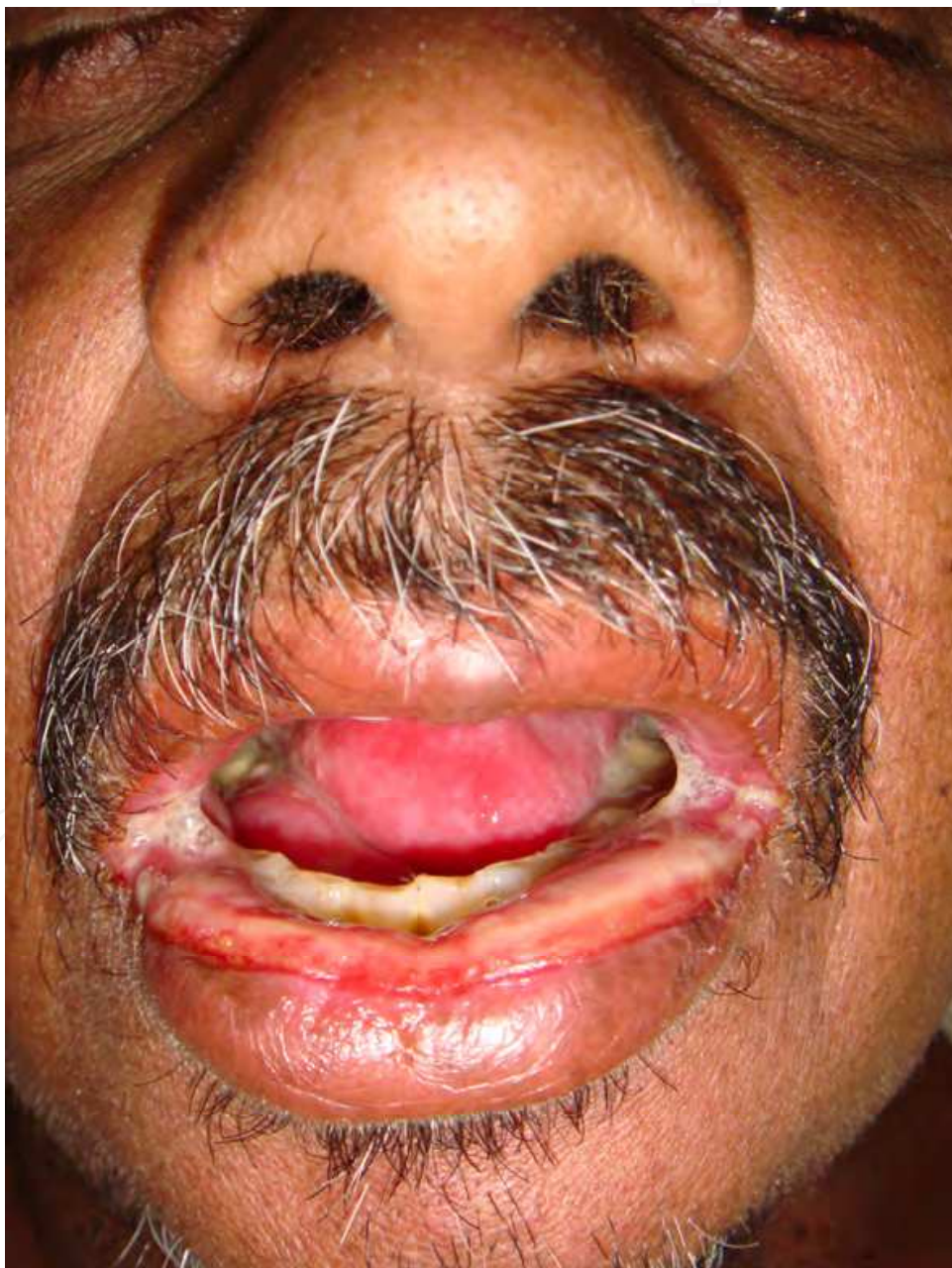

Fig. 2. Oral mucositis in a patient.

4.1.2 Morphine in pain control

In a study to compare the effect of locally applied morphine mouthwash(MO) with Magic mouth wash (MG) on mucositis-related oral pain and on the maintenance of oral intake in patients with tumors of the head and neck area treated with a chemoradiotherapy regimen⁵¹. Additional objectives were to evaluate the safety of MO by determining the frequency of treatment-emergent drug-related adverse events (local and systemic) or hematologic and biochemical abnormalities, the intensity of chemoradiotherapy administered, tumor response, weight loss, need of a nasogastric tube, and mucositis-related hospitalizations. The duration of severe pain was 3.5 days less in the Morphine group compared with the Magic mouth wash group ($P = 0.032$). The intensity of oral pain was also significantly lower in the MO group compared with the MG group. More patients in the MG group needed supplementary (oral or parenteral) analgesia compared with the MO group ($P = 0.019$). Nevertheless, the time elapsed before the first supplemental analgesic and the total amount of analgesics taken was similar for both groups. Of 12 patients in the MG group, 3 (25%) and none in the MO group required third-step opiates for alleviation of mouth pain. However, the differences in the maximum WHO step needed for control of pain were not statistically significant. There was a significant difference in duration of severe functional impairment. Nevertheless, the body weight change was similar for both groups. There were no significant differences in documented or highly suspected infections, change in performance status, tumor response rate, and intensity of the chemoradiotherapy delivered between the two treatment groups. No patients required hospitalization due to mucositis during the study. Patients in the MG group reported more local side effects^[51].

4.2 Nutritional support

A soft diet or liquid diet was more easily tolerated than a normal diet, when oral mucositis is present; gastrostomy tube is more beneficial, when there is severe mucositis.

4.3 Selective oral decontamination

It has been hypothesized that microbial colonization of oral mucositis lesions exacerbates the severity of oral mucositis and, therefore, decontamination may help to reduce mucositis. Due to the fact that the oral cavity contains a high amount of Gram-negative bacilli and considering its etiological role in mucositis, the concept of 'Selective Decontamination' has been developed. In this regard, lozenges composed of polymyxin E, tobramycin, and amphotericin B have been studied in patients receiving radiation for cancers of head and neck in a randomized trial that compared lozenges with placebo or chlorhexidine rinses, the antimicrobial lozenges provided more effective mucositis prevention in patients receiving head and neck irradiation. Addition of ciprofloxacin or ampicillin with clotrimazole to Sucralfate has shown reduction in mucositis.^[22]

4.4 Oral hygiene

Significant reduction in oral mucositis can be attained by proper oral hygiene measures.^[23] It was noted that proper oral care also reduced oral toxicity of radiation therapy. Indeed, multiple studies have demonstrated that maintenance of good oral hygiene can reduce the severity of oral mucositis. Furthermore, oral decontamination can reduce infection of the oral cavity by opportunistic pathogens.^[24] Therefore, a second function of oral decontamination can be to reduce the risk of systemic sepsis from resident oral and/or opportunistic pathogens. Intensive oral care protocol decreased risk of oral mucositis, but not the percentage of patients with a documented septicemia.^[25]

The RTOG and MASCC/ISOO (Mucositis study group of the multinational association for supportive care in cancer and the International society of oral oncology) guidelines recommend use of a standardized oral care protocol, including brushing with a soft toothbrush, flossing, and the use of nonmedicated rinses (for example, saline or sodium bicarbonate rinses). Patients and caregivers should be educated regarding the importance of effective oral hygiene [26, 52, 53].

4.5 Palliation of dry mouth

In cancer therapy, patients often develop transient or permanent xerostomia and hyposalivation. Hyposalivation can further aggravate inflamed tissues, increase risk for local infection, and make mastication difficult. Many patients also complain of a thickening of salivary secretions, because of a decrease in the serous component of saliva. The following measures can be taken for palliation of a dry mouth:

- Sip water as needed to alleviate mouth dryness; several supportive products including artificial saliva are available.
- Rinse with a solution of half a teaspoon of baking soda half in one cup warm water several times a day to clean and lubricate the oral tissues and to buffer the oral environment.
- Chew sugarless gum to stimulate salivary flow.
- Use cholinergic agents as necessary.

4.6 Kaolin pectin

Kaolin pectin, combined with diphenhydramine, which is a H1-histamine antagonist and local anesthetic, was found to reduce oral pain without reducing the degree of mucositis in a double blind randomized and controlled study.[27]

5. Growth factors

One of the problem faced by the therapy is the loss of proliferation of the oral epithelial cells, it has seen that various growth factors that can increase epithelial cell proliferation have been studied for the management of oral mucositis. Recent evidence shows that intravenous recombinant human keratinocyte growth factor-1, Palifermin, significantly reduced incidence of WHO grades 3 and 4 oral mucositis in patients with hematologic malignancies (for example, lymphoma and multiple myeloma) receiving high-dose chemotherapy and total body irradiation before autologous hematopoietic cell transplantation.[28]

Human keratinocyte growth factor-2, Repifermin, was found to be ineffective in reducing the percentage of subjects who experienced severe mucositis.[29] Intravenous human fibroblast growth factor-20, Velafermin, is currently in clinical development for reduction of mucositis secondary to high-dose chemotherapy in autologous hematopoietic cell transplant patients.[30] The safety of this class of growth factors has not been established in patients with nonhematologic malignancies. There is a theoretical concern that these growth factors may promote growth of tumor cells, which may have receptors for the respective growth factor. However, one recent study found no significant difference in survival between subjects with colorectal cancer receiving Palifermin or placebo at a median follow-up duration of 14.5 months.[31] Further studies are ongoing to confirm the safety of epithelial growth factors in the solid tumor setting, including patients receiving radiation therapy for head and neck cancer.

Source	Grade 0	Grade 1	Grade 2	Grade 3	Grade 4
WHO	No change	Soreness/erythema	Erythema, ulcers, can eat solids	Ulcers; requires liquid diet only	Alimentation not possible
RTOG	No change over baseline	May experience mild pain not requiring analgesic	Patchy mucositis may have a serosanguinous discharge. May experience pain requiring analgesics. < 1.5 cm, noncontiguous	Confluent fibrinous mucositis/ may include severe pain requiring narcotics, > 1.5 cm, contiguous	Necrosis or deep ulceration, ± bleeding.
NCI CTC	None	Painless ulcers, erythema or mild soreness	Painful erythema, oedema or ulcers, but can eat.	painful erythema, edema or ulcers can not eat.	Requires Parenteral or enteral support
Van der schueren <i>et al</i>	None	Slight erythema	Pronounced erythema	Spotted mucositis	Confluent mucositis patches >0.5cm.
Byfield <i>et al</i>	---	Minimal dysphasia, thinning but no overt break in mucosal integrity.	Significant dysphasia, semi soft foods only, focal mucosal vesicles or denuded patches.	Fluids only tolerated, obviously large confluent patches of mucosal denudation	Parenteral fluids only, severe confluent mucosal denudation with bleeding.
Seto <i>et al</i>	----	Localized erythema with no pain	Generalized erythema without pain or localized erythema or ulcers with mild pain.	Multiple ulcers or generalized erythema with moderate pain	Generalized erythema or ulcers with moderate to severe pain.
Eilers <i>et al</i>	----	Pink and moist	Reddened or white film without ulcerations	Ulceration with or without bleeding	-----
NCIC	None	Painless ulcers, erythema, or mild soreness.	Painful erythema, oedema, or ulcers, but can eat	Painful erythema, oedema, or ulcers, but can not eat	Mucosal necrosis and/or requires Parenteral or enteral support, dehydration.
Spijkervet <i>et al</i>	None	White discoloration	Erythema	Pseudomembrane	ulceration
Macejowski	None	Type: mild erythematous area: <25%	Type : severe erythematous area: 25-50%	Type: spotted mucositis area >50%	Type:confluent mucosistis
Hickey <i>et al</i>	No stomatitis	Whitish gingival or slight burning sensation or discomfort.	Moderate erythema and ulcerations or white patches. pain, but can eat, drink and swallow.	severe erythema and ulcerations or white patches. Severe Pain and can not eat, drink or swallow.	-----

Table 1. Comparison of commonly used mucositis scoring system

6. Anti-inflammatory agents

6.1 Benzydamine hydrochloride

It is a nonsteroidal antiinflammatory drug that inhibits proinflammatory cytokines including TNF- α . In a Phase III trial, Benzydamine hydrochloride mouthrinse reduced the severity of mucositis in patients with head and neck cancer undergoing radiation therapy of cumulative doses up to 50-Gy radiation therapy.^[32] Based on this and previous studies, the MASCC/ISOO guidelines recommends use of this agent in patients receiving moderate-dose radiation therapy.^[33]

6.2 Saforis

It is a proprietary oral suspension of L-glutamine that enhances the uptake of this amino acid into epithelial cells. Glutamine may reduce mucosal injury by reducing the production of proinflammatory cytokines and cytokine-related apoptosis;^[34,35] and may promote healing by

increasing fibroblast and collagen synthesis.^[36] In a Phase III study, this topical agent reduced the incidence of clinically significant chemotherapy-induced oral mucositis compared to placebo.^[37] By comparison, the MASCC/ISOO guidelines recommend that systemically administered glutamine not be used for the prevention of GI mucositis because of lack of efficacy.^[38]

6.3 Amifostine

It (phosphothiorate, radiation protection agent) is thought to act as a scavenger for harmful reactive oxygen species that are known to potentiate mucositis.^[39] However, because of insufficient evidence of benefit, various guidelines could not be established regarding the use of this agent in oral mucositis in chemotherapy or radiation therapy patients. The use of amifostine has been recommended for the prevention of esophagitis in patients receiving chemoradiation for nonsmall-cell lung cancer.^[40]

6.4 RK- 0202 (RxKinetix)

It consists of the antioxidant, *N-acetylcysteine*, in a proprietary matrix for topical application in the oral cavity. In a placebo-controlled phase II trial in patients with head and neck cancer, this agent significantly reduced the incidence of severe oral mucositis up to doses of 50-Gy radiation therapy.^[41]

6.5 Beta carotene

Beta carotene, a vitamin A derivative, is a scavenger of singlet oxygen. Based on the findings of different randomized controlled study, it is of the view that supplemental dietary beta-carotene lead to a mild decrease in the severity of chemotherapy and radiotherapy-induced oral mucositis.^[42]

7. Immunomodulatory drugs

7.1 Pentoxifylline

Oral pentoxifylline reduced the frequency and severity of all major complications after BMT, including reduction of oral mucositis.^[43] Contradictory to this, other workers reported a significant aggravation of symptoms when they studied the effect of IV Pentoxifylline in 92 patients.^[44] However, no difference in symptoms was noted in patients who undergo chemo radio therapy.

7.2 Indomethacin

Indomethacin, a nonsteroidal antiinflammatory drug inhibiting prostaglandin synthesis is noted to delay the onset of mucositis.

7.3 Immunoglobulin

Treatment with low-dose intra muscular immunoglobulin is said to decrease the severity and duration of radio therapy-induced oral mucositis. Immunoglobulin has also been tried as a therapeutic agent in radiation-induced mucositis in various clinical trials and the observations were promising.^[45]

7.4 Cytokines

Preclinical models have been used to demonstrate that the cytokines interleukin-1, interleukin-2, epidermal growth factor, interleukin-11, and transforming growth factor-beta

have direct effect on intestinal or oral mucosa. Interleukin-1 increases thymidine labeling, and protects oral and intestinal mucosa, when given to mice before radiation. Interleukin-11 can decrease mucositis, when given to hamster models.

7.5 G-CSF, GM-CSF

The mucosal protection effects of granulocyte colony stimulating factor G-CSF were observed in patients treated with various chemotherapy regimens by many authors.^[46] But controversies to this exist in other clinical trials. In a recent preliminary report of a pilot study found significant reduction in oral mucositis.^[47] The study was to evaluate the effect of GM-CSF in reduction of radiotherapy induced oral mucositis. At about second week of radiotherapy, when oral pain was experienced 400 µg of GM-CSF was administered locally once a day, until completion of radiotherapy. The patients were evaluated weekly for mucosal reaction and functional impairment. The result of the study was prompting with reduction and almost healing of oral mucositis in 14 out of 17 patients with completion of radiotherapy within the preplanned schedule. Moreover patients did not show a significant weight loss or functional impairment.

8. Anti-viral drugs

8.1 Acyclovir

Although acyclovir prophylaxis is effective in preventing oropharyngeal shedding of the virus in herpes simplex virus seropositive patients receiving intensive chemotherapy or BMT, it did not influence chemotherapy, radiotherapy and BMT-related oral toxicity.

9. Role of safe radiotherapy

Normal tissue reactions can be reduced in a substantial number of patients with head and neck cancer by the use of computed tomography (CT)-based target delineation, Intensity-Modulated Radiation Therapy (IMRT), and simple, custom-made, intraoral devices that are designed to exclude uninvolved tissues from the treatment portals or to provide shielding of tissues within the treatment area.^[43] Stents can be useful in excluding the palate mucosa during treatment of the tongue or floor of the mouth. These shielding stents can decrease the amount of radiation that is delivered to the contra-lateral mucosa. More frequent use of electron-beam and/or sophisticated three-dimensional conformal, multibeam, wedged-pair, or oblique treatment plans will also help to exclude or minimize the radiation dose to uninvolved mucosa. Packing gauze between metallic dental restorations and mucosa of the lateral tongue and buccal area appears to be very beneficial in minimizing the dose from scattered radiation.

9.1 Antifungal therapy

The mucosa of patients undergoing radiation therapy to the oral cavity should be examined at least once a week, and antibiotic or antifungal medications should be prescribed when infections are documented. Clotrimazole troches, dissolved in the mouth five times a day for 14 days, generally works well for oral candidiasis. However, if significant mucositis, altered taste, or xerostomia has developed, the troches might not be tolerated. In this situation, nystatin oral suspension or Fluconazole in tablet or liquid form is often effective. Fluconazole is more effective than nystatin and might need to be given at a higher dose and/or for an extended period of time in patients who are receiving combined chemotherapy and radiation therapy due to infections with resistant species.^[48]

9.2 Low-level laser therapy

The mechanism of low-level laser therapy is not understood, but many studies have proved the efficacy of the same in reducing the symptoms related to oral mucositis. Low-level laser therapy may reduce levels of reactive oxygen species and/or proinflammatory cytokines that contribute to the pathogenesis of mucositis.^[49] The various guidelines suggest the use of low-level laser therapy for reducing the severity of chemotherapy and radiotherapy-induced oral mucositis.^[50]

9.3 AMP-18 (Antral mucosal protein) 18

A study on AMP18 (AMP-18 is a protein constitutively expressed in epithelial cells of the gastric antrum that is cell protective, mitogenic and motogenic in cell culture and in vivo) shows, AMP peptide, by activating CCKBR (cholecystokinin-B/gastrin receptor), targets TJs(Tight Junctions) to maintain mucosal integrity, and sets in motion protective and cell regenerative mechanisms for the prevention and treatment of OM. Treatment with AMP peptide protected the surface epithelium of the mouse oral mucosa. AMP-18 peptide stimulates growth of diverse types of epithelial cells including HaCaT cells ^[54].

10. Summary

Mucositis is an inevitable side effect of radiation. The severity of the mucositis depends on the type of ionizing radiation, the volume of irradiated tissue, the daily dose, and the cumulative dose. As the mucositis becomes more severe, pseudomembranes and ulcerations develop. Poor nutritional status further interferes with mucosal regeneration by decreasing cellular migration and renewal. Radiation-induced oral mucositis affects the quality of life of the patients and the family concerned. The present day management of oral mucositis is mostly palliative and or supportive care. Management includes good oral hygiene, avoiding irritating or abrasive substances, use of bland rinses, topical anesthetic agents, and systemic analgesics. Though, the newer guidelines are suggesting Palifermin, which is the first active mucositis drug as well as Amifostine, for radiation protection and cryotherapy for symptoms related to high-dose melphalan; the role of safe radiotherapy remains the ultimate goal in reducing the symptoms of radiation-induced oral mucositis. Future research for the newer drugs in the field of radiation-induced oral mucositis is a must, and the current management should focus more on palliative measures, such as pain management, nutritional support, and maintenance, of good oral hygiene.


11. References

- [1] Sonis ST. Is mucositis an inevitable consequence of intensive therapy for hematologic cancers? *Nat Clin Pract Oncol* 2005;2:134-5.
- [2] Keefe DM. Mucositis guidelines: What have they achieved, and where to from here? *Support Care Cancer* 2006;14:489-91.
- [3] Trotti A, Bellm LA, Epstein JB, Frame D, Fuchs HJ, Gwede CK, *et al.* Mucositis incidence, severity and associated outcomes in patients with head and neck cancer receiving radiotherapy with or without chemotherapy: A systematic literature review. *Cancer* 2008;113:2704-13.
- [4] Satheesh Kumar PS, Balan A, Sankar A, Bose T. Radiation induced oral mucositis. *Indian J Palliat Care* 2009;15:95-102

- [5] Satheeshkumar PS, Chamba MS, Balan A, Sreelatha KT, Bhatathiri VN, Bose T. Effectiveness of triclosan in the management of radiation-induced oral mucositis: A randomized clinical trial. *J Can Res Ther* 2010;6:466-72.
- [6] P.S Satheeshkumar, A. Balan. Subjective response of pain on patients treated with aqueous base Hexidine and weekly dentist assisted oral hygiene maintenance for radiation induced oral mucositis- An interventional study." *Oral Oncology*, Volume 47, Supplement 1, July 2011, Page S82
- [7] Logan RM, Gibson RJ, Sonis ST, Keefe DM. Nuclear factor- κ B (NF- κ B) and cyclooxygenase-2 (COX-2) expression in the oral mucosa following cancer chemotherapy. *Oral Oncol* 2007;43:395-401.
- [8] Gibson RJ, Bowen JM, Cummins AG, Logan R, Healey T, Keefe DM. Ultrastructural changes occur early within the oral mucosa following cancer chemotherapy [abstract A-373]. *Support Care Cancer* 2004;12:389.
- [9] Sonis ST, Elting LS, Keefe D, Peterson DE, Schubert M, Hauer-Jensen M, *et al.* Perspectives on cancer therapy-induced mucosal injury: Pathogenesis, measurement, epidemiology, and consequences for patients. *Cancer* 2004;100:1995-2025.
- [10] Sonis ST, Elting LS, Keefe D, Peterson DE, Schubert M, Hauer-Jensen M, *et al.* Perspectives on cancer therapy-induced mucosal injury: Pathogenesis, measurement, epidemiology, and consequences for patients. *Cancer* 2004;100:1995-2025.
- [11] Sonis ST, Peterson RL, Edwards LJ, Lucey CA, Wang L, Mason L, *et al.* Defining mechanisms of action of interleukin-11 on the progression of radiation-induced oral mucositis in hamsters. *Oral Oncol* 2000;36:373-81.
- [12] Dorr W, Emmendorfer H, Haide E. Proliferation equivalent of 'accelerated repopulation' in mouse oral mucosa. *Int J Radiat Biol* 1994;66:157-67.
- [13] Epstein JB, Gorsky M, Guglietta A, Le N, Sonis ST. The correlation between epidermal growth factor levels in saliva and the severity of oral mucositis during oropharyngeal radiation therapy. *Cancer* 2000;89:2258-65.
- [14] Dodd MJ, Miaskowski C, Greenspan D, MacPhail L, Shih AS, Shiba G, *et al.* Radiation-induced mucositis: A randomized clinical trial of micronized sucralfate versus salt and soda mouthwashes. *Cancer Invest* 2003;21:21-33.
- [15] Nottage M, McLachlan SA, Brittain MA, Oza A, Hedley D, Feld R, *et al.* Sucralfate mouthwash for prevention and treatment of 5-fluorouracil-induced mucositis: A randomized, placebo-controlled trial. *Support Care Cancer* 2003;11:41-7.
- [16] Barclay L. Morphine mouthwash relieves pain of oral mucositis. *Cancer* 2002;95:2230-6.
- [17] Spijkevet FK, van saene JJ, Panders AK, Vermy A, Mehta DM, Filder V. Effect of selective elimination of the oral flora on mucositis in irradiated head and neck cancer patients. *J Surg Oncol* 1991;46:167-73.
- [18] Matthews RH, Ercal N. Prevention of mucositis in irradiated head and neck cancer patients. *J Exp Ther Oncol* 1996;1:135-8.
- [19] Borowski B, Benhamou E, Pico JL, Laplanche A, Margainaud JP, Hayat M. Prevention of oral mucositis in patients treated with high-dose chemotherapy and bone marrow transplantation: A randomized controlled trial comparing two protocols of dental care. *Eur J Cancer B Oral Oncol* 1994;308:93-7.
- [20] Yoneda S, Imai S, Hanada N, Yamazaki T, Senpuku H, Ota Y, *et al.* Effects of oral care on development of oral mucositis and microorganisms in patients with esophageal cancer. *Jpn J Infect Dis* 2007;60:23-8.
- [21] McGuire DB, Correa ME, Johnson J, Wienandts P. The role of basic oral care and good clinical practice principles in the management of oral mucositis. *Support Care Cancer* 2006;14:541-7.

- [22] Barker G, Loffus L, Cuddy P, Barker B. The effects of of sucralfate suspension and diphenhydramine syrup plus kaolin-pectin on radiotherapy-induced mucositis. *Oral Surg Oral Med Oral Pathol* 1991;71:288-93.
- [23] Spielberger R, Stiff P, Bensinger W, Gentile T, Weisdorf D, Kewalramani T, *et al.* Palifermin for oral mucositis after intensive therapy for hematologic cancers. *N Engl J Med* 2004;351:2590-8.
- [24] von Bultzingslowen I, Brennan MT, Spijkervet FK, Logan R, Stringer A, Raber-Durlacher JE, *et al.* Growth factors and cytokines in the prevention and treatment of oral and gastrointestinal mucositis. *Support Care Cancer* 2006;14:519-27.
- [25] Scherlacher A, Beaufort-Spontin E. Radiotherapy of head-neck neo-plasms:prevention of inflammation of the mucosa by sucralfate treatment. *HNO* 1990;38:24-28.
- [26] Pfeiffer P, Hansen O, Madsen el, *et al.* A prospective pilot study on the effect of sucralfate mouth-swishing in reducing stomatitis during radiotherapy of the oral cavity. *Acta Oncol* 1990;29:471-3.
- [27] Epstein jb, Wong FLW The efficacy of sucralfate suspension in the prevention of oral mucositis due to radiation therapy. *Int J Radiat Oncol Biol Phys* 1994;28:693-698.
- [28] Barker G, Loftus L, Cuddy P, *et al.* The effects of sucralfate suspension and diphenhydramine syrup plus kaolin-pectin on radiotherapy-induced mucositis. *Oral Surg Oral Med Oral Pathol Oral Radiol Endod* 1991;71:288-293.
- [29] Lalla RV. Velafermin (CuraGen). *Curr Opin Investig Drugs* 2005;6:1179-85.
- [30] Rosen LS, Abdi E, Davis ID, Gutheil J, Schnell FM, Zalberg J, *et al.* Palifermin reduces the incidence of oral mucositis in patients with metastatic colorectal cancer treated with fluorouracil-based chemotherapy. *J Clin Oncol* 2006;24:5194-200.
- [31] Epstein JB, Silverman S Jr, Paggiarino DA, Crockett S, Schubert MM, Senzer NN, *et al.* Benzydamine HCl for prophylaxis of radiation-induced oral mucositis: Results from a multicenter, randomized, double-blind, placebo-controlled clinical trial. *Cancer* 2001;92:875-85.
- [32] Lalla RV, Schubert MM, Bensadoun RJ, Keefe D. Anti-inflammatory agents in the management of alimentary mucositis. *Support Care Cancer* 2006;14:558-65.
- [33] Coeffier M, Marion R, Leplingard A, Lerebours E, Ducrotté P, Déchelotte P. Glutamine decreases interleukin-8 and interleukin-6 but not nitric oxide and prostaglandins e production by human gut in-vitro. *Cytokine* 2002;18:92-7.
- [34] Evans ME, Jones DP, Ziegler TR. Glutamine prevents cytokine-induced apoptosis in human colonic epithelial cells. *J Nutr* 2003;133:3065-71.
- [35] Bellon G, Monboisse JC, Randoux A, Borel JP. Effects of preformed proline and proline amino acid precursors (including glutamine) on collagen synthesis in human fibroblast cultures. *Biochim Biophys Acta* 1987;930:39-47.
- [36] Peterson DE, Jones JB, Petit RG 2nd. A Randomized, placebo-controlled trial of Saforis for prevention and treatment of oral mucositis in breast cancer patients receiving anthracycline-based chemotherapy. *Cancer* 2007;109:322-31.
- [37] Pytlik R, Benes P, Patorkova M, Chocenská E, Gregora E, Procházka B, *et al.* Standardized parenteral alanyl-glutamine dipeptide supplementation is not beneficial in autologous transplant patients: A randomized, doubleblind, placebo controlled study. *Bone Marrow Transplant* 2002;30:953-61.
- [38] Mantovani G, Maccio A, Madeddu C, Mura L, Massa E, Gramignano G, *et al.* Reactive oxygen species, antioxidant mechanisms and serum cytokine levels in cancer patients, Impact of an antioxidant treatment. *J Environ Pathol Toxicol Oncol* 2003;22:17-28.

- [39] Bensadoun RJ, Schubert MM, Lalla RV, Keefe D. Amifostine in the management of radiation induced and chemo-induced mucositis. *Support Care Cancer* 2006;14:566-72.
- [40] Barasch A, Peterson DE, Tanzer JM, D'Ambrosio JA, Nuki K, Schubert MM, *et al.* Helium-neon laser effects on conditioning induced oral mucositis in bone marrow transplantation patients. *Cancer* 1995;76:2550-6.
- [41] Mills EE. The modifying effect of beta-carotene on radiation and radiotherapy and chemotherapy induced oral mucositis. *Br J Cancer* 1988;57:416-7.
- [42] Bianco JA, Appelbaum FR, Nemunaitis J, Almgren J, Andrews F, Kettner P, *et al.* Phase I-II trial of pentoxifyline for the prevention of transplant-related toxicities following bone marrow transplantation. *Blood* 1991;78:1205-11.
- [43] Clift RA, Bianco JA, Appelbaum FR, Buckner CD, Singer JW, Bakke L, *et al.* A randomized controlled trial of pentoxifylline for the prevention of regimen-related toxicities in patients undergoing allogeneic marrow transplantation. *Blood* 1993;82:2025-30.
- [44] Mose S, Adametz IA, Saran F, Thilmann C, Hayd R, Knecht R, *et al.* Can Prophylactic application of immunoglobulin decrease radiotherapy-induced oral mucositis. *Am J Clin Oncol* 1997;20:407-11.
- [45] Hermann F, Schuiz G, Weser M, Kolbe K, Nicolay U, Noack M, *et al.* Effect of granulocyte-macrophage colony stimulating factor on neutropenia and related morbidity induced by myelotoxic chemotherapy. *Am J Med* 1990;88:619-24.
- [46] Gluckman E, Lotsberg J, Devergie A, Zhao XM, Melo R, Gomez-Morales M, *et al.* Oral acyclovir prophylactic treatment of herpes simplex infection after bone marrow transplantation. *J Antimicrob Chemother* 1983;12:161-7.
- [47] Kaanders JH, Fleming TJ, Ang KK, Maor MH, Peters LJ. Devices valuable in head and neck radiotherapy. *Int J Radiat Oncol Biol Phys* 1992;23:639-45.
- [48] Dahiya MC, Redding SW, Dahiya RS, Eng TY, Kirkpatrick WR, Coco BJ, *et al.* Oropharyngeal candidiasis caused by non-albicans yeast in patients receiving external beam radiotherapy for head-and-neck cancer. *Int J Radiat Oncol Biol Phys* 2003;57:79-83.
- [49] Bensadoun RJ, Franquin JC, Ciais G, Darcourt V, Schubert MM, Viot M, *et al.* Low-energy He/Ne laser in the prevention of radiation-induced mucositis: A multicenter phase III randomized study in patient's with head and neck cancer. *Support Care Cancer* 1999;7:244-52.
- [50] Migliorati CA, Oberle-Edwards L, Schubert M. The role of alternative and natural agents, cryotherapy, and/or laser for management of alimentary mucositis. *Support Care Cancer* 2006;14:533-40.
- [51] Cerchietti LC, Navigante AH, Bonomi MR, Zaderajko MA, Menéndez PR, Pogany CE, Roth BM. Effect of topical morphine for mucositis-associated pain following concomitant chemoradiotherapy for head and neck carcinoma. *Cancer*. 2002 Nov 15;95(10):2230-6.
- [52] S.K. Poolakkad Sankaran, A. Balan. Neighbourhood Dental Clinic programme (NDCP) for oral care in patients undergoing head and neck cancer therapy. *Support Care Cancer* (2011) 19 (Suppl 2):S67-S370.
- [53] S.K. Poolakkad Sankaran, A. Balan. The degree of discomfort due to mucositis is related to the prior patient awareness? *Support Care Cancer* (2011) 19 (Suppl 2):S67-S370.
- [54] Chen P, Lingen M, Sonis ST, Walsh-Reitz MM, Toback FG. Role of AMP-18 in oral mucositis. *Oral Oncol*. 2011 Sep;47(9):831-9. Epub 2011 Jul 6



Pain Management - Current Issues and Opinions

Edited by Dr. Gabor Racz

ISBN 978-953-307-813-7

Hard cover, 554 pages

Publisher InTech

Published online 18, January, 2012

Published in print edition January, 2012

Pain Management - Current Issues and Opinions is written by international experts who cover a number of topics about current pain management problems, and gives the reader a glimpse into the future of pain treatment. Several chapters report original research, while others summarize clinical information with specific treatment options. The international mix of authors reflects the "casting of a broad net" to recruit authors on the cutting edge of their area of interest. Pain Management - Current Issues and Opinions is a must read for the up-to-date pain clinician.

How to reference

In order to correctly reference this scholarly work, feel free to copy and paste the following:

P. S. Satheesh Kumar (2012). Radiation Mucositis, Pain Management - Current Issues and Opinions, Dr. Gabor Racz (Ed.), ISBN: 978-953-307-813-7, InTech, Available from: <http://www.intechopen.com/books/pain-management-current-issues-and-opinions/radiation-mucositis>

INTECH
open science | open minds

InTech Europe

University Campus STeP Ri
Slavka Krautzeka 83/A
51000 Rijeka, Croatia
Phone: +385 (51) 770 447
Fax: +385 (51) 686 166
www.intechopen.com

InTech China

Unit 405, Office Block, Hotel Equatorial Shanghai
No.65, Yan An Road (West), Shanghai, 200040, China
中国上海市延安西路65号上海国际贵都大饭店办公楼405单元
Phone: +86-21-62489820
Fax: +86-21-62489821

© 2012 The Author(s). Licensee IntechOpen. This is an open access article distributed under the terms of the [Creative Commons Attribution 3.0 License](#), which permits unrestricted use, distribution, and reproduction in any medium, provided the original work is properly cited.

IntechOpen

IntechOpen