

We are IntechOpen, the world's leading publisher of Open Access books Built by scientists, for scientists

4,800

Open access books available

122,000

International authors and editors

135M

Downloads

Our authors are among the

154

Countries delivered to

TOP 1%

most cited scientists

12.2%

Contributors from top 500 universities



WEB OF SCIENCE™

Selection of our books indexed in the Book Citation Index
in Web of Science™ Core Collection (BKCI)

Interested in publishing with us?
Contact book.department@intechopen.com

Numbers displayed above are based on latest data collected.
For more information visit www.intechopen.com



Epidural Lysis of Adhesions and Percutaneous Neuroplasty

Gabor B. Racz¹, Miles R. Day¹, James E. Heavner¹, Jeffrey P. Smith¹, Jared Scott², Carl E. Noe³, Laslo Nagy⁴ and Hana Ilner¹

¹*Texas Tech University Health Sciences Center, Lubbock, Texas*

²*Advanced Pain Medicine Associates, Wichita, Kansas*

³*University of Texas Southwestern Medical Center, Dallas, Texas*

⁴*Texas Tech University Health Sciences Center and Covenant Medical Center, Department of Pediatric Neurosurgery USA*

1. Introduction

Chances are relatively high that each of us will experience low back pain at some point in our lives. The usual course is rapid improvement with 5% to 10% developing persistent symptoms.¹ In the 1990s the estimated cost of low back pain to the health industry was in the billions of dollars, and with a larger proportion of our population now reported to be older, this number can only be expected to increase.^{2, 3} Treatment typically begins with conservative measures such as medication and physical therapy and may even include minimally and highly invasive pain management interventions. Surgery is sometimes required in patients who have progressive neurologic deficits or those who do not respond to conservative treatment sometimes chose surgery. A quandary sometimes arises, following a primary surgery, as to whether repeat surgery should be attempted or another alternative technique should be tried. This is the exact problem that the epidural adhesiolysis procedure was designed to address. Failed back surgery or postlaminectomy syndrome led to the development of the epidural adhesiolysis procedure.

It was shown to be effective in many patients with chronic pain after back surgery presumably by freeing up nerves and breaking down scar formation, delivering site-specific corticosteroids and local anesthetics, and reducing edema with the use of hyaluronidase and hypertonic saline. Epidural adhesiolysis has afforded patients a reduction in pain and neurologic symptoms without the expense and occasional long recovery period associated with repeat surgery, and often prevents the need for surgical intervention. Epidural adhesiolysis was given an evidence rating of strong correlating to a 1B or 1C evidence level for post-lumbar surgery syndrome in the most recent American Society of Interventional Pain Physicians evidence-based guidelines. The therapy is supported by observational studies and case series along with randomized-control trials. The recommendation was also made that this therapy could apply to most patients with post laminectomy syndrome or failed back syndrome in many circumstances with informed consent.⁴ Additionally, current procedural terminology (CPT) codes have been assigned to the two different kinds of adhesiolysis: CPT 62263 for the three-times injections over 2 to 3 days, usually done in an

inpatient hospital setting, and CPT 62264 for the one-time injection series surgery-center model that may need to be repeated 3 to 3.5 times in a 12-month period.

2. Pathophysiology of epidural fibrosis (scar tissue) as a cause of low back pain with radiculopathy

The etiology of chronic low back pain with radiculopathy after appropriate surgery is not well understood. Kuslich et al⁵ addressed this issue when they studied 193 patients who had undergone lumbar spine operations given local anesthetic into the epidural space. It was postulated that sciatica could only be produced by stimulation of a swollen, stretched, restricted (i.e., scarred) or compressed nerve root.⁵ Back pain could be produced by stimulation of several tissues, but the most common tissue of origin was the outer layer of the annulus fibrosus and the posterior longitudinal ligament. Stimulation for pain generation of the facet joint capsule rarely generated low back pain, and facet synovium and cartilage surfaces of the facet or muscles were never tender.⁶

The contribution of fibrosis to the etiology of low back pain has been debated.⁷⁻⁹ There are many possible etiologies of epidural fibrosis, including surgical trauma, an annular tear, infection, hematoma, or intrathecal contrast material.¹⁰ These etiologies have been well documented in the literature. LaRocca and Macnab¹¹ demonstrated the invasion of fibrous connective tissue into postoperative hematoma as a cause of epidural fibrosis, and Cooper et al¹² reported periradicular fibrosis and vascular abnormalities occurring with herniated intervertebral disks. McCarron et al¹³ investigated the irritative effect of nucleus pulposus on the dural sac, adjacent nerve roots, and nerve root sleeves independent of the influence of direct compression on these structures. Evidence of an inflammatory reaction was identified by gross inspection and microscopic analysis of spinal cord sections after homogenized autogenous nucleus pulposus was injected into the lumbar epidural space of four dogs. In the control group consisting of four dogs injected with normal saline, the spinal cord sections were grossly normal. Parke and Watanabe¹⁴ showed significant evidence of adhesions in cadavers with lumbar disk herniation.

It is widely accepted that postoperative scar renders the nerve susceptible to injury by a compressive phenomena.⁹ It is natural for connective tissue or any kind of scar tissue to form fibrous layers (scar tissue) as a part of the process that transpires after disruption of the intact milieu.¹⁵ Scar tissue is generally found in three components of the epidural space. Dorsal epidural scar tissue is formed by reabsorption of surgical hematoma and may be involved in pain generation.¹⁶ In the ventral epidural space, dense scar tissue is formed by ventral defects in the disk, which may persist despite surgical treatment and continue to produce low back pain and radiculopathy past the surgical healing phase.¹⁷ The lateral epidural space includes the epiradicular structures outside the root canals, known as the lateral recesses or “sleeves,” which are susceptible to lateral disk defects, facet hypertrophy, and neuroforaminal stenosis.¹⁸

Although scar tissue itself is not tender, an entrapped nerve root is. Kuslich et al⁵ surmised that the presence of scar tissue compounded the pain associated with the nerve root by fixing it in one position and thus increasing the susceptibility of the nerve root to tension or compression. They also concluded that no other tissues in the spine are capable of producing leg pain. In a study of the relationship between peridural scar evaluated by magnetic resonance imaging (MRI) and radicular pain after lumbar discectomy, Ross et al¹⁹ demonstrated that subjects with extensive peridural scarring were 3.2 times more likely to experience recurrent radicular pain.

This evidence also parallels a new study by Gilbert et al²⁰ in which lumbosacral nerve roots were identified as undergoing less strain than previously published during straight leg raise and in which hip motion greater than 60 degrees was determined to cause displacement of the nerve root in the lateral recess.

3. Fluid foraminotomy: Foraminal adhesiolysis or disentrainment

Relative or functional foraminal root entrapment syndrome secondary to epidural fibrosis with corresponding nerve root entrapment is frequently evident after an epidurogram and signified by lack of epidural contrast flow into epidural finger projections at those levels. The lysis procedure effectively serves as a fluid foraminotomy reducing foraminal stenosis caused by epidural fibrosis. In addition to increasing foraminal cross-sectional area, adhesiolysis serves to decompress distended epidural venous structures that may exert compression at nearby spinal levels (Fig. 1) and inevitably cause needle stick related epidural hematomas. Adhesiolysis has led to the development of flexible epiduroscopy that is being pioneered by, primarily initiated, pursued and to this day supported by Dr. James Heavner.^{21,22}

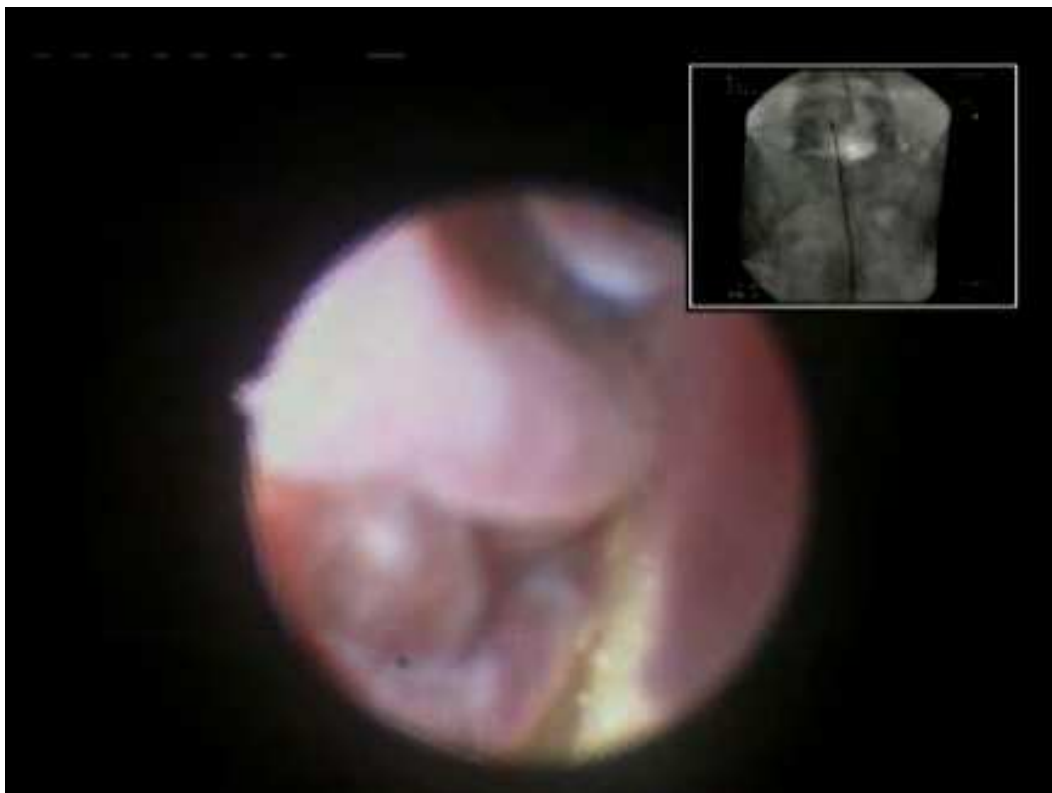

Fig. 1. Engorged blood vessels in the epidural cavity as observed during epiduroscopy. Insert in upper right corner is fluoroscopy showing location for epiduroscopy tip (left anterior border of L5)

4. Diagnosis and radiologic diagnosis of epidural fibrosis

As with any patient, a thorough musculoskeletal and neurologic examination should be performed. In addition to standard dural tension provocative tests, we recommend a provocative test called 'dural tug'. To perform the test, the patient should be instructed to sit

up with a straight leg, bend forward flexing the lumbar spine until their back pain starts to become evident, and the head and neck flexed rapidly forward. During this maneuver, the dura is stretched cephalad and if adhered to structures such as the posterior longitudinal ligament, the most heavily innervated spinal canal structure, the movement of the dura will elicit back pain that is localized to the pain generator. A positive dural tug maneuver has been observed to resolve after percutaneous neuroplasty. (Fig 2 A-E)

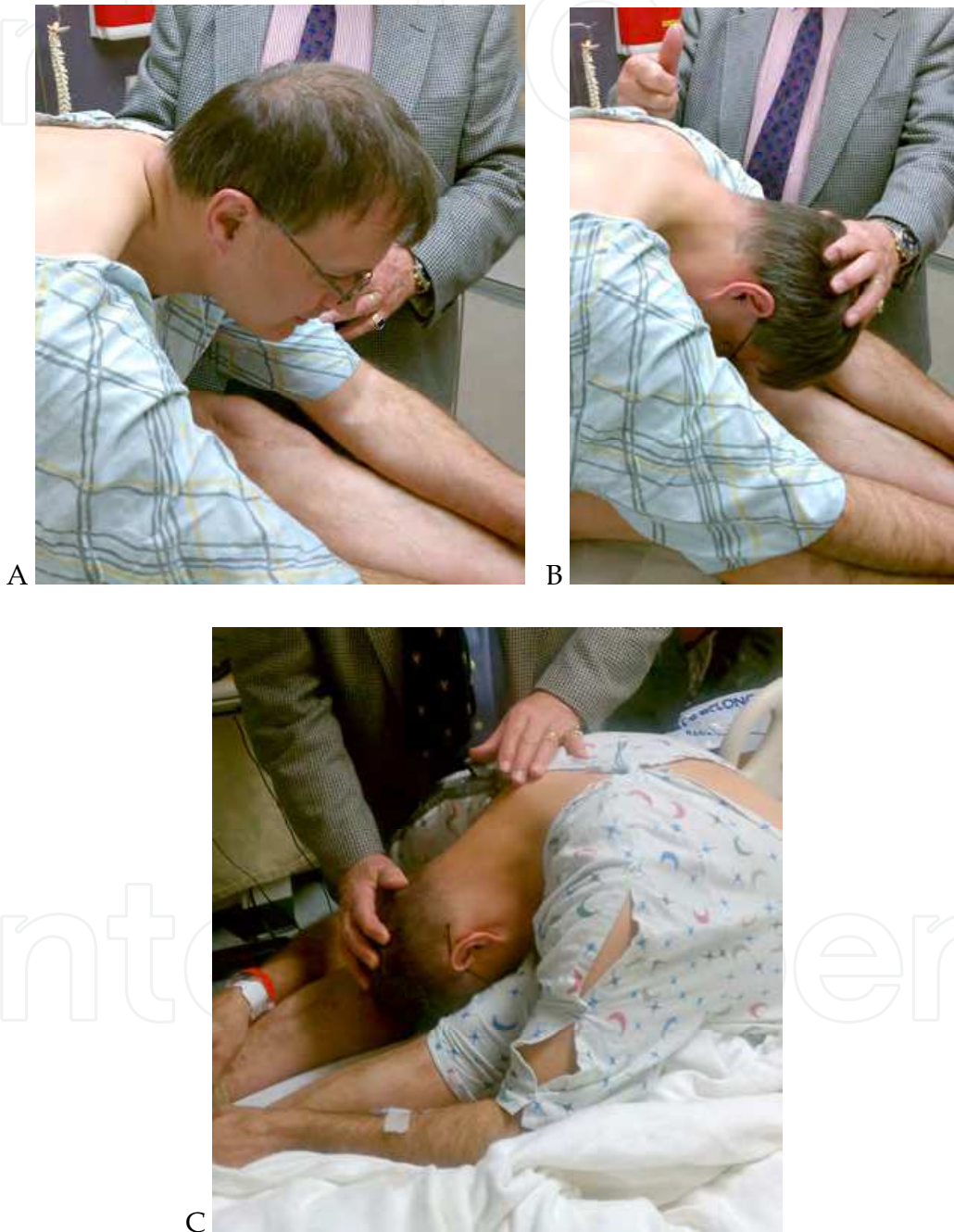

Fig. 2. A-C. A) The 'dural tug' maneuver being performed prior to percutaneous neuroplasty. B) Note pain reproduction prior to full neck flexion secondary to dural adhesions. C) Patient after percutaneous neuroplasty with pain free neck and back flexion due to treatment of dural adhesions.

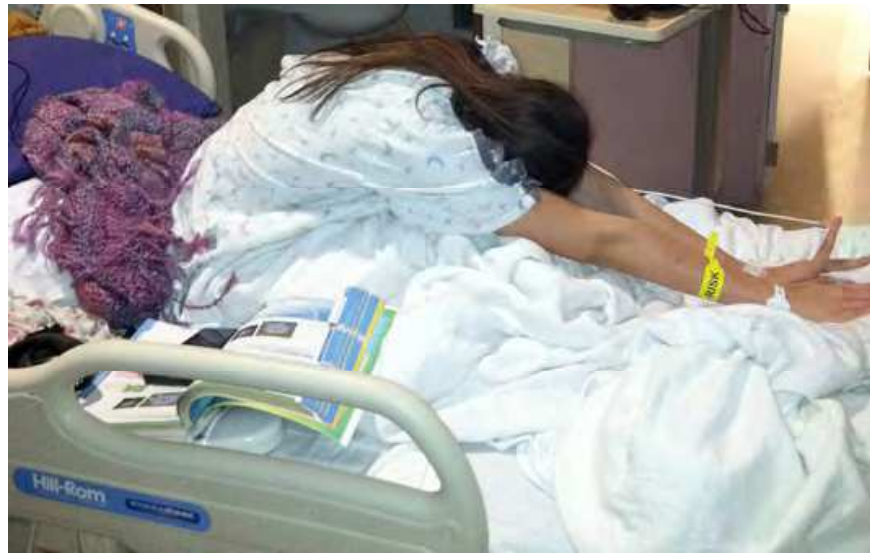
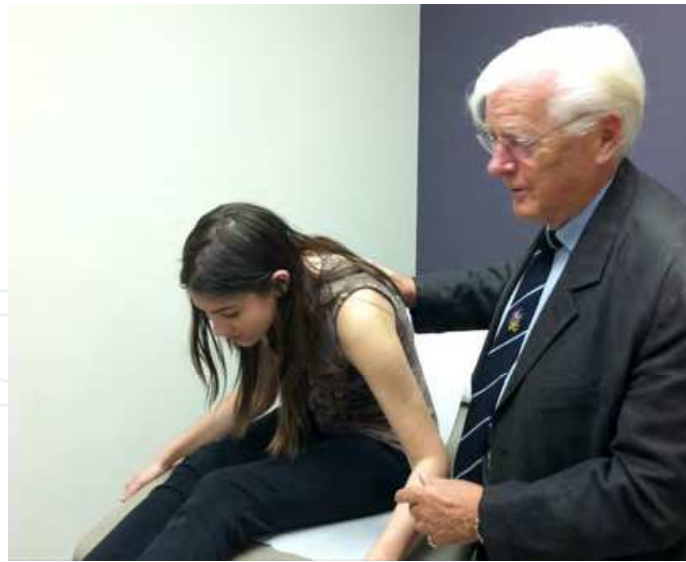
Fig. 2. D-E. D) There is decreased spine flexion prior to treatment secondary to dural adhesions. E) After treatment, the same patient demonstrates increased painless flexion of the spine.

MRI and computed tomography (CT) are diagnostic tools; sensitivity and specificity are 50% and 70%, respectively.¹⁵ CT myelography may also be helpful, although none of the aforementioned modalities can identify epidural fibrosis with 100% reliability. In contrast, epidurography is a technique used with considerable success and it is believed that epidural fibrosis is best diagnosed by performing an epidurogram.²³⁻²⁶ It can detect filling defects in good correlation with a patient's symptoms in real time.²⁶ A combination of several of these techniques would undoubtedly increase the ability to identify epidural fibrosis.

5. Current Procedural Terminology or CPT codes

The American Medical Association has developed Current Procedural Terminology codes for epidural adhesiolysis, which include 62264 for a single infusion and 62263 for a staged three-series infusion.

6. Indications for epidural adhesiolysis

Although originally designed to treat radiculopathy secondary to epidural fibrosis following surgery, the use of epidural adhesiolysis has been expanded to treat a multitude of pain etiologies. These include the following²⁷:

1. Failed back surgery syndrome
2. Postlaminectomy syndrome of the neck and back after surgery
3. Disk disruption
4. Metastatic carcinoma of the spine leading to compression fracture
5. Multilevel degenerative arthritis
6. Facet pain
7. Spinal stenosis
8. Pain unresponsive to spinal cord stimulation and spinal opioids
9. Thoracic disk related chest wall and abdominal pain (after mapping)

7. Contraindications

The following are absolute contraindications for performing epidural adhesiolysis:

1. Sepsis
2. Chronic infection
3. Coagulopathy
4. Local infection at the procedure site
5. Patient refusal
6. Syrinx formation

A relative contraindication is the presence of arachnoiditis. With arachnoiditis, the tissue planes may be adherent to one another, increasing the chance of loculation of contrast or medication. It may also increase the chance of spread of the medications to the subdural or subarachnoid space, which can increase the chance of complications. Practitioners with limited experience with epidural adhesiolysis should consider referring these patients to a clinician with more training and experience.

8. Patient preparation

When epidural adhesiolysis has been deemed an appropriate treatment modality, the risks and benefits of the procedure should be discussed with the patient and informed consent obtained. The benefits are pain relief, improved physical function, and possible reversal of neurologic symptoms. Risks include, but are not limited to, bruising, bleeding, infection, reaction to medications used (i.e., hyaluronidase, local anesthetic, corticosteroids, hypertonic saline), damage to nerves or blood vessels, no or little pain relief, bowel/bladder incontinence, worsening of pain, and paralysis. Patients with a history of urinary incontinence should have a urodynamic evaluation by a urologist before the procedure to document the preexisting urodynamic etiology and pathology.

9. Anticoagulant medication

Medications that prolong bleeding and clotting parameters should be withheld before performing epidural adhesiolysis. The length of time varies depending on the medication taken. A consultation with the patient's primary physician should be obtained before

stopping any of these medications, particularly in patients who require chronic anticoagulation such as those with drug-eluting heart stents or prosthetic heart valves. Nonsteroidal anti-inflammatory drugs and aspirin, respectively, should be withheld 4 days and 7 to 10 days before the procedure. Although there is much debate regarding these medications and neuraxial procedures, we tend to be on the conservative side. Clopidogrel (Plavix) should be stopped 7 days before, whereas ticlopidine (Ticlid) is withheld 10 to 14 days before the adhesiolysis.²⁸ Warfarin (Coumadin) stoppage is variable but 5 days is usually adequate.²⁷ Patients on subcutaneous heparin should have it withheld a minimum of 12 hours before the procedure, whereas those on low-molecular-weight heparin require a minimum of 24 hours.²⁸ Over-the-counter homeopathic medications that prolong bleeding parameters should also be withheld. These include fish oil, vitamin E, ginkgo biloba, garlic, ginseng, and St. John's Wort. Adequate coagulation status can be confirmed by the history, INR, prothrombin time, partial thromboplastin time, and a platelet function assay or bleeding time. The tests should be performed as close to the day of the procedure as possible. Tests performed only a few days after stopping the anticoagulant medication may come back elevated because not enough time has elapsed to allow the anticoagulant effects of the medication to resolve. The benefits of the procedure must be weighed against the potential sequelae of stopping the anticoagulant medication and this should be discussed thoroughly with the patient.

10. Preoperative laboratory

Before the procedure, a complete blood count and a clean-catch urinalysis are obtained to check for any undiagnosed infections. An elevated white count and/or a positive urinalysis should prompt the physician to postpone the procedure and refer the patient to the primary care physician for further workup and treatment. In addition, history of bleeding, abnormalities a prothrombin time, partial thromboplastin time, and platelet function assay or bleeding time, are obtained to check for coagulation abnormalities. Any elevated value warrants further investigation and postponement of the procedure until those studies are complete.

11. Technique

This procedure can be performed in the cervical, thoracic, lumbar, and caudal regions of the spine. The caudal and transforaminal placement of catheters will be described in detail, whereas highlights and slight changes in protocol will be provided for cervical and thoracic catheters. Our policy is to perform this procedure under strict sterile conditions in the operating room. Prophylactic antibiotics with broad neuraxial coverage are given before the procedure. Patients will receive either ceftriaxone 1 g intravenously or Levaquin 500 mg orally in those allergic to penicillin. The same dose is also given on day 2. An anesthesiologist or nurse anesthetist provides monitored anesthesia care.

12. Caudal approach

The patient is placed in the prone position with a pillow placed under the abdomen to correct the lumbar lordosis and a pillow under the ankles for patient comfort. The patient is asked to put his or her toes together and heels apart. This relaxes the gluteal muscles and

facilitates identification of the sacral hiatus. After sterile preparation and draping, the sacral hiatus is identified via palpation just caudal to the sacral cornu or with fluoroscopic guidance. A skin wheal is raised with local anesthetic 1-inch lateral and 2 inches caudal to the sacral hiatus on the side opposite the documented radiculopathy. A distal subcutaneous approach theoretically provides some protection from meningitis, as a local skin infection would be much preferred over infection closer to the caudal epidural space. The skin is nicked with an 18-gauge cutting needle, and a 15- or 16-gauge RX Coudé (Epimed International) epidural needle is inserted through the nick at a 45-degree angle and guided fluoroscopically or by palpation to the sacral hiatus (Figs. 3 and 4).

When the needle is through the hiatus, the angle of the needle is dropped to approximately 30 degrees and advanced. The advantages of the RX Coudé needle over other needles are the angled tip, which enables easier direction of the catheter, and the tip of the needle is less sharp. The back edge of the distal opening of the needle is designed to be a noncutting surface that allows manipulation of the catheter in and out of the needle. A Touhy needle has the back edge of the distal opening, which is a cutting surface and can more easily shear a catheter. A properly placed needle will be inside the caudal canal below the level of the S3 foramen on anteroposterior (AP) and later fluoroscopic images. A needle placed above the level of the S3 foramen could potentially puncture a low-lying dura. The needle tip should cross the midline of the sacrum toward the side of the radiculopathy.

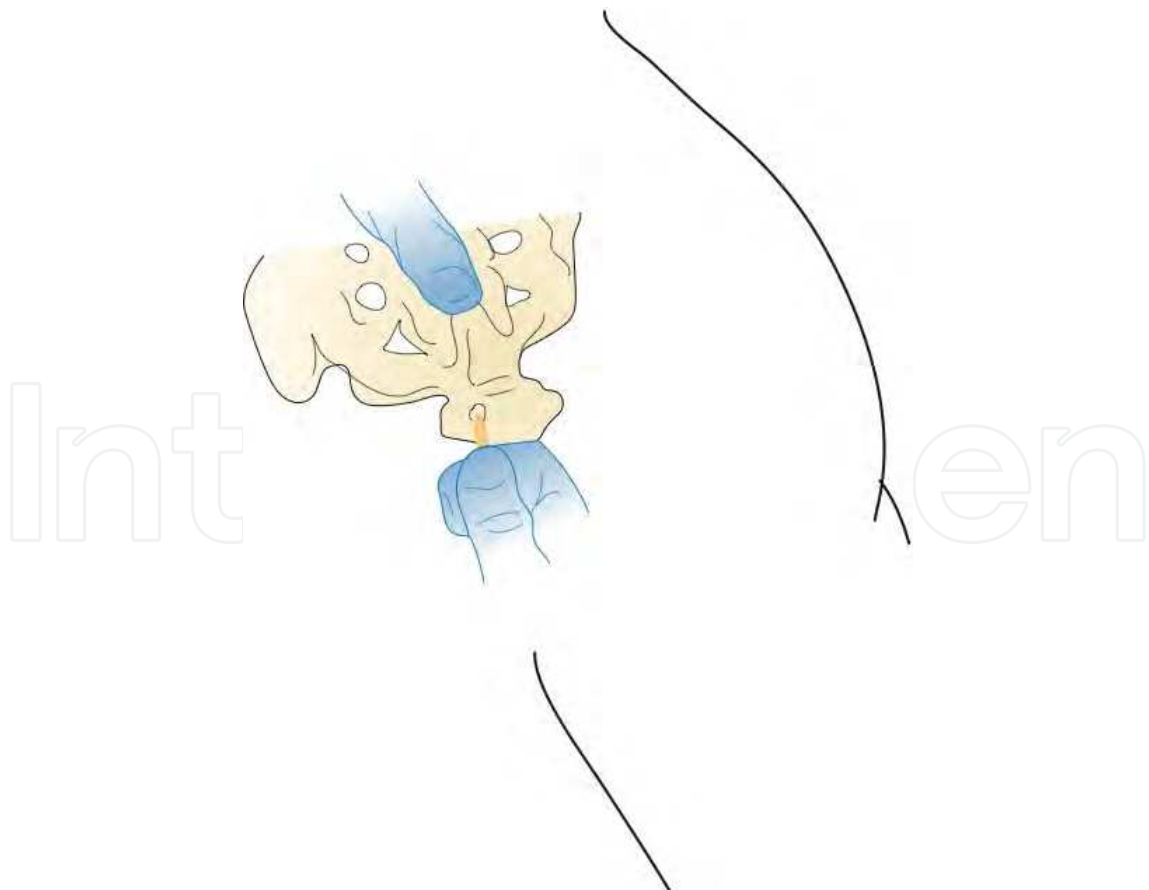


Fig. 3. Caudal lysis sequence – first find sacral hiatus and tip of coccyx.

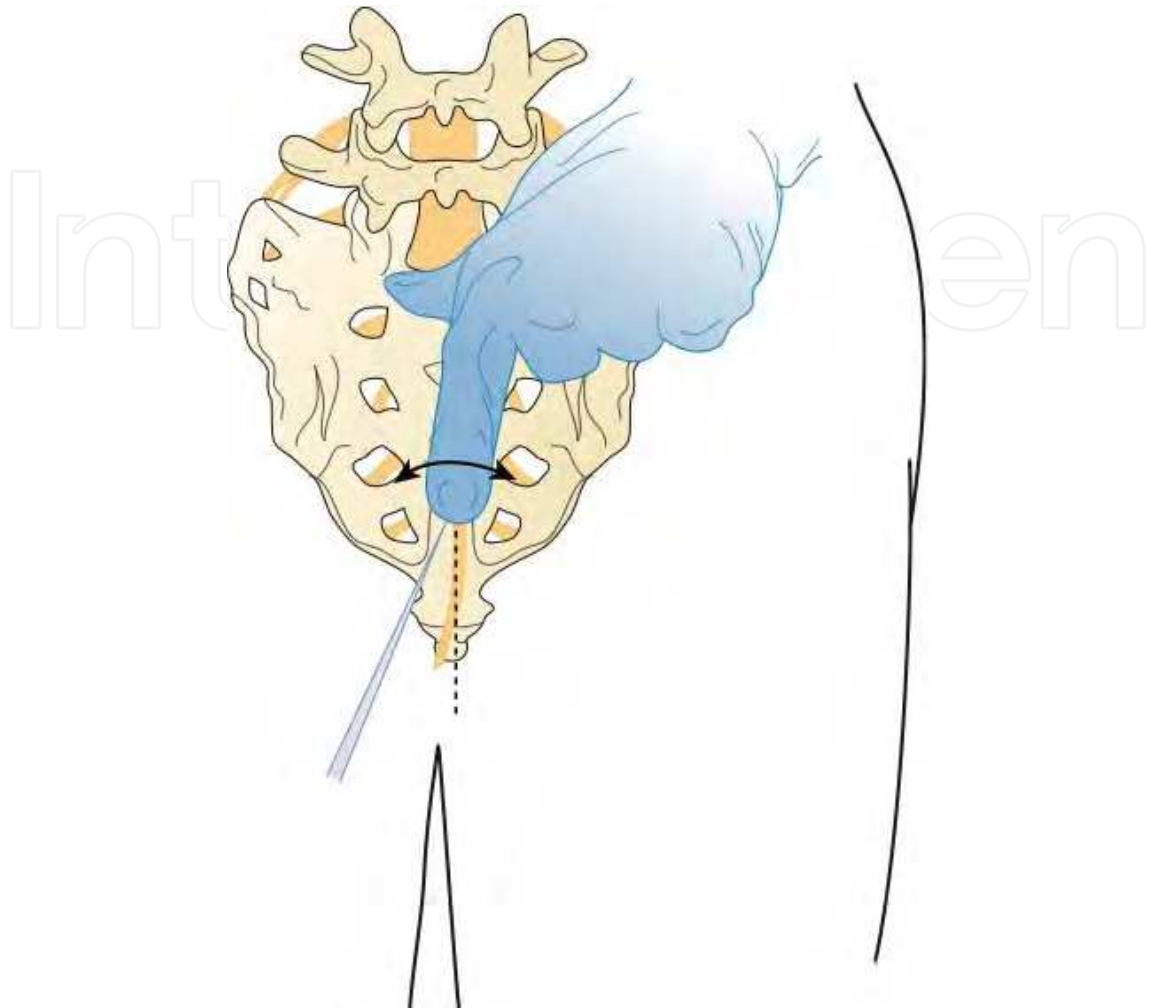


Fig. 4. Roll palpating index finger to identify the sacral cornu and thus the target sacral hiatus.

An epidurogram is performed using 10 mL of a non-ionic, water-soluble contrast agent. Confirm a negative aspiration for blood or cerebrospinal fluid before any injection of the contrast or medication. Omnipaque and Isovue are the two agents most frequently used and are suitable for myelography.^{29, 30} Do not use ionic, water-insoluble agents such as Hypopaque or Renografin or ionic, water-soluble agents such as Conray.^{31,32} These agents are not indicated for myelography. Accidental subarachnoid injections can lead to serious untoward events such as seizure and possibly death. Slowly inject the contrast agent and observe for filling defects. A normal epidurogram will have a “Christmas tree” pattern with the central canal being the trunk and the outline of the nerve roots making up the branches. An abnormal epidurogram will have areas where the contrast does not fill (Fig. 5). These are the areas of presumed scarring and typically correspond to the patient's radicular complaints. If vascular uptake is observed, the needle needs to be redirected.

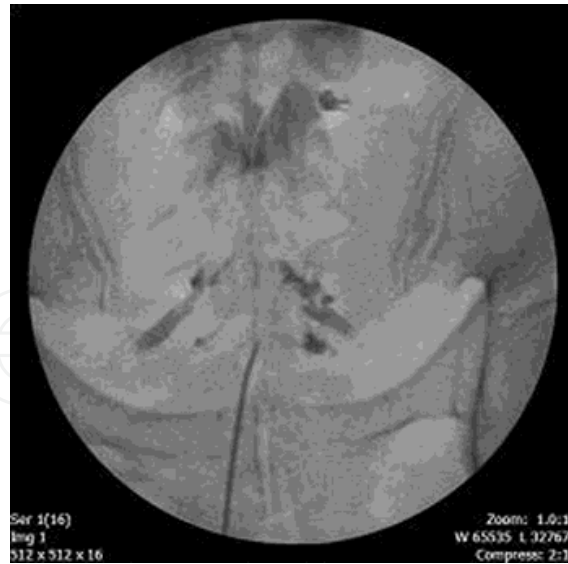

Fig. 5. Initial dye injection Omnipaque 240 (10 mL) showing sacral S3 runoff and filling defects at S2, S1, and right L5

After turning the distal opening of the needle ventral lateral, insert a TunL Kath or TunL-XL (stiffer) catheter (Epimed International) with a bend on the distal tip through the needle (Figs. 6 and 7). The bend should be 2.5 cm from the tip of the catheter and at a 30-degree angle. The bend will enable the catheter to be steered to the target level (Fig 8). Under continuous AP fluoroscopic guidance, advance the tip of the catheter toward the ventral-lateral epidural space of the desired level. The catheter can be steered by gently twisting the catheter in a clockwise or counterclockwise direction. Avoid “propellering” the tip (i.e., twisting the tip in circles) because this makes it more difficult to direct the catheter. Do not advance the catheter up the middle of the sacrum because this makes guiding the catheter to the ventral-lateral epidural space more difficult. Ideal location of the tip of the catheter in the AP projection is in the foramen just below the midportion of the pedicle shadow (Figs 9 and 10). Check a lateral projection to confirm that the catheter tip is in the ventral epidural space.

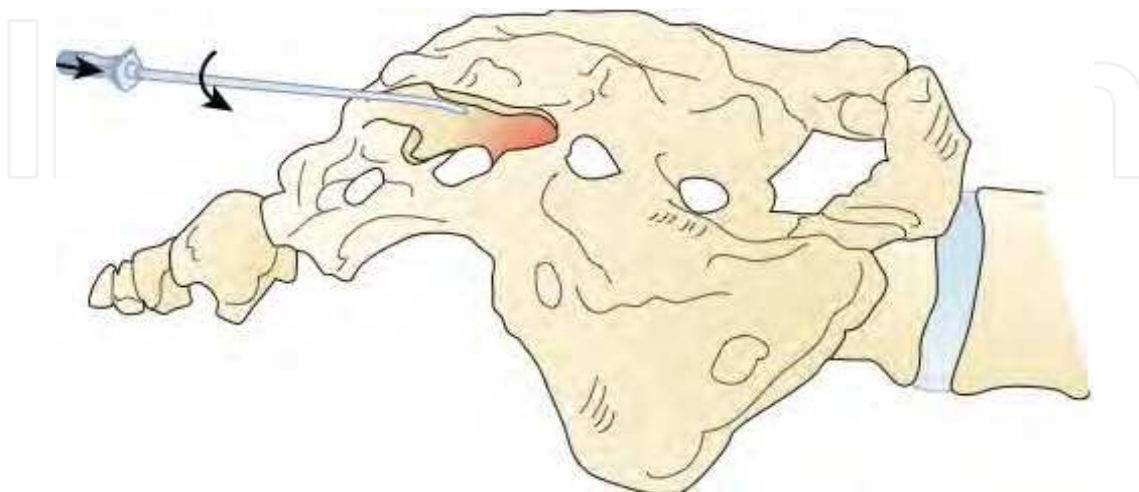


Fig. 6. The needle is placed through the sacral hiatus into the sacral canal and rotated in the direction of the target. Do not advance beyond the S3 foramen.




Fig. 7. The Epimed Racz catheter is marked for the location of the bend, or use the thumb as reference for the 15-degree angle bend

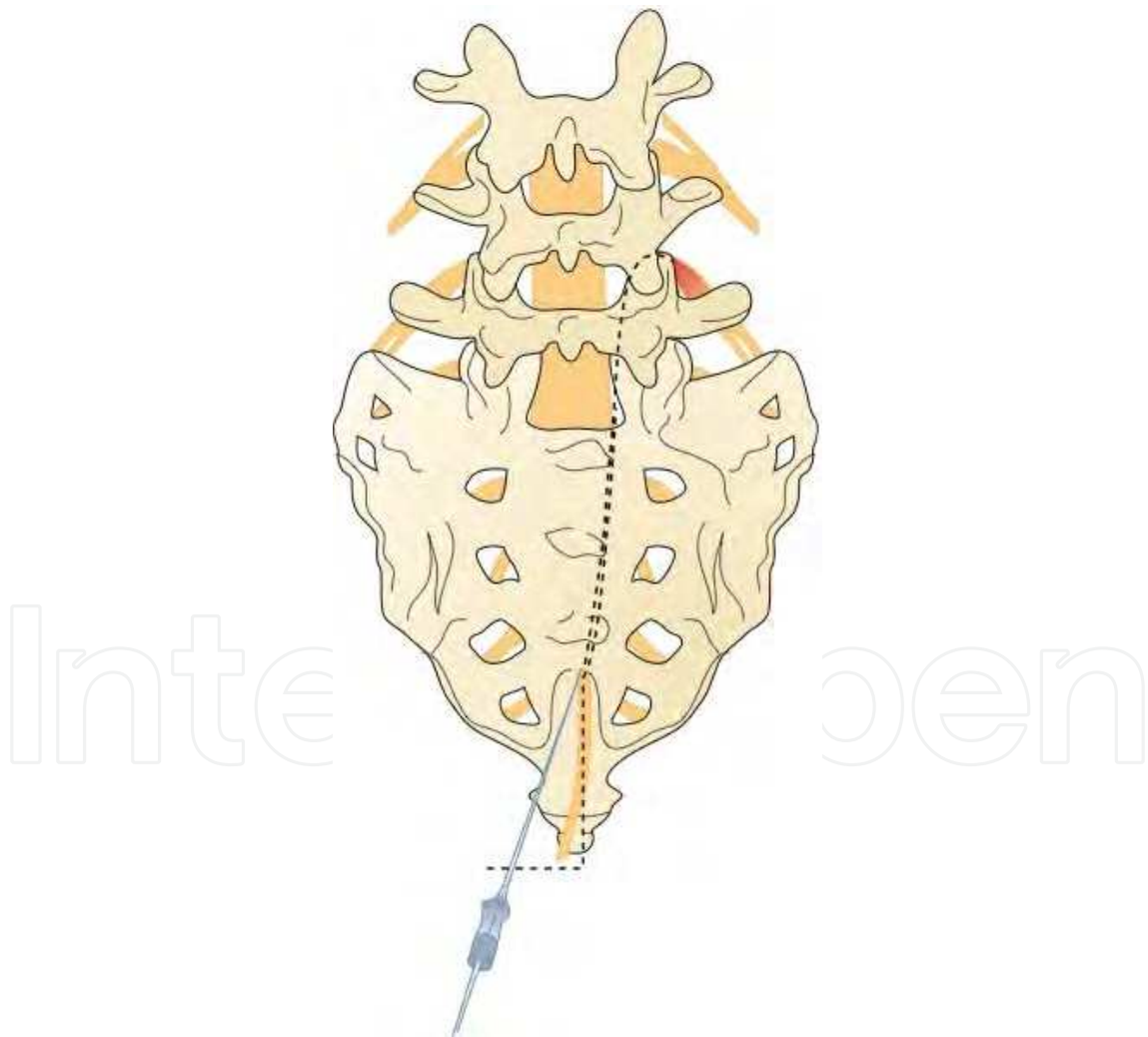


Fig. 8. The direction of the catheter is just near the midline; direct the curve under continuous fluoroscopic guidance to the ventral lateral target site. The needle rotation, as well as the catheter navigation, may need to be used to reach the target

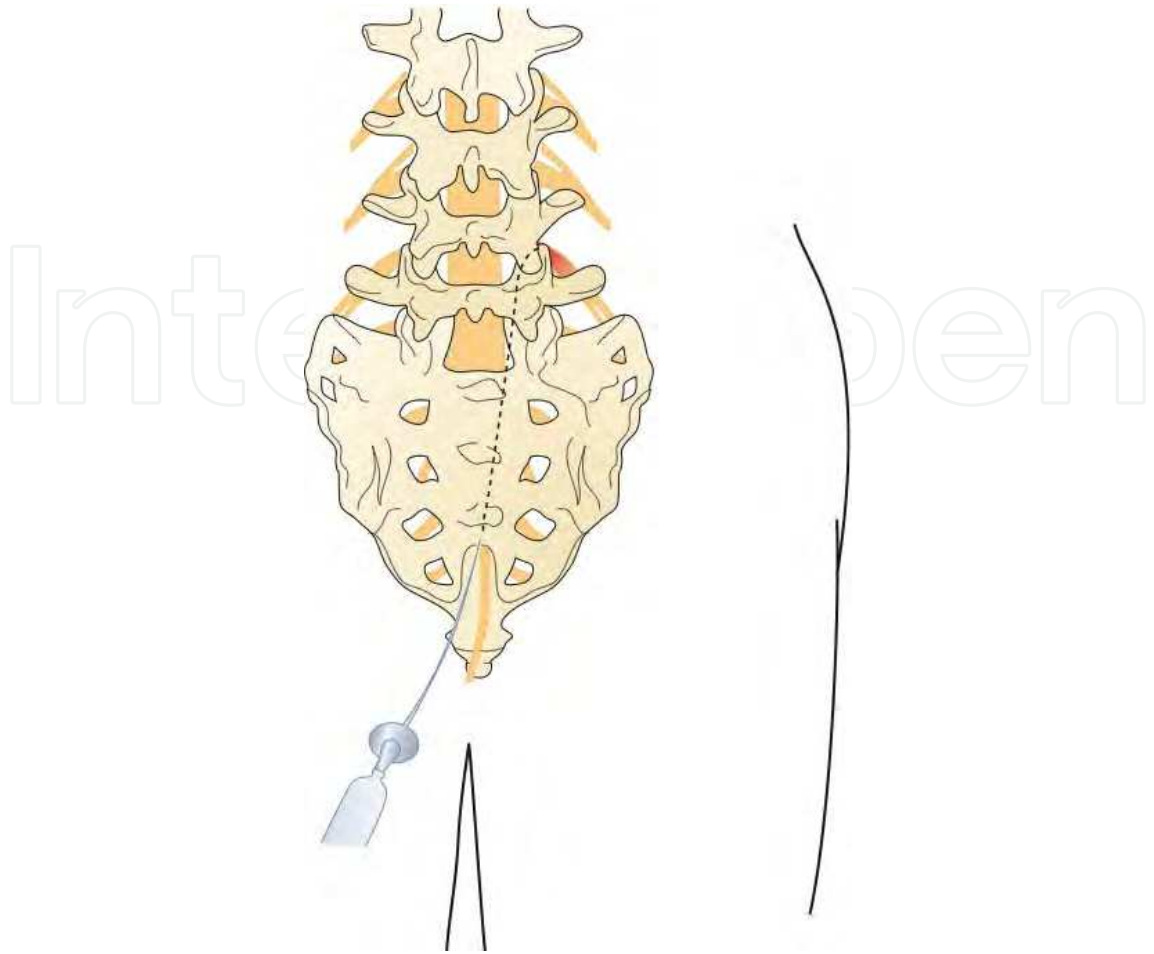


Fig. 9. The needle is removed, and the catheter is placed in the ventral lateral epidural space ventral to the nerve root

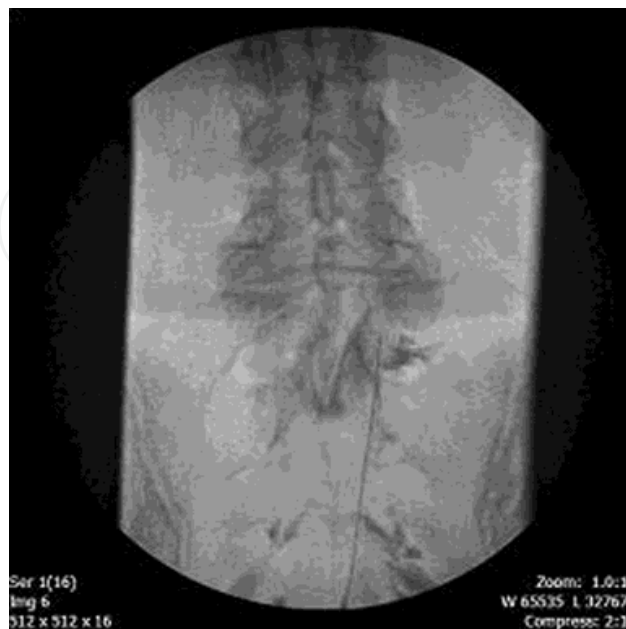

Fig. 10. Catheter (24xL) is threaded to lateral L5 neural foramen

Under real-time fluoroscopy, inject 2 to 3 mL of additional contrast through the catheter in an attempt to outline the “scarred in” nerve root (Fig 11). If vascular uptake is noted, reposition the catheter and reinject contrast. Preferably there should not be vascular runoff, but infrequently secondary to venous congestion, an epidural pattern is seen with a small amount of vascular spread. This is acceptable as long as the vascular uptake is venous in nature and not arterial. Extra caution should be taken when injecting the local anesthetic to prevent local anesthetic toxicity. Toxicity is volume and dose related and so far there has not been any reported complications from small volume venous spread. Any arterial spread of contrast always warrants repositioning of the catheter. We have never observed intra-arterial placement in 25 years of placing soft, spring-tipped catheters.

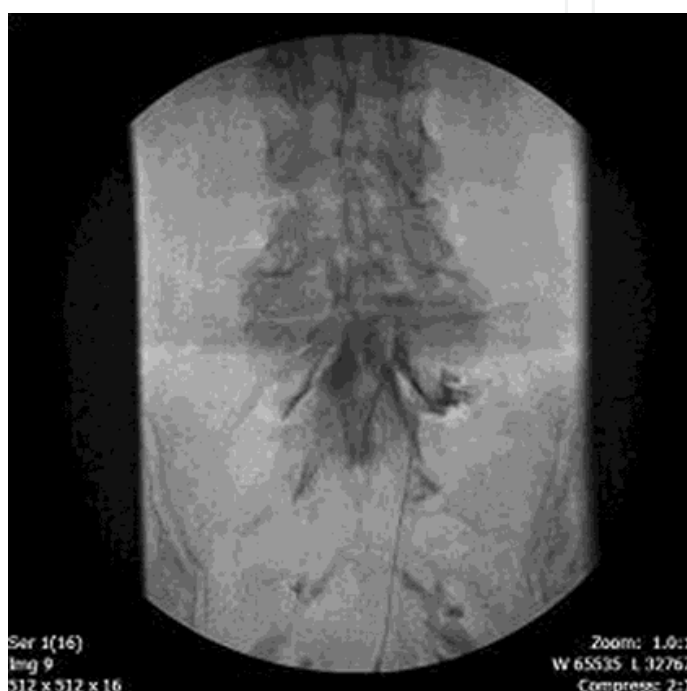

Fig. 11. Contrast injection Omnipaque 240, additional 5 mL opening right L5, S1, S2, and S3 perineural spaces; also left L5, S1, S2, and S3 in addition to right L4 spread in cephalad direction

Inject 1500 U of hyaluronidase dissolved in 10 mL of preservative-free normal saline. A newer development is the use of Hylanex or human-recombinant hyaluronidase, which carries the advantage of a reportedly increased effectiveness at the body's normal pH compared to bovine-recombinant hyaluronidase.³³ This injection may cause some discomfort, so a slow injection is preferable. Observe for “opening up” (i.e. visualization) of the “scarred in” nerve root (Figs 12 and 13 ; see also Fig. 11). A 3 mL test dose of a 10 mL local anesthetic/steroid (LA/S) solution is then given. Our institution used 4 mg of dexamethasone mixed with 9 mL of 0.2% ropivacaine. Ropivacaine is used instead of bupivacaine for two reasons: the former produces a preferential sensory versus a motor block, and it is less cardiotoxic than a racemic bupivacaine. Doses for other corticosteroids commonly used are 40 to 80 mg of methylprednisolone (Depo-Medrol), 25 to 50 mg of triamcinolone diacetate (Aristocort), 40 to 80 mg of triamcinolone acetonide (Kenalog), and 6 to 12 mg of betamethasone (Celestone Solu span). If, after 5 minutes, there is no evidence of intrathecal or intravascular injection of medication, inject the remaining 7 mL of the LA/S solution.

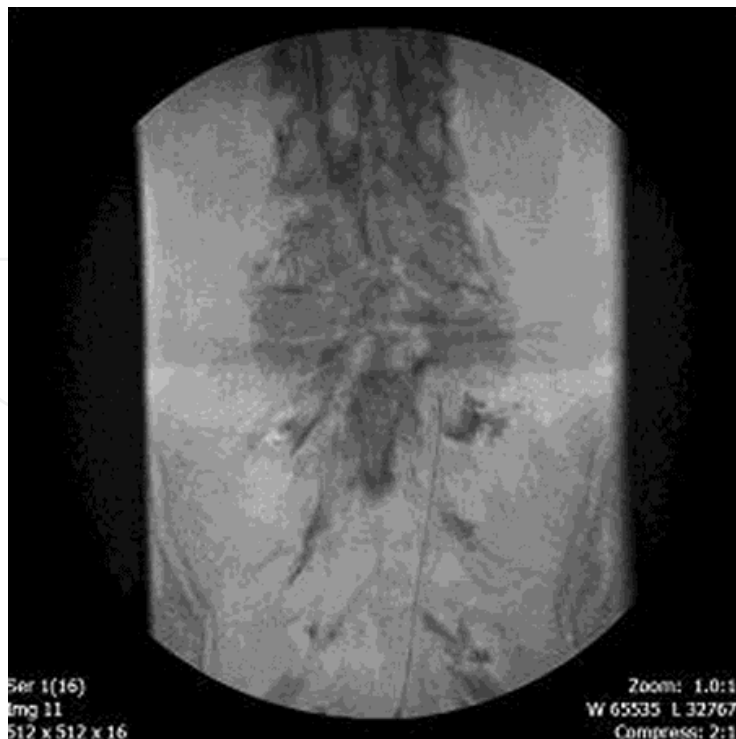

Fig. 12. Additional contrast and hyaluronidase injection opens up bilaterally formerly scarred areas. The Christmas tree appearance is obvious.

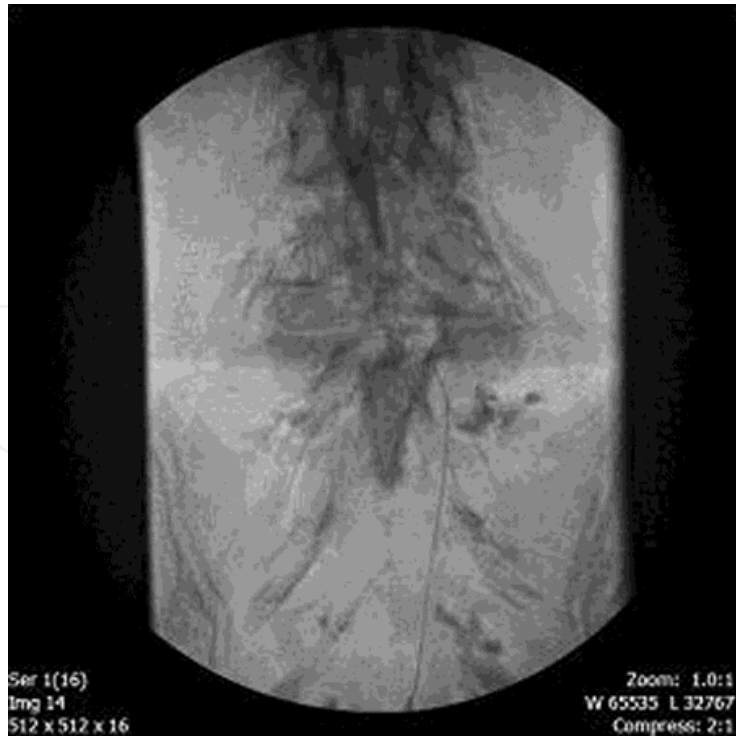


Fig. 13. Catheter advances to the desired symptomatic level of right L5 in the ventral lateral epidural space. Injection of contrast followed by 10 mL hyaluronidase 1,500 units opens up bilaterally L3-5, S1, S2, and S3 neural foramina.

Remove the needle under continuous fluoroscopic guidance to ensure the catheter remains at the target level (Fig 14). Secure the catheter to the skin using nonabsorbable suture and coat the skin puncture site with antimicrobial ointment. Apply a sterile dressing and attach a 0.2 μ m filter to the end of the catheter. Affix the exposed portion of the catheter to the patient with tape and transport the patient to the recovery area.

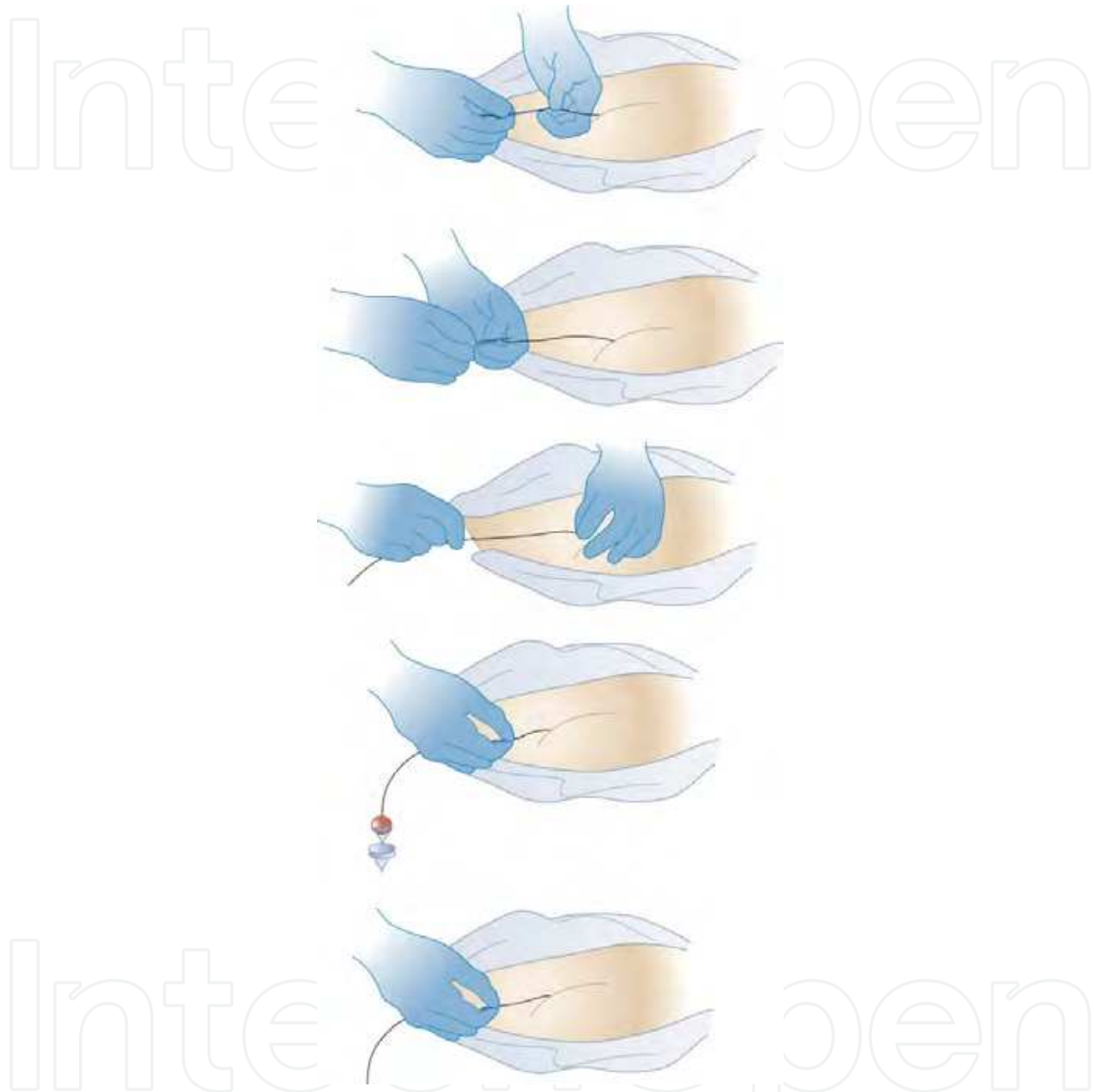


Fig. 14. Five picture sequence of removal of the needle to prevent dislodging the catheter from target site before suturing and application of dressing.

A 20- to 30-minute period should elapse between the last injection of the LA/S solution and the start of the hypertonic saline (10%) infusion. This is necessary to ensure that a subdural injection of the LA/S solution has not occurred. A subdural block mimics a subarachnoid block but it takes longer to establish, usually 16 to 18 minutes. Evidence for subdural or subarachnoid spread is the development of motor block. If the patient develops a subarachnoid or subdural block at any point during the procedure, the catheter should be removed and the remainder of the adhesiolysis canceled. The patient needs to be observed to document the resolution of the motor and sensory block and to document that 10 mL of

the hypertonic saline is then infused through the catheter over 15 to 30 minutes. If the patient complains of discomfort, the infusion is stopped and an additional 2 to 3 mL of 0.2% ropivacaine is injected and the infusion is restarted. Alternatively, 50 to 75 μ g of fentanyl can be injected epidurally in lieu of the local anesthetic. After completion of the hypertonic saline infusion, the catheter is slowly flushed with 2 mL of preservative-free normal saline and the catheter is capped.

Our policy is to admit the patient for 24-hour observation status and do a second and a third hypertonic saline infusion the following day. On post-catheter insertion day 2, the catheter is twice injected (separated by 4- to 6-hour increments) with 10 mL of 0.2% ropivacaine without steroid and infused with 10 mL of hypertonic saline (10%) using the same technique and precautions as the day 1 infusion. At the end of the third infusion, the catheter is removed and a sterile dressing applied. The patient is discharged home with 5 days of oral cephalexin at 500 mg twice a day or oral levofloxacin (Levaquin) at 500 mg once a day for penicillin-allergic patients. Clinic follow-up is in 30 days.

13. Transforaminal catheters

Patients with an additional level of radiculopathy or those in whom the target level cannot be reached by the caudal approach may require placement of a second catheter. The second catheter is placed into the ventral epidural space via a transforaminal approach.

After the target level is identified with an AP fluoroscopic image, the superior endplate of the vertebra that comprises the caudal portion of the foramina is “squared,” that is, the anterior and posterior shadows of the vertebral endplate are superimposed. The angle is typically 15 to 20 degrees in a caudocephalad direction. The fluoroscope is then oblique approximately 15 degrees to the side of the radiculopathy and adjusted until the spinous process is rotated to the opposite side. This fluoroscope positioning allows the best visualization of the superior articular process (SAP) that forms the inferoposterior portion of the targeted foramen. The image of the SAP should be superimposed on the shadow of the disk space on the oblique view. The tip of the SAP is the target for the needle placement (Fig 15). Raise a skin wheal slightly lateral to the shadow of the tip of the SAP. Pierce the skin with an 18-gauge needle and then insert a 15- or 16-gauge RX Coudé needle and advance using gun-barrel technique toward the tip of the SAP. Continue to advance the needle medially toward the SAP until the tip contacts bone. Rotate the tip of the needle 180 degrees laterally and advance about 5 mm (Fig 16). Rotate the needle back medially 180 degrees (Fig 17).

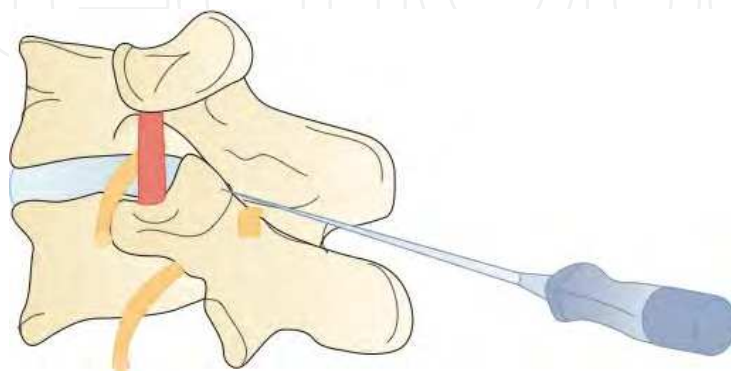


Fig. 15. Transforaminal lateral-oblique view. Target the SAP with the advancing RX Coude needle.

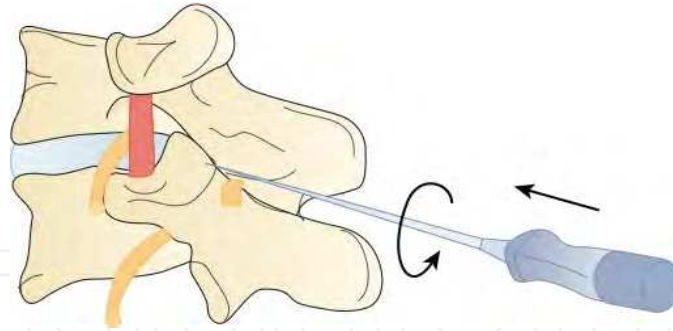


Fig. 16. Following bony contact with SAP. Lateral rotation of 180 degrees to allow passage toward the target.

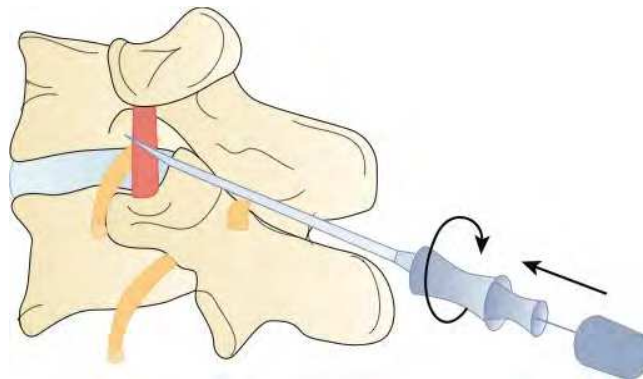


Fig. 17. Note the intertransverse ligament. The needle tip with the RX Coude 2 that has 1 mm protruding blunt stylet will pass through the ligament and will be less likely to damage the nerve.

As the needle is advanced slowly, a clear “pop” is felt as the needle penetrates the intertransverse ligament. Obtain a lateral fluoroscopic image. The tip of the needle should be just past the SAP in the posterior foramen. In the AP plane, the tip of the needle under continuous AP fluoroscopy, insert the catheter slowly into the foramen and advance until the tip should be just short of the middle of the spinal canal (Fig 18 to 20).

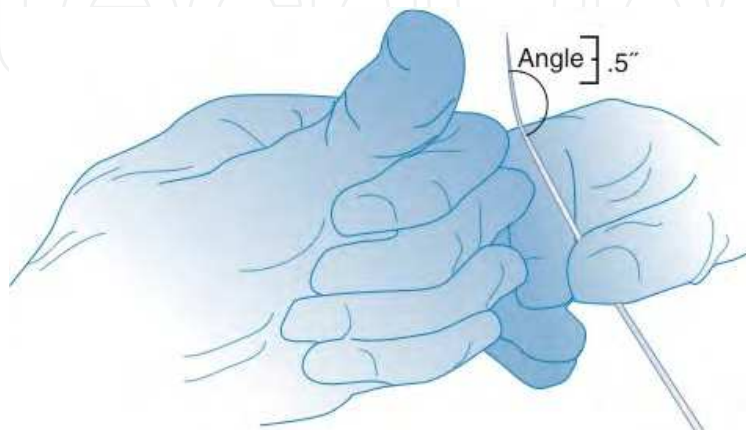


Fig. 18. The distal tip of the catheter may be bent 15-degrees, 3/4 inch length.

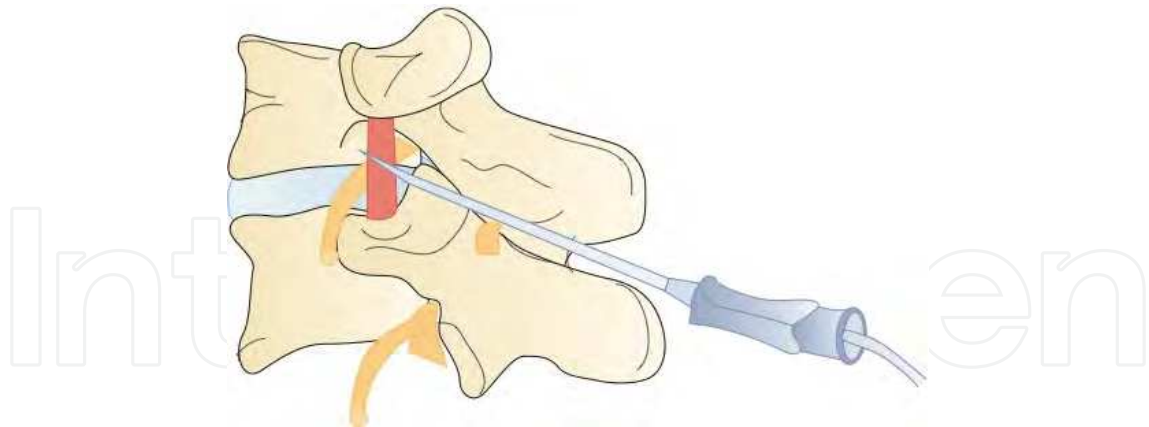


Fig. 19. Once the intertransverse ligament is perforated, the catheter is steered to the ventral lateral epidural space (lateral view).

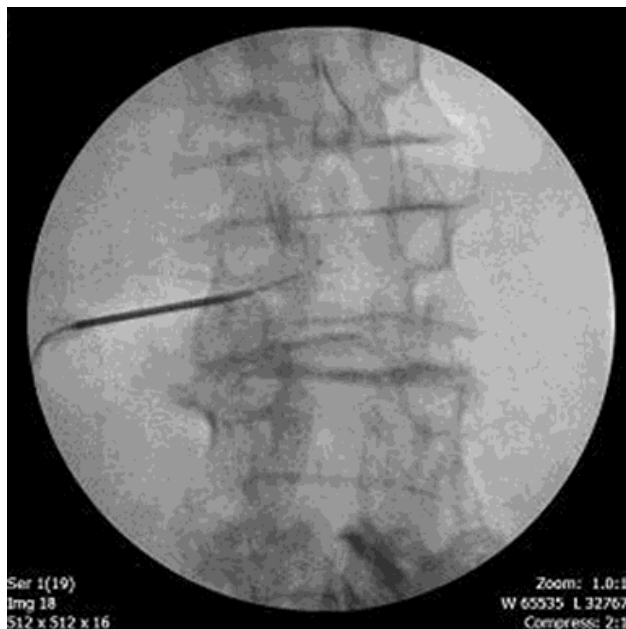

Fig. 20. Transforaminal 15-gauge RX-Coude 2 (Epimed International, Johnstown, NY) catheter at left L3-4 threaded almost to near *midcanal* position (anteroposterior view).

Confirm that the catheter is in the anterior epidural space with a lateral image (Fig 21). Anatomically, the catheter is in the foramen above or below the exiting nerve root (Fig 22). If the catheter cannot be advanced, it usually means the needle is either too posterior or too lateral to the foramen. It can also indicate that the foramen is too stenotic to allow passage of the catheter. The needle can be advanced a few millimeters anteriorly in relation to the foramen, and that will also move it slightly medial into the foramen. If the catheter still will not pass, the initial insertion of the needle will need to be more lateral. Therefore the fluoroscope angle will be about 20 degrees instead of 15 degrees. The curve of the needle usually facilitates easy catheter placement. The final position of the catheter tip is just short of the midline.

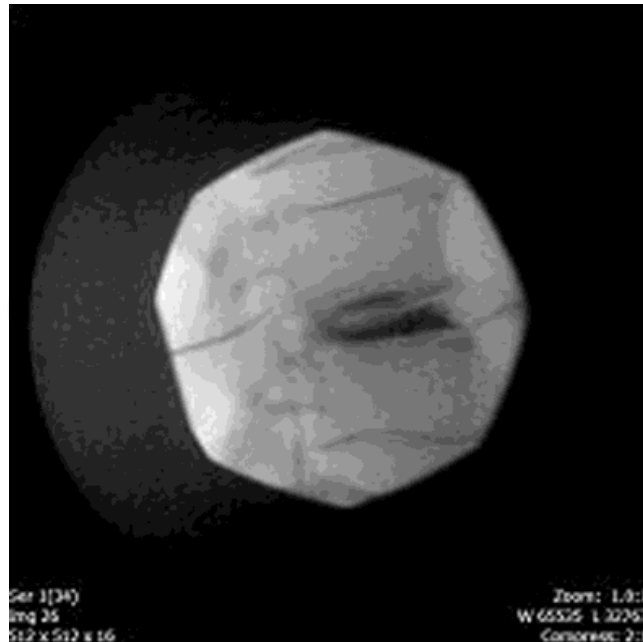


Fig. 21. Lateral view of Fig. 169-13 . Transforaminal-ventral-anterior catheter dye spread to epidural and L3-4 intradiscal area (through annular tear).

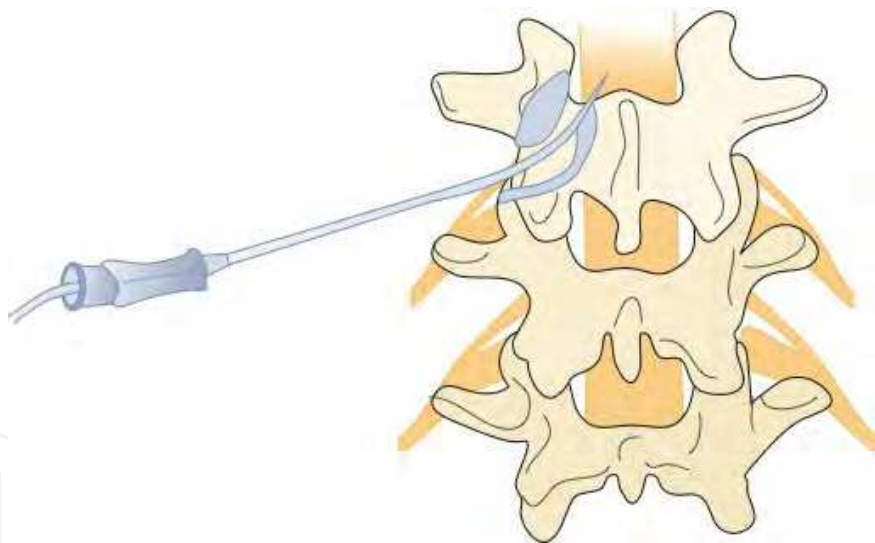


Fig. 22. Anteroposterior view. The catheter is in optimal position near midline via the transforaminal placement.

Inject 1 to 2 mL of contrast to confirm epidural spread. When a caudal and a transforaminal catheter are placed, the 1500 U of hyaluronidase are divided evenly between the two catheters (5 mL of the hyaluronidase/saline solution into each). The LA/S solution is also divided evenly, but a volume of 15 mL (1 mL steroid and 14 mL 0.2% ropivacaine; of the total volume, 5 mL is transforaminal and 10 mL is caudal) is used instead of 10 mL. Remove the needle under fluoroscopic guidance to make sure the catheter does not move from the original position in the epidural space. Secure and cover the catheter as described previously. The hypertonic saline solution is infused at a volume of 4 to 5 mL per

transforaminal and 8 to 10 mL per caudal catheter over 30 minutes. The hypertonic saline injection volume should always be less than or equal to the local anesthetic volume injected to avoid pain from injection. It behooves the practitioner to check the position of the transforaminal catheter under fluoroscopy before performing the second and third infusions. The catheter may advance across the epidural space into the contralateral foramen or paraspinous muscles or more commonly back out of the epidural space into the ipsilateral paraspinous muscles.

This results in deposition of the medication in the paravertebral tissue rather than in the epidural space. As with the caudal approach, remove the transforaminal catheter after the third infusion. A recent development is the R-X Coude 2 needle in which a second protruding stylet may allow closer needle placement and less chance of nerve injury.

14. Cervical lysis of adhesions

The success of the caudal approach for lysis of adhesions led to the application of the same technique to the cervical epidural space. The indications and preprocedure workup are the same as those for the caudal lysis technique, but there are a few differences in technique and volumes of medication used.

The epidural space should be entered via the upper thoracic interspaces using a paramedian approach on the contralateral side. The most common levels are T1-2 and T2-3. Entry at these levels allows for a sufficient length of the catheter to remain in the epidural space after the target level has been reached. If the target is the lower cervical nerve roots, a more caudal interspace should be selected. We place the patient in the left lateral decubitus position, but use a prone approach in larger patients.

A technique referred to as the “3-D technique” is used to facilitate entry into the epidural space. The “3-D” stands for *direction*, *depth*, and *direction*. Using an AP fluoroscopic image, the initial *direction* of the 15- or 16-gauge RX Coudé needle is determined. Using a modified paramedian approach with the skin entry one and a half levels below the target interlaminar space, advance and direct the needle toward the midpoint of the chosen interlaminar space with the opening of the needle pointing medial. Once the needle engages the deeper tissue planes (usually at 2 to 3 cm), check the depth of the needle with a lateral image. Advance the needle toward the epidural space and check repeat images to confirm the *depth*. The posterior border of the dorsal epidural space can be visualized by identifying the junction of the base of the spinous process of the vertebra with its lamina. This junction creates a distinct radiopaque “straight line.” Once the needle is close to the epidural space, obtain an AP fluoroscopic image to recheck the *direction* of the needle. If the tip of the needle has crossed the midline as defined by the spinous processes of the vertebral bodies, pull the needle back and redirect. The “3-D” process can be repeated as many times as is necessary to get the needle into the perfect position.

Using loss-of-resistance technique, advance the needle into the epidural space with the tip of the RX-Coudé needle, pointed caudally. Once the tip is in the epidural space, rotate the tip cephalad, and inject 1 to 2 mL of contrast to confirm entry. Rotation or movement of any needle in the epidural space can cut the dura. This technique has been improved with the advent of the RX Coudé 2 needle, which has a second interlocking stylet that protrudes slightly beyond the tip of the needle and functions to push the dura away from the needle tip as it is turned 180 degrees cephalad (Fig. 23 A-E).

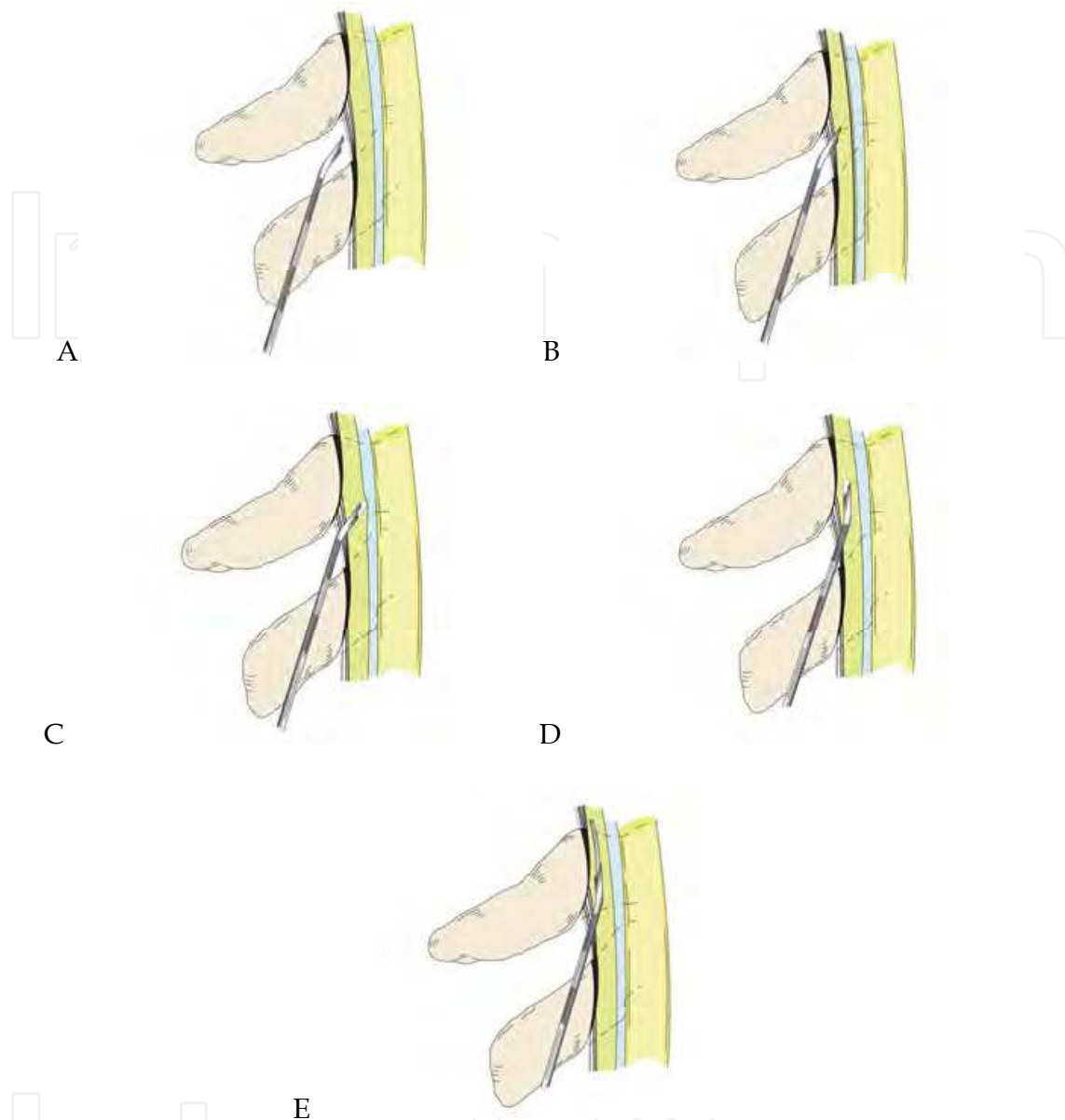


Fig. 23. Sequence of stages to place a catheter using the R-X Coude. **A** and **B**. The needle is inserted into the epidural space with the tip directed as shown. **C**. The protruding stylet is inserted. **D**. Then the needle is rotated so the tip is parallel to the dura. **E**. The catheter is inserted.

Inject an additional small volume as needed to complete the epidurogram. If there is no free flow of injected contrast, pressure may build up in the lateral epidural space. Characteristic fluid spread by the path of least resistance can be recognized as *perivenous counter spread* (PVCS). Presence of PVCS means pressure builds up in the lateral epidural space that is unable to spread laterally to decompress. The dye spread picks the path of least resistance to the opposite side. Pressure may build up and lead to ischemic spinal cord injury. Flexion and rotation of the head and neck can open up lateral runoff and release the pressure through the enlarged neural foramina (Fig 24)³⁴

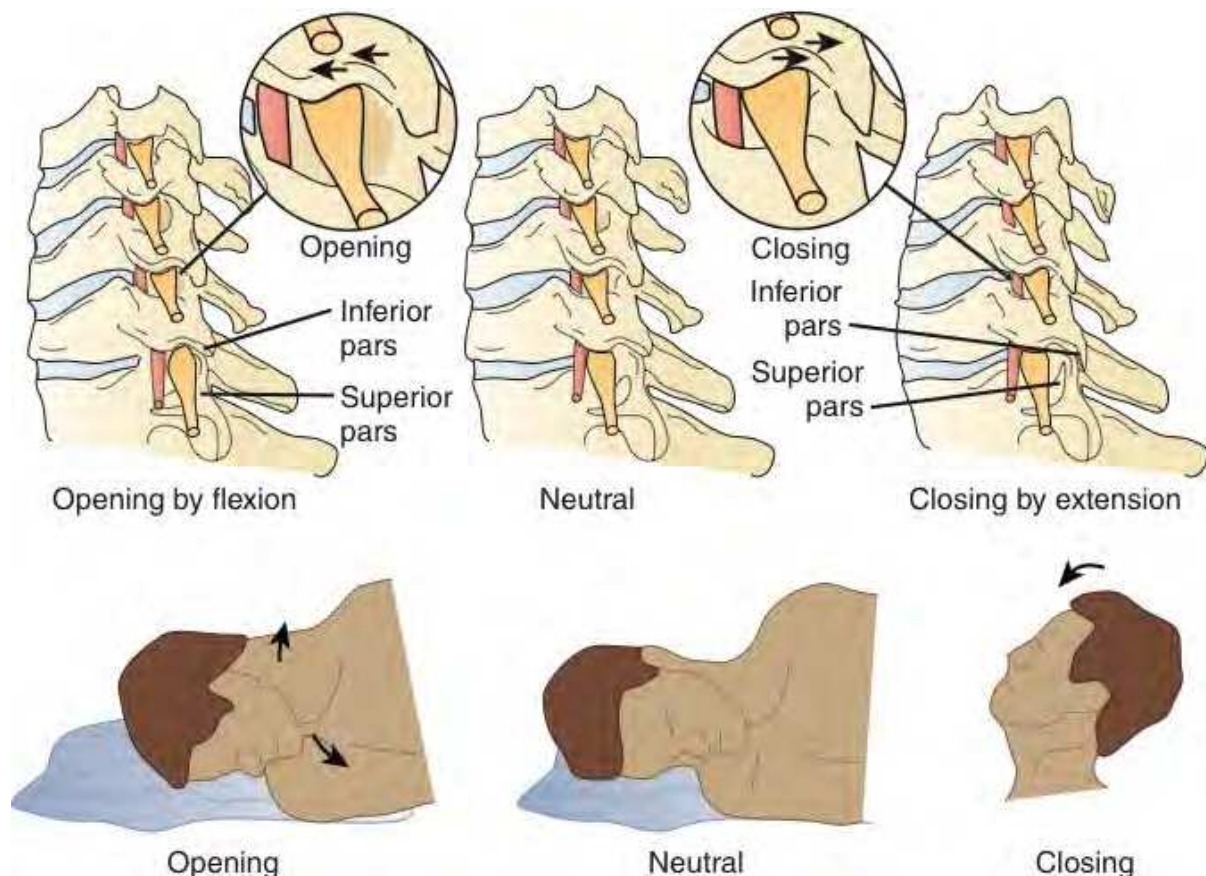


Fig. 24. Flexion rotation, left to right regardless patient position. The neural foramen enlarges on flexion rotation and gets smaller with extension. The inferior pars slides forward over the superior pars to enlarge the foramen. This allows lateral run off and pressure release with PVCS.

As with the caudal epidurogram, look for filling defects. It is extremely important to visualize spread of the contrast in the cephalad and caudal directions. Loculation of contrast in a small area must be avoided as this can significantly increase the pressure in the epidural space and can compromise the already tenuous arterial blood supply to the spinal cord. Place a bend on the catheter as previously described for the caudal approach and insert it through the needle (Fig 23E). The opening of the needle should be directed toward the target side. Slowly advance the catheter to the lateral gutter and direct it cephalad. Redirect the catheter as needed and once the target level has been reached, turn the tip of the catheter toward the foramen (Fig 25A). Inject 0.5 to 1 mL of contrast to visualize the target nerve root. Make sure there is runoff of contrast out of the foramen (Fig 25B). Slowly instill 150 U of Hylanex dissolved in 5 mL of preservative-free normal saline. Follow this with 1 to 2 mL of additional contrast and observe for "opening up" of the "scarred in" nerve root. Give a 2 mL test dose of a 6 mL solution of LA/S. Our combination is 5 mL of 0.2% ropivacaine and 4 mg of dexamethasone. If after 5 minutes there is no evidence of intrathecal or intravascular spread, inject the remaining 4 mL. Remove the needle, and secure and dress the catheter as previously described. Once 20 minutes have passed since the last dose of LA/S solution and there is no evidence of a subarachnoid or subdural block, start an infusion of 5 mL of hypertonic saline over 30

minutes. At the end of the infusion, flush the catheter with 1 to 2 mL of preservative-free normal saline and cap the catheter.

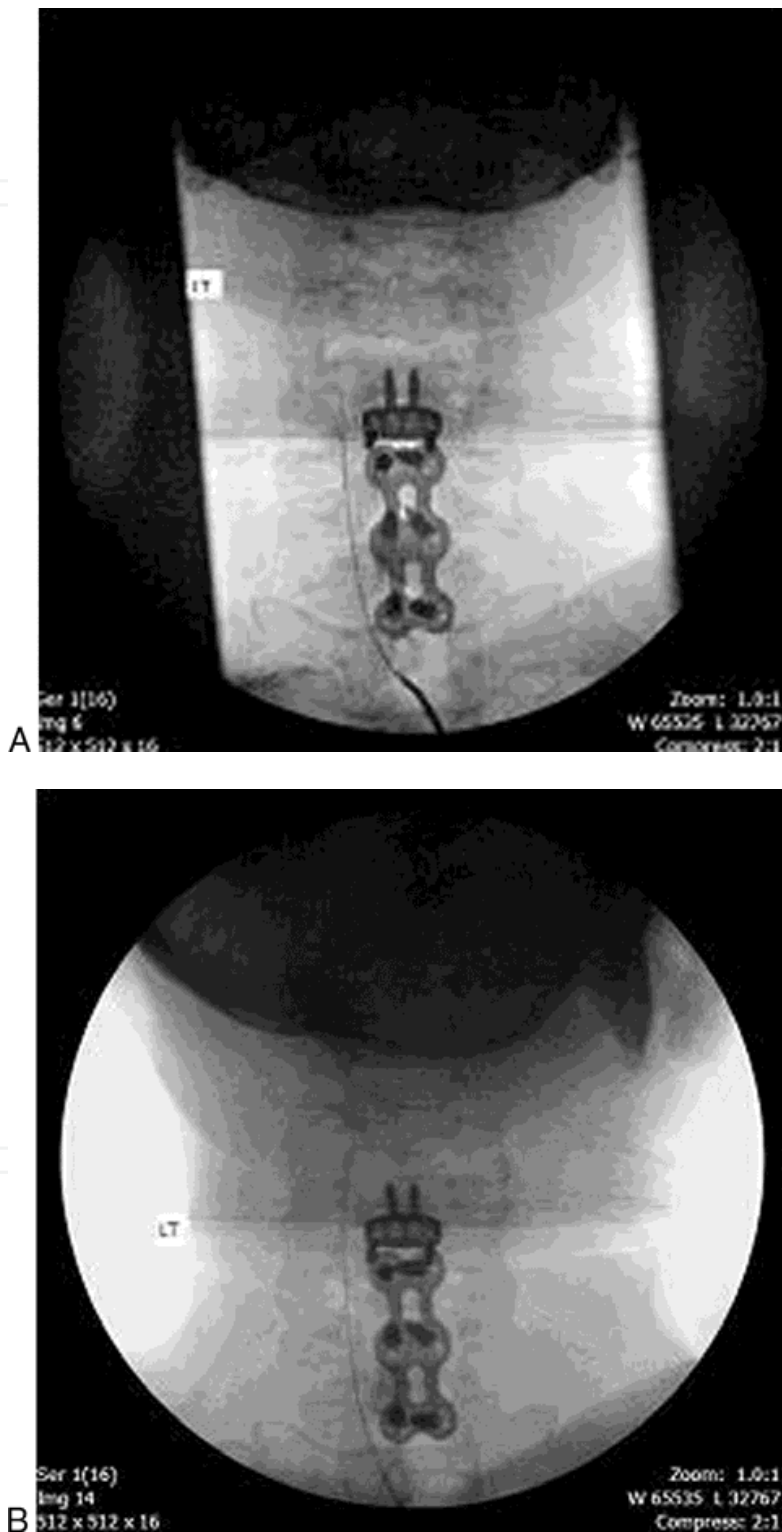


Fig. 25. A & B. **A** Cervical left ventral lateral catheter to the upper level of fusion C5-7. **B** Cervical-left ventral lateral catheter threaded to above level of fusion of C4. The dye injection spreads cephalad and lateral.

The second and third infusions are performed on the next day with 6 mL of 0.2% ropivacaine without spread and 5 mL of hypertonic saline using the same technique and precautions described for the first infusion. The catheter is removed and prophylactic antibiotics are prescribed. Clinic follow-up is 30 days.

15. Thoracic lysis of adhesions

The technique for entry into the thoracic epidural space for adhesiolysis is identical to that for the cervical region. Always remember the 3-D technique. Make sure to get a true lateral when checking the depth of the needle. This can be obtained by superimposing the rib shadows on one another. The target is still the ventrolateral epidural space with the tip of the catheter in the foramen of the desired level. The major difference for thoracic lysis compared to the caudal and cervical techniques is the volumes of the various injectates. Volumes of 8 mL are used for the contrast, Hylenex, LA/S, and hypertonic saline. (Table 1) lists typical infusion volumes for epidural adhesiolysis.

| | Contrast | Hyaluronidase and Normal Saline | Local Anesthetic and Steroid | 10% Hypertonic Saline Infusion |
|---------------------------|-----------------------|---------------------------------|------------------------------|---|
| Caudal | 10 mL | 10 mL | 10 mL | 10 mL |
| Caudal and transforaminal | 5 mL in each catheter | 5 mL in each catheter | 5 mL in each catheter | 8 mL in caudal catheter and 4 mL in transforaminal catheter |
| Thoracic | 8 mL | 8 mL | 8 mL | 8 mL |
| Cervical | 5 mL | 6 mL | 6 mL | 5 mL |

Table 1. Typical Infusion Volumes for Epidural Adhesiolysis

16. Neural flossing

The protocol for epidural adhesiolysis has been aided by neural flossing exercises that were designed to mobilize nerve roots by “sliding” them in and out of the foramen (Fig 26). This breaks up weakened scar tissue from the procedure and prevents further scar tissue deposition. If these exercises are done effectively three to four times per day for a few months after the procedure, the formation of scar tissue will be severely restricted.

In patients with multilevel radiculopathy and complex pain, it can be difficult to determine from where the majority of the pain is emanating. We have been using a technique that we have termed *mapping* to locate the most painful nerve root with stimulation and then carry out the adhesiolysis at that level. There are several references in the literature regarding the use of stimulation to confirm epidural placement of a catheter and for nerve root

localization.³⁵ The TunL Kath and the TunL-XL catheter can be used as stimulating catheters to identify the nerve root(s).

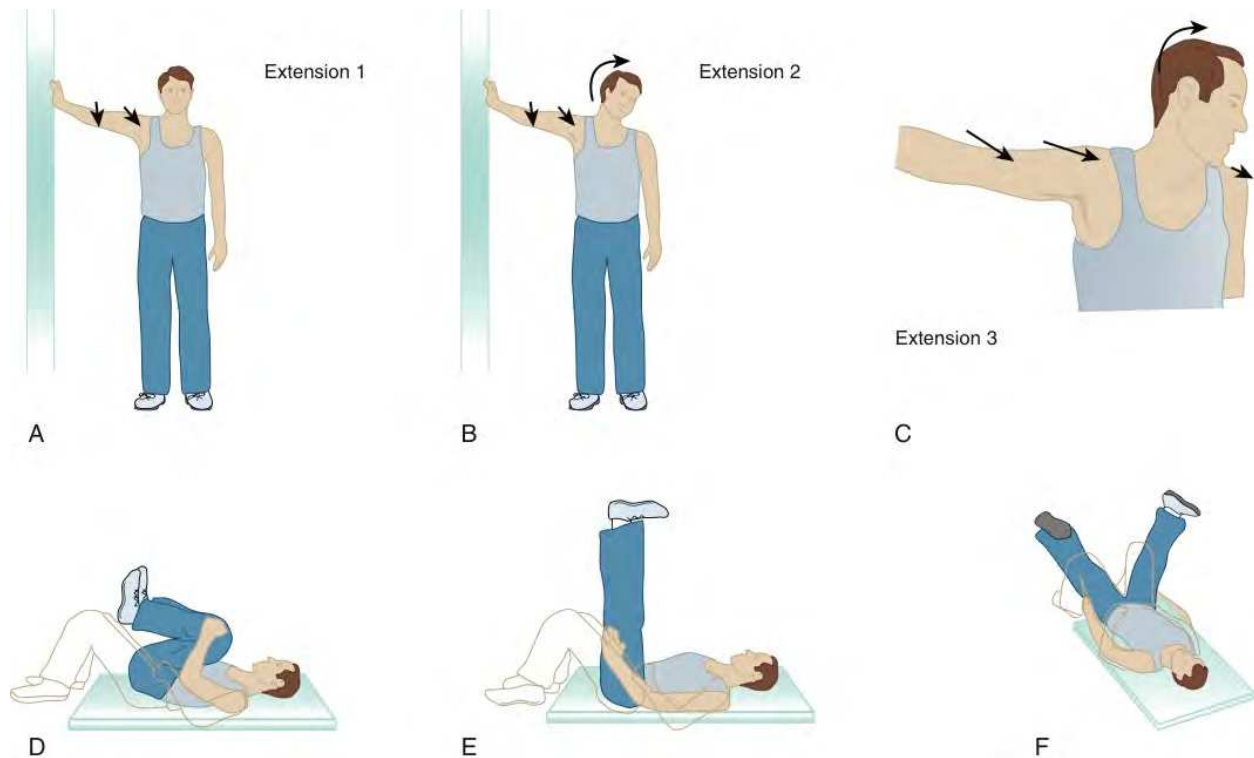


Fig. 26. **A-F Neural flossing exercises.** **A**, Standing erect, firmly grasp a stable surface (e.g., a door frame) with outstretched arm. Press elbow and shoulder forward. **B**, Next, slowly tilt head in opposite direction from outstretched arm to achieve gentle tension. **C**, Finally, rotate chin toward opposite shoulder as is comfortable. Hold this final position for approximately 20 to 30 seconds. **D**, Lay down supine on an exercise mat without a pillow. Slowly bring both knees close to the chest with bent legs and hold this position for 20 seconds. Release and assume a neutral position. **E**, Again in supine position, raise both legs to 90 degrees, with knees straight while laying flat on a firm surface. Hold for 20 seconds. Assume a neutral position and rest briefly. **F**, Bring both legs to a 90-degree angle while lying supine. Slowly spread legs in a V shape, as much as is comfortable, and hold for 20 seconds. **Epidural Mapping**

After entering the epidural space, advance the catheter into the ventrolateral epidural space past the suspected target level. Make sure the tip of the catheter is pointing laterally toward the foramina, just below the pedicle. Pull the catheter stylet back approximately 1 cm. Using alligator clips, attach the cathode to the stylet and ground the anode on the needle or ground pad or a 22-gauge needle inserted into the skin. Apply electrical stimulation with a stimulator box with a rate of 50 pulses per second and a pulse width of 450 milliseconds, dialing up the amplitude until a paresthesia is perceived in small increments, usually less than 2 or 3 volts. Inquire of the patient as to whether or not the paresthesia is felt in the area of the patient's recognized greatest pain. This process is repeated at each successive level until the most painful nerve root is identified. Once

identified, the adhesiolysis is carried out at that level. The mapping procedure is also useful to identify the optimal site of surgery either before the first surgery or when surgery has failed one or more times.

17. Complications

As with any invasive procedure, complications are possible. These include bleeding, infection, headache, damage to nerves or blood vessels, catheter shearing, bowel/bladder dysfunction, paralysis, spinal cord compression from loculation of the injected fluids or hematoma, subdural or subarachnoid injection of local anesthetic or hypertonic saline, and reactions to the medications used. We also include on the consent form that the patient may experience an increase in pain or no pain relief at all. Although the potential list of complications is long, the frequency of complications is very rare. However, there is clearly a learning curve, and recent studies reflect this by the significantly improved long-term outcome and the very rare publications of complications and medicolegal consequences when one considers the ever-increasing clinical experience.

Subdural spread is a complication that should always be watched for when injecting local anesthetic. During the caudal adhesiolysis, particularly if the catheter is advanced along the midline, subdural catheter placement is a risk (Figs 27 and 28). Identification of the subdural motor block should occur within 16 to 18 minutes. Catheters used for adhesiolysis should never be directed midline in the epidural space.

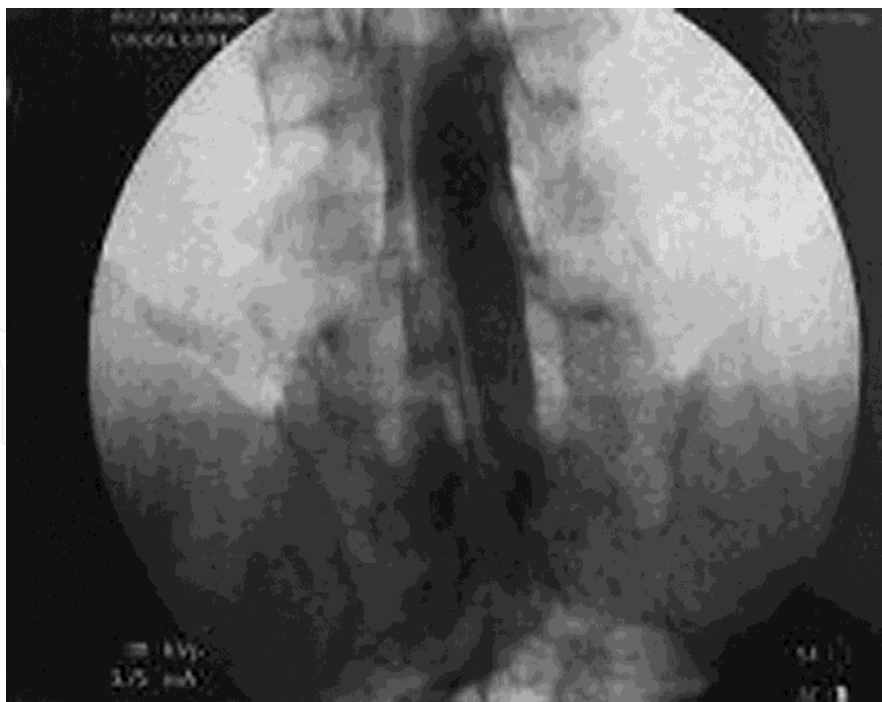

Fig. 27. Midline catheter placement enters subdural space. There is also some epidural dye spread. But the patient starts to complain of bilateral leg pain.

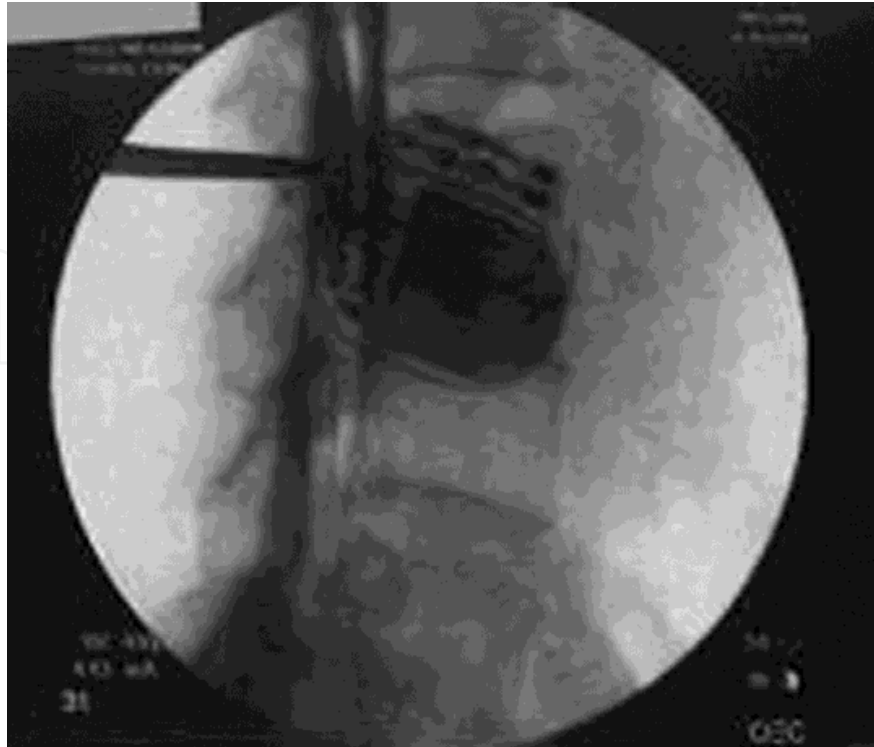

Fig. 28. A 22-gauge spinal needle and extension set with syringe placed in the subdural space and 12 mL fluid aspirated. The patient reported immediate reversal of bilateral leg pain. Note the dye in the extension tubing and syringe at the 7-o'clock position.

18. Outcomes

Initially in the early 1980s the protocol was designed to direct site-specific medication onto the dorsal root ganglion; however, after performing a number of the procedures, it was found that the dorsal root ganglion was exceptionally hard to reach secondary to developing scar tissue or adhesions. In the early days, our understanding was coming from the use of local anesthetics for surgery giving a 2- to 4-hour block for the surgeon to operate. It was gratifying to see chronic pain patients get months and years of pain relief following the placement of the new steerable x-ray visible catheter. The early report in 1985 by Racz et al³⁶ described the use of phenol at the dorsal root ganglion followed by an observational listing of outcomes that were clearly not as good as the latest studies on failed back surgery and spinal stenosis showing 75% to 80% improvement at 12 months' follow-up by Manchikanti.³⁴ Initially we were pleased to see some patients getting 3 to 4 months of relief and report seeing recovery of footdrops. This philosophy still proves to be true even in studies in 2008 by Sakai et al³⁷ in which they found that adhesiolysis with catheter-directed steroid and local anesthetic injection during epiduroscopy alleviated pain and reduced sensory nerve dysfunction in patients with chronic sciatica. The evolution of these findings has changed the process into what it is today.³⁸ Racz and Holubec first reported on epidural adhesiolysis in 1989.³⁹ There were slight variations in the protocol compared to today's protocol, namely the dose of local anesthetic and the fact that hyaluronidase was not used. Catheter placement was lesion-specific (i.e., the tip of the catheter was placed in the foramen corresponding to the vertebral level and side of the suspected adhesions). The retrospective

analysis conducted 6 to 12 months after the procedure reported initial pain relief in 72.2% of patients ($N = 72$) at time of discharge. Relief was sustained in 37.5% and 30.5% of patients at 1 and 3 months, respectively. Forty-three percent decreased their frequency and dosage of medication use and 16.7% discontinued their medications altogether. In total, 30.6% of patients returned to work or returned to daily functions. In April 1990, at a presentation of the 7th IASP World Congress on Pain in Adelaide, Australia, Arthur et al⁴⁰ reported on epidural adhesiolysis in 100 patients, 50 of whom received hyaluronidase as part of the procedure. In the hyaluronidase group, 81.6% of the participants had initial pain relief, with 12.3% having persistent relief; 68% of the no hyaluronidase group had relief of pain, with 14% having persistent relief at the end of the 3-year follow-up period from which the study sample was randomly selected.

In 1994 Stolker et al⁴¹ added hyaluronidase to the procedure, but omitted the hypertonic saline. In a study of 28 patients, they reported greater than 50% pain reduction in 64% of patients at 1 year. They stressed the importance of the patient selection and believed that the effectiveness of adhesiolysis was based on the effect of the hyaluronidase on the adhesions and the action of the local anesthetic and steroids on the sinuvertebral nerve.

Devulder et al⁴² published a study of 34 patients with failed back surgery syndrome in whom epidural fibrosis was suspected or proved with MRI.⁴² An epidural catheter was inserted via the sacral hiatus to a distance of 10 cm into the caudal canal. Injections of contrast dye, local anesthetic, corticosteroid, and hypertonic saline (10%) were carried out daily for 3 days. No hyaluronidase was used. Filling defects were noted in 30 of 34 patients, but significant pain relief was noted in only 7 patients at 1 month, 2 patients at 3 months, and no patients at 12 months. They concluded that epidurography may confirm epidural filling defects for contrast dye in patients with filling defects, but a better contrast dye spread, assuming scar lysis does not guarantee sustained pain relief. This study was criticized for lack of lesion-specific catheter placement resulting in nonspecific drug delivery.⁴³ The catheter was never directed to the ventral lateral epidural space where the dorsal root ganglion is located and the lateral recess scarring occurs.

Heavner et al⁴⁴ performed a prospective randomized trial of lesion-specific epidural adhesiolysis on 59 patients with chronic intractable low back pain. The patients were assigned to one of four epidural adhesiolysis treatment groups: (1) hypertonic (10%) saline plus hyaluronidase, (2) hypertonic saline, (3) isotonic (0.9%) saline, or (4) isotonic saline plus hyaluronidase. All treatment groups received corticosteroid and local anesthetic. Overall, across all four treatment groups, 83% of patients had significant pain relief at 1 month compared to 49% at 3 months, 43% at 6 months, and 49% at 12 months. The hyaluronidase and the hypertonic saline study group had a much lower incidence of additional need for pain procedures than the placebo groups, showing that site-specific catheter placement is important. Active substances and preservative free normal saline were blinded for the placebo effect.

Manchikanti et al⁴⁵ performed a retrospective randomized evaluation of a modified Racz adhesiolysis protocol in 232 patients with low back pain. The study involved lesion specific catheter placement, but the usual 3-day procedure was reduced to a 2-day (group 1) or a 1-day (group 2) procedure. Group 1 had 103 patients and group 2 had 129 patients. Other changes included changing the local anesthetic from bupivacaine to lidocaine, substituting methylprednisolone acetate or betamethasone acetate and phosphate for triamcinolone diacetate, and reduction of the volume of injectate. Of the patients in groups 1 and 2, 62% and 58% had greater than 50% pain relief at 1 month, respectively, with these percentages

decreasing to 22% and 11% at 3 months, 8% and 7% at 6 months, and 2% and 3% at 1 year. Of significant interest is that the percentage of patients receiving greater than 50% pain relief after four procedures increased to 79% and 90% at 1 month, 50% and 36% at 3 months, 29% and 19% at 6 months, and 7% and 8% at 1 year for groups 1 and 2, respectively. Short-term relief of pain was demonstrated, but long-term relief was not.

Manchikanti, in 1999, evaluated two groups of randomly pulled, 150 patients for a 2-day reinjection procedure, and a second 150 patients for a one-day procedure out of a pool of 536 patients. It was concluded that repeat use of the one-day procedure is also cost effective when evaluated on a 12-month follow-up. The cost effectiveness indicated the lysis procedure to be superior to surgery or the rehabilitation activity program.⁴⁵

In a randomized, prospective study, Manchikanti et al⁴⁶ evaluated a 1-day epidural adhesiolysis procedure against a control group of patients who received conservative therapy. Results showed that cumulative relief, defined as relief greater than 50% with one to three injections, in the treatment group was 97% at 3 months, 93% at 6 months, and 47% at 1 year. The study also showed that overall health status improved significantly in the adhesiolysis group. Conservative therapy consisted of physical therapy and medications.

In 2004 Manchikanti et al⁴⁷ published their results of a randomized, double-blind, controlled study on the effectiveness of 1-day lumbar adhesiolysis and hypertonic saline neurolysis in treatment of chronic low back pain. Seventy-five patients whose pain was unresponsive to conservative modalities were randomized into one of three treatment groups. Group 1 (control group) underwent catheterization where the catheter was in the sacral canal without adhesiolysis, followed by injection of local anesthetic, normal saline, and steroid. Group 2 consisted of catheterization with site-specific catheter placement being ventral-lateral for adhesiolysis, followed by injection of local anesthetic, normal saline, and steroid. Group 3 consisted of site-specific catheter placement for adhesiolysis, followed by injection of local anesthetic, hypertonic saline, and steroid. Patients were allowed to have additional injections based on the response, either after unblinding or without unblinding after 3 months. Patients without unblinding were offered either the assigned treatment or another treatment based on their response. If the patients in group 1 or 2 received adhesiolysis and injection and injection of hypertonic saline, they were considered withdrawn, and no subsequent data were collected. Outcomes were assessed at 3, 6, and 12 months using visual analog scale pain scores, Oswestry Disability Index, opioid intake, range-of-motion measurement, and P-3. Significant pain relief was defined as average relief of 50% or greater. Seventy-two percent of patients in group 3, 60% of patients in group 2, and 0% of patients in group 1 showed significant pain relief at 12 months. The average number of treatments for 1 year was 2.76 in group 2 and 2.16 in group 3. Duration of significant relief with the first procedure was $2.8 + 1.49$ months and $3.8 + 3.37$ months in groups 2 and 3, respectively. Significant pain relief (>50%) was also associated with improvement in Oswestry Disability Index, range of motion, and psychologic status.

Manchikanti et al^{48,49} furthered this research using comparisons of percutaneous adhesiolysis versus fluoroscopically guided caudal epidural steroid injections. The first study involved a population of patients with chronic low back pain and known spinal stenosis. The results showed a 76% reduction in pain relief at 1 year with epidural adhesiolysis compared to 4% in the control group. The second study performed in a population of patients with post-lumbar surgery syndrome showed a reduction in pain and

improvement in functional status in 73% of the epidural adhesiolysis group compared to 12% in the control group.

In 2006 a study by Veihelmann et al⁵⁰ evaluated patients with a history of chronic low back pain and sciatica. Inclusion criteria were radicular pain with a corresponding nerve root compressing substrate found on MRI or CT. All patients were randomized to receive physiotherapy, analgesics, or lysis of adhesions. The lysis group had statistically significantly better outcome than the physical therapy treatment group.

Two other prospective evaluations by Chopra et al and Gerdesmeyer et al^{51, 52} evaluated patients with monosegmental radiculopathy of the lumbar spine. All the patients suffered from chronic disk herniations or failed back syndrome. All these randomized trials showed positive short-term and long-term relief. Two prospective evaluations also showed positive short- and long-term relief.^{51,52}

19. Conclusion

Epidural adhesiolysis has evolved over the years as an important treatment option for patients with intractable cervical, thoracic, and low back and leg pain. Studies show that patients are able to experience significant pain relief and restoration of function. Manchikanti's studies show that the amount and duration of relief can be achieved by repeat procedures. Recent prospective randomized double-blind studies on failed back surgery and spinal stenosis show 75% and 80% improvement in visual analog scale scores and functional improvements at 12 months' follow-up. There have been no negative studies to date where the lysis target was the ventral-lateral epidural space. The one negative study used a 10 cm sacral mid-canal catheter placement which was non-target specific.⁴³ This negative study was subsequently used as the placebo group in a study performed by Manchikanti.⁴⁷ Manchikanti's study consisted of 3 treatment groups: placebo (sacral mid-canal catheter placement), target specific ventral-lateral epidural without hypertonic saline and target specific ventral-lateral epidural with hypertonic saline. The later two treatment groups had positive outcomes with the hypertonic saline group superior; whereas, the placebo group did not.⁴⁷ The evolution in the recognition of the site-specific importance of the catheter and medication delivery together with the fact that physicians need to acquire the skills to be able to carry out the procedure led to the improved outcomes seen in recent prospective randomized studies.

The management of failed back surgery syndrome and post laminectomy syndrome will likely continue to be controversial among the multitude of practitioners who treat these patients. However, in experienced hands, it is established as a reasonable option for many patients.

Percutaneous neuroplasty via a transforaminal approach evolved from the caudal approach. Lysis of adhesions via the caudal approach involves introducing a catheter through the sacral hiatus and advancing it to the affected nerve root in the ventral-lateral epidural space. On the other hand, transforaminal percutaneous neuroplasty achieves a midline catheter placement in the epidural space that is able to target the two most heavily innervated structures in the spine—the posterior annulus fibrosus and the posterior longitudinal ligament.⁵ Apart from a surgical approach, the ventral epidural structures have been otherwise inaccessible.

Endoscopy offers direct visualization of the affected nerve roots in addition to mechanical adhesiolysis, and may become more mainstream as the technique is refined.

Facet pain is commonly associated with the postlysis period or after provocative testing a month or so later if two-facet diagnostic blocks show efficacy. In addition to epidural lysis of adhesions, the combined use of radiofrequency facet denervation gives us the best long-term outcome.

Epidural adhesiolysis has been accepted as a treatment for post laminectomy syndrome, failed back syndrome, and cervical and thoracic radicular syndromes. Additional studies are underway to further refine the technique and indications. The combined use of long term patient education for neural flossing exercises and the inclusion of the facet delayed treatment in the algorithm further improves patient outcome. The identification of back pain provocation by saline injection and the successful use of percutaneous neuroplasty in the treatment represents hopeful promise for a cost effective treatment of back pain.

20. Acknowledgements

Racz GB, Day MR, Heavner JE, Scott J. *Lysis of Epidural Adhesions*. In: Waldman S, ed. *Pain Management, 2nd Edition*. Elsevier; 2011: 1258-1272.

Racz GB, Day MR, Heavner JE, Smith JP. The Racz Procedure: Lysis of Epidural Adhesions (Percutaneous Neuroplasty). In: Deer T, ed. *The AAPM Text of Pain Medicine*. Springer; 2011.

The authors would also like to thank Marzieh N. Brown and Paula Brashear for their assistance in the editing of this chapter.

21. References

- [1] Lawrence R., Helmick C., Arnett F., et al: Estimates of the prevalence of arthritis and selected musculoskeletal disorders in the United States. *Arthritis Rheum* 1998; 41(5):778-799.
- [2] Straus B.: Chronic pain of spinal origin: the costs of intervention. *Spine* 2002; 27(22):2614-2619.
- [3] National Center for Health Statistics : *National hospital discharge survey*, Washington, DC, US Department of Health and Human Services, Centers for Disease Control and Prevention, 1990. Report no. PB92-500818
- [4] Van Zundert J.: *Personal communication*. 2005.
- [5] Kuslich S., Ulstrom C., Michael C.: The tissue origin of low back pain and sciatica. *Orthop Clin North Am* 1991; 22:181-187.
- [6] Racz G., Noe C., Heavner J.: Selective spinal injections for lower back pain. *Curr Rev Pain* 1999; 3:333-341.
- [7] Anderson S.: A rationale for the treatment algorithm of failed back surgery syndrome. *Curr Rev Pain* 2000; 4:396-406.
- [8] Pawl R.: Arachnoiditis and epidural fibrosis: the relationship to chronic pain. *Curr Rev Pain* 1998; 2:93-99.
- [9] Cervellini P., Curri D., Volpin L., et al: Computed tomography of epidural fibrosis after discectomy: a comparison between symptomatic and asymptomatic patients. *Neurosurgery* 1988; 23(6):710-713.
- [10] Manchikanti L., Staats P., Singh V.: Evidence-based practice guidelines for interventional techniques in the management of chronic spinal pain. *Pain Phys* 2003; 6:3-81.


- [11] LaRocca H., Macnab I.: The laminectomy membrane: studies in its evolution, characteristics, effects and prophylaxis in dogs. *J Bone Joint Surg* 1974; 56(13):545-550.
- [12] Cooper R., Freemont A., Hoyland J., et al: Herniated intervertebral disc-associated periradicular fibrosis and vascular abnormalities occur without inflammatory cell infiltration. *Spine* 1995; 20:591-598.
- [13] McCarron R., Wimpee M., Hudkins P., et al: The inflammatory effects of nucleus pulposus; a possible element in the pathogenesis of low back pain. *Spine* 1987; 12:760-764.
- [14] Parke W., Watanabe R.: Adhesions of the ventral lumbar dura: an adjunct source of discogenic pain?. *Spine* 1990; 15:300-303.
- [15] Viesca C., Racz G., Day M.: Special techniques in pain management: lysis of adhesions. *Anesthesiol Clin North Am* 2003; 21:745-766.
- [16] Songer M., Ghosh L., Spencer D.: Effects of sodium hyaluronate on peridural fibrosis after lumbar laminectomy and discectomy. *Spine* 1990; 15:550-554.
- [17] Key J., Ford L.: Experimental intervertebral disc lesions. *J Bone Joint Surg Am* 1948; 30:621-630.
- [18] Olmarker K., Rydevik B.: Pathophysiology of sciatica. *Orthop Clin North Am* 1991; 22:223-233.
- [19] Ross J., Robertson J., Frederickson R., et al: Association between peridural scar and recurrent radicular pain after lumbar discectomy; magnetic resonance evaluation. *Neurosurgery* 1996; 38:855-863.
- [20] Gilbert K., Brismee J., Collins D., et al: Lumbosacral nerve roots displacements and strain: part 1. A novel measurement technique during straight leg raise in unembalmed calavers. *Spine* 2007; 32(14):1513-1520. Phila Pa 1976
- [21] Heavner JE, Chokhavatia S, Kizelshteyn G: Percutaneous evaluation of the epidural and subarachnoid space with a flexible fiberscope, *Reg Anesth* 1991;15:85.
- [22] Bosscher HA, Heavner JE: Incidence and severity of epidural fibrosis after back surgery: an endoscopic study, *Pain Pract* 2010; 10: 18-24.
- [23] Hatten Jr H.: Lumbar epidurography with metrizamide. *Radiology* 1980; 137:129-136.
- [24] Stewart H., Quinnell R., Dann N.: Epidurography in the management of sciatica. *Br J Rheumatol* 1987; 26(6):424-429.
- [25] Devulder J., Bogaert L., Castille F., et al: Relevance of epidurography and epidural adhesiolysis in chronic failed back surgery patients. *Clin J Pain* 1995; 11:147-150.
- [26] Manchikanti L., Bakhit C., Pampati V.: Role of epidurography in caudal neuroplasty. *Pain Digest* 1998; 8:277-281.
- [27] Day M., Racz G.: Technique of caudal neuroplasty. *Pain Digest* 1999; 9(4):255-257.
- [28] Horlocker T., Wedel D., Benzon H., et al: Regional anesthesia in the anticoagulated patient: defining the risks (the second ASRA Consensus Conference on Neuraxial Anesthesia and Anticoagulation). *Reg Anesth Pain Med* 2003; 28:172-197.
- [29] *Omnipaque product insert*, Princeton, NJ, Nycomed, Inc.
- [30] *Isovue product insert*, Princeton, NJ, Bracco Diagnostics, Inc.
- [31] *Hypaque product insert*, Princeton, NJ, Amersham Health, Inc.
- [32] *Conray product insert*, Phillipsburg, NJ, Mallinckrodt, Inc.
- [33] Racz G., Day M., Heavner J., et al: Hyaluronidase: a review of approved formulations, indications and off-label use in chronic pain management. *Expert Opin Biol Ther* 2010; 10(1):127-131.

- [34] Racz G.B., Heavner J.E.: Cervical spinal canal loculation and secondary ischemic cord injury – PVCS – perivenous counter spread – danger sign!!. *Pain Pract* 2008; 8:399-403.
- [35] Larkin T., Carragee E., Cohen S.: A novel technique for delivery of epidural steroids and diagnosing the level of nerve root pathology. *J Spinal Disord Tech* 2003; 16(2):186-192.
- [36] Racz G.B., Sabonghy M., Gintautas J., et al: Intractable pain therapy using a new type of epidural catheter. *JAMA* 1985; 248:579-580.
- [37] Sakai T., Aoki H., Hojo M., et al: Adhesiolysis and targeted steroid/local anesthetic injection during epiduroscopy alleviates pain and reduces sensory nerve dysfunction in patients with chronic sciatica. *J Anesth* 2008; 22(3):242-247.
- [38] Anderson S., Racz G., Heavner J.: Evolution of epidural lysis of adhesions. *Pain Physician* 2000; 3(3):262-270.
- [39] Racz G., Holubec J.: *Lysis of adhesions in the epidural space*. In: Raj P., ed. *Techniques of neurolysis*, Boston: Kluwer Academic; 1989:57-72.
- [40] Arthur J., Racz G., Heinrich R., et al: *Epidural space: identification of filling defects and lysis of adhesions in the treatment of chronic painful conditions*. Abstracts of the 7th World Congress on Pain, Paris: IASP Publications; 1993.
- [41] Stolker R., Vervest A., Gerbrand J.: The management of chronic spinal pain by blockades: a review. *Pain* 1994; 58:1-19.
- [42] Devulder J., Bogaert L., Castille F., et al: Relevance of epidurography and epidural adhesiolysis in chronic failed back surgery patients. *Clin J Pain* 1995; 11:147-150.
- [43] Racz G., Heavner J.: In response to article by Drs. Devulder et al. *Clin J Pain* 1995; 11:151-154.
- [44] Heavner J., Racz G., Raj P.: Percutaneous epidural neuroplasty: prospective evaluation of 0.9% saline versus 10% saline with or without hyaluronidase. *Reg Anesth Pain Med* 1999; 24:202-207.
- [45] Manchikanti L., Pakanati R., Bakhit C., et al: Role of adhesiolysis and hypertonic saline neurolysis in management of low back pain: evaluation of modification of the Racz protocol. *Pain Digest* 1999; 9:91-96.
- [46] Manchikanti L., Pampati V., Fellow B., et al: Role of one day epidural adhesiolysis in management of chronic low back pain: a randomized clinical trial. *Pain Phys* 2001; 4:153-166.
- [47] Manchikanti L., Rivera J., Pampati V., et al: One day lumbar adhesiolysis and hypertonic saline neurolysis in treatment of chronic low back pain: a randomized, double-blinded trial. *Pain Phys* 2004; 7:177-186.
- [48] Manchikanti L., Cash K., McManus C., et al: The preliminary results of a comparative effectiveness of adhesiolysis and caudal epidural injections in managing chronic low back pain secondary to spinal stenosis. *Pain Phys* 2009; 12(6):E341-E354.
- [49] Manchikanti L., Singh V., Cash K., et al: A comparative effectiveness evaluation of percutaneous adhesiolysis and epidural steroid injections in managing lumbar post surgery syndrome. *Pain Phys* 2009; 12(6):E355-E368.
- [50] Veihelmann A., Devens C., Trouiller H., et al: Epidural neuroplasty versus physiotherapy to relieve pain in patients with sciatica: a prospective randomized blinded clinical trial. *J Orthop Sci* 2006; 11(4):365-369.

- [51] Gerdesmeyer L., Lampe R., Veihelmann A., et al: Chronic radiculopathy: use of minimally invasive percutaneous epidural neurolysis according to Racz. *Der Schmerz* 2005; 19:285-295.
- [52] Gerdesmeyer L., Rechl H., Wagenpfeil S., et al: Minimally invasive epidural neurolysis in chronic radiculopathy: a prospective controlled study to prove effectiveness. *Der Orthopade* 2003; 32:869-876.

IntechOpen

IntechOpen



Pain Management - Current Issues and Opinions

Edited by Dr. Gabor Racz

ISBN 978-953-307-813-7

Hard cover, 554 pages

Publisher InTech

Published online 18, January, 2012

Published in print edition January, 2012

Pain Management - Current Issues and Opinions is written by international experts who cover a number of topics about current pain management problems, and gives the reader a glimpse into the future of pain treatment. Several chapters report original research, while others summarize clinical information with specific treatment options. The international mix of authors reflects the "casting of a broad net" to recruit authors on the cutting edge of their area of interest. Pain Management - Current Issues and Opinions is a must read for the up-to-date pain clinician.

How to reference

In order to correctly reference this scholarly work, feel free to copy and paste the following:

Gabor B. Racz, Miles R. Day, James E. Heavner, Jeffrey P. Smith, Jared Scott, Carl E. Noe, Laslo Nagy and Hana Ilner (2012). Epidural Lysis of Adhesions and Percutaneous Neuroplasty, Pain Management - Current Issues and Opinions, Dr. Gabor Racz (Ed.), ISBN: 978-953-307-813-7, InTech, Available from: <http://www.intechopen.com/books/pain-management-current-issues-and-opinions/epidural-lysis-of-adhesions-and-percutaneous-neuroplasty>

INTECH
open science | open minds

InTech Europe

University Campus STeP Ri
Slavka Krautzeka 83/A
51000 Rijeka, Croatia
Phone: +385 (51) 770 447
Fax: +385 (51) 686 166
www.intechopen.com

InTech China

Unit 405, Office Block, Hotel Equatorial Shanghai
No.65, Yan An Road (West), Shanghai, 200040, China
中国上海市延安西路65号上海国际贵都大饭店办公楼405单元
Phone: +86-21-62489820
Fax: +86-21-62489821

© 2012 The Author(s). Licensee IntechOpen. This is an open access article distributed under the terms of the [Creative Commons Attribution 3.0 License](#), which permits unrestricted use, distribution, and reproduction in any medium, provided the original work is properly cited.

IntechOpen

IntechOpen