

# We are IntechOpen, the world's leading publisher of Open Access books Built by scientists, for scientists

**4,800**

Open access books available

**122,000**

International authors and editors

**135M**

Downloads

Our authors are among the

**154**

Countries delivered to

**TOP 1%**

most cited scientists

**12.2%**

Contributors from top 500 universities



**WEB OF SCIENCE™**

Selection of our books indexed in the Book Citation Index  
in Web of Science™ Core Collection (BKCI)

Interested in publishing with us?  
Contact [book.department@intechopen.com](mailto:book.department@intechopen.com)

Numbers displayed above are based on latest data collected.

For more information visit [www.intechopen.com](http://www.intechopen.com)



# Detection of *Mycobacterium avium* subsp. *paratuberculosis* in Crohn's Disease Patients and Ruminants Intestine by In Situ Hybridization

Lucía C. Favila-Humara\* et al.

Laboratorio de Tuberculosis. CENID-Microbiología Animal. INIFAP. México

## 1. Introduction

*Mycobacterium avium* subsp. *paratuberculosis* is an acid fast rod, extremely slow growing and mycobactin-dependent for its *in vitro* growth. This mycobacterium is the etiological agent of the chronic enteritis that affects domestic and wild ruminants, well-known as paratuberculosis or Johne's disease. In humans, a possible *M. avium* subsp. *paratuberculosis* infection has been suggested to be involved in the pathogenesis of Crohn's disease [1, 2], sarcoidosis; and recently sarcoidosis-like multisystem autosomal-dominant granulomatous disorder (Blau syndrome) [3, 4].

Crohn's disease encompasses a spectrum of clinical and pathological patterns manifested by focal, asymmetric, transmural, and, chronic granulomatous inflammation affecting the gastrointestinal tract with the potential for systemic and extraintestinal complications. The etiology of Crohn's disease is thought to be multifactorial, involving an interaction between genetic susceptibility, environmental triggers, and immune-mediated tissue injury. In this regard, there is considerable suggestive evidence to support an environmental factor, such as *M. avium* subsp. *paratuberculosis* infection. This evidence includes similarity of the macro and microscopic injuries, bacteriological isolation and molecular biology tests which have allowed the detection of this mycobacterium in intestine, milk and peripheral blood of

---

\* Gilberto Chávez-Gris<sup>2</sup>, Francisco J. García-Vázquez<sup>3</sup>, José M. Remes-Troche<sup>4</sup>, Luis F. Uscanga<sup>4</sup>, Marco A. Santillán Flores<sup>1</sup>, Fernando Paolicchi<sup>5</sup>, Erika M. Carrillo-Casas<sup>6</sup>, Rigoberto Hernández Castro<sup>6</sup>

<sup>1</sup> Laboratorio de Tuberculosis. CENID-Microbiología Animal. INIFAP. México

<sup>2</sup> Centro de Enseñanza, Investigación y Extensión en Producción Animal en Altiplano, Facultad de Medicina Veterinaria y Zootecnia, Universidad Nacional Autónoma de México. Tequisquiapan, Querétaro, México

<sup>3</sup> Departamento de Patología Molecular. Instituto Nacional de Pediatría. Coyoacán 04530. México

<sup>4</sup> Departamento de Gastroenterología. Instituto Nacional de Ciencias Médicas y Nutrición "Salvador Zubirán". Tlalpan 14000. México

<sup>5</sup> Grupo de Sanidad Animal/Animal Health Group. INTA, Est Exp Agrop Balcarce - Facultad Cs Agrarias UNMdP. Casilla de Correo 276/ PO Box 276. 7620 Balcare, Argentina

<sup>6</sup> Departamento de Biología Molecular e Histocompatibilidad. Hospital General "Dr. Manuel Gea González". Tlalpan 14080 México

patients with Crohn's disease [5, 6, 7]. Despite this; *M. avium* subsp. *paratuberculosis* is still not recognized as a human pathogen.

Crohn's disease has a high prevalence in North America, and Northern and Western Europe is less so in South Africa, Australia, and South and Middle Europe. It is considered a rare disease in Asia, Africa and Latin America. However, recently an increase in the incidence of Crohn's disease has been noted in Spain and Latin American countries, such as Puerto Rico and Brazil [10, 11]. These populations are very similar to the Mexican population, mainly composed by Mexican Mestizo individuals which have a proportion of 56% Native American Indian genes, 40% Caucasian genes (the most common European ancestry are the Spaniards), and 4% Afro-American genes [12]. In 2010, 14,706 persons were diagnosed with tuberculosis in Mexico (1.39% of them suffering meningitis), unfortunately the prevalence of other mycobacteriosis remains unknown [13]. The present study used *in situ* hybridization to detect a fraction of *M. avium* subsp. *paratuberculosis* specific sequence IS900, it was carried out to determine the presence of *M. avium* subsp. *paratuberculosis* on formalin fixed intestinal samples of Mexican patients with Crohn's disease, and in samples of ruminants with paratuberculosis.

## 2. Material and methods

### 2.1 Samples origin and characteristics

Twenty three paraffin blocks with intestinal samples from 14 patients with clinical and histopathological diagnosis of Crohn's disease were included. All patients underwent surgical resection of the small and/or large bowel segments for disease at the Medical Sciences and Nutrition National Institute "Salvador Zubirán". A sample of human intestine diagnosed with intestinal tuberculosis and ulcerative colitis was included as a negative control; this case was kindly facilitated by the National Institute of Pediatrics. Paraffin blocks with intestine samples from 1 bovine, 2 goats and 9 ovines, previously diagnosed with paratuberculosis by ELISA, histopathology and tissue culture were used, as controls.

### 2.2 Test area selection

Histopathological evaluation to characterize the inflammatory disease and select appropriate target areas for the application of the hybridisation probe was performed on all the intestine samples after staining with hematoxylin and eosin (HE); and Ziehl-Neelsen (ZN). The Criteria for group formation, was to consider the presence or absence of acid fast bacilli after ZN stain, accordingly we separated the animal tissues into two paratuberculosis groups: Group A with 8 samples showing a granulomatous reaction and ZN (+); and group B with 4 samples showing granulomatous reaction but ZN (-).

All Crohn's disease cases were negative to the ZN stain. Group C included those Crohn's disease cases in which at histopathological examination we observed transmural inflammatory infiltrate with the presence of macrophages, epithelioid cells and sometimes giant Langhans cells; and considered as granulomatous. Whereas group D consisted of those cases in which infiltration was predominantly lymphocytic with plasma cells or mixed with some granulocytes at mucosal or transmural level which were considered as non granulomatous. In a single case with multiple samples, one was classified within group C and another one in group D. Group C consisted of 7 patients and 10 samples, whereas group D comprised 8 patients with 13 samples.

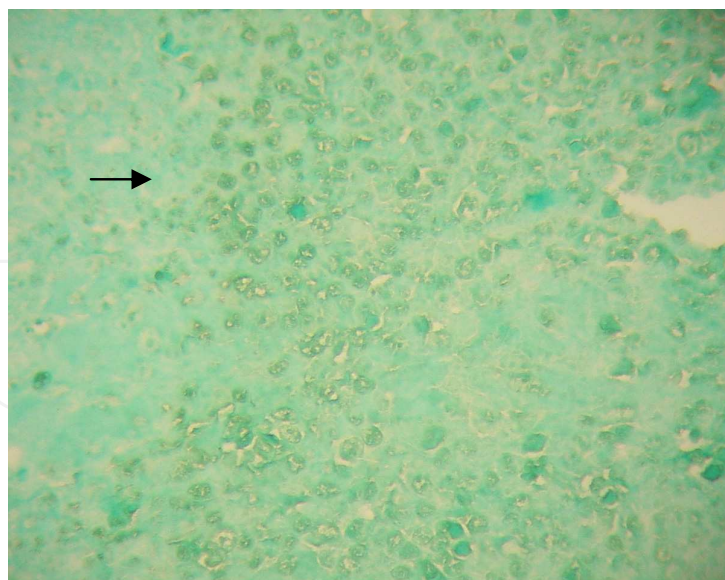


Fig. 1. Case of paratuberculosis from group A. ISH, DAB. 40x. Positive reaction inside macrophages in ileal submucosa.

### 2.3 In situ hybridization (ISH)

The biotinylated probe used consists in 25 bases: TAGGACTGGTCGGCTGCAAGGTAG. This sequence belongs to the region 639-664 of the 3' chain of IS900. Sections of 2  $\mu\text{m}$  of thickness were placed in positive charged and pre-cleaned slides (FisherBiotech, USA). The slides were baked for 30 min at 60°C and submerged 5 min in xylol, rehydrated through graded alcohol (2 x 100%, 96%, 70%, 3 min each step) and air dried. Sections were incubated with proteinase K (DakoCytomation, USA) for 10 min at 42°C. Sections were washed twice with distilled water and H<sub>2</sub>O<sub>2</sub> 0.3% were added and placed 5 min at room temperature (RT). By capillarity, 5-10  $\mu\text{l}$  of the probe at 17.04  $\mu\text{g}/\text{ml}$  was added (depending on the large of the sample). Slides were placed in termoblock for 10 min at 94.5°C. Hybridization was allowed overnight at 37°C. Sections were washed 4 times with Tris Buffered Solution (TBS, pH 7.5). Immediately, 50  $\mu\text{l}$  of the stringent wash solution (0.015 M NaN<sub>3</sub>) were added on each slide and they were placed in termoblock, 30 min at 40°C and Finally TBS-washing for 4 times.

### 2.4 Signal detection

Two systems of signal detection were used. Catalyzed signal amplification system (CSA). 50  $\mu\text{l}$  of primary streptavidin-HRP was added and slides were placed in termoblock 20 min at 37°C. Slides were washed 4 times with TBS. Then, the slides were incubated with a drop of Biotinyl-tyramide 20 min at RT. Slides were washed 4 times with TBS and a drop of secondary streptavidin-HRP was added to the sections and incubated 15 min at RT. Reaction was revealed with 20  $\mu\text{l}$  of 1:50 dilution of diaminobenzidine tetrahydrochloride (DAB). The reaction was observed in the microscope and it was stopped rinsing slides with distilled water.

### 2.5 Alkaline peroxidase system (AP)

Alkaline streptavidin phosphatase (DakoCytomation, USA) was added and incubated 30 min at 37°C. Slides were washed 4 times with TBS and the reaction was revealed adding 2

drops of N2 N-dimethylformamide (NBT/BCIP) to the 1.7%. Every 10 min the reaction was observed in the microscope and finally stopped rinsing slides with distilled water. Finally the reaction was counterstained with light green at 3%. Slides were rinsed with alcohol 96%; air dried and submerged in xylol to adhere them a cover slip with entellan resin. The results were submitted to a difference between proportions test in the program Statistica 6.0 (Statsoft, Tulsa Ok. EU), to verify the difference between groups A and B, as well as between groups C and D, with a confidence level of 95%. A  $p$  value of less than 0.05 was considered to be significant.

### 3. Results

In the ruminant groups A and B, as expected, all the samples were positive by *in situ* hybridization. In humans (groups C and D), overall positivity for *M. avium* subsp. *paratuberculosis* by *in situ* hybridization was 64.28% (n= 9). According to the groups distribution, all 7 patients (100%) in group C were positive for *M. avium* subsp. *paratuberculosis* by *in situ* hybridization, compared to 3/8 (37.5%) patients in group D; this difference was statistically significant ( $p= 0.0239$ ).

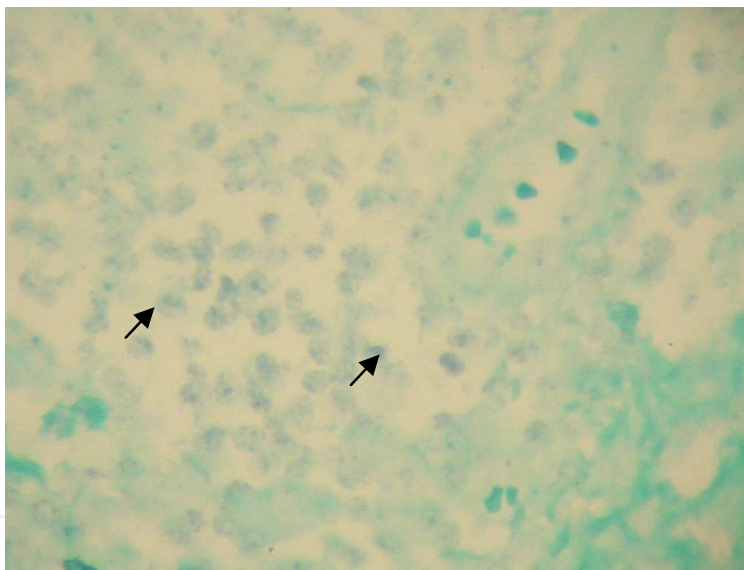


Fig. 2. Case of Crohn's disease from group C, ISH, NBT/BCIP. 40x. Positive reaction inside macrophages in the colonic submucosa.

Of the 8 patients in which more than one sample was analyzed, 3 of them were positive, 2 (25%) showed one positive and one negative sample and in 3 cases (37.5%) all were negative.

After *in situ* hybridization *M. avium* subsp. *paratuberculosis* was observed intracellularly within macrophages, epithelioid cells and giant cells in the intestinal mucosa and submucosa. In groups A, B and C the positive signal was observed within granulomas, whereas in group D it was seen within little macrophages that contribute to the inflammatory infiltrate. The positive signals were granular and intracytoplasmic. In group A, the cases in group A with abundant intracellular Mycobacteria; the reaction coalesces and looks diffuse in the cytoplasm.

#### 4. Discussion

Crohn's disease is a chronic inflammatory bowel disease of as yet unknown and possibly heterogeneous etiology. Diet, infections, immune dysregulation, and other unidentified environmental factors, all working under the influence of a genetic predisposition, have been suspiciously regarded. Among these, one of the most enduring hypotheses has been that *M. avium* subsp. *paratuberculosis* could be the causative agent of Crohn's disease.

By bacteriological isolation, serology and techniques of molecular biology several authors have been able to detect the presence of *M. avium* subsp. *paratuberculosis* in a great proportion of patients with Crohn's disease [2, 3, 5-7]. Even more, some authors have reported clinical remission of Crohn's disease patients who received anti-mycobacterial therapy which included macrolide antibiotics [8].

However, early results were inconsistent so that the role of this chronic enteric pathogen in the pathogenesis of Crohn's disease is not yet clearly established. The disparity in the earlier results can be due to several factors; among them the application of different methodologies. Successful isolations have been achieved by bacteriologists in veterinary laboratories since human medicine laboratories do not routinely culture mycobactin dependent mycobacteria, and therefore, don't necessary have adequate media for the isolation of these very difficult and slow growing organisms. In addition, when culture has been successful, the primary isolation consists on ZN-negative cell wall deficient forms which require long incubation times; which can extend for years to revert to bacillary forms [1]. In this study all cases showed a granular and intracytoplasmic stain pattern, as expected for intracellular bacteria like mycobacteria and *Chlamydophila* in agreement with the previous work described by Hulten *et al* and Meijer *et al*. [12, 14-15].

In the veterinary group A, the tissues were from multibacillary Johne's disease, with the labeled probe therefore hybridizing to the bacillary forms of *M. avium* subsp. *paratuberculosis*. In group B, as well as in the cases of Crohn's disease in groups C and D; the labeled probe hybridized *in situ* to the ZN-negative form of these versatile pathogens showing that this technique is capable of recognizing the cell wall deficient phenotype. Therefore, the protocol of *in situ* hybridization used identifies both forms of *M. avium* subsp. *paratuberculosis*. The enzymatic digestion treatment is apparently able to permeabilise the mycobacterial cellular wall without altering intestine tissue architecture in ruminants and humans.

The identification, by *in situ* hybridization of positive cases to *M. avium* subsp. *paratuberculosis* in groups B, C and D is consistent with the findings of the study of Hulten *et al* in which they identify spheroplasts of this mycobacterium in paucibacillary cases of Johne's disease in ovines [14], as well as their later study when they demonstrated the presence of spheroplasts in 7 of 37 (18.91%) of the Crohn's disease patients [15]. In the same way, Sechi *et al* demonstrated by *in situ* hybridization, the presence of *M. avium* subsp. *paratuberculosis* spheroplasts in 35 of 48 (72.91%) of Crohn's disease patients, despite the fact that on this occasion they did not find *M. avium* subsp. *paratuberculosis* by PCR IS900 in the same samples [17]. However, these authors did identify *M. avium* subsp. *paratuberculosis* by PCR in subsequent work using improved sample processing procedures [18].

Although some literature classifies patients with Crohn's disease according to the fistulous or obstructive phenotype, in our present series of clinical cases we observed that the same patient can demonstrate both phenotypes in different intestinal segments. The value of this

method of classification is in our view uncertain. Most of the studies of the molecular pathology in Crohn's disease do not differentiate between patients with the granulomatous and non granulomatous presentation. The results obtained in the present study indicate that a greater proportion of patients with granulomatous disease are *M. avium* subsp. *paratuberculosis* positive by *in situ* hybridization. This observation agrees with those of Hulten *et al.* However; we found the positive *in situ* hybridization signal particularly in relation to the granulomas in Crohn's disease patients.

Greenstein suggested that the identification of *M. avium* subsp. *paratuberculosis* DNA in the tissues of patients with Crohn's disease cannot be taken as proof of a causal association between this mycobacterium with Crohn's disease. It could be a coincidence of *M. avium* subsp. *paratuberculosis* DNA being in the intestinal lumen of people who had ingested cow's milk containing these pathogens [19]. In the present study using an *in situ* diagnostic procedure we were able to confirm the presence of *M. avium* subsp. *paratuberculosis* within the inflamed gut wall and related to the granulomatous lesions. In this situation *M. avium* subsp. *paratuberculosis* is most unlikely to be a transient food-borne contaminant. It is much more likely that is well characterized multi-host chronic enteric pathogen is related to the causation of the chronic inflammatory intestinal disease. The exact mechanism is not known but one theory is that *M. avium* subsp. *paratuberculosis* either can infect the host and cause a primary infection responsible for the development of the disease, or it is a secondary opportunistic infection that could perpetuate the cycle of inflammation and cytokine release. Regarding the Crohn's disease pathogenesis, there is no doubt that Crohn's disease is a result of immune dysregulation, where an excessive TH1-driven, cell-mediated immune response is elicited and persists. In this context, chronic intracellular *M. avium* subsp. *paratuberculosis* infection may be the trigger for this excessive TH1 immune response that results in the clinical, endoscopic, radiological, and histological manifestation known as Crohn's disease.

Even if *M. avium* subsp. *paratuberculosis* is not causally linked with Crohn's disease, the presence of DNA from *M. avium* subsp. *paratuberculosis* and other bacteria within the mucosa might have secondary clinical implications. Some studies have proved that bacterial DNA has immunomodulatory activity by signaling via pattern recognition receptors such as toll-like receptor 9 on host epithelial cells [20]. Further studies are needed, and it is imperative that researchers adopt standardized methods and techniques, including appropriate controls, and search for intracellular bacteria other than *M. avium* subsp. *paratuberculosis*. The availability of these tests could influence the therapeutic approach of these patients; antimycobacterial therapy may include macrolide antibiotics which have been beneficial for remission of intestinal lesions [8].

Although previous epidemiological studies have suggested that the incidence of inflammatory bowel disease is lower in Latin American populations, recent studies have demonstrated that the incidence is increasing and may be higher than suspected. For example, Appleyard *et al.* showed that in Puerto Rico, an Hispanic predominant population; the total incidence of IBD increased significantly between 1996 and 2000 (3.07/100,000 to 7.74/100,000;  $p < 0.001$ ), being significantly higher for Crohn's disease (four-fold increase,  $p < 0.01$ ), but not for ulcerative colitis (1.7-fold increase) [10]. Puerto Ricans are genetically complex and comprised of various proportions of Native American, African, and European genetic origins, as our Mexican population. Although the reasons for this are unclear, the data suggest several possible explanations such as changes in health care system, movement

from rural areas to urban cities, a more Westernized and fairly high carbohydrates and fat diet, and decrease in the incidence of intestinal parasites; which have a protective effect via regulation of the immune response.

## 5. Conclusion

In conclusion, despite the obvious need to evaluate a greater number of Mexican patients with and without inflammatory bowel disease these initial results remark the exposure of the Mexican population to *M. avium* subsp. *paratuberculosis* and provide further evidence in support of the zoonotic features of this agent. Taking on account the public health relevance of the issue as well as its economic impact, wider studies are needed in Mexico.


## 6. References

- Chiodini RJ, Van Kruiningen HJ, Thayer WR, *et al.* Spheroplastic phase of mycobacteria isolated from patients with Crohn's disease. *J Clin Microbiol.* 1986;27:357-363.
- Bull TJ, McMinn EJ, Sidi-Boumedine K, *et al.* Detection and verification of *Mycobacterium avium* subsp *paratuberculosis* in fresh ileocolonic mucosal biopsy specimens from individuals with and without Crohn's disease. *J Clin Microbiol.* 2003; 41:2915-23.
- Ikonomopoulos JA, Gorgoulis VG, Kastrinakis NG, *et al.* Sensitive differential detection of genetically related mycobacterial pathogens in archival material. *Am J Clin Pathol.* 2000;114(6):940-50.
- Dow CT. Paratuberculosis in Blau Syndrome tissues. Memories from the 8<sup>th</sup> International Colloquium on Paratuberculosis. August 14-18 2005. Copenhagen, Denmark.
- Schwartz D, Shafran I, Romero C, *et al.* Use of short-term culture for identification of *Mycobacterium avium* subsp. *paratuberculosis* in tissue from Crohn's disease patients. *Clin Microbiol Infect.* 2000;6:303-307.
- Naser SA, Schwartz D, Shafran I. Isolation of *Mycobacterium avium* subsp *paratuberculosis* from Breast Milk of Crohn's Disease Patients. *Am J Gastroenterol.* 2000;95:1094-5.
- Naser SA, Ghobrial G, Romero C, *et al.* Culture of *Mycobacterium avium* subspecies *paratuberculosis* from the blood of patients with Crohn's disease. *Lancet.* 2004;364:1039-44.
- Gui GP, Thomas PR, Tizard ML. Two-year outcomes analysis of Crohn's disease treated with rifabutin and macrolide antibiotic. *J Antimicrob Chemother.* 1997;39: 393-400.
- Jinch H, Rojas E, De Castro R. Regional enteritis in Mexico. *Gac Med Mex.* 1967;97:681-91.
- Appleyard CB, Hernandez G, Rios-Bedoya CF. Basic epidemiology of Inflammatory Bowel Disease in Puerto Rico. *Inflamm Bowel Dis.* 2004;10:106-11.
- Souza MH, Troncon LE, Rodrigues CM, *et al.* Trends in the occurrence (1980-1999) and clinical features of Crohn's disease and ulcerative colitis in a university hospital in southeastern Brazil. *Arq Gastroenterol.* 2002;39:98-105.
- Yamamoto-Furusko JK, Uscanga LF, Vargas-Alarcon G, *et al.* Clinical and genetic heterogeneity in Mexican patients with ulcerative colitis. *Hum Immunol.* 2003;64(1):119-23.
- Sistema Nacional de Vigilancia Epidemiológica. Boletín Epidemiológico 2011;32(27) 2009. Available in: <http://www.dgepi.salud.gob.mx/boletin/2010/2010/sem52.pdf>.
- Hulten K, Karttunen TJ, El-Zimaity HM, Naser SA, Collins MT, Graham DY, El-Zaatari FA. Identification of cell wall deficient forms of *M. avium* subsp. *paratuberculosis* in



- paraffin embedded tissues from animals with Johne's disease by *in situ* hybridization. *J Microbiol Methods*. 2000; 42(2):185-95.
- Hulten K, El-Zimaity HM, Karttunen TJ, Almashhrawi A, Schwartz MR, Graham DY, El-Zaatari FA. Detection of *Mycobacterium avium* subspecies *paratuberculosis* in Crohn's diseased tissues by *in situ* hybridization. *Am J Gastroenterol*. 2001;96:1529-35.
- Meijer A, Roholl PJ, Gielis-Proper SK, et al. *Chlamydia pneumoniae* *in vitro* and *in vivo*: a critical evaluation of *in situ* detection methods. *J Clin Pathol*. 2000;53(12):904-10.
- Sechi LA, Mura M, Tanda F, et al. Identification of *Mycobacterium avium* subsp. *paratuberculosis* in biopsy specimens from patients with Crohn's disease identified by *in situ* hybridization. *J Clin Microbiol*. 2001;39:4514-7.
- Sechi LA, Mura M, Tanda E, et al. *Mycobacterium avium* subsp. *paratuberculosis* in tissue samples of Crohn's disease patients. *New Microbiol*. 2004;27(1):75-7.
- Greenstein RJ. Is Crohn's disease caused by a mycobacterium? Comparisons with leprosy, tuberculosis, and Johne's disease. *Lancet Infect Dis*. 2003;3:507-14.
- Watson JL, McKay DM. The immunophysiological impact of bacterial CpG DNA on the gut. *Clin Chim Acta*. 2005;:1-11.

IntechOpen



## **Crohn's Disease**

Edited by Dr. Sami Karoui

ISBN 978-953-307-811-3

Hard cover, 210 pages

**Publisher** InTech

**Published online** 13, January, 2012

**Published in print edition** January, 2012

In this book, several important points regarding Crohn's disease are discussed. In the first section, we focus on etiopathogeny of Crohn's disease and the recent advances in our overall understanding of the disease - specifically, the role of the gut epithelium, alterations of the epithelial crypts, and the roles of the different cytokines in the pathophysiology of Crohn's disease. In the second section, a diagnosis of Crohn's disease is discussed. Another particular area of focus is in the diagnosis of intestinal tuberculosis, and the role of mycobacterium avium in Crohn's disease. In the third and final section, the management of Crohn's disease is discussed, with a focus on recent evidence-based medicine recommendations.

### **How to reference**

In order to correctly reference this scholarly work, feel free to copy and paste the following:

Lucía C. Favila-Humara, Gilberto Chávez-Gris, Francisco J. García-Vázquez, José M. Remes-Troche, Luis F. Uscanga, Marco A. Santillán Flores, Fernando Paolicchi, Erika M. Carrillo-Casas, Rigoberto Hernández Castro (2012). Detection of Mycobacterium avium subsp. paratuberculosis in Crohn's Disease Patients and Ruminants Intestine by In Situ Hybridization, Crohn's Disease, Dr. Sami Karoui (Ed.), ISBN: 978-953-307-811-3, InTech, Available from: <http://www.intechopen.com/books/crohn-s-disease/detection-of-mycobacterium-avium-subsp-paratuberculosis-in-crohn-s-disease-patients-and-ruminants-in>

**INTECH**  
open science | open minds

### **InTech Europe**

University Campus STeP Ri  
Slavka Krautzeka 83/A  
51000 Rijeka, Croatia  
Phone: +385 (51) 770 447  
Fax: +385 (51) 686 166  
[www.intechopen.com](http://www.intechopen.com)

### **InTech China**

Unit 405, Office Block, Hotel Equatorial Shanghai  
No.65, Yan An Road (West), Shanghai, 200040, China  
中国上海市延安西路65号上海国际贵都大饭店办公楼405单元  
Phone: +86-21-62489820  
Fax: +86-21-62489821

© 2012 The Author(s). Licensee IntechOpen. This is an open access article distributed under the terms of the [Creative Commons Attribution 3.0 License](#), which permits unrestricted use, distribution, and reproduction in any medium, provided the original work is properly cited.

IntechOpen

IntechOpen