

We are IntechOpen, the world's leading publisher of Open Access books Built by scientists, for scientists

4,800

Open access books available

122,000

International authors and editors

135M

Downloads

Our authors are among the

154

Countries delivered to

TOP 1%

most cited scientists

12.2%

Contributors from top 500 universities



WEB OF SCIENCE™

Selection of our books indexed in the Book Citation Index
in Web of Science™ Core Collection (BKCI)

Interested in publishing with us?
Contact book.department@intechopen.com

Numbers displayed above are based on latest data collected.

For more information visit www.intechopen.com



Electromyography in Myofascial Syndrome

Juhani Partanen

University Hospital of Helsinki

*Department of Clinical Neurophysiology
Finland*

1. Introduction

Myofascial syndrome is a muscular pain syndrome with regional symptoms, often in limb girdle or neck and back area. It is common and causes much disability and inability to work. Myofascial pain may be activated by precision work, repetitive strain or recent injury. Typical findings in symptomatic muscles are taut bands and painful trigger points (TrPs), where pressure elicits a typical spreading of pain (Cummings & Baldry, 2007). Microdialysis of TrPs has detected local elevation of contraction, and inflammatory and pain metabolites (Shah et al., 2008). Reduced high-energy phosphate levels but no signs of myositis have observed in painful muscles in histological studies (Bengtsson et al., 1986).

2. Electromyography of trigger points

There are several studies of EMG in TrPs. There is no sustained spontaneous activation of motor unit potentials (MUPs) (spasticity) or any signs of denervation i.e. fibrillation potentials or motor unit potential alterations typical for nerve sprouting (Couppé et al., 2001).

2.1 Spontaneous electrical activity at the endplate

When EMG in TrPs is compared to EMG in painless points of the same or other muscle, there are some differences. TrPs show more numerous local findings of spontaneous electrical activity (SEA) than control points (Couppé et al., 2001). SEA may consist of endplate activity which is reflected in two forms, often activated together: endplate noise (EPN) (miniature end plate potentials MEPPs) and end plate spikes (EPS). In EPN there are either small, discrete high-frequency depolarizations rarely exceeding 100 μ V (MEPPs) or just "sea shell" noise, depending on the orientation and localization of the needle electrode with respect to the source (Wiederholt, 1970). It was also claimed that EPN is more prevalent in TrPs within the end plate zone and more prevalent in active than latent TrPs (Simons et al., 2002). End plate spikes are larger in amplitude than MEPPs, exceeding even several hundred microvolts. EPSs are usually observed together with EPN (Fig. 1).

EPSs have a characteristic irregular firing pattern with numerous short intervals less than 30 ms. Thus it is easy to distinguish EPSs from other spontaneous EMG patterns or MUPs. In addition, EPSs have a characteristic wave form with initial negativity or with a short (less than 0,3 ms) initial positivity. Rarely, EPSs with a typical firing pattern but a large polyphasic waveform may be observed (Partanen, 1999).

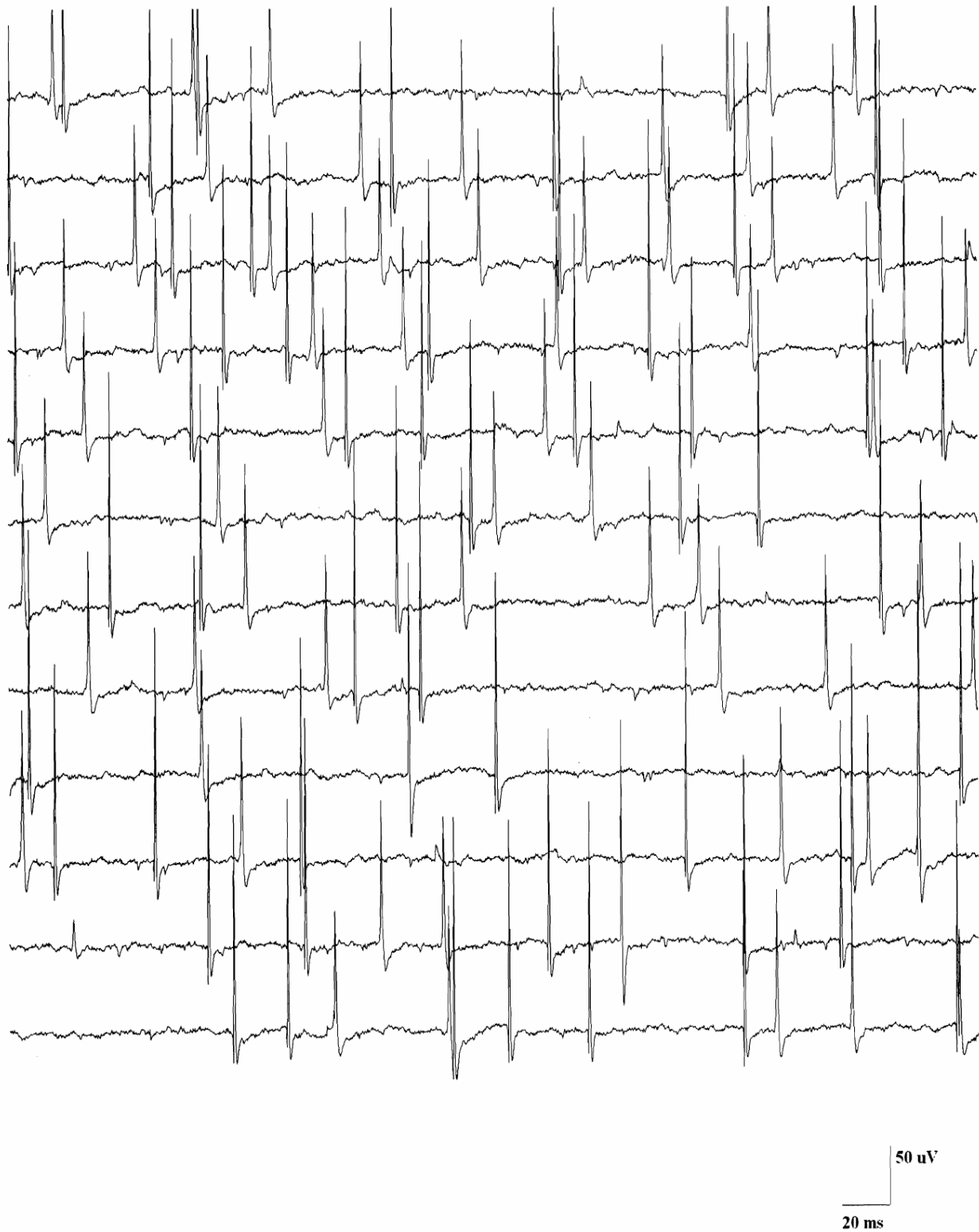


Fig. 1. Several sequences of end plate spikes in an active spot of a normal relaxed muscle. Most of them have a negative onset but some have a short initial positive component. Observe also the end plate noise in the background. From Pathophysiology, with permission.

2.2 Complex repetitive discharge

Another spontaneous waveform, which is repeatedly found in taut bands is complex repetitive discharge (CRD) (Fig. 2). It was originally described by Janet Travell in TrPs




Fig. 2. Complex repetitive discharge (33 Hz) in a taut band of the levator scapulae muscle of a patient suffering from myofascial syndrome. Otherwise the needle EMG was normal. From Pathophysiology, with permission

(Travell, 1957) but later on it was depicted in about 15% of patients suffering from myofascial syndrome (Ojala et al., 2006). CRD has been observed in several types of chronic neuropathy or myopathy (Emeryk et al., 1974a), but in these cases CRD is accompanied by other pathological alterations in EMG. In myofascial syndrome CRD is observed in muscles with otherwise normal EMG (Ojala et al., 2006).

3. Prevailing hypotheses of the origin of EPN, EPS and CRD

EPN and MEPPs are observed to originate from the postsynaptic surface of the neuromuscular junction. MEPPs are activated by spontaneous leakage of small amounts of acetylcholine (exocytosis) from the nerve terminal. MEPPs are local, non-propagated discrete depolarizations of muscle membrane. MEPPs should be found mainly at the end plate zone of the muscle, where neuromuscular junctions are localized. EPSs are supposed to be elicited by summation of a number of MEPPs, if the sum potential exceeds the critical level to fire an action potential (Buchthal & Rosenfalck, 1966). Another explanation is a nerve potential activated by the irritation caused by the EMG needle electrode. The nerve potential then travels to the nerve terminal and activates a postsynaptic action potential which is recorded with the same EMG needle as an EPS (Dumitru, 1995). CRD is supposed to arise when an action potential is circulating in muscle fibres, leaping from one fibre to another with ephaptic conduction, forming eventually a vicious cycle with sustained circulation of action potentials (Trontelj & Stålberg, 1983). The participation of motor neurone and even "spindelisation" of extrafusal muscle fibres due to changed innervation was also discussed (Emeryk et al., 1974b).

4. Discussion of the discrepancies of prevailing hypotheses for EPS and CRD and suggestions for new explanations

Even if mechanical irritation of nerve terminal may cause marked increase of the frequency of MEPPs, there are no data demonstrating that this may cause activation of postsynaptic action potentials of the muscle fibre, recorded as EPSs. The mechanical irritation of the terminal motor nerve branch by the needle electrode may cause injury potential and rarely rhythmic spontaneous activity but sustained irregular firing has not been described in experimental studies (Wall et al., 1974). Thus the firing pattern of EPSs clearly differs from the known patterns of injury potentials (Macefield, 1998). CRDs are not found in totally denervated muscles (personal observation). Thus, evidently CRD needs the presence of intramuscular motor axons. In fact, CRD in myofascial syndrome may represent activation of a spinal reflex arch, instead of an ephaptic circuit of muscle fibres (see Heading 7).

The third explanation for EPSs is that they are action potentials of intrafusal muscle fibres. There are several points which suggest this possibility, for example activation of EPSs by passive stretching of the muscle (Partanen, 1999; Partanen & Nousiainen, 1983).

5. Multi-channel recordings of EPSs

Different patterns of propagation of EPSs may be observed with multi-channel recording of EPSs in relaxed human muscles, using 3-5 EMG needles in parallel with the muscle fibres (Fig 3).

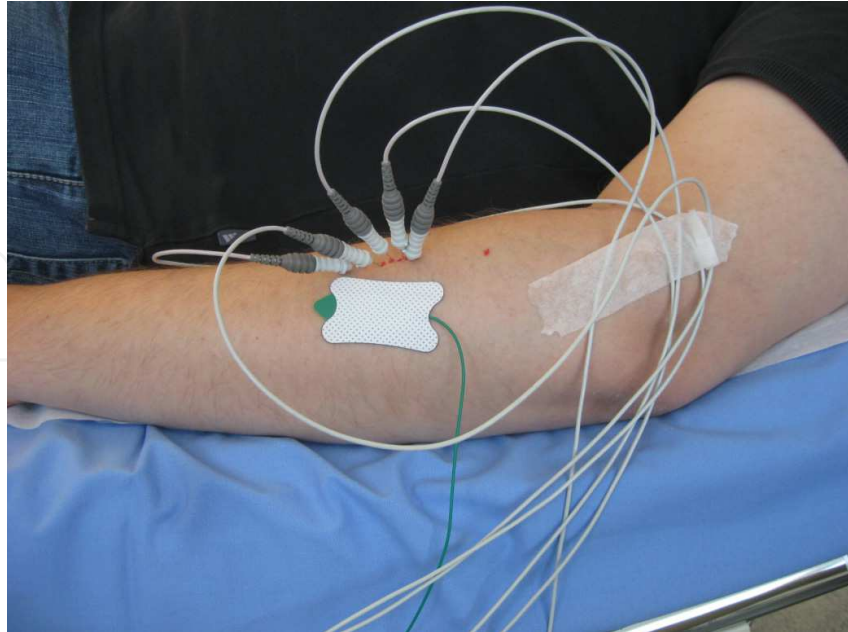


Fig. 3. A five-channel recording of the extensor carpi radialis muscle. The EMG needles are lying in parallel with the muscle fibres and the interelectrode distance is 3 mm.

The first type of EPSs does not propagate at all: there are local large potentials (Fig. 4). The second type of EPSs propagates for a short distance (a few mm) (Fig. 5) and third type propagates like a motor unit potential (Fig. 6-7). The first type may reflect activity of intrafusal nuclear bag fibres, which show this non-propagating junctional potential pattern in experimental recordings (Barker et al., 1978). The second type of EPS with a short propagation

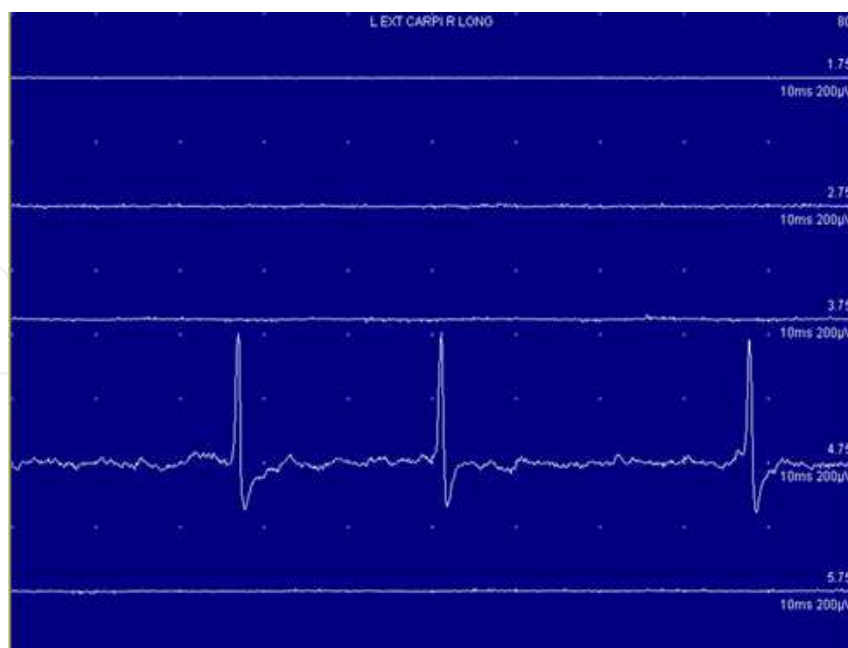


Fig. 4. An end plate spike sequence in channel 4. It does not propagate at all. It was not possible to find synchronous potentials in any of the other channels. End plate spikes may represent activation of a nuclear bag muscle fibre. Calibration 10 ms, 200 μ V.

distance is in concert with the activity of nuclear chain fibres (Barker et al., 1978) and the third type corresponds to the activity of beta motor units (Partanen, 1999; Partanen & Palmu, 2009).

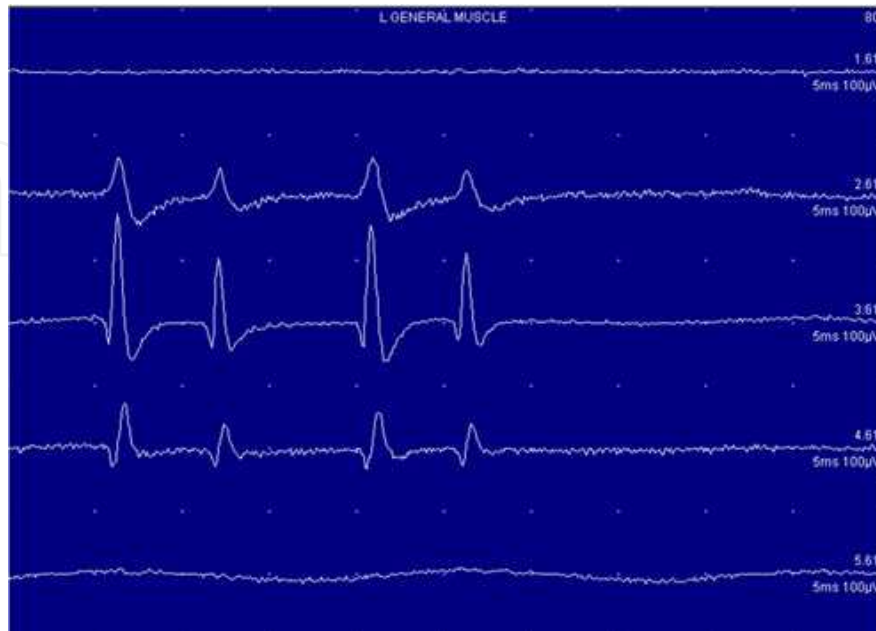


Fig. 5. Sequence of end plate spikes propagating from channel 2 to channel 4 (note the development of positive onset). This sequence may represent activation of nuclear chain muscle fibres. Calibration 5 ms, 100 μ V.

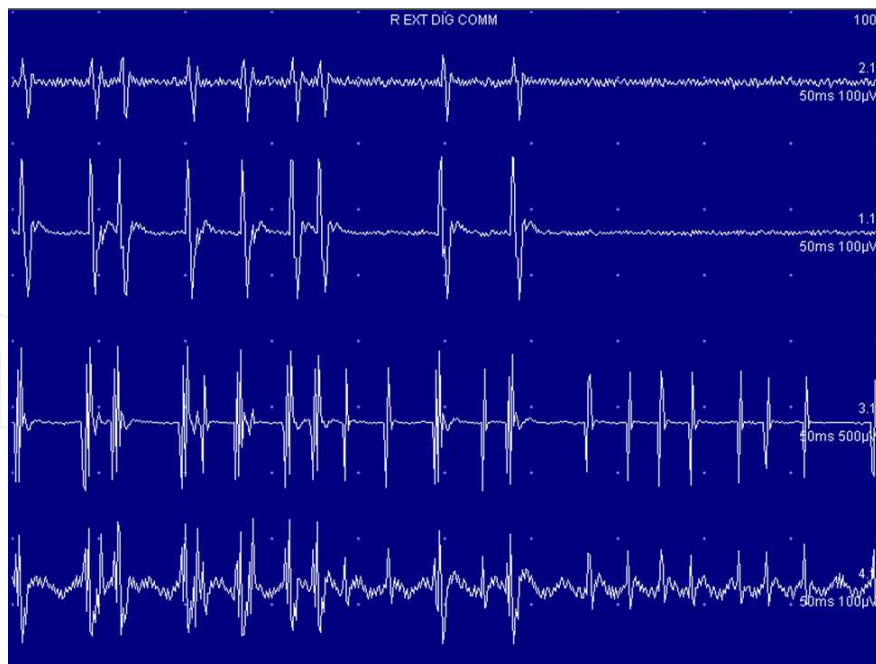


Fig. 6. Two sequences of end plate spikes. One is propagating to all channels and may represent beta motor unit potentials. The other propagates only from channel three to channel four and may represent activation of nuclear chain fibres. Calibration 50 ms, 100 μ V, except Ch 3, 500 μ V.

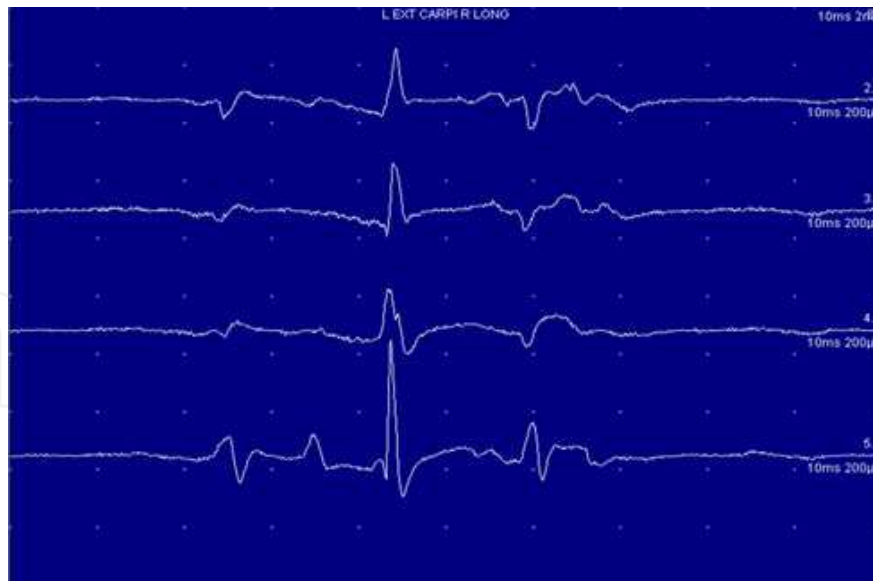

Fig. 7. Propagation of voluntarily activated motor unit potentials to all channels. Because of the slow firing of motor unit potentials compared to end plate spikes, they do not recur in this time window. Calibration 10 ms, 200 μ V.

6. The “integrated hypothesis” for myofascial syndrome

The “integrated hypothesis” for myofascial syndrome comprises a local energy crisis of muscle tissue caused by strain. This leads to accumulation of irritative metabolites and thus activation of local nerve terminals with sustained contraction of postsynaptic muscle fibre. This is followed by rigor and a contraction knot, and development of a taut band, as well as activation of pain and sympathetic nerve fibres (Simons et al., 1999; Cummings & Baldry, 2007).

7. Discussion of the discrepancies of “integrated hypothesis” and suggestion of a new explanation for myofascial syndrome

The capillaries of extrafusal muscle tissue offer an effective perfusion, which is able to transport all irritative metabolites out of the muscle tissue. Thus the local inflammation of muscle without any signs of myositis seems improbable. On the other hand the capillaries of muscle spindles are different. There is a blood/spindle barrier and a non-permeable capsule around the spindle (Banks & Barker, 2004). Thus metabolites released into the capsular periaxial space of muscle spindle are readily concentrated. Sustained fusimotor activation of muscle spindle caused by for example precision work may achieve increased release of contraction metabolites intrafusally. This may activate release of inflammatory metabolites and finally pain metabolites. Only Ia-afferents of the muscle spindle activate alpha motor neurons (myotatic reflex). II- III- and IV-afferents activate intrafusal muscle fibres via gamma- and beta efferent pathways. III- and IV-afferents have been observed inside the muscle spindle (Paintal, 1960, Stacey, 1969). If inflammatory and pain metabolites are concentrated intrafusally, III- and IV-afferents, which comprise also chemical and pain receptors, may activate gamma- and beta-efferent activity via spinal reflex pathway. Beta efferent activation may be seen as CRD in EMG of taut bands for a limited time. Thus taut bands may be formed by extrafusal muscle fibres of beta motor

units in metabolic exhaustion and rigor. Myotatic reflex (twitch) is present in taut bands (Shah et al., 2008) and this reflex is evidently activated by intact Ia afferent- alpha efferent reflex arch (Partanen et al., 2010).

8. Final comments

Needle EMG in myofascial syndrome is usually normal. In 15 % of patients CRD may be observed in some of the trigger points in taut bands (Ojala et al., 2006). This finding seems to be specific for myofascial syndrome, if there are no other EMG alterations. It remains to be seen if a thorough study of as many trigger points as possible increases the possibility to find CRD in a greater percentage of patients. The search may be justified because dry needling is also one of the treatments of myofascial syndrome (Cummings & Baldry, 2007). Incidence of end plate activity is increased in trigger points but this fact is not useful for diagnostics, because end plate activity is often observed in painless points as well. MEPPs with EPSs may represent intrafusal activity. In neuromuscular junctions of alpha motor units only MEPPs but not EPSs may be seen (Partanen et al., 2010). The different hypotheses discussed here can be tested and they help to comprehend the context “myofascial syndrome”, which is not accepted by all physicians. At present the diagnosis of myofascial syndrome is clinical: there are no specific laboratory or imaging studies or other means to confirm the diagnosis (Dommerholt & Huijbregts, 2011).

9. References


- Banks, R. W., & Barker, D. (2004). The muscle spindle, In: *Myology* (3rd edition), Engel, A., & Franzini-Armstrong, C., pp. 489-509, McGraw-Hill, Medical Publishing Division, New York
- Barker, D., Bessou P., Jankowska, E., Pagès, B., Stacey, M.J. (1978). Identification of intrafusal muscle fibres activated by single fusimotor axons and injected with fluorescent dye in cat tenuissimus spindles. *J. Physiol*, Vol 275, pp. 149-165
- Bengtsson, A., Henriksson, K. G., & Larsson, J. (1986). Reduced high-energy phosphate levels in the painful muscles of patients with primary fibromyalgia. *Arthritis & Rheumatism*, Vol.29, No.7, (July 1986), pp. 817-821
- Buchthal, F., & Rosenfalck, P. (1966). Spontaneous electrical activity of human muscle. *Electroencephalography and Clinical Neurophysiology*, Vol.20, No.4, (April 1966), pp. 321-336
- Couppé, C., Midttun, A., Hilden, J., Jørgensen, U., Oxholm, P., & Fuglsang-Frederiksen, A. (2001). Spontaneous needle electromyographic activity in myofascial trigger points in the infraspinatus muscle: a blinded assessment. *Journal of Musculoskeletal Pain*, Vol.9, No.3, pp. 7-17
- Cummings, M., & Baldry, P. (2007). Regional myofascial pain: diagnosis and management. *Best Pract Res Clin Rheumatol.*, Vol.21, No.2, (April 2007), pp. 367-387
- Dommerholt, J., & Huijbregts, P. (2011). *Myofascial trigger points: pathophysiology and evidenceinformed diagnosis and management*, Jones and Bartlett Publishers, Sudbury, Mass.

- Dumitru, D. (1995). *Electrodiagnostic Medicine*, pp. 29-64, 218-221, Hanley & Belfus, Philadelphia
- Emeryk, B., Hausmanowa-Petrusewicz, I., & Nowak, T. (1974a). Spontaneous volleys of bizarre high-frequency potentials (b.h.f.p.) in neuro-muscular diseases. Part 1. Occurrence of spontaneous volleys of b.h.f.p. in neuro-muscular diseases. *Electromyogr Clin Neurophysiol*, Vol.14, No.3, (June-July 1974), pp. 303-312
- Emeryk, B., Hausmanowa-Petrusewicz, I., & Nowak T. (1974b). Spontaneous volleys of bizarre high-frequency potentials (b.h.f.p.) in neuro-muscular diseases. Part II. An analysis of the morphology of spontaneous volleys of bizarre high-frequency potentials in neuro-muscular diseases. *Electromyogr Clin Neurophysiol*, Vol.14, No.4, (August-September 1974), pp. 339-354
- Macefield, V. G. (1998). Spontaneous and evoked ectopic discharges recorded from single human axons. *Muscle & Nerve*, Vol.21, No.4, (April 1998), pp. 461-468
- Ojala, T. A., Arokoski, J. P. A., & Partanen, J. V. (2006). Needle-electromyography findings of trigger points in neck-shoulder area before and after injection treatment. *J. Musculoskel. Pain*, Vol.14, pp. 5-14
- Paintal, A. S. (1960). Functional analysis of group III afferent fibres of mammalian muscles. *J Physiol* Vol.152, pp. 250-270
- Partanen, J. (1999). End plate spikes in the human electromyogram. Revision of the fusimotor theory. *J Physiol*, Paris, Vol.93, No.1-2, (January-April 1999), pp. 155-166
- Partanen, J. V., & Nousiainen, U. (1983). End-plate spikes in electromyography are fusimotor unit potentials. *Neurology*, Vol.33, No.8, (August 1983), pp. 1039-1043, Cleveland
- Partanen, J. V., Ojala, T. A., & Arokoski, J. P. A. (2010). Myofascial syndrome and pain: A neurophysiological approach. *Pathophysiology*, Vol.17, (February 2010), pp. 19-28
- Partanen, J. V., & Palmu, K. (2009). Different ways of propagation of human end plate spikes in electromyography. *Muscle Nerve*, Vol.40, (2009), pp. 720-721
- Shah, J. P., Danoff, J. V., Desai, M. J., Parikh, S., Nakamura, L. Y., Phillips, T. M., & Gerber, L. H. (2008). Biochemicals associated with pain and inflammation are elevated in sites near to and remote from active myofascial trigger points. *Arch Phys Med Rehabil*, Vol.89, No.1, (January 2008), pp. 16-23
- Simons, D. G., Hong, C. Z., & Simons, L. S. (2002). Endplate potentials are common to midfiber myofascial trigger points. *Am J Phys Med Rehabil*, Vol.81, No.3, (March 2002), pp. 212-222
- Simons, D. G., Travell, J. G., & Simons, L. S. (1999) *Myofascial Pain and Dysfunction: The Trigger Point Manual*, Vol.1, *Upper Half of Body*, (2nd edition), Williams & Wilkins, Baltimore
- Stacey, M. J. (1969). Free nerve endings in skeletal muscle of the cat. *J Anat*; Vol.105, pp. 231-254.
- Travell, J. (1957). Symposium of the mechanisms and management of pain syndromes. *Proc Rudolf Virchow Med Soc*, Vol.16, pp. 128-136
- Trontelj, J., & Stålberg, E. V. (1983). Bizarre repetitive discharges recorded with single fibre EMG. *J Neurol Neurosurg Psychiatry*, Vol.46, No.4, (April 1983), pp. 310-316

- Wall, P. D., Waxman, S., & Basbaum, A. I. (1974). Ongoing activity in peripheral nerve: injury discharge. *Exp Neurol*, Vol. 45, pp. 576-589
- Wiederholt, W. C. (1970). End-plate noise in electromyography. *Neurology*, Vol.20, No.3, (March 1970), pp. 214-224, Minneapolis

IntechOpen

IntechOpen



EMG Methods for Evaluating Muscle and Nerve Function

Edited by Mr. Mark Schwartz

ISBN 978-953-307-793-2

Hard cover, 532 pages

Publisher InTech

Published online 11, January, 2012

Published in print edition January, 2012

This first of two volumes on EMG (Electromyography) covers a wide range of subjects, from Principles and Methods, Signal Processing, Diagnostics, Evoked Potentials, to EMG in combination with other technologies and New Frontiers in Research and Technology. The authors vary in their approach to their subjects, from reviews of the field, to experimental studies with exciting new findings. The authors review the literature related to the use of surface electromyography (SEMG) parameters for measuring muscle function and fatigue to the limitations of different analysis and processing techniques. The final section on new frontiers in research and technology describes new applications where electromyography is employed as a means for humans to control electromechanical systems, water surface electromyography, scanning electromyography, EMG measures in orthodontic appliances, and in the ophthalmological field. These original approaches to the use of EMG measurement provide a bridge to the second volume on clinical applications of EMG.

How to reference

In order to correctly reference this scholarly work, feel free to copy and paste the following:

Juhani Partanen (2012). Electromyography in Myofascial Syndrome, EMG Methods for Evaluating Muscle and Nerve Function, Mr. Mark Schwartz (Ed.), ISBN: 978-953-307-793-2, InTech, Available from:

<http://www.intechopen.com/books/emg-methods-for-evaluating-muscle-and-nerve-function/electromyography-in-myofascial-syndrome>

INTECH
open science | open minds

InTech Europe

University Campus STeP Ri
Slavka Krautzeka 83/A
51000 Rijeka, Croatia
Phone: +385 (51) 770 447
Fax: +385 (51) 686 166
www.intechopen.com

InTech China

Unit 405, Office Block, Hotel Equatorial Shanghai
No.65, Yan An Road (West), Shanghai, 200040, China
中国上海市延安西路65号上海国际贵都大饭店办公楼405单元
Phone: +86-21-62489820
Fax: +86-21-62489821

© 2012 The Author(s). Licensee IntechOpen. This is an open access article distributed under the terms of the [Creative Commons Attribution 3.0 License](#), which permits unrestricted use, distribution, and reproduction in any medium, provided the original work is properly cited.

IntechOpen

IntechOpen