

We are IntechOpen, the world's leading publisher of Open Access books Built by scientists, for scientists

4,800

Open access books available

122,000

International authors and editors

135M

Downloads

Our authors are among the

154

Countries delivered to

TOP 1%

most cited scientists

12.2%

Contributors from top 500 universities



WEB OF SCIENCE™

Selection of our books indexed in the Book Citation Index
in Web of Science™ Core Collection (BKCI)

Interested in publishing with us?
Contact book.department@intechopen.com

Numbers displayed above are based on latest data collected.

For more information visit www.intechopen.com



Appendicitis in Children

Ngozi Joy Nwokoma

*Addenbrooke's Hospital, Cambridge University Hospitals, Cambridge
United Kingdom*

1. Introduction

Abdominal pain is a common clinical problem in children. The challenge is to determine which could be secondary to serious pathology. For the paediatric surgeon, the evaluation of a child with abdominal pain is often to ascertain if there is a surgically amenable pathology. The first clinical report of appendicitis in 1711 is credited to a German surgeon called Lorenz Heister (Ramsted et al., 1993). Appendicitis is the commonest acute childhood surgical abdominal emergency in developed countries. The peak incidence of acute appendicitis in children is in the second decade of life, at about 12 years of age (Pearl et al., 1995; Tsze et al., 2011). It is uncommon in children less than 5 years old, rare in infants and neonates, slightly more frequent in males than females with an incidence ratio of 1:1.5. The overall lifetime risk of appendicitis is 7%, slightly higher in females.

2. Embryology

The appendix develops as a true diverticulum of the caecum and becomes visible at the eighth week of gestation. It becomes more distinct as the inferior border of the caecum fails to enlarge as rapidly as the rest of it (Swain, 2005). As the proximal colon enlarges the caecum undergoes a downwards displacement into the right iliac fossa region of the abdomen. In certain congenital anomalies the final position of the appendix is outside the right lower quadrant. In situs inversus, the orientation of the intra-abdominal organs is reversed so that left sided organs are on the right and vice versa. The thoracic organs may also be involved in situs inversus totalis. In this condition, the appendix ends up in the left lower quadrant. In developmental arrest of the normal rotation of the midgut, the appendix may lie in the subhepatic region or towards the left side of the abdomen.

3. Anatomy

3.1 Position

The base of the appendix is located in the posteromedial aspect of the caecum; below and within 3cm of the ileocaecal junction. Though the base of the appendix assumes a relatively fixed position the final position of the appendix body and tip is variable (Figure 1). It commonly lies behind the caecum (retrocaecal: 64%) or crossing the pelvic brim into the pelvic cavity (pelvic: 32%). It could also lie posterior to the proximal colon (retrocolic), posterior to the terminal ileum (retroileal), anterior to the terminal ileum (preileal), just below the caecum (subcolic), along the lateral border of the caecum and colon

(paracolic/precaecal) or it may be an obturator appendix crossing over the obturator internus muscle (Moore & Dalley, 2006; Standing et al., 2005). Rarely, the appendix may lie on the right kidney or duodenum with a retroperitoneal tip and has been reported to ulcerate into the duodenum (Ellis & Mahadevan, 2010).




Fig. 1. Positional variation of appendicular body and tip: A. retrocaecal; B. Pelvic; C. retrocolic; D. retroileal; E. preileal; F. subcolic; G. paracolic/precaecal; H. obturator.

The superficial landmark of the base of the appendix corresponds to the level of the first segment of the sacral vertebrae (S1) at the McBurney's point. The McBurney's point is the junction of the outer and middle thirds of an imaginary line running from the right anterior superior iliac spine to the centre of the umbilicus. However, the appendix is located within 5cm of the McBurney's point less than 50% of the time (Karim et al., 1990).

3.2 Innervation

The midline development of the intra-abdominal viscera and associated innervation results in visceral pain being perceived in the midline. The level of pain may also be different from the level of the organ from which the pain stimulus arises due to the cranial migration of the nervous system. In line with the foregoing, epigastric pain is typically associated with pathology or irritation of the organs that originate from the foregut, periumbilical pain relates to midgut organs while infraumbilical or suprapubic pain relates to disease in the

hindgut. The midgut stretches from the second part of the duodenum to the midpoint of the transverse colon. Being a midgut-originated structure, the initial pain sensation from the appendix is felt in the periumbilical region. Perception of abdominal pain occurs when the nociceptors in the respective organ or region of the abdomen have been stimulated by appropriate agents. Appendicitis represents inflammation of a magnitude great enough to stimulate these nociceptors.

The nerve supply to the appendix is derived from the autonomic nervous system and has fibres that respond to stretch rather than pain which explains the poorly localised symptoms until the parietal peritoneum becomes involved. The sympathetic nerve supply is from the superior mesenteric plexus while the parasympathetic nerve supply is from the Vagus nerve.

3.3 Structure

The appendix is commonly referred to as the *vermiform appendix* because of its worm-like tubular structure. The length of the appendix is variable ranging from 2 - 25cm but can be up to 31cm. It is longer in children, than in adults probably due to age-related atrophy. The external diameter could range from 3 - 8mm and the luminal diameter between 1 - 3mm (Williams & Myers, 1994; Petras & Goldblum, 1996). The maximum transverse diameter of the appendix is attained by the age of 4 years. It progressively narrows with age with increasing fibrosis after 40 years.

The three taeni coli of the proximal colon converge at the base of the appendix. The anterior taenia coli is commonly used as a landmark to identify the base of the appendix. In the neonate, the characteristic haustration of the large bowel are absent appearing within the first 6months and the taenia coli are thin (Standring et al., 2005).

The appendicular wall consists of four main layers: mucosa, sub-mucosa, muscularis propria and the serosa. The mucosa is similar to the colonic mucosa and consists of the epithelial lining, the lamina propria and the muscularis mucosa. The epithelial lining is a single layer of surface epithelial cells including columnar cells with basally located nuclei, goblet cells, apical mucin and absorptive cells as well as scattered paneth and endocrine cells. The lamina propria contains crypts of Lieberkühn. The muscularis mucosa of the appendix is poorly developed unlike the rest of the gastrointestinal tract. The sub-mucosa contains a rich network of arterioles, venules, capillaries and lymphatics in a connective tissue framework. It also contains a plexus of nerves, the Meissner's plexus. The neurosecretory cells in the submucosa are few till the age of 9years. The age-related increase in the number of these cells is thought to explain the increase in number of carcinoid tumours in older patients.

The muscularis propria contains muscles which are arranged in a similar pattern as those of the small intestine. The outer longitudinal muscle fibres aggregate into the taenia coli to become continuous with them at the base of the appendix. The inner circular muscles are thicker. Between these muscle layers is the myenteric or Auerbach's plexus of nerves which is morphologically similar to the Meissner's plexus in the submucosa, unlike the rest of the gastrointestinal tract where the Meissner's plexus is thinner.

3.4 Lymphatics

The appendix belongs to the group of lymphatic organs called the Mucosa Associated Lymphatic Tissue which also includes the intestinal Peyer's patches, the tonsils and the

lymphoid follicles in the walls of the bronchi. They are thought to protect the gastrointestinal tract and the respiratory tract from recurrent infections from foreign matter and organisms entering these body cavities (Snell, 2004b). However, its role in immune protection in the gastrointestinal tract is unclear. The submucosa of the appendix contains prominent lymphoid tissue similar to that in the terminal ileum; this feature differentiates the appendix from the colon. These may become hypertrophic in the presence of inflammation and may obstruct the lumen in acute appendicitis. Lymphoid hyperplasia is at its peak during the second decade of life. This has been postulated to be the reason behind the high incidence of appendicitis in this age group. Lymphoid hyperplasia is thought to be responsible for 60% of acute appendicitis and occurs mainly in children.

The appendicular lymphatic vessels drain into the lymph nodes in the mesoappendix, the anterior ileocolic lymph nodes which often become enlarged during acute appendicitis and then into the right para-aortic lymph nodes.

3.5 Vasculature

The appendicular artery arises from the inferior branch of the ileocaecal artery and the vein drains through the ileocaecal vein into the portal venous system. The meso-appendix connects the appendix to the ileal mesentery. The artery enters the mesoappendix a short distance from the appendicular base where it gives off the recurrent branch which anastomosis with a branch of the posterior caecal artery. It is common to find accessory arteries associated with the appendix (Standring et al., 2005). These must be handled carefully to limit blood loss during appendicectomy. The appendicular artery runs through the meso-appendix along its free edge and lies on the appendix wall in its distal aspect. The anastomosis at the base gives rise to a good blood supply but it is an end artery from the midpoint to distal appendix where its close proximity to the appendix makes it susceptible to thrombosis as the appendix enlarges during acute inflammation.

4. Aetiology of appendicitis

The aetiology is multi-factorial and may involve interplay of factors including obstruction, infections, ischaemia and hereditary factors. Obstruction from lymphoid hyperplasia is a common causal factor and this has been addressed in detail elsewhere in this chapter. A faecolith is a small stone-like mass of stool. Its formation starts with entrapment of vegetable fibre. Like the colonic mucosa, the appendix mucosa is well equipped for water absorption resulting in concentration of its contents with mucous entrapment. Several layers of deposits eventually result in increase in diameter and a faecolith diameter of 1cm leads to appendicular obstruction. Faecoliths are less common in children than in adults; 7.7% versus 42% (Gillick et al., 2001). A primary neoplasm of the appendix is found in 0.5-1.0% of specimens removed for appendicitis. The neoplasm could be mucinous adenoma, mucinous adenocarcinoma, colonic type adenocarcinoma, non-Hodgkins lymphoma, classical carcinoid tumour, or goblet cell carcinoid tumour. 30-50% of patients with carcinoid present with acute appendicitis, being associated with obstruction of the appendix in 25% of cases. An appendicular diameter greater than 15mm should raise suspicion as to the presence of an appendicular tumour (Pickhardt et al., 2002). Carcinoid tumours mostly are located in the distal tip of the appendix, taking the form of a bulbous solid tumour of about 2-3cm diameter. In children it is usually of a diameter of less than 2cm. 75% is at the tip; 20% mid-

appendix and 5% at the base. The incidence of carcinoid tumours in surgical specimens is about 0.08-0.7%; 0.2-0.5% in children. It is the most frequent tumour of the gastrointestinal tract in childhood and adolescence. It occurs more in white females. A mucocele is a dilated appendix filled with mucinous substance. It may present as an obstructed appendix containing inspissated mucin or be a consequence of mucinous cystadenoma or mucinous cystadenocarcinoma.

Bacterial and fungal infections can also lead to appendicitis. The bacteria involved are usually of a mixed aerobic and anaerobic population; most commonly *Bacteroides fragilis* and *Escherichia coli*. Others include *Streptococcus milleri* (associated with a seven-fold increased risk of abscess formation) and *Campylobacter jejuni* (Fenoglio-Preiser et al., 2008). Infections may further lead to fibrin thrombi which can block the small appendicular vessels leading to secondary ischaemia. The appendix is particularly prone to ischaemic insult because the appendicular artery is an end artery beyond the base of the appendix. Torsion of the appendix may occur resulting in ischaemic appendicitis; but, this condition is rare (Fenoglio-Preiser et al., 2008). Familial aggregation of appendicitis suggests polygenic inheritance and the appendicitis usually manifests before the age of 10 years. The hypothesis of appendicitis being associated with low fibre diet is weakened by the finding in Africa that populations on high fibre diet did not have a lower appendicitis rate (Naaeder & Archampong, 1998).

5. Pathophysiology

The human appendix secretes up to 2ml of clear fluid containing mucin, amylase and proteolytic enzymes, which may be produced by bacteria each day. The appendicular aperture is guarded by semilunar mucosal folds which give it a valve effect. The basal intraluminal caecal pressure is approximately 5cm of water while the appendicular intraluminal pressure ranges from 15 - 25cm of water creating a pressure gradient of about 10cm of water. This is believed to keep gut contents from entering the appendicular lumen.

Experimental studies have shown that the obstruction of exteriorised human appendices can raise the intra-luminal pressures to an extent that exceeds the perfusion pressure in the vascular plexus within the wall of the appendix. The distal end of the appendix is most vulnerable to this reduction in blood flow. Electrical stimulation of the appendix has been demonstrated to cause closure of the ileocaecal valve (Williams and Myers, 1994). This may be a contributing factor to the nausea and vomiting associated with acute appendicitis.

The peritoneum consists of a continuous visceral and parietal layer. Both layers are of mesodermal origin, but develop separately with independent nerve supplies. The visceral layer covers the intra-abdominal organs and is supplied by autonomic nerves. The parietal peritoneum lines the under surface of the abdominal wall and is supplied by somatic nerves. Pathways for pain differ in each layer and so also the quality of pain. Visceral pain has a dull aching character, often crampy and may be associated with nausea and sweating. Parietal pain on the other hand is mostly sharp, severe and persistent in nature. Visceral organs have limited response to pain stimulus but the stretching of the mesentery and irritation of the parietal peritoneum produces severe pain.

Visceral afferent fibres carrying sensation of distension and pressure are responsible for the initial pain of appendicitis, poorly localised initially and referred to the periumbilical region. Afferent nerve fibres from viscera enter the dorsal horn of the spinal cord along with afferent nerve fibres from cutaneous structures of the corresponding dermatome. These two groups of nerve fibres overlap at the synaptic junctions in the dorsal horn leading to the

phenomenon of referred pain whereby pain is perceived by the brain as arising from the corresponding cutaneous structures. Nerve fibres decussate and travel up to the thalamus along the lateral spinothalamic tract and then onwards to the cerebral cortex. Increased intravisceral pressure by stretch, distension or contraction of the viscus especially against an obstruction leads to visceral pain. The dermatomal distribution associated with the midgut relates to the umbilical region, with nerves entering the spinal column at the tenth thoracic spinal segment (T10). The midgut extends from the second part of the duodenum to the midpoint of the transverse colon. Therefore, pain arising from the midgut is felt initially in the umbilicus before the parietal peritoneum becomes involved (Klish, 2006).

In 1886, the American pathologist - Reginald Fitz became the first person to describe the pattern of the pathophysiological basis of appendicitis in literature. He noted that the condition started with onset of inflammation, followed by perforation, abscess formation and peritonitis (Morrow & Newman, 2005). Appendicitis is commonly secondary to luminal obstruction which is demonstrable in 50-80% of cases (Turner, 2010). As stated previously, the commonest cause of luminal obstruction in children is lymphoid hyperplasia or hypertrophy which mostly results from dehydration and viral infection. Faecoliths take several years to form. They are commoner in older children and may cause direct focal or diffuse mucosal ulceration. The stasis that results creates an environment which favours bacterial proliferation and also causes ischaemic injury.

The fore-going results in inflammatory changes including oedema, neutrophilic infiltration of the lumen, muscular wall and periappendicular soft tissue. In early appendicitis, subserosal vessels become congested and perivascular neutrophilic infiltrate develops within all the layers of the wall leading to loss of lustre which gives the appendix a dull granular erythematous appearance. Therefore, the histological diagnosis of acute appendicitis must demonstrate neutrophilic infiltration of the muscularis propria not just within the lumen (Turner, 2010). Figure 2 illustrates the sequence of events that follow appendicular obstruction.

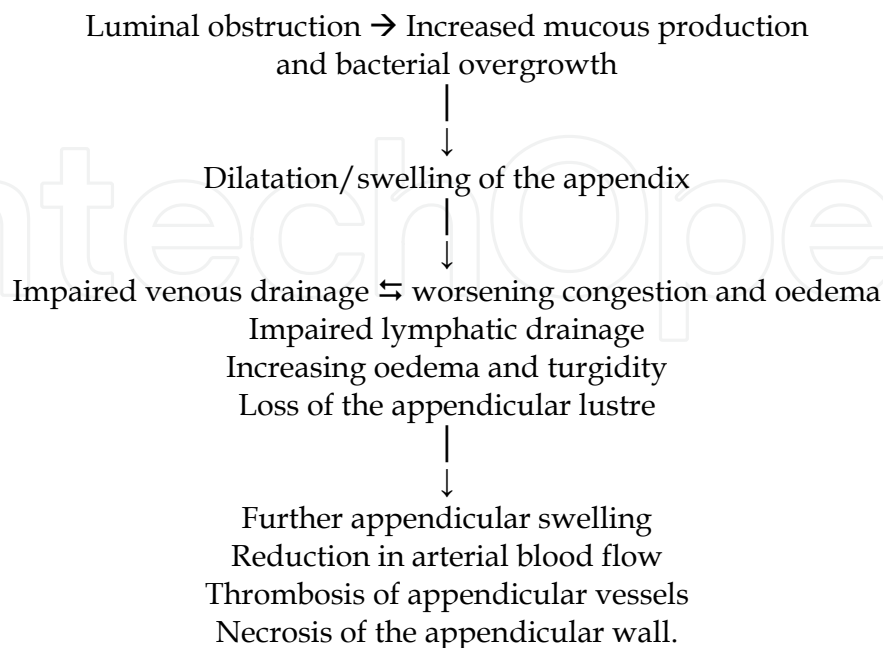


Fig. 2. Sequence of events that follow appendicular obstruction

More severe inflammation results in prominent neutrophilic exudate which generates serosal fibrino-purulent reaction that gives the appendix the creamy yellow appearance associated with this stage of the inflammatory process. If the inflammatory process is not curbed at this stage, it progresses to formation of focal abscesses within the appendicular wall; this is acute suppurative appendicitis. Progressive increase in the intraluminal pressure leads to venous flow compromise. Laplace law suggests that the wall tension of a tubular structure is directly proportionate to the thickness of the wall divided by the square of the radius. Further increase in the wall tension culminates in necrosis of the appendix. Further inflammation leads to the formation of large areas of haemorrhagic ulceration with gangrenous necrosis that extends to the serosal layer; this is acute gangrenous appendicitis. Rupture of the appendix follows with suppurative peritonitis (Turner, 2010). The risk of perforation of the appendix rises with the duration of symptoms being about 30% for <24hours and greater than 70% in >48hours (Swain, 2005). The perforation rate also varies with the age of the child. The average rate is 30-45% which may be as high as 80% in those under 5years and nearly 100% in those under 2years (Morrow & Newman, 2005; Stevenson, 2003).

The normally glistening serosal and peritoneal surface becomes dull and lustreless; serous or slightly turbid fluid begins to accumulate within 2-4hours of the onset of inflammation. With progression of the inflammatory process creamy suppurative material with increasing viscosity accumulates. At this point, the process can take the form of localisation by the omentum and viscera to be controlled in a small area of the abdominal cavity, or become widespread filling the entire abdomen. The cellular response results in the formation of dense collections of neutrophils and fibrinopurulent debris that coat the viscera and abdominal wall at the site of the inflammation (Turner, 2010). The greater omentum is smaller in children and only at the level of the umbilicus in the neonate containing small amount of fat and therefore providing limited omental protection (Standring et al., 2005).

Inflammation of the peritoneum and surrounding intra-abdominal organs follows with peritonitis. Bowel obstruction may result from the adhesive inflammatory process. Irritation of the rectosigmoid may lead to enteritis manifesting with frequent loose stools. Irritation of the bladder by the inflammatory process may cause dysuria, increased frequency of micturition and urgency simulating urinary tract infection. Severe inflammation may lead to haemorrhagic cystitis.

The inflammatory process may also be accompanied by increased tissue porosity or permeability with bacterial translocation. Peritonitis from bacterial translocation across the porous inflamed wall of the appendix may still occur in the absence of obvious perforation or faecal contamination.

6. Histopathological features

In the acute phase, serosal injection leads to loss of the normal appendiceal lustre; if inflammation progresses purulent exudate forms on the surface of the appendix followed by perforation. There may be fecolith within the appendix lumen; or the lumen may be distended with pus or mucous. *Enterobius vermicularis* may be present in the lumen and sometimes within the mucosa where they may induce a granulomatous reaction. They can be identified on microscopy by their lateral spines evident on the cross section of the transected worms (Sebire et al, 2010).

Histological features of acute appendicitis include

- Acute transmural inflammatory aggregation of neutrophils and eosinophils
- Hyperplasia of mucosal lymphoid tissue
- Haemorrhagic changes in the mucosa
- Pus within the appendicular lumen
- Mucosal ulceration
- Acute serosal inflammation
- Haemorrhagic necrosis of the appendicular wall
- Adenovirus inclusions may be seen in the epithelial cell nuclei
- There may be vasculitic changes with or without thrombi within the vessels in the wall
- Following interval appendicectomy, there may be chronic inflammatory changes with fibrosis of the wall with or without occlusion of the appendicular lumen (Sebire et al, 2010).

Inflammation without mucosal ulceration is of uncertain significance. In acute intraluminal appendicitis, there is increased neutrophil presence in the appendicular lumen with no evidence of mucosal infiltration. Similar findings have been documented in incidentally removed appendix specimens (Feneglio-Preser et al., 2008).

The issue of sending normal appearing appendix for histological analysis is supported by the fact that certain conditions may present in the appendix with macroscopically normal appearance. These include polyarteritis nodosa, tuberculosis, amoebiasis, parasitic infestations including bilharziasis, schistosomiasis, trichuriasis, ascariasis and clonorchiasis, actinomycosis as well as epithelial tumours. 2 - 5% of macroscopically normal appendices may have significant unsuspected pathological condition (Williams & Myers, 1994). Furthermore, neurogenic appendicopathy may appear macroscopically normal and can only be diagnosed with certainty on histological analysis (Zaupa et al., 2011).

7. Microbiological perspective

Peri-appendicular abscesses may occur from bacteria usually present in the bowel including *Escherichia coli*, *Proteus* species, other enterobacteriaceae, *Bacteroides* species, anaerobic cocci and other anaerobes. Infections are therefore commonly polymicrobial. The resultant secondary peritonitis commonly yields *Escherichia coli* and other enterobacteriaceae and anaerobes from intra-operative peritoneal pus swabs. Some authors argue that the precise value of peritoneal swabs in many cases of secondary peritonitis is difficult to assess because the bacteriology seldom influences antibiotic treatment which is given empirically on clinical grounds for short duration, often ending within 2-3 days before the full bacteriology results become available (Baker et al, 2004).

The gastrointestinal tract like other portals of entry into the human body, has a normal flora that helps protect it against pathogenic micro-organisms. The flow rate reduces from the small intestine to the large intestine giving the bacteria more time to colonise and reproduce leading to higher concentration of the organisms. The amount of flora increases in number and varies in type as the gastrointestinal tract progresses from the oral cavity to the anorectum. About one thousand species of micro-organisms are present in the large intestine. Approximately 20% of the volume of faecal matter in the healthy person consists of bacteria, most of which come from the colon. The terminal ileum flora is similar to colonic flora. More than 90% of these are anaerobes, mostly *Bacteroides*, *Fusobacterium*, *Eubacterium* and *Clostridium*. Others include *E. coli*, enterococci, yeasts and numerous

others (VanMeter et al, 2010). Organisms commonly isolated from peritoneal microbiological tests in secondary peritonitis are mostly anaerobes which outnumber aerobes in the bowel by a thousand fold (Forbes et al, 2007).

Enterobius vermicularis is the most common nematode infection in humans and can be found in up to 3% of appendices in the USA. Schistosomiasis of the appendix is rare. *Strongiloides stercoralis* infection results in eosinophilic appendicitis. Viral appendicitis has been associated with measles in the prodromal phase. Other viruses that may cause appendicitis are adenovirus and gastrointestinal cytomegalovirus infection. Acute infectious mononucleosis and Epstein Barr virus infection rarely may give rise to abdominal pain (Petras & Goldblum, 1996).

8. Diagnosis

8.1 Clinical presentation

Making a diagnosis of acute appendicitis in children can be a difficult task even for the experienced paediatric surgeon. Negative appendicectomy rate was found to be higher among children operated upon in district general hospital than in a specialist paediatric centre, 20% versus 4% (Whisker et al., 2009). Chang et al., (2010) found that approximately 12-15% of paediatric appendicitis were missed at the first visit to the emergency department with the rate of perforation of 73.1% versus 49% in those diagnosed at first presentation. The duration of symptoms was longer in the former group and the rate of perforation higher the longer the duration of symptoms.

Generally, clinical symptoms are the patient's report of the manifestation(s) of dysfunction in the normal body physiology. Thus, the younger the child, the less accurate the report of symptoms can be expected to be. Neurodevelopmental immaturity precludes accurate understanding, interpretation and description of symptoms by children particularly those younger than eight years of age. Not surprisingly, this is the age group that commonly presents late with advanced appendicitis. Furthermore, parents of infants often ascribe febrile illness and vomiting to "teething" and do not seek medical evaluation early. The clinical symptoms of appendicitis are often secondary to luminal obstruction leading to colicky abdominal pain at onset which progresses to constant pain with progression of the inflammatory process. Nausea and vomiting are commonly present. Clinical signs are discussed in detail later in this chapter and often include tenderness in the right lower quadrant of the abdomen.

Advanced appendicitis is often associated with delayed presentation especially in children below the age of five years and also with retroileal, retrocolic or pelvic appendicitis. Irritation of pelvic structures may produce symptoms and signs suggestive of urinary tract infection or enteritis.

8.2 History

Rigorous pursuit of a detailed history is invaluable in the diagnosis of appendicitis. In children, patience is an indispensable virtue and a rushed history increases the risk of misdiagnosis. Possession of the clinical skills required for eliciting appropriately focused and chronologically accurate history from the child and parent is key to early diagnosis. The surgeon therefore has to make the most of open-ended and direct questioning at appropriate key moments of the history taking applying sensitivity to the emotional climate.

Background information of the child's usual status of health should be obtained. The onset of the current symptoms should be carefully ascertained. Site of onset of abdominal pain and its present location may suggest migration of pain which may be associated with acute appendicitis; usually starting in the peri-umbilical region, the pain later localises to the region of the right iliac fossa. In addition it is often preceded by nausea or vomiting. Characterising the abdominal pain is key to accurate diagnosis of its source. The onset of the pain associated with acute appendicitis is often gradual, progressively worsening. It may be intermittent initially then sharp and constant within a few hours. Children may not give this typical presentation; even the older ones may become very quiet and distracted by other issues including pain, fear, strange environment with unfamiliar people or even psychosocial circumstances in the family.

The usual duration of symptoms at presentation is 24 - 36 hours. There may be a history of pain being made worse by road bumps on the way to the hospital. This suggests the presence of rebound tenderness. Enquiry into the presence of associated factors should be made. Nausea and vomiting may be present in up to 90% of patients. Diminished appetite may be absent in children with appendicitis. Diarrhoea may suggest irritation of the anorectum by inflamed tissue in the rectovesical pouch. The sigmoid colon is often redundant in children, with a tendency to loop into the pelvis. Consequently, it may come in contact with an inflamed appendix manifesting as diarrhoea. Care must be taken not to mistake this for gastroenteritis. Dysuria may be associated with appendicitis from irritation of the urinary bladder by an inflamed pelvic appendix.

The history should also explore other possible causes of abdominal pain. Symptoms of upper respiratory tract infection may suggest mesenteric adenitis. Cough may suggest pneumonia with referred abdominal pain as a diagnosis. Vulvovaginal irritation with or without vaginal discharge may suggest pelvic inflammatory disease. Abdominal pain may also be referred from an acute scrotal condition and older boys in particular do not offer this important information without direct questioning. Constipation may produce symptoms in children that may imply the presence of pathology and should be considered. In addition, enquiry should be made about any previous history of abdominal pain, previous abdominal surgery, recent foreign travel, current or recent medications as well as the presence of similar condition in other family members or pupils in the same school.

8.3 Differential diagnosis of acute abdominal pain in children

The cause of acute abdomen in children may vary according to sex and age. Possible causes are presented below. The list is by no means exhaustive and not in order of frequency. In addition, some conditions may co-exist.

8.3.1 Infants

- Viral enteritis
- Intussusception
- Pyelonephritis/ other urinary tract infection (UTI)
- Gastro-oesophageal reflux
- Bacterial enterocolitis
- Chest infection
- Appendicitis
- Pyloric stenosis

Strangulated hernia of the anterior abdominal wall
Testicular torsion
Mesenteric cysts
Ruptured abdominal tumour
Pancreatitis
Meckel's diverticulitis
Hirschsprung's disease with or without enterocolitis
Poisoning
Trauma
Non-accidental injury

8.3.2 Children aged between 2-10years old

Meckel's diverticulitis
Cystitis
Pyelonephritis
Viral enteritis
Bacterial enterocolitis
Appendicitis
Non-specific abdominal pain
Crohn's disease
Abdominal trauma, including non-accidental injury
Chest infection
Mesenteric adenitis
Neutropenic enterocolitis
Pancreatitis
Ruptured intra-abdominal tumours
Poisoning

8.3.3 Children above 11years old

Viral enteritis
Bacterial enterocolitis
Appendicitis
Non-specific abdominal pain
Mesenteric adenitis
Pelvic inflammatory disease
Tubo-ovarian cysts
Tubo-ovarian abscess with or without rupture
Torsion of an ovarian cyst
Haemorrhage in an ovarian cyst
Endometriosis
Mittelschmerz
Crohn's disease
Pancreatitis
Neutropenic enterocolitis
Chest infection
Haematocolpos

Peptic ulcer disease
Psychosomatic condition
Trauma
Ectopic pregnancy
Dysmenorrhoea
Gall stone disease including cholecystitis, biliary colic, cholangitis
Urinary tract infections
Neuronal abdominal wall pain including shingles, spinal or nerve root problem, iatrogenic peripheral nerve injury
Spontaneous rectus sheath haematoma

8.4 Physical examination

A thorough physical examination would compliment the clinical suspicion formed from the reported symptoms. A general examination of the child with abdominal pain is imperative and requires experience in identifying the sick child. The child's appearance should be noted - body habitus, facial expression, position, willingness or reluctance to move, alertness, pallor and whether the child is flushed or sweaty. Assess the child's pulse for volume and rate. The temperature in early appendicitis may be normal or mildly raised. A temperature above 38°C should prompt further investigation or evaluation to exclude other causes. Ears, throat and lymph nodes should be evaluated. Tachypnoea, recessions, shallow breathing and flaring of the alar nasi may suggest a respiratory tract problem or be secondary to circulatory system contraction. An antalgic gait, leaning to right side, limping on the right leg and slow motion are all cues to the presence of abdominal pathology. Flexion at the hip suggests abdominal wall discomfort with or without peritoneal irritation. Younger children typically poorly localise pain. Most of the under five-year-olds point to their umbilical region as the site of all pain; perhaps because the umbilicus is a central feature with a unique appearance that sets it out as a point of focus which captures the child's attention. The demonstration of certain clinical signs may further qualify the pain but atypical abdominal pain is seen in about 40 - 45% of patients. One should beware of the child who is on antibiotic therapy for other presumed infection who presents with attenuated features of appendicitis.

The child's anxiety should be taken into consideration and reducing the number of people in the room or creating a distraction may help. Distraction may be accomplished with the help of a paediatric play therapist. Building a rapport with the parents gains the child's trust and allays anxiety. A warm child-friendly environment is desirable and is common practice in many paediatric specialist centres. Focused examination of the abdomen should commence with inspection for distension, abdominal wall excursions with respiratory activity, hernia orifices, external signs of trauma, scars or visible peristalsis. Percussion of the abdomen may reveal the presence of rebound tenderness suggesting peritonism. Palpation of the abdomen should in the first instance be superficial and general, starting away from the site of pain. This gives the examiner the opportunity to explore all the quadrants of the abdomen and improves the chance of identifying non-appendicular pathology. This gentle approach reassures the child and allows him or her to trust the examiner, and also to relax the abdominal wall. Guarding may be present as well as tenderness. Depending on the child's level of development and co-operation, he or she may be encouraged to cough, laugh, distend the abdomen or retract the abdominal wall. Rebound tenderness may be present if

these activities elicit pain. This is followed by deep palpation to explore the presence of an intra-abdominal mass. The character of any palpable mass should be evaluated – soft, firm, mobile or fixed to surrounding structures, regularity of its palpable surface and possible organ of origin. Due to the variability of position of the appendicular tip as previously discussed, the parietal pain may be related to the right upper quadrant, right loin or pelvis. The practice of gently rocking the pelvis from side to side is still practised by some surgeons and may elicit rebound tenderness.

Auscultation should evaluate bowel sounds but is generally not very useful. Bowel sounds may be absent or diminished in advanced inflammation. However, the presence of normal bowel sounds does not exclude advanced appendicitis. For the tense anxious child, using the stethoscope as a palpation tool can help with the evaluation of the abdomen. Also palpating over the child's hand can play the same role. An auscultation of the chest is part of the evaluation for probable appendicitis to rule out or confirm chest pathology. In the presence of positive chest signs, the abdomen should still be carefully evaluated for the presence of possible co-existing intra-abdominal pathology.

Children are not good at responding to the question – “Does this hurt?” The young child is very likely to respond in the affirmative when asked such questions. Conversely, beware of the older child who denies any pain for fear of being admitted into the hospital. The child with acute appendicitis would often be reluctant to move and may express discomfort by facial grimace or tears rather than verbally. Therefore careful observation of the child's facial expression and non-verbal responses is paramount to the interpretation of clinical signs.

Right lower quadrant pain, tenderness and rebound tenderness should be elicited. The traditional method of eliciting rebound tenderness by suddenly withdrawing the hand following a deep palpation, is not advisable in children. It results in sudden severe pain which may make the child lose confidence in the doctor. Rather, rebound tenderness is usually tested for by asking the child to increase the intra-abdominal pressure by coughing (Dunphy sign). This brings the inflamed appendix or surrounding tissues to the anterior abdominal wall manifesting as rebound tenderness. Similarly, the abdominal pain may also be exaggerated by attempting to move the abdominal wall outwards – “blowing out the abdomen” or moving the abdominal wall inwards – “sucking the abdomen inwards”. McBurney's sign is the presence of maximum tenderness over the McBurney's point. This was first described by McBurney who was the first to recommend appendectomy for treatment of appendicitis (Morrow, 2005).

Rovsing sign is positive if there is perception of pain in the right lower quadrant on palpation of the left lower quadrant. Obturator sign may be positive. To elicit this sign, the patient lies supine with the right knee and hip flexed to 90degrees. The examiner, holding the patient's right ankle in the right hand, places the left hand on the knee. Outward rotation of the flexed right knee causes internal rotation of the right hip which causes the obturator internus to become tense. The test is positive if pain in the right lower quadrant is elicited; usually in appendicitis in the pelvic or obturator positions where the appendicular tip lies over the obturator fascia covering the obturator internus muscle. The iliopsoas comprising of the powerful hip flexors – iliacus and psoas major, can become inflamed in appendicitis which is retrocaecal and therefore retroperitoneal giving a positive psoas or iliopsoas sign. This can be evaluated by two approaches. With the patient lying supine, the examiner's hand is placed just above the right knee and the patient asked to flex the right hip against resistance. Eliciting pain means positive psoas sign. An alternative method is to have the patient lie on the left side, if hyper-extension on

the right hip elicits pain, the sign is positive. A psoas abscess from a different cause would elicit similar pain (Liu & McFadden, 2003).

The introduction of the algometry for the diagnosis of acute abdominal pain in children has been welcomed by many paediatric surgeons (Vajcner et al., 2011). This device is used to predict acute appendicitis by observing the abdominal tenderness threshold which is the minimum pressure applied to the anterior abdominal wall to produce discomfort. With regards to diagnosing acute appendicitis, when combined with other clinical findings, it was found to have a sensitivity of 82% specificity of 73% and positive likelihood ratio of 3.03. This new innovation may become popular in the future but it needs evaluation through appropriately designed clinical trials.

9. Investigations

In cases where the clinical history or physical signs are atypical and inconclusive for the diagnosis of acute appendicitis, various investigations may be used to complement the clinical findings, strengthen the diagnosis and exclude the presence of alternative pathology. They may also aid the peri-operatively management of the patient. These may be bed-side, laboratory, radiological or laparoscopic investigations.

There is no one investigation that can accurately diagnose appendicitis every time. The clinical value and economic benefit of laboratory investigations for the diagnosis of appendicitis has been the cause of much debate (Liu and McFadden, 2003).

The general rule to the selection of an investigation is that it would:

- Complement the history and examination
- Determine what other clinical tests may be required
- Alter treatment approach.

An ideal diagnostic test should offer the following benefits:

- High level of accuracy: high sensitivity and specificity
- Capable of assessing the extent of disease
- Cost effective: cost of investigation should be less than the consequences of treatment without the benefit of the information derived from the examination
- Short length of study
- Quick and easy access to result or diagnostic information
- Non-invasive
- Suited to local needs, resources and available expertise (Hernanz-Schulman, 2010)

9.1 Bedside investigations

Bedside investigations can be done alongside the initial evaluation. Urinalysis with urine dipstix may suggest urinary tract irritation or infection, diabetes or pregnancy-related conditions. A bedside blood sugar test is a quick check for possible diabetic ketoacidosis.

9.2 Laboratory investigations

Laboratory tests commonly used to evaluate acute abdominal pain include full blood count, electrolyte studies, C-reactive protein (CRP), urine microscopy and culture, liver function tests and serum amylase level. Approximately two-thirds of the patients would have elevated white blood cell (WBC) count with neutrophilia but this is not specific to

appendicitis. The relative neutrophil count may be above normal range even in the presence of a normal total white blood count. Serum levels of inflammatory markers may not be raised in early appendicitis. Repeating the investigations at least 6 hours after the initial test may increase the diagnostic yield (Wu & Fu, 2010).

Laboratory urine microscopy would assess for presence of pyuria and micro-organisms. Urinalysis may be abnormal in up to 48% of patients with acute appendicitis. This may show microscopic haematuria, pyuria or proteinuria (Rothrock & Pagane, 2000). Pyuria may arise as a consequence of irritation of the urinary bladder or the ureter by the inflamed appendix or surrounding inflamed tissue. Serum or urine β hCG tests should be performed in young women of child-bearing age and if positive, an ectopic pregnancy should be excluded by further evaluation involving the gynaecologist. Moreover, pregnancy and appendicitis can co-exist.

Serum electrolytes and creatinine levels should be requested and any abnormalities corrected appropriately. Blood glucose should be obtained and any abnormality appropriately managed. It must be borne in mind that diabetic ketoacidosis may present as acute abdomen. The CRP is an acute phase reactant synthesized in the liver which is often raised within 12 hours of an acute inflammatory process. It may be raised in 50-90% of patients with acute appendicitis but again it is non-specific. Serum levels of inflammatory markers including CRP and WBC count cannot be reliably used to distinguish between acute appendicitis and other causes of abdominal pain (Dalal et al., 2005). They are more effective in supporting a clinical diagnosis of appendicitis than excluding the diagnosis (Birchley, 2006).

9.3 Radiological investigations

Radiological investigations should be tailored to the specific presentation and possible differential diagnoses. A chest radiograph may be useful in the presence of clinical suspicion of lower respiratory tract infection or complications there from.

9.3.1 Plain abdominal radiograph

Plain abdominal radiographs are not commonly used in the evaluation of abdominal pain in children particularly when appendicitis is felt to be a likely cause. There are several reasons for this stance, one being that children present with abdominal pain commonly and obtaining an abdominal radiograph each time may lead to a significant amount of radiation. Extremes of age are more sensitive to radiation and it should be avoided as much as possible. The average plain abdominal radiograph exposes the patient to a typical effective radiation dose of 0.7 millisieverts (mSv), equivalent to 4 months of natural background radiation which is equal to 35 chest radiographs (Hampson and Shaw, 2010). It is of limited use in the evaluation of abdominal pain in children but it may be useful in atypical presentation where no obvious diagnosis can be made after adequate history, examination and laboratory investigations. It is noteworthy that only 10% of patients with an acute abdomen have abnormalities on plain radiographs. A study in the adult population demonstrated that the specificity of abdominal radiograph for acute appendicitis can be as low as 0% (Hampson & Shaw 2010).

An adequate abdominal radiograph should include the diaphragm and pelvis; antero-posterior and lateral shoot through views may be required if the patient is unable to sit up. The preperitoneal fat often gives rise to a fine line of fat on a plain abdominal radiograph. Inflammation of a retrocaecal appendix may be associated with infiltration of the preperitoneal fat and lead to a focal absence of this fine line of fat. In addition, a mass

between the preperitoneal fat and ascending colon, gas in the appendix lumen, a faecolith above the anterior superior iliac spine combined with haustral irregularity of the ascending colon can raise the suspicion of appendicitis on plain abdominal radiograph. As stated earlier faecoliths are uncommon in children. Retrocaecal extraperitoneal gas suggests perforation. Extraluminal gas on radiograph from a perforated appendicitis may be demonstrable in 1% of perforated cases. Loss of shadow of the right psoas suggests advanced appendicitis with retroperitoneal inflammation.

An abdominal radiograph may also demonstrate dilated loops of bowel suggesting obstruction or extraluminal gas in perforation of abdominal viscus. Bowel obstruction in the absence of features of peritonism may be secondary to adhesive obstruction. It has a significant role in the evaluation of the neonate with suspected intra-abdominal pathology where it may demonstrate radiological features of necrotising enterocolitis as clinical signs would not conclusively demonstrate perforations. In addition, it may demonstrate the renal outline with a huge outline being suggestive of obstructive uropathy.

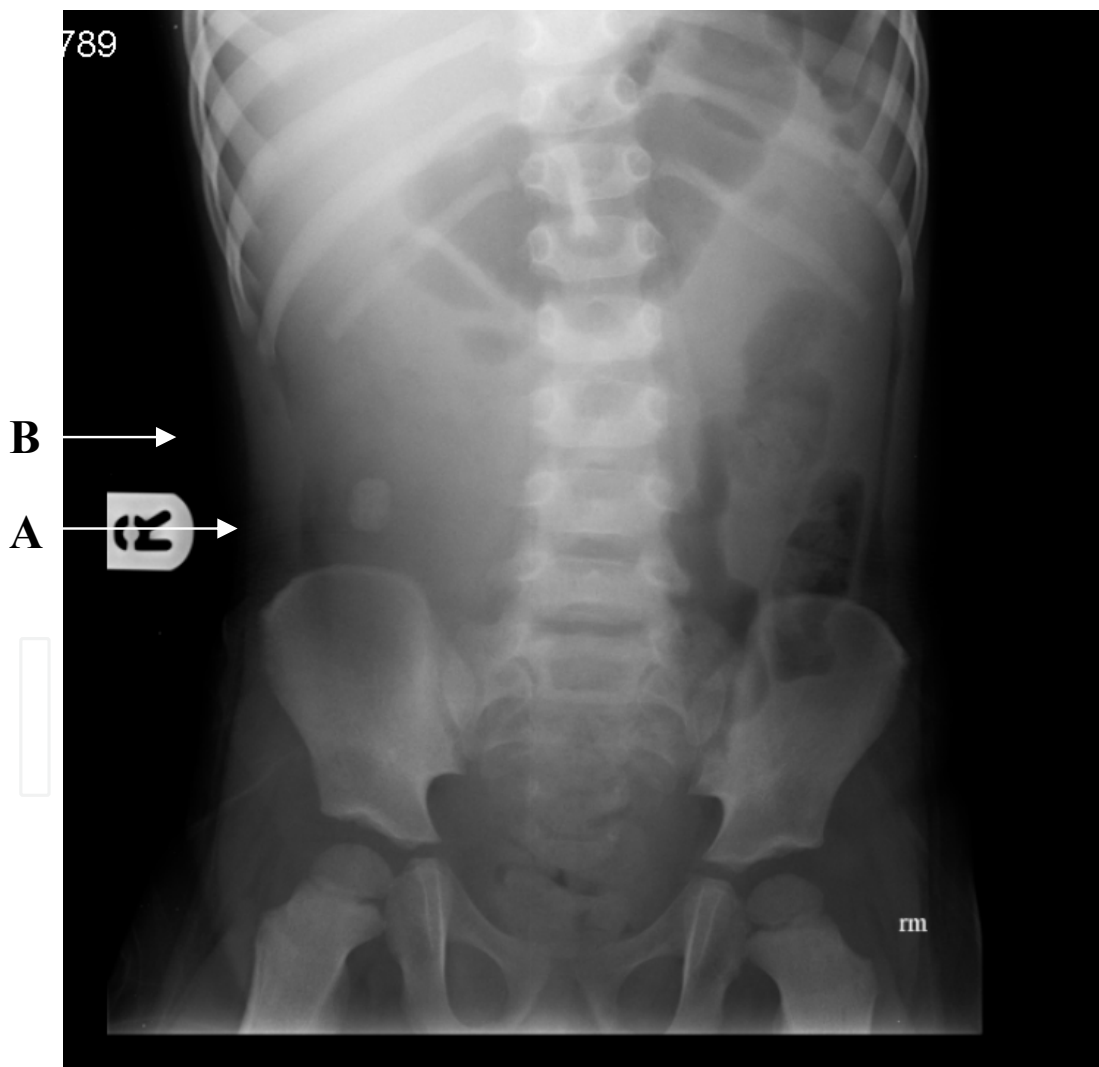


Fig. 3. Plain abdominal radiograph of a 2year old showing: A. Faecolith; B. Focal absence of fine line of preperitoneal fat (uninterrupted on the left side). Note also, the absence of bowel gas in the same region.

9.3.2 Ultrasonography

Where clinical observation by an experienced paediatric surgeon over a 48hr period still reveals equivocal diagnosis and suspicion of appendicitis persists, imaging is recommended, mainly by way of abdominal ultrasonography (Lander, 2007). Ultrasonography for the evaluation of appendicitis was introduced by Puylaert in 1986. It is a useful investigation in the further evaluation of abdominal pain with atypical and inconclusive findings. Some authors suggest that its specificity and sensitivity may be higher in children than in adults (Rothrock & Pagane, 2000). This is particularly relevant to peripubertal and older girls where ovarian pathology may mimic appendicitis. Even a left pedunculated ovarian cyst could present with right-sided symptoms if it assumes a right lower quadrant position. Abdominal ultrasonography can usually be performed without any sedation and the sonographer can communicate with the child and ask where the pain or tenderness is maximal. However, this may be distracting in children who localise pain poorly. The closeness is reassuring to the child and also allows the sonographer to observe the child's facial expression or reaction to contact with the examination probe. Appropriate application of the probe relies heavily on co-operation from the patient and the graded compression can be limited by the presence of guarding. In addition, ultrasound is operator dependent and has reduced efficacy in obese patients. It can achieve up to 98.5% sensitivity, 98.2% specificity, 98.0% positive predictive value and 98.7% negative predictive value in experienced hands (Strouse, 2010). A repeat ultrasound in case of persisting clinical borderline suspicion may increase diagnostic yield (Schuh et al., 2011).

Ultrasonographic features suggestive of appendicitis include:

1. Rigid non-compressible appendix
2. Tenderness on attempted compression
3. Non-peristalsing appendix
4. Appendicular wall thickness of > 6mm
5. Distension of the appendicular lumen
6. Presence of abscess in the peri-appendicular region
7. Increased amount of intraperitoneal fluid
8. Inflammatory changes in surrounding tissues
9. Discontinuity of the appendicular wall
10. Extruded faecolith
11. Thickening of ileum or caecum which may represent part of the inflammatory mass around the inflamed appendix but may also suggest a diagnosis of Crohn's disease.

9.3.3 Computed Tomography (CT)

CT has been demonstrated to be more effective than ultrasonography in the diagnosis of appendicitis and evaluation of abdominal pathology in general. The radiation load from an abdominal CT remains a hindrance to its widespread application in children. The typical effective radiation dose from a CT of abdomen/pelvis is 10 mSv (Hampson and Shaw, 2010). For a single abdominal CT study in a 5 year old child, the life time risk of radiation induced malignancy would be 26.1/100 000 in girls and 20.4/100 000 in boys.

Reported CT sensitivity is 79-98%, increased with intravenous contrast. Luminal contrast may further improve its sensitivity (Theoni and Thornton, 2007). Kaiser et al., (2002)

demonstrated that compared to graded compression ultrasound in acute childhood appendicitis, CT sensitivity is 97%, with accuracy of 95%, negative predictive value of 92% while ultrasound sensitivity was found to be 80%, accuracy of 89% and negative predictive value of 88%. CT is also preferable in obese patients and those with significant ileus or bowel gas. It was found to lead to a reduction in negative appendicectomy rates in children. The negative appendicectomy rate without imaging was found to be 14%, 17% with ultrasound but reduced to 2% with CT. No difference was observed in perforation rate (Theoni and Thornton, 2007). Lower abdominal CT should be performed with intravenous contrast where possible. Features suggesting appendicitis include (Theoni and Thornton, 2007):

- Appendicular diameter of more than 6mm
- Presence of inflammatory changes in the peri-appendicular area combined with a dilated or thickened appendix
- Inflammatory changes extending to the psoas muscle
- A calcified faecolith may be seen
- There may be free fluid with or without an enhancing rim suggesting abscess
- Thickened caecum and terminal ileum with inflamed appendix
- Periappendicular fat stranding
- Air in the appendix wall, retroperitoneum or abdomen associated with inflammatory changes in the area around the appendix
- Advanced appendicitis may give CT findings of pericaecal phlegmon or abscess
- The right lower quadrant may demonstrate free air which suggests perforation.

Early appendicitis may not be distinguishable from normal appendix because the features mentioned above would be absent. Consequently, failure to visualise the appendix radiologically does not rule out acute appendicitis. It is noteworthy that air within the appendix lumen may be normal in the absence of other features of periappendicular inflammation and the appendix may not be demonstrable in the presence of focal inflammatory changes of the appendix. Thickening of the wall of the appendix observed on axial images as three concentric rings or as single thick ring of enhancement with or without periappendicular soft tissue stranding may be the only feature present. Disadvantages of CT include the following:

- Risk of radiation.
- CT costs more to perform
- Patients are at risk of allergic reaction to the contrast agent
- It takes longer to perform
- It may have a lower sensitivity in patients with low body fat (Rothrock & Pagane, 2000).

9.3.4 Radionuclide scanning

Radionuclide scanning using ^{99m}Tc -hexamethylpropyleneamine oxime (HMPAO) labelling of patient's leucocyte or technetium- 99m -labelled antigranulocyte antibodies can be used to evaluate abdominal pain in children presenting with equivocal clinical and laboratory findings. Accumulation of the radionuclide material in the right lower quadrant of the abdomen indicates positivity for appendicitis. The sensitivity is between 91-94% and specificity is 82-94%. The disadvantages to its use include the issue that it is not universally available, takes long to perform and interpretation of the scan is operator dependent (Sarosi & Turnage, 2002).

9.3.5 Contrast studies

A contrast enema is not usually employed in children for the diagnosis of acute appendicitis because it is unpleasant to the child, may require sedation, involves contrast going through probably inflamed bowel and may not contribute much to the evaluation following the use of other radiological investigations. If it is done, it may show failure of the appendix to fill with contrast. However, 10-20% of normal appendixes do not fill during contrast study. False negative result may be caused by distal appendicitis at the tip without proximal obstruction or partial obstruction in early appendicitis. It may demonstrate right colonic or terminal ileal mucosal changes secondary to infective enterocolitis e.g from *Yersinia enterocolitica*, *Salmonella* spp. *Shigella* spp. *Campylobacter* spp. *Bacteroides* spp. *Escherichia coli*, as well as changes due to Crohn's disease or non-specific inflammatory bowel disease. It may compliment CT and US in equivocal cases, particularly in recurrent abdominal pain. An upper gastrointestinal contrast study may be used to evaluate the rotational status of the midgut in such cases.

Contrast studies offer advantages of being

1. Simple
2. Safe
3. Readily available where ultrasound and CT are not available

Disadvantages include:

- Up to 40% of barium studies may be equivocal where CT and US have been equivocal (Liu and McFadden, 2003)
- In the presence of perforation, contrast may extravasate into the peritoneal cavity
- It takes time to set up
- It may require sedation.

9.3.6 Laparoscopy

Up to 59% of patients with right lower quadrant pain may have appendicitis confirmed at laparoscopy for suspected appendicitis. 35% of the females with suspected appendicitis may be found to have gynaecological pathology at laparoscopy (Liu and McFadden, 2003). Laparoscopy also offers the advantages of direct inspection of all the intra-abdominal organs as well as the opportunity to treat the identified pathology where appropriate.

9.4 Clinical scoring systems

Several scoring systems have been put forward to facilitate the diagnosis of appendicitis. Unfortunately, paucity of validation studies limits their clinical application. It should be borne in mind however that achieving a maximum score in any of the scoring systems may still lead to a negative appendicectomy. Two of these are discussed.

The Paediatric Appendicitis Score (PAS) for the evaluation of children aged between 4-15years with probable appendicitis is based on scores assigned to the clinical history, presenting signs and laboratory results. A score of ≤ 5 implies the diagnosis is unlikely to be appendicitis; ≥ 6 is compatible and 7-10 indicates a high probability of appendicitis. PAS has been advocated and shown to reduce the rate of normal appendicectomy to less than 5% giving a mean score of 3.1 ± 1.1 in non-appendicitis cases and 9.1 ± 0.1 in appendicitis (Samuel, 2002). Samuel (2002) also demonstrated that the PAS had a sensitivity of 100%, specificity of 87%, positive predictive value of 90% and negative predictive value of 100%. Table 1 shows the details of the scoring system.

Diagnostic indicator	PAS (maximum 10)
Tenderness with cough or percussion or hopping	2
Anorexia	1
Pyrexia	1
Nausea/ vomiting	1
Tenderness in right lower quadrant	2
Leucocytosis $\geq 10,000$ ($10^9/L$)	1
Neutrophilia	1
Migration of pain	1

Table 1. Paediatric Appendicitis Score

Similarly, the Alvarado score (Table 2) employs clinical and laboratory values in predicting the possibility that the cause of abdominal pain is acute appendicitis. Shreef et al., (2010) in their review of 350 children demonstrated that with an Alvarado score of ≥ 6 , the sensitivity of the scoring system could be as high as 100%, specificity 84.4%, positive predictive value of 83% and accuracy of 91.1%.

Diagnostic indicator	Alvarado score(maximum 10)
Tenderness in right iliac fossa	2
Rebound tenderness in right iliac fossa	1
Anorexia	1
Pyrexia >37.3	1
Nausea/Vomiting	1
Leucocytosis	2
Neutrophilia ($>75\%$)	1
Migration of pain	1

Table 2. Alvarado Score

10. Treatment

10.1 Suspected appendicitis

Where a definite diagnosis is not reached following history taking and examination in a child with significant symptoms, admission for observation should be undertaken. The child should be managed according to symptoms with analgesia and rehydration therapy where appropriate. The gastric emptying in children with inflammatory intestinal problems is delayed, therefore, these patients should be kept on clear liquid diet to avoid aggravating the condition and also to minimise the risk of aspiration during induction of anaesthesia should this subsequently becomes necessary. Surana et al., (1995) demonstrated that active observation of children with suspicion of appendicitis was not associated with a significant increase in complication rate; 5.5% vs. 4.2% in those diagnosed at presentation. Moreover, after the inflammation reaches the submucosa, it progresses quickly to involve the rest of the appendix (Fenglio-Preiser et al., 2008). Therefore, hospital admission and active observation is recommended with regular review of the patient at intervals of 4-6hours.

10.2 Immediate treatment

The immediate management of a child with presumed acute appendicitis should include resuscitation, analgesia +/- abdominal decompression with a nasogastric tube. The child's clinical status should be evaluated to determine the appropriate level of care most suitable for the individual child. Some children would require level 2 intensive care nursing, or higher, before and/or after surgical treatment. Fluid resuscitation should be commenced and the child should be well-hydrated to ensure safe surgery. Broad spectrum antibiotics should be administered once the diagnosis of acute appendicitis has been made and surgery planned. There is evidence that commencing antibiotics at least 4 hours before surgery reduces the risk of post-operative wound infection particularly when the duration of symptoms is longer than 48 hours (Krukowski et al., 1987; Lander et al., 1992). Using a protocol involving adequate fluid resuscitation and a minimum of two pre-operative doses of antibiotics (Coamoxiclav +/- Gentamicin), Cleeve et al., (2011) demonstrated a complication rate of 6% in children with advanced appendicitis. The choice of antibiotics should cover the micro-organisms expected at the site of infection as described in the microbiology section of this chapter. Commonly, a third or fourth generation cephalosporin is used with or without a penicillin. An aminoglycoside, often Gentamicin, should be added where there are features suggesting advanced appendicitis. In the supine position, the lowermost levels of the peritoneal cavity are the right subphrenic space and the pelvic cavity. In peritonitic patients the rate of absorption of toxins from the intraperitoneal infection can be reduced by keeping them in the 45° position to encourage gravitation into the pelvis where the rate of toxin absorption is slow (Snell, 2004).

10.3 Conservative treatment

Delayed diagnosis is associated with higher rate of perforation, pelvic abscess, longer duration of hospital stay, delayed return to normal activities and greater risk of adhesive bowel obstruction. Up to 30% of children under 3 years of age present with appendix mass with a duration of symptoms usually longer than 4-5 days (Stevenson, 2003). In cases with long duration of symptoms, ultrasound should be performed before planning surgery if the clinical status of the abdomen precludes adequate palpation, or if the presence of a mass cannot be excluded. In the presence of a clinically palpable or radiologically identified appendicular mass and absence of gross peritonitis, conservative management with broad spectrum intravenous antibiotics can be safely undertaken. Hoffman et al., (1984) demonstrated that up to 80% of patients successfully managed with antibiotics for an appendix mass required no further treatment, 14% of these presented with recurrent abdominal pain not related to appendicitis; 20% had recurrent appendicitis and 66% of these occurred within 2 years of initial treatment. Swain et al., (2005) also demonstrated that an appendix-related abscess of ≤ 2 cm can be successfully treated conservatively. Larger abscesses should be drained whenever this can be safely undertaken either by radiology-guided approach or surgically using laparoscopy or into the rectum.

Careful monitoring of physical signs, both local and systemic should be undertaken at regular intervals. The temperature, heart rate, respiratory rate, abdominal tenderness and size of inflammatory mass should be observed. Laboratory investigations should be used to compliment clinical findings. Repeat radiological investigations may also be required. The resolution may take a few days to become evident though generally a definite improvement should be noticed after 48 hours. If the acute appendicitis settles, interval appendectomy

should be performed within 6 weeks to 3 months. For those who show persistent or worsening clinical signs, early appendectomy should be undertaken to avoid more serious complications.

10.4 Definitive surgery

Complications of appendicitis include pyelophlebitis, portal venous thrombosis, cholangitis, liver abscesses and bacteraemia. Also, fistula formation may result from appendicitis including enteroenteric, enterovaginal, enterocutaneous and enterovesical fistulae. Therefore, in the presence of strong suspicion of appendicitis, it is less of a clinical risk to undertake the removal of a normal appendix than expose the patient to the significant morbidity associated with advanced appendicitis. A negative appendectomy rate of 5-10% can be expected (Stevenson, 2003). Oyetunji et al., (2011) observed a reduction in the negative appendectomy rate over the years from 8.1 % in 2000 to 5.2% in 2006, being higher in rural areas, younger children, and girls. Of patients with negative appendectomy, 12% may have a different surgical condition, 18-20% may have non-surgical pathology and 60% may have no identifiable pathology. Complication rate for negative appendectomy may range from 5-15% including wound related problems, pulmonary complications, urinary tract infection and small bowel obstruction (Sarosi & Turnage, 2002).

Following induction of anaesthesia, palpation of the abdomen should be undertaken. In the presence of a clearly defined mass which was not identified earlier, further management would involve two main secondary options: to continue with the planned surgery, or, to defer the operation and further evaluate the child with treatment using intravenous antibiotics. The latter view was strongly expressed by Surana and Puri (1995). Gillick et al., (2001) found that children who had a palpable mass under anaesthesia, which was not diagnosed clinically earlier, had a shorter duration of symptoms (mean 2days) than those with clinically palpable or ultrasound diagnosed mass (mean 4days). In their series, half of the children aged ≤ 2 years and one-third of those ≤ 3 years had an appendix mass present at the time of first evaluation. 15.8% of their patients failed to settle with conservative management, 41.5% of whom had abscess drainage followed by appendectomy, while 26% required early appendectomy; 50% of these had post-operative complications. 10% of those who settled with conservative management had recurrent appendicitis. Considering the short duration of symptoms associated with a mass that was not palpable before anaesthesia, the author recommends that surgical treatment should proceed in these cases; having commenced antibiotic therapy at least 4hours before surgery where the duration of symptoms was longer than 48hours as suggested above. This recommendation is also given by Stevenson, (2003) and adopted by many paediatric surgeons in the United Kingdom.

10.4.1 Anaesthetic considerations

Appendicitis is usually an acute illness in otherwise healthy persons. It is often associated with gastroparesis and a patient who is admitted for observation for a probable diagnosis of appendicitis should be given fluid diet if not nil per oral as the stomach may not empty as well as in other conditions. Intraoperative precautions should be observed as for patients with a full stomach with rapid sequence intravenous induction of anaesthesia (Oberhelman & Malott, 2004). Once anaesthetised, the stomach should be promptly emptied with a nasogastric tube. The presence of associated peritonitis and abdominal distension may lead

to splinting of the diaphragm which in turn reduces the functional lung volume. Respiratory impairment may be present especially in very young children. Tachypnoea may be a manifestation of respiratory embarrassment, pain, dehydration or sepsis. The circulatory system may be affected by hypoperfusion from associated fever, vomiting, diarrhoea or nausea with resultant reduced oral intake. This may manifest as increased heart rate and end organ signs including increased capillary refill time, reduced peripheral temperature, dry mucous membranes and reduced urine output. Preoperative correction of any hypovolaemia is mandatory for safe anaesthesia. There may be coexistent electrolyte imbalance and this also needs to be appropriately corrected preoperatively (Oberhelman & Malott, 2004).

Muscle relaxation is required to facilitate surgery whether open approach where muscle splitting is applied or laparoscopy which requires adequate exposure by pneumoperitoneum using the lowest possible intra-abdominal pressure. The physiological challenges posed by the pneumoperitoneum required for laparoscopic surgery needs careful attention from the anaesthetists (Nwokoma & Tsang, 2011).

10.4.2 Laparoscopic approach

Since the description of laparoscopic appendectomy by the German gynaecologist Kurt Semm in 1983 (Semm, 1983), this approach to appendectomy has continued to gain wide acceptance. With the advances in laparoscopic surgery in recent years, it has become common practice in many centres to have laparoscopic approach to appendectomy in the absence of contraindications (Table 3).

Patient unsuitable for open surgery
Uncontrolled bleeding or coagulation problems
Multiple previous abdominal surgery

Table 3. Contraindications to paediatric laparoscopy

Where the child presents with features of advanced appendicitis with bowel obstruction, this may constitute a relative contraindication to the use of laparoscopy due to increased risk of injury to the dilated bowel loops. Previous abdominal surgery predisposes the patient to intra-abdominal adhesions which increase the risk of bowel injury and bleeding but this risk is less if the previous surgery was performed laparoscopically (Nwokoma et al., 2009b).

Laparoscopic approach has been safely used to treat advanced appendicitis in children with results similar to that in open approach. We demonstrated that laparoscopic approach offered significant advantages with better outcomes than open approach in paediatric advanced appendicitis with less wound-related complications: 8.6% versus 17.6% (Nwokoma et al., 2009a), and a conversion rate of 0%. Brügger et al., (2011) and Garg et al., (2009) drew similar conclusions from their studies. Brügger et al., (2011) further demonstrated the rate of wound infections (0.50% vs. 6.98-7.97%), post-operative ileus (0.15% vs. 0.33%), urinary complications (0.13% vs. 0.66%) and pulmonary complications (0.18 vs. 1.19%) to be lower in their group of laparoscopically treated appendicitis than data from large studies using the open approach.

The age-long principles of safe surgery include quick and adequate access, adequate target organ visualisation and minimal tissue trauma. In children, access can be quite a challenge because of the smaller height/width ratio of the abdomen particularly observed in those under 8 years of age. In many cases, however long the incision, gaining access to the target organ or indeed to the four quadrants of the abdomen and pelvis, can be very difficult. Laparoscopy offers the paediatric surgeon the advantage of being able to visualise these areas while reducing the trauma usually consequent upon use of large abdominal wall incisions (Nwokoma & Tsang, 2011).

There is growing evidence that laparoscopy has more advantages and benefits to offer children than was earlier presumed to be the case. These benefits have been widely reported (Table 4) and significantly outweigh any concerns regarding the technical difficulties (Table 5) which are largely overcome with increasing experience and further developments in the laparoscopic equipment.

Reduced wound size
Reduced wound trauma
Less wound infection
Less incisional hernia
Less wound dehiscence
Less wound pain
Early mobilisation
Less bleeding
Less heat loss from tissue
Wider field of vision
Less postoperative adhesions
Less postoperative ileus
Earlier return to usual activities
Earlier commencement of chemotherapy
Less respiratory complications
Less risk of thromboembolism
Reduction in nerve entrapment

Table 4. Advantages of laparoscopy

Loss of tactile sensation
Loss of spatial and depth orientation
Two-dimensional imaging
Difficulty with control of bleeding
Difficulty with extraction of resected tissue or organ

Table 5. Technical difficulties of laparoscopy

A 10mm primary port should be inserted using the Hasson's open technique either in the suprapubic region, half way between the symphysis pubis and the umbilicus making sure that the urinary bladder is not in the path of entry or in the umbilical region – centrally or

infraumbilically. Two secondary 5mm ports should be inserted under laparoscopic guidance in the left lower quadrant for instruments. Alternatively, with an umbilical primary port, each of the two secondary ports can be placed on either side in the left and right lower quadrants. Single port transumbilical laparoscopy-assisted appendicectomy is gaining popularity and has been demonstrated to give results comparable to standard laparoscopic appendicectomy for uncomplicated appendicitis (Guanà et al., 2010). It has been successfully used to treat uncomplicated appendicitis as day case procedures (Alkhoury et al., 2011). Local anaesthetic injection into the port sites is advisable. Safe pneumoperitoneum should be established with 5-8mmHg in the newborn, 10-12mmHg in infants and <15mmHg in older children (Nwokoma & Tsang, 2011). Pus can be obtained with the suction device for microbiological analysis. The appendix is dissected free, the appendicular vessels divided by diathermy cauterisation or between endoclips. Ligation of the appendix should be carried out with three endosurgical loops; two proximally and one distally, as close to the base as possible to avoid the complications of stump appendicitis and enterocutaneous fistula (Lintula et al., 2002). Stump appendicitis which can occur following open or laparoscopic appendicectomy may occur in residual appendix as small as 6mm (Waseem & Devas, 2008) and is associated with significant morbidity. Cauterisation of the appendicular stump may prevent later formation of a mucocele. All incisions \geq 5mm should be closed with absorbable sutures to the deep fascia and subcutaneous tissue to avoid port site hernia. Advanced appendicitis poses a significant challenge for the paediatric surgeon and many opt for the open approach if this is suspected preoperatively. This is because the abdomen in children is shorter in height and relatively wider than in adults, especially children younger than eight years of age which is the group that commonly present with advanced appendicitis. However, as we demonstrated above, advanced appendicitis can be safely managed laparoscopically in children with outcome comparable to those of open approach. An inflammatory mass may be present during surgery and this can be drained laparoscopically with good vision of all four quadrants of the abdomen. Following laparoscopic drainage of the abscess, liberal peritoneal lavage should be performed as appropriate and the inflammatory mass should be assessed with regards to safety of continuing with the operation. Where the tissues are very friable, it is preferable to postpone the appendicectomy and treat with intravenous antibiotics with a view of performing interval appendicectomy safely at a later date. It is preferable to place the patient in a reverse Trendelenburg position and drain the purulent material from the pelvic cavity before putting the patient in the Trendelenburg position required for good access for the appendicectomy. This practice should reduce the risk of post-operative subphrenic, subhepatic and parasplenic abscesses.

Following laparoscopic appendicectomy in 7446 cases (age range between 12 and 100years), Brügger et al. (2011) observed an overall complication rate of 8.63% with individual complications detailed in Table 6.

10.4.3 Open appendicectomy

The open approach to appendicectomy has been established for over a century. The first recorded appendicectomy was performed by Claudius Amyand in 1735 at St. George's Hospital in London (United Kingdom) where he removed an appendix containing a calcified mass around a pin in a patient presenting with inguinal hernia. Lawson Tait performed the first successful appendicectomy for appendicitis in 1880 (Williams and Myers 1994).

<i>Complication</i>	<i>% frequency</i>
Intraoperative complications	1.88
Haematoma/intra-abdominal bleeding	0.6
Haematoma/ abdominal wall bleeding	0.28
Injury to intra-abdominal organ	0.13
Injury to stomach/ bowel	0.08
Vascular injury	0.07
Inadvertent bowel puncture by trocar	0.07
Inadvertent puncture by Veress needle	0.01
Other intraoperative complications	0.63
Postoperative Complications	6.75
Surgical postoperative complications	4.24
Abscess	0.98
Peritonitis	0.59
Paralytic ileus	0.56
Haematoma/intra-abdominal bleeding	0.50
Haematoma/abdominal wall bleeding	0.34
Haematoma/bleeding requiring transfusion	0.13
Wound infection	0.50
Obstructive ileus	0.15
Intestinal perforation	0.04
Stricture	0.01
Other surgical complications	0.44
General postoperative complications	2.51
Cardiac complication	0.36
Pulmonary embolism	0.15
Urinary tract infection	0.13
Jaundice	0.05
Pneumonia	0.03
Deep vein thrombosis	0.01
Stroke	0.01
Nerve compression	0.01
Other general postoperative complications	1.75

Table 6. Complication rates following laparoscopic appendicectomy

The commonly applied incision in children is the Lanz incision. It is an almost transverse incision in the right lower quadrant, about 2cm above and medial to the anterior superior iliac spine with its centre in the McBurney's point. The Lanz incision is more popular in

children than the gridiron incision which also has its centre as the McBurney's point but runs perpendicular to an imaginary line between the anterior superior iliac spine and the pubic tubercle. This is because the Lanz incision has better cosmesis and healing, being along the Langerhan's lines. It also offers the surgeon the qualities of a good incision including easy and quick access to the abdominal cavity, extendable if required and easy to close. It crosses less dermatomal regions making the post-operative pain less and easier to control. As mentioned earlier, the abdomen of young children is relatively wider than its height on the longitudinal axis. Therefore access to the abdominal organs during surgery is best achieved by an incision that can go across the abdomen; the Lanz incision offers this advantage. Some authors advocate palpating the abdomen just before induction of anaesthesia and placing the incision just below the point of maximum tenderness. The problem with this is that the point of maximum tenderness usually marks the appendicular tip and may be far from the base. This may result in a longer than necessary incision. For example a pelvic appendix tip may give maximum tenderness suprapubically and a retrocaecal appendix may give maximum tenderness in the right upper quadrant. An incision over the region of the base of the appendix works best with various positions of the appendix body and tip. In certain situations, lengthening of the incision is necessary to perform a four-quadrant examination and drainage of associated pus. The Lanz incision allows such an extension of the incision to be undertaken safely and effectively.

Muscle splitting is preferable to the muscle cutting approach because the reduced tissue trauma is associated with reduced risk of bleeding, infection and post-operative pain. The peritoneum should be entered between clips, avoiding damage to the underlying bowels by ensuring bowel clearance from the edges of the clips. A microbiological swab of the peritoneal fluid should be taken, preferably from the appendix itself to increase micro-organism yield. Pus is the creamy-yellow viscid fluid present in infected tissues which consists of bacteria - living and dead, dead polymorphonuclear leukocytes, extravasated plasma and damaged host cells or tissue debris (Eykyn, 1998). If purulent material is present, a sample of it should be sent for analysis as well as a swab sample. The caecum should be identified and the anterior taenia followed inferomedially to the appendix base. Any inflammatory adhesion should be carefully released by blunt digital dissection. The peritoneal folds along the lateral and inferior borders of the caecum may need to be divided to adequately mobilize the caecum and deliver the appendix into the wound, especially so when it lies retroperitoneally. The mesoappendix is narrowest at the tip and widest at the base with the appendicular vessels within its edge. Ligation of the vessels usually commences from the tip towards the base. This is the antegrade dissection. In some cases retrograde dissection from the base may be required for safe appendicectomy. The appendix base should be crushed with a straight clamp as close to the caecum as can be safely achieved. Reapplying the clamp just above the crushed portion, the appendix should be transfixed and ligated with strong absorbable suture material, then cut above this. Cauterisation of the appendicular stump reduces risk of formation of a mucocele. Inversion of the appendicular stump with a purse string suture or a Z- stitch anchored within the taenia coli on the caecum adjacent to the base is still common practice. Taking too much caecum into the purse string suture or Z-stitch may lead to the development of a mucocele or become a lead point for intussusception (Swain, 2005). With local purulent peritonitis, local irrigation is preferable to wide spread lavage in order to minimise any dissemination of infective agents. On the other hand, if free pus is present, liberal peritoneal lavage is

recommended. The addition of Betadine (Povidone iodine) or antibiotic agent(s) to the lavage fluid is widely practiced. However, it is noteworthy that Schneider et al., (2005) reported no significant advantage from the use of adjuvant peritoneal Taurolidine lavage in children with appendicitis associated with localised peritonitis. Local anaesthetic injection into the wound at this point compliments immediate post-operative analgesia. The abdominal wall should be closed carefully with absorbable suture material in layers or as mass closure. Subcuticular absorbable sutures should be used to close the skin. Pauniahio et al., (2010) demonstrated a reduced incidence of wound-related complications in acute appendicitis using subcuticular absorbable sutures than with the use of non-absorbable sutures.

The complication rate following open appendicectomy in children varies with age and severity of the appendicitis. Intra-abdominal abscesses may complicate up to 20% of perforated appendicitis; wound abscess <5%; faecal fistula <1% and wound haematoma <0.5%. Other complications include intestinal obstruction, missed bowel injury and bleeding. Mortality for non-perforated appendicitis is <0.1% and for perforated appendicitis this rises to up to 2% (Oberhelman & Malott, 2004).

10.5 Post-operative management

Careful monitoring of the patient in the post-operative period should follow the principles of management of the critically ill surgical patient. As stated earlier, level 2 (or higher) nursing care may be required. Careful management of respiratory and cardiovascular system should be continued. In the very young patient a urinary catheter may be a useful adjunct to fluid management and opiate analgesia may make the child prone to urinary retention. A nasogastric tube may be required if features of bowel obstruction are present. A peripherally inserted central line may be inserted intra-operatively if prolonged antibiotics or significant delay to return of bowel function is anticipated.

Post-operative analgesia may initially be administered as a patient or nurse-controlled intravenous opiate analgesia. Where advanced appendicitis has necessitated a wide incision and laparotomy, an epidural analgesia may be preferable. If epidural analgesia is used, a urethral catheter should be placed. Oral analgesia should be introduced when gastrointestinal function returns.

The administration of antibiotics for any reason can potentially upset the balance of the normal gastrointestinal flora. This may create an environment that is favourable for the multiplication of exogenous pathogens as well as the overgrowth of select pathogenic strains. Antibiotic-related complications are common with use beyond 5 days (Mui et al., 2005).

Principles for the selection of antibiotic therapy (Raftery, 2002) are as follows;

- There should be clinical evidence of infection
- Best guess antibiotics to cover known likely infective micro-organism(s)
- Where possible, remove infected tissue or foreign body
- Appropriate specimen collection from the site of infection for microbiology examination
- Cheapest and most effective drug or drug combination with known effectiveness over known likely organisms
- Monitoring of clinical response to treatment
- Appropriate route to achieve therapeutic levels of drug at site of infection

- Duration of administration should cover acute infection period, avoiding prolonged antibiotic treatment
- Re-evaluate clinical response with microbiology result and change antibiotics if clinically indicated.

Appendicectomy creates a contaminated wound with an infection risk of 12%. In the presence of pus or a perforation, a dirty wound results, with infection risk of 25% (Raftery, 2002). Perioperative antibiotics administration should follow local sensitivities, usually - Amoxicillin/ Gentamicin/ Metronidazole or a cephalosporin given instead of Amoxicillin. The former combination is used in our institution. Antibiotics should be given at least one hour before the skin incision is made to ensure adequate therapeutic plasma levels. Further antibiotic therapy should be based on intraoperative findings. In the presence of normal looking appendix, no further antibiotic is required. Single dose combined antibiotic therapy has been demonstrated to be adequate surgical prophylaxis in non-perforated appendicitis (Mui et al., 2005). In addition, Lee et al., (2010) observed that single or double agent antibiotics were effective and of lower cost than triple therapy. The author's recommendation in the case of an inflamed non-perforated appendix with no pus present is that a 24hr antibiotic therapy of single or double agents be given. This is because inflamed bowel is known to be associated with some micro-organism translocation. If heart rate and temperature remain within normal limits at 24 hours, antibiotics can be discontinued. A perforation may not be evident on resected specimen due to the extensive inflammation (Fenoglio-Preiser et al., 2008). In a cutaneous abscess, it is possible to clear out the pus. In the abdominal cavity, this is not possible and one must assume that infective agents remain free in the peritoneal cavity even after extensive peritoneal lavage. Five days of intravenous antibiotics is recommended in the presence of pus or an obvious perforation, preferably a triple agent therapy. The results of the microbiology analysis of any pus sample should be ascertained before the end of the five-day antibiotic therapy. There is evidence that intraperitoneal abscess formation is commoner with *Streptococcus milleri* (Fenoglio-Preiser et al., 2008) and a longer duration of antibiotics, about 7days, is recommended in these situations.

Thromboprophylaxis should be administered by mechanical and/or chemical means as appropriate to each patient. In particular, older children above average weight or on contraceptive medication or who smoke should have peri-operative thromboprophylaxis. Some children show signs of gastric irritation following appendicectomy more with advanced appendicitis. If features of gastric irritation are observed including new onset epigastric pain and coffee-ground appearance of the vomitus, H-2 antagonists or proton pump inhibitors should be given to cover the period of acute illness till symptoms resolve.

11. Special considerations

11.1 The normal appendix: Remove or not remove?

Since the introduction of the Antegrade Colonic Enema procedure to aid the management of functional problems of the large bowel, the need to preserve the normal appendix particularly in children has been the subject of much discussion. Children without functional bowel problem or spina bifida at the time of presentation are unlikely to require the ACE procedure in the future. The appendix is also used for urinary diversion or vesicocutaneous channel in the Mitrofanoff procedure and for biliary drainage (Swain, 2005). Arguably, while this may not be required at the time of surgery, the child's condition might

change in the future. The likelihood that a child would need an appendix-related reconstructive surgery in the absence of a previous health problem is less than the likelihood of having appendicitis (Morrow, 2005). On this premise, it would appear that incidental appendicectomy has more benefits to offer by avoiding a future appendicitis.

Contraindications of incidental appendicectomy include impaired immunity, presence of surgical implants, presence of Crohn's disease in the adjacent caecum, intra-operative instability, history of recent abdominal radiation and an inaccessible appendix (Stevenson, 2003).

As discussed earlier, a normal-appearing appendix may be pathological. It is arguable that the presence of a Lanz incision may imply that appendicectomy had previously been undertaken which could be misleading with needless delay to the diagnosis of appendicitis where the appendix had actually not been removed. On the other hand, removing a normal appendix converts a clean operation into a dirty operation with increased risk of complications. The author recommends appropriate pre-operative evaluation and the removal of the normal-appearing appendix discovered intra-operatively.

11.2 Neurogenic appendicopathy

This condition is caused by the proliferation of nerve fibres in the appendix and can only be diagnosed with certainty on histological analysis. It may be present in up to 4.2% of specimens removed for presumed appendicitis. It is commoner in girls and older children, with up to 80% of specimens showing no histological features of inflammation. The use of antiserotonin or antihistamine therapy is advocated in suspicious cases (Zaupá et al., 2011).

11.3 Inflammatory bowel disease in appendicitis

Crohn's disease: The appendix is involved in 25% of Crohn's disease leading to surgical treatment. However, Crohn's disease manifesting as appendicitis at the time of diagnosis is rare with less than 100 cases reported in literature. 7-10% of these are thought to progress to Crohn's disease at other sites. Ulcerative colitis: The appendix is involved in up to 50% of resected ulcerative colitis specimens. Some of these manifest as skip lesions without caecal involvement or in continuity with caecal disease (Petras & Goldblum, 1996).

11.4 Acute appendicitis in the neonate

Neonatal acute appendicitis is rare but associated with high morbidity and mortality of about 50-80%. Diagnosis is often late or missed and found at post-mortem (Swain, 2005). It may result from the presence of necrotising enterocolitis, cystic fibrosis, Hirschsprung's disease or bacteraemia associated with maternal chorioamnionitis (Pressman et al., 2001).

The neonatal anatomy presents special challenge due to its difference from the rest of the paediatric population. The abdomen in these children is often protuberant due to the flat diaphragm, shallow pelvis and reduced sacral curvature. Consequently, the organs that would have been within the rib cage and pelvis are intra-abdominal (Standring et al., 2005).

11.5 Chronic appendicitis

An organising phase of acute appendicitis occurs with the finding of granulation tissue and a mixture of acute and chronic inflammatory changes as well as recently laid down connective tissue. However, true chronic appendicitis with lymphocyte and plasma cells present in the muscularis propria and serosa without significant acute inflammation is rare (Petras and Goldblum, 1996).

11.6 Tuberculosis of the appendix

Appendicular tuberculosis occurs in 0.1-3% of patients with tuberculosis but isolated tuberculosis of the appendix is rare. Appendicectomy followed by antituberculous chemotherapy is the treatment of choice. Abdominal tuberculosis in children affects the immunocompromised and those who have not received the BCG vaccine. It manifests with weight loss, malaise, abdominal distension, abdominal pain, anaemia raised white cell count and altered albumin: globulin ratio (Rangabashyam et al., 2000)

11.7 Neoplasm of the appendix

Neoplasm of the appendix is found in 1.08 to 1.3% of appendicectomy specimens. The carcinoid tumour is very rare but it is the most common neoplasm of the gastrointestinal tract in children. It may be found in 0.3% of paediatric appendicectomies. Mean peak age of incidence in children is 15 years though children as young as 6 years old may be affected (Stevenson, 2003). Carcinoid syndrome comprises of flushing, diarrhoea and cardiac disease. It is usually associated with liver or retroperitoneal metastasis; with increased urinary 5-hydroxyindoleacetic acid. Lymph node metastasis is seen in 4-5% of paediatric patients with carcinoid tumour but distant metastasis of appendicular carcinoid is very rare in children. It may also be associated with multiple endocrine neoplasia type 2. (Christianakis et al., 2008). Adenocarcinoma of the appendix is exceedingly rare. More a problem of older patients, it develops in the appendicular base with appendicitis from luminal occlusion being the commonest mode of presentation. 50% are metastasized at diagnosis. It commonly spreads to the peritoneum directly. Adenocarcinoids are also rare. The histological features are of combined carcinoid and adenocarcinomas. The treatment of neoplasm of the appendix is largely limited to appendicectomy. Extension beyond the appendix requires treatment by right hemicolectomy (Liu & McFadden, 2003). Cystadenocarcinomas are mucin-filled. Perforation results in mucin-secreting peritoneal deposits manifesting as pseudomyxoma peritonei which is treated by repeated debulking and eventually fatal. In advanced cases, the abdomen is filled with tenacious semisolid mucin.

11.8 Recurrent appendicitis

Recurrent appendicitis is becoming increasingly accepted as a diagnosis. Appendicitis like any other inflammation in the human body may become arrested and not progress to full-blown process. To lend support to this, approximately a quarter of patients with histologically proven acute appendicitis report a history of prior episodes of abdominal pain of similar character as that which culminated in appendicectomy. Furthermore, sometimes histopathological analysis of acute appendicitis specimen shows both acute and chronic inflammatory characteristics. Also, about 60% of patients who respond well to treatment of advanced appendicitis report abdominal pain suggestive of recurrent appendicitis prior to interval appendicectomy (Swain, 2005).

11.9 Antibiotic-associated *Clostridium difficile* infection

Clostridium difficile (*C. diff.*) is a spore-forming gram positive rod. It produces its pathogenic features by the production of toxins. Toxin A is an enterotoxin while toxin B is a cytotoxin. Diagnosis is by detecting these toxins in stool. *C. diff.* toxins can be detected in the stool of 2-5% of the general population and up to 50% of infants. Its clinical significance is anchored on being the causative agent of antibiotics associated diarrhoea included in this

chapter as a likely complication of prolonged perioperative antibiotic administration. It has been found to be responsible for approximately 30% of cases of the simple uncomplicated diarrhoea that often follows antibiotic administration. It is associated with 90% of cases where pseudomembranous colitis is present. Alteration of colonic flora especially by Ampicillin or Cephalosporins and Clindamycin favours the proliferation and virulence of *C. diff.* The clinical manifestation of *C. diff.* colitis depends on which toxin is predominant in the colon. In situation of toxin A predominance, watery diarrhoea manifests; with toxin B predominance pseudomembranous colitis results. *C. diff.* diarrhoea onset is usually 5-10 days after starting antibiotics but this could range from day 1 to weeks after cessation of the therapy. Clinical effects may be mild and watery or bloody with or without severe crampy abdominal pain, raised levels of white blood cells and raised temperature. Treatment of *C. diff.* colitis consists of discontinuation of implicated antibiotics which would usually lead to complete resolution of symptoms. However, if there is no response to antibiotic withdrawal or the patient is severely ill, Metronidazole or Vancomycin given orally is recommended. The risk of relapse or re-infection requiring repeat treatment may be up to 20% (Ryan & Ray, 2010).

11.10 Appendicitis in cancer patients on chemotherapy

Appendicitis in the neutropaenic child on anticancer chemotherapy is a great challenge. As much as possible, surgery should be avoided and conservative management with antibiotics instituted with a plan to perform interval appendicectomy when the child is better. A CT scan is often required to differentiate this from typhlitis. Joint care should be undertaken with specialist paediatric oncology staff. Granulocyte Colony Stimulating agents are often used to improve the neutrophil count. Some authors recommend elective appendicectomy in patients diagnosed with malignancy who are about to commence chemotherapy if surgery for other reason was to be performed before chemotherapy with a view of preventing appendicitis that may occur in neutropenic patients while on chemotherapy. This practice was not found to be associated with increased complications rate but only 0.2% of patients who did not have incidental appendicectomy went on to have appendicitis during a median follow up period of 5years (Morrow, 2005).

12. References

- Alkoury F.; Burnweit C.; Malvezzi L.; Knight C.; Diana J.; Pasaron R.; Mora J.; Nazarey P.; Aserlind A. & Stylianos S. (2011). A prospective study of ambulatory appendectomy for acute appendicitis: safety and satisfaction with same day discharge in 126 children. *Presented at the British Association of Paediatric Surgeons Conference*. Belfast, U.K. (July 2011).
- Baker N.; Bushell A. & Hawkey P. M. (2004). Bacteriology of superficial and deep tissue infection. In: *Medical Bacteriology*. (2004) 157-160. Hawkey P. M. & Lewis D. (Eds.) Second edition. Oxford University Press Inc. New York, USA. ISBN: 019963778-4
- Birchley D. (2006). Patients with clinical acute appendicitis should have pre-operative full blood count and CRP assays. *Annals of the Royal College of Surgeons of England*. Vol. 88, No. 1, (January 2006), pp. 27-32. ISSN: 0035-8843
- Brügger L.; Rosella L.; Candinas D. & Güller U. (2011). Improving Outcome After Laparoscopic Appendectomy, A population-based, 12year Trend Analysis of 7446 Patients. *Annals of Surgery*, Vol.253, No.2, (February 2011), pp. 309-313, ISSN: 0003-4932


- Chang Y.; Chao H. C.; Kong M. S.; Hsia S. H. & Yan D. C. (2010). Misdiagnosed acute appendicitis in children in the emergency department. *Chang Gung Medical Journal*. Vol. 33, No. 5, (September-October 2010), pp. 551-556, ISSN: 20720939
- Cleeve S.; Jones N.; Joshi A.; Phelps S.; Misra D. & Ward H. (2011). Trends in childhood appendicitis. *Presented at the British Association of Paediatric Surgeons Conference*. Belfast, U.K. (July 2011).
- Dalal I.; Somekh E.; Bilker-Reich A.; Boaz M.; Gorenstein A. & Serour F. (2005). Serum and Peritoneal inflammatory mediators in children with suspected acute appendicitis. *Archives of Surgery*. Vol. 140, No. 2, (February 2005), pp. 169-173 ISSN: 0004-0010
- Doria A. S. (2009). Optimising the role of imaging in appendicitis. *Pediatric Radiology*, Vol. 39, Supplement 2, (April 2009), pp. S144-8, ISSN: 1432-1998
- Ellis H. & Mahadevan V. (2010). *Clinical Anatomy*. Twelfth edition. Pp. 87-88. Wiley-Blackwell, West Sussex, United Kingdom. ISBN 978-1-4051-8617-9
- Eykyn S. J. Surgical infections and the use of antibiotics. In: *The New Aird's Companion in Surgical Studies*, (1998). Second edition. K.G. Burnand and A.E. Young, (Eds.), 66, Churchill Livingstone, ISBN 0443 05326X, London, United Kingdom
- Fenoglio-Preiser C. M.; Noffsinger A. E.; Stemmermann G. N.; Lantz P. E. & Isaacson P. G. (2008). *Gastrointestinal Pathology: An Atlas and Text*. Third edition. 502-505. Wolters Kluwer/Lippincott Williams & Wilkins, Philadelphia, USA. ISBN-13: 978-0-78-17-7146-7
- Forbes B. A.; Sahm D. F. & Weissfeld A. S. (2007). *Bailey and Scott's Diagnostic Microbiology*. Twelfth edition. P. 905. Mosby Elsevier, St. Louis, Missouri, USA. ISBN: 139780323030656
- Garg C. P.; Vaidya B. B. & Chengalath M. M. (2009) Efficacy of laparoscopy in complicated appendicitis. *International Journal of Surgery*. Vol. 7, No. 3, (May 2009), pp. 250-252, ISSN: 1743-9191
- Gillick J.; Velayudham M. & Puri P. (2001). Conservative management of appendix mass in children. *British Journal of Surgery*. Vol. 88, No. 11, (November 2001), pp. 1539-1542, ISSN: 0007-1323
- Hampson F. A. & Shaw A. S. Assessment of the acute abdomen: role of the plain abdominal radiograph. *Reports in Medical Imaging*. (2010), No. 3, 93-105, Dove Medical Press limited.
- Hernanz-Schulman M. (2010). CT and US in the diagnosis of appendicitis: an argument for CT. *Radiology*. Vol 255, no. 1, (April 2010), pp. 3-7, ISSN: 0033-8419
- Hoffman J.; Lindhard A. & Jensen H. (1984). Appendix mass: conservative management without interval appendectomy. *The American Journal of Surgery*. Vol. 148, No. 3, (September 1984), pp. 379-382, ISSN: 0002-9610
- Karim O. M.; Boothroyd A. E. & Wyllie J. H. (1990). McBurney's point - fact or fiction? *Annals of the Royal College of Surgeons of England*. Vol. 72, No. 5, (September 1990), 304, ISSN: 0035-8843
- Krukowski Z. H.; Al-Sayer H. M.; Reid T. M. S. & Matheson N. A. (1987). Effect of topical and systemic antibiotics on bacterial growth kinesis in generalised peritonitis in man. *British Journal of Surgery*. Vol. 74, No. 1, (April 1987), pp. 303-306, ISSN: 0007-1323
- Lander A. (2007). The role of imaging in children with suspected appendicitis: the UK perspective. *Pediatric Radiology*. Vol. 37, No. 1, (January 2007), pp. 5-9, ISSN: 0301-0449
- Lander A. D.; Ward H. & Brereton R. J. (1992). Perforated appendicitis in children: progress towards non-urgent operative treatment. *Unpublished Report*. (January 1992).
- Lee S. L.; Islam S.; Cassidy L. D.; Abdullah F. & Arca M. J. (2010). Antibiotics and appendicitis in the pediatric population; An American Pediatric Surgical

- association outcomes and Clinical Trials Committee Systematic review. *Journal of Pediatric Surgery*. Vol. 45, No. 11, (November 2010), pp. 2181-2185, ISSN 0022-3468
- Lintula H.; Kokki H.; Vanamo K.; Antila P. & Eskelinene M. (2002). Laparoscopy in children with complicated appendicitis. *Journal of Pediatric Surgery*. Vol. 37, No. 9, (September 2002), pp. 1317-1320, ISSN 0022-3468
- Liu C. D. & McFadden D. W. Acute abdomen and appendix. In: *Surgery – Scientific Principles and Practice*, (2003). Second edition. L. J. Greenfield, M. Mulholland, K.T. Oldham, G.B. Zelenock, K.D. Lillemoe, (Eds.), 1248-1260, Lippincott-raven-Publishers, ISBN 0-397-51481-6, Philadelphia, USA
- Mui L. M.; Ng C. S. H.; Wong S. K. H.; Lam Y. -H.; Fung T. M. K.; Fok K. -L.; Chung S. S. C. & Ng E. K. W. (2005). Optimum duration of prophylactic antibiotics in acute non-perforated appendicitis. *The Australian and New Zealand Journal of Surgery*. Vol. 75, No. 6, (June 2005), pp. 425-428, ISSN 1445-2197
- Naaeder S. B. & Archampong E. Q. (1998). Acute appendicitis and dietary fibre intake. *West African Journal of Medicine*. Vol. 17, No. 4, (October –December 1998), pp. 264-267, ISSN 0189-160X
- Nwokoma N. J. & Tsang T. T. (2011). Laparoscopy in Children and Infants, *Advanced Laparoscopy*, Ali Shamsa (Ed.), ISBN: 978-953-307-674-4, In Tech, available from: <http://www.intechopen.com/articles/show/title/laparoscopy-in-children-and-infants>
- Nwokoma N. J.; Hassett S. & Tsang TT. (2009). Trocar site adhesions after laparoscopic surgery in children. *Surgical Laparoscopic Endoscopic Percutaneous Techniques*. Vol. 19, No. 6, (December 2009), pp.511-513, ISSN 1530-4515
- Nwokoma N. J.; Swindells M. G.; Pahl K.; Mathur A. B.; Minocha A.; Kulkarni M. & Tsang T. T. (2009). Pediatric advanced appendicitis: open versus laparoscopic approach. *Surgical Laparoscopic Endoscopic Percutaneous Techniques*. Vol. 19, No. 2, (April 2009), pp.110-113, ISSN 1530-4515
- Oberhelman H. A. & Malott K. A. (2004). Intestinal Surgery. In: *Anesthesiologists Manual of Surgical Procedures*. Third edition. Jaffe R. A., Samuels S. I. (Eds.), Pp. 407-410. Lippincott Williams & Wilkins. Philadelphia USA. ISBN: 0-7817-4332-X
- Oyetunji T. A.; Ong'uti S. K.; Bolorundoro O. B.; Cornwell III E. E. & Nwomeh B. C. (2011). Pediatric Negative Appendectomy Rate: trend, predictors and Differentials. *Journal of Surgical Research*. (May 2011) 1-5. Epublication ahead of print. ISSN 0022-4804
- Pauniah S. L.; Vasama T.; Helminen M. T.; Iber T.; Mäkelä E. & Pajulo O. Non-absorbable interrupted versus absorbable continuous skin closure in pediatric appendectomies. *Scandinavian Journal of Surgery*. Vol. 99, No 3, (March 2010), pp. 142-146. ISSN 1457-4969
- Petras R. E. & Goldblum J. R. (1996). Appendix. In: *Anderson's pathology*. Tenth edition. I. Damjanov and J. Linder. (Eds.) 1728-1732. Mosby-Year Book. St. Louis, Missouri, USA. ISBN 0801672368
- Pickhardt P. J.; Levy A. D.; Rohrmann Jr. C. A. & Kende A. I. (2002). Primary neoplasms of the appendix manifesting as acute appendicitis: Ct findings with pathologic comparison. *Radiology*. Vol. 224, No. 3, (September 2002), pp. 775-781, ISSN: 0033-8419
- Puri P.; McGuinness E. P. & Guiney E. J. (1989) Fertility following perforation appendicitis in girls. *Journal of Pediatric Surgery*, Vol. 24, No. 6, (June 1989), pp. 547-549, ISSN: 0022-3468
- Raftery A.T. (2002). Basic Microbiology. In: *Applied Basic Science for Basic Surgical Training*. A.T. Raftery (Ed.) Pp. 139-157, Elsevier Science Limited. Philadelphia, USA. ISBN: 0443-061440

- Ramsden W. H.; Mannion R. A.; Simpkins K. C. & deDombal F. T. (1993). Is the appendix where you think it is - and if not does it matter? *Clinical Radiology*. Vol 47, No. 2, (February 1993), p. 100, ISSN: 0009-9260
- Rangabashyam N.; Anand B. S. & OmPrakash R. (2000). Abdominal tuberculosis. In: *Oxford Textbook of Surgery*. Second edition. P.J. Morris, W.C. Wood (Eds.) 3247-3249, Oxford University Press, New York, USA. ISBN: 0192628844.
- Rothrock S. G. & Pagane J. (2000). Acute appendicitis in children: emergency department diagnosis and management. *Annals of Emergency Medicine*. Vol 36, No. 1, (July 2000), p. 39, ISSN: 0196-0644
- Ryan K. J. & Ray C. G. (2010). *Sherris Medical Microbiology*. Fifth edition. Pp. 528-531. McGraw Hill Medical. USA. ISBN: 978-0-07-160402-4
- Samuel M. (2002) Paediatric Appendicitis Score. *Journal of Pediatric Surgery*, Vol. 37, No. 6, (June 2002), pp. 877-881, ISSN: 0022-3468
- Sarosi G. A. & Turnage R. H. (2002). Appendicitis. In: *Sleisenger and Fordtram's Gastrointestinal and Liver Disease*. Seventh edition. M. Feldman, L. S. Friedman, M.H. Sleisenger. (Eds.) Pp. 2089-2099. Saunders. Philadelphia, USA. ISBN: 0-7216-8973-6
- Schneider A.; Sack U.; Rothe K. & Bennek J. (2005). Peritoneal taurolidine lavage in children with localised peritonitis due to appendicitis. *Pediatric Surgery International*. Vol. 21, No. 6, (June 2005), pp. 445-448, ISSN: 0179-0358
- Schuch S.; Man C.; Cheng A.; Murphy A.; Mohanta A.; Moineddin R.; Tomlinson G.; Langer J. C. & Doria A. S. (2011) Predictors of non-diagnostic ultrasound scanning in children with suspected appendicitis. *Journal of Pediatrics*. Vol. 158, No. 1, (January 2011), pp. 112-8, ISSN: 0022-3476
- Sebire N. J.; Malone M.; Ashworth M. & Jacques T. S. (2010) *Diagnostic Pediatric Surgical Pathology*, p. 587. Churchill Livingstone Elsevier, Philadelphia. ISBN: 978-0-443-06808-9
- Semm, K. (1983). Endoscopic appendectomy. *Endoscopy*, Vol.15, No.2, (March 1983), pp. 59-64, ISSN: 0013726X
- Shreef K. S.; Waly A. H.; Abd-Elrahman S. & AbdElhafez M. A. (2010). Alvarado score as an admission criterion in children with pain in the right iliac fossa. *African Journal of Paediatric Surgery*. (2010), Vo. 7. No. 3, pp. 163-165, ISSN: 0186-2391
- Snell R. S. (2004). *Clinical Anatomy*. Seventh edition. P. 227. Lippincott Williams & Wilkins. Philadelphia, USA ISBN: 0-7817-4315-X
- Snell R. S. (2004). *Clinical Anatomy*. Seventh edition. P. 782. Lippincott Williams & Wilkins. Philadelphia, USA ISBN: 0-7817-4315-X
- Standring S.; Ellis H.; Healy J. C.; Johnson D. & Williams A. (2005). *Gray's Anatomy*. Thirty-ninth edition. 1188-1190. Elsevier Churchill Livingstone, Philadelphia, USA. ISBN: 0-443-06676-0
- Stevenson R. J. (2003). Appendicitis. In: *Operative Pediatric Surgery*. Ziegler M. M., Azizkhan R. G., Weber T. R. (Eds.), pp. 671-689. McGraw-Hill Companies. New York, USA. ISBN: 0-07-121239-6
- Strouse P. J. (2010) Paediatric appendicitis: an argument for US. *Radiology*. (Vol. 255, No. 1, (April 2010), pp. 8-13, ISSN: 0033-8419
- Surana R. & Puri P. (1995a). Appendiceal mass in children. *Pediatric Surgery International*, (February 1995), Vol. 10, No. 2-3, pp. 79-81, ISSN: 0179-0358
- Surana R.; O'Donnell B. & Puri P. (1995b). Appendicitis diagnosed following active observation does not increase morbidity in children. *Pediatric Surgery International*. Vol. 10, No. 2-3, (February 1995), pp. 76-78, ISSN: 0179-0358

- Swain R. S. (2005). Appendix and Meckel's diverticulum. In: *Principles and Practice of Pediatric Surgery*. K.T. Oldham, P.M. Clobani, R. P. Foglia & M. A. Skinner. Vol.2, p. 1269, Lippincott Williams & Wilkins, Philadelphia, USA. ISBN: 078174290-0
- Thoeni R. F. & Thornton R. Radiology of the Colon. In: *Diseases of the Colon*. (2007). S. D. Wexner and N. Stollman (Eds.), 178-183, informa healthcare, ISBN: 0-8247-2999-4, New York, USA
- Tsze D.S.; Asnis L. M.; Merchant R. C.; Amanullah S. & Linakis J. G. (2011). Increasing Computed Tomography Use for Patients With Appendicitis and Discrepancies in Pain management Between Adults and Children: Analysis of the NHAMCS. *Annals of Emergency medicine*, Vol. 58, No. 2, (August 2011), In press corrected proof) ISSN: 0003-4932
- Turner J. R. (2010). The gastrointestinal tract. In: *Robbins and Cotran Pathologic Basis of Disease*. V. Kumar, A.K. Abbas, N. Fausto, J.C. Aster (Eds.), 825-828, Saunders Elsevier, Philadelphia, USA. ISBN: 978-1-4160-3121-5,
- Vajcner G.; Postuma R. & Postuma R. (2011). Algometry: A novel tool in the diagnosis of children presenting with acute abdominal pain. *Presented at the 12th European Congress of Paediatric Surgeons*. Barcelona, Spain. (June 2011).
- VanMeter K. C.; VanMeter W. G. & Hubert R. J. (2010). Microbiology for the Healthcare Professional. Pp. 237-240. Mosby Elsevier. Missouri, USA. ISBN: 978-0-323-04594-0
- Waseem M. & Devas G. (2008). A child with appendicitis after appendectomy. *Journal of Emergency Medicine*. Vol. 34, No. 1, (January 2008), pp. 59-61, ISSN: 0736-4679
- Whisker L.; Luke D.; Hendrickse C.; Bowley D. M. & Lander A. (2009). Appendicitis in children: a comparative study between a specialist paediatric centre and a district general hospital. *Journal of Pediatric Surgery*. Vol. 44, No. 2, (February 2009), pp. 362-367, ISSN: 0022-3468
- Williams R. A. & Myers P. (1994). *Pathology of the Appendix*. 1-11, Chapman & Hall medical, London, United Kingdom. ISBN: 0-412-54810-0
- Wu H. P. & Fu Y. C. (2010). Application with repeated serum biomarkers in pediatric appendicitis in clinical surgery. *Pediatric Surgery International*. Vol. 26, No. 2, (February 2010), pp.161-166, ISSN: 0179-0358
- Zaupa P.; Lange C.; Bäuml D.; Karpf E. & Höllwarth M. (2011). Neurogenic appendicopathy in children. *Presented at the 12th European Congress of Paediatric Surgery*, (June 2011).

IntechOpen



Appendicitis - A Collection of Essays from Around the World

Edited by Dr. Anthony Lander

ISBN 978-953-307-814-4

Hard cover, 226 pages

Publisher InTech

Published online 11, January, 2012

Published in print edition January, 2012

This book is a collection of essays and papers from around the world, written by surgeons who look after patients of all ages with abdominal pain, many of whom have appendicitis. All general surgeons maintain a fascination with this important condition because it is so common and yet so easy to miss. All surgeons have a view on the literature and any gathering of surgeons embraces a spectrum of opinion on management options. Many aspects of the disease and its presentation and management remain controversial. This book does not answer those controversies, but should prove food for thought. The reflections of these surgeons are presented in many cases with novel data. The chapters encourage us to consider new epidemiological views and explore clinical scoring systems and the literature on imaging. Appendicitis is discussed in patients of all ages and in all manner of presentations.

How to reference

In order to correctly reference this scholarly work, feel free to copy and paste the following:

Ngozi Joy Nwokoma (2012). Appendicitis in Children, Appendicitis - A Collection of Essays from Around the World, Dr. Anthony Lander (Ed.), ISBN: 978-953-307-814-4, InTech, Available from:
<http://www.intechopen.com/books/appendicitis-a-collection-of-essays-from-around-the-world/appendicitis-in-children>

INTECH
open science | open minds

InTech Europe

University Campus STeP Ri
Slavka Krautzeka 83/A
51000 Rijeka, Croatia
Phone: +385 (51) 770 447
Fax: +385 (51) 686 166
www.intechopen.com

InTech China

Unit 405, Office Block, Hotel Equatorial Shanghai
No.65, Yan An Road (West), Shanghai, 200040, China
中国上海市延安西路65号上海国际贵都大饭店办公楼405单元
Phone: +86-21-62489820
Fax: +86-21-62489821

© 2012 The Author(s). Licensee IntechOpen. This is an open access article distributed under the terms of the [Creative Commons Attribution 3.0 License](#), which permits unrestricted use, distribution, and reproduction in any medium, provided the original work is properly cited.

IntechOpen

IntechOpen