

We are IntechOpen, the world's leading publisher of Open Access books Built by scientists, for scientists

4,800

Open access books available

122,000

International authors and editors

135M

Downloads

Our authors are among the

154

Countries delivered to

TOP 1%

most cited scientists

12.2%

Contributors from top 500 universities



WEB OF SCIENCE™

Selection of our books indexed in the Book Citation Index
in Web of Science™ Core Collection (BKCI)

Interested in publishing with us?
Contact book.department@intechopen.com

Numbers displayed above are based on latest data collected.
For more information visit www.intechopen.com



Imaging in Suspected Appendicitis

Nadim M. Muallem, Antoine N. Wadih and Maurice C. Haddad
*American University of Beirut Medical Center,
Department of Diagnostic Radiology, Beirut,
Lebanon*

1. Introduction

This chapter reviews the imaging modalities available for the diagnosis of appendicitis. The advantages and disadvantages of each technique and the impact of pre-operative imaging on the management of appendicitis as well cost- effectiveness are discussed.

2. Epidemiology

Appendicitis is a common problem encountered in acute care departments and represents approximately one fourth of all acute abdominal emergencies [1]. Addiss et al [2], estimated that approximately 250,000 cases of appendicitis occur annually in the United States alone. In a population of about 300 million, this translates into 1 case per 1200 individuals per year. The highest incidence of appendicitis was found in those aged 10-19 years with males having higher rates of appendicitis than females for all age groups. The lifetime risk of appendicitis is 8.6% for males and 6.7% for females whereas the lifetime risk of appendectomy is higher, estimated at 12.0% for males and 23.1% for females [2]. This suggests that more appendectomies are performed than required. Note that these figures were based on data collected during 1979-1984 at a time when cross-sectional imaging technology was only burgeoning, but it illustrates well the concern practitioners had about the morbidity and mortality of a ruptured or perforated appendicitis. The mortality rate of a complicated appendicitis had reached 3% and about 47% of patients experienced significant morbidity [3], which led to the accepted general notion that a negative appendectomy rate of 20% was acceptable with its much lower morbidity to balance the higher risks associated with perforation. Overall, an estimated 36 incidental procedures are performed to prevent one future case of appendicitis. Currently, negative appendectomy rates are much less, because of the incorporation of imaging tests in the pre-operative work-up.

In patients presenting to the emergency room with right iliac fossa pain, appendicitis remains the most frequent diagnosis accounting for 39% of patients, whilst less frequent causes include: non-specific abdominal pain (26%), gynecological (22%), and miscellaneous causes (14%) [4].

Given its high prevalence, the accurate diagnosis of appendicitis is therefore essential in any emergency setting in order to provide the most adequate management. The ideal diagnostic test or process, one with a high sensitivity and specificity, would be one that minimizes the rates of missed appendicitis, but also one that minimizes the need for unnecessary appendectomies.

3. Clinical diagnosis

The clinical diagnosis of appendicitis is suspected on the basis of history, physical examination and laboratory tests. A clinical scoring system may help and one was first developed by Alvarado [5] (see appropriate chapters). In the Alvarado system a low score of 1 to 4 suggests that there is only a low probability of appendicitis and some patients may be discharged without further investigation though some should be considered for imaging. It can be argued that all those with an Alvarado score of 5 to 7 should have imaging performed. In those with Alvarado scores of 8 to 10 there is a very high probability for appendicitis and appendectomy should be performed promptly without further studies.

The standard Alvarado scoring is useful in areas with limited resources and no imaging diagnostic tools. It may even help in avoiding unnecessary testing and eventually unnecessary exposure to ionizing radiation in clear cut cases with typical presentations and clinical findings of appendicitis. However, the standard Alvarado score has inadequate predictive values especially in children [6],[7], and results in a relatively high negative appendectomy rate of 8.8% [8].

Laboratory blood testing has been a staple in the evaluation of any clinically suspected infection; it even figures in the predictive scoring system of Alvarado. However, more recent studies suggest that WBC count is a poor predictor of the severity of the appendicitis [9].

Laparoscopy is a useful diagnostic and potentially therapeutic tool for evaluating patients with right lower abdominal pain especially in women and can be an alternative to active clinical observation [10].

4. Diagnostic imaging

The diagnosis of appendicitis should be prompt and accurate, and dependence on imaging techniques has become necessary. The risks of delay in the management of appendicitis secondary to waiting for imaging are largely outweighed by the benefits of the additional information provided by the imaging tests. Recent data show that the temporal components associated with perforated appendicitis are the duration of pre-hospital symptoms rather than the in-hospital delays to surgery [4]. Recently, a clear evidence-based guideline from the Dutch College of Surgeons recommends that appendectomy should not be carried out without prior imaging [11].

In this section, we review the most commonly available imaging techniques and their application to the diagnosis of appendicitis with emphasis on appropriateness, advantages, disadvantages and contraindications.

4.1 Conventional radiography

The traditional imaging techniques include conventional plain abdominal radiographs (PAR) and barium enema. PAR may show an appendicolith (Fig. 1) which is only present in 15% of patients with appendicitis. Importantly, those without appendicitis may have an incidental appendicolith identified on PAR or on CT scan (Fig. 2), with an incidence estimated at 2.6% in children. Appendicitis has been seen to develop in 5.8% to 6.7% of those with an appendicolith, which is little different than the average lifetime risk. Therefore, an incidental appendicolith may be a marker of increased but low risk for developing appendicitis when compared to the normal population and it is not an indication for prophylactic appendectomy in children and adults [12], [13].

The presence of air-fluid levels in the right lower quadrant or a “sentinel loop” may suggest a localized paralytic ileus or mechanical obstruction. Free peritoneal or extraluminal air can indicate a perforated appendicitis. Loss of the right psoas margin or displacement of the bowel loops in the right lower quadrant may be seen with abscess or phlegmon formation. However, these are non-specific features.

The diagnosis of appendicitis by barium enema depends mainly on the identification of indirect signs including non-filling of the appendix with barium sulfate or the presence of an extrinsic impression on the caecum by an appendiceal abscess.

Both the PAR and barium enema are insensitive methods for diagnosing appendicitis but in the absence of more advanced facilities, they are simple and inexpensive and may provide some useful information. Advanced cross-sectional imaging modalities have largely replaced PAR and barium enema in the diagnosis of appendicitis because of their limited diagnostic value [14].

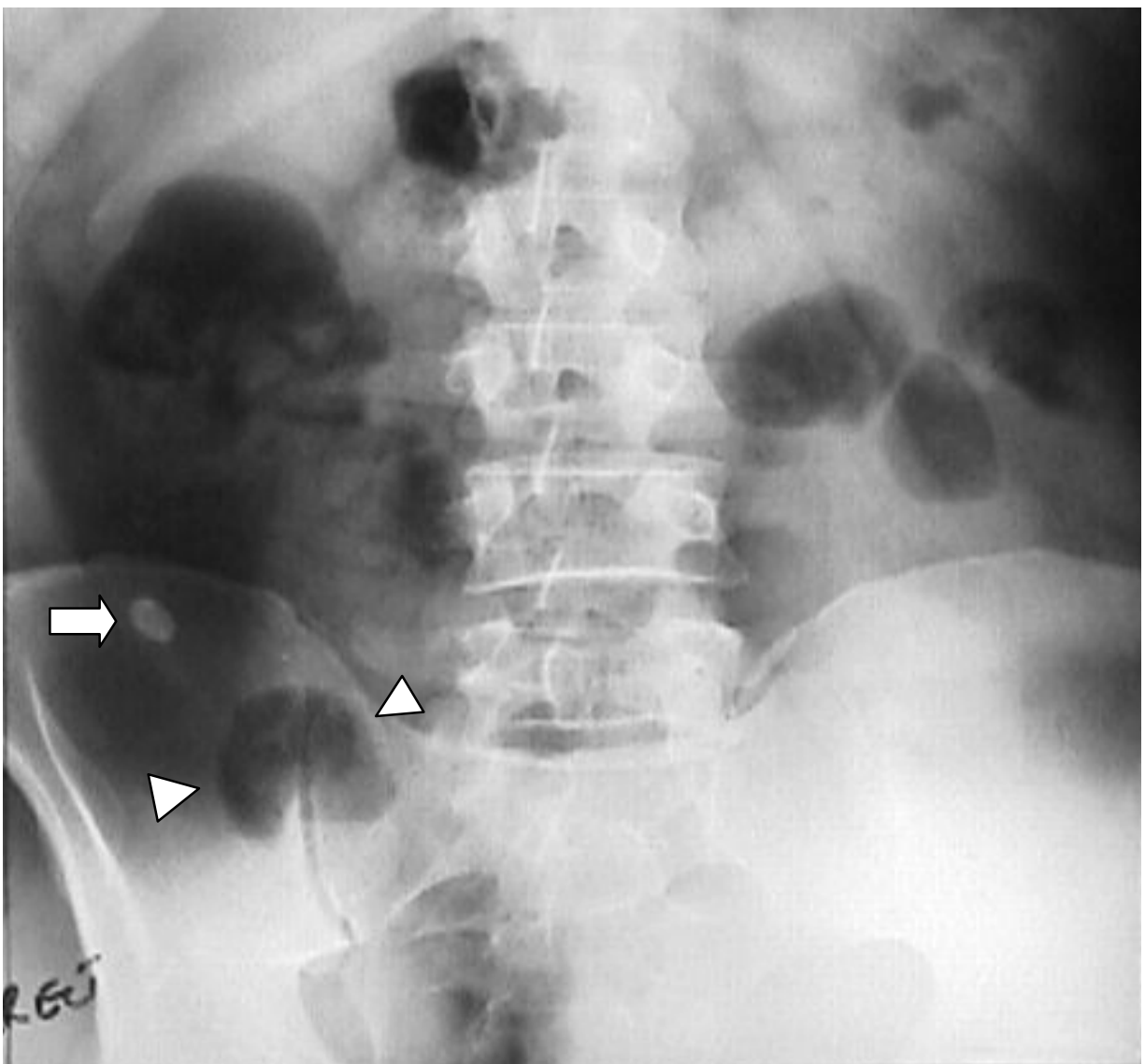


Fig. 1. Plain abdominal radiograph demonstrating the presence of an appendicolith (arrow) and a sentinel loop (arrowheads) in the right lower quadrant.

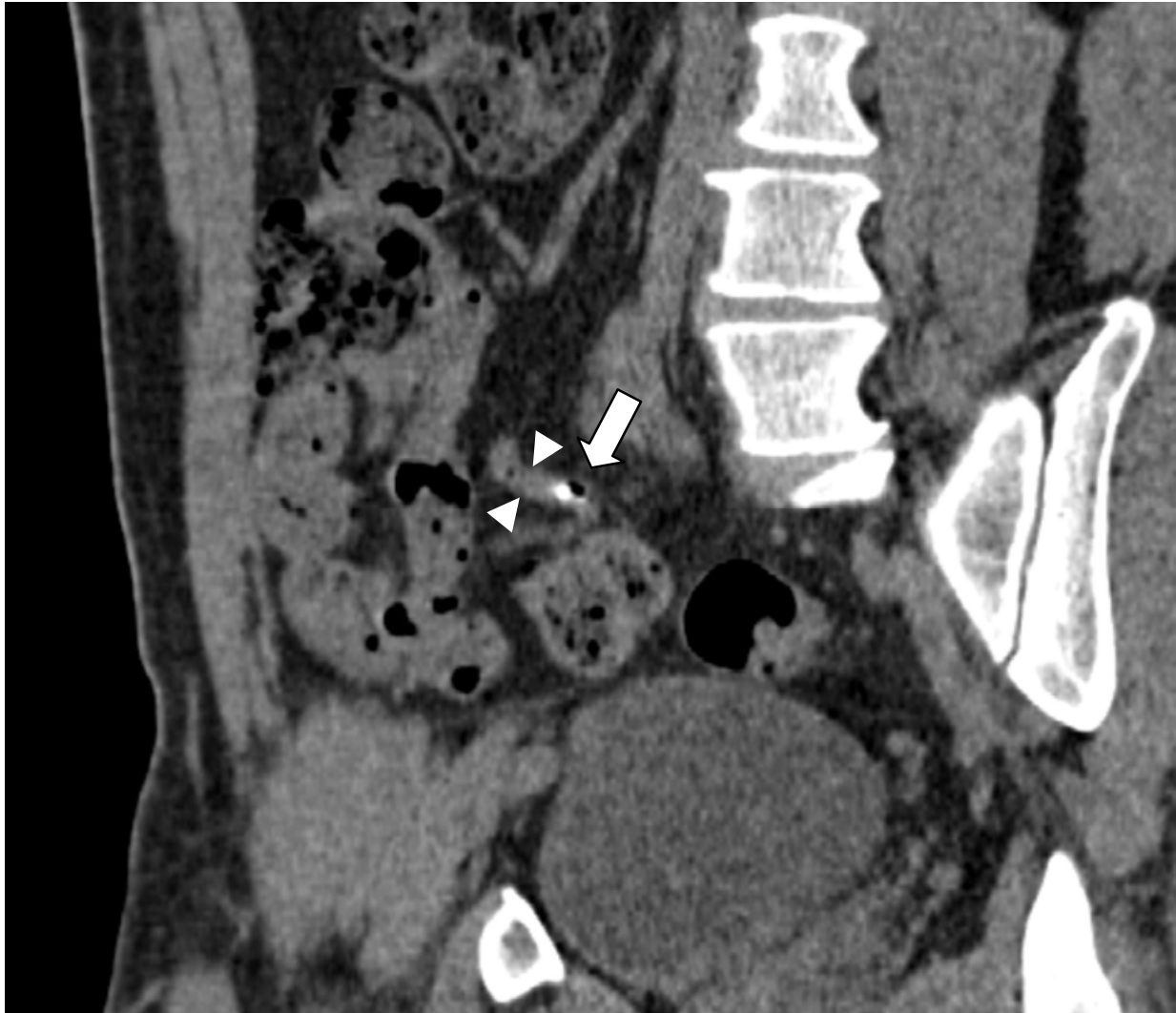

Fig. 2. Incidental appendicolith (white arrow) seen on a non-enhanced MDCT of the abdomen. This patient presented for routine evaluation and had no signs or symptoms of appendicitis. Notice the normal looking appendix (arrowheads) and lack of periappendiceal inflammation.

4.2 Cross-sectional imaging

The most widely used cross-sectional imaging techniques for the diagnosis of appendicitis are graded compression color Doppler ultrasound (CDUS) which is a non-irradiating technique and multi-detector CT scan (MDCT). Each has its particular advantages and disadvantages. MRI has been gaining popularity with its shorter acquisition times and with resolution approaching that of CT imaging without the burden of ionizing radiation.

4.2.1 Ultrasound US

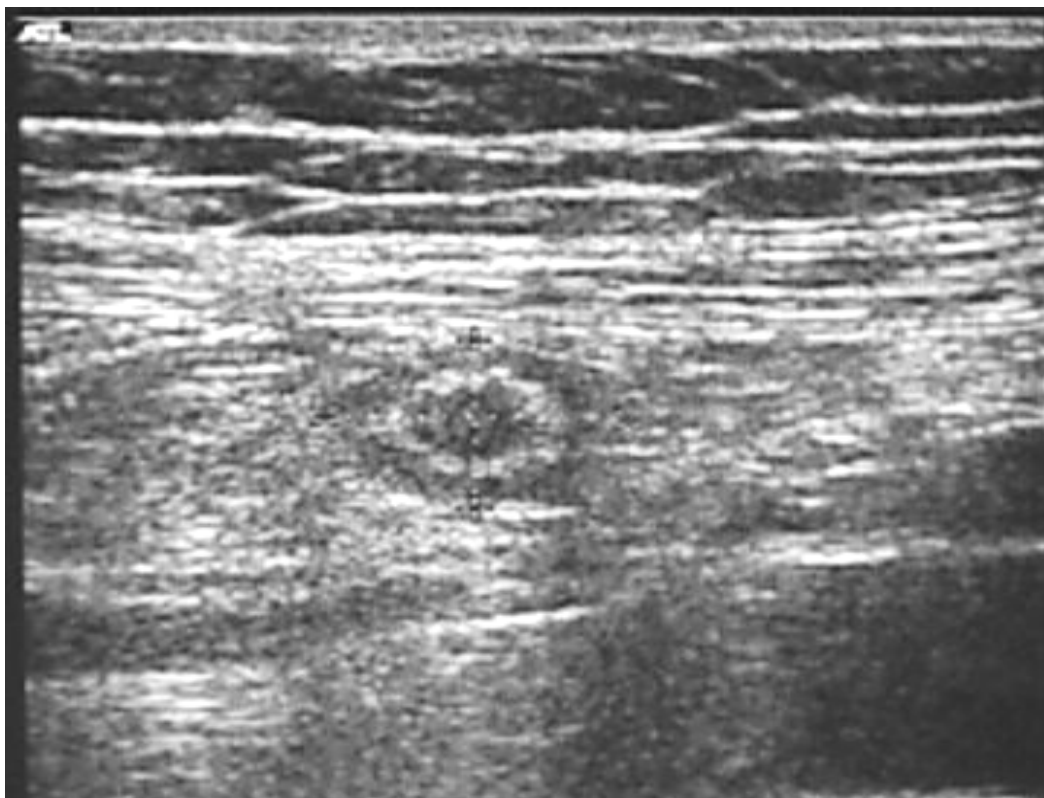Graded compression sonography using a linear high frequency 5-12 MHz transducer is a non-invasive low cost technique which is particularly suitable for children, young and pregnant women with suspected appendicitis. However, sonography has limitations

especially in the obese where tissue penetration is reduced and in the presence of a retrocecal appendix surrounded by bowel gas which prevents sound transmission. US allows visualization of a normal appendix in approximately 4% - 12% of patients without appendicitis as opposed to 43% to 75% with more advanced modalities such as MDCT [14], [15], [16]. Finally, sonography is essentially operator-dependent and requires years of formative training. Qualified technologists are not always available and the sensitivity of the examination is directly affected by the operator's competence, therefore, it has to be performed by experienced sonographers.

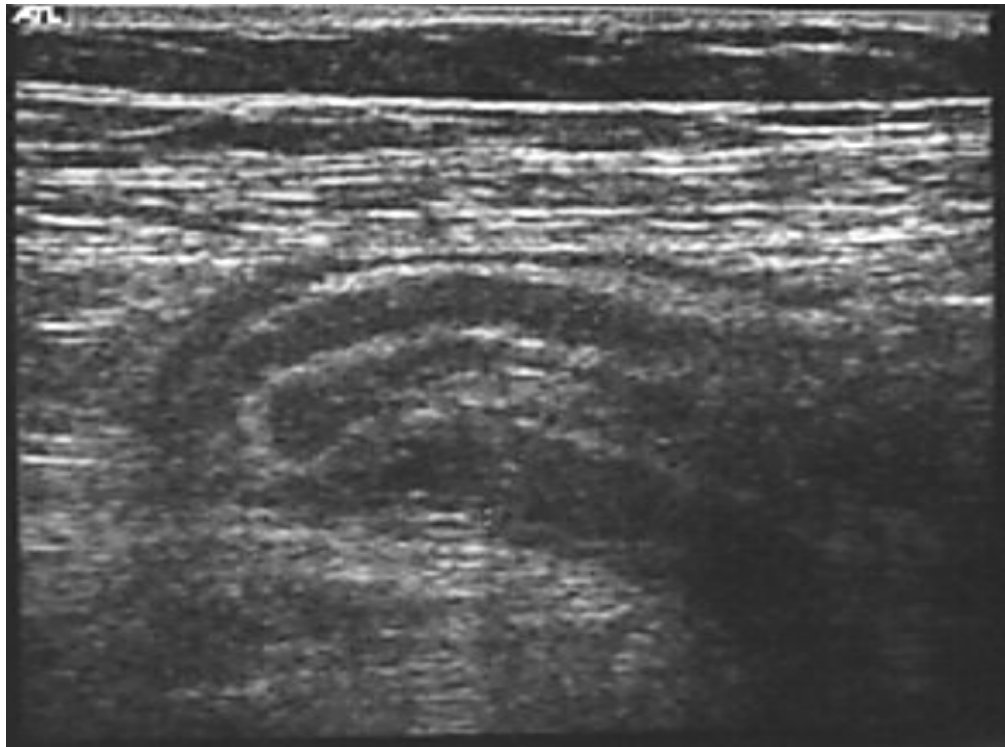
On real-time graded compression sonography, the identification of a non-compressible, thickened appendix greater than 6-7 mm in diameter is diagnostic of appendicitis (Fig. 3a, 3b). Other associated findings that can be determined on ultrasound are the presence of a hyperechoic appendicolith with posterior acoustic shadowing, or the presence of anechoic fluid or an abscess in the right lower quadrant (Fig. 4). Similar to the sonographic Murphy's sign in the diagnosis of cholecystitis, a sonographic "McBurney's" sign can be elicited by compressing the visualized inflamed appendix using the ultrasound probe which further enhances the diagnostic value of the ultrasound examination.

Color Doppler sonography permits the detection of increased blood flow in the wall of the inflamed appendix (Fig. 3c) and the absence of blood flow in the thickened appendiceal wall of the gangrenous appendix.

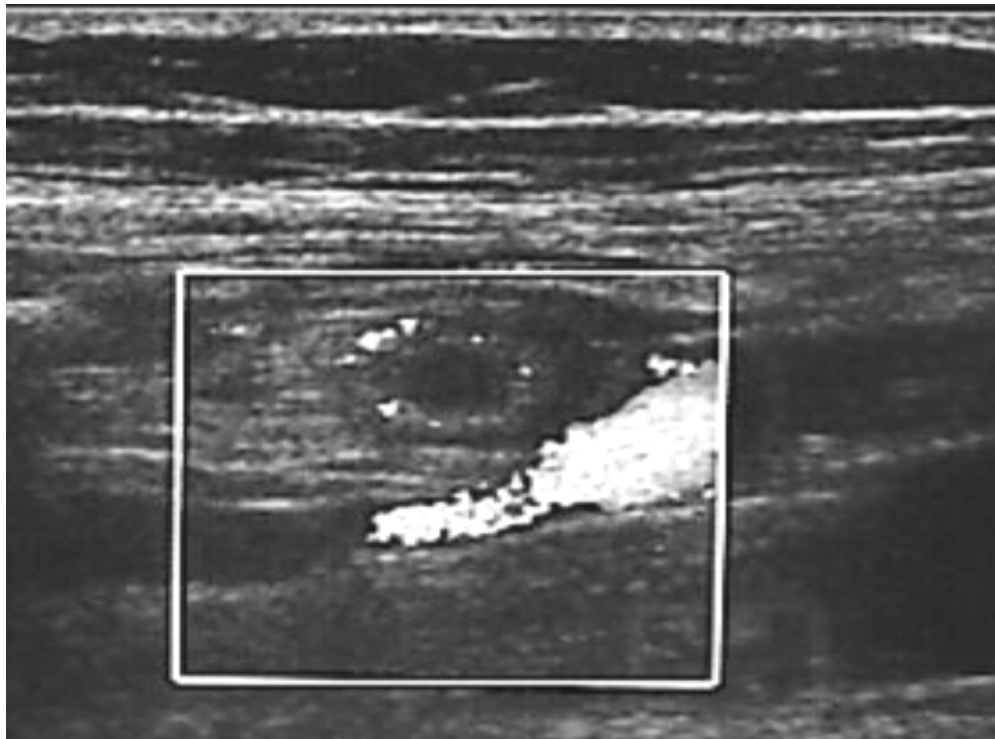
Real-time ultrasound elastography can be helpful in the depiction of the severity of inflammation [17].



a



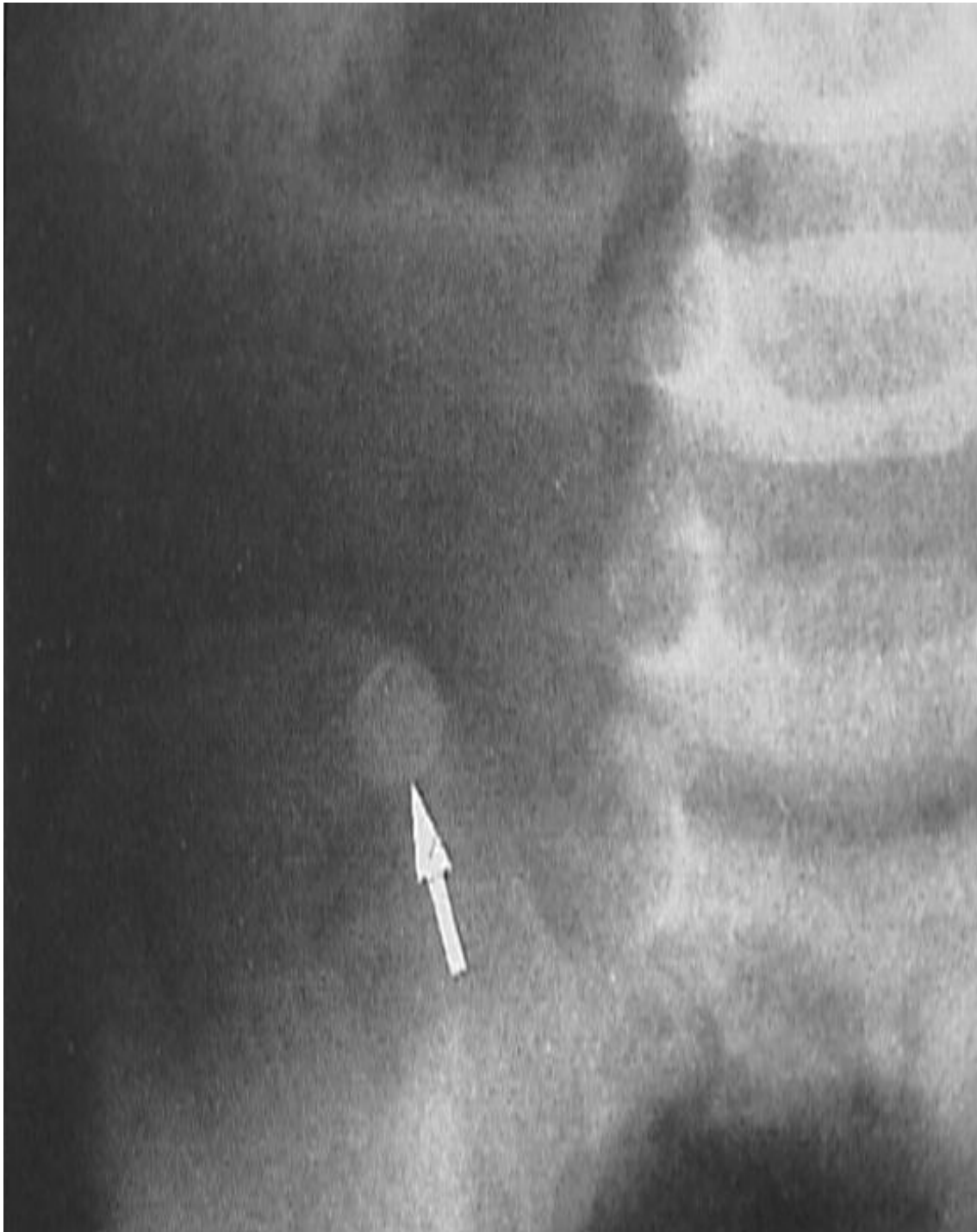
b



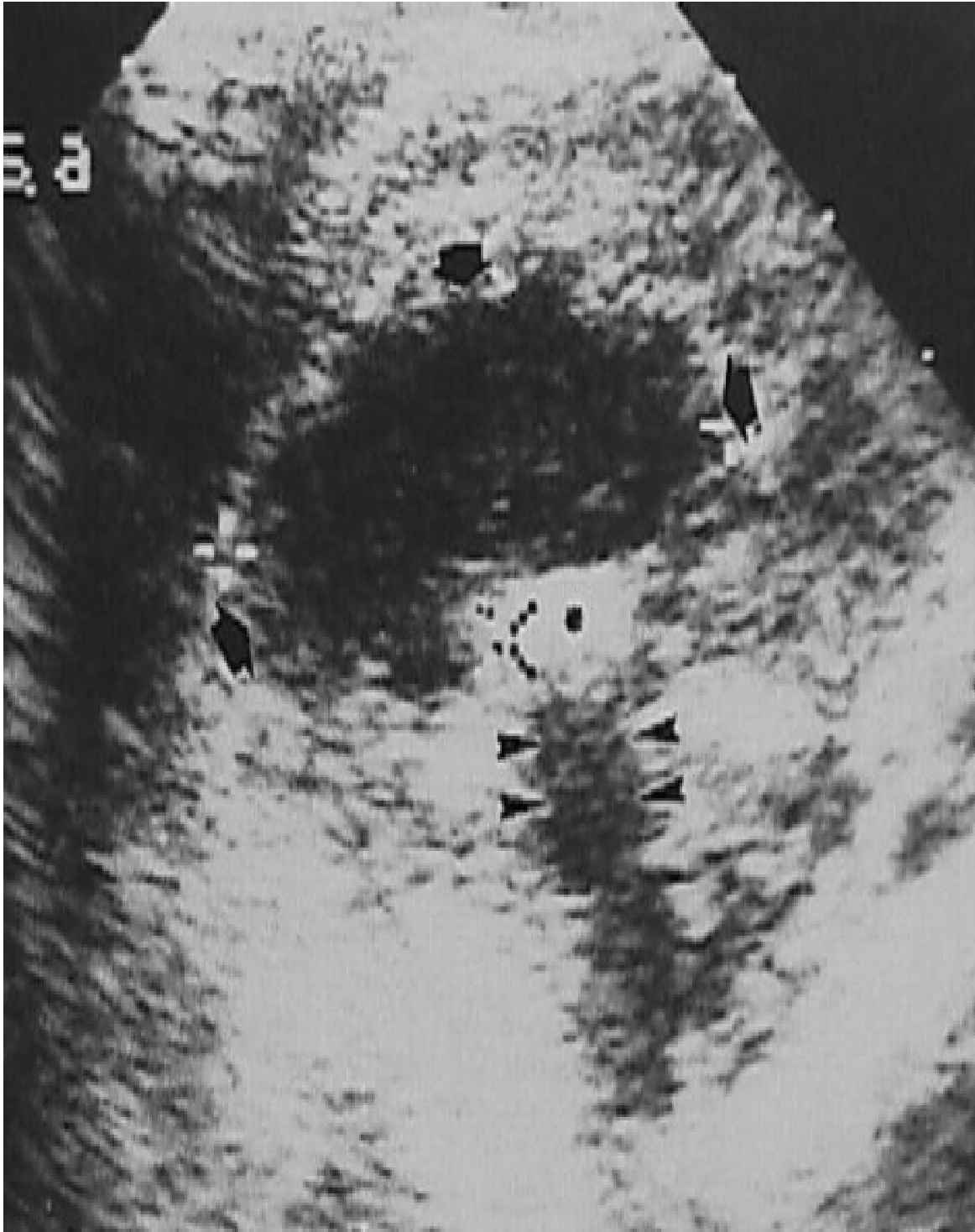
c

Fig. 3. Graded compression sonography images in transverse (a) and longitudinal (b) sections of an enlarged, non-compressible appendix (cursors) compatible with non-complicated appendicitis. Color Doppler flow image (c) demonstrated increased blood flow in the wall of the inflamed appendix due to hyperemia.

Because of its diagnostic limitations, if sonography is not capable of demonstrating a normal appendix or the sonographic diagnosis of appendicitis is equivocal, indeterminate or inconclusive, further evaluation preferably by more advanced cross-sectional imaging is required, such as an emergency MRI (in pediatric, young or pregnant patients). If MRI is not available, a contrast enhanced low dose MDCT with lower mA and kV exposure factors to minimize radiation is an option.



a



b

Fig. 4. Plain abdominal radiograph (a) and focal right lower quadrant ultrasound (b) images in a child with an appendiceal abscess showing the presence of an appendicolith (white arrow) on the plain abdominal radiograph, which demonstrates increased echogenicity and posterior acoustic shadowing on ultrasound (black arrowhead). The abscess is also seen on ultrasound as an overlying hypoechoic fluid collection containing debris (black arrows).

4.2.2 Multi-Detector Computed Tomography (MDCT)

Multi-detector CT (MDCT) is a fast scanning method which costs more than sonography and uses ionizing radiation. It is because of its exceptional higher diagnostic accuracy, speed of image acquisition and high resolution that MDCT has emerged in many centers as the primary imaging modality for pediatric and non-pregnant adult patients with suspected appendicitis. Table 1 lists the main differences between MDCT and ultrasound for the diagnosis of appendicitis.

Ultrasound	MDCT
Low cost	Higher cost
No radiation (use in children & women)	High radiation dose (caution in children & women, use of low dose MDCT)
Widely available	Not widely available
Operator-dependent	Not operator-dependent
Lower overall reported sensitivity & accuracy	Higher overall reported sensitivity & accuracy
Visualization of a normal appendix in 4%-12% of patients without appendicitis	Visualization of a normal appendix in 43% to 75% of patients without appendicitis

From: Haddad MC, et al. *LMJ* 2003; 51(4):211-5

Table 1. Listed differences between ultrasound and MDCT

Imaging findings on MDCT

On a contrast enhanced MDCT scan with intravenous and oral or rectal contrast, a normal appendix is identified at the cecal pole below the ileo-cecal valve, it appears filled with air and contrast material. Its caliber should be normally less than 7 mm, with intact periappendicular mesenteric fat (Fig. 5). However, a normal appendix may reach 11 mm in maximal diameter on a contrast enhanced MDCT scan with rectal contrast because of a better distention of the colon than with oral contrast [18], [19]. Non-filling of a thickened appendix with enhancement of its wall and streaking of the periappendiceal fat are major and direct diagnostic signs of a non-complicated appendicitis (Fig. 6, 7), whilst an appendicitis complicated by perforation will show periappendiceal abscess formation on MDCT (Fig. 8). An appendicolith may or may not be seen and is usually found on MDCT much more frequently than on conventional radiographs. Secondary or indirect signs of appendicitis which may provide clues to the diagnosis include inflammatory changes and fat streaking around the cecal pole, a fluid collection in the right lower quadrant and small bowel obstruction.

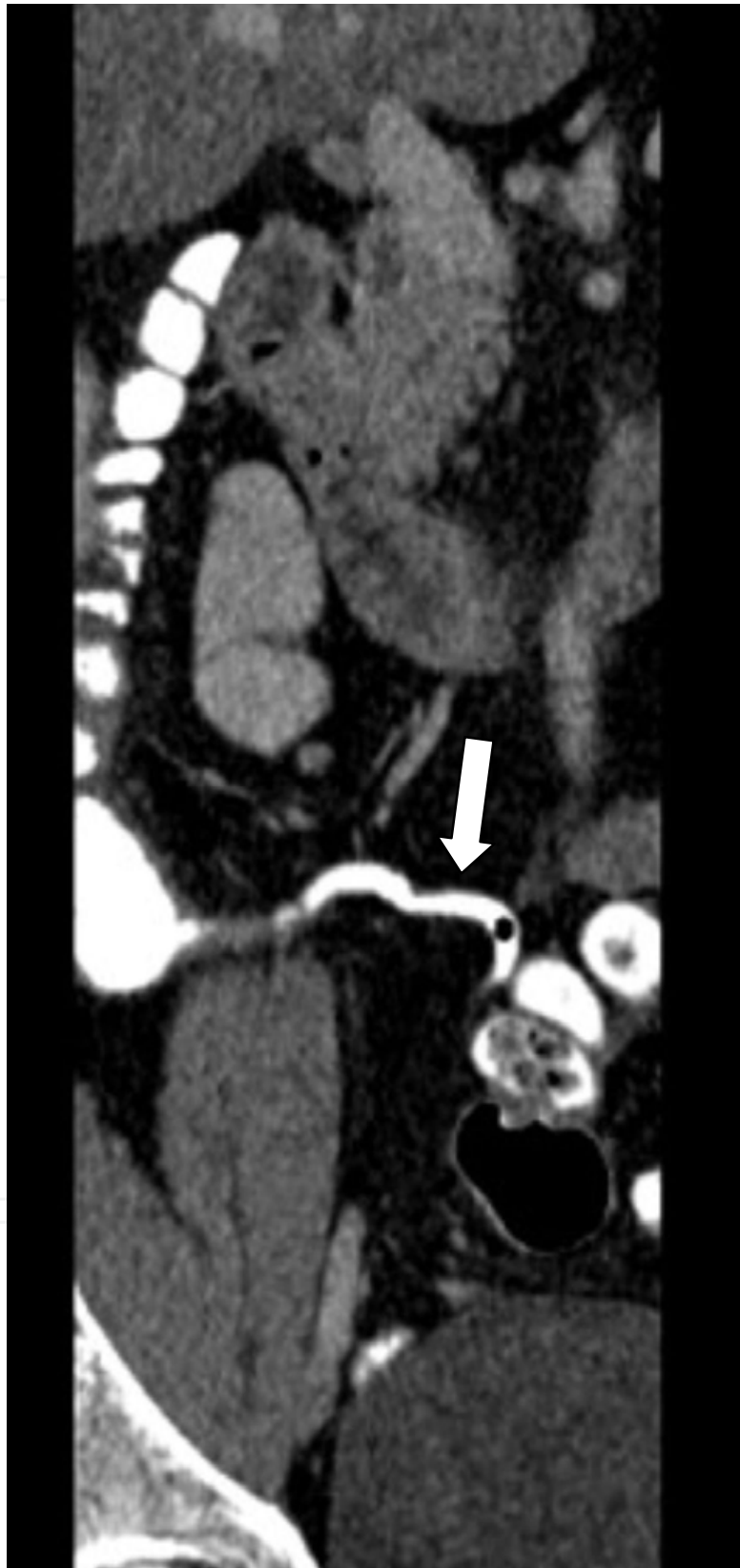

Fig. 5. Coronal image of a MDCT scan with intravenous and rectal contrast enema. The appendix is shown filled with contrast (white arrow) and has a normal caliber (6mm). The surrounding mesenteric fat is intact.

In a study by Nikolaidis et al. [20], non-visualization of the appendix on MDCT with intravenous and oral contrast was encountered in 15% of adults and in 30% of children. The main cause was the paucity of intra-abdominal fat which deprives the radiologist from the negative contrast that fat provides. However, in the absence of a distinctly visualized appendix and secondary inflammatory changes, the incidence of appendicitis was found to be low, estimated at 2%.

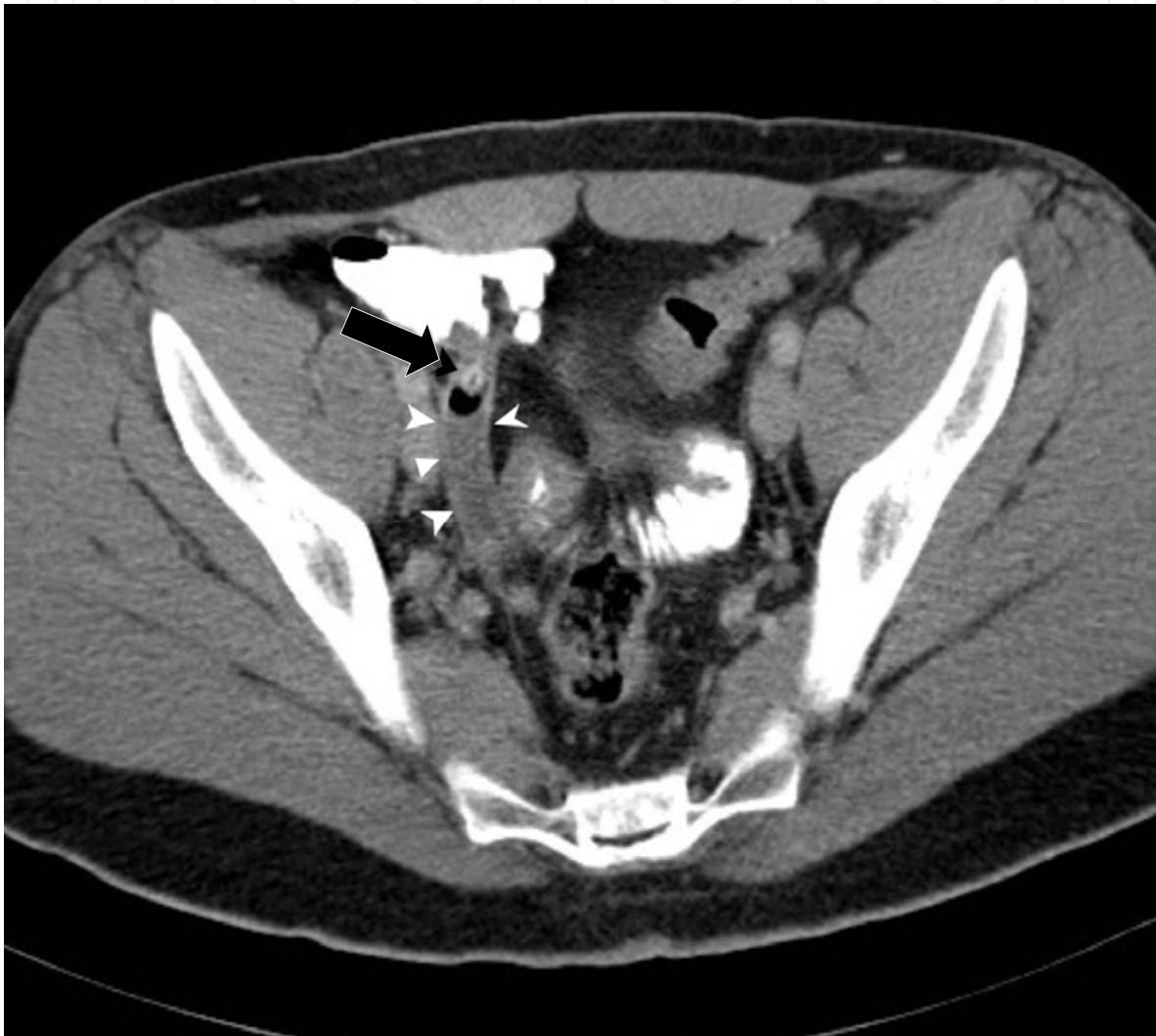

Fig. 6. MDCT scan with intravenous and oral contrast in a 29-year-old man with right lower quadrant pain, vomiting, and low-grade fever. The appendix (white arrowheads) is fluid filled, shows an increased caliber ($> 7\text{mm}$), and is not opacified by contrast despite adequate filling of the cecum consistent with non-complicated appendicitis. An appendicolith (*black arrow*) is identified in its proximal segment.

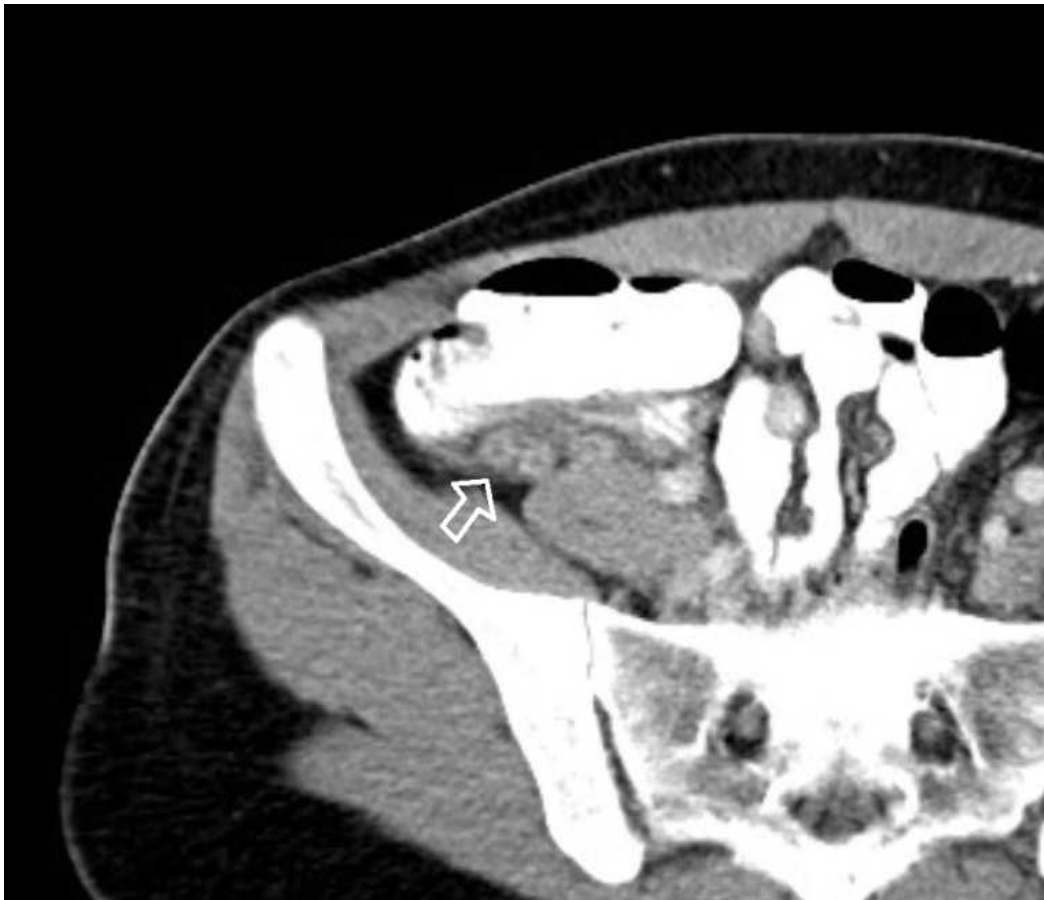
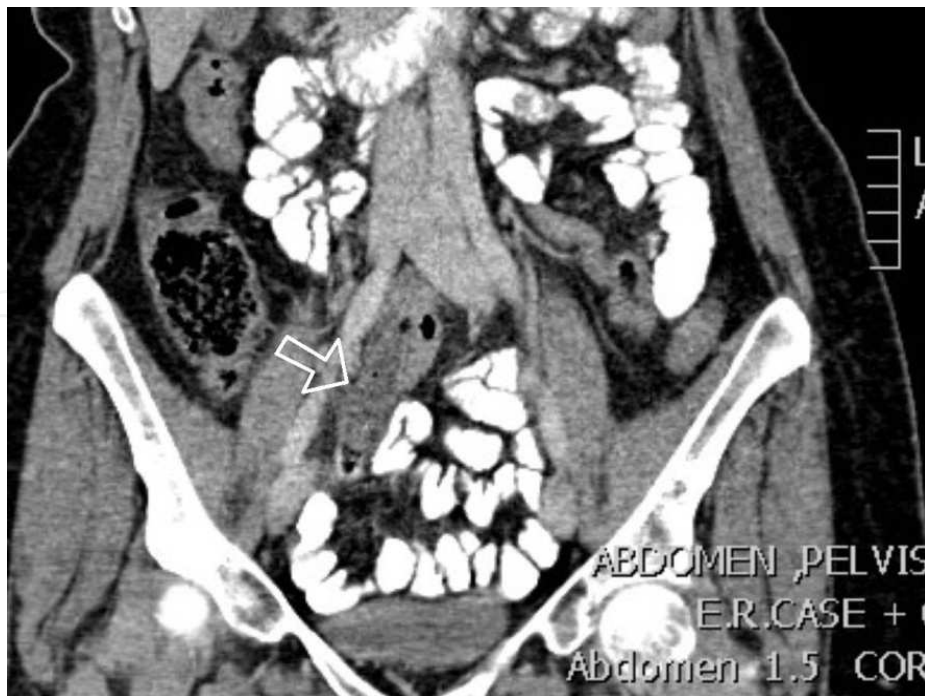
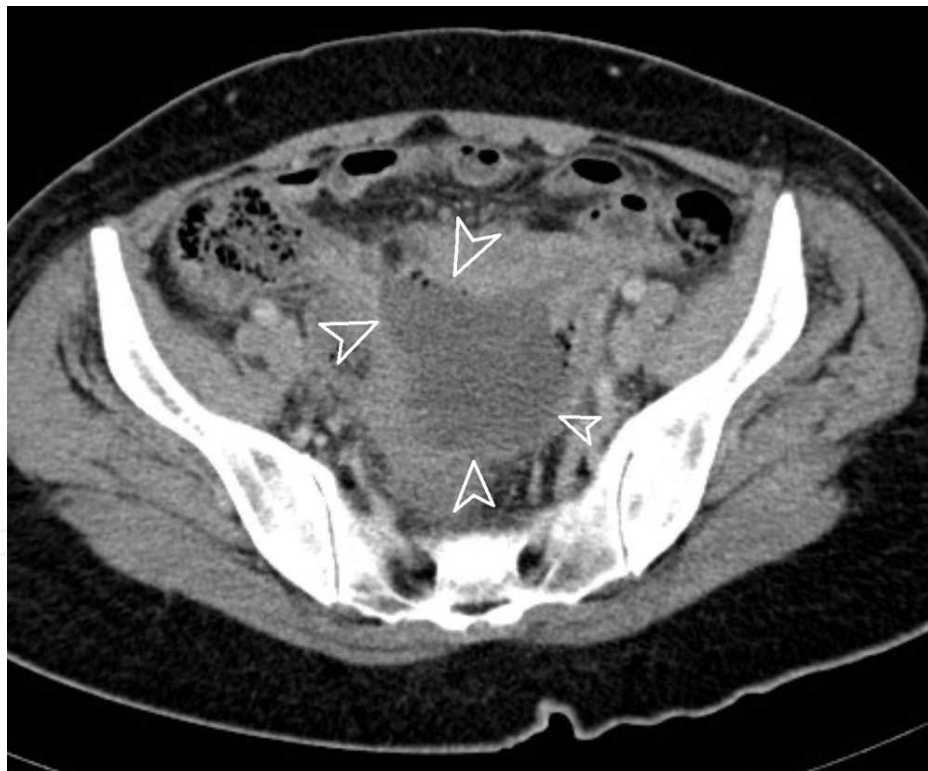Fig. 7. MDCT with intravenous and oral contrast axial image demonstrating a retrocecal appendix (*white arrow*) that is not opacified with contrast with wall enhancement and streaking of the surrounding mesenteric fat consistent with non-complicated appendicitis.

CT imaging protocols

There are a variety of different imaging and contrast protocols for the diagnosis of appendicitis. It has been the experience at our institution that the highest diagnostic value can be obtained from a contrast enhanced MDCT scan with an intravenous contrast bolus and a rectal contrast enema. 25 ml (Telebrix 350 mgI/ml, Guerbet) of water-soluble iodinated contrast diluted in 1.5 L of warm water is given as a rectal enema in an adult in the right decubitus position to properly opacify the cecum. Contrast enhanced MDCT with rectal contrast enema has yielded an accuracy of 94.7% in the diagnosis of appendicitis [18]. The advantages of a MDCT with intravenous and rectal contrast enema include high diagnostic accuracy, particularly in the thin or constipated patient where visualization of the appendix can be limited. A rectal contrast enema serves to distend and opacify the appendix if it is normal and has a patent lumen. Non opacification of the appendix despite adequate filling of the cecum is a highly sensitive, specific and reproducible diagnostic sign of appendicitis [18]. It is a relatively fast technique and it takes about 5-10 minutes more than a non-enhanced MDCT scan in order to account for the time needed for the administration of the enema. The disadvantage of MDCT with a rectal contrast enema is that some patients may experience discomfort, intolerance and abdominal cramps during the administration of the enema. It is therefore recommended to use warm water for the enema and a slow enema infusion rate as well as spasmolytics if needed.



a



b

Fig. 8. MDCT scan with intravenous and oral contrast images of a patient in whom appendicitis was missed on initial presentation and later returned with a ruptured appendicitis and pelvic abscess formation. Initial exam (a) revealed a fluid filled blind-ended tubular structure (arrow) with extensive surrounding fat streaking consistent with the inflamed appendix. On the patient's second presentation (b), the appendix had ruptured and produced a large pelvic abscess (arrowheads) containing tiny pockets of gas.

Alternatively, contrast enhanced MDCT with intravenous and oral contrast administration for bowel opacification is a more commonly used technique. It is generally more accepted by patients than rectal contrast enema, however, its main disadvantage compared to the MDCT with rectal contrast enema is a prolonged waiting time as mentioned previously, mainly because of the contrast transit time to reach the cecum (60 to 120 minutes) in order to properly opacify the terminal ileum and possibly the appendix.

Furthermore and because of its progression through the entire small bowel, the amount of contrast that eventually reaches the cecum does not provide sufficient luminal distention as compared to the rectal contrast enema study. Therefore distention and opacification of the appendix, even when normal, is not always guaranteed with oral contrast MDCT studies.

Also, many patients presenting to the emergency department with suspected appendicitis have nausea and vomiting which precludes the drinking of the 1.5 L of oral contrast.

The use of IV contrast is advocated in both rectal and oral contrast MDCT studies as it provides additional diagnostic clues that may indicate the presence of appendicitis such as appendiceal wall enhancement which also represents a major criterion or diagnostic sign.

Finally, a non-enhanced or plain MDCT scan may be used if there is a contraindication for the usage of iodinated contrast material such as contrast-induced nephropathy in patients with renal function impairment, or a positive history for severe allergic reactions to contrast media. A non-enhanced MDCT scan remains the fastest study that can be performed with short image acquisition time while still maintaining a high diagnostic accuracy without fear of adverse reactions or patient intolerance.

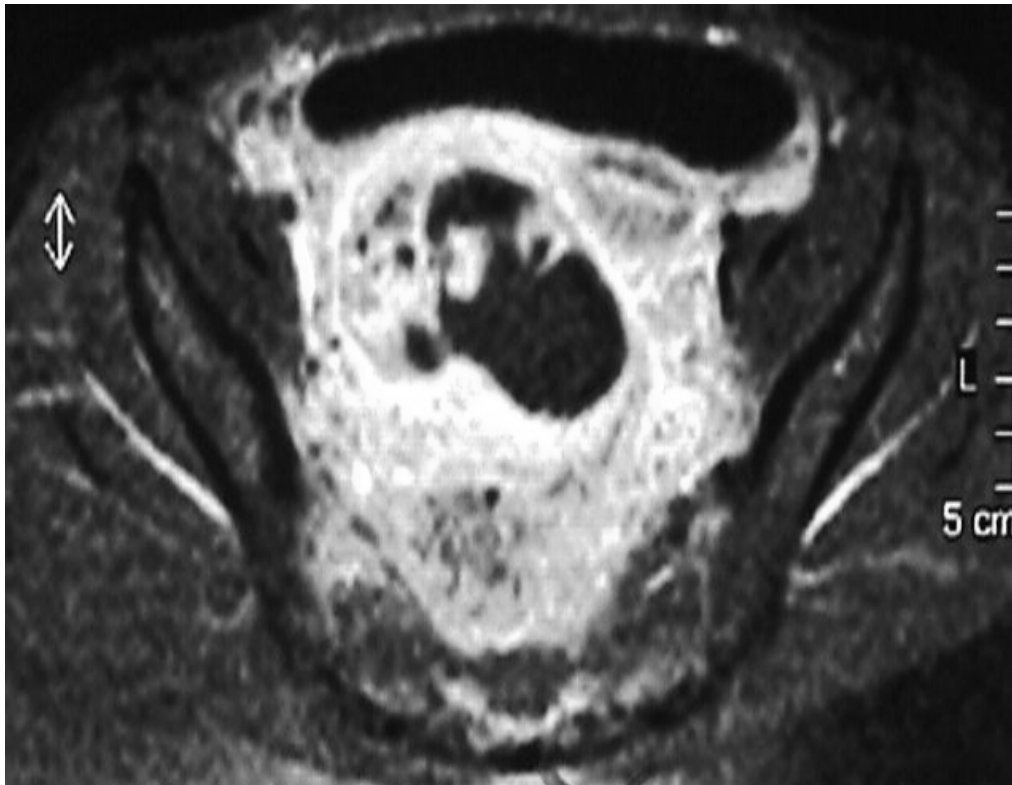
It is important to emphasize, however, that the routine use of MDCT imaging, despite its high diagnostic accuracy, carries the burden of increased exposure to ionizing radiation. Care should be taken not to expose pediatric and pregnant women without proper justification and discussion with the patients or surrogates about the risks of the examination versus the benefits.

4.2.3 Magnetic Resonance Imaging (MRI)

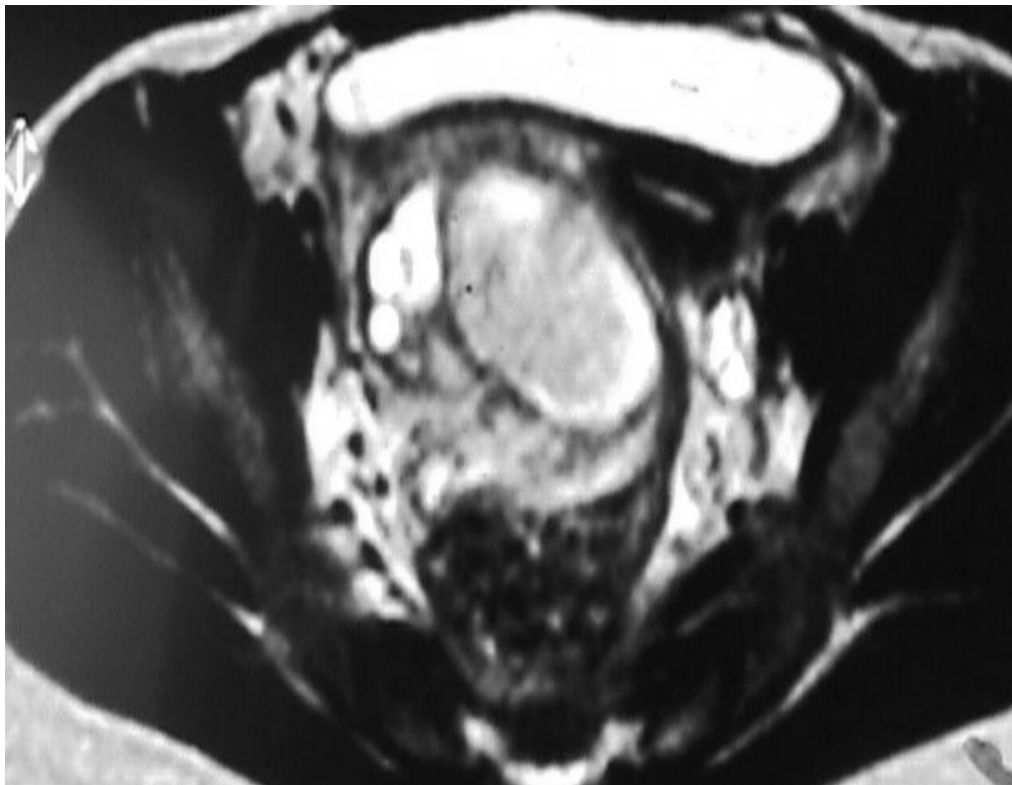
MRI is a non-irradiating imaging technique but is not as widely or readily available as ultrasound and MDCT. It is more expensive and the examination itself takes a longer time to perform, and image quality has a higher chance of becoming degraded by motion artifacts [21].

Because of major concern about risks and hazards from exposure to high radiation doses and potential allergic and toxic effects of intravenous contrast material associated with MDCT, MRI is increasingly becoming the study of choice to evaluate children and pregnant women with suspected appendicitis and non-diagnostic ultrasound results. Pregnant patients can be accepted to undergo MR scans at any trimester or stage of pregnancy, however, MR contrast agents should not be administered to pregnant patients because of their potential teratogenic effects [22]. Most studies reported the use of T1, T2 and T2 fat saturation sequences with axial and coronal acquisitions, with or without additional T1 post contrast image in the absence of any contraindication.

On MRI (Fig. 9), a thickened appendix of more than 7 mm in diameter, an appendiceal wall thicker than 2 mm, signs of inflammatory changes surrounding the appendix or presence of a pelvic abscess are diagnostic signs of appendicitis [21]. A meta-analysis of recently published data regarding the utility of MRI in pregnant women with suspected appendicitis performed by Blumenfeld and colleagues showed high diagnostic accuracies of MRI in the diagnosis of appendicitis [23].



a



b

Fig. 9. T2-weighted MR images (a and b) demonstrating an abscess formation in the pelvis secondary to a ruptured or perforated appendicitis in a child.

4.3 Scintigraphy

Scintigraphy using technetium-99m labeled leukocytes (Tc-99m HMPAO) or technetium-99m monoclonal antibodies-leukoscan (LeuTech anti-CD 15) allow detection of appendicitis with a sensitivity ranging between 81% and 100% and a reported specificity ranging between 82% and 100% [12]. The scintigraphic examinations should be interpreted with caution because focally increased uptake of the radiotracer in the right lower quadrant can indicate an inflammatory source that may be due to appendicitis as well as other inflammatory conditions such as diverticulitis and Crohn's disease. The major disadvantages of scintigraphy are cost, exposure of patients to ionizing radiation, limited availability of the radiotracer and a long scanning time.

The utility of 18F-FDG PET-CT imaging in the diagnosis of appendicitis was highlighted by researchers in a few case reports [24], [25], [26]. Its performance compared to conventional MDCT scan is yet to be determined, and availability of the radiotracer also limits its regular use in most centers.

5. Differential diagnosis

There are many conditions that may mimic appendicitis and one of the reasons why MDCT scan has gained such an increasing popularity over recent years is because of its ability to detect and differentiate other causes of right lower quadrant pain which occur in approximately 32% of patients investigated for suspected appendicitis [27], [28]. It is important to keep in mind these alternative diagnostic possibilities or differential diagnoses when evaluating patients with right lower quadrant pain, as their treatment options differ from each other and from that of appendicitis.

These clinical mimickers include:

- Mesenteric adenitis
- Crohn's disease
- Primary epiploic appendagitis
- Neutropenic typhlitis in cancer and transplant patients on immunosuppression
- Cecal diverticulitis
- Familial Mediterranean fever
- Omental torsion
- Lupus peritonitis
- Bowel perforation without evidence of a pneumoperitoneum
- Torsion of a Meckel's diverticulum
- Ureteric colic
- Gynecological emergencies such as ovarian torsion, pelvic inflammatory disease, uterine fibroids, etc...

Some of these conditions may be surgical, but on the other hand it is of utmost importance to recognize the non-surgical conditions at imaging such as mesenteric adenitis or epiploic appendagitis among others, thus avoiding unnecessary surgery. Color Doppler ultrasound and MDCT can readily exclude appendicitis and differentiate it from these mimickers by the identification or visualization of a normal appendix.

6. Treatment

Differentiation of complicated from uncomplicated appendicitis may be of greater importance in the future as several studies are now suggesting differing treatment options.

In uncomplicated appendicitis, laparoscopic appendectomy is currently the standard treatment but non-operative management with antibiotics alone may be a justifiable alternative [29], [30].

For appendicitis complicated by perforation and abscess formation, MDCT scan can help guide percutaneous catheter drainage (Fig. 10) followed by interval appendectomy [31], [32].

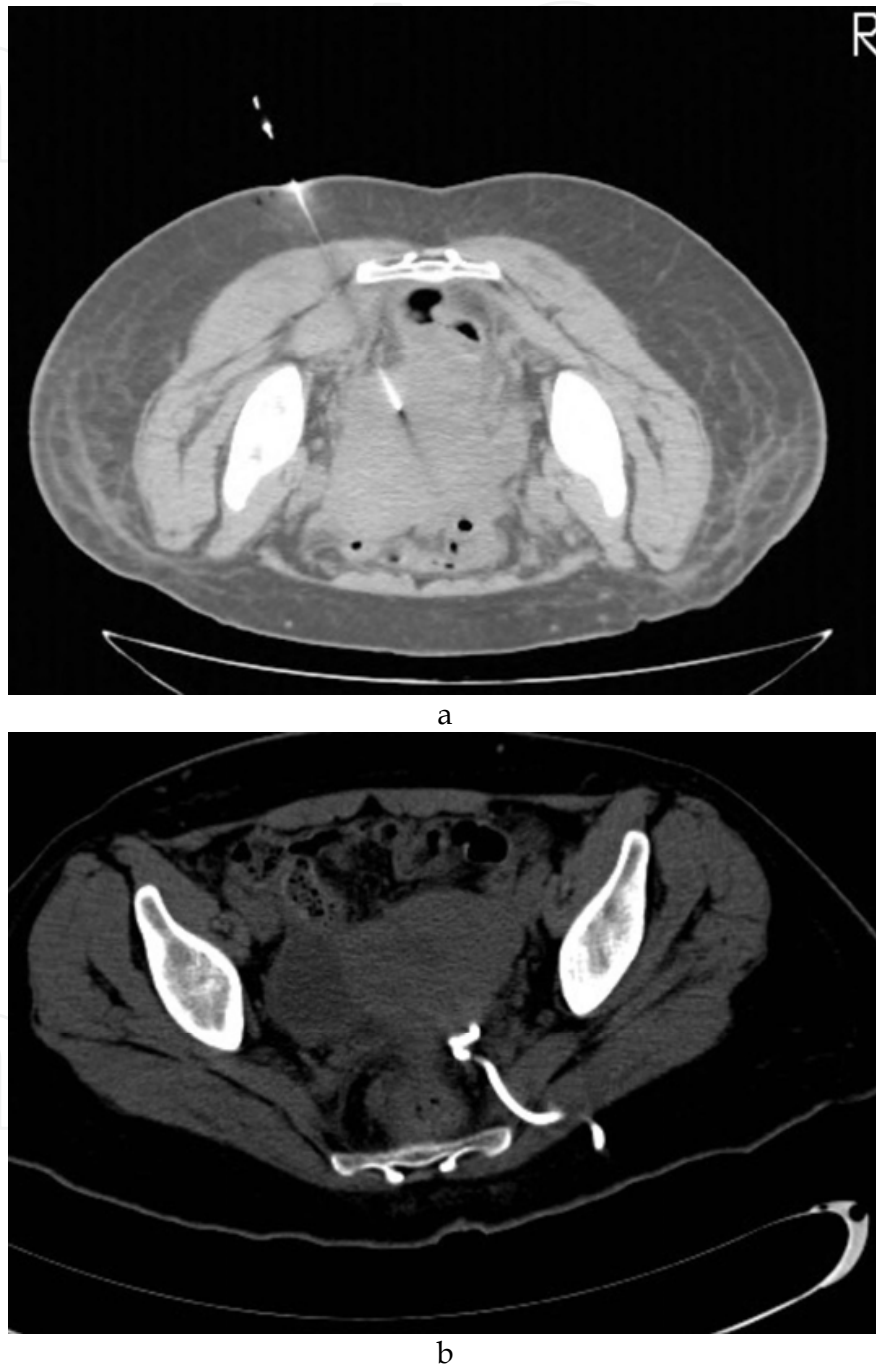


Fig. 10. CT-guided percutaneous catheter drainage of a pelvic abscess secondary to a ruptured appendicitis. (a) CT-guidance for a percutaneous transgluteal approach needle and catheter insertion. (b) Follow-up MDCT image showing complete healing of the pelvic abscess. Patient underwent subsequent elective and interval appendectomy shortly afterward.

7. Cost-effectiveness

Imaging provides a quick and accurate diagnosis of appendicitis, which has several clinical and economical implications.

- It allows an early diagnosis of appendicitis and so in some may reduce the risk of perforation with its associated morbidity and prolonged hospitalization time.
- Its routine use results in a reduction in the number of patients admitted to the hospital for clinical observation with a reduction in cost.
- It identifies alternative diagnoses namely non-surgical acute abdominal and pelvic emergencies, therefore avoiding unnecessary operations and reducing cost.
- It significantly decreases the negative appendectomy rate which is used in several hospitals as a Performance Indicator (PI) for quality assurance and accreditation. Routine pre-operative imaging for suspected appendicitis has significantly reduced the negative appendectomy rate (NAR) to 4% at our institution compared to a previous NAR of 16% during the era of clinical diagnosis when used alone without pre-operative imaging [33]. This is of particular concern since some third party payers may not cover the costs of removal of a histologically normal appendix at surgery.

8. Conclusion

There is an increasing consensus for routine pre-operative imaging in patients with suspected appendicitis. Ultrasound is the imaging modality of first choice in children and pregnant women because of concerns about exposure to ionizing radiation and secondary carcinogenic and teratogenic potential risks. If the ultrasound examination is non-diagnostic, then MRI is the next choice. Multi-detector CT remains the preferred imaging modality in adults because of its higher diagnostic accuracy. Imaging has proven to have a great impact on clinical outcome and cost-effectiveness in patients presenting to the emergency room with suspected appendicitis.


9. References

- [1] Federle MP. Focused appendix CT technique: a commentary. *Radiology* 1997 Jan;202:20-1.
- [2] Addiss DG, Shaffer N, Fowler BS, et al. The epidemiology of appendicitis and appendectomy in the United States. *Am J Epidemiol* 1990;132:910-25.
- [3] Rybkin AV, Thoeni RF. Current concepts in imaging of appendicitis. *Radiol Clin North Am* 2007;45:411-22.
- [4] McCartan DP, Fleming FJ, Grace PA. The management of right iliac fossa pain - is timing everything? *Surgeon*. 2010 Aug;8(4):211-7.
- [5] Alvarado A. A practical score for the early diagnosis of acute appendicitis. *Ann Emerg Med*. 1986 May;15(5):557-64.
- [6] Schneider C, Kharbanda A, Bachur R. Evaluating appendicitis scoring systems using a prospective pediatric cohort. *Ann Emerg Med*. 2007 Jun;49(6):778-84.
- [7] Mandeville K, Pottker T, Bulloch B. Using appendicitis scores in the pediatric ED. *Am J Emerg Med*. 2010 Jul 30. [Ahead of print]

- [8] Bhatt M, Joseph L, Ducharme FM, Dougherty G, McGillivray D. Prospective validation of the pediatric appendicitis score in a Canadian pediatric emergency department. *Acad Emerg Med*. 2009 Jul;16(7):591-6.
- [9] Coleman C, Thompson JE Jr, Bennion RS, Schmit PJ. White blood cell count is a poor predictor of severity of disease in the diagnosis of appendicitis. *Am Surg*. 1998 Oct;64(10):983-5.
- [10] Lim GH, Shabbir A, So JB. Diagnostic laparoscopy in the evaluation of right lower abdominal pain: a one-year audit. *Singapore Med J*. 2008 Jun;49(6):451-3.
- [11] Bakker OJ, Go PM, Puylaert JB, Kazemier G, Heij HA. Guideline on diagnosis and treatment of acute appendicitis: imaging prior to appendectomy is recommended. *Ned Tijdschr Geneesk*. 2010;154:A303.
- [12] Rollins MD, Andolsek W, Scaife ER, Meyers RL, Duke TH, Lilyquist M, Barnhart DC. Prophylactic appendectomy: unnecessary in children with incidental appendicoliths detected by computed tomographic scan. *J Pediatr Surg*. 2010 Dec;45(12):2377-80.
- [13] Rabinowitz CB, Egglin TK, Beland MD, Mayo-Smith WW. Outcomes in 74 patients with an appendicolith who did not undergo surgery: is follow-up imaging necessary? *Emerg Radiol*. 2007 Jul;14(3):161-5.
- [14] Haddad MC, Azzi MC, Hourani MH. Current diagnosis of acute appendicitis. *J Med Liban*. 2003 Oct-Dec;51(4):211-5.
- [15] Rao PM, Rhea JT, Novelline RA. Helical CT of appendicitis and diverticulitis. *Radiol Clin North Am*. 1999 Sep;37(5):895-910.
- [16] Lehmann D, Uebel P, Weiss H, Fiedler L, Bersch W. Sonographic representation of the normal and acute inflamed appendix in patients with right-sided abdominal pain. *Ultraschall Med*. 2000 Jun;21(3):101-6.
- [17] Kapoor A, Kapoor A, Mahajan G. Real-time elastography in acute appendicitis. *J Ultrasound Med*. 2010 Jun;29(6):871-7.
- [18] Naffaa LN, Ishak GE, Haddad MC. The value of contrast-enhanced helical CT scan with rectal contrast enema in the diagnosis of acute appendicitis. *Clin Imaging*. 2005 Jul-Aug;29(4):255-8.
- [19] Applegate KE, Sivit CJ, Myers MT, Pschesang B. Using helical CT to diagnosis acute appendicitis in children: spectrum of findings. *AJR Am J Roentgenol*. 2001 Feb;176(2):501-5.
- [20] Nikolaidis P, Hwang CM, Miller FH, Papanicolaou N. The nonvisualized appendix: incidence of acute appendicitis when secondary inflammatory changes are absent. *AJR Am J Roentgenol*. 2004 Oct;183(4):889-92.
- [21] Parks NA, Schroepel TJ. Update on imaging for acute appendicitis. *Surg Clin North Am*. 2011 Feb;91(1):141-54.
- [22] Kanal E, Barkovich AJ, Bell C, et al. ACR guidance document for safe MR practices: 2007. *AJR Am J Roentgenol*. 2007 Jun;188(6):1447-74.
- [23] Blumenfeld YJ, Wong AE, Jafari A, Barth RA, El-Sayed YY. MR imaging in cases of antenatal suspected appendicitis--a meta-analysis. *J Matern Fetal Neonatal Med*. 2011 Mar;24(3):485-8.
- [24] Moghadam-Kia S, Nawaz A, Newberg A, Basu S, Alavi A, Torigian DA. Utility of 18F-FDG-PET/CT imaging in the diagnosis of appendicitis. *Hell J Nucl Med*. 2009 Sep-Dec;12(3):281-2.

- [25] Koff SG, Sterbis JR, Davison JM, Montilla-Soler JL. A unique presentation of appendicitis: F-18 FDG PET/CT. *Clin Nucl Med*. 2006 Nov;31(11):704-6.
- [26] Ogawa S, Itabashi M, Kameoka S. Significance of FDG-PET in Identification of Diseases of the Appendix - Based on Experience of Two Cases Falsely Positive for FDG Accumulation. *Case Rep Gastroenterol*. 2009 Apr 29;3(1):125-130.
- [27] Lane MJ, Mindelzun RE. Appendicitis and its mimickers. *Semin Ultrasound CT MR*. 1999 Apr;20(2):77-85.
- [28] Karam AR, Birjawi GA, Sidani CA, Haddad MC. Alternative diagnoses of acute appendicitis on helical CT with intravenous and rectal contrast. *Clin Imaging*. 2007 Mar-Apr;31(2):77-86.
- [29] Mason RJ. Surgery for appendicitis: is it necessary? *Surg Infect (Larchmt)*. 2008 Aug;9(4):481-8.
- [30] Sakorafas GH, Mastoraki A, Lappas C, Sampanis D, Danias N, Smyrniotis V. Conservative treatment of acute appendicitis: heresy or an effective and acceptable alternative to surgery? *Eur J Gastroenterol Hepatol*. 2011 Feb;23(2):121-7.
- [31] Friedell ML, Perez-Izquierdo M. Is there a role for interval appendectomy in the management of acute appendicitis? *Am Surg*. 2000 Dec;66(12):1158-62.
- [32] St Peter SD, Aguayo P, Fraser JD, Keckler SJ, Sharp SW, Leys CM, Murphy JP, Snyder CL, Sharp RJ, Andrews WS, Holcomb GW 3rd, Ostlie DJ. Initial laparoscopic appendectomy versus initial nonoperative management and interval appendectomy for perforated appendicitis with abscess: a prospective, randomized trial. *J Pediatr Surg*. 2010 Jan;45(1):236-40.
- [33] Birjawi GA, Nassar LJ, Atweh LA, Akel S, Haddad MC. Emergency abdominal radiology: the acute abdomen. *J Med Liban*. 2009 Jul-Sep;57(3):178-212.

IntechOpen



Appendicitis - A Collection of Essays from Around the World

Edited by Dr. Anthony Lander

ISBN 978-953-307-814-4

Hard cover, 226 pages

Publisher InTech

Published online 11, January, 2012

Published in print edition January, 2012

This book is a collection of essays and papers from around the world, written by surgeons who look after patients of all ages with abdominal pain, many of whom have appendicitis. All general surgeons maintain a fascination with this important condition because it is so common and yet so easy to miss. All surgeons have a view on the literature and any gathering of surgeons embraces a spectrum of opinion on management options. Many aspects of the disease and its presentation and management remain controversial. This book does not answer those controversies, but should prove food for thought. The reflections of these surgeons are presented in many cases with novel data. The chapters encourage us to consider new epidemiological views and explore clinical scoring systems and the literature on imaging. Appendicitis is discussed in patients of all ages and in all manner of presentations.

How to reference

In order to correctly reference this scholarly work, feel free to copy and paste the following:

Nadim M. Muallem, Antoine N. Wadih and Maurice C. Haddad (2012). Imaging in Suspected Appendicitis, *Appendicitis - A Collection of Essays from Around the World*, Dr. Anthony Lander (Ed.), ISBN: 978-953-307-814-4, InTech, Available from: <http://www.intechopen.com/books/appendicitis-a-collection-of-essays-from-around-the-world/imaging-in-suspected-appendicitis>

INTECH
open science | open minds

InTech Europe

University Campus STeP Ri
Slavka Krautzeka 83/A
51000 Rijeka, Croatia
Phone: +385 (51) 770 447
Fax: +385 (51) 686 166
www.intechopen.com

InTech China

Unit 405, Office Block, Hotel Equatorial Shanghai
No.65, Yan An Road (West), Shanghai, 200040, China
中国上海市延安西路65号上海国际贵都大饭店办公楼405单元
Phone: +86-21-62489820
Fax: +86-21-62489821

© 2012 The Author(s). Licensee IntechOpen. This is an open access article distributed under the terms of the [Creative Commons Attribution 3.0 License](#), which permits unrestricted use, distribution, and reproduction in any medium, provided the original work is properly cited.

IntechOpen

IntechOpen