

We are IntechOpen, the world's leading publisher of Open Access books Built by scientists, for scientists

4,800

Open access books available

122,000

International authors and editors

135M

Downloads

Our authors are among the

154

Countries delivered to

TOP 1%

most cited scientists

12.2%

Contributors from top 500 universities



WEB OF SCIENCE™

Selection of our books indexed in the Book Citation Index
in Web of Science™ Core Collection (BKCI)

Interested in publishing with us?
Contact book.department@intechopen.com

Numbers displayed above are based on latest data collected.

For more information visit www.intechopen.com



Atrial Fibrillation in Children

Thomas C. Martin and Sean C. Hagenbuch
*University of Vermont College of Medicine, Burlington, Vermont,
Division of Pediatric Cardiology, Department of Pediatrics,
Eastern Maine Medical Center, Bangor, Maine
USA*

1. Introduction

Atrial fibrillation is a relatively uncommon arrhythmia in childhood which is seen in a variety of pediatric clinical settings and continues to challenge health care providers. Atrial fibrillation may be seen at any age during childhood. Recent advances have allowed for prenatal diagnosis and treatment. Perinatal atrial fibrillation has been described, often in the absence of obvious structural or electrophysiological cardiac abnormality. In childhood, atrial fibrillation may be seen occasionally in association with cardiac tumors, myocarditis or cardiomyopathy. Certain medications and drug exposures may precipitate atrial fibrillation in children. Several congenital defects may be associated with atrial fibrillation in early adulthood, if left unrepaired or repaired or palliated with surgical or catheter intervention. The clinical significance of atrial fibrillation may range from trivial to life threatening, depending on the clinical setting and underlying electrophysiological or structural substrate. Recent research into the origins of atrial fibrillation, new drug therapy, interventional catheter and surgical procedures offer new treatment options for children or young adults at risk. This chapter reviews the recent advances in genetic, structural, electrophysiological, pharmacological, medical and surgical observations and the impact on understanding and management of this arrhythmia in children.

2. Atrial embryology

Atrial fibrillation is a relatively rare arrhythmia in the pediatric age group. But the antecedents for atrial fibrillation in adulthood are often the consequence of alterations in the developmental genetics, anatomy, function and electrical properties of the developing heart. Most of the information regarding the developing atrial conduction system comes from animal studies (Gourdie et al., 2003; Ho & Anderson, 1990; Jongbloed et al., 2004). The most useful model for the developing human cardiac conduction system concerns the rings of specialized tissue separating the five components of the primitive heart tube (at the juncture of the venous sinus, primitive atrium, inlet and outlet portions of the ventricular segment and the arterial segment). These rings form the primordial conduction system, a concept that can be extended to account for the ectopic distribution in malformed hearts (Gourdie et al., 2003; Ho & Anderson, 1990; Jongbloed et al., 2004). Among the atrial structures of the conduction system, the sinoatrial node is recognizable as early as the first stage of cardiac looping, at the juncture of the superior caval vein and the right atrium (Boyett, 2009;

Gourdie et al., 2003; Ho & Anderson, 1990; Jongbloed et al., 2004). The histologically discrete nodal cells are set in a connective tissue matrix, which increases in size toward birth. The remainder of the sinoatrial junction is infolded to form the valves of the venous sinus (Boyett, 2009; Gourdie et al., 2003; Ho & Anderson, 1990; Jongbloed et al., 2004). The sinus node was first identified by Sir Arthur Keith (suspected perpetrator of the Piltdown fraud) in 1907 (Boyett, 2009). Although textbooks show the sinoatrial node as a discrete nodule, electrophysiologic data and newer anatomic techniques suggest a more variable and extensive structure extending from the superior vena cava toward the inferior vena cava (Boyett, 2009; Dobrzynski et al., 2005; Scheussler et al., 1996).

There is debate about whether significant connections exist between the sinoatrial nodal tissues and the atrioventricular node (Mommersteeg et al., 2009; Platanov, 2007; Sherf & James, 1979). Although illustrated in prior works, the circumferential muscle bundle located at the anterior wall of the left atrium connecting the right and left atrial appendages was named after George Bachmann, who described its participation in the interatrial propagation of electrical impulses in 1916 (Sherf & James, 1979). Recent embryologic studies in mice suggest that arrhythmogenic areas such as Bachmann's bundle, the pulmonary veins and sinus venosus are intranodal structures which demonstrate lacZ gene expression, a characteristic of specialized conduction tissue (Boyett, 2009; Jongbloed et al., 2004; Mommersteeg, 2009; Platanov 2007).

The atrioventricular node development is quite complex (Boyett, 2009; Gourdie et al., 2003; Ho & Anderson, 1990; Jongbloed et al., 2004). The ring of specialized tissue at the atrioventricular junction forms the primordium of the atrioventricular node. It is initially sandwiched between the atrioventricular sulcus and the endocardial cushion tissue (Boyett, 2009; Gourdie et al., 2003; Ho & Anderson, 1990; Jongbloed et al., 2004). The conduction tissue on the inlet and apical trabecular components of the ventricular septum are brought together to form a continuous ventricular conduction axis. The endocardial cushions gradually regress, bringing the conduction bundle into direct contact with the inferior rim of the atrial septum (Boyett, 2009; Gourdie et al., 2003; Ho & Anderson, 1990; Jongbloed et al., 2004). The atrial tissues immediately around the contact region become the transitional cell zone, while the end of the bundle becomes the compact atrioventricular node (Boyett, 2009; Gourdie et al., 2003; Ho & Anderson, 1990; Jongbloed et al., 2004). The atrioventricular node was first described in 1906 by Sunao Tawara working in Ludwig Aschoff's laboratory in Germany (Boyett, 2009). Recent genetic work in animals and human beings suggest that mutations in the transcription factor Nkx2.5 may be associated with conduction system developmental abnormalities (Gittenberger-De Groot et al., 2007; Jay et al., 2004).

The atrial and ventricular working myocardial cells are similar in characteristics but different in anatomic arrangement (Boyett, 2009; Gourdie et al., 2003; Ho & Anderson, 1990). These cells are characterized by a greater degree of depolarization at rest, no spontaneous pacemaker activity and rapid impulse conduction (Boyett, 2009; Gourdie et al., 2003; Ho & Anderson, 1990). Differentiation of conduction system elements from working atrial myocardial cells involves switching on and off controlling genes (Boyett, 2009). The transcription factor Tbx3 is expressed in the developing conduction system tissues and is usually turned off in working atrial myocytes (Boyett, 2009; Hoogaars et al., 2007). Working atrial myocardial cells have more efficient electrical coupling due to expression of genes controlling the connexin Cx43 in creating more and larger gap junctions (Boyett, 2009, Chandler et al., 2009). Cardiac conduction system cells have fewer and smaller gap junctions and express the connexin Cx45 instead (Boyett, 2009, Chandler et al., 2009). An

examination of messenger ribonucleic acid (mRNA) from human hearts show that sinoatrial and atrioventricular nodal cells have increased expression of hyperpolarization-activated cyclic nucleotide-gated channels, HCN4, (controlling I_f current) and decreased expression of K_{ir} channel genes, especially $K_{ir}2.1$ (controlling $I_{K,1}$ current) resulting in decreased resting potential, slower conduction and spontaneous depolarization through other ion channels (Boyett, 2009; Chandler et al., 2009; Hoogaars et al., 2007). The cardiac sodium channel, $Na_v1.5$, (controlling I_{Na} current) is abundantly expressed in working myocardial cells but not in nodal tissue (Boyett, 2009). Genetic issues, such as persistence of Tbx3 activity or acquired genetic alterations in ion channel function, may underlie the propensity to develop atrial fibrillation later in life (Hoogaars et al., 2007; Roberts & Gollob, 2010).

3. Atrial genetics

Recent reports suggest that channelopathies play a part to play in the development of atrial fibrillation (Darbar et al., 2008; Johnson et al., 2008; Kaufman, 2009; Patel & Pavri, 2009; Thejus & Francis, 2009). Atrial fibrillation may be associated with genes resulting in either ion channel gain-of-function or loss-of-function (Darbar et al., 2008; Johnson et al., 2008; Kaufman, 2009; Patel & Pavri, 2009; Thejus & Francis, 2009) and may be seen in 2% of patients with long QT syndrome, 10% of patients with Brugada syndrome and 30% of patients with short QT syndrome (Johnson et al., 2008; Patel & Pavri, 2009; Roberts & Gollob, 2010, Thejus & Francis, 2009). Familial atrial fibrillation has also been associated with identified channelopathies (Benito et al., 2008; Darbar et al., 2008; Johnson et al., 2008; Kaufman 2009; Patel & Pavri, 2009; Roberts & Gollob, 2010; Thejus & Francis, 2009). Mutations involving ion transport associated with atrial fibrillation include SCN5A, KCNH2, KCNQ1, KCNJ2, KCNE2, KCNA5, HERG + MiRP1, KCNE1 and probably others (Benito et al., 2008; Darbar et al., 2008; Johnson et al., 2008; Kaufman 2009; Patel & Pavri, 2009; Thejus & Francis, 2009). Although these mutations affect cardiac myocyte action potential height and duration, cellular repolarization duration and cardiac impulse conduction speed, the exact relation of ion channel abnormalities to atrial fibrillation development is unknown. The fact these genetic variants have been identified in families of patients with atrial fibrillation may facilitate new approaches to the diagnosis, prevention and treatment (Otway et al., 2007).

Mechanisms other than enhanced atrial action potential repolarization (from gain-of-function mutations) and delayed atrial action potential repolarization (from loss-of-function mutations) may be inherited. There has been a recent focus on hormonal control of atrial electrophysiology, including genes controlling atrial natriuretic peptide levels and mineralocorticoid receptor expression, in patients with atrial fibrillation (Hodgson-Zingman et al., 2008; Roberts & Gollob, 2010; Tsai et al., 2010). Re-expression of dormant fetal genes may be one mechanism associated with the development of atrial fibrillation in adults, as was demonstrated by the appearance of the fetal ssTnI isoform of troponin in patients with atrial fibrillation (Thijssen et al., 2004). These changes could be primary causes of atrial fibrillation or may represent secondary changes related to other changes in myocardial metabolism, function or distension.

4. Atrial fibrillation in the fetus

Atrial fibrillation in the fetus is rare, but not unheard of. Depending on the report, fetal atrial flutter or fibrillation accounts for somewhere between 20-33% of all fetal tachyarrhythmias

(Azancot-Benistry et al., 1992; Belhassen et al., 1982; Silverman et al., 1985; Simpson et al., 1998) and may be detected on routine obstetrical examination as an irregular or rapid fetal heart rate. In general, any congenital heart disease may predispose to development of atrial fibrillation in this period, but several specific entities are generally considered higher risk. The Wolff-Parkinson-White (WPW) syndrome was first noted to have intrauterine atrial fibrillation and several other observations have come as fetal echocardiography has developed into a fully accepted clinical technique. Atrial septal defects, ventricular septal defects, atrioventricular canal, Ebstein anomaly, cor triatriatum and any single ventricular anatomy (most prominently hypoplastic left heart) are all felt to be higher than average risk for fetal atrial tachyarrhythmia. The most common arrhythmia defined in several series is premature atrial contractions, which is most often benign, but has the potential to convert to an atrial tachyarrhythmia (Belhassen et al., 1982; Silverman et al., 1985). Detection of fetal arrhythmia is primarily done clinically using ultrasound in most settings, and is well validated in multiple reports. Physiologic correlations have been demonstrated, the most severe of which is hydrops fetalis (Azancot-Benistry et al., 1992; Frohn-Mulder et al., 1995; Hajdu et al., 1997; Hansmann et al., 1991; Jaeggiet al., 1998; Kleinman et al., 1999; Matta et al., 2010; Naumburg et al., 1997; Reed et al., 1987; Soyeur D, 1996; Szabo et al., 1997; van Engelen et al., 1994; Zielinsky et al., 1998). As discussed above, familial atrial fibrillation has been noted to occur prenatally in the absence of hereditary structural heart disease, and may be indication for referral for high risk obstetrical screening (Aburawi et al., 2006; Bertram et al., 1996; Soyeur, 1996; Tikanoja et al., 1998).

As the common pathway of hydrops fetalis is a devastating and often fatal diagnosis, early detection of fetal atrial flutter and other fetal supraventricular tachyarrhythmias is essential to prevention. The published mortality that has generally been attributed to fetal atrial flutter is in the 8-10% range, and while some have theorized that it is both harder to control and more likely to lead to fetal demise secondary to this phenomenon, a recent meta-analysis of published data has shown that the overall risk of atrial flutter is similar to all other types of atrial tachyarrhythmia when taken together (Krapp et al., 2003).

As fetal ultrasonography is essentially a mechanical observation of a presumed electrical phenomenon based upon our knowledge of extrauterine life, much research has been ongoing to refine techniques that will allow us to noninvasively monitor a fetus with suspected arrhythmia. One of the more exciting advances has been fetal magnetocardiography. As magnetic resonance imaging (MRI) technology has advanced, cardiac MRI has become a viable field for extrauterine evaluation of the heart. To date, the motion artifacts associated with fetal movement have conspired to render fine detailed anatomic evaluation of the fetal cardiac structures as just a goal, but the physics of detecting the magnetic signature of the fetal electrical impulses have proven to be very promising, if somewhat cumbersome (Kahler et al., 2001; Wakai et al., 2003). Fetal magnetocardiography (fMCG) has advanced by leaps and bounds in recent years, and can be reliably performed beginning at 20 weeks gestation in the correct setting. The technique essentially takes advantage of the physical fact that electrical movement generates a magnetic field, and that when this magnetic field is affected by a second, focused and known magnetic field like an MRI scanner, the final vectors can be transformed to give an approximation similar to a surface ECG, which can then be interpreted similarly. This is a simplification of complex concepts and may give the impression that this technique should be readily and widely available. However, this technique, while promising, is currently only investigatory. It is,

however, one of the few areas under investigation that would give us a potential leap forward in both detecting and understanding fetal arrhythmias.

Many different treatments have been attempted and recommended for fetal atrial flutter and fibrillation, and this condition may be the most accurate representation of the medical truism that the greater the number of potential treatments, the less likely any one is to be successful. The paradigm that is currently held is that any fetal tachycardia that is intermittent, present less than roughly half the time, and without obvious impact to the fetus, is followed closely but otherwise left untreated. (Cuneo & Strasburger, 2000). If treatment is indicated due to cardiac or valve dysfunction potentially leading to hydrops, the current mainstay of therapy at this time in the United States is digoxin. It has excellent ability to cross the placenta and has generally demonstrated good efficacy. For the same indications in Europe, the intervention of choice has become flecainide (Strasburger & Wakai, 2010). For atrial flutter or fibrillation resistant to digoxin or flecainide in the absence of ventricular dysfunction, the current recommendation is to attempt to control the arrhythmia with sotalol and amiodarone (Cuneo & Strasburger, 2000; Srinivasan & Strasburger, 2008; Strasburger et al., 2004; Strasburger & Wakai, 2010).

There have been several reports of alternative methods to maternal oral administration with varying degrees of success (Hallak et al., 1991; Parilla et al., 1996; Weiner et al., 1988), but most of these have been met without much general enthusiasm for the increased risk when the success rate of traditional therapy is in excess of 90% (Cuneo & Strasburger, 2000; Kleinman & Nehgme, 2004; Maeno et al., 2009; Srinivasan & Strasburger, 2008; Strasburger et al., 2004; Strasburger & Wakai, 2010). A recent report suggests that neurodevelopmental outcome for babies who experience fetal arrhythmias is very good (Lopriore et al., 2009).

5. Atrial fibrillation in neonates

The diagnosis of atrial fibrillation in the neonate is simpler than in the fetus due to the convenience of direct access to the patient. A 12-lead electrocardiogram can be obtained and diagnostic accuracy greatly increased. Rarely is a neonatal invasive electrophysiological study indicated, but esophageal monitoring and pacing may be performed relatively easily. Additionally, the transition from the fetal circulation to the neonatal circulation puts added stretch and stress on the left atrium (and the pulmonary veins) due to lower pulmonary resistance and increased pulmonary blood flow. (Estlin et al., 1998; Larmay & Strasberger, 2004). Two iatrogenic causes of atrial fibrillation or flutter may be seen in newborn infants. The most common of these is due to introduction of an umbilical venous catheter (UVC) into the right atrium. It is not uncommon to find that even a carefully measured UVC line will end up in the right atrium and cause premature atrial contractions, atrial flutter or atrial fibrillation that will be intermittent and spontaneously resolve when the catheter is repositioned to outside of the atrium (da Silva & Waisberg, 2010; Sinha et al., 2005). A second major cause is exposure to the stress of surgical interventions in the neonatal period. If the neonate has structural heart disease, the incidence of atrial flutter or fibrillation is significantly higher, but less intuitive is the structurally normal heart of the infant that must undergo anesthesia and surgical correction of other conditions. Several case reports emphasize the variability with regard to underlying anatomic and electrophysiologic substrate and response to intervention (Bronzetti et al., 2009; Larmay & Strasburger, 2004; Mainzer et al., 2008). The sudden shifts in volume and potential cardiac effects of both inhaled and parenteral anesthetics associated with surgical intervention can easily overtax

even the normal neonatal heart and lead to arrhythmias, including atrial flutter and fibrillation. Intrathoracic procedures may add to this risk, with incidental mechanical contact with the neonatal atria triggering an arrhythmia. (Estlin et al., 1998; Gilbert-Barnes & Barnes 2006; Texter et al., 2006).

The increased risk with neonates is not just limited to their small size and relative fragility, however. It is felt that the immature myocardium, and specifically the atrioventricular node, is also more suited to conduct rapidly, and therefore set the neonate at particularly high risk for rapid ventricular response of any atrial tachyarrhythmia, which in turn puts the infant at high risk for a sudden and precipitous drop in cardiac output. If the resultant cardiac output is insufficient for tissue oxygen delivery, the affected infant will then be at significant risk for both developing an irrecoverable rhythm and having end organ damage if the rhythm is not converted in a timely fashion. The largest study of neonates to date identified 50 children over a 25 year period that entered into atrial flutter (seen more often than atrial fibrillation in neonates) with no prior cardiac surgery and only an atrial septal defect found as an associated congenital defect (Texter et al., 2006). There were excellent results with electrical cardioversion (20 of 23, 87%), moderate success with transesophageal pacing (7 of 22, 32%), and only 7 of 50 (14%) who required chronic antiarrhythmic therapy. Of those experiencing recurrence of atrial flutter (6 of 50, 12%), all developed an additional supraventricular arrhythmia. Most of the initial atrial flutter (36 of 50, 72%) presented within the first 48 hours of life, and the vast majority (5 of 6, 83%) of recurrent atrial flutter occurred within 24 hours of initial cardioversion. There were an additional five infants who did not experience recurrent atrial flutter (10%) who developed a second supraventricular rhythm (Texter et al., 2006).

Drugs which do not cross the placenta easily are now available for use in newborns if primary electrical cardioversion fails or the infant is in stable arrhythmia and the clinical decision to attempt chemical cardioversion as first line therapy is made. Adenosine may be useful in slowing the ventricular response (which may help identify the underlying arrhythmia) but may not be useful in terminating an atrial tachyarrhythmia. Ventricular rate may be slowed with beta blockade but hypotension and hypoglycemia are even more prevalent in the neonate than in older patients, and should be monitored closely when initiating therapy. Regardless of initial therapy choice, atrial tachyarrhythmias may be difficult to control, and often may require trial and error prior to arriving at either the correct therapeutic drug or drug combination. Once arrhythmia control is established, these patients may be allowed to "outgrow" their medication regimens after careful weight adjustment and monitoring as an outpatient for several months. As they mature, and the atrial conduction system matures, a large number of them have no reported recurrence.

6. Atrial fibrillation in children with myocarditis, cardiomyopathy and cardiac tumors

Infants and children make up a small percentage of patients presenting with atrial fibrillation (Martin, 2001). The seminal report of Radford and Izukawa on atrial fibrillation in children examined the spectrum of conditions associated with this arrhythmia (Radford & Izukawa, 1977). In the 35 cases of atrial fibrillation in children reported, associated conditions included rheumatic heart disease, cardiomyopathy, atrial tumors, infective endocarditis, Marfan syndrome, endocardial fibroelastosis and structural congenital heart disease (Radford & Izukawa, 1977). Cardiomyopathy (six patients), cardiac tumors (three patients), myocarditis and endocarditis (four patients) accounted for 37% of their reported

series. One specific type of myocarditis, acute rheumatic fever and subsequent rheumatic heart disease, has decreased to very low levels in developed countries, and will not be discussed in this review.

Myocarditis, cardiomyopathy and cardiac tumors all can present with atrial fibrillation. Myocarditis is often the most difficult of these to diagnose and often requires a high level of clinical suspicion. Fulminant myocarditis can progress to a potentially fatal cardiac failure, often heralded by difficult to control arrhythmias, including atrial fibrillation (Ichikawa et al., 2011). The acute onset and probable viral etiology are keys in the history, but often myocarditis may present with only sudden onset atrial tachyarrhythmia. Resolution is often just as sudden if inflammation recedes and no myocardial scarring occurs. This is particularly the case if the inflamed myocardium is limited to the posterior left atrium. These children would have no findings other than the atrial fibrillation or flutter, possibly with clinical or laboratory evidence of a viral syndrome. Even myocardial biopsies may be negative as they are rarely if ever taken from the atria due the extreme risk of this maneuver. Myocarditis may be suggested on pathological specimens (Chimenti et al., 2010; Frustaci et al., 1997). It is possible that cardiac MRI may be prove useful in the noninvasive diagnosis of myocarditis. There has been some controversy recently surrounding the generally held precept that atrial fibrillation in the setting of myocarditis is caused by the inflammation that is the hallmark of the disease. The potential exists that the arrhythmias are not caused by the active inflammation, but by the remodeling and healing process that comes after the inflammation recedes (Boos et al., 2006; Boos & Lip, 2008; McCabe et al., 2008; Hoyano et al., 2010; Yap, 2009). The progressive nature of atrial structural remodeling appears to underlie the progression of atrial fibrillation in other settings (de Vos et al, 2010; Wolf et al., 2009).

Myocarditis in the setting of other structural or electrophysiologic abnormalities may present special issues. It has been postulated that atrial myocarditis and atrial tachyarrhythmias in the setting of ventricular pre-excitation may cause of sudden death in susceptible children and young adults (Basso et al., 2001). Myocarditis carries a higher risk for some children with congenital heart disease. Children with single ventricular physiology tend to be more reliant on atrial contraction to maintain cardiac output, and may have experienced extensive cardiac surgery. Atrial scarring also characterizes those having undergone atrial switch procedures. Extensive suture lines, atrial scarring, chronic stretch would increase the risk of inflammation and remodeling associated with myocarditis. Treating the underlying myocarditis may be needed to control persistent arrhythmia (Korantzopoulos et al., 2005).

Myocarditis and cardiomyopathy may be linked with acute inflammation leading to chronic myocardial dysfunction. There are many cases of cardiomyopathy that do not follow myocarditis, however. Uncontrolled atrial tachyarrhythmias, particularly with rapid ventricular responses, can cause tachycardia-mediated cardiomyopathy. The genetics of cardiomyopathy and the genetics of atrial fibrillation are intertwined in complicated ways that are being identified. Some recent studies have shown links between cardiomyopathy and arrhythmia (Banwell et al., 1999; Karst et al., 2008; McNair et al., 2011). All types of cardiomyopathy have the potential for arrhythmia. Similar to children with single ventricle physiology, those with cardiomyopathy are dependent on upon atrial contraction for cardiac output. As atrial pressure, stretch, and remodeling occur with deterioration in ventricular function, the frequency of atrial fibrillation increases. The stress on the atrial chamber increases the potential for atrial inflammation and progression to a noninfectious

atrial myocarditis (Hsu, 2010). Atrial fibrillation has been shown to be a major clinical risk factor for morbidity in hypertrophic cardiomyopathy (Kubo et al., 2009).

Cardiac tumors are both easier to understand and diagnose. The infamous “tumor plop” may be present on physical exam. They may obstruct flow into the ventricular cavity, or become caught in the atrioventricular valve causing significant regurgitation. Tumors are easily recognizable using echocardiography by their distinct appearance. Depending on the type and location of the tumor, symptoms will vary. Intracardiac tumors which are myxomatous may be pedunculated and mobile, and may swing wildly around the affected atria, potentially bouncing off the interior walls and inciting atrial fibrillation by this contact (Vermeulen et al., 2009; Yu et al., 2006). The treatment for these tumors is predominantly surgical, and reasonable success has been obtained in this manner (Chuaratanaphong et al., 1995; Ipek et al., 2005). Cardiac rhabdomyomas are a hallmark of tuberous sclerosis, and their natural history is that they recede from the time of birth onward. They rarely require intervention unless they are so large that they obstruct the flow of blood, typically by encompassing so much of the myocardium that they impede filling of the ventricles. These can easily be detected prenatally if they are of sufficient size. Atrial tachyarrhythmias may occur when the tumors involve the atrial walls. They may interfere with atrial depolarization or conduction leading to atrial flutter or fibrillation (Yamashita et al., 1987).

Tumors involving the heart, but not originating there, may be associated with atrial fibrillation. Cardiac effects may be due the high output states, inflammatory or chemotherapeutic processes, or direct tumor infiltration of cardiac chambers of the myocardium. Hypercoagulability may be associated with neoplasia, and combined with atrial fibrillation may predisposes to embolic phenomenon from potential mural wall thrombus formation or mural endocarditis. Benign tumors that arise in the pericardium may also cause mechanical pressure on the atria due to the limited space available to them to grow. All of these may lead to atrial fibrillation, and the resulting clinical impact (Chen et al., 1992; Cooper et al., 1994; Radford & Izukawa, 1977).

7. Atrial fibrillation in children without structural heart disease

Radford and Izukawa noted that atrial fibrillation in childhood may occur at any age, with nearly 50% of those reported by presenting after age 10 years (Radford & Izukawa, 1977). In describing the children with this arrhythmia, they described four cases of atrial fibrillation associated with supraventricular tachycardia (without structural heart disease) and one case of “lone” atrial fibrillation (Radford & Izukawa, 1977). Atrial fibrillation in the absence of structural heart disease, or “lone” atrial fibrillation, accounted for 6% of the older children in this series. Recent reports in adolescents and young adults suggests that “lone” atrial fibrillation may be associated with an abnormal atrial electrophysiologic substrate, and may not be as “lone” as previously suspected (Holmqvist et al., 2011; Korantzopoulos et al., 2009; Stiles et al., 2009). One case of lone atrial fibrillation with complete heart block in a ten year old boy has been reported, suggesting the possibility of more generalized conduction system dysfunction (Krishna Kumar et al., 1991). In a report of nine adolescents with “lone” atrial fibrillation, irregular rapid atrial tachycardias in the region of the pulmonary veins, left atrium and crista terminalis were noted (Nanthakumar et al., 2004), suggesting the possibility of congenital abnormalities in impulse initiation or conduction in these areas. Recently, a single nucleotide polymorphism has been identified that is associated with prolonged atrial conduction and lone atrial fibrillation in young adults (Goodloe et al., 2011)

Atrial fibrillation has also been reported in adolescents without known cardiac disease experiencing the “holiday heart” phenomenon (Koul et al., 2005; Thorton, 1984). The holiday heart consists of atrial fibrillation occurring after binge alcohol consumption in young people without underlying disease or cardiac abnormalities (Koul et al., 2005; Thorton, 1984). Chronic alcohol consumption is also associated with an increased risk of atrial fibrillation and has been reported in some adolescents (Kodama et al., 2011). The use of alcohol with other illicit drugs has also been linked with atrial fibrillation in young adults (Krisnamoorthy et al., 2009). The use of highly caffeinated beverages by adolescents, a popular new phenomenon, is another reported association (Di Rocco et al., 2011). Obesity appears to be a risk factor for atrial fibrillation in younger adults, and the epidemic of obesity in children may represent an increasing risk factor (Guglin, et al., 2011; Niemann, et al. 2011). Additional types of mayhem have been linked to atrial fibrillation in adolescents. There was one report of atrial fibrillation after Taser exposure in an adolescent who tested positive for marijuana (Multerer et al., 2009). Scorpion bite has been linked to cardiac disorders including atrial fibrillation (Alan et al., 2004).

Prescribed medication use may be associated with atrial fibrillation in children without structural heart disease. The use of corticosteroids, taken orally and inhaled, has been linked to atrial fibrillation in children (Huerta et al., 2005; Oteri et al., 2010; Ueda et al., 1988; Yamamura et al., 2011). There is one report of a child with hyperthyroidism presenting with atrial fibrillation (Perry & Hung, 1971). The low frequency of these reported associations would suggest that a genetic propensity toward atrial fibrillation may have been present in the affected individuals.

Atrial fibrillation associated with the WPW syndrome may be life threatening (Paul et al., 1990; Piertersen et al., 1992). Conduction from the fibrillating atria via an accessory atrioventricular connection with a short refractory period may lead to ventricular fibrillation (Brembilla-Perrot et al., 2010; Paul et al., 1990; Piertersen et al., 1992; Sarubbi, 2006). One of the difficulties is determining which of the children with pre-excitation on their electrocardiograms are at risk. In one reported series, spontaneous atrial fibrillation was seen in 4% of children with WPW syndrome, with 22% of children demonstrating atrial fibrillation during electrophysiologic study (Lee et al., 2004). Degeneration of supraventricular tachycardia into atrial fibrillation was seen in 51% of 53 young patients with WPW syndrome, with 34% having a rapid ventricular response rate (Harahsheh et al., 2008). In another study of 62 asymptomatic children with pre-excitation on their electrocardiogram, supraventricular tachycardia was initiated in 58% and atrial fibrillation was observed in 13% (Sarubbi et al., 2005). In a prospective study of asymptomatic children with WPW syndrome, arrhythmias were seen in 51 of 184 patients, 19 of which were life-threatening including three patients with syncope and three with cardiac arrest (Santinelli et al., 2009). Risk factors for life-threatening arrhythmias included a short antegrade effective refractory period for the accessory atrioventricular connection (≤ 240 msec) and multiple accessory atrioventricular connections (Santinelli et al., 2009). Most pediatric electrophysiologists recommend invasive electrophysiologic testing to stratify risk and assess the need for radiofrequency or cryotherapy catheter ablation of the accessory atrioventricular connection in asymptomatic children with manifest pre-excitation (Campbell et al., 2003, Lee et al., 2006; Santinelli et al., 2006). Some children presenting with recurrent atrial fibrillation have supraventricular tachycardia unrelated to pre-excitation or the WPW syndrome as a triggering event and they may be successfully treated by catheter ablation of their supraventricular tachycardia substrate (Streiper et al., 2010).

8. Atrial fibrillation in children with structural heart disease

Nearly half of the cases of atrial fibrillation in children and young adults are associated with congenital heart disease (Radford & Izukawa, 1977). Congenital heart defects may be associated with atrial arrhythmias either before or after surgical correction (Attenhofer Jost et al., 2005; Berger et al., 2005; Bouchardy et al., 2009; Chatzis et al., 2008; Chauvaud et al., 2001; Collins, 2009; Hallioglu et al., 2004; Hayashi et al., 2006; Kammeraad et al., 2004; Kaseno et al., 2008; Khairy et al., 2010; Khositeth et al., 2004; Luciani et al., 2008; Marelli et al., 2010; Massin et al., 2010; Porter & Garson, 1993; Radford & Izukawa, 1977; Saul, 2008; Spies et al., 2008; Sugimoto et al., 2001; Trojnarska et al., 2009). Those congenital heart defects occurring in conjunction with atrial fibrillation include those associated with abnormalities in the development of the cardiac conduction system, abnormalities in the development of atrial structure, abnormalities in flow resulting in atrial enlargement, abnormalities in impulse initiation or conduction from surgical atrial scarring. The risk factors for developing atrial fibrillation originate in early in life but not become manifest until adulthood.

Congenital heart defects that are most often associated with atrial fibrillation include atrial septal defect, Ebstein anomaly, anomalies in pulmonary venous drainage, transposition of the great arteries, single ventricle, tetralogy of Fallot and Marfan syndrome (Attenhofer Jost et al., 2005; Berger et al., 2005; Bouchardy et al., 2009; Chatzis et al., 2008; Chauvaud et al., 2001; Collins, 2009; Hallioglu et al., 2004; Hayashi et al., 2006; Kammeraad et al., 2004; Kaseno et al., 2008; Khairy et al., 2010; Khositeth et al., 2004; Luciani et al., 2008; Marelli et al., 2010; Martin et al., 1983; Massin et al., 2010; Porter & Garson, 1993; Radford & Izukawa, 1977; Saul, 2008; Spies et al., 2008; Sugimoto et al., 2001; Trojnarska et al., 2009). Atrial fibrillation has also been seen following heart transplantation in pediatric patients (Collins et al., 2003). Risk factors for atrial fibrillation in congenital heart disease include age at operation, atrial dilatation from intra-cardiac shunting, atrial dilatation from valve insufficiency, extensive atrial suture lines and ventricular myocardial dysfunction. Recent advances in pediatric heart disease management include repair of congenital defects at younger ages, percutaneous catheter and device intervention to avoid complications of cardiac bypass, modifications of surgery to avoid atrial scarring and more aggressive management of residual regurgitant valve lesions. The hope is that these changes will decrease the burden of atrial fibrillation associated with congenital heart disease.

9. Management of atrial fibrillation in children

The diagnosis of atrial fibrillation in childhood is not difficult in most instances. Intravenous adenosine and transesophageal electrode recording can be used to assist in the diagnosis (Fazio et al., 2008; Gewitz & Woolf, 2006; Kaltman & Shah, 2004). Guidelines are available for treatment of atrial fibrillation in adults, and with modifications, provide a framework for treating children with the arrhythmia (American College of Cardiology/American Heart Association/European Society of Cardiology, 2006; American College of Cardiology Foundation/American Heart Association/Heart Rhythm Society (ACCF/AHA/HRS), 2011). Emergency management of children with significant hemodynamic compromise would include electrical cardioversion (Gewitz & Woolf, 2006; Kaltman & Shah, 2004). In more stable children, the use of intravenous beta-adrenergic blocker (eg, esmolol, propranolol) or calcium channel blocker (eg, verapamil, diltiazem) could be used to slow the ventricular response rate (Fazio et al., 2008; Gewitz & Woolf, 2006; Kaltman & Shah, 2004). See table for a listing of useful drugs in the management of atrial fibrillation in children. Intravenous digoxin or amiodarone could be used emergently and continued on a chronic

Drug	Dose	Effect	Indication
Adenosine	Child: 0.1-0.2 mg/kg IV Adolescent (> 50 kg): 6mg IV	Slow AV conduction	Rapid ventricular response Diagnosis Afib
Amiodarone	Child: 5 mg/kg IV 5-15 mg/kg po qd Adolescent: 600 mg/1.73 m ² IV 200-1600 mg po qd	Slow AV conduction Prevent AFib recurrence Slow WPW conduction	Rapid ventricular response Persistent or recurrent AFib
Atenolol	Child: 0.5-1 mg/kg po qd Adolescent: 25-100 mg po qd	Slow AV conduction	Rapid ventricular response
Digoxin	Infant: 15-30 mcg/kg IV qd: load 20-35 mcg/kg po qd: load 4-8 mcg/kg IV qd: maintenance 5-10 mcg/kg po qd: maintenance Child: 20-40 mcg/kg IV qd: load 30-50 mcg/kg po qd: load 6-9 mcg/kg IV qd: maintenance 8-12 mcg/kg po qd: maintenance Adolescent (> 10 y, < 100 kg): 8-12 mcg/kg IV qd: load 10-15 mcg/kg po qd: load 2-3 mcg/kg IV qd: maintenance 2.5-5 mcg/kg po qd: maintenance	Slow AV conduction Improve contractility	Rapid ventricular response Avoid in WPW
Diltiazem	Child: 1.5-2 mg/kg po tid or qid Adolescent: 30-120 mg/kg po tid or qid 120-300 mg/kg po qd or bid (SR)	Slow AV conduction	Rapid ventricular response Avoid in WPW
Dofetilide	Adolescent (≥ 18 y): 125-500 mcg/kg po bid	Prevent Afib recurrence	Persistent or recurrent Afib
Esmolol	Child & Adolescent: 100-500 mcg/kg IV: load 25-100 mcg/kg/min IV: infusion Titrated: 50-1000 mcg/kg/min	Slow AV conduction	Rapid ventricular response
Flecainide	Child: 1-2 mg/kg po bid Adolescent: 25-150 mg po bid	Prevent Afib recurrence Slow WPW conduction	Persistent or recurrent Afib Rapid ventricular response
Heparin	Child: 75 U/kg IV: load 18-28 U/kg/h IV: infusion 75-100 U/kg q 4 h IV: intermittent Adolescent: 50-100 U/kg IV: load 15-25 U/kg/h IV: infusion 75-125 U/kg q 4 h IV: intermittent	Anticoagulation	Persistent or recurrent Afib Prior to cardioversion
Ibutilide	Adolescent (≥ 18 y) < 60 kg: 0.01 mg/kg IV ≥ 60 kg: 1 mg IV	Prevent Afib recurrence Slow WPW conduction	Persistent or recurrent Afib Rapid ventricular response
Procainamide	Child: 2-15 mg/kg IV: load 20-80 mcg/kg/min IV: infusion 15-50 mg/kg/24 h q 3-6 h po Adolescent: 50-100 mg IV: load Titrated to 1-6 mg/min IV 250-500 mg po q 3-6 h 500-1000 mg q 6 h (SR)	Prevent Afib recurrence Slow WPW conduction	Persistent or recurrent Afib Rapid ventricular response
Propafenone	Adolescent (≥ 18 y): 150-300 mg po tid	Prevent Afib recurrence Slow WPW conduction	Persistent or recurrent Afib Rapid ventricular response
Propranolol	Child: 0.01-0.1 mg/kg IV Max: 1 mg infants; 3 mg child 0.5-1 mg/kg/24 h po q 6-8 h Adolescent: 1 mg/kg IV; max 5 mg 10-20 mg po tid or qid	Slow AV conduction	Rapid ventricular response
Verapamil	Child: 0.1-0.3 mg/kg IV Max: 5-10 mg 4-8 mg/kg/24 h tid or qid Adolescent: 5-10 mg IV 240-480 mg po tid or qid 240-480 mg/kg bid or qd (SR)	Slow AV conduction	Rapid ventricular response Avoid in WPW
Warfarin	Child: 0.2 mg/kg po qd Max: 5 mg po qd Titrated to INR 2-3 Adolescent: 5-10 mg po qd	Anticoagulant	Persistent or recurrent Afib

Afib = atrial fibrillation; AV = atrioventricular; bid = 2 times per day; h = hours; IV = intravenously; kg = kilogram
mcg = micrograms; mg = milligrams; min = minutes; po = by mouth; qid = 4 times per day; qd = daily;
tid = 3 times per day; WPW = Wolff Parkinson White syndrome.
Drug recommendations and dosages are subject to change, check prior to administration.
Table adapted from Taketomo, et al., 2010; Lee, et al., 2009 & Manzi, 2006.

Table 1. Useful drugs in the management of atrial fibrillation in infants and children.

basis if needed (Fazio et al, 2008; Gewitz & Woolf, 2006; Kaltman & Shah, 2004). Other drugs available for the management of acute and chronic atrial fibrillation in children include sotalol, propafenone, procainamide, flecainide, ibutilide, and dofetilide (Gewitz & Woolf, 2006; Kaltman & Shah, 2004; Fazio et al, 2008). In patients with WPW syndrome, digoxin and verapamil should not be used due to tendency to increase antegrade conduction via the accessory atrioventricular connection (Byrum et al, 1982; Fazio et al, 2008; Gewitz & Woolf, 2006; Kaltman & Shah, 2004; Rowland, 1983). If elective cardioversion is needed, transeosophageal or transthoracic echocardiography will be needed to assess the need for anticoagulation prior to the procedure (ACC/AHA/ESC, 2006; Fazio et al, 2008; Gewitz & Woolf, 2006; Horenstein et al, 2004; Kaltman & Shah, 2004). Long term oral anticoagulation with coumadin may be need in high risk pediatric patients with chronic or recurrent atrial fibrillation.

The demonstrated success of the Maze procedure for the surgical treatment of atrial fibrillation (Cox et al., 1991; Cox, 2010) and the development of subsequent percutaneous catheter ablation techniques (Haissaguerre et al., 1998; Weerasooriya et al., 2011) have led to new options in the management of atrial fibrillation. Arrhythmia surgery has been successful in children with and without congenital heart disease (Deal et al, 2003). Congenital heart defects associated with arrhythmias have been successfully treated with combined surgical and ablative procedures (Deal et al., 2003; Fujita et al., 2009; Greason et al., 2003; Mavroudis et al., 2008; Stulak et al., 2006; Therrien et al., 2001). These new techniques allow for an individual approach tailored to the needs of specific patients (Brenyo & Aktas, 2011). Recurrence of atrial fibrillation following surgical or catheter ablation remains a risk and the need for oral anticoagulation is being debated (Themistoclakis et al, 2010). Newer drugs (eg, dabigatran) for long-term anticoagulation may be useful in some childhood cases of atrial fibrillation (Dahl & Huisman, 2010).

10. Prognosis

No prospective long-term follow-up is reported in children with atrial fibrillation. Children in the newborn period with no underlying disease have an excellent prognosis, as do those older patients with a triggering event or disease which is reversible. Lone atrial fibrillation in older children and young adults has a good outcome. Patients with atrial fibrillation associated with abnormal cardiac structural, functional or electrophysiologic substrate have a variable outcome. Newer drugs offer clinical improvement on a short term basis but long-term outcomes, especially for children, are not available. Surgical and catheter management techniques continue to offer a new alternative, but no long-term follow-up in young patients is available.

11. Conclusions

Atrial fibrillation is a relatively uncommon arrhythmia in childhood. It may be associated with genetic, electrophysiologic and structural variables that are present from the prenatal period. It may become manifest early in life under conditions of infection, neoplasia, structural, functional or electrical cardiac disease. It may be seen in the absence of cardiac disease in metabolic, infectious or systemic disease. Drug or alcohol exposure, electric shock or scorpion envenomation may precipitate an attack. Diagnosis and treatment will vary with age, electrophysiologic and anatomic substrate and clinical status. Newer diagnostic tools, pharmacologic therapies, surgical and catheter procedures allow for individualized approach in this interesting group of patients.

12. Acknowledgements

This work is dedicated to Angela C. Gilladoga, MD, FACC, pediatric cardiologist at Eastern Maine Medical Center. Her dedication to the care of pediatric cardiology patients in eastern and northern Maine for the past 30 years is recognized and appreciated.

13. References

- Aburawi, E.; Thomson, J. & Blackburn, M. (2006) Familial idiopathic atrial fibrillation with fetal bradycardia. *Acta Paediatr*; Vol.95, pp. 1700-1702.
- Akinci, E.; Alp, M. & Yakut C. (2005) Surgical management of cardiac myxoma. *J Card Surg*, May-Jun, Vol. 20, No. 3, pp. 300-304.
- Alan, S.; Ulgen, M.S.; Soker, M.; Geyik, F.; Karabulut, A. & Toprak, N. (2004) Electrocardiologic and echocardiographic features of patients exposed to scorpion bite. *Angiology*, Vol.55, No.1, pp. 79-84.
- American College of Cardiology/American Heart Association /European Society of Cardiology 2006 Guidelines for the management of patients with atrial fibrillation: a report of the American College of Cardiology/American Heart Association Task Force on Practice Guidelines and the European Society of Cardiology Committee for Practice Guidelines (Writing Committee to Revise the 2001 Guidelines for Management of Patients With atrial Fibrillation). (2006) *Circulation*, Vol.114:pp. e257-354.2011
- American College of Cardiology Foundation/American Heart Association/Heart Rhythm Society focused update on the management of patients with atrial fibrillation (updating the 2006 guideline): a report of the American College of Cardiology Foundation/ American Heart Association Task Force on Practice Guidelines. (2011) *J Am Coll Cardiol*, Vol.57, No.2, pp. 223-242.
- Attenhofer Jost, C. H.; Connolly, H. M.; Danielson, G. K.; Bailey, K. R.; Schoff, H. V.; Shen, W. K.; Warnes, C. A.; Seward, J. B.; Puga, F. J. & Talik, A. J. (2005) Sinus venosus atrial septal defect: long-term postoperative outcome for 115 patients. *Circulation*, Vol.11, No.13, pp. 1953-1958.
- Azancot-Benistry, A; Jacqz-Aigrain, E.; Guirgis, N. M.; Decrepy, A.; Oury, J. F. & Blot, P. (1992) Clinical and pharmacologic study of fetal supraventricular tachyarrhythmias. *J Pediatr*, Vol.121, pp. 608-613.
- Banwell, B.L.; Becker, L. E.; Jay, V.; Taylor, G. P. & Vajsar, J. (1999) Cardiac manifestations of congenital fiber-type disproportion myopathy. *J Child Neurol*, Vol.14, No.2, pp. 83-87.
- Basso, C.; Corrado, D.; Rossi, L. & Thiene, G. (2001) Ventricular preexcitation in children and young adults: atrial myocarditis as a possible trigger of sudden death. *Circulation*, Vol.103, pp. 269-275.
- Belhassen, B.; Pauzner, D.; Bleiden, L.; Sherez, J.; Zinger, A.; David, M.; Muhlbauer, B. & Laniado, S. (1982) Intrauterine and postnatal atrial fibrillation in the Wolff-Parkinson-White syndrome. *Circulation*, Vol.66, pp. 1124-1128
- Benito, B.; Brugada, R.; Perich, R.M.; Lizotte, E.; Cinca, J.; Mont, L.; Berruezo, A.; Tolosana, J. M.; Freixa, X.; Brugada, P. & Brugada, J. (2008) A mutation in the sodium channel is responsible for the association of long QT syndrome and familial atrial fibrillation. *Heart Rhythm*, Vol.5, No.10, pp. 1434-1440.

- Berger, F.; Vogel, M.; Kretschmar, O.; Dave, H.; Pretre, R. & Dodge-Khatami A.(2005) Arrhythmias in patients with surgically treated atrial septal defects. *Swiss Med Wkly* Vol.135. No.11-12, pp. 175-178.
- Bertram, H.; Paul, T.; Beyer, F. & Kallfelz, H. C. (1996) Familial idiopathic atrial fibrillation with bradyarrhythmia. *Eur J Pediatr*, Vol.155. No.1, pp. 7-10.
- Boos, C. J.; Anderson, R. A. & Lip, G. Y. (2006) Is atrial fibrillation an inflammatory disorder? *Eur Heart J*, Jan, Vol.27, No.2, pp. 136-149.
- Boos, C. J. & Lip, G.Y. (2008) Inflammation and atrial fibrillation: cause or effect? *Heart*, Vol.94, No.2, pp. 133-134.
- Bouchardy, J.; Therrien, J.; Pilote, L.; Ionescu-Ittu, R.; Martucci, G.; Bottega, N. & Marelli, A. J. (2009) Atrial arrhythmias in adults with congenital heart disease. *Circulation*, Vol.120, pp. 1679-1686.
- Boyett, M. R. (2009;) 'And the beat goes on' The cardiac conduction system: the wiring system of the heart. *Exp Physiol*, Vol.94, No.10, pp. 1035-1049.
- Brembilla-Perrot, B.; Tater, C. & Sutj-Selton, C. (2010) Risk factors of adverse presentation as the first arrhythmia in Wolff-Parkinson-White syndrome. *Pacing Clin Electrophysiol*, Vol.33, No.9, pp. 1074-1081.
- Brenyo, A. J. & Aktas, M. K. (2011). Non-pharmacologic management of atrial fibrillation. *Am J Cardiol*, Vol.108, pp. 317-325.
- Bronzetti, G.; D'Angelo, C.; Angelini, A.; Picchio, F. M. & Boriani, G. (2009) Resolution of atrial thrombosis with heparin in a newborn with atrial flutter. *Acta Paediatr*, Vol.8, pp. 1211-1214.
- Byrum, C. J.; Wahl, R. A.; Behrendt, D.M. & Dick, M. (1982) Ventricular fibrillation associated with the use of digitalis in a newborn infant with Wolff-Parkinson-White syndrome. *J Pediatr*, Vol.101, pp. 400-403.
- Campbell, R. M.; Strieper, M. J.; Frias, P.A.; Collins, K. K.; Van Hare, G. F. & Dubin, A. M. (2003) Survey of current practice of pediatric electrophysiologists for asymptomatic Wolff-Parkinson-White syndrome. *Pediatrics*, Vol.111, No.3, e245-e247.
- Chandler, N. J.; Greener, I.D.; Tellez, J. O.; Inada, S.; Musa, H.; Molenaar, P.; DiFrancesco, D.; Baruscotti, M.; Longhi, R.; Anderson, R. H.; Billeter, R.; Sharma, V.; Sigg, D.C.; Boyett, M.R. & Dobrzynski, H. (2009) Molecular architecture of the human sinus node - insights into the function of the cardiac pacemaker. *Circulation*;119:1562-1575.
- Chatzis, A. C.; Giannopoulos, N. M.; Milonakis, M.; Contrafouris, C.A.; Tsoutsinos, A.; Kolettis, T.; Panagiotou, C.; Zavaropoulos, P.; Maraki, P.; Koussi, T.; Sofianidou, J.; Kirvassilis, G.V. & Sarris, G. E. (2008) Mid-term results following surgical treatment of congenital cardiac malformations in adults. *Cardiol Young*, Vol.18, No.5, pp. 461-466.
- Chauvaud, S. M.; BranCaccio, G. & Carpentier, A. F. (2001) Cardiac arrhythmias in patients undergoing surgical repair of Ebstein's anomaly. *Ann Thorac Surg*, Vol.71, No.5, pp. 1547-1552.
- Chen, H. Z.; Jiang, L.; Rong, W.H.; Wang, J. S.; Shen, C.; Shi, Y. F. & Pu, S. Y. (1992) Tumors of the heart. An analysis of 79 cases. *Chin Med J (Engl)*. Feb, Vol.105, No.2, pp. 153-158.
- Chimenti, C.; Russo, M. A.; Carpi, A. & Frustaci, A. (2010) Histological substrate of human atrial fibrillation. *Biomed Pharmacother*, Mar, Vol.64, No.3, pp. 177-83.

- Collins, K. K. (2009) The spectrum of long-term electrophysiologic abnormalities in patients with univentricular hearts. *Congenit Heart Dis*, Vol.4, No.5, pp. 310-317.
- Collins, K. K.; Thiagarajan, R. R.; Chin, C.; Dubin, A. M.; Van Hare, G. F.; Robbins, R. C.; Mayer, J. E.; Bernstein, D.; Berul, C. I. & Blume, E. D. (2003); Atrial tachyarrhythmias and permanent pacing after pediatric heart transplantation. *J Heart Lung Transplant*, Vol.22, No.10, pp. 1126-1133.
- Cooper, M. J.; deLorimier, A. A.; Higgins, C. B.; Van Hare, G. F. & Enderlein, M. A. (1994) Atrial flutter-fibrillation resulting from left atrial compression by an intrapericardial lipoma. *Am Heart J*. Apr Vol.127, No.4 Pt 1, pp 950-951.
- Cox, J. L. (2010) The longstanding, persistent confusion surrounding surgery for atrial fibrillation. *J Thorac Cardiovasc Surg*, Vol.139, pp. 1374-1386.
- Cox, J. L.; Scheussler, J. B.; D'Agostino, H. J. Jr.; Stone, C. M.; Chang, B.C.; Cain, M. E.; Corr, P. B. & Boineau, J. P. (1991) The surgical treatment of atrial fibrillation III: development of a definitive surgical procedure. *J Thorac Cardiovasc Surg*, Vol.101, No.4, pp. 569-583.
- Cuneo, B. F. & Strasburger, J. F. (2000) Management strategy for fetal tachycardia. *Obstet Gynecol.*, Vol.96, pp. 575-581.
- Dahl, O. E. & Huisman, M. V. (2010) Dabigatran etexilate: advances in anticoagulation therapy. *Expert Rev Cardiovasc Ther*, Vol.8, No.6, pp. 771-774.
- Darbar, D.; Kannankeril, P. J.; Donahue, B. S.; Kucera, G.; Stubblefield, T.; Haines, J. L.; George, A.L.; Roden DM. (2008) Cardiac sodium channel (*SCN5A*) variants associated with atrial fibrillation. *Circulation*, Vol.117, pp. 1927-1935.
- da Silva, P. S. & Waisberg, J. (2010) Induction of life-threatening supraventricular tachycardia during central venous catheter placement: an unusual complication. *J Pediatr Surg*, Aug, Vol.45, No.8, pp. E13-E16
- Deal, B. J.; Mavroudis, C. & Backer C. L. (2003) Beyond Fontan conversion: surgical therapy of arrhythmias including patients with associated complex congenital heart disease. *Ann Thorac Surg*, Vol.76, No.2, pp. 542-553.
- de Vos, C. B.; Pisters, R.; Nieuwlaat, R.; Prins, M. H.; Tieleman, R.G.; Coelen, R.-J. S., van den Heijkant, A. C.; Alessie, M. A. & Crijns, H. J. G. M. (2010) Progression from paroxysmal to persistent atrial fibrillation. *J Am Coll Cardiol*, Vol.55, pp. 725-731.
- Di Rocco, J. R.; Durning, A.; Morelli, P. J.; Heyden, M. & Biancaniello, T. A. (2011) Atrial fibrillation in healthy adolescents after highly caffeinated beverage consumption: two case reports. *J Med Case Reports*, Vol.5, No.1, p.18.
- Dobrzynski, H.; Li, J.; Tellez, J.; Greener, I. D.; Nikolski, V. P.; Wright, S. E.; Parson, S. H.; Jones, S. A.; Lancaster, M. K.; Yamamoto, M.; Honjo, H.; Takagishi, Y.; Kodama, I.; Efimov, I.R.; Billeter, R. & Boyett, MR. (2005) Computer three-dimensional reconstruction of the sinoatrial node. *Circulation*, Vol.111, 846-854.
- Estlin, E. J.; Bennett, M. K.; Skinner, J. R.; Milligan, D. W. & Wren, C. (1998) Atrial fibrillation with neonatal pulmonary lymphangiectasia. *Acta Paediatr*, Dec, Vol.87, No.12, pp. 1304-1306.
- Fazio, G.; Visconti, C.; D'Angelo, L.; Novo, G.; Barbaro, G. & Novo, S. (2008) Pharmacological therapy in children with atrial fibrillation and atrial flutter. *Curr Pharm Des*, Vol.14, No.8, pp. 770-775.

- Frohn-Mulder, I.M.; Stewart, P. A.; Witsenburg, M.; Den Hollander, N. S.; Wladimiroff, J. W. & Hess, S. (1995) The efficacy of flecainide versus digoxin in the management of fetal supraventricular tachycardia. *Prenat Diagn*, Vol.15, pp. 1297-1302.
- Frustaci, A.; Chimenti, C.; Bellocci, F.; Morgante, E.; Russo, M. A. & Maseri, A. (1997) Histological substrate of atrial biopsies in patients with lone atrial fibrillation. *Circulation*, Vol.96, pp. 1180-1184.
- Fujita, S.; Takahashi, K.; Takeuchi, D.; Manaka, T.; Shoda, M.; Hagiwara, N.; Kurosawa, H. & Nakanishi, T. (2009) Management of late atrial tachyarrhythmias long after Fontan operation. *J Cardiol*, Vol. 53 No.3, 410-416.
- Gewitz, M. H. & Woolf, P.K. (2006) Cardiac emergencies. In: *Textbook of Pediatric Emergency Medicine*, 5th ed., Fleisher, G. R.; Ludwig, S.; Henretig, F.M., eds., Lippincott Williams & Wilkins, Philadelphia PA, pp. 717-758.
- Gilbert-Barnes, E. & Barnes, L. A. (2006) Pathogenesis of cardiac conduction disorders in children genetic and histopathologic aspects. *Am J Med Genet A*. Oct 1, Vol.140, No.19, pp. 1993-2006.
- Gittenberger-De Groot, A. C.; Mahtab, E. A. F.; Hahurij, N. D.; Wisse, L. J.; DeRuiter, M. C.; Wijffels, M.C. E. F. & Poelman, R. E. (2007) Nkx2.5-negative myocardium of the posterior heart field and its correlation with podoplanin expression in cells from the developing cardiac pacemaking and conduction system. *Anat Rec*, Vol.290, pp 115-122.
- Goodloe, A. H.; Herron, K. J. & Olson, T. M. (2011) Uncovering an intermediate phenotype associated with rs2200733 at 4q25 in lone atrial fibrillation. *Am J Cardiol*, Vol.107, pp. 1802-1805.
- Gourdie, R. G.; Harris, B. S.; Bond, J.; Justus, C.; Hewett, K. W.; O'Brien, T. X.; Thompson, R. P. & Sedmera, D. (2003) Development of the cardiac pacemaking and conduction system. *Birth Defects Research (Part C)*, Vol.69, pp. 46-57.
- Greason, K.L.; Dearan, J. A.; Theodoro, D. A.; Porter, C. B.; Warnes, C. A. & Danielson, G. K. (2003) Surgical management of atrial tachyarrhythmias associated with congenital cardiac anomalies: Mayo Clinic experience. *Semin Thorac Cardiovasc Surg Pediatr Card Surg Annu*, Vol.6, pp. 59-71.
- Guglin, M.; Maradia, K.; Chen, R. & Curtis, A. B. (2011) Relation of obesity to recurrence rate and burden of atrial fibrillation. *Am J Cardiol*, Vol.107, pp. 579-582.
- Haissaguerre, M.; Jais, P.; Shah, D. C.; Takahashi, A.; Hosini, M.; Quinon, G.; Garrique, S.; Le Mouroux, A.; Le Metayer, D. & Clementy, J. (1998) Spontaneous initiation of atrial fibrillation by ectopic beats originating in the pulmonary veins. *N Engl J Med*, Vol.339, No.10, pp. 659-666.
- Hajdu, J.; Szabo, I.; Papp, C.; Gorbe, E.; Cesko, I. & Papp, Z. (1997) [Treatment of haemodynamically significant fetal arrhythmias]. *Orv Hetil*, Vol.138, pp. 2335-2338.
- Hallak, M.; Neerhof, M.G.; Perry, R.; Nazir, M. & Huhta, J. C. (1991) Fetal supraventricular tachycardia and hydrops fetalis: combined intensive, direct, and transplacental therapy. *Obstet Gynecol*, Vol.78 (Pt 2) pp. 523-525.
- Hallioglu, O.; Aytemir, K. & Celiker, A. (2004) The significance of P wave duration and P wave dispersion for risk assessment of atrial tachyarrhythmias in patients with corrected tetralogy of Fallot. *Ann Noninvasive Electrocardiol*, Vol.9, No.4, pp. 339-344.

- Hansmann, M.; Gembruch, U.; Bald, R.; Manz, M. & Redel, D. A. (1991) Fetal tachyarrhythmias: transplacental and direct treatment of the fetus - a report of 60 cases. *Ultrasound Obstet Gynecol*, Vol.1, pp. 162-70.
- Harahsheh, A.; Du, W.; Singh, H. & Karpawich, P. P. (2008) Risk factors for atrioventricular tachycardia degenerating into atrial flutter or fibrillation in the young with Wolff-Parkinson-White. *Pacing Clin Electrophysiol*, Vol.31, No.10, pp 1307-1312.
- Hayashi, G.; Kurosaki, K.; Echigo, S.; Kado, H.; Fukushima, N.; Yokota, M.; Niwa, K.; Shinohara, T. & Nakazawa M. (2006) Prevalence of arrhythmias and their risk factors mid- and long-term after the arterial switch operation. *Pediatr Cardiol*, Vol.27, No.6, pp. 689-694.
- Ho, S.Y. & Anderson, R. H. (1990) Embryology and anatomy of the normal and abnormal conduction system. In: *Pediatric Arrhythmias: Electrophysiology and Pacing*. Gillette, P. C. & Garson, A. Jr., eds. W. B. Saunders Company, Philadelphia PA, pp. 2-27.
- Hodgson-Zingman, D. M.; Karst, M. L.; Zingman, L. V.; Heublein, D. M.; Darbar, D.; Herron, K. J.; Ballew J. D.; de Andrade, M.; Burnett, J.C. Jr. & Olson, T. M. (2008) Atrial natriuretic peptide frameshift Mutation in familial atrial fibrillation. *N Engl J Med*, Vol.359, pp. 158-165.
- Holmqvist, F.; Olesen, M. S.; Tveit, A.; Enger, S.; Topanainen, J.; Jurkko, R.; Havmoller, R.; Haimso, S.; Carlson, J.; Svendsen, J.H. & Platanov, P. G. (2011) Abnormal atrial activation in young patients with lone atrial fibrillation. *Europace*, Vol.13, pp. 188-192.
- Hoogaars, W. M. H.; Engel, A.; Brons, J. F.; Verkerk, A. O.; de Lange, F. J.; Wong, L. Y. E.; Bakker, M. L.; Clout, D. E.; Wakker, V.; Barnett, P.; Ravesloot, J. H.; Moorman, A. F. M.; Verheijck, E. E. & Christoffels, V. M. (2007). Tbx3 controls the sinoatrial gene program and imposes pacemaker function on the atria. *Genes Dev*, Vol.21, pp. 1098-1112.
- Horenstein, M. S.; Karpawich, P. P.; Epstein, M. L. & Singh, T. P. (2004) Transthoracic echocardiography for precardiopercutaneous screening during atrial flutter/fibrillation in young patients. *Clin Cardiol*, Vol.27, No.7, pp. 413-416.
- Hoyano, M.; Ito, M.; Kimura, S.; Tanaka, K.; Okamura, K.; Komura, S.; Mitsuma, W.; Hirono, S.; Chinushi, M.; Kodama, M. & Aizawa, Y. (2010) Inducibility of atrial fibrillation depends not on inflammation but on atrial structural remodeling in rat experimental autoimmune myocarditis. *Cardiovasc Pathol*, Sep-Oct, Vol.19, No.5, pp. e149-e157.
- Hsu, D. T. (2010) Cardiac manifestations of neuromuscular disorders in children. *Paediatr Respir Rev*, Mar, Vol.11, No.1, pp. 35-38.
- Huerta, C.; Lanes, S. F. & Garcia Rodriguez, L. A. (2005) Respiratory medications and risk of cardiac arrhythmia. *Epidemiology*, Vol.16, No.3, pp. 360-366.
- Ichikawa, R.; Sumitomo, N.; Komori, A.; Abe, Y.; Nakamura, T.; Fukuhara, J.; Matsumura, M.; Miyashita, M.; Kanamaru, H.; Ayusawa, M. & Mugishima, H. (2011) The follow-up evaluation of electrocardiogram and arrhythmias in children with fulminant myocarditis. *Circ J*, Apr, Vol.75, No.4, pp. 932-938.
- Ipek, G.; Erentug, V.; Bozbuga, N.; Polat, A.; Guler, M.; Kirali, K.; Peker, O.; Balkanay, M.; Chuaratanaphong, S.; Songthanasak, T.; Nawarawong, W. & Asavapiyanond, S. (1995) The surgical treatment of atrial myxomas: clinical experience in 6 patients. *J Med Assoc Thai.*, Aug, Vol. 78, No.8, pp. 415-418.

- Jaeggi, E.; Fouron, J. C. & Drblik, S.P. (1998) Fetal atrial flutter: diagnosis, clinical features, treatment, and outcome. *J Pediatr*, Vol.132, pp. 335-339.
- Jay, P. Y.; Harris, B. S.; Buerger, A.; Rozhitskaya, O.; Maguire CT, Barbosky, LA.; McCusty, E.; Berul, C. I.; O'Brien, T. X.; Gourdie, R. G. & Izumo, S. (2004) Function follows form: cardiac conduction system defects in Nkx2.5 mutation. *Anat Rec Part A*, Vol.280A, pp. 966-972.
- Johnson, J. N.; Tester, D. J.; Perry, J.; Salisbury, B.A.,; Reed, C. R. & Ackerman, M. J. (2008) Prevalence of early-onset atrial fibrillation in congenital long QT syndrome. *Heart Rhythm*, Vol.5, No.5, pp. 704-709.
- Jongbloed, M. R. M.; Schalij, M.J.; Poelmann, R. E.; Blom, N. A. Fekkes, M. L.; Wang, Z.; Fishman, G. I. & Gittenberger-DeGroot, A. C. (2004;) Embryonic conduction tissue: a special correlation with adult arrhythmogenic areas. *J Cardiovasc Electrophysiol* Vol.15, No.3, pp. 349-365.
- Kahler, C.; Grimm, B.; Schleussner, E.; Schneider, A.; Schneider, U.; Nowak, H.; Vogt, L. & Seewald, H. J. (2001)The application of fetal magnetocardiography (FMCG) to investigate fetal arrhythmias and congenital heart defects (CHD). *Prenat Diagn*, Vol.21, No.3, pp. 176-182.
- Kaltman, J. & Shah, M. (2004) Evaluation of the child with an arrhythmia. *Pediatr Clin N Am*, Vol.51, pp. 537-1551.
- Kammeraad, J. A.; van Deurzen, C. H.; Sreeram, N.; Bink-Boelkins, M. T.; Ottenkamp, J.; Helbing, W. A.; Lam, J.; Sobotka-Plojhar, M. A.; Daniels, O. & Balaji, S. (2004) Predictors of sudden death after Mustard or Senning repair for transposition of the great arteries. *J Am Coll Cardiol*, Vol.44, No.5, pp. 1095-1102.
- Karst, M. L.; Herron, K.J & Olson, T. M. (2008) X-linked nonsyndromic sinus node dysfunction and atrial fibrillation caused by emerin mutation. *J Cardiovasc Electrophysiol*, Vol.19, No.5, pp. 510-515.
- Kaseno, K.; Tada, H.; Koyama, K.; Jingu, M.; Hiramatsu, S.; Yokokawa, M.; Goto, K.; Naito, S.; Oshima, S. & Taniguchi, K. (2008;) Prevalence and characterization of pulmonary vein variants in patients with atrial fibrillation determined using 3-dimensional computed tomography. *Am J Cardiol*, Vol.101, No.11, pp. 1638-1642.
- Kaufman. E. S. (2009) Mechanisms and clinical management of inherited channelopathies: long QT syndrome, Brugada syndrome, catecholaminergic polymorphic ventricular tachycardia, and short QT syndrome. *Heart Rhythm*, Vol.6, No.8 Suppl, pp. S51-S55.
- Khairy, P.; Aboulhosn, J.; Gurvitz, M.Z.; Opatowsky, A. R.; Mongeon, F. P.; Kay, J.; Valente, A. M.; Earing, M. G.; Lui, G.; Gersony, D. R.; Cook, S.; Ting, J. G.; Nickolaus, M. J.; Webb, G.; Landzberg, M. J. & Broberg CS. (2010) Alliance for Adult Research in Congenital Cardiology. Arrhythmia burden in Adults with surgically repaired tetralogy of Fallot: a multi-institutional study. *Circulation*, Vol.122, No.9. pp. 868-875.
- Khositeth, A.; Danielson, G.K.; Dearani, J. A.; Munger, T. M. & Porter, C. J. (2004) Supraventricular tachyarrhythmias in Ebstein's anomaly: management and outcome. *J Thorac Cardiovasc Surg*, Vol.128, No.6, pp. 826-833.
- Klein, G. J.; Bashore, I. M.; Sellers, T. D.; Prichett, E. L.; Smith, W. M. & Gallagher, J. J. (1979) Ventricular fibrillation in the Wolff-Parkinson-White syndrome. *N Engl J Med*, Vol.301, pp. 1080-1085.

- Kleinman, C. S. & Nehgme, R. A. (2004) Cardiac arrhythmias in the human fetus. *Pediatr Cardiol*, Vol.25, No.3, pp. 234-251.
- Kleinman, C. S.; Nehgme, R. & Copel, JA.(1999) Fetal cardiac arrhythmias: diagnosis and therapy. In: Creasy, R. K. & Resnik, R., eds., *Maternal-Fetal Medicine*, 4th ed. Philadelphia: PA, WB Saunder Co, pp. 301-318.
- Kodama, S.; Saito, K.; Tanaka, S.; Horikawa, C.; Saito, A.; Heianza, Y.; Anasako, Y.; Nishigaki, Y.; Yachi, Y.; Iida, K. T.; Ohashi, Y. & Yamada, N. (2011) Alcohol consumption and risk of atrial fibrillation. *J Am Coll Cardiol* Vol.57, pp. 427-436.
- Korantzopoulos, P.; Kolettis, T. M. & Kountouris, E. (2005) Inflammation and anti-inflammatory interventions in atrial fibrillation. *Int J Cardiol*, Oct, Vol.10, No.104(3), pp. 361-362.
- Korantzopoulos, P.; Liu, T.; Milionis, H. J.; Li, G. & Goudevenos JA.(2009) 'Lone' atrial fibrillation: hunting for the underlying causes and links. *Int J Cardiol*, Vol.131, No.2, pp. 180-185.
- Koul, P. B.; Sussman, J.B.; Cunil-De Sauta, B. & Minarek, M. (2005) Atrial fibrillation associated with alcohol ingestion in adolescence: holiday heart in pediatrics. *Pediatr Emerg Care*, Vol.21, No.1, pp. 38-39.
- Krapp, M.; Kohl, T.; Simpson, J. M. ; Sharland, G. K; Katalinic, A. & Gembruch, U. (2003) Review of diagnosis, treatment, and outcome of fetal atrial flutter compared with supraventricular tachycardia. *Heart*, Vol.89, pp. 913-917.
- Krishna Kumar, R.; Saxena, A. & Talwar, K. K. (1991) Lone atrial fibrillation with complete heart block in a child. *Int J Cardiol*, Vol.30, No.3, pp. 349-351.
- Krishnamoorthy, S.; Lip, G. Y. & Lane, D. A. (2009) Alcohol and illicit drug use as precipitants of atrial fibrillation in young adults: a case series and literature review. *Am J Med*, Vol.122, No.9, pp. 851-856.e3.
- Kubo, T.; Kitaoka, H.; Okawa, M.; Hirota, T.; Hayato, K.; Yamasaki, N.; Matsumura, Y.; Yabe, T.; Takata, J. & Doi, Y. L. (2009) Clinical impact of atrial fibrillation in patients with hypertrophic cardiomyopathy. Results from Kochi RYOMA Study. *Circ J*, Sep, Vol.73, No.9, pp. 1599-1605.
- Larmay, H. J. & Strasburger, J. F. (2004) Differential diagnosis and management of the fetus and newborn with an irregular or abnormal heart rate. *Pediatr Clin North Am*, Vol.51, No.4, pp. 1033-1050.
- Lee, C.; Custer, J. W. & Rau, R. E. (2009). Drug doses. In: *The Harriet Lane Handbook: A Manual for Pediatric House Officers*. 18th ed., Custer, J. W. & Rau, R. E., eds., Elsevier Mosby, Philadelphia PA, pp. 717-1029.
- Lee, P. C.; Hwang, B.; Chen, Y. J.; Tai, C. T.; Chen, S.A. & Chiang, C.E. (2006) Electrophysiologic characteristics and radiofrequency catheter ablation in children with Wolff-Parkinson-White syndrome. *Pacing Clin Electrophysiol*, Vol.29, No.5, pp. 490-495.
- Lee, P. C.; Hwang, B.; Tai, C. T.; Chiang, C.E.; Yu, W. C. & Chen, S. A. (2004) The different electrophysiologic characteristics in children with Wolff-Parkinson-White syndrome between those with and without atrial fibrillation. *Pacing Clin Electrophysiol*, Vol.27, No.2, pp. 235-239.
- Lopriore, E.; Aziz, M. I.; Nagel, H. T.; Blom, N. A.; Rozendaal, L.; Kanhai, H. H. H. & Vandebussche, F. P. H. A. (2009) Long-term neurodevelopmental outcome after fetal arrhythmia. *Am J Obstet Gynecol*, Vol. 4, pp. e1-e5.

- Luciani, G. B.; Viscardi, F.; Pilati, M.; Crepaz, R.; Faggian, G. & Mazzucco, A. (2008) Age at repair affects the very long-term outcome of sinus venosus defect. *Ann Thorac Surg*, Vol.86, No.1, pp. 153-159.
- Maeno, Y.; Hirose, A.; Kanbe, T. & Hori, D. (2009) Fetal arrhythmia: prenatal diagnosis and perinatal management. *J Obstet Gynaecol Res*, Vol.35, No.4, pp. 623-629.
- Mainzer, G.; Khoury, A.; Gelernter-Yaniv, L. & Lorber, A. (2008) Neonatal atrial fibrillation after surgical repair of tracheoesophageal fistula with esophageal atresia. *Pediatr Cardiol*, Vol.29, No.1, pp. 150-152.
- Manzi, S. F. (2006) Appendix B: Emergency Drug Compendium. In: *Textbook of Pediatric Emergency Medicine* 5th ed., Flaisher, G. R.; Ludwig, S. & Henretz F. M., eds. Lippincott Williams & Wilkins, Philadelphia PA, pp. 1963-1993.
- Marelli, B.M.; Marelli, A.J.; Pilote, L.; Bouchardy, J.; Bottega, N.; Martucci, G. & Therrien, J. (2010) Atrial arrhythmias in adult patients with right- versus left-sided congenital heart disease anomalies. *Am J Cardiol*, Vol.106, No.4, pp. 547-551.
- Martin, T.C.; Smith, L.; Hernandez, A. & Weldon, C. (1983) Dysrhythmias following the Senning operation for d-transposition of the great arteries. *J Thorac Cardiovasc Surg*, Vol.85, pp. 928-933
- Martin, T.C. (2001) Echocardiographic findings in a contemporary Afro-Caribbean population referred for evaluation of atrial fibrillation or flutter. *West Ind Med J*, Vol.50, pp. 294-298.
- Matta, M.J & Cuneo, B. F. (2010) Doppler echocardiography for managing fetal cardiac arrhythmia. *Clin Obstet Gynecol*, Vol.53, No.4, pp. 899-914.
- Massin, M. M.; Dessy, H.; Malekzadeh-Milani, S. G.; Van Aerschot, I. & Verbeet, T. (2010) Prevalence of preoperative arrhythmias in children with delayed treatment of severe congenital heart disease. *Acta Cardiol*, Vol.65, No.1, pp. 37-42.
- Mavroudis, C.; Deal, B. J.; Backe, C. L. & Tsao, S. (2008) Arrhythmia surgery in patients with and without congenital heart disease. *Ann Thorac Surg*, Vol.86, No.3, pp. 857-868.
- McCabe, J. M.; Smith, L. M.; Tseng, Z. H.; Badhwar, N.; Lee, B. K.; Lee, R. J.; Scheinman, M. M.; Olgin, J. E. & Marcus, G. M. (2008) Protracted CRP elevation after atrial fibrillation ablation. *Pacing Clin Electrophysiol*, Sep, Vol.31, No.9, pp. 1146-1151.
- McNair, W. P.; Sinagra, G.; Taylor, M. R. G.; Di Lenarda, A.; Ferguson, D.A.; Salcedo, E. E.; Slavov, D.; Zhu, X.; Caldwell, J. H. & Mestroni, L. and the Familial Cardiomyopathy Registry Research Group. (2011) SCN5A mutations associate with arrhythmic dilated cardiomyopathy and commonly localize to the voltage-sensing mechanism. *J Am Coll Cardiol*, Vol.57, pp. 2160-2168.
- Mommersteeg, M. T.; Christoffels, V. M.; Anderson, R. H. & Moorman, A. F. (2009) Atrial fibrillation: a developmental point of view. *Heart Rhythm*, Vol.6, No.12, pp. 1818-1824.
- Multerer, S.; Berkenbosch, J. W.; Das, B. & Johnsrude, C. (2009) Atrial fibrillation after Taser exposure in a previously healthy adolescent. *Pediatr Emerg Care* Vol.25, No.12, pp. 851-853.
- Nanthakumar, K.; Lau, Y. R.; Plumb, V. J.; Epstein, A. E. & Kay, G. N. (2004) Electrophysiological findings in adolescents with atrial fibrillation who have structurally normal hearts. *Circulation*, Vol.110, pp. 117-123.

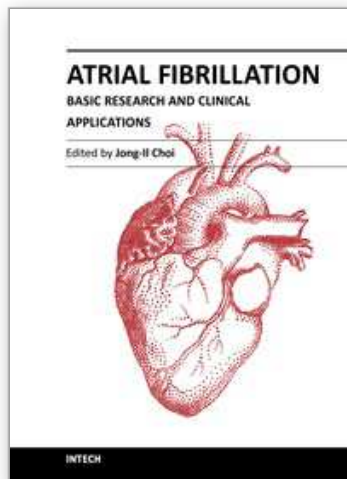
- Naumburg, E.; Riesenfeld, T. & Axelsson, O. (1997) Fetal tachycardia: intrauterine and postnatal course. *Fetal Diagn Ther*, Vol.12, pp. 205-209.
- Niemann, B.; Chen, Y.; Teschner, M.; Li, L.; Silber, R.-E. & Rohrbach, S. (2011) Obesity induces signs of premature aging in younger patients. The role of mitochondria. *J Am Coll Cardiol*, Vol.57, 577-585.
- Oteri, A.; Bussolini, A.; Sacchi, M.; Clementi, E.; Zuccotti, G.V. & Radice, S. (2010) A case of atrial fibrillation induced by inhaled fluticasone propionate. *Pediatrics*, Vol.126, pp. e1237-e1241.
- Otway, R.; Vandenberg, J. I. & Fatkin, D. (2007) Atrial fibrillation - a new cardiac channelopathy. *Heart Lung Circ*, Vol.16, No.5, pp. 356-360.
- Parilla, B.V.; Strasburger, J. F. & Socol, M. L. (1996) Fetal supraventricular tachycardia complicated by hydrops fetalis: a role for direct fetal intramuscular therapy. *Am J Perinatol*, Vol.13, pp. 483-486.
- Patel, U. & Pavri, B. B. (2009) Short QT syndrome: a review. *Cardiol Rev*, Vol.17, No.6, pp. 300-303.
- Paul, T.; Guccione, P. & Garson, A. Jr. (1990) Relation of syncope in young patients with Wolff-Parkinson-White syndrome to rapid ventricular response during atrial fibrillation. *Am J Cardiol*, Vol.65, No.5, pp. 318-321.
- Perry, L. W. & Hung, W. (1971) Atrial fibrillation and hyperthyroidism in a 14-year-old boy. *J Pediatr*, Vol.79, No.4, pp. 668-671.
- Piertersen, A. H.; Andersen, E. D. & Sandoe, E. (1992) Atrial fibrillation in the Wolff-Parkinson-White syndrome. *Am J Cardiol*, Vol.70, No.5, pp. 38A-43A.
- Platanov, P. G. (2007) Interatrial conduction in the mechanisms of atrial fibrillation: from anatomy to cardiac signals and new treatment modalities. *Europace* Vol.9, pp. vi10-vi16.
- Porter, C. J & Garson, A. Jr. (1993) Incidence and management of dysrhythmias after Fontan procedure. *Herz*, Vol.18, No.5, pp. 318-327.
- Radford, D. J. & Izukawa, T. (1977) Atrial fibrillation in children. *Pediatrics*, Vol.59, pp. 250-256.
- Reed, K. L.; Sahn, D. J.; Marx, G. R.; Anderson, C. F. & Shenker, L. (1987) Cardiac Doppler flows during fetal arrhythmias: physiologic consequences. *Obstet Gynecol*, Vol.70, No.1, pp.1-6.
- Roberts, J. D. & Gollob, M. H. (2010) Impact of genetic discoveries on the classification of lone atrial fibrillation. *J Am Coll Cardiol*, Vol.55, pp. 705-712.
- Rowland, T. W. (1983) Augmented ventricular rate following verapamil treatment for atrial fibrillation with Wolff-Parkinson-White syndrome. *Pediatrics*, Vol.72, pp. 245-246.
- Sarubbi, B. (2006) The Wolff-Parkinson-White electrocardiogram pattern in athletes: how to evaluate the risk for dangerous arrhythmias. The opinion of a paediatric cardiologist. *J Cardiovasc Med (Hagerstown)*, Vol.7, No.4, pp. 271-278.
- Sarubbi, B.; D'Alto, M.; Vergara, P.; Calvanese, R.; Mercurio, B.; Russo, M. G. & Calabro, R. (2005) Electrophysiologic evaluation of asymptomatic ventricular pre-excitation in children and adolescents. *Int J Cardiol*, Vol.98, No.2, pp. 207-214.
- Saul, J. P. (2008) Mechanism and treatment of the single ventricle patient: focus on intraatrial reentry. *Heart Rhythm*, Vol.5, No.11, pp. 1615-1618.
- Scheussler, R.B.; Boineau, J. P. & Bromberg, B. I. (1996) Origin of the sinus impulse. *J Cardiovasc Electrophysiol*, Vol.7, pp. 263-274.

- Sherf, L. & James, T. N. (1979) Fine structure of cells and their histologic organization within intranodal pathways of the heart: clinical and electrocardiographic implications. *Am J Cardiol*, Vol.44, No.2, pp. 345-369.
- Silverman, N. H.; Enderlein, M.A.; Stanger, P.; Teitel, D. F.; Heymann, M.A. & Golbus, M. S. (1985) Recognition of fetal arrhythmias by echocardiography. *J Clin Ultrasound*, Vol.13, No.4, pp. 255-263.
- Simpson, J. M. & Sharland, G. K. (1998) Fetal tachycardias: management and outcome of 127 consecutive cases. *Heart*, Vol.79, pp. 576-581.
- Sinha, A.; Fernandes, C. J.; Kim, J. J.; Fenrich, A. L. Jr., & Enciso, J. (2005) Atrial flutter following placement of an umbilical venous catheter. *Am J Perinatol*, Jul, Vol.22, No.5, pp. 275-277.
- Soyeur, D. (1996) Atrial flutter in the human fetus: diagnosis, hemodynamic consequences, and therapy. *J Cardiovasc Electrophysiol*, Vol.7, pp. 989-999.
- Spies, C.; Khandelwal, A.; Timmermanns, I. & Schrader, R. (2008) Incidence of atrial fibrillation following transcatheter closure of atrial septal defects in adults. *Am J Cardiol*, Vol.102, pp. 902-906.
- Srinivasan, S. & Strasburger, J. (2008) Overview of fetal arrhythmias. *Curr Opin Pediatr*, Vol.20, No.5, pp.522-531.
- Stiles, M.K.; John, B.; Wong, C. X.; Kuklik, P.; Brooks, A. G.; Lau, D. H.; Dimitri, H.; Roberts-Thomson, K. C.; Wilson, L.; De Sciscio, P.; Young, G. D. & Sanders, P. (2009) Paroxysmal lone atrial fibrillation is associated with an abnormal atrial substrate: characterizing the "second factor". *J Am Coll Cardiol* Vol.53. No.14, pp. 1182-1191.
- Strasburger, J. F.; Cuneo, B. F.; Michon, M. M.; Gotteiner, N. L.; Deal, B. J.; McGregor, S. N.; Oudijk, M. A.; Meijboom, E. J.; Feinkind, L.; Hussey, M. & Parilla, B. V. (2004) Amiodarone therapy for drug-refractory fetal tachycardia. *Circulation*, Jan 27 Vol.109, No.3, pp. 375-379.
- Strasburger, J. F & Wakai, R. T. (2010) Fetal cardiac arrhythmia detection and in utero therapy. *Nat Rev Cardiol*, Vol.7, No.5, pp. 277-290.
- Strieper, M. J.; Frias, P.; Fischbach, P.; Costello, L. & Campbell, R. M. (2010) Catheter ablation of primary supraventricular tachycardia substrate presenting as atrial fibrillation in adolescents. *Congenit Heart Dis*, Vol.5, No.5, pp. 65-69.
- Stulak, J. M.; Dearani, J. A.; Puga, F. J.; Zehr, K. J.; Schaff, H. V. & Danielson, G. K. (2006) Right-sided Maze procedure for atrial tachyarrhythmias in congenital heart disease. *Ann Thorac Surg*, Vol.81, No.5, pp.1780-1784.
- Sugimoto, S.; Takagi, N.; Hachiro, Y. & Abe, T. (2001) High frequency of arrhythmias after Fontan operation indicates earlier anticoagulant therapy. *Int J Cardiol*, Vol.78, No.1, pp. 33-39.
- Taketomo, C. K.; Hurlburt Hodding, J. & Kraus, D. M. (2010) *Pediatric Dosage Handbook*, 17th ed., American Pharmacists Association, Lexi-Comp, Inc. Hudson, OH.
- Texter, K. M.; Kertesz, N.J.; Friedman, R. A. & Fenrich, A.L.Jr. (2006) Atrial flutter in infants. *J Am Coll Cardiol*, Sep 5, Vol.48, No.5, pp.1040-1046.
- Thejus, J. & Francis, J. (2009) Atrial fibrillation in cardiac channelopathies. *Indian Pacing Electrophysiol J* Vol.9, No.6, pp. 342-350.
- Therrien, J.; Siu, S. C.; Harris, L.; Dore, A.; Niwa, K.; Janousek, J.; Williams, W. G.; Webb, G & Gatzoulis, M. A. (2001) Impact of pulmonary valve replacement on arrhythmia

- propensity late after repair of tetralogy of Fallot. *Circulation*, Vol.103, No.20, pp. 2489-2494.
- Themistoclakis, S.; Corrado, A.; Marchlinski, F. E.; Jais, P.; Zado, E.; Rossillo, A.; Di Biase, L.; Schweikert, R. A.; Saliba, W. I.; Horton, R.; Mohanty, P.; Patel, D.; Burkhardt, D. J.; Wazni, O.M.; Bonso, A.; Callans, D. J.; Haissaguerre, M.; Raviele, A. & Natale, A. (2010) The risk of thromboembolism and need for oral anticoagulation after successful atrial fibrillation ablation. *J Am Coll Cardiol*, Vol.55, pp. 735-743.
- Thijssen, V. L. J. L.; Ausma, J.; Gorza, L.; van der Velden, H. M. W.; Allesie, M. A.; Van Gelder, I. C.; Borgers, M. & van Eys, G. J. J. M. (2004) Troponin I isoform expression in human and experimental atrial fibrillation. *Circulation*;110:770-775.
- Thorton, J. R. (1984) Atrial fibrillation in healthy non-alcoholic people after an alcohol binge. *Lancet*, Vol.2(8410), pp. 1013-1015.
- Tikanoja, T.; Kirkinen, P.; Nikolajev, K.; Eresmaa, L. & Haring, P. (1998) Familial atrial fibrillation with fetal onset. *Heart*, Vol.79, No.2, pp. 195-197.
- Trojnarska, O.; Grajek, S.; Kramer, L. & Gwizdala, A. (2009) Risk factors of supraventricular arrhythmia in adults with congenital heart disease. *Cardiol J*Vol.16, No.3, pp. 218-226.
- Tsai, C.-T.; Chiang, F.-T.; Tseng, C.-D.; Hwang, J.-J.; Kuo, K.-T.; Wu, C.-K.; Yu, C.-C.; Wang, Y.-C.; Lai, L.-P. & Lin J.-L.(2010) Increased expression of mineralocorticoid receptor in human atrial fibrillation and a cellular model of atrial fibrillation. *J Am Coll Cardiol*, Vol.55, pp. 758-770.
- Ueda, N.; Yoshikawa, T.; Chihara, M.; Kawaguchi, S.; Niinomi, Y. & Yasaka, T. (1988) Atrial fibrillation following methylprednisolone pulse therapy. *Pediatr Nephrol*, Vol.2, No.1, pp. 29-31.
- van Engelen, A.D.; Weijtens, O.; Brenner, J. I.; Kleinman, C. S.; Copel, C.A.; Stoutenbeek, P. & Meijboom, E. J.(1994) Management, outcome and follow-up of fetal tachyarrhythmia. *J Am Coll Cardiol* Vol.24, pp. 1371-1375.
- Vermeulen, T.; Conraads, V. M.; Vrints, C. & Rodrigus, IE.(. 2009) Recurrent left ventricular myxoma presenting as cerebrovascular accidents in a teenage girl. *Acta Cardiol Dec*,Vol.64, No.6, pp. 811-814.
- Wakai, R. T.; Strasburger, J. F.; Li, Z.; Deal, B. J. & Gotteiner, N. L. (2003) Magnetocardiographic rhythm patterns at initiation and termination of fetal supraventricular tachycardia. *Circulation*, Vol.107, No.2, pp. 307-312.
- Weerasooriya, R.; Khairy, P.; Litalien, J.; Macle, L.; Hocini, M.; Sacher, F.; Lellouche, N.; Knecht, S.; Wright, M.; Nault, I.; Miyazaki, S.; Scavee, C.; Clemency, J.; Haissaguerre, M. & Jais, P. (2011) Catheter ablation foratrial fibrillation: are results maintained at 5 years of follow-up? *J Am Coll Cardiol*, Vol.57, pp.160-166.
- Weiner, C. P. & Thompson, M. I. (1988) Direct treatment of fetal supraventricular tachycardia after failed transplacental therapy. *Am J Obstet Gynecol*, Vol.158 (Pt 1), pp. 570-573.
- Wolf, C. M.; Seslar, S. P.; den Boer, K.; Juraszek, A. L.; McGowan, F. X.; Cowan, D. B.; Del Nido, P.; Triedman, J. K.; Berul C. I. & Walsh, E. P. (2009) Atrial remodeling after the Fontan operation. *Am J Cardiol*Vol.104, pp. 1737-1742.
- Yamamura, K.; Ohga, S.; Nishiyama, K.; Doi, T.; Tsutsumi, Y.; Ikeda, K.; Fujishima, A.; Takada, H. & Hara, T. (2011) Recurrent atrial fibrillation after high-dose

- methylprednisolone therapy in a girl with lupus-associated hemophagocytic syndrome. *Lupus*, Mar 17 [Epub ahead of print].
- Yamashita, H.; Nagaoka, H.; Matsushima, R.; Nakayama, I.; Goto, K.; Ogawa, T. & Fujii, H. (1987) Cardiac rhabdomyoma associated with tuberous sclerosis. An autopsy case of newborn infant died of cardiac failure. *Acta Pathol Jpn.* Apr, Vol.37, No.4, pp. 645-653.
- Yap, Y. G. (2009) Inflammation and atrial fibrillation: cause or para-phenomenon? *Europace* Aug, Vol.11, No.8, pp. 980-981.
- Yu, S. H.; Lim, S.H.; Hong, Y. S.; Yoo, K.J.; Chang, B. C. & Kang, M. S. (2006) Clinical experiences of cardiac myxoma. *Yonsei Med J*, Jun 30, Vol.47, No., pp. 367-371.
- Zielinsky, P.; Dillenburg, R. F.; de Lima, G. G. & Zimmer, L. P. (1998) [Fetal supraventricular tachyarrhythmias. Experience of a fetal cardiology reference center]. *Arq Bras Cardiol*, Vol.70, pp. 337-340.

IntechOpen



Atrial Fibrillation - Basic Research and Clinical Applications

Edited by Prof. Jong-Il Choi

ISBN 978-953-307-399-6

Hard cover, 414 pages

Publisher InTech

Published online 11, January, 2012

Published in print edition January, 2012

Atrial Fibrillation-Basic Research and Clinical Applications is designed to provide a comprehensive review and to introduce outstanding and novel researches. This book contains 22 polished chapters and consists of five sections: 1. Basic mechanisms of initiation and maintenance of atrial fibrillation and its pathophysiology, 2. Mapping of atrial fibrillation and novel methods of signal detection. 3. Clinical prognostic predictors of atrial fibrillation and remodeling, 4. Systemic reviews of catheter-based/surgical treatment and novel targets for treatment of atrial fibrillation and 5. Atrial fibrillation in specific conditions and its complications. Each chapter updates the knowledge of atrial fibrillation, providing state-of-the art for not only scientists and clinicians who are interested in electrophysiology, but also general cardiologists.

How to reference

In order to correctly reference this scholarly work, feel free to copy and paste the following:

Thomas C. Martin and Sean C. Hagenbuch (2012). Atrial Fibrillation in Children, Atrial Fibrillation - Basic Research and Clinical Applications, Prof. Jong-Il Choi (Ed.), ISBN: 978-953-307-399-6, InTech, Available from: <http://www.intechopen.com/books/atrial-fibrillation-basic-research-and-clinical-applications/atrial-fibrillation-in-children>

INTECH
open science | open minds

InTech Europe

University Campus STeP Ri
Slavka Krautzeka 83/A
51000 Rijeka, Croatia
Phone: +385 (51) 770 447
Fax: +385 (51) 686 166
www.intechopen.com

InTech China

Unit 405, Office Block, Hotel Equatorial Shanghai
No.65, Yan An Road (West), Shanghai, 200040, China
中国上海市延安西路65号上海国际贵都大饭店办公楼405单元
Phone: +86-21-62489820
Fax: +86-21-62489821

© 2012 The Author(s). Licensee IntechOpen. This is an open access article distributed under the terms of the [Creative Commons Attribution 3.0 License](#), which permits unrestricted use, distribution, and reproduction in any medium, provided the original work is properly cited.

IntechOpen

IntechOpen