

We are IntechOpen, the world's leading publisher of Open Access books Built by scientists, for scientists

4,800

Open access books available

122,000

International authors and editors

135M

Downloads

Our authors are among the

154

Countries delivered to

TOP 1%

most cited scientists

12.2%

Contributors from top 500 universities



WEB OF SCIENCE™

Selection of our books indexed in the Book Citation Index
in Web of Science™ Core Collection (BKCI)

Interested in publishing with us?
Contact book.department@intechopen.com

Numbers displayed above are based on latest data collected.
For more information visit www.intechopen.com



Hepatoprotective Effect of *Zanthoxylum armatum* DC

Nitin Verma¹ and Rattan Lal Khosa²

¹*Institute of Pharmacy and Emerging Science (IPES), Baddi University
of Emerging Science and Technology, Makhunmajara, Baddi,*

²*School of Pharmacy, BIT, Meerut, U.P.,
India*

1. Introduction

The liver is the prime organ concerned with various states of metabolic and physiologic homeostasis of organism and is a key organ of metabolism and excretion playing an important role in the maintenance of internal environment of the body through its multiple and diverse functions. It is continuously exposed to a variety of xenobiotics and therapeutic agents exposing the organ to numerous and varied disorders. There is a progressive increase in the incidence of hepatic damage mainly due to the viral infection, hepatotoxic chemicals (alcohol), toxin in food (especially aflatoxins), peroxides (particularly peroxidized edible oil), pharmaceuticals (antibiotics, chemotherapeutics, and CNS active agents), environment pollutants and xenobiotics (*Hikino et al 1988*).

Though liver disease are among the most important disease affecting mankind, no remedy is available at present in the modern system of medicine which include corticosteroids and immunosuppressive agents which bring about symptomatic relief supporting only the process of healing of liver regeneration and in most cases have no influence on the disease process. Further, their use is associated with the risk of relapses and danger of side effects. An actual curative therapeutic agent has not yet been found and thus management of liver disease is still a challenge to the modern scientific community. Hence increasing attention is being given to plants recommended for the treatment of hepatic disorders in traditional system of medicine. A number of medicinal preparations have been advocated especially in Ayurvedic system of Indian medicine, for the treatment of liver disorders. Their usage is in vogue since centuries and are quite often claimed to offer significant relief. In addition, the use of many folklore remedies mainly plant products are also common throughout India.

About 600 commercial preparations with claimed liver protecting activity are available all over the globe. In India about 33 patent herbal formulations are available for liver ailments and these preparations are a variety of combinations out of 100 Indian medicinal plants belonging to about 40 families (*Handa et al 1986*). Only a few scientific data with regard to their hepatoprotective action are on record. Phytoconstituents remains to be a major

contributor in the treatment of liver disorders. The growing concern for the identification of novel hepatoprotective agents from natural sources is evident from literature available on the same.

1.1 Free radicals in hepatic disease

The role of free radicals in the hepatic disorder is being suggested because of the fact that the detoxification of xenobiotics and toxic substances, an important function of liver, leads to the generation of large amounts of reactive oxygen intermediates. Though liver is one of the organs best supplied with antioxidant, chronic exposure to such substances overpowers the antioxidant defense system and cause hepatic damage. The role of lipid peroxidation (LPO) induced damage in the pathogenesis of chronic liver disease based on enzymatic studies (lysosomal enzyme in the serum), has been suggested. Pathological free radical reactions probably play a role in the hepatotoxicity of halothane, hydrazine, acetaminophen, carbon disulphide and α -methyl dopa. Free radical reactions participate secondarily in the development of organ damage in Wilson's disease, haemochromatosis and secondary haemosiderosis. The majority of drugs used in the treatment of liver diseases are antioxidants (Vitamin E, lipoic acid, methionine etc.) (Feher, et al 1986). The injurious roles played by the free radicals have brought in to use the antioxidants obtained from the plants for alleviating the severity of liver disorders (Meyer, et al 1990). Some plants which exhibit hepatoprotective and antioxidant activities are give belows:

Silymarin (*Silybum marianum*) (Romellini, et al 1976); schizandrins wuweizischun (*Schizandra chinensis*) (Handa, et al 1986); Saikosaponin (*Bupleurum falcatum*) (Hikino, et al 1988); glycyrrhizin, glycyrrhetic acid (*Glycyrrhiza glabra*) (Handa, et al 1986); catechin (*Uncaria gambir*) (Handa, et al 1986, Galvez, et al 1995 & Ubeda et al 1995); epicatechin (*Acacia catechin*) (Handa, et al 1986); andrographolide, andrographoside, neoandrographolides (*Andrographis panicles*) (Handa, et al 1986 & Kaul, et al 1994); picroside (*Picrorrhiza kurrao*) (Handa, et al 1986); acicubin (*Plantago asiatica*) (Handa, et al 1986); ginsenosides (*Panax ginseng*) (Handa, et al 1986); piceid and resveratrol (*Polygonum cuspidatum*) (Handa, et al 1986); arcapallin (*Artemisia capillaris*) (Handa, et al 1986); Sb-1 (*Scutellaria baicabensis*); α -tocopherol (embryos of cereals, vegetable oil, fresh vegetables) (Handa, et al 1986); curcuminoid (*Curcuma longa*) (Ravishankar, et al 1993); oil (*Bunium persicum*); quercetin, kaempferol naringenin (*Helichrysum arenarium*) (Handa, et al 1986); kaempferol 3-rhamnoglucoside, quercetin 3-rhamnoglucoside, stepposide (*Euphorbia palustris* and *E. stepposa*) (Handa, et al 1986, Galvez, et al 1995 & Ubeda, et al 1995); mixed flavonoids (*Mentha arvensis*, *Stachy neglecta*, *Colinicum coggyria*, *Anemone hepatria*, *Convallaria majalis*, *Ononis arvensis*) (Handa, et al 1986, Galvez, et al 1995 & Ubeda, et al 1995); brevifolin hyperin, ellagic acid (*E. nematocypa*) (Handa, et al 1986, Galvez, et al 1995 & Ubeda, et al 1995); *Costus speciosus* (Verma & Khosa 2009) and *Zanthoxylum armatum* (Verma & Khosa 2010).

2. *Zanthoxylum armatum* DC

Synonyms: *Zanthoxylum alatum* Roxb.
Family: Rutaceae

2.1 Common (Indian) name

Hindi - Darmar, nepali dhaniya, tejphal, tumuru

Bengali - Gaira, tambul,

Oriya - Tundopoda

Sanskrit - Tumburu, dhiva, gandhalu

2.2 Distribution

A large genus of aromatic, prickly, dioecious or rarely monoecious tree or shrubs, mainly pantropical, through also distributed in the subtropics. The genus as dealt with in the article includes species of *Fagara*, through some authors treat them as two distinct genera. About 13 species are recorded from India.

Zanthoxylum armatum DC found in the hot valleys of the Himalayas from Jammu to Bhutan at altitudes of 1,000-2100 m and in Eastern Ghats in Orissa and Andhra Pradesh at 1,200 m., in India. It is also sometimes planted for hedges in Assam.

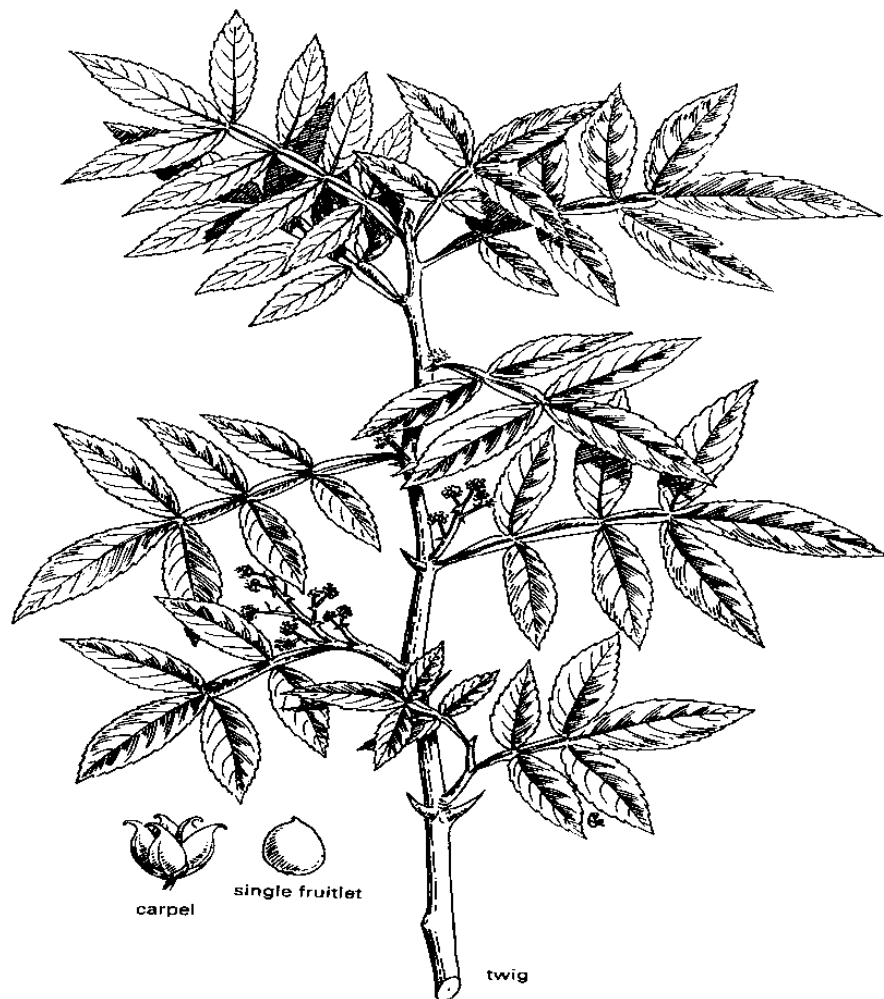

Fig. 1. *Zanthoxylum armatum*

2.3 Description

Zanthoxylum armatum DC, is an armed scandent or erect shrub or a small tree, 6 m tall or more with dense foliage, branches armed, the prickles flattened, up to 2 cm. long, bark pale brown, deep-furrowed, leaves imparipinnate or trifoliolate, 5-23 cm. long, often with flattened prickles, leaflets up to 5 pairs, opposite, ovate to lanceolate, entire to glandular crenate, acute to obtusely acuminate, flower green or yellow, in dense terminal, and occasionally axillary sparse panicles, follicles generally reddish, sub-globose, glabrous, seeds solitary in a fruit, globose, shining black. (Kirti & Basu 1975).

2.4 Phytochemical review

Several alkaloids have been isolated from the stem-bark and root-bark. The fruits of a number of species yielded essential oils. The oils from *Z. acanthopodium*, *Z. armatum*, and *Z. nitidum* are potential source of linalool, an important perfumery material; the first two species are also employed on a limited scale for the production of wartara oil. *Z. americanum* Mill., a shrub of eastern North America, is used in its native country for toothache and rheumatism.

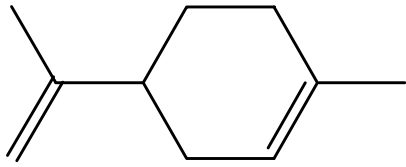
The stems and roots contain β -amyrin, β -sitosterol, L-asarinin, L-planinin, and zanthobungeanine.

The fruits contain 3.5% oil. The characteristics and constituents of the oil are summarized in Table. The fruit oil contains the rare monoterpene triol, 3, 7-dimethyl-1-octane-3, 6, 7-triol. It contains: limonene (I), linalool (II), methyl cinnamate (III), myrcene and α -thujene (IV) as the main constituents. The oil also contains 1, 8-cineol, *p*-cymene (V), *cis*-ocimene (VI), γ -terpinene, camphor (VII), α -fenchol (VIII), carvone (IX), tagetonol and alloaromadendrene, besides α -terpeniol and β -caryophyllene.

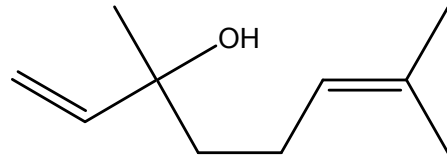
The seeds contain 6-hydroxynonadec-(4Z)-enoic acid (C₁₉H₃₆O₃, m. p. 40-42°C) (X), 8-hydroxy pentadec-(4Z)-enoic acid (C₁₅H₂₈O₃) (viscous) (XI), 7-hydroxy-7-vinylhexadec-(4Z)-enoic acid (C₁₈H₃₂O₃) (XII) and hexadec-(4Z)-enoic acid (C₁₆H₃₀O₂, m. p. 49-50°C) (XIII) along with *cis*-9-hexadecenoic, eicosenoic, palmitic acid (XIV), tambuletin and methyl cinnamate has been reported in seeds (Ahmad *et al* 1993). Further the chemical studies on the seeds of *Zanthoxylum alatum* Roxb. (Rutaceae) led to the isolation of two new phenolic constituents characterized as 3-methoxy-11-hydroxy-6,8-dimethylcarboxylate biphenyl (XV) and 3,5,6,7-tetrahydroxy-3',4'-dimethoxyflavone-5- β -D-xylopyranoside (XVI) along with the five known compounds, 1-methoxy-1,6,3-anthraquinone, 1-hydroxy-6,13-anthraquinone, 2-hydroxybenzoic acid, 2-hydroxy-4-methoxy benzoic acid, and stigmasta-5-en-3 β -D-glucopyranoside, on the basis of spectral data and chemical analysis (Akhtar *et al* 2009).

A number of alkaloids has been isolated and reported from the various parts of the *Zanthoxylum armatum* Dc. berberine (bark), dictamnine (stem-bark), magnofluorine (0.02% as picrate), xanthoplanine (0.01% as picrate) (wood and bark), magnofluorine (0.17% as picrate), xanthoplanine, skimmianine, dictamnine and γ -fagarine (Wealth of India 2005).

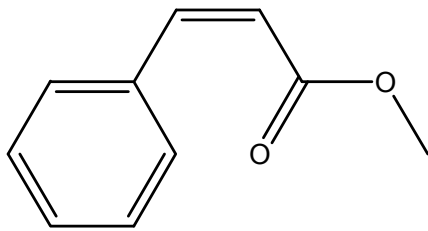
A new amide designated as armatamide along with two lignans, asarinin and fargesin, α - and β -amyrins, lupeol, and β -sitosterol- β -D-glucoside - has been isolated from the bark of *Zanthoxylum armatum*. The structure of the new compound was deduced by spectral and chemical analysis as N-(4'-methoxyphenyl ethyl)-3, 4-methylenedioxy cinnamoyl amide (Kalia *et al* 1999).



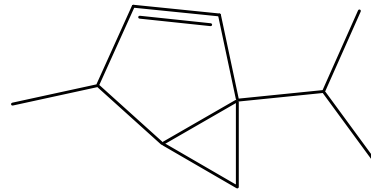
limonene
(I)



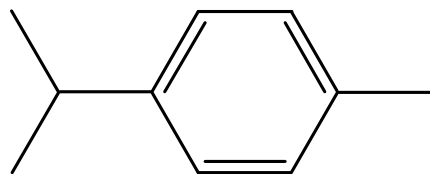
linalool
(II)



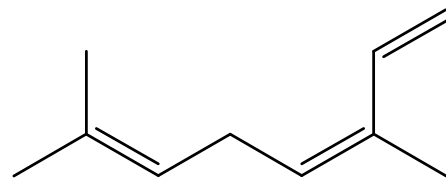
methyl cinnamate
(III)



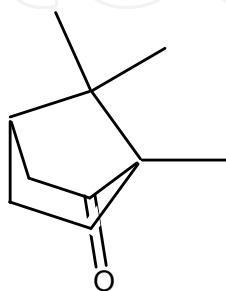
thujene
(IV)



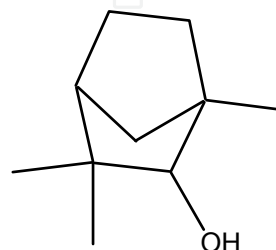
p-cymene
(V)



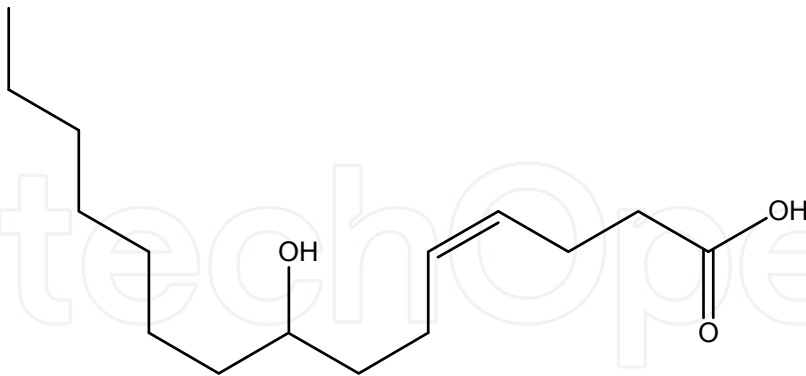
cis-ocimene
(VI)



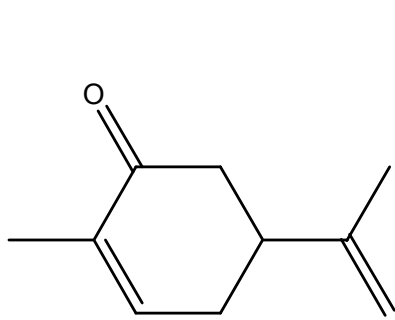
camphor
(VII)



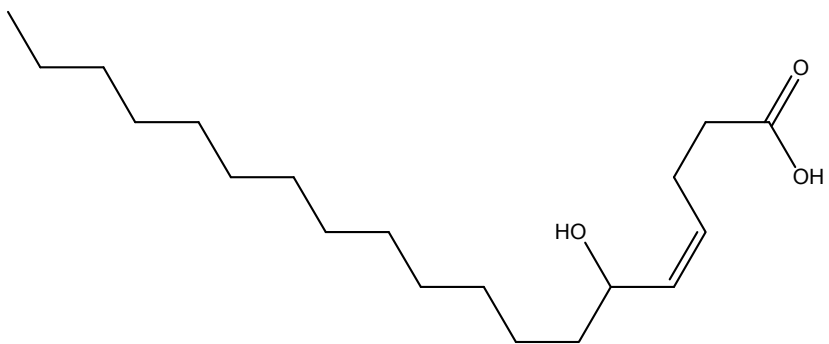
alpha-fenchol
(VIII)



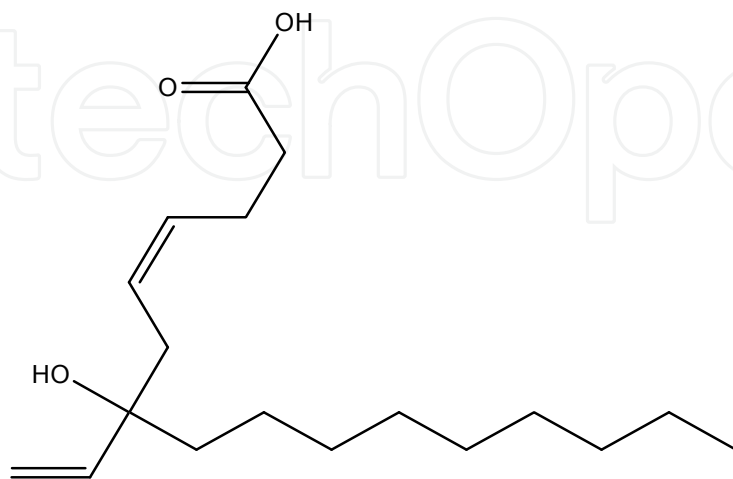
8-hydroxy pentadec-(4Z)-enoic acid (XI)



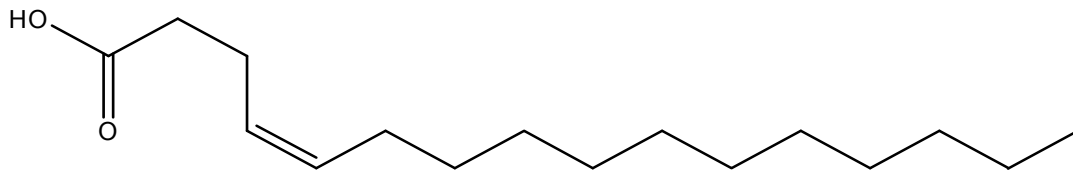
**carvone
(IX)**



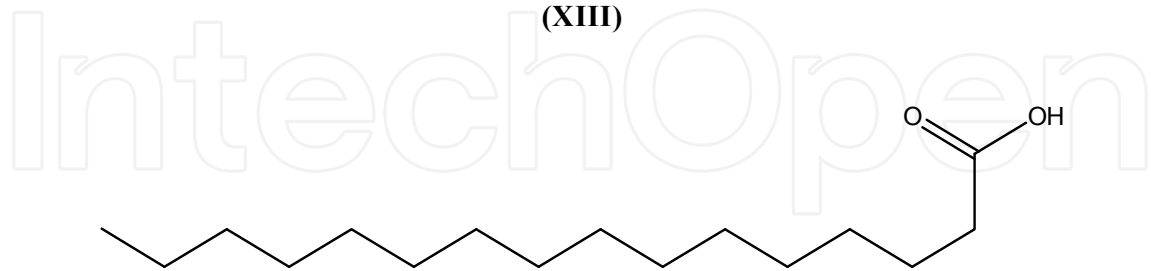
**6-hydroxynonadec-(4Z)-enoic acid
(X)**



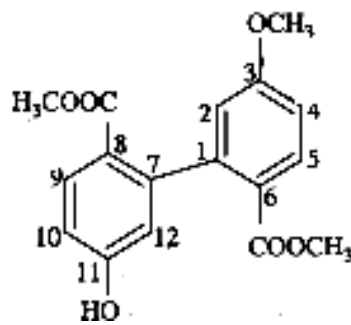
**7-hydroxy-7-vinylhexadec-(4Z)-enoic acid
(XII)**



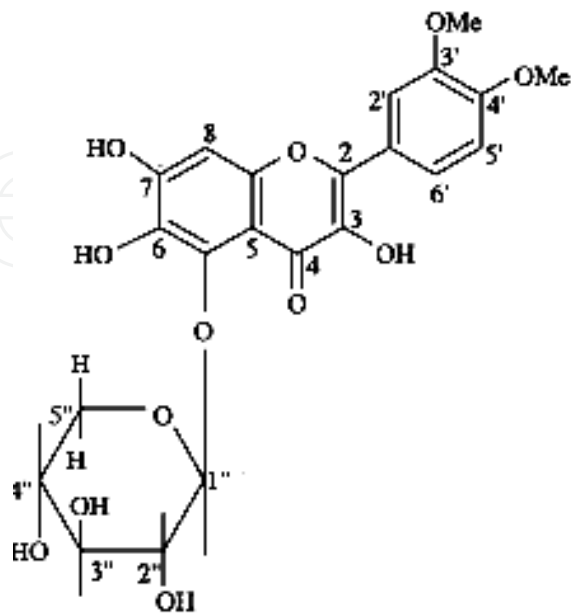
hexadec-(4Z)-enoic acid
(XIII)



palmitic acid
(XIV)



3-methoxy-11-hydroxy-6,8-dimethylcarboxylate biphenyl (XV)



3, 5, 6, 7-tetrahydroxy-3', 4'-dimethoxyflavone-5- β -d-xylopyranoside (XVI)

2.5 Pharmacological review

The bark, fruits, and seeds of *Z. armatum* are extensively used in indigenous system of medicine as a carminative, stomachic and anthelmintic. The stem has exhibited hypoglycemic activity in the preliminary trials. The bark is pungent and used to clean teeth. The fruits and seeds are employed as an aromatic tonic in fever and dyspepsia. An extract of the fruits is reported to be effective in expelling round worms. Because of their deodorant, disinfectant and antiseptic properties, the fruits are used in dental troubles, and their lotion for scabies.

Zanthobungeanine, found in stems and roots shows inhibitory activity to platelet aggregation, L-plananin is the most active compound.

The bark is used in India, for treating diarrhea and cholera. The fruits are analgesic and anodyne and used in tooth powder.

The bark of several Indian species of *Zanthoxylum* is medicinally active and noted for febrifugal, sudorific and diuretic properties (*Wealth of India 2005*).

The essential oil is said to possess antiseptic, disinfectant and deodorant properties. The freshly distilled essential oil from the seeds exhibited strong antibacterial activity against *Escherichia coli*, *Vibro cholera*, *Micrococcus pyrogens* var. *aureus*, *Shigella dysenteriae* and *Salmonella typhi*. The seed oil possesses ascaricidal, antibacterial, anthelmintic and antifungal properties. The oil on account of high percentage of linalool is highly fragrant and attractive and can be commercialized on this account.

The oil obtained by steam-distillation of the fresh plant showed antifungal activity against a number of fungi.

It is established that plants which having antioxidant property also exert hepatoprotective action (*Fehar et al 1986*). As *Z. armatum* has shown significant antioxidant activity (*Verma et al 2008*) and also contain phenolic compounds, therefore, we have to investigate the hepatoprotective activity of ethanolic extract of *Z. armatum* in rats.

3. Experimental

3.1 Plant material

The *Zanthoxylum armatum* were procured from the Plant Physiology Division, Jawaharlal Nehru Krishi Vishwa Vidyalaya, Krishi Nagar, Jabalpur, M.P. (India) and authenticated by the taxonomic division, National Herbarium of Cultivated Plants, National Bureau of Plant Genetic and Resources, New Delhi. A voucher specimen (**vide accession no. NHCP/NBPGR/2007/100/2225 dated 22/08/2007**) was retained in our laboratory. The plant material was dried under shade at room temperature, reduced to moderately coarse powder and extracted successively with petroleum ether (60-80°C) and 95% ethanol using soxhlet apparatus. The ethanolic extract was dried under vacuum (yield, 6.67%). The defatted ethanolic extract of *Zanthoxylum armatum* (EEZA) was used for the preliminary phytochemical screening and hepatoprotective studies.

3.2 Preliminary phytochemical screening

A preliminary phytochemical screening was carried out for the extracts employing the standard procedure revealed the presence of various phytoconstituents *viz.* alkaloids,

steroids, terpenes, flavonoids, saponins, tannins, glycosides, carbohydrates and proteins (Harborne 1998).

3.3 Chromatographic studies

Thin layer chromatography (TLC) and High Performance Thin Layer Chromatography (HPTLC), of the alcoholic extract of *Costus speciosus* was done.

3.4 Animals

The Institutional Animal Ethics Committee, (IAEC) review the protocol and approved the use of animals for the studies, (**Ethical clearance number: 711/02/a/CPCSEA**).

Wistar albino rats of both sexes (weighing 130–170 g) were used in the present study. They were housed in clean polypropylene cages (38X23X10 cm) with not more than three animals per cage and maintained under standard laboratory condition (temperature $25 \pm 2^\circ\text{C}$) with dark and light cycle (12/12 h) and provided standard pellet diet (Hindustan Lever, Kolkata, India) and water *ad libidum*.

3.5 Acute toxicity studies

Acute toxicity study was performed for the extract according to the acute toxic classic methods as per OECD guidelines (OECD Guidelines 1996). Wister albino rats were used for acute toxicity study. The animals were kept fasting for overnight providing only water, after which the extract was administered orally 500 mg/kg b. w. and observed for 14 days. The animals were observed If mortality was observed in 2 out of 3 animals, then the dose administered was assigned as toxic dose. If mortality was observed in 1 animal, then the dose administered was repeated again to confirm the toxic dose. If mortality was not observed, the procedure was repeated for further higher dose i.e. 2000 mg/kg.

3.6 Assessment of hepatoprotective activity

The rats were divided in to four groups of six rats each. The animals of group A and group B served as control and carbon tetrachloride (CCl_4) control received vehicle (0.1% tween 80, 10 ml/kg b. w.). Group C served as standard and received silymarin (100 mg/kg b. w. in 0.1% tween 80), and group D was given EEZA (500 mg/kg b. w. in 0.1% tween 80). All administration of doses was made by gastric intubations once daily for 7 days.

On the 8th day 1 h after the administration of last dose, the animals of group B; C and D were given an intraperitoneal injection of CCl_4 with an equal quantity of liquid paraffin (0.5 ml/kg b. w.). All the animals were then fasted for 24 h and anaesthetized and the blood was collected by cardiac puncture. The liver was quickly dissected, washed with ice-cold saline and stored in freezer. The blood samples were allowed to coagulate at room temperature for 1 h. Serum was separated by centrifugation at 12,000 rpm at 4°C for 5 min (Verma et al 2007).

3.6.1 Biochemical estimation

Serum was analyzed for various biochemical parameters, i.e. serum glutamyl oxalacetic acid transaminase (SGOT, AST), serum glutamyl pyruvate transaminases (SGPT, ALT) (Reitman

et al 1957), alkaline phosphatase (ALKP) (*Bessey et al 1946*) and for serum bilirubin (SBLN) (*Malloy et al 1937*).

3.6.2 Histopathological studies

The hepatoprotective activity was confirmed through histopathological studies on liver of rats. Slices of liver were cut and washed in Ringer's solution soaked with filter paper for 1.5 min, then liver slices were fixed in Carnay's fluid I (Ethanol: chloroform: Glacial acetic acid-6:3:1) and processed for paraffin embedding following the standard microtechniques. Sections of liver, stained with aqueous haematoxylin and alcoholic eosin were observed microscopically for histopathological changes (*Galigher et al 1971*).

3.6.3 Statistical analysis

The data represent $M \pm S.E.M$. Results were analyzed statistically by one-way ANOVA, followed by Students' *t* test. The minimum level of significance was set at $P < 0.001$ compared to control. The entire statistics were estimated by using **Sigma Stat 3.5™**, statistical software.

4. Result & discussion

4.1 Phytochemical screening

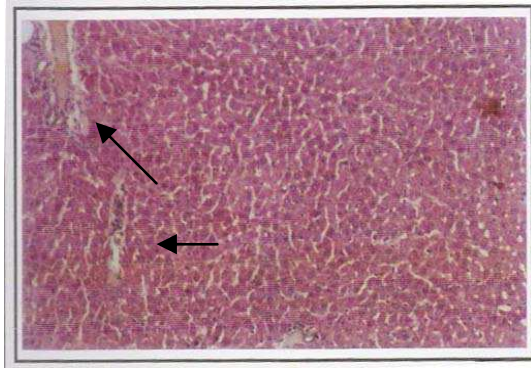
Phytochemical screening for the ethanolic extract of *Zanthoxylum armatum* revealed the presence of phytoconstituents like sterols, alkaloids, phenolic, flavonoids and reducing sugars. The ethanolic extract did not cause any mortality up to 2000 mg/kg and considered as safe.

4.2 CCl₄ induced Hepatotoxicity

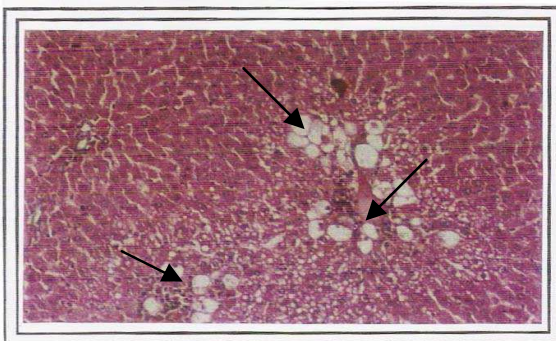
The results of CCl₄-induced hepatotoxicity are represented in Table 1. CCl₄ intoxication in normal rats elevated the levels of SGOT, SGPT, ALKP, SBLN and liver inflammation were observed significantly indicating acute hepatocellular damage and biliary obstruction. The rats that received 500 mg/kg of EEZA showed a significant ($P < 0.001$) decrease in all the SGOT, SGPT, ALKP, SBLN levels and liver inflammation, compared to induced control group.

Normal histology of rat liver showed sinusoidal degeneration (Fig. 2a). The liver sections of the rats treated with CCl₄ showed cellular degeneration hydropic changes which were more around the central vein and fatty changes with wide spread hepatocellular necrosis and centrilobular necrosis (Fig. 2b). The liver section of EEZA treated showed micro fatty changes with dense collection of lymphoid cells, suggesting evidence of very little necrosis or degeneration. There was no hepatocellular damage, except small arrears of focal degeneration and sinusoidal dilation in treated rat livers (Fig. 2c and d).

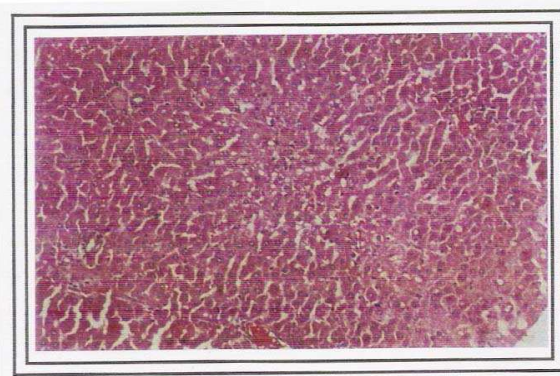
CCl₄ is biotransformed in to cytochrome P450 in the liver endoplasmic reticulum to the highly reactive trichloromethyl free radical which in turn reacts with oxygen to form a trichloromethyl peroxyradical, which may attack lipids on the membrane of endoplasmic



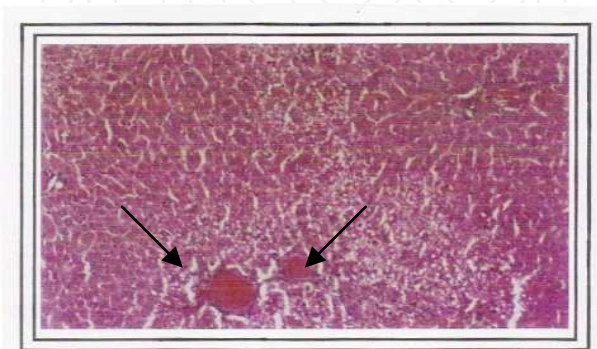
(a) **Group I (control)** - section shows central vein surrounded by hepatic cord of cells (normal architecture).



(b) **Group II (CCl₄ treated)** - section shows patches of liver cell necrosis, inflammatory collections and accumulation of fatty lobules around central vein.



(c) **Group III (Standard silymarin treated)** - almost near normal.



(d) **Group IV (treated with ethanolic extract of *Z. armatum*)** - minimal inflammatory cellular infiltration. Almost near normal liver architecture. Regeneration of hepatocytes around central vein.

Fig. 2. Histopathology of liver tissues at X 400 magnification

reticulum more readily than trichloromethyl free radical. The trichloromethylperoxy radical leads to elicit lipid peroxidation, the disruption of Ca^{2+} homeostasis, elevation of hepatic enzymes and finally results in cell death (Clawson *et al* 1989).

The results obtained from the present study indicated that the EEZA exhibited hepatoprotective effect against CCl_4 -induced liver damage by normalizing the elevated levels of the hepatic enzymes. This suggested the possibility that EEZA is able to condition the hepatocytes, so as to cause accelerated regeneration of parenchyma cells, thus protecting against membrane fragility and decreases of leakage of the marker enzymes into the circulation as compared to silymarin, reported to have protective effect on the plasma membrane of hepatocytes (Ramellini *et al* 1976). The results supported the use of this plant for the treatment of hepatitis in oriental traditional medicine.

Parameters Groups	Biochemical Parameters					
	SGPT(IU/L)	SGOT(IU/L)	SALP(IU/L)	Bilirubin(mg/dl)		Liver weight (gm)
				Total	Direct	
Group A Control	53.25±3.83	382.50±21.32	196.68±1.09	0.93±0.03	0.17±0.08	3.21±0.22
Group B Toxicant (Induction control)	268.32±23.04***	702.45±6.6***	489.23±5.7***	3.14±0.24 ***	1.29±0.25***	3.38±0.24**
Group C Standard (Silymarin 100mg/kg b.w.)	78.67±7.33	408.29±4.68	213.55±4.27	1.64±0.82	0.19±0.03	3.22±0.01
Group D EEZA (500mg/kg b.w.)	104±9.75*	438.00±7.0**	249.59±6.07*	1.82±0.38**	0.24±0.88*	3.32±0.10**

Note: n= six animals in each group

EEZA= Ethanolic extract of *Zanthoxylum armatum*

Values are expressed as Mean ± SEM

* p<0.05 compared to control.

**p<0.02 compared to control.

***p<0.001 compared to control.

Table 1. Effect of Ethanolic Extract of *Zanthoxylum armatum* on CCl_4 Induced Hepatotoxicity in Rats.

Flavonoids have been reported as active substances for the treatment of hepatitis induced by chemicals (Khalid *et al* 2002) and virus (Kang *et al* 2006) *in vitro* and *in vivo*. Ethanolic extract of *Z. armatum* showed positive results for the presence of phenolics and flavonoids during preliminary phytochemical screening. The possible mechanism may be that the antioxidant potentiality of flavonoids can scavenge free radicals and protect the cell membrane from destruction. Hence, the transaminases (ALT/AST) may not leak into blood from the necrotic hepatocytes.


5. References

- [1] Hikino, H. and Kiso, Y., In: *Economic and Medicinal Plant Research*, Eds: Wagner, H., Hikino, H. and Farnsworth, N. R., (Academic Press, London), vol.2, 39, 1988.
- [2] Handa, S.S., Sharma, A. and Chakraborti, K.K., *Fitoterapia*, Vol. LVII, 307, 1986.
- [3] Feher, J., Csomos, G. and Vereckei, A. (Eds), *Free Radical reaction in Medicine*, Springer-Verlag, Berlin, 107, 1986.
- [4] Meyer, B. and Elstner, E. F., *Planta Med.*, 56, 666, 1990.
- [5] Romellini, G. and Meldolesi, J., *Arzneim Forsch. (Drug Res.)*, 26, 69, 1976.
- [6] Galvez, J., DeCruz, J. P., Zarzuelo, A. and DeLacuesta, F.S., *Pharmaco.*, 51,127, 1995.
- [7] Ubeda, A., Esteve, M.L., Alcarz, K.H., Cheeseman, T.F. and Slater, T.F., *Phytother. Res.*, 9, 416, 1995.
- [8] Kaul, I.B. and Kapil, A., *Indian J. Pharmaco.*, 26, 297, 1994.
- [9] De, S., Ravishankar, B. and Bhavsar, G.C., *Indian J. Pharmaco.*, 26, 297, 1994.
- [10] Verma, N. and Khosa, R.L., *Nat. Prod. Rad.*, 8, 123, 2009.
- [11] Verma, N. and Khosa, R.L., *J. Biochemistry & Biophysics*, 47, 124, 2010.
- [12] Kirtikar, K.R. and Basu, B. D., *Indian Medicinal Plants*, Lalit Mohan Basu, 4, Leaders Road, Allahabad., 461, 1975.
- [13] Verma, N. and Khosa, R. L., *Indian J. Nat. Prod.*, 24, 3, 2008.
- [14] Verma, N. and Khosa, R. L., *Naresuan Phayao Journal*, 1, 99, 2008.
- [15] Akhtar, N., Ali, M., and Alam, M.S., *J. Asian Natural Prod. Res.*, 11, 91, 2009.
- [16] Anonymous, *The Wealth of India-A Dictionary of Indian Raw Materials & Industrial Products*, Vol. XI (X-Z) Publication and Information Directorate, CSIR, New Delhi. 568, 2005.
- [17] Kalia, N.K., Singh, B., and Sood, R. P., *J. Nat. Prod.*, 62, 311 1999.
- [18] Harborne, J. B., *Phytochemical Methods: A Guide to Modern Techniques of Plant Analysis*, Chapman & Hall, 1998.
- [19] Guidance document on acute oral toxicity testing, Series on testing and assessment No. 24, Organization for economic co-operation and development, OECD Environment, health and safety publications, Paris, 1996.
- [20] Verma, N., Khosa, R. L., & Pathak, A. K., *Indian J. Nat. Prod.*, 23, 2007.
- [21] Reitman, S., & Frankel, S. A., *American J. Clinical Pathology*, 28, 1957.
- [22] Bessey, O. A., Lowery, O. H., & Bros, M. J., *J Biological Chemistry*, 164, 321, 1946.
- [23] Malloy, H. T., & Evelyn, K. A., *Journal of Biology chemistry*, 119, 481, 1937.
- [24] Galigher, A. E., & Kozloff, E. N., *Essential of Practical Microtechnique*, 2nd Edition, Lea and Febiger, Philadelphia, 77, 1971.
- [25] Clawson, G. A., *Pathology and Immunopathology Research*, 8, 104, 1989.

- [26] Ramellini, G., & Meldolesi, J., *Arzneim Forsch (Drug Research)*, 26, 69, 1976.
- [27] Khalid, H. J., Sheikh, A. S., & Anwar, H. G., *Fitoterapia*, 73, 557, 2002.
- [28] Kang, E. H., Kown, T.Y., Oh, W.F., Park, S.I., Lee, Y. I., *Antiviral Research*, 72, 100, 2006.

IntechOpen

IntechOpen



Bioactive Compounds in Phytomedicine

Edited by Prof. Iraj Rasooli

ISBN 978-953-307-805-2

Hard cover, 218 pages

Publisher InTech

Published online 18, January, 2012

Published in print edition January, 2012

There are significant concerns regarding the potential side effects from the chronic use of conventional drugs such as corticosteroids, especially in children. Herbal therapy is less expensive, more readily available, and increasingly becoming common practice all over the world. Such practices have both their benefits and risks. However, herbal self-therapy might have serious health consequences due to incorrect self-diagnosis, inappropriate choice of herbal remedy or adulterated herbal product. In addition, absence of clinical trials and other traditional safety mechanisms before medicines are introduced to the wider market results in questionable safe dosage ranges which may produce adverse and unexpected outcomes. Therefore, the use of herbal remedies requires sufficient knowledge about the efficacy, safety and proper use of such products. Hence, it is necessary to have baseline data regarding the use of herbal remedies and to educate future health professionals about various aspects of herbal remedies.

How to reference

In order to correctly reference this scholarly work, feel free to copy and paste the following:

Nitin Verma and Rattan Lal Khosa (2012). Hepatoprotective Effect of Zanthoxylum armatum DC, Bioactive Compounds in Phytomedicine, Prof. Iraj Rasooli (Ed.), ISBN: 978-953-307-805-2, InTech, Available from: <http://www.intechopen.com/books/bioactive-compounds-in-phytomedicine/hepatoprotective-effect-of-zanthoxylum-armatum-dc>

INTECH
open science | open minds

InTech Europe

University Campus STeP Ri
Slavka Krautzeka 83/A
51000 Rijeka, Croatia
Phone: +385 (51) 770 447
Fax: +385 (51) 686 166
www.intechopen.com

InTech China

Unit 405, Office Block, Hotel Equatorial Shanghai
No.65, Yan An Road (West), Shanghai, 200040, China
中国上海市延安西路65号上海国际贵都大饭店办公楼405单元
Phone: +86-21-62489820
Fax: +86-21-62489821

© 2012 The Author(s). Licensee IntechOpen. This is an open access article distributed under the terms of the [Creative Commons Attribution 3.0 License](#), which permits unrestricted use, distribution, and reproduction in any medium, provided the original work is properly cited.

IntechOpen

IntechOpen