

We are IntechOpen, the world's leading publisher of Open Access books Built by scientists, for scientists

4,800

Open access books available

122,000

International authors and editors

135M

Downloads

Our authors are among the

154

Countries delivered to

TOP 1%

most cited scientists

12.2%

Contributors from top 500 universities



WEB OF SCIENCE™

Selection of our books indexed in the Book Citation Index
in Web of Science™ Core Collection (BKCI)

Interested in publishing with us?
Contact book.department@intechopen.com

Numbers displayed above are based on latest data collected.
For more information visit www.intechopen.com



Endoscopic Vidian Neurectomy: The Anatomy Consideration and Preoperative Images Analysis

Wan-Fu Su, Shao-Cheng Liu and Hsing-Won Wang
Graduate Institute of Clinical Medicine and Department of Otolaryngology, Taipei Medical University - Shuang Ho Hospital, Taipei, Taiwan Republic of China

1. Introduction

Although surgery is not a primary treatment for managing rhinitis, it can have some adjuvant benefit in patients with significant nasal congestion or poor pharmacologic response. It is usually performed by surgical approaches to the inferior turbinate, and the more aggressive procedures such as the vidian neurectomy have not been widely applied. Traditional approaches to the vidian canal necessitate larger incisions, including transeptal, transpalatal and transantral methods. These approaches are often not reliable and at the risk of injury to the abutting neurovascular structures. Pioneers in endoscopic surgery are exploring alternatives to these traditional techniques in an attempt to minimize morbidity and the lack of irrelevant incisions. The main difficulties encountered during endoscopic approach are anatomic variations such as canal wall dehiscence, intra-sphenoid septa, pneumatization degree of pterygoid process and the relationship between vidian canal and middle turbinate. Those variations will have effect in determining the surgical success rate and the related complications. Therefore, a powerful tool, in the purpose of identifying the canal location and its surrounding anatomy, is very important to guide the surgeon in preoperative assessment and intraoperative approach. Computed tomography (CT) scanning is superior for the evaluation of the bony confines of the sinonasal tract and skull base. The most minimal recesses of the sinonasal region are easily assessed and it is possible to evaluate the position and configuration of the vidian canal. That valuable information provided by imaging studies enhances the surgical feasibility and offers an alternative for treating the rhinitis. This chapter describes the use of CT images in this capacity. Growing surgical experience and evolving technology will help to advance the feasibility of endoscopic vidian neurectomy and elucidate their indications by using preoperative images.

2. General principles

The term rhinitis refers to an inflammatory disease of the nasal mucosa. This inflammation can be acute or chronic and leads to a cluster of symptoms that may include sneezing, nasal itching, rhinorrhea, impairment in smell, and nasal congestion. A number of discrete mechanisms are involved in the pathogenesis of chronic rhinitis, including both allergic and

nonallergic. A recent consensus document has classified rhinitis into one of four categories: (a) structural, (b) infectious, (c) allergic, and (d) other.(Bernstein 2010) These categories can be difficult to apply and overlap between two or more of these classes is quite common, leading to a classification of rhinitis as being “mixed” in a significant proportion of patients complaining of symptoms of nasal inflammation. Furthermore, the lack of clear diagnostic criteria and the absence of reliable diagnostic tests often add to the confusion in reaching a precise diagnosis of the type of rhinitis and its most favorable treatment. (Scadding et al. 2008)

Allergic rhinitis (AR) is an immunologic nasal response, primarily mediated by immunoglobulin E (IgE). It has traditionally been divided into two categories based on the seasonality of the symptoms: seasonal allergic rhinitis, which is defined as AR symptoms triggered by seasonal increases in relevant antigens, such as pollens and outdoor molds, and perennial allergic rhinitis, defined as AR symptoms occurring throughout most of the year, and related to perennial antigens such as animal dander, dust mites, cockroach, and indoor molds.(Broide 2010) In contrast to AR, nonallergic rhinitis (NAR) is a disease that cannot be explained by any uniform pathophysiologic mechanism. It is rather considered a diagnosis of exclusion among patients with allergic symptoms yet negative to allergy testing. The condition exists in a variety of forms that are a function of differing physiologic processes and are considered a syndrome that is broadly referred to as NAR. These various influences include infection, hormonal fluctuations, pharmacological agents, and autonomic dysfunction.(Salib et al. 2008)

Vasomotor rhinitis (VMR) is the most common form of chronic NAR with the clinical presentations including nasal obstruction, postnasal drip, itching, clear rhinorrhea, epiphora, crocodile tears and Sluder syndrome. It has been thought to result from an imbalance in the autonomic input to the nasal mucosa with increased parasympathetic stimulation without adequate sympathetic balance.(van Rijswijk et al. 2005) The vidian nerve, with its autonomic fibers formed by the union of the greater and deep petrosal nerve, is responsible for VMR. This nerve exits the lateral part of the anterior end of the carotid canal, passes along the upper part of the anterolateral edge of the foramen lacerum, courses through the vidian canal, and ends in the pterygopalatine ganglion in the posterior part of the pterygopalatine fossa.(Osawa et al. 2009) Clinically it serves as an important landmark in endoscopic and microsurgical approaches to the cranial base, especially for the lacerum and petrosal segment of the internal carotid artery. Damage to the vidian nerve does not prevent normal mucosal reaction to colds; however, it may reduce lacrimation as measured by Schirmer’s test.(Jang et al. 2011) Its surgical role in treating chronic rhinitis is yet to be established since different healing results were reported in the past.

The successful treatment of both AR and NAR is based on the patient's understanding of the nature of the disease, its triggers, and the strategy for its management. Because rhinitis is a chronic condition that requires treatment over time, the complete participation of the patient in treatment is necessary. Education is essential as a component of the overall treatment strategy. The treatment involves mainly stimulant avoidance and pharmacological approaches such as mast cell stabilizers, anti-histamines, decongestants, immunotherapy or corticosteroids. Surgery is not a primary treatment in treating chronic rhinitis. In patients with significant nasal congestion, surgical approaches to the inferior turbinate can have some adjuvant benefit because of the nasal resistance reduction.(Mora et al. 2009) As for other nasal presentations, the vidian neurectomy is an option because it can inhibit the excessive efferent stimulation of the parasympathetic system and interrupt cholinergic

innervation to the nasal mucosa. An increased feasibility with the advance in instruments and image analysis is obtained and we believe this surgery plays a role in treating patients with chronic rhinitis who shows poor response to an at least 3-month medical treatment.

3. History of vidian neurectomy

Golding-Wood first described vidian neurectomy (VN) in the early 1960s.(Golding-Wood, 1961) Various approaches were developed thereafter, including transseptal, transpalatal and transantral methods.(Chandra 1969; Gregson 1969; Minnis and Morrison 1971; Nomura et al. 1971) The multitude of proposed surgical approaches to the vidian nerve connotes that none is totally satisfactory, mainly because of difficulties in nerve identifications, highly demanding surgical technique and risk of complication. The vidian nerve is seated deep at the base of the skull, an area which is anatomically difficult to reach and is surrounded by numerous important structures. Therefore, this technique had been largely abandoned for about 20 years after Golding-Wood.

The transnasal approach had been advocated with the help of an operating microscope and diathermy coagulation since the 1980s.(Krajina 1989) It once had been viewed as an ideal technique which was fast, less invasive and associated with a lower complication rate. Most of these approaches obtained their outcome by cauterization of the vidian nerve. It raised a concern of inaccurate or inadequate nerve function block. In the 1990s, the endoscope was introduced and facilitated the same procedures in the pterygopalatine fossa (PPF).(el Shazly 1991; Kamel and Zaher 1991) The use of endoscope led to a precise identification of the vidian nerve and enabled a nerve resection instead of a nerve cauterization. Kamel and Shazly etc were pioneers in this entity with the region targeted confined in the PPF. They approached the anterior opening of vidian canal subperiosteally by carefully pushing the mucoperiosteum and contents of PPF slightly laterally. In their attempts, the brisk bleeding from injury of sphenopalatine artery (SPA) was the major surgical difficulty. Besides, the difficulty to remove sphenoid process of palatine bone between sphenopalatine foramen and anterior wall of sphenoid sinus and its resultant bone oozing usually frustrate frustrated surgeons and reduced their willingness to attempt this process. Shazly etc admitted that two main difficulties were encountered: bleeding and working in a relatively narrow operative field.

Robinson and Wormald were the first ones who took advantage of sphenoid sinus as guidance.(Robinson and Wormald 2006) He claimed that enlargement of the sphenopalatine foramen posteriorly up to the anterior face of the sphenoid to the level of the floor of the sphenoid sinus using a bone punch facilitated the identification of vidian nerve in the PPF. To eliminate the intimidation of vascular risk, the SPA should be cauterized first. Transection of the vidian nerve was performed before its entrance into the PPF. In those above retrograde fashion (from sphenopalatine foramen to anterior opening of vidian canal), the surgical difficulties include failure to find the sphenopalatine artery at the expected site since the relationship between the sphenopalatine foramen and ethmoid crest is so variable. Middle turbinate with large posterior end and unintentional penetration of the posterior ethmoid sinuses also rendered this technique unfit for a precise nerve transection. With better understanding of vidian canal anatomy in the sphenoid sinus and encountering the difficulties in duplicating the retrograde approach, antegrade approach, (from intrasphenoid vidian canal to PPF), has been introduced recently in Taiwan.(Liu 2010) There are two common antegrade nerve resection fashions, which were developed by Su

and Wang in 2006. The vidian canal courses in the floor of the sphenoid sinus and may protrude into the sphenoid sinus, especially into the anterior part of a well-pneumatized sinus. If the prominence over the vidian canal in the floor of sphenoid sinus can be unroofed directly in the sinus cavity without resection of the sphenoid body or pterygoid process, this procedure is named type I transsphenoid approach. If the prominence over the vidian canal is absent or it is situated laterally and hampered by the pterygoid process, the vidian nerve management can be achieved via an additional removal of partial sphenoid wall and pterygoid process, and type II transsphenoid approach will be named. The type I maneuver has its advantages, such as less intraoperation bleeding, less risk of important vascular injury, shorter operating time and a minimized wound. But most patients are not good candidates for it, since this approach often failed due to the intrasphenoid septum, the embedded canal and an extreme lateralized position. Therefore, type II approaches are more widely used and usually serves as a rescue after a failure of attempted type I surgery. By using antegrade fashions, the precise intraoperative vidian nerve recognition is no longer a difficulty. However, not all patients with identified nerve can be definitely transacted and still a portion of those required using cauterization as a remedy. Again, the anatomy variances are crucial in determining the appropriate surgical approaches. The preoperative CT images are therefore vital tools for this purpose.

4. Endoscopic vidian neurectomy

4.1 Indications

VN of whatever form is not the first-line management of chronic rhinitis. The vast of majority of both rhinitis can be managed by conservative treatment.(Brozek et al. 2010) Therefore, no absolute indications exist for surgical intervention in chronic rhinitis. However, the surgery should be considered if the symptoms interfere with daytime function, adversely impact sleep or cause a decline in global or specific quality of life despite treatment with corticosteroids and anti-allergy medications. VN (destruction of the vidian nerve) is originally designed to treat patients suffering from VMR. It also has been advocated for the management of AR and nasal polyposis.(Nomura 1974) Recent clinical results show ideal postoperative symptom improvement in patients with allergic and non-allergic rhinitis both. This may be explained by the fact that the pathophysiology of the rhinitis is commonly overlapping between two or more of these classes. Once one of those is intervened, such as the vasomotor component, the threshold for a stimulant to cause symptoms might be elevated and lead to reduced symptoms. A unilateral nerve resection shows adequate symptom relief and this might also be the result of the elevated threshold. The reflex arc is broken by cutting the parasympathetic fibers on one side and the reduction of half the afferent supply leading to a bilateral effect. Some studies shows that the denervation will lead to a significant reduction of stromal edema and eosinophilic cellular infiltration, a reduction in mast cell levels and histamine concentrations and a reduction of the contents of the acini of mucosal glands.(Konno 2010) Because of this, there are also some authors advocating the use of VN for managing nasal polyposis. However, additional research is warranted in the possible role of VN for nasal polyposis and chronic rhinosinusitis.

A variety of headache and autonomic disturbances attributes to impulses transmitted by the vidian nerve have been relieved by its interruption. For example, cluster headache can be treated with lesions in the pterygopalatine ganglion.(Alvernia et al. 2007) Cluster headache

is characterized by a constant unilateral orbital localized pain that radiates into the forehead, temple, and cheek and is associated with ipsilateral autonomic phenomena such as a blocked nostril, rhinorrhea, injected conjunctivum, lacrimation, ptosis, miosis, forehead or facial sweating, lid edema, and a flush and edema of the cheek. Symptomatic cluster headaches have been reported in association with sellar (hypophyseal tumors) and parasellar (meningioma arteriovenous fistula or malformations) lesions, as well as internal carotid artery dissection. (Halker et al. 2010) They can have the similar causal mechanism of the cluster headache. The pathophysiology related to autonomic system imbalance has been proposed as following: 1) swelling of the internal carotid wall compromises the pericarotid sympathetic plexus and causes Horner syndrome, 2) the sympathoplegia may cause dilatation of the ophthalmic artery and lead to pain, and 3) paroxysmal parasympathetic discharge mediated through the greater petrosal nerve and pterygopalatine ganglion. (Francis et al. 2010) The vidian nerve conveys the autonomic fibers to the pterygopalatine ganglion, thus, the vidian nerve may have an important role in the autonomic dysfunction of the cluster headache and could be a target for the treatment. Lesions in the vidian canal can also cause autonomic disturbances. The majority of the branches of the pterygopalatine ganglion are maxillary division sensory fibers to the palate, nasal mucosa, pharynx, and orbit that pass through the ganglion without synapsing and enter the maxillary nerve through its ganglionic branches. Consequently, therapy targeting the ganglion can cause sensory disturbance in these areas.

Relative contraindications to endoscopic vidian neurectomy include absence of sphenoid pneumatization (conchal type) on radiographic examination or the presence of osteomyelitis of the sphenoid bone. Damage to the vidian nerve can lead to a loss of lacrimation with desiccation of the cornea and dry nose caused by damage to the parasympathetic fibers. This neurectomy does not prevent normal mucosal reaction to colds; however, it may reduce lacrimation as measured by Schirmer's test. Patients who have complained preoperatively of a lack of tears under emotional circumstances, associated eye discomfort and redness, should be considered as a relative contraindication. Most patients without preoperative eye dryness can be treated effectively by the use of tear substitutes when postoperative dry eye is encountered. Bilateral neurotrophic keratopathy with miosis and frontal headache has been a very rare occurrence after the VN. (Lin et al. 2001) Some of the side effects related to neural damage are thought to be attributable to the spread of current from electrocoagulation used to obliterate the branches of the maxillary artery near the vidian nerve. Therefore, thorough explanation and informed consent should be completed before any procedure.

4.2 Instrumentation

VN requires instrumentation that provides good visualization and precise nerve transection. As such, necessary endoscopic equipment includes a 0-, 30- or 70-degree telescope as well as bone-punching instruments. Cameras, monitors, and beam splitters may improve surgeon ergonomics and are important for teaching and documentation. Although the 0-degree is used to identify major landmarks (middle turbinate, anterior sphenoid wall), the angled telescopes allow broader visualization of the more lateralized vidian canal and enable a significantly more thorough surgical dissection.

A Freer elevator (Aesculap, Tuttlingen, Germany) is very suitable for lateralizing the middle turbinate and penetrating the anterior sphenoid sinus wall. A monopolar diathermy

or bipolar forceps (such as Stammberger bipolar suction forceps) with suction lumen is used to secure the intraoperation bleeding arising from injury of the pterygovaginal branch from internal maxillary in the inferiolateral aspect of the anterior wall of sphenoid sinus. Kerrison rongeur (Aesculp) instruments are necessary for anterior sphenoid wall removal. Suction elevators are also needed to elevate the mucoperiosteal soft tissue from the anterior surface of sphenoid sinus to the lateral part of pterygoid process. Chisel or osteotome with hammer has enhanced our ability to penetrate the thicker anterior wall of the sphenoid sinus. The embedded vidian canal is sometimes difficult to identify and removal of pterygoid process around the canal can be achieved by Kerrison punch, chisel or osteotome. A double-end probe with a suitably shaped ball tip can be helpful in isolating the vidian nerve from its canal.

Image guidance systems have also improved the accuracy of VN. Computer-assisted surgical navigation aids in intraoperative localization, particularly in cases with accompanied chronic rhinosinusitis in which the anatomy has been significantly altered. They are also helpful in resident teaching. However, in a well-trained hand, the image guidance systems may offer a little help and probably the most important role for computer-assisted surgery is in preoperative surgical planning.

4.3 Patient evaluation

Patient evaluation requires a thorough medical history. The onset, frequency, duration, and severity of the patient's rhinitis should be delineated. A list of previous medical treatments should be obtained to assess whether maximal medical therapy has been administered. The use of topical and systemic medications for the treatment of rhinitis remains the backbone of therapy. There are a variety of classes of medications that are used for the treatment of both AR and NAR. These medications are noted in Table 1. Antihistamines, leukotriene inhibitors, and systemic immunotherapy are available options used for patients with significant symptoms. Steroid preparations are effective for all forms of rhinitis, allergic and nonallergic. They are available both in systemic form for oral or parenteral use and as topical intranasal sprays. Corticosteroids work extremely well in reducing the symptoms of rhinitis when used systemically but are limited by the significant adverse event profile that accompanies systemic steroid use. Depot injections have also been used for many years but are not recommended for use under current guidelines for the management of AR. Oral corticosteroids can be used for short periods of time with significant symptoms. Topical corticosteroids have become the primary treatment and in many analyses have been shown to be more efficacious than antihistamines in the management of AR. Topical nasal corticosteroids have been shown to decrease neutrophil and eosinophil chemotaxis in the nose, as well as reducing intracellular edema. They reduce a variety of inflammatory mediators as well, including interleukin (IL)-6, IL-8, granulocyte-macrophage colony-stimulating factor (GM-CSF), and both IL-4 and IL-5.

Previous surgical attempts and postoperative management should be reviewed and documented. Comorbidities such as asthma, chronic rhinosinusitis, granulomatous diseases, and so forth must be identified. In addition, a detailed allergy history, both pharmacological and environmental, should be obtained as well as any therapeutic measures (i.e., immunotherapy) that have been attempted. A family history is also necessary to determine if a genetic predilection may exist. Finally, a social history is important to ascertain potential exposure to noxious substances either at home or in the workplace (i.e., tobacco, mold) that may influence surgical outcome.

Agent	Rhinorrhea	Congestion	Sneezing	Itching	Eye Symptoms
Oral antihistamines	++	-	++	++	++
Nasal antihistamines	+	-	+	+	-
Intranasal corticosteroid	++	+++	++	++	+
Leukotriene modifiers	+	+	+	+	+
Oral decongestants	-	++	-	-	-
Nasal decongestants	-	+++	-	-	-
Nasal mast-cell stabilizers	+	+	+	+	-
Topical anticholinergics	+++	-	-	-	-

+++ , marked benefit; ++, substantial benefit; +, some benefit; +/-, minimal benefit; -, no benefit.

Table 1. Pharmacological effects on symptoms of rhinitis:

The diagnosis of rhinitis involves not only an examination of the nose itself but a complete head and neck examination. Chronic serous otitis media is frequently seen in patients with AR. In addition, asthma is a frequent comorbidity and auscultation of the chest with normal and forced expiration may demonstrate wheezing, suggestive of asthma. The examination should begin with an inspection of the face. Signs of facial puffiness, edema, asymmetry, or discoloration should be noted. Conjunctival injection or erythema should be noted. Darkening of the skin under the eyes from venous stasis is a sign of nasal congestion and is seen commonly in patients with chronic rhinitis. In addition, allergic patients, especially children, often have fine creases in the upper eyelids called Dennie lines, caused by spasms of Mueller muscles. Second, both the external and internal anatomy should be examined. The external structure of the nose is examined for obvious deformity or asymmetry. A transverse crease at the superior border of the lower lateral cartilages is characteristic of the stigmata resulting from repeated rubbing of the itchy allergic nose. The anterior septum is inspected for deformity or deflections that compromise the airway. The size of the turbinates and their degree of impingement on the nasal airway are noted, as well as the reversibility of this hypertrophy with topical decongestants. The appearance of the mucosa and the nasal secretions should be characterized. Allergic mucosa is often edematous and congested and frequently has a boggy gray-to-blue appearance on examination. Erythematous, inflamed mucosa is often seen in the turbinates with rhinitis medicamentosa or in cigarette smokers. Although mucosal appearance can be suggestive of pathophysiology, it is not pathognomonic of any specific disease. Nasal secretions may be present or absent and if present may be described as serous, mucoid, or mucopurulent. Presence of septal excoriations or bloodstained mucus should be noted. Lymphoid islands, which form a raised, red, cobblestone appearance in the posterior pharyngeal wall or lateral raised vertical lymphoid bands behind the tonsillar pillars, are frequently seen in allergic patients. Adenoid hypertrophy is common in allergic children. Chronic nasal obstruction can contribute to dental malocclusion because of chronic mouth breathing.

Comprehensive diagnostic nasal endoscopy has become routine in patients with nasal and sinus complaints. The nasal endoscope allows visualization of the more posterior portions of the nasal cavity and nasopharynx that cannot be appreciated on anterior rhinoscopy alone. Both rigid and flexible fiberoptic endoscopes can be used for this purpose. It is evaluated in the office under topical anesthesia. One method is to systematically examine the sinonasal cavity using three passes with a rigid endoscope and deflected angle of view. The first pass is made along the floor of the nasal cavity proceeding posteriorly toward the nasopharynx. During this pass, the inferior turbinate, septum, nasopharynx, and eustachian tube orifice are all examined for mucosal changes and the presence of secretions. The endoscope may also be rolled under the inferior turbinate to visualize the inferior meatus and Hasner valve. The second pass is made between the inferior and middle turbinate, then courses medial to the middle turbinate into the sphenoidal recess. The superior septum, inferior aspect of the middle meatus, superior turbinate, and sphenoid sinus ostia should all be visualized with this pass. Finally, the third pass involves maneuvering the endoscope below the middle turbinate into the middle meatus to examine the lateral nasal wall and ostiomeatal complex. The ethmoid bulla, hiatus semilunaris, and uncinate process should all be examined with this pass. Not all structures may be visualized on endoscopy if narrowed anatomy is present.

If AR is suspected, specific testing for allergic sensitivities can be conducted both to confirm the diagnosis of AR and to aid in treatment planning. Both *in vivo* and *in vitro* methods are available for the testing of allergic sensitivities in adults and children. (Knipping et al. 2009) The most commonly used methods for allergic assessment involve one of several skin testing approaches. Skin testing can be either epicutaneous, as in prick testing, or can be percutaneous, as with intradermal testing. *In vitro* tests involve the use of laboratory studies to assess both the presence of allergic sensitivity and the specific antigens to which the patient is allergic. Simple screens for allergy include both the calculation of total eosinophilia and the level of total IgE in the serum. Although both of these studies can be useful when levels are markedly elevated, the interpretation of marginal elevations can be difficult and can be influenced by a variety of confounding factors. An additional method for testing allergic sensitivity among patients with rhinitis involves direct provocation of symptoms through introducing allergen directly into the nose. Observations have noted that results obtained through nasal challenge do not necessarily correlate directly with results noted on skin testing. There appear to be differential responses to nasal challenge with various antigens. The use of nasal provocation testing for the diagnosis of AR is not currently used for clinical practice but may offer promise as a technique for future use in the diagnosis of AR versus nonallergic rhinitis.

VN is performed only after aggressive attempts to eliminate symptoms with medical treatment have failed. The surgery is best considered an adjunct to medical therapy in the management of chronic rhinitis rather than being a primary treatment modality. Once the patient is deemed to have completed appropriate medical options and to be a surgical candidate, preoperative CT should be performed to evaluate the anatomy. Because dry eye is emphasized as a possible complication in the preoperative consent procedure it is important to preoperatively assess eye tearing with a Schirmer's test and compare this with the postoperative findings because this symptom may be overreported by patients. Anterior rhinomanometry with a face mask can be used to assess the change of nasal airflow and resistance in patients undergoing VN. However, the value of this exam need to be explored in future studies.

4.4 Preoperative computed tomography evaluation

CT images should be thinly sliced (3 mm or less) and directed in the coronal, sagittal and axial planes using a bony algorithm. Presurgical CT evaluation involves analysis of six specific anatomic areas to avoid possible complications during surgery. First, the sphenoid sinus should be analyzed throughout its length. The pattern of pneumatization and presence of intrasinus septum should be assessed. The degree of pneumatization of the sphenoid is the prime preoperative concern for type I antigrade VN approach. (Liu 2010) Type of sphenoid sinus pneumatization depends on the position of the sinus in relation to the sella turcica, and includes conchal, presellar, sellar, and postsellar type (Fig. 1). This is best seen in the sagittal slices. High-resolution CT scan may show pneumatization of the sphenoid sinuses as early as 2 years of age. Pneumatization progresses in an inferior and posterolateral direction. The pneumatized basisphenoid plate often extends to, but not past, the sphenoid-occipital synchondrosis in the mature sphenoid sinus. The sinus attains its mature size by the age of 14 years. The degree of pneumatization of the sphenoid sinus varies considerably. The sella turcica is seen as a prominence in the roof of a well-pneumatized sphenoid sinus and is known as the sellar bulge. This is considered one of the most important surgical landmarks to the sellar floor. In the previous study, the most common type of pneumatization of the sphenoid sinus is the sellar type (54.7%). The conchal pneumatization is the least frequent (2%), (Hamid et al. 2008) The conchal non-pneumatized sphenoid is considered to be a relative contraindication to the trans-sphenoid approach. It will make type I approach unavailable and type II approach less favourable. However, with the surgeon informed in advance, different tools can make such an approach feasible. The availability of intraoperative navigational devices can be used to confirm surgical landmarks, making it possible to access the vidian canal even in these poorly pneumatized cases. The operative time is, of course, longer. On the other hand, a highly pneumatized sphenoid sinus may distort the anatomic configuration and may attenuate the bone over the lateral wall, placing the optic nerve and carotid artery at greater risk. The postsellar pneumatization of the sphenoid and that of the dorsum sella may result in penetrating the posterior wall of the sphenoid, with resultant CSF leak. This can result from excessive dissection along the nasal floor, as the speculum will tend to slide downward, directing the surgeon to the posteriorly pneumatized recess. Therefore, type I approach should be performed carefully to avoid morbid consequences during surgery since it bears the risk of intracranial complications. There is usually an intra-sphenoid septum (Fig. 2). Presence of the septum between the canal and the natural ostium would block visualization and hinder surgery. This septum sometimes needs to be removed to access the vidian canal. Removal of the septum is usually time-consuming and may be associated with greater intraoperative bleeding and unintentional skull base penetration. The septum usually deviates to one side. Care should be taken in removing the lateral attachment of these septa, especially when the preoperative imaging showed that it ends on the carotid prominence. In 41 to 89% of patients the septum deviates quite laterally and terminates on the carotid artery. (Fernandez-Miranda et al. 2009) In this situation it is wise to use extreme caution while removing the terminal septum in order to prevent accidental and disastrous injury to the carotid artery. The terminal septa are usually inserted lateral to the sinus floor and may not require complete removal for adequate exposure.

Second, the pterygoid process should also be identified. The anterior opening of the vidian canal is positioned on the superomedial part of the anterior surface of the pterygoid process, at the level of the floor of the sphenoid sinus and inferomedial to the foramen rotundum.

The pterygoid process forms the posterior wall of the PPF. Through the sphenopalatine notch, which is bounded inferiorly by the upper part of the perpendicular plate of the palatine bone, the vidian nerve runs into the PPF. In the anterior opening of the vidian canal, it is located in the line of fusion between the pterygoid process and the body of the sphenoid bone. The gap between the pterygoid process of the sphenoid bone and the sphenoid process of the palatine bone (SPP) determines the feasibility of type II approach (Fig. 3). If the gap allows the passing through of a curved probe, the vidian nerve will be hooked out by the probe or sickle knife. If the gap is too narrow to allow this procedure, the pterygoid process or the SPP need to be partially removed and sometimes the canal opening is not easily accessible due to the severe obscuration of pterygoid process. An image guidance system may be necessary in this situation.

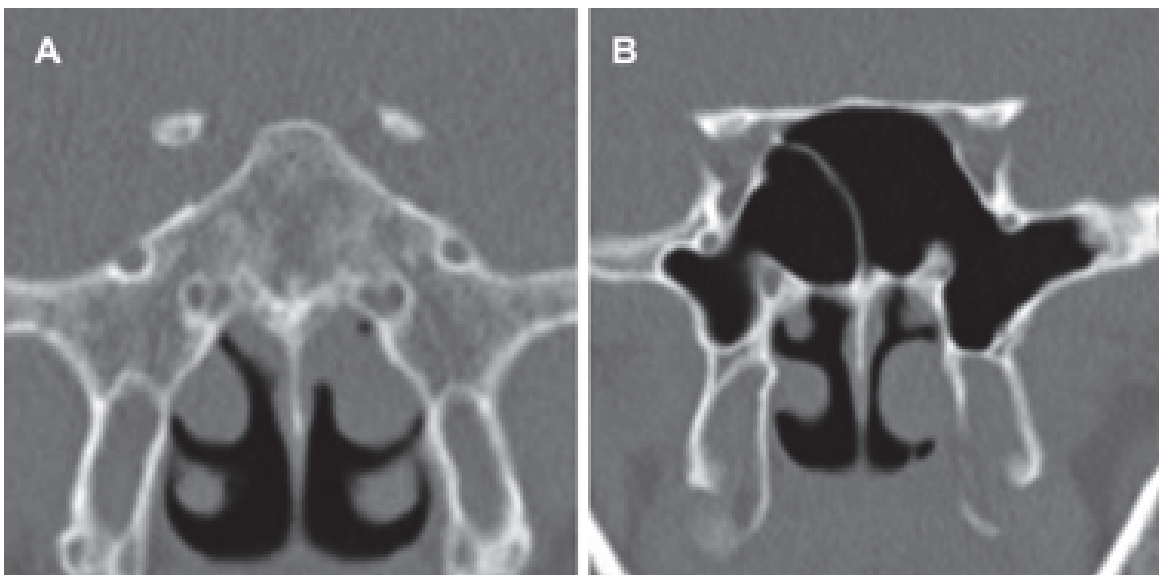


Fig. 1. Coronal CT slices showing the different type of sphenoid sinus pneumatization. A: conchal type. B: sellar type.

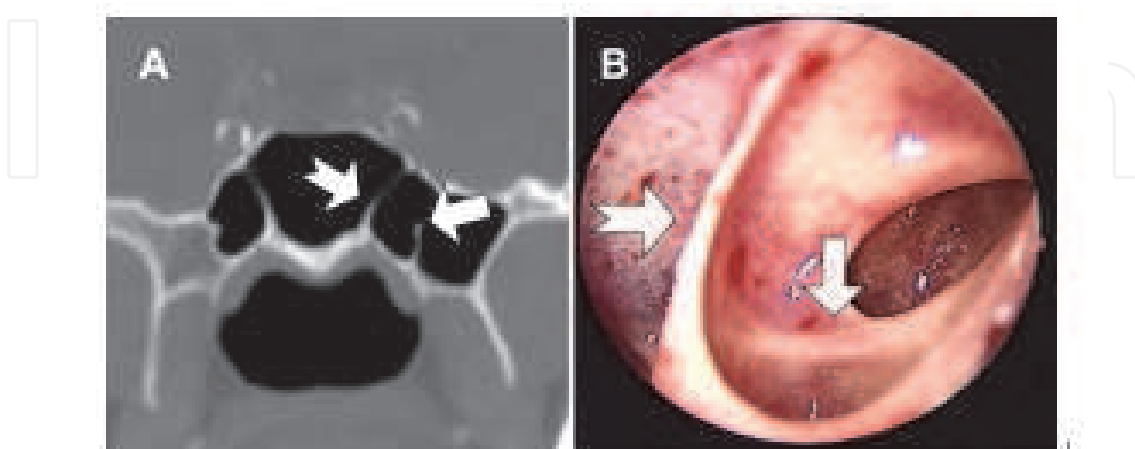


Fig. 2. The intra-sphenoid septum is demonstrated on A: Coronal CT slice; B: intraoperative endoscopic view. Arrows indicate vidian canal; the bifid tail arrow indicates the intra-sphenoid septum

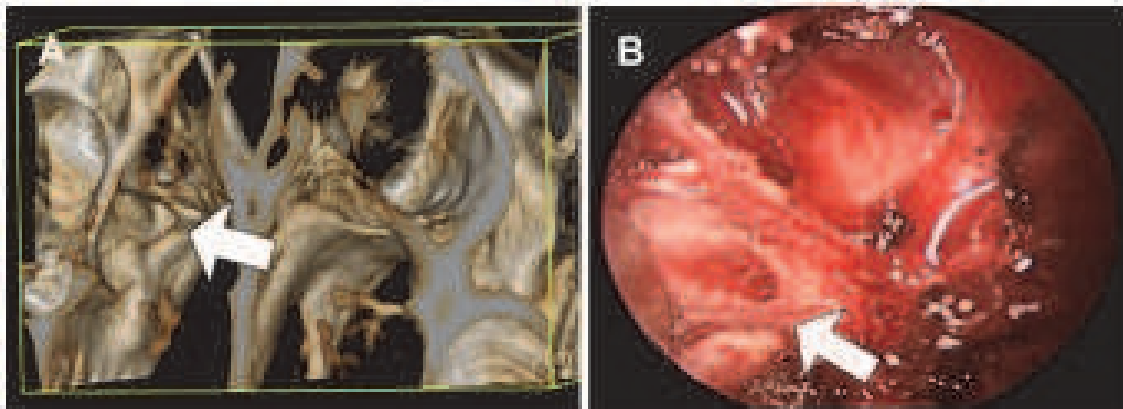


Fig. 3. The gap (arrow) between the sphenoid sinus anterior wall and the pterygoid process or the SPP is demonstrated on A: pre-operative 3D reconstruction CT image; B: intraoperative endoscopic view.

Third, the continuation of the vidian canal bony structure should be identified and its position relative to the sphenoid determined. The relationship between the canal and the sphenoid bone (canal corpus type) can be categorized as follows: (1) embedded inside the sphenoid corpus, (2) partially protruding, or (3) connected to the bone with a stalk inside the sinus. The relationship between the canal and the sphenoid sinus floor (canal floor type) is categorized as follows: (1) the floor is flat, and the canal is at the same level as the floor; (2) the floor is upsloping, and the canal is superior to it; (3) the floor is downsloping; or (4) the canal is inferior to it, and the floor is an inverted V shape (Fig. 4). (Liu 2010) Extrapolation to clinical application has been explored in our previous study. We have shown that it is impossible to precisely identify the vidian canal in the sphenoid sinus floor when it is embedded inside the sphenoid corpus. All patients with this anatomy (canal corpus type 1) should receive VN by type II approach. In patients with the remaining 2 canal corpus types, protrusion of the canal into the floor of the sphenoid sinus can aid in locating the vidian canal, but not all of these patients are candidates for the type I approach. The canal floor relationship influences the choice of surgical approach. The type I approach can be considered only in patients with a canal floor relationship type 1 or type 2. In patients with type 3 or type 4, visualization of the vidian canal and instrument blockage are observed in our study, limiting application of the transsphenoidal approach. In contrast, patients with dehiscence of the bony roof of the canal in the floor of the sphenoid sinus are good candidates for the type I approach. This anatomy is observed in 30.4% (207 of 682 canals) of CT images reviewed in our study and in 4.4% to 32% of canals in other radiologic investigations. In this situation, the nerve can be easily intra-sphenoid transected by a probe. Fourth, the relationship between the anterior opening of the vidian canal and the posterior part of middle turbinate need to be explored. The first step in performing endoscopic VN is to lateralize the prominent middle turbinate in order to access the anterior wall of the sphenoid sinus. Therefore, one of the key points in determining a successful operation is the relationship between the posterior end of the middle turbinate and the lateralization degree of the vidian canal. The anterior opening of the vidian canal is usually positioned at the superiolateral aspect of the posterior end of the middle turbinate. The included angle representing the relationship of those two anatomies can be measured from coronal and axial CT slices (Fig. 5). The results of our study establish the value in both successful and failed cases. (Liu 2011) We found a statistical significance that the greater angle led to a

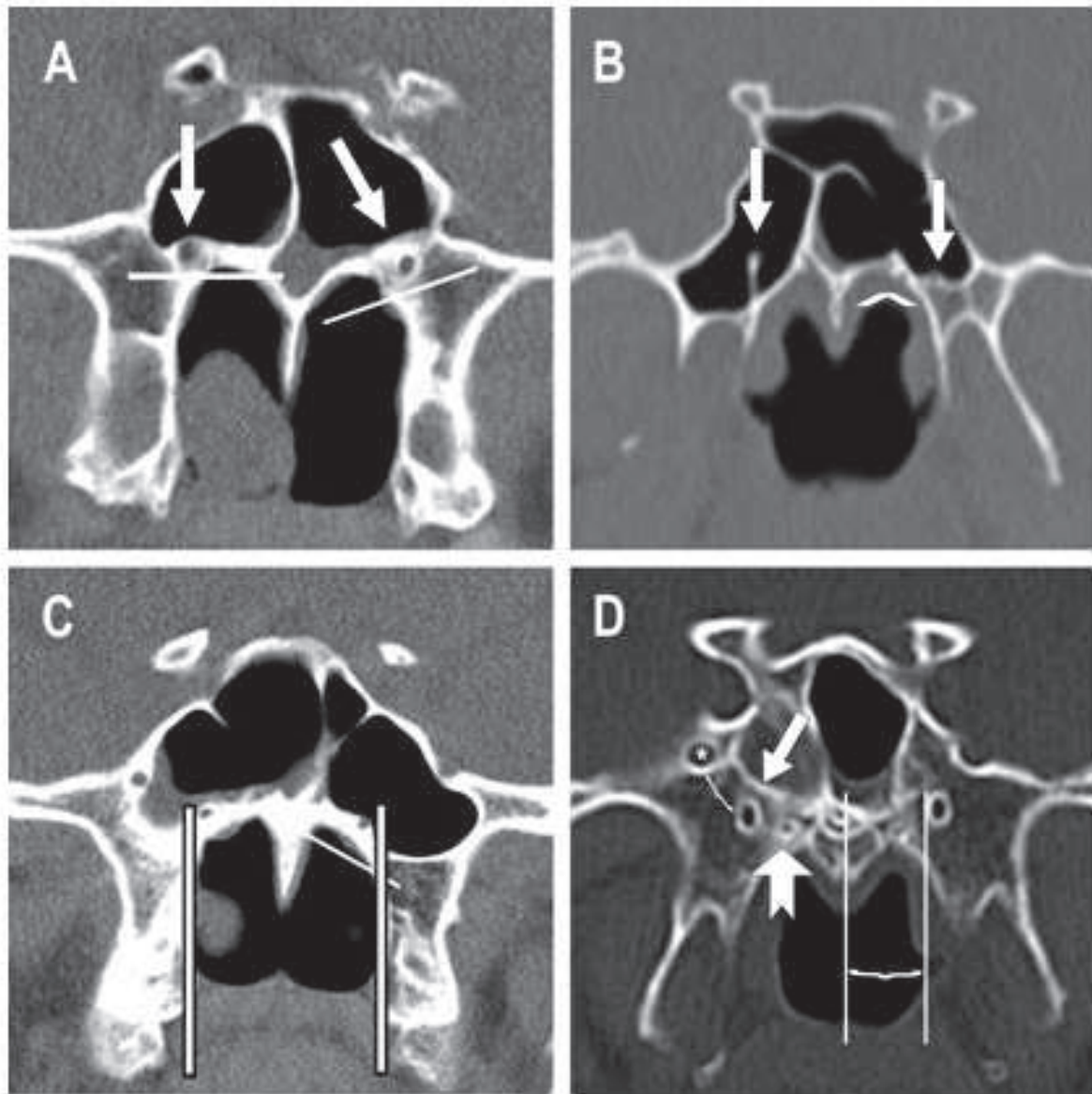


Fig. 4. Coronal computed tomography sections showing the vidian canal and its different positions. A, The vidian canal is embedded in the bone (left). Canal floor type 1 (right) and type 2 (left) are shown. B, Complete (right) and partial protrusion (left) into the sinus. Canal floor type 4 with canal wall dehiscence (left) is shown. C, The vidian canal is medially located close to the medial lamina of the pterygoid process (bilateral). Canal floor type 3 (left) is shown. D, Caliper measurement of the distance between the vidian canal and the vomerine crest (left) and between the vidian canal and the foramen rotundum (right; asterisk). Arrows indicate vidian canal; straight lines in A, C, and D and the caret in B indicate the canal-floor relationships. The bifid tail arrow in D indicates the palatovaginal canal.

higher failure rate. No negative angle value, which represented the anterior opening is medial to the middle turbinate, was recognized. In those difficult cases with a greater angle, a larger area of mucosal destruction and appropriate partial removal of pterygoid process is required. Doing so will bear the risk of brisk bleeding, resulting from injury of the SPA or its

major branches. Sometimes, the retrograde nerve resection fashion is employed to handle this situation. Since a unilateral vidian neurectomy already shows acceptable outcomes, choosing an easy-to-approach side is comprehensive. Therefore, the included angle should be assessed and the decision to intervene the surgical side with a smaller angle can be made.

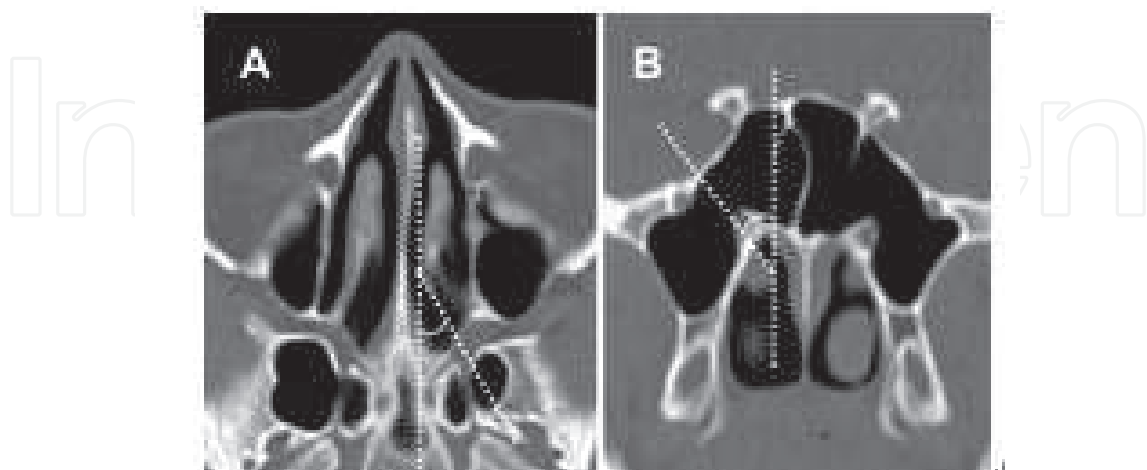


Fig. 5. The included angle between the posterior end of the middle turbinate and the most lateral part of the vidian canal anterior opening was measured (white dotted line). A. Axial view. B. Coronal view.

Fifth, the foramen rotundum on the lateral side and the palatovaginal canal on the medial side should be identified, to prevent it from being mistaken for the vidian canal. In our review of CT images from 341 patients, the foramen rotundum is located 1.7 to 15.5 mm superolateral to the vidian canal. The palatovaginal canal is recognized bilaterally in 37.0% (126 patients) and unilaterally in 19.4% (66 patients). Similar results are obtained by Rumboldt et al, with bilateral and unilateral incidence rates of 38% and 20.7%, respectively. (Rumboldt et al. 2002) The palatovaginal canal is located between the upper edge of the sphenoid process of the palatine bone and the vaginal process of the sphenoid bone, which projects medially from the upper end of the medial pterygoid plate (Fig. 6). This canal opens anteriorly through the posterior wall of the pterygopalatine fossa and transmits the minute pharyngeal branch that arises from the third part of the maxillary artery and the pharyngeal branch of the pterygopalatine ganglion to the pharyngeal orifice of the eustachian tube. Although mistaken transection of this nerve does not lead to any pronounced complication, nasal discomfort will persist, and the patient may require another procedure. Therefore, surgeons should keep this anatomic structure in mind when performing vidian neurectomy transnasally.

Finally, the nasal septum and turbinate should be reviewed. The presence of extreme septum deviation and the relative size of middle and inferior turbinate will effect the surgical feasibility. Choosing an easy side to approach is recommended and sometimes we may need to perform a combined septoplasty, inferior turbinate lateralization or partial inferior turbinectomy in order to access the vidian canal. Overall, preoperative CT images provide objective data for choosing a surgical approach. Interactive coronal, axial, and sagittal reconstructions of the sinuses assist the surgeon in understanding the anatomy in three dimensions. Optimally, the surgeon has a complete mental image of this anatomy prior to the surgical procedure

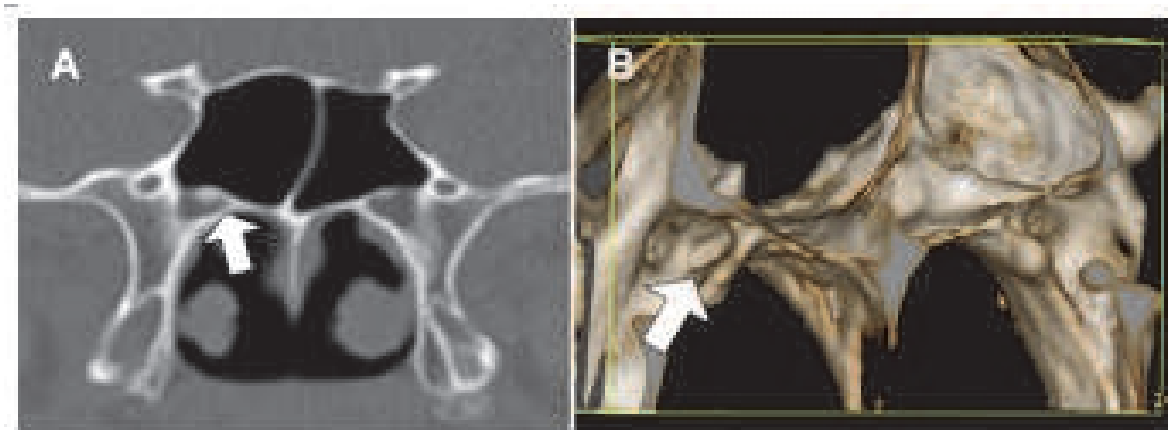


Fig. 6. The presence of palatovaginal canal (arrow) can be demonstrated on A: coronal CT slice and more clearly on B: 3D reconstruction image.

4.5 Anesthesia

VN are now all done under general anesthesia because as the surgery has been performed near the skull base and meticulous management is warranted. However, even with the administration of general anesthesia, topical vasoconstrictors and anesthetics are typically applied prior to surgery to minimize bleeding. It is advantageous to spray oxymetazoline into the nasal cavity 1 hour prior to the procedure. This allows for decongestion prior to introducing applicators or pledgets. A sphenopalatine block is performed transorally or transnasally to augment anesthesia and vasoconstriction as well as reduce bleeding. The transnasal route is usually selected when the nose is widely patent and the inferior part of the basal lamella can be visualized. It is carefully identified by passing the needle posteriorly and laterally through the horizontal part of the basal lamella. Intranasal injection of the nasal wall is performed under direct endoscopic vision into the superior attachment of the middle turbinate, medial surface of the middle turbinate and anterior wall of sphenoid sinus with 1% lidocaine with 1:100,000 epinephrine. As with topical anesthesia, these injections are performed one side at a time; the second side is not injected until surgery on the first side has been completed. Maintenance of an intraoperative heart rate under 60 beats per minute has been found to result in a clearer surgical field.

4.6 Technique

The keys to successful endoscopic VN are to minimize bleeding and how to precisely identify the vidian nerve via the interaction between the CT image guidance and nasal endoscopic visualization. It is particularly important not to traumatize the anterior part of the nose where the endoscope lens will rest or pass during the procedure. This requires using very gentle technique. Nasal mucosal stimulation has been demonstrated to cause vasodilatation and thus may cause bleeding, even at a site some distance from the primary site of stimulation. Additionally, the anterior part of the nose should be carefully suctioned from time to time during the procedure to ensure that the tip of the endoscope does not become contaminated with blood.

VN is begun with the patient placed in the semi-Fowler's position. Cottonoids soaked with diluted epinephrine (1:100 000) and cocaine, 10% (benzoylmethylecgonine), are positioned between the middle turbinate and the nasal septum to enlarge the space between them and to obtain decongestion of the nasal mucosa. The head of the middle turbinate is delicately

dislocated laterally to further widen the virtual space between the middle turbinate and the nasal septum. After an adequate space between the middle turbinate and the nasal septum is created, the endoscope is angled upward along the roof of the choana until it reaches the anterior wall of sphenoid sinus. An ostium is created on the anterior wall of sphenoid sinus using a freer, usually located approximately 1.0 cm above the roof of the choana and between the superior turbinate and the nasal septum. Coagulation of the mucosa around the created ostium and inferiolaterally the mucosa on pterygoid process is performed. This serves to avoid arterial bleeding originating from septal branches of the SPA and facilitates the subsequent ostium enlargement. Kerrison's punch is used to enlarge the ostium inferiolaterally in an attempt to enhance the visualization of intrasphenoid cavity. Care must be taken in the inferolateral direction, where the SPA or its major branches lie. To avoid these vessels, it is sufficient to cut away the nasal mucosa slightly in an inferolateral direction and to coagulate it with monopolar diathermy or bipolar forceps, completely exposing the sphenoid rostrum (Fig. 7). The sphenoid rostrum is removed in fragments. Once the anterior sphenoidotomy is completed, small amounts of bleeding originating from the edges of the sphenoidotomy must always be checked to avoid occluding the lens of the endoscope. A 30° or 70° endoscope is used to try to identify the vidian canal, usually at the sphenoid sinus floor. Transection of the nerve is performed using an angle probe when direct vision can be obtained (Fig. 8). Caution must be taken if an intrasinus septum is removed. The incidence of clinical dehiscence of the carotid artery has been demonstrated to be 23%. In addition, the presence of a sphenoid (Onodi) cell, a posterior ethmoid air cell that pneumatizes lateral and superior to the sphenoid sinus, places the optic nerve and occasionally the carotid artery at risk because of the nerve's intimate association with the lateral wall at the apex of the cell.

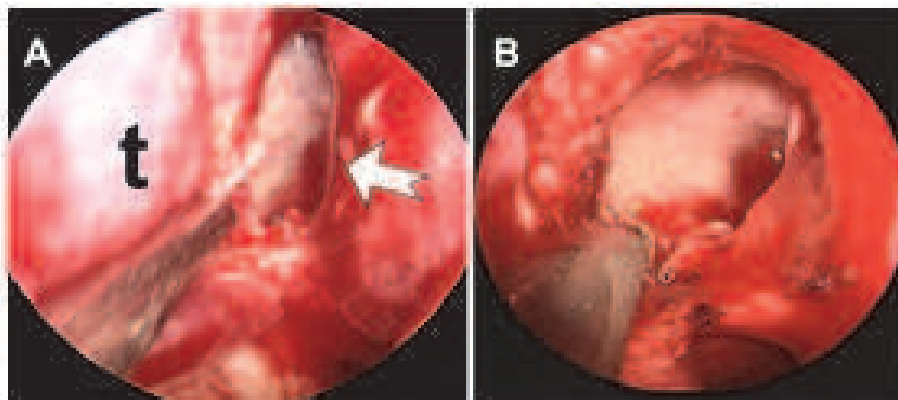


Fig. 7. Intraoperative endoscopic view: A: an ostium (bifid tail arrow) medial to the posterior end of middle turbinate (t) is created on the anterior wall of sphenoid sinus. B: monopolar diathermy is used before further dissection in the inferolateral direction to avoid brisk bleeding.

If there is no bony protrusion inside the sphenoid sinus floor as a visual guidance or the access to the vidian canal with or without protrusion is hampered by the pterygoid process, the approach is extended laterally by removing the pterygoid process around the vidian canal opening using a Kerrison's punch or chisel. The mucoperiosteal soft tissue can be elevated from the anterior surface of sphenoid sinus and then laterally the pterygoid process meticulously by a suction elevator, followed by the bone removal of sphenoid wall, or

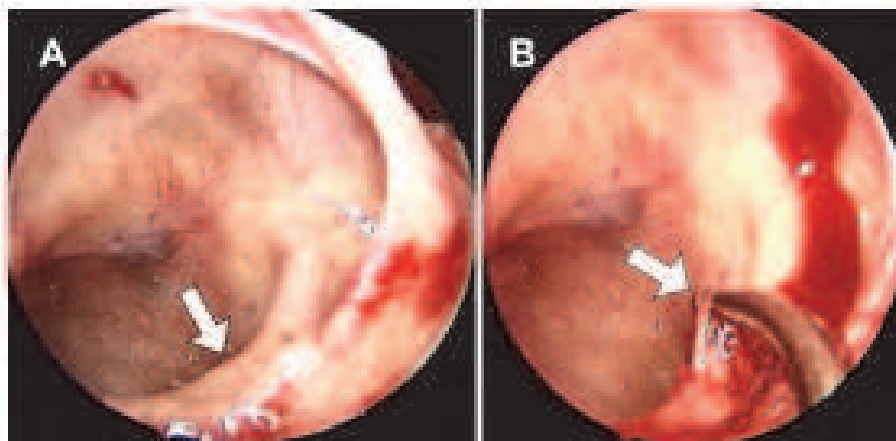


Fig. 8. Intraoperative endoscopic views of type I approach. A: The vidian canal (arrow) can be visualized at the floor of the sphenoid sinus. B: A probe is used to transect the nerve.

SPP. If the gap between sphenoid sinus wall and pterygoid process allows the passing through of a curved probe, the vidian nerve will be hooked out by the probe or sickle knife (Fig. 9). If the gap is too narrow to allow this procedure, the pterygoid process or the SPP will be partially removed by chisel or Kerrison's punch based on the anatomical variation to discover the anterior opening of the vidian canal. The nerve hooking by probe can be repeated under this better visualization of canal opening. The vidian nerve can be usually stretched out of the canal opening as long as 2 centimetres and even more. Resection (precise nerve cut) plus cauterization of the nerve ends will follow it. The precise nerve hooking may be occasionally unable to be achieved on account of unintentional cauterization of the nerve during the dissection procedure or an uncertain nerve break

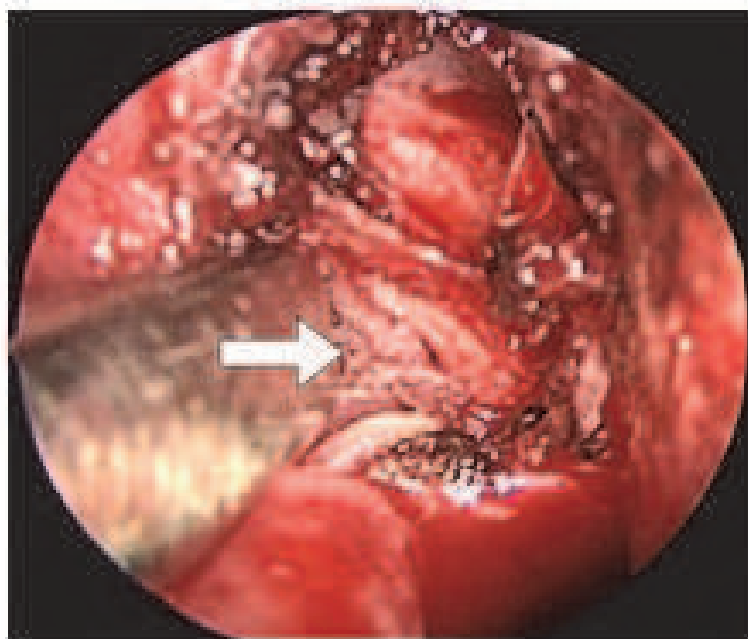


Fig. 9. Intraoperative endoscopic views of type II approach. The vidian canal (arrow) can be visualized at the gap between the anterior sphenoid sinus wall and SPP.

during nerve hooking procedure. Under this situation, the whole edge of the canal opening will be identified and the whole contents will be resected (semiprecise nerve cut). If the canal opening is not easily accessible or not fully exposed due to the severe obscuration of pterygoid process or SPP, a monopolar cauterization can be used to dysfunction the vidian nerve (cauterization) under visual guidance of vidian canal in the sphenoid sinus floor or image guidance of pterygoid process, sphenoid sinus floor, and even the sinus lateral wall. Concurrent endoscopic septoplasty or partial resection of the inferior turbinate may also be performed once endoscopic VN has been completed on the side opposite from the septal deviation. The incision is made on the wider side. Endoscopic surgery can then proceed on the narrower side after the septoplasty has been completed. The fragment of the nerve is removed whenever possible to avoid nerve regeneration leading to symptom recurrence. Pathologic examination confirms the nerve tissue will help in adding surgeon confidence. At the end of the procedure, hemostasis is obtained, and the middle turbinate is gently restored in a medial direction. Packing of the nasal cavity is not always necessary except in the event of diffuse intraoperative bleeding from the nasal mucosa or in patients with poorly controlled hypertension, in which case packing is usually removed on the second day. Most patients are discharged 2 days after surgery.

4.7 Postoperative care

Meticulous postoperative care is just as critical in producing a successful outcome as the surgery itself. Any sponges placed can be removed the day following surgery and the nose can be suctioned of blood clots. During the initial postoperative period, inflammation and edema is heightened and mucociliary clearance disrupted, thereby increasing the risk of scar formation and development of postoperative sinusitis.

Avoidance of the offending antigens can be very useful in decreasing the burden of exposure, leading to reduced symptoms and improved quality of life. Although avoidance of perennial antigens such as animal dander can be reasonably well accomplished, the avoidance of seasonal pollens and molds can be more challenging due to their widespread airborne distribution. Measures to reduce exposure to dust mite antigen in the home include the use of covers for mattresses and pillows. The use of high-efficiency filtration can also be useful. In more extreme cases the removal of carpeting and curtains can be of benefit. In the case of mold allergy, the home should be kept at a low humidity and any plant material should be removed from the home. In the case of animal allergy, animals should be eliminated from the home, although the clearance of animal dander from the home can take many months.

Continued medical therapy in the postoperative period is still beneficial. In our opinion, topical nasal steroids and antihistamines may be reinitiated in the early postoperative period.

4.8 Outcomes

Multiple retrospective studies have documented the efficacy of VN in treating chronic rhinitis using both subjective and objective outcomes measures. Surgical outcomes of VN are generally good. Published Success rates range from 50% to 90%, with significant improvements in both symptomatology and general health status. Robinson and Wormald performed 14 retrograde VN among 9 patients with vasomotor rhinitis.(Robinson and Wormald 2006) All patients had negative screening for allergies on their serum or on skin-prick tests. A mean follow-up of 25 months of surgical results was analyzed. A significant

improvement in the symptoms of rhinorrhea ($p = 0.018$) and nasal obstruction ($p = 0.011$) can be obtained by VAS score analysis. However, there was no significant difference between the pre- to post-operative symptoms for postnasal drip or sneezing. The most common minor adverse effect was dry eyes (35.7%) and nasal crusting (28.6%). One patient complained of a temporary mild numbness of the cheek/gums or palate after surgery. There were no changes to visual acuity after vidian neurectomy. Seven of the 14 (50%) vidian neurectomies were deemed to be successful by the patients. In terms of overall satisfaction, poor satisfaction was encountered in one patient (7.1%) and the rest 92.9% exhibit at least good satisfaction. There was one recurrence case with an initial improvement in their nasal symptoms, which returned to their preoperative state 6 months after the vidian neurectomy. Jang et al. had performed retrograde VN in 6 intractable rhinitis patients. (Jang et al. 2011) The nasal obstruction and rhinorrhea had the best improvement with significant lower postoperative VAS scores. However, although lower, changes of VAS scores in sneezing and itching were not statistically significant. All patients complained of mild dry eyes in the immediate postoperative period. The results of Schirmer's test performed immediately after surgery were significantly decreased compared to preoperative values (4.6 ± 2.2 mm vs. 14.5 ± 3.7 mm, $P < 0.01$). Complaints of mild dry eyes persisted for 1 month after vidian neurectomy, but after 2 months, 5 of 6 patients reported marked improvement of xerophthalmia. The amount of tears by the Schirmer's test was also increased. There were no serious complications, aside from mild crusting of the nasal cavity and mild postoperative pain, which all subsided within 2 weeks. During the follow up period, no patient needed additional treatment, such as antihistamines or corticosteroids. All 6 patients were satisfied with the results of the surgery, although 1 patient reported mild deterioration of symptoms compared to the immediate postoperative period. Improvements persisted for up to 7 years after the primary surgery can be achieved.

In our un-published data, a total of 317 patients who underwent 414 endoscopic vidian neurectomies were reviewed. The change of VAS scores were analyzed in 236 antegrade VN among 163 cases with the mean follow up of 23 months (range, 6-58 months). One hundred and twelve patients underwent unilateral VN and 51 underwent bilateral procedures. The VAS score shows significant improvement in respective item of allergic symptoms, including rhinorrhea, obstruction, sneezing, nasal itchiness, eye itchiness and post-nasal dripping (Fig. 10). The dry eye developed in 172 of 236 sides (72.88%). They felt restored in average of 23 days (from 7 to 60 days). Long term use of eye drop substitute (more than 6 months) was required in 6 sides (2.54%). Palatal numbness occurred in 7 of 236 sides (2.97%) and disappeared in average of 13 days (from one to 21 days). Six postoperative bleeding (2.54%) occurred and stopped spontaneously without any assistance of nasal packing. All except 3 patients felt satisfied with their improvement of symptoms. Three recurrences (1.27%) were detected within one year follow-up and one of them received a successful reoperation.

Seldom reports explore the precise nerve cut rate in retrograde VN. Even in Robinson and Wormald report, we can't see the definite case number that how many of them had precise nerve severance or just function block by cauterization. In our preliminary report with 106 antegrade VN among 67 patients, we found that type I VN was performed successfully in 42 sides (39.6%) while the type II approach achieved 85.8% (91 of 106 sides) operating success rate. The operating success rate largely depended on anatomy variance, which can be pre-operatively recognized by CT images. In type I surgery, the precise nerve cut rates corresponding to the CT canal-corporis type including type 1, 2 and 3 were 0%, 72.1% (31 of 43 sides) and 84.6% (11 of 13 sides), respectively. In view of the CT canal-floor relationship,

the operating success rates for the type I approach were 50% (28 of 56 sides), 51.9% (14 of 27 sides), 0% (0 of 9 sides) and 0% (0 of 14 sides) for type 1, 2, 3 and 4, respectively. Either the embedded canal or the type 3 or 4 canal-floor relationship would fail the type I approach. The presence of the septum made the type I approach more difficult and time-consuming. This anatomic variation failed the type I approach in 6 patients that were viewed as candidates preoperatively. On the other hand, patients with the dehiscence of the canal bony structure were viewed as good candidates for the type I approach. There were 15 canals with more lateral situated anatomy which failed the type II approach. Although the anterior opening of the canals could still be identified, the direct views of nerve transection were not achieved. Further emptying the canal followed by cauterization (semi-precise) was used as a remedy for the 15 canals. With experience growing up with 414 antegrade VN in our un-published data, the precise cut rate of vidian nerve reaches 70.53% and a 19.81% of the semiprecise cut rate can be achieved. Only 9.66% had their nerve function blocked by cauterization. We also found the relationship between the anterior opening of the vidian canal and the posterior end of the middle turbinate had a determining role in antegrade VN. The included angle between the two structures can be measured from CT imaging, both in axial and coronal slices. A more hypertrophied middle turbinate, which represents a larger angle, was associated with a significantly higher surgical failure rate. The findings support the decision to intervene the surgical side with a smaller angle. This result again emphasized the value of pre-operation CT images analysis. As for surgeon's handedness, there was no statistical significance can be observed.

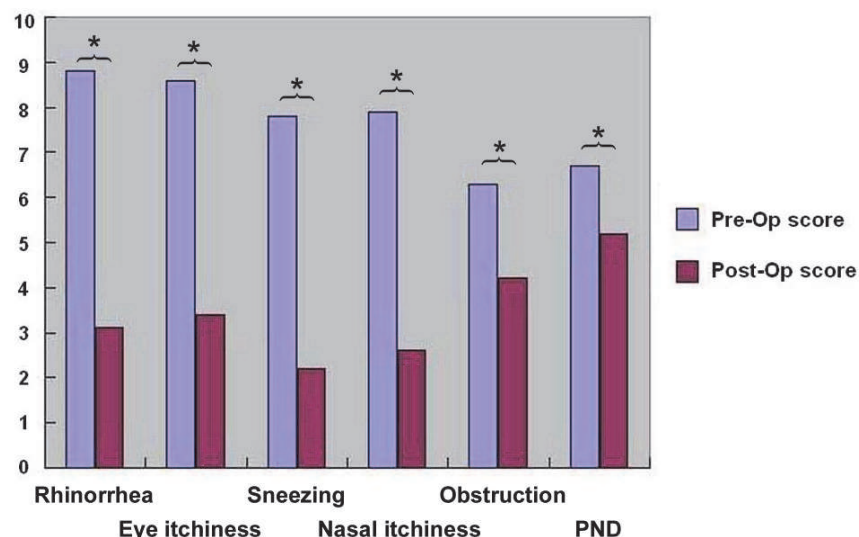


Fig. 10. Mean score for each symptom. *: significant difference. Test applied: paired t test, PND: Post-nasal dripping

The histological difference of the nasal mucosa before and after VN had been seldom discussed. Krajina compared the histological change in 16 VN cases and a very pronounced difference was found. (Krajina 1973) During the operation and 10 days after it, the nasal mucosa was examined. While the mucous membrane of the nose before cutting of the nerve showed very numerous mucous glands in the hyperactive state, after cutting the glands were decreasing in number and also contained some sympathetic branches from stage of normal and stabilized secretion. Moreover, eosinophils in the mucous sympathetic part which had its interruption in the membrane of the nose disappeared after VN. Therefore,

the author recommended VN in all cases refractory to all conservative treatment bases on this pathophysiological finding. Ogawa et al. had once employed ELISA to examine local production of cytokines in nasal lavage samples.(Ogawa et al. 2007) A comparison of the cytokine levels (IL-5, eotaxin, and normal T cell expressed and secreted proteins, RANTES) before and 6 month after denervation was performed. The mean levels of both IL-5 and eotaxin significantly decreased after surgery (from 1094.8 to 183.8 pg/mg protein, from 540.6 to 165.0 pg/mg protein, respectively), while the mean levels of RANTES did not (from 385.8 to 331.0 pg/mg protein). The inferior turbinate mucosa was checked and the number of inflammatory cells and nasal glands was markedly reduced in the lamina propria after surgery. Further, the superficial epithelial layer of the turbinate mucosa became covered with stratified columnar cells, and the number of secretory goblet cells decreased. Recent study conducted by Ikeda et al. demonstrated the denervation effect of nasal mucosa.(Ikeda et al. 2008) Morphological analysis of the inferior turbinate mucosa before and after nerve resection showed an apparent decrease in nasal gland acinar cells after surgery, but the vascular structure of the mucosa seemed to be unchanged. Morphometric analysis of the density of the nasal gland showed a significant reduction, whereas no significant change was recognized in the density of the vessels. These findings suggest that denervation results in a decrease in nasal secretion but does not affect the congestion of the nasal mucosa. The reduction in glandular cells may be explained by decreased secretion of the nerve growth factor or epidermal growth factor regulated by acetylcholine, a major neurotransmitter of parasympathetic systems. On the other hand, no change in vascular structures implies that the vascular proliferation cannot be regulated by neural interaction. The infiltration of inflammatory cells in the nasal mucosa was also observed before and after operation. A significant reduction in the number of infiltrating neutrophils, eosinophils, and lymphocytes was recognized. The reduction of inflammatory cells may be explained by inhibition of nerve activities via neurogenic inflammation. In both allergic and idiopathic rhinitis, pathophysiological features such as fluid secretion mediated by orothrodromic reflex involving efferent nerve predominantly parasympathetic and release of neurotransmitters and neuropeptides from the sensory neurons via antidromic reflex are characterized by interaction of nerve activities with inflammatory cells. This report support the VN did improve the symptom of rhinorrhea. However, other underlying mechanisms still need to be evaluated in further work.

5. Conclusion

AR and NAR are significant, burdensome disorders that affect a large number of adults and children around the world. Rhinitis is associated with several important comorbid conditions, including asthma, rhinosinusitis, and otitis media with effusion. The use of appropriate therapeutic options will improve the outcome of patients with both AR and NAR. Medical treatment remains the backbone in treating chronic rhinitis.

VN can have some adjuvant benefit in patients who showed poor response to medical approaches. However the availability of nerve resection is largely determined by a favourable anatomy. The course of the vidian canal may vary from person to person, and it may also vary from one side to the other side in the same person. Therefore, a careful preoperative planning is warrant. CT imaging can offer good delineation of it and its relationship with the neighboring structures. Surgeons dealing with disease in this area must be familiar with the classic imaging characterization before initiation.


The transsphenoid approach is a simple method to accomplish a vidian neurectomy, able to spare SPA ligation and even duplicable in an occasional endoscopist. However, the

recurrence of disease needs further investigation in the long term follow-up although the outcome is comparable with other reports in the 6 months follow-up. In view of anatomical variation, there is still no a completely satisfactory and consistent procedure to handle this entity. More powerful instrumentation is expected to facilitate this procedure.

6. References

- Alvernia, J. E.; Spomar, D. G.; Olivero, W. C. (2007). A computed tomography scan and anatomical cadaveric study of the pterygopalatine ganglion for use in Gamma Knife treatment of cluster headache. *J Neurosurg*, Vol.107, No.4, (October 2007), pp. 805-8, ISSN 0022-3085
- Bernstein, J. A. (2010). Allergic and mixed rhinitis: Epidemiology and natural history. *Allergy Asthma Proc*, Vol.31, No.5, (October 2010), pp. 365-9, ISSN 1539-6304
- Broide, D. H. (2010). Allergic rhinitis: Pathophysiology. *Allergy Asthma Proc*, Vol.31, No.5, (October 2010), pp. 370-4, ISSN 1539-6304
- Brozek, J. L.; Bousquet, J.; Baena-Cagnani, C. E.; Bonini, S.; Canonica, G. W.; Casale, T. B.; van Wijk, R. G.; Ohta, K.; Zuberbier, T.; Schunemann, H. J. (2010). Allergic Rhinitis and its Impact on Asthma (ARIA) guidelines: 2010 revision. *J Allergy Clin Immunol*, Vol.126, No.3, (September 2010), pp. 466-76, ISSN 1097-6825
- Chandra, R. (1969). Transpalatal approach for vidian neurectomy. *Arch Otolaryngol*, Vol.89, No.3, (March 1969), pp. 542-5, ISSN 0003-9977
- el Shazly, M. A. (1991). Endoscopic surgery of the vidian nerve. Preliminary report. *Ann Otol Rhinol Laryngol*, Vol.100, No.7, (July 1991), pp. 536-9, ISSN 0003-4894
- Fernandez-Miranda, J. C.; Prevedello, D. M.; Madhok, R.; Morera, V.; Barges-Coll, J.; Reineman, K.; Snyderman, C. H.; Gardner, P.; Carrau, R.; Kassam, A. B. (2009). Sphenoid septations and their relationship with internal carotid arteries: anatomical and radiological study. *Laryngoscope*, Vol.119, No.10, (October 2009), pp. 1893-6, ISSN 1531-4995
- Francis, G. J.; Becker, W. J.; Pringsheim, T. M. (2010). Acute and preventive pharmacologic treatment of cluster headache. *Neurology*, Vol.75, No.5, (August 2010), pp. 463-73, ISSN 1526-632X
- Golding-Wood, P. H. (1961). Observations on petrosal and vidian neurectomy in chronic vasomotor rhinitis. *J Laryngol Otol.*, Vol.75, (March 1961), pp. 232-47, ISSN 0022-2151
- Gregson, A. E. (1969). Relief of chronic epiphora by transantral vidian neurectomy. *Br J Ophthalmol*, Vol.53, No.12, (December 1969), pp. 858-9, ISSN 0007-1161
- Halker, R.; Vargas, B.; Dodick, D. W. (2010). Cluster headache: diagnosis and treatment. *Semin Neurol*, Vol.20, No.2, (April 2010), pp. 175-85, ISSN 1098-9021
- Hamid, O.; El Fiky, L.; Hassan, O.; Kotb, A.; El Fiky, S. (2008). Anatomic Variations of the Sphenoid Sinus and Their Impact on Trans-sphenoid Pituitary Surgery. *Skull Base*, Vol.18, No.1, (January 2008), pp. 9-15, ISSN 1531-5010
- Ikeda, K.; Yokoi, H.; Saito, T.; Kawano, K.; Yao, T.; Furukawa, M. (2008). Effect of resection of the posterior nasal nerve on functional and morphological changes in the inferior turbinate mucosa. *Acta Otolaryngol*, Vol.128, No.12, (July 2008), pp. 1337-41, ISSN 1651-2251
- Jang, T. Y.; Kim, Y. H.; Shin, S. H. (2011). Long-term effectiveness and safety of endoscopic vidian neurectomy for the treatment of intractable rhinitis. *Clin Exp Otorhinolaryngol*, Vol.3, No.4, (January 2011), pp. 212-6, ISSN 2005-0720
- Kamel, R. and S. Zaher (1991). Endoscopic transnasal vidian neurectomy. *Laryngoscope*, Vol.101, No.3, (March 1991), pp. 316-9, ISSN 1531-4995

- Knipping, S.; Holzhausen, H. J.; Riederer, A.; Schrom, T. (2009). Allergic and idiopathic rhinitis: an ultrastructural study. *Eur Arch Otorhinolaryngol*, Vol.266, No.8, (August 2009), pp. 1249-56, ISSN 1434-4726
- Konno, A. (2010). Historical, pathophysiological, and therapeutic aspects of vidian neurectomy. *Curr Allergy Asthma Rep*, Vol.10, No.2, (March 2010), pp. 105-12, ISSN 1534-6315
- Krajina, Z. (1973). Vidian neurectomy in vasomotor rhinitis. *Acta Otolaryngol*, Vol.76, No.5, (November 1973), pp. 366-71, ISSN 0001-6489
- Krajina, Z. (1989). Critical review of Vidian neurectomy. *Rhinology*, Vol.27, No.4, (December 1989), pp. 271-6, ISSN 0300-0729
- Lin, P. Y.; Cheng, C. Y.; Wu, C. C.; Yen, M. Y.; Wang, S. J.; Liao, K. K.; Lee, S. M. (2001). Bilateral neurotrophic keratopathy complicating Vidian neurectomy. *Am J Ophthalmol*, Vol.132, No.1, (July 2001), pp. 106-8, ISSN 0002-9394
- Liu, S. C. and W. F. Su (2011). Evaluation of the feasibility of the vidian neurectomy using computed tomography. *Eur Arch Otorhinolaryngol.*, Vol., No., (February 2011), pp. , ISSN 1434-4726
- Liu, S. C.; Wang, H. W.; Su, W. F. (2010). Endoscopic vidian neurectomy: the value of preoperative computed tomographic guidance. *Arch Otolaryngol Head Neck Surg*, Vol.136, No.6, (June 2010), pp. 595-602, ISSN 1538-361X
- Minnis, N. L. and A. W. Morrison (1971). Trans-septal approach for Vidian neurectomy. *J Laryngol Otol.*, Vol.85, No.3, (March 1971), pp. 255-60, ISSN 0022-2151
- Mora, F.; Cassano, M.; Mora, R.; Gallina, A. M.; Ciprandi, G. (2009). V.A.S. in the follow-up of turbinectomy. *Rhinology*, Vol.47, No.4, (December 2009), pp. 450-3, ISSN 0300-0729
- Nomura, Y. (1974). Vidian neurectomy-some technical remarks. *Laryngoscope*, Vol.84, No.4, (April 1974), pp. 578-85, ISSN 0023-852X
- Nomura, Y.; Terao, H.; Matsuura, T. (1971). Method in the vidian neurectomy. *Nippon Jibiinkoka Gakkai Kaiho*, Vol.74, No.2, (February 1971), pp. 504-5, ISSN 0030-6622
- Ogawa, T.; Takeno, S.; Ishino, T.; Hirakawa, K. (2007). Submucous turbinectomy combined with posterior nasal neurectomy in the management of severe allergic rhinitis: clinical outcomes and local cytokine changes. *Auris Nasus Larynx*, Vol.34, No.3, (September 2007), pp. 319-26, ISSN 0385-8146
- Osawa, S.; Rhoton, A. L., Jr.; Seker, A.; Shimizu, S.; Fujii, K.; Kassam, A. B. (2009). Microsurgical and endoscopic anatomy of the vidian canal. *Neurosurgery*, Vol.64, No.5 Suppl 2, (May 2009), pp. 385-411, discussion 411-2, ISSN 1524-4040
- Robinson, S. R. and P. J. Wormald (2006). Endoscopic vidian neurectomy. *Am J Rhinol*, Vol.20, No.2, (May 2006), pp. 197-202, ISSN 1050-6586
- Rumboldt, Z.; Castillo, M.; Smith, J. K. (2002). The palatovaginal canal: can it be identified on routine CT and MR imaging? *AJR Am J Roentgenol*, Vol.179, No.1, (July 2002), pp. 267-72, ISSN 0361-803X
- Salib, R. J.; Harries, P. G.; Nair, S. B.; Howarth, P. H. (2008). Mechanisms and mediators of nasal symptoms in non-allergic rhinitis. *Clin Exp Allergy*, Vol.38, No.3, (March 2008), pp. 393-404, ISSN 1365-2222
- Scadding, G. K.; Durham, S. R.; Mirakian, R.; Jones, N. S.; Leech, S. C.; Farooque, S.; Ryan, D.; Walker, S. M.; Clark, A. T.; Dixon, T. A.; Jolles, S. R.; Siddique, N.; Cullinan, P.; Howarth, P. H.; Nasser, S. M. (2008). BSACI guidelines for the management of allergic and non-allergic rhinitis. *Clin Exp Allergy*, Vol.38, No.1, (January 2008), pp. 19-42, ISSN 1365-2222
- van Rijswijk, J. B.; Blom, H. M.; Fokkens, W. J. (2005). Idiopathic rhinitis, the ongoing quest. *Allergy*, Vol.60, No.12, (December 2005), pp. 1471-81, ISSN 0105-4538



Computed Tomography - Clinical Applications

Edited by Dr. Luca Saba

ISBN 978-953-307-378-1

Hard cover, 342 pages

Publisher InTech

Published online 05, January, 2012

Published in print edition January, 2012

Computed Tomography (CT), and in particular multi-detector-row computed tomography (MDCT), is a powerful non-invasive imaging tool with a number of advantages over the others non-invasive imaging techniques. CT has evolved into an indispensable imaging method in clinical routine. It was the first method to non-invasively acquire images of the inside of the human body that were not biased by superimposition of distinct anatomical structures. The first generation of CT scanners developed in the 1970s and numerous innovations have improved the utility and application field of the CT, such as the introduction of helical systems that allowed the development of the "volumetric CT" concept. In this book we want to explore the applications of CT from medical imaging to other fields like physics, archeology and computer aided diagnosis. Recently interesting technical, anthropomorphic, forensic and archeological as well as paleontological applications of computed tomography have been developed. These applications further strengthen the method as a generic diagnostic tool for non-destructive material testing and three-dimensional visualization beyond its medical use.

How to reference

In order to correctly reference this scholarly work, feel free to copy and paste the following:

Wan-Fu Su, Shao-Cheng Liu and Hsing-Won Wang (2012). Endoscopic Vidian Neurectomy: The Anatomy Consideration and Preoperative Images Analysis, *Computed Tomography - Clinical Applications*, Dr. Luca Saba (Ed.), ISBN: 978-953-307-378-1, InTech, Available from: <http://www.intechopen.com/books/computed-tomography-clinical-applications/endoscopic-vidian-neurectomy-the-anatomy-consideration-and-preoperative-images-analysis>

INTECH
open science | open minds

InTech Europe

University Campus STeP Ri
Slavka Krautzeka 83/A
51000 Rijeka, Croatia
Phone: +385 (51) 770 447
Fax: +385 (51) 686 166
www.intechopen.com

InTech China

Unit 405, Office Block, Hotel Equatorial Shanghai
No.65, Yan An Road (West), Shanghai, 200040, China
中国上海市延安西路65号上海国际贵都大饭店办公楼405单元
Phone: +86-21-62489820
Fax: +86-21-62489821

© 2012 The Author(s). Licensee IntechOpen. This is an open access article distributed under the terms of the [Creative Commons Attribution 3.0 License](#), which permits unrestricted use, distribution, and reproduction in any medium, provided the original work is properly cited.

IntechOpen

IntechOpen