

We are IntechOpen, the world's leading publisher of Open Access books Built by scientists, for scientists

4,800

Open access books available

122,000

International authors and editors

135M

Downloads

Our authors are among the

154

Countries delivered to

TOP 1%

most cited scientists

12.2%

Contributors from top 500 universities



WEB OF SCIENCE™

Selection of our books indexed in the Book Citation Index
in Web of Science™ Core Collection (BKCI)

Interested in publishing with us?
Contact book.department@intechopen.com

Numbers displayed above are based on latest data collected.
For more information visit www.intechopen.com



Treatment of Colorectal Stricture After Circular Stapling Anastomoses

S. Shimada¹, M. Kuramoto¹, A. Matsuo¹, S. Ikeshima¹,
H. Kuhara¹, K. Eto¹ and H. Baba²

¹Department of Surgery, Yatsushiro Social Insurance General Hospital,

²Department of Gastroenterological Surgery, Graduate School of Medical Sciences,

Kumamoto University

Japan

1. Introduction

Performing an end-to-end low rectal anastomosis with the linear single stapling technique was first reported in 1979 (Ravitch & Steichen, 1979). An improved circular stapling technique for anterior resection of the rectum, i.e. double stapling technique, overcoming the problems of insertion of the purse-string on the rectum stump and of disparity in size between the rectum and colon was introduced (Knight & Griffen, 1980). Although conventional double stapling technique is mainly performed for tumors greater than 6 cm from the anal verge (Shrikhande et al., 2007), recent prospective case series have described a variation of double stapling technique for ultra-low anterior resection involving vertical transaction of the rectum followed by an anastomosis with a circular stapler which results in a vertically oriented elliptical anastomotic orifice (Sato et al., 2007). Thus, circular stapling anastomosis of the rectum has been widely used and has been regarded as a safe and quick technique, however, the development of anastomotic strictures is the major post-operative complication of this procedure. (Blamey & Lee, 1982; Cade et al., 1981; Fain et al., 1975; Kumar et al., 2011; Kyzer & Gordon, 1992; Leff et al., 1982; Luchtefeld et al., 1989; Marchena et al., 1997; Smith, 1981; Vezeridis et al., 1982). It has been reported that the circular stapled anastomosis has a higher stricture rate than a handsewn anastomosis in the colon (Brennan et al., 1982; Dziki et al., 1991; MacRae & McLeod, 1998; Polglase et al., 1981) and that the incidence of the stricture after the double stapling technique varies from 0 to 30% (Blamey & Lee, 1982; Cade et al., 1981; Gordon & Vasilevsky, 1984; Kumar et al., 2011; Kyzer & Gordon, 1992; Luchtefeld et al., 1989; Marchena et al., 1997; Smith, 1981).

The complication of anastomotic stricture associated with stapling is harmful and distressing for patients with anterior resection of the rectum. Dilation is the only treatment and is variously used with techniques such as digital, a sigmoidoscope, an esophageal dilator, or balloon dilators. (Cade et al., 1981; Leff et al., 1982; Luchtefeld et al., 1989; Moran et al., 1992; Smith, 1981; Verma et al., 1990; Vezeridis et al., 1982; Whitworth et al., 1988). These techniques, however, have their drawbacks, that is, digital or sigmoidoscopic dilation has insufficient effects, and esophageal and balloon dilators need fluoroscopy and other optional equipments, and recurrence is common. Dilators can dilate the deformed and

shrunk staple line caused by the thickened circumferential scar formation but hardly split the closed staple line, resulting in reverting to the shape before dilation followed by a re-stricture. Thus, a new device of "staple cutter (STENO-CUTTER™)" was developed to split the circular staple line in the stricture (Shimada et al., 1996).

In the present manuscript, incidence and factors of the stricture, development of this new device of STENO-CUTTER™ for the treatment of the stricture, and the clinical effects and advantages is reviewed. In addition, application of STENO-CUTTER™ for the treatment of intractable stricture caused by anastomotic leakage as well as anastomotic ischemia is described.

2. Incidence and risk factors of stricture after circular stapling anastomoses

With the advance of surgical techniques and the circular staple device, the incidence of leakage of coloproctostomy has been significantly decreasing. On the other hand, the development of anastomotic stricture has become a major post-operative complication (Brower & Freeman, 1984; Knight & Giffen, 1980; Kozarek, 1986; Kumar et al., 2011; Kyzer & Gordon, 1992; Luchtefeld et al., 1989; Marchena et al., 1997). A meta-analysis of 13 randomized controlled trials showed increased stricture rates following stapled anastomosis compared to hand-sewn (MacRae et al., 1998). A previous review of 10 series has reported 6% incidence of strictures with stapled anastomosis (Waxmann et al., 1983). They also noticed a reduced stricture rate with Russian staples, which deliver a single row of staples, compared to the new generation staples, which deliver two rows of staples (Kyzer & Gordon, 1992). In recent series (Kumar et al., 2011), 22.9% developed strictures after stapled anastomosis, which is higher than the 13.3% developed after hand-sewn anastomosis; however, it was not statistically significant.

In our previous study (Shimada et al., 1996), thirty patients with the double stapling coloproctoanastomosis were followed up for six to 24 months in detail and the stricture rate was 30%, suggesting high frequent postoperative complication after coloproctostomotic anastomosis by using the double stapling technique. The rectal stricture was defined as the inability to pass a 12.3 mm sigmoidoscope (CF-P 20S, OLYMPUS, Tokyo, Japan) through the stenosis. All the patients with stricture had the symptom of frequent bowel movement (Table 1). Among the non-stricture group, temporary frequent defecation was observed in 10 cases (47 %).

Patient No.	Sex	Age	Stage (Dukes)	Resected artery	EEA size (mm)	Distance* (cm)	Cutting** (week)	No. of defecation		Therapeutic success	Repeated cutting	Follow-up (month)
								pre-cut	post-cut			
1	F	61	A	SRA	31	4	14	11	3	yes	0	24
2	M	70	B	IMA	31	5	7	12	11	no	0	23
3	F	69	C	IMA	31	4	9	13	4	yes	0	18
4	M	50	B	IMA	31	5	7	14	3	yes	1	15
5	F	53	B	IMA	31	4	6	14	5	yes	0	12
6	F	40	A	SRA	31	4	6	16	4	yes	0	10
7	F	68	B	IMA	31	8	3	12	4	yes	0	10
8	M	73	A	SRA	28	5	14	13	4	yes	1	9
9	M	72	A	SRA	31	6	3	12	5	yes	0	6

* distance from anal verge
 ** post operative weeks of staple cutting
 SRA = superior rectal artery; IMA = inferior mesenteric artery; EEA = end-to-end anastomosis stapler.

Table 1. Summary of nine patients with colorectal stricture (Shimada et al., 1996)

It is generally accepted that anastomotic leak results in the high stricture rate, because a leak predispose the patient to intense inflammation and scarring. Regarding risk factors for stricture without postoperative leakage, it has been reported that 103 patients with stapled anastomosis had a 4% stricture rate, and the strictures were more common when a 28 mm diameter stapler was used as compared to one of 31 mm (Miller & Moritz, 1996). In our study (Shimada et al., 1996), however, compared with non-stricture group, there were no significant relationships of sex, age, tumor stage, EEA size, distance of anastomosis from the anal verge, or timing of postoperative diet in the stricture group (Table 2). For one instance of evaluation of blood supply to the anastomosis (Orsay et al., 1995), we compared the incidence of stenosis between devascularization and preservation of the inferior mesenteric artery. However there was no relationship between them.

	stricture (n=9)	non-stricture (n=21)
Sex		
Male	4	11
Female	5	10
Age	60.5±11.7	64.0±6.8
Tumor stage		
Dukes A	4	8
B	4	6
C	1	7
Devascularization		
IMA	5	16
SRA	4	5
EEA size		
31 mm	8	20
28 mm	1	1
Distance from anal verge	4.8±1.3	5.0±0.9
Timing of diet	9.8±2.1	10.8±4.7
Follow up month	15.1±6.0	14.8±5.5

Table 2. Comparison of clinical factors between stricture and non stricture group (Shimada et al., 1996)

3. Development of new device of STENO-CUTTER™ for treatment of the anastomotic stricture

We experienced a case who had been suffering from frequent defecation (more than 10 times a day) for 3 months due to the circular stapling anastomotic stricture after coloproctostomy and was dramatically relieved from the stricture and its symptom after natural loss of the part of the staple ring, and no further recurrence of stricture has been observed. Through this case, we hit on the idea that staple cutting followed by digital dilation might be effective on the anastomotic stenosis caused by a circular stapler. We surmised that the circular stapling anastomoses may have different mechanisms in the formation of stricture from those of handsewn anastomoses. Thus, a new device of "STENO-CUTTER™ (Heiwa Medical Appliance, Yamaguchi, Japan)" was developed to split the circular staple line in the stricture (Shimada et al., 1996). As shown in Fig.1, the staple cutter is so simple and consists of two 5 mm sharp edges and a handle. There are two types of

STENO-CUTTER™ which differ on the total length, i.e., 26.5 cm (STENO-CUTTER-short™) and 30.5 cm (STENO-CUTTER-long™) for treatment of anastomotic stricture due to low and high anterior resection, respectively. The head was made as small as possible to pass the anastomotic stenosis (8 mm wide).

Staple cutting was performed on patients with the stricture of coloproctostomy or colectostomy with the STENO-CUTTER-short™ or STENO-CUTTER-long™, and dilated digitally or sigmoidoscopically, respectively, at the bedside mainly at the outpatient clinic. Using an anoscope (20 mm in diameter, 90 mm in length) (Fig. 1A) or rectoscope (20 mm in diameter, 190 mm in length) (Fig. 1B) with electric light, two feasible sites (usually opposite sites) of the stricture were cut with the staple cutter under direct vision, as shown in Fig. 2.

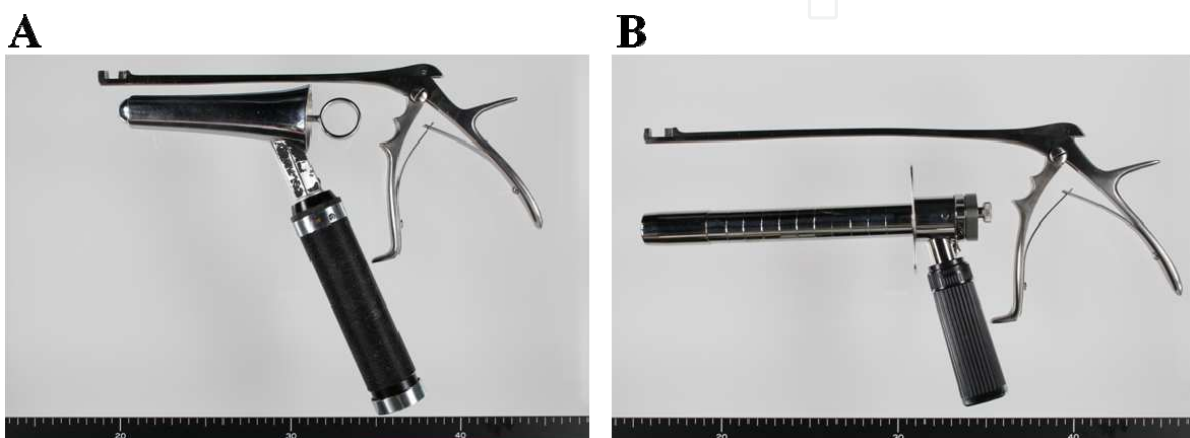


Fig. 1. A new device of "STENO-CUTTER™" (the top of Fig.s) was developed for the treatment of colorectal stenoses after the circular stapling anastomoses by us. The cutter is so simple and consists of two 5 mm sharp edges and a handle. There are two types of STENO-CUTTER™ which differ on the total length, i.e., 26.5 cm (STENO-CUTTER-short™) (A) and 30.5 cm (STENO-CUTTER-long™) (B) for treatment of anastomotic stricture due to low and high anterior resection, assisted by the conventional anoscope (A) and rectoscope (B), respectively. The head was made as small as possible to pass the anastomotic stenosis (8 mm wide).

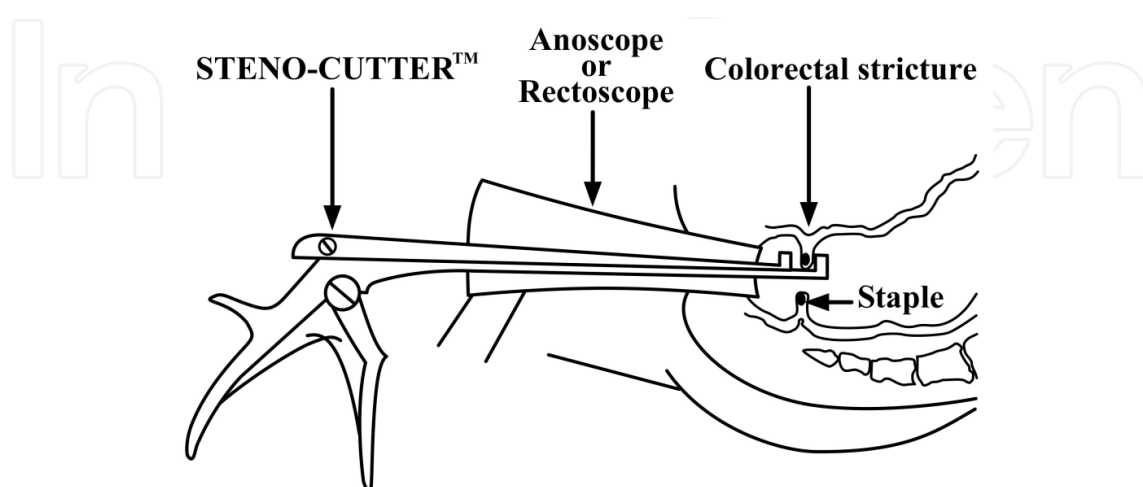


Fig. 2. Presentation of a staple cutting technique by STENO-CUTTER™. The two sites of a colorectal stricture are cut using the assisted by a conventional anoscope or rectoscope.

Successively, complete staple cutting was examined and dilation was performed digitally or sigmoidoscopically. The complete staple cutting made dilatation of the stricture digitally or sigmoidoscopically very easy. After the treatment of staple cutting and digital or sigmoidoscopic dilation, the stricture less than 12.3 mm in diameter expanded more than 20 mm compared with the diameter of an anoscope or sigmoidoscopy (Fig. 3). No perforation nor significant bleeding during and/or after the treatment was observed. The first trial was done at 100 post-operative days for fear of causing perforation. However, as each subsequent treatment with staple cutting proved so successful, the post-operative treatment period become more shortened, with the shortest one being done at 23 post-operative days.

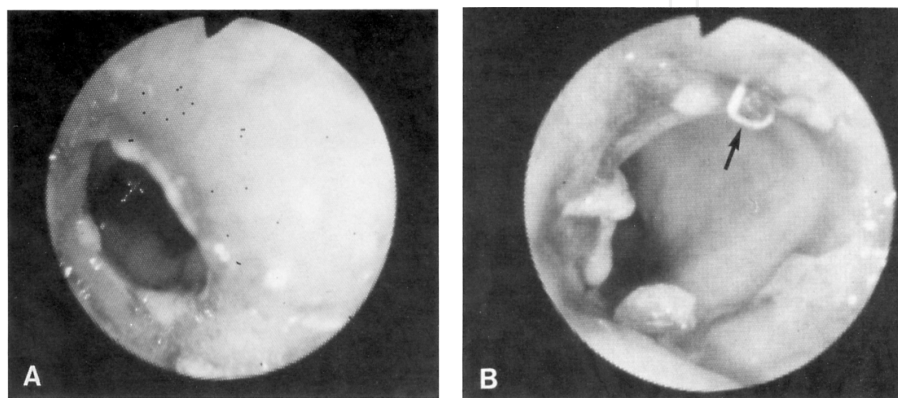


Fig. 3. Endoscopic evaluation of the effect of staple cutting before (A) and after (B) cutting (Shimada et al., 1996). Just two staple cuttings enabled us to dilate easily the stricture to more than 20 mm in diameter compared with anoscope or rectoscope width. The exposed staple (arrow) indicates complete cutting of the staple line.

4. Clinical effects and advantages of the STENO-CUTTER™

Thirty patients with adenocarcinoma of the rectum underwent low anterior resection and low colorectal anastomosis by a double stapling technique using TLH-60 (Johnson & Johnson Co., Ethicon, Cincinnati, OH) and PCEEA (United States Surgical Corporation, Norwalk, CT), and were followed up at least twice a month for more than five years (Shimada et al., 1996). We had no clinically evident anastomotic leaks and no intra-abdominal abscess. There were no significant complications related to surgical techniques. The patients were divided into two groups, stricture and non-stricture group. The rectal stricture was defined as the inability to pass a 12.3 mm sigmoidoscope through the stenosis.

Nine out of 30 patients (30 %) had anastomotic stricture with the symptom of distressing frequent bowel movement (Table 1). There was no significant relationship between the clinical factors and the stricture when compared with those of non-stricture patients. Excellent dilation was performed in all of the 9 strictures using the STENO-CUTTER-short™ and the symptom of stricture disappeared dramatically in eight cases (89 %) within one week (Fig. 4). The recurrence of stricture occurred in 2 patients, however it has not been observed after one further use of this treatment. The treatment using STENO-CUTTER-short™ is safe and easy to use even at the bedside, and except for a conventional anoscope or rectoscope no special equipment including fluoroscope was needed.

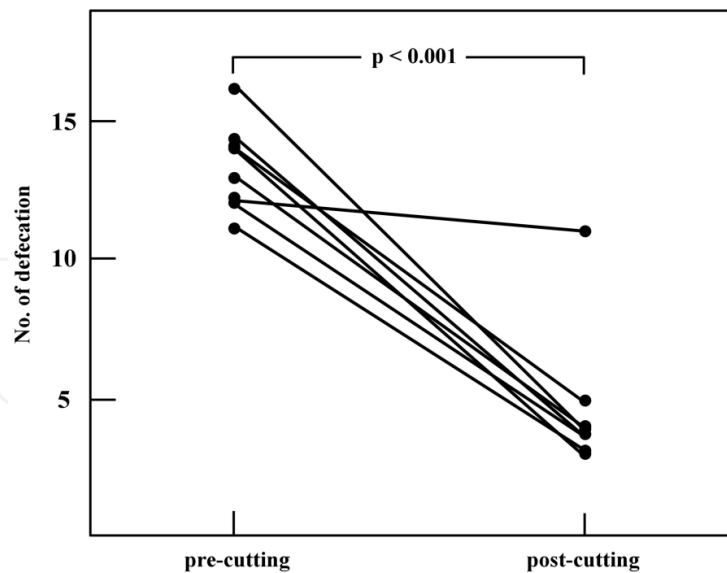


Fig. 4. Clinical effect of the staple cutting (Shimada et al., 1996). The symptom of frequent defecation decreased significantly after the treatment ($p < 0.001$).

In addition, five cases of anastomotic stricture after high anterior resection reconstructed by double stapling technique were treated using STENO-CUTTER-long™ combined with conventional rectoscope (Fig. 1B). Excellent dilation was also performed in all of the 5 strictures and the symptom of stricture disappeared dramatically in all cases within one week. The recurrence of stricture did not occur in all patients. The treatment using STENO-CUTTER-long™ is also safe to use.

5. Application of STENO-CUTTER™ for the treatment of intractable stricture caused by anastomotic leakage

Leakage of colo-rectal anastomosis after low anterior resection reconstructed by a double stapling technique is a relatively rare complication. The incidence of the leakage when using this technique has been reported as from 1.0% to 12.5% (Averbach et al., 1996; Boccola et al., 2010; DuBrow et al., 1995; Griffen et al., 1990; Kumar et al., 2011; Laxamana et al., 1995; Schlegel et al., 2001; Vignali et al., 1997). Once, however, it occurs, granulation tissue followed by firm fibrosis surrounding the anastomosis contributes the formation of severe and long narrowing of the anastomosis. Accordingly, this type of stricture is usually resistant to conventional treatment, resulted in surgical reoperation or the need for permanent stoma (Bailey et al., 2003; Köhler et al., 2000; Ohman & Svenberg, 1983). Recent advances in fluoroscopic and endoscopic modalities enable us to perform an effective, relatively safe, and less invasive treatment such as fluoroscopically guided bougienage, balloon dilation or endoscopic modalities for these patients who experience acute, recurrent, or chronic stricture of the alimentary tract (Garcea et al., 2003; Johansson, 1996; Kozarek, 1986; Lange & Shaffer, 1991; Oz & Forde, 1990; Werre et al., 2000). Good clinical results have been obtained in the simple gastrointestinal anastomotic strictures. These techniques, however, are less helpful for patients with long irregular stricture associated with anastomotic disruption or ischemic injury (Garcea et al., 2003). It is reported that up to 28% of patients have a severe stenosis that can not be cured with these current dilators and require surgical correction with laparotomy (Schlegel et al., 2001).

STENO-CUTTER-short™ was applied in order to evaluate the clinical effects for the treatment of severe rectal stricture associated with anastomotic leakage (Shimada et al., 2007). The details of the cutting procedure using the staple cutter for patients with short strictures have been described as above. Generally, the stricture cutting was performed on patients in lateral position without anesthesia at the bedside mainly at the outpatient clinic. However, in patients with highly severe strictures, before the procedure, intravenous sedation was accomplished with 15 mg of pentazocine and 10 mg of diazepam, and fluoroscopically guided balloon dilatation of an anastomosis with stricture is needed to pass the head of cutter (Fig. 5). Using a conventional anoscope with electric light, the three cuts were made in the right, left and posterior sites of the stricture with the under direct vision, which were considered safer than the anterior part to avoid perforation. Successively, cutting was examined with an endoscope and further dilation was performed digitally (Fig. 6A & 6B).

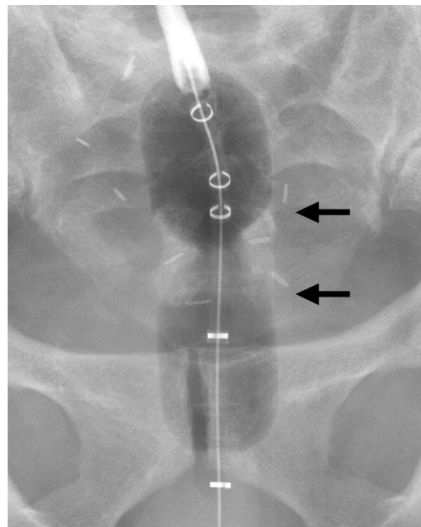


Fig. 5. Fluoroscopic view of the balloon dilatation for a stricture associated with leakage (Shimada et al., 2007). The length of the stricture was measured by the length of waist of inflated balloon (arrows). This suggests that balloon dilatation is ineffective for strictures caused by anastomotic leakage.

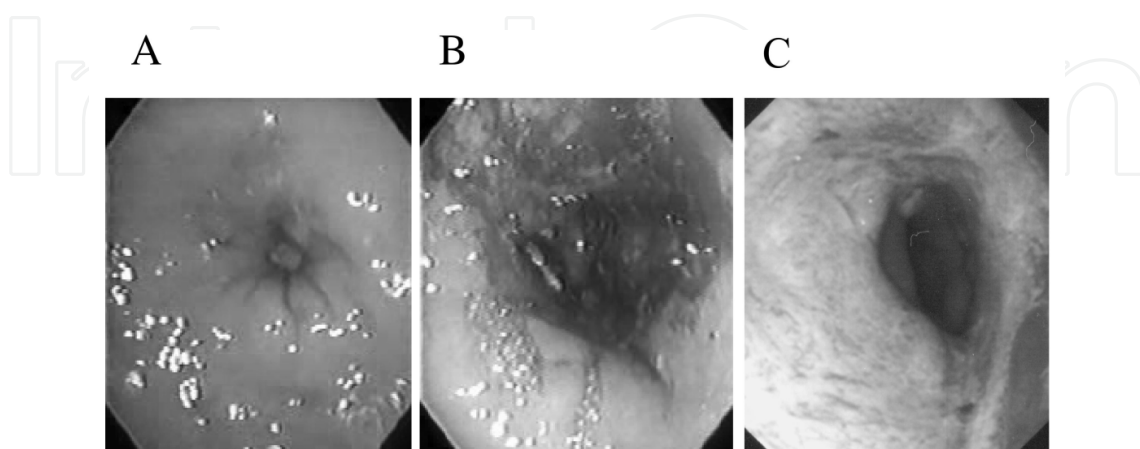


Fig. 6. Endoscopic view of the effect of the anastomotic stricture being associated with leakage by treatment with the STENO-CUTTER™ before (A), just after the surgery (B), and 5 years after treatment (C) (Shimada et al., 2007).

Incidence of leakage after double stapling technique is eleven out of 371 patients (3.0%) (Table 3). Compared with non-leakage group, there were no significant relationships of sex, age, tumor stage, stapler size, or distance of anastomosis from the anal verge in the leakage group. However, the incidence of the subsequent stricture formation in the leakage group (54.5%) was significantly higher than that in the non-leakage group (6.7%) ($P < 0.0001$) (Table 3). Six out of eleven with leakage had anastomotic stricture with the distressing symptoms of frequent bowel movements and ileus. From the operative records in the stricture cases associated with leaks, it was assumed that the tension at anastomoses caused by absence of mobilization of the splenic flexure of the colon (patients 1, 4 and 5), and contamination of colonic discharge to the anastomosis (patient 2) may affected to the causes of leakage, leading to subsequent severe strictures. A notable feature in the strictures associated with leaks was the progressive narrowing of the anastomoses. Three out of 6 patients (50%) formed almost complete stricture, resulted in the symptom of ileus. All the remaining patients without ileus had the symptom of frequent bowel movements.

	Leakage group	Non-leakage group	<i>P</i> value
No. of patients (%)	11 (3)	360 (97)	
Sex			0.903
Male	6	203	
Female	5	157	
Age	62.5±11.9	65.0±7.8	0.475
Tumor stage			0.196
Dukes A	3	138	
B	6	112	
C	2	110	
Devascularization			0.475
IMA	5	126	
SRA	6	234	
EEA size			0.845
33 mm	2	81	
31 mm	8	277	
28 mm	1	2	
Doughnuts			1.000
Complete	11	360	
Incomplete	0	0	
Distance from anal verge	4.9±1.1	5.1±0.8	0.807
Stricture (%)	6/11 (54.5)	24/360 (6.7)	< 0.0001
Follow up month	40.1±17.0	39.8±15.5	0.274

Table 3. Comparison of Clinical Factors between Leakage and Non-leakage Groups (Shimada et al., 2007)

Effects of stricture cutting in the six patients with colorectal stricture associated with leakage were summarized in Table 4. All the six patients had previous treatments: fluoroscopic balloon dilation for cases 1, 2, 4 and 6; esophageal bougie dilation for cases 3 and 5. But, those were little effective in spite of multiple trials. The time of initial treatment by the technique of STENO-CUTTER-short™ ranged from three to seven months (mean ± SD = 5.0 ± 1.4 months) after the multiple conventional dilations. The colorectal strictures thickened with circumferential firm scar formation were observed in all six patients. Furthermore, different from simple strictures without leakage, the strictures formed quite long narrow segments, and the mean length was 1.7 ± 0.4 cm. All the stenoses were biopsied and local recurrences were ruled out. Before the cutting procedure, in such patients with highly severe stricture as patients 1, 2 and 4, fluoroscopically guided balloon dilatation of the anastomosis was needed to pass the head of cutter (Fig. 5). Unlike patients with short

strictures without leaks, multiple cuttings were needed for the each site, because the stricture was consisted of a firm fibrosis and formed a long narrow segment as described above. In all six patients, this procedure enabled us to obtain sufficient dilation more than 20 mm in diameter compared with the diameter of the anoscope. In the patients 3 and 5, a single stricture cutting and digital dilation treatment succeeded in significantly decreasing the number of bowel movements within 48 hours, and the occurrence of re-stricture has not been observed. In the patients of 1, 2, 4 and 6, the re-stricture and the symptoms occurred after approximately four weeks from first cutting, although the first treatments were effective in these cases. The patient of 1, 2, 4 and 6 necessitated three, two, two and one more cuttings and digital dilation, respectively. However, the recurrence of stricture has not been occurred in any case in the long follow-up ranged from 17 to 61 months (mean \pm SD = 40 \pm 17 months). Endoscopic view of Fig. 6C showed lysis of a severe stricture 5 year after the last stenosis cutting for one instance (patient 1). Complications such as perforation and/or significant bleeding were not observed in any case.

Patient No.	Sex	Age	Stage (Dukes)	Resected artery	Stapler size (mm)	Distance* (cm)	Local factor	Previous treatment	Stenosis cutting † (month)	Stenosis length (cm)	No. of defecation		Therapeutic success	Repeated cutting	Follow-up month ‡
											Pre-cut	Post-cut			
1	F	61	B	IMA	33	6	Tension	Balloon	5	2.4	0 (Ileus)	5	Yes	3	61
2	M	70	B	IMA	33	5	Infection	Balloon	6	2.0	0 (Ileus)	4	Yes	2	55
3	F	69	A	SRA	31	4	None	Bougie	9	1.4	16	4	Yes	0	48
4	M	50	C	IMA	31	5	Tension	Balloon	7	1.8	0 (Ileus)	3	Yes	2	36
5	M	75	B	IMA	31	4	Tension	Bougie	4	1.2	14	5	Yes	0	24
6	F	58	A	SRA	31	4	None	Balloon	6	1.5	16	4	Yes	1	17
Mean \pm SD		64 \pm 9			32 \pm 1.0	4.7 \pm 0.8			6.2 \pm 1.7	1.7 \pm 0.4		4.2 \pm 0.8		1.3 \pm 1.2	40 \pm 17

*Distance from anal verge, † Post operative months of stenosis cutting, ‡ After the last stenosis cutting

SD = the standard deviation

SRA = superior rectal artery; IMA = inferior messentenic artery; EEA = end-to-end anastomosis staapler.

Table 4. Summary of Six Patients with Colorectal Stricture Associated with Leak

Anastomotic distance from anal verge, pelvic infection, duration of surgery, incomplete doughnuts, and extent of proximal colon resection have been proposed as the factors that may contribute to leakage after a double stapling technique (Averbach et al., 1996; Giffen et al., 1990; Laxamana et al., 1995; Vignali et al., 1997). Our comparison of clinical factors between leakage and non-leakage group could not point out definite factors, with the exception that the leakage was clearly related to the formation of subsequent anastomotic stricture compared with the non-leak group ($P < 0.0001$) (Shimada et al., 2007). It has been emphasized that the leak rate increased progressively with the extent of proximal colon resection (Averbach et al., 1996). Other authors (Giffen et al., 1990; Laxamana et al., 1995; Vignali et al., 1997) also considered that lower rectal anastomosis appeared to increase the clinical leak rate. Our three of six cases (50%) with leakage followed by stricture had tension at the anastomosis caused by the large extent of proximal colon resection. It is generally accepted that a stapled anastomosis is restored by the scar formation according to the secondary wound healing mechanism, whereas a hand-sewn double layer anastomosis is repaired by the primary wound healing mechanism (Buchmann et al., 1983; Graffner et al., 1984; Jansen, 1981). That is, the stapled anastomosis necessitates indirect bridging of the submucosal layer defect by smaller and longer strands of newly synthesized collagen tissue in the outer intestinal layers with a collateral circulation from the submucosal plexus to the

arterial plexuses in these layers (Jansen et al., 1981). Therefore, tension at the anastomosis is probably one of the major factors of leakage after the double stapling technique. Because local blood flow of colonic anastomosis is strongly influenced by the tension at the anastomosis. Further, it has been described that the sensitivity of the local microcirculation systems to tension is higher in the colorectum than in the small intestine (Shikata & Shida, 1986). Tension free anastomosis is highly recommended to the low anterior resection (Shimada et al., 2007).

Most of the anastomotic strictures are short narrowings less than 1 cm that can be successfully treated by an esophageal bougie or a balloon dilator (Johansson, 1996; Kozarek, 1986; Lange & Shaffer, 1991; Oz & Forde, 1990; Schlegel et al., 2001; Werre et al., 2000). In our study, all stenoses were irregular, kinked, fixed, and long (mean \pm SD = 1.7 \pm 0.4 cm). The treatment of stricture caused by disruption and/or ischemic injury is very difficult, since the stricture is usually severe and has a long narrow segment with firm fibrosis (Shimada et al., 2007). Such a stricture may have accelerated effects on the formation of re-stricture, that is, the stricture with hard fibrosis may return to the same condition as was before dilation. Esophageal or balloon dilators can temporary dilate the broad narrow segment caused by the thickened circumferential scar formation but hardly split the hard fibrosis, resulting in reverting to the shape before dilation followed by a re-stricture. These may explain why the current conventional dilations had failed. It has been reported that 27 patients with severe colorectal stenoses resistant to dilation or endoscopic modalities have been treated with surgical resection of strictures followed by reconstruction of new colorectal anastomoses for upper rectal strictures or Soave's procedure for middle or lower rectal strictures (Schlegel et al., 2001). In all cases, intestinal continuity has been restored and the surgical operation has offered satisfactory long-term functional results. If, however, there is a non-surgical technique which is effective, it will be greatly beneficial to patients with severe colorectal strictures as well as to surgeons who want to relieve the quite distressing symptom of his patients. Thus, a device of STENO-CUTTER-short™ was applied to split the stricture formed by the hard fibrosis. This treatment is considered to be a promising option, when current fluoroscopic and endoscopic modalities such as esophageal and balloon dilators failed to relieve the stricture.

6. Application of STENO-CUTTER™ for the treatment of intractable stricture caused by ischemic injury

The resected cervical esophagus is commonly reconstructed by the cervical transposition of a jejunal segment with vascular anastomosis (Chen & Tang, 2000; Fisher et al., 1985; Kasai & Nishihira, 1986; Urayama et al., 1997). However, a major complication of this procedure is disruption and/or ischemic injury of the pharyngo-jejunal anastomosis or the transpositioned jejunal segment, leading to severe stricture, which requires surgical treatment (Fisher et al., 1985; Golshani et al., 1999; Mansour et al., 1997). Because this type of stricture is usually severe and has long narrow segment, it is intractable to dilatation and recurrence is common. Although the STENO-CUTTER™ was initially developed to split a circular stapler line in a colorectal stricture, we considered that the device and technique could be used to cut the severe fibrosis in strictures of pharyngo-jejunal anastomosis after ischemic injury as well as disruption (Shimada et al. 2002).

A 56-year-old Japanese female with cervical esophageal cancer underwent surgery to remove the cervical esophagus after chemo-radiation therapy (chemotherapy: 500 mg/body

of 5-fluorouracil and 10 mg/body of cisplatin for 3 weeks; radiation: total of 40 Gy). Reconstruction was done using a jejunal segment with vascular anastomosis. The pharyngo-jejunal anastomosis was performed end-to-side with Albert-Lembert interrupted sutures. Pathological examination revealed that the histological type of the tumor was moderately differentiated adenocarcinoma and that it involved the larynx and thyroid, but there was no lymph node metastasis. Her postoperative course was uneventful and the anastomosis appeared healing well. She was discharged on postoperative day (POD) 27. The patient, however, was readmitted 4 years later with severe dysphagia. An upper gastrointestinal series and endoscopic examination showed a severe stricture in the upper transpositioned jejunal segment (Fig. 7A and Fig. 9A). Angiography of the cervical arteries suggested ischemic change in the upper part of the transpositioned jejunal segment. Although fluoroscopically guided bougie dilation using a 15-mm bougie was performed twice within 10 days of admission, a radiograph showed minimal improvement of the stricture, and the symptoms of stenosis were unresolved. In the outpatient clinic, multiple bouginages were required for complete dysphagia, every year for the next 3 years, with little improvement each time. Soon after the unsuccessful bouginage, the surgery was performed .

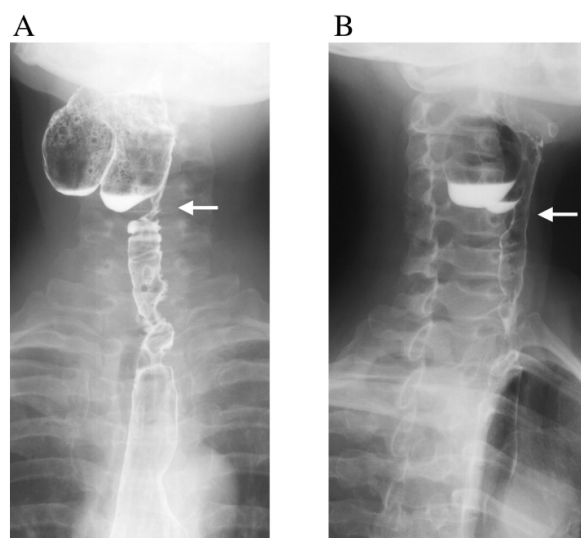


Fig. 7. Upper gastrointestinal series clearly showed the effect of the STENO-CUTTER™ technique, before (A) and after (B) cutting (arrows) (Shimada et al., 2002). This device was initially developed for the treatment of colorectal stenoses after circular stapling anastomoses including the double stapling technique.

With the patient under general anesthesia, we cut the severe stricture in the transpositioned jejunum using a STENO-CUTTER-long™. As shown in Fig. 8A, a conventional rectoscope (19 cm long) was inserted to just in front of the stricture through the patient's mouth, and the stricture was cut by the STENO-CUTTER-long™ under direct vision. The two parts of the stricture were cut so that the severe stenosis was removed (Fig. 8B). The two cuts were made in the right and left anterior sites of the stricture, which were considered safer than the lateral or posterior sites, to avoid injuring the adjacent vessels. The possible complications of the STENO-CUTTER-long™ are bleeding and perforation of the cervical portion, but no substantial bleeding or perforation occurred during or after cutting. After the cutting, a video endoscope (OLYMPUS, GIF-Q200) was inserted to confirm the dilation. The endoscope passed through the anastomosis easily. Histologically, the biopsied

specimens showed no malignancy in the stricture. Postoperative recovery was rapid and uneventful, and the patient was discharged without any clinical symptoms. When examined 1 month later, then 6 months later in the outpatient clinic, upper gastrointestinal endoscopy revealed lysis of the stricture in the transpositioned jejunum, and no dysphagia. Complete resolution of the stricture has been maintained without any additional treatment for more than 1 year (Fig. 7B and Fig. 9B).

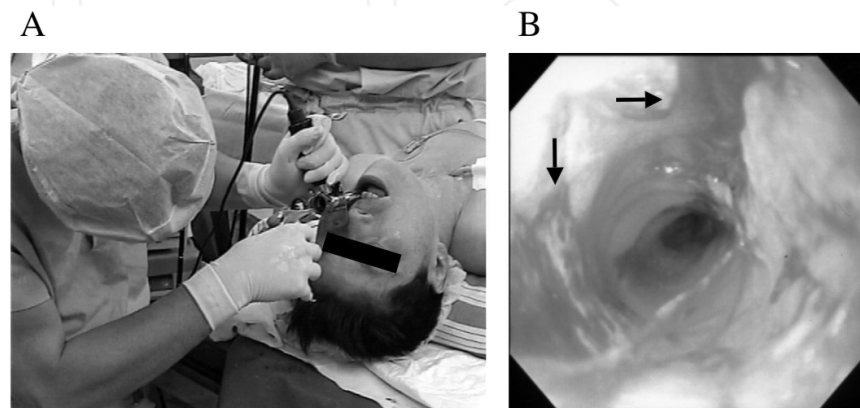


Fig. 8. The technique of cutting with the STENO-CUTTER™ (Shimada et al., 2002). The two sites of the stricture were cut using the cutter assisted by a conventional rectal scope (A). B Endoscopic view after cutting (the two arrows indicate the cut sites of stenosis)

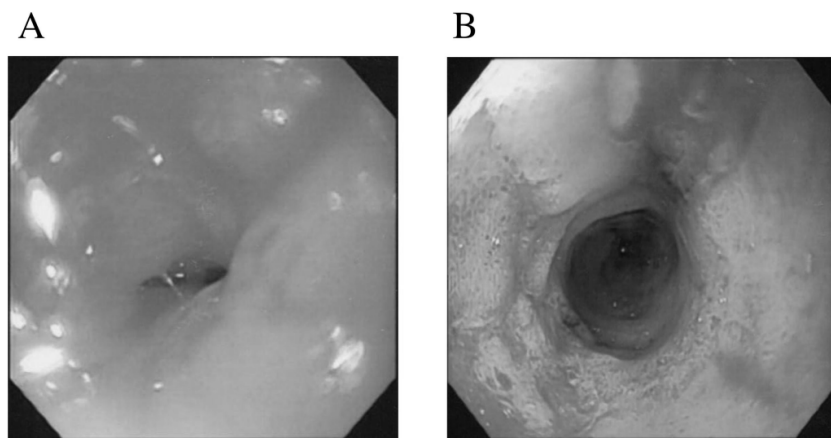


Fig. 9. Endoscopic evaluation of the effect of staple cutting (Shimada et al., 2002). A: before cutting. B: one year after cutting

Severe and recurrent stenosis of a pharyngo-jejunal anastomosis or jejunal segment after reconstruction by transposition of the jejunal segment with a vascular anastomosis is a challenging problem for the surgeon who wants to relieve the patient's distressing symptoms. The treatment of a stricture caused by disruption and/or ischemic injury is very difficult, since it is usually severe and has a long narrow segment with hard fibrosis. This type of stricture may have an accelerated effect on the formation of re-stricture. In other words, a stricture with hard fibrosis may return to the same condition as was before dilation. Esophageal or balloon dilators (Hernandez et al., 2000; Kadakia et al., 1993; Marshall et al., 1996) can temporarily dilate the long narrow segment caused by the thickened circumferential scar formation, but it hardly splits the hard fibrosis. The result is

that it reverts to the shape before dilation, followed by a re-stricture. In our patient, repeated esophageal and balloon dilators failed to relieve the symptoms caused by the stricture. A more effective and less invasive therapeutic modality was necessary, and therefore, the STENO-CUTTER™ was used to split the stricture formed by the hard fibrosis.

7. Conclusions

We describe a new method using a STENO-CUTTER™ to successfully treat the patients with colorectal stricture following surgery for rectal cancer. This device is so simple, easy to use under direct vision with the use of a conventional anoscope, and does not need fluoroscope or other special optional equipment. This treatment was generally performed at the bedside even in the outpatient clinic and the significant complications such as bleeding and/or perforation have not been observed. From the excellent efficacy in addition to safe and easy usage, the treatment using the device of STENO-CUTTER™ is highly recommended for the treatment of circular stapling anastomotic stricture of the rectum, even in severe stricture associated with anastomotic leakage or ischemic injury. The positive results achieved in these patients suggest that our new method could represent a promising option of treatment for strictures when conventional modalities fail.

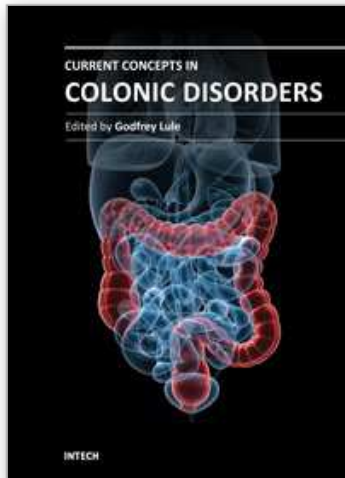
8. References

- Averbach, A.M., Chang, D., Koslowe, P. & Sugarbaker, P.H. (1996). Anastomotic leak after double-stapled low colorectal resection. *Diseases of the Colon and Rectum*, Vol.39, No.7, pp. 780-787
- Bailey, C.M., Wheeler, J.M., Birks, M. & Farouk, R. (2003). The incidence and causes of permanent stoma after anterior resection. *Colorectal Disease*, Vol.5, No.4, pp. 331-334
- Blamey, S.L. & Lee, P.W. (1982). A comparison of circular stapling devices in colorectal anastomoses. *The British Journal of Surgery*, Vol.69, No.1, pp. 19-22
- Boccola, M.A., Lin, J., Rozen, W.M. & Ho, Y.H. (2010). Reducing anastomotic leakage in oncologic colorectal surgery: an evidence-based review. *Anticancer Research*, Vol.30, No.2, pp. 601-607
- Brennan, S.S., Pickford, I.R., Evans, M. & Pollock, A.V. (1982). Staples or sutures for colonic anastomoses: a controlled clinical trial. *The British Journal of Surgery*, Vol.69, No.12, pp. 722-724
- Brower, R.A. & Freeman, L.D. (1984). Balloon catheter dilation of a rectal stricture. *Gastrointestinal Endoscopy*, Vol.30, No.2, pp. 95-97
- Buchmann, P., Schneider, K. & Gebbers, J.O. (1983). Fibrosis of experimental colonic anastomosis in dogs after EEA stapling or suturing. *Diseases of the Colon and Rectum*, Vol.26, No.4, pp. 217-220
- Cade, D., Gallagher, P., Schofield, P.F. & Turner, L. (1981). Complications of anterior resection of the rectum using the EEA stapling device. *The British Journal of Surgery*, Vol.68, No.5, pp. 339-340
- Chen, H.C. & Tang, Y.B. (2000). Microsurgical reconstruction of the esophagus. *Seminars in surgical oncology*, Vol.19, No.3, pp. 235-245
- DuBrow, R.A., David, C.L. & Curley, S.A. (1995). Anastomotic leaks after low anterior resection for rectal carcinoma: evaluation with CT and barium enema. *American Journal of Roentgenology*, Vol.165, No.3, pp. 567-571

- Dziki, A.J., Duncan, M.D., Harmon, J.W., Saini, N., Malthaner, R.A., Trad, K.S., Fernicola, M.T., Hakki, F. & Ugarte, R.M. (1991). Advantages of handsewn over stapled bowel anastomosis. *Diseases of the Colon and Rectum*, Vol.34, No.6 pp. 442-448
- Fain, S.N., Patin, C.S. & Morgenstern, L. (1975). Use of mechanical suturing apparatus in low colorectal anastomosis. *Archives of Surgery*, Vol.110, No.9, pp. 1079-1082
- Fisher, S.R., Cole, T.B., Meyers, W.C. & Seigler, H.F. (1985). Pharyngoesophageal reconstruction using free jejunal interposition grafts. *Archives of Otolaryngology*, Vol.111, No.11, pp. 747-752
- Garcea, G., Sutton, C.D., Lloyd, T.D., Jameson, J., Scott, A. & Kelly, M.J. (2003). Management of Benign Rectal Strictures: a review of present therapeutic procedures. *Diseases of the Colon and Rectum*, Vol.46, No.11, pp. 1451-1460
- Golshani, S.D., Lee, C., Cass, D., Thomas, A. & Mandpe, A.H. (1999). Microvascular "supercharged" cervical colon: minimizing ischemia in esophageal reconstruction. *Annals of Plastic Surgery*, Vol.43, No.5, pp. 533-538
- Gordon, P.H. & Vasilevsky, C.A. (1984). Experience with stapling in rectal surgery. *The Surgical Clinics of North America*, Vol.64, No.3, pp. 555-566
- Graffner, H., Andersson, L., Lowenhielm, P. & Walther, B. (1984). The healing process of anastomoses of the colon. A comparative study using single, double-layer or stapled anastomosis. *Diseases of the colon and rectum*, Vol.27, No.12, pp. 767-771
- Griffen, F.D., Knight, C.D. Sr., Whitaker, J.M., Whitaker, J.M. & Knight, C.D. Jr. (1990). The double stapling technique for low anterior resection. Results, modifications, and observations. *Annals of Surgery*, Vol.211, No.6, pp. 745-751
- Hernandez, L.J., Jacobson, J.W. & Harris, M.S. (2000). Comparison among the perforation rates of Maloney, balloon, and savary dilation of esophageal strictures. *Gastrointestinal Endoscopy*, Vol.51, pp. 460-462
- Jansen, A., Becker, A.E., Brummelkamp, W.H., Keeman, J.N. & Klopper, P.J. (1981). The importance of the apposition of the submucosal intestinal layers for primary wound healing of intestinal anastomosis. *Surgery, Gynecology & Obstetrics*, Vol.152, No.1, pp. 51-58
- Johansson, C. (1996). Endoscopic dilation of rectal strictures: a prospective study of 18 cases. *Diseases of the Colon and Rectum*, Vol.39, No.4, pp. 423-428
- Kadokia, S.C., Parker, A., Carrougner, J.G. & Shaffer, R.T. (1993). Esophageal dilation with polyvinyl bougies, using a marked guidewire without the aid of fluoroscopy: an update. *The American Journal of Gastroenterology*, Vol.88, No.9, pp. 1381-1386
- Kasai, M. & Nishihira, T. (1986). Reconstruction using pedicled jejunal segments after resection for carcinoma of the cervical esophagus. *Surgery, Gynecology & Obstetrics*, Vol.163, No.2, pp. 145-152
- Knight, C.D. & Griffen, F.D. (1980). An improved technique for the low anterior resection using the EEA stapler. *Surgery*, Vol.88, No.5, pp. 710-714
- Köhler, A., Athanasiadis, S., Ommer, A. & Psarakis, E. (2000). Long-term results of low anterior resection with intersphincteric anastomosis in carcinoma of the lower one-third of the rectum: analysis of 31 patients. *Diseases of the Colon and Rectum*, Vol.43, No.6, pp. 843-850
- Kozarek, R.A. (1986). Hydrostatic balloon dilation of gastrointestinal stenoses: a national survey. *Gastrointestinal Endoscopy*, Vol.32, No.1, pp. 15-19
- Kumar, A., Daga, R., Vijayaragavan, P., Prakash, A., Singh, R.K., Behari, A., Kapoor, V.K. & Saxena, R. (2011). Anterior resection for rectal carcinoma - risk factors for

- anastomotic leaks and strictures. *World Journal of Gastroenterology*, Vol.17, No.11, pp. 1475-1479
- Kyzer, S. & Gordon, P.H. (1992). Experience with the use of the circular stapler in rectal surgery. *Diseases of the Colon and Rectum*, Vol.35, No.7, pp. 696-706
- Lange, E.E. & Shaffer, H.A. Jr. (1991). Rectal strictures: treatment with fluoroscopically guided balloon dilation. *Radiology*, Vol.178, No.2, pp. 475-479
- Laxamana, A., Solomon, M.J., Cohen, Z., Feinberg, S.M., Stern, H.S. & McLeod, R.S. (1995). Long-term results of anterior resection using the double-stapling technique. *Diseases of the Colon and Rectum*, Vol.38, No.12, pp. 1246-1250
- Leff, E.I., Hoexter, B., Labow, S.B., Eisenstat, T.E., Rubin, R.J., Salvati, E.P. (1982). The EEA stapler in low colorectal anastomoses: initial experience. *Diseases of the Colon and Rectum*, Vol.25, No.7, pp. 704-707
- Luchtefeld, M.A., Milsom, J.W., Senagore, A., Surrell, J.A. & Mazier, W.P. (1989). Colorectal anastomotic stenosis. Results of a survey of the ASCRS membership. *Diseases of the Colon and Rectum*, Vol.32, No.9, pp. 733-736
- MacRae, H.M. & McLeod, R.S. (1998). Handsewn vs. stapled anastomoses in colon and rectal surgery: a meta-analysis. *Diseases of the Colon and Rectum*, Vol.41, No.2, pp. 180-189
- Mansour, K.A., Bryan, F.C. & Carlson, G.W. (1997). Bowel interposition for esophageal replacement: twenty-five-year experience. *The Annals of Thoracic Surgery*, Vol.64, No.3, pp. 752-756
- Marchena, G.J., Ruiz, C.E., Gomez, G.G., Vallejo, G.I., Garcia-Anguiano, F., Hernandez, R. J.M. (1997). Anastomotic stricture with the EEA-Stapler after colorectal anastomosis. *Revista Espanola de Enfermedades*, Vol.89, No.11, pp. 835-842
- Marshall, J.B., Afridi, S.A., King, P.D., Barthel, J.S. & Butt, J.H. (1996). Esophageal dilation with polyvinyl (American) dilators over a marked guidewire: practice and safety at one center over a 5-yr period. *The American Journal of Gastroenterology*, Vol.91, No.8, pp. 1503-1506
- Miller, K. & Moritz E. (1996). Circular stapling techniques for low anterior resection of rectal carcinoma. *Hepato-gastroenterology*, Vol.43, No.10, pp. 823-831
- Moran, B.J., Blenkinsop, J. & Finnis, D. (1992). Local recurrence after anterior resection for rectal cancer using a double stapling technique. *The British Journal of Surgery*, Vol.79, No.8, pp. 836-838
- Ohman, U. & Svenberg, T. (1983). EEA stapler for mid-rectum carcinoma. Review of recent literature and own initial experience. *Diseases of the Colon and Rectum*, Vol.26, No.12, pp. 775-784
- Orsay, C.P., Bass, E.M., Firfer, B., Ramakrishnan, V. & Abcarian, H. (1995). Blood flow in colon anastomotic stricture formation. *Diseases of the Colon and Rectum*, Vol.38, No.2, pp. 202-206
- Oz, M.C. & Forde, K.A. (1990). Endoscopic alternatives in the management of colonic strictures. *Surgery*, Vol.108, No.3, pp. 513-519
- Polglase, A.L., Hughes, E.S., McDermott, F.T., Pihl, E. & Burke, F.R. (1981). A comparison of end-to-end staple and suture colorectal anastomosis in the do. *Surgery, Gynecology & Obstetrics*, Vol.152, No.6, pp. 792-796
- Ravitch, M.M. & Steinchen, F.M. (1979). A stapling instrument for end-to-end inverting anastomoses in the gastrointestinal tract. *Annals of Surgery*, Vol.189, No.6, pp. 791-797

- Sato, H., Maeda, K., Hanai, T. & Aoyama, H. (2007). Colorectal anastomosis using a novel double-stapling technique for lower rectal carcinoma. *International Journal of Colorectal Disease*, Vol.22, No.10, pp. 1249-1253
- Schlegel, R.D., Dehni, N., Parc, R., Caplin, S. & Tiret, E. (2001). Results of reoperations in colorectal anastomotic strictures. *Diseases of the Colon and Rectum*, Vol.44, No.10, pp. 1464-1468
- Shikata, J. & Shida, T. (1986). Effects of tension on local blood flow in experimental intestinal anastomoses. *The Journal of Surgical Research*, Vol.40, No.2, pp. 105-111
- Shimada, S., Matsuda, M., Uno, K., Matsuzaki, H., Murakami, S. & Ogawa, M. (1996). A new device for the treatment of coloproctostomic stricture after double stapling anastomoses. *Annals of Surgery*, Vol.224, No.5, pp. 603-608
- Shimada, S., Honmyo, U., Hayashi, N., Matsuda, M. & Ogawa, M. (2002). Successful new treatment for intractable cervical esophageal stenosis of a jejunal segment transpositioned with a vascular anastomosis: report of a case. *Surgery Today*, Vol.32, No.11, pp. 996-999
- Shimada, S., Yagi, Y., Yamamoto, K., Matsuda, M. & Baba, H. (2007). Novel treatment of intractable rectal strictures associated with anastomotic leakage using a stenosis-cutting device. *International Surgery*, Vol.92, No.2, pp. 82-88
- Shirikhande, S.V., Saoji, R.R., Barreto, S.G., Kakade, A.C., Waterford, S.D., Ahire, S.B., Golowale, F.M. & Shukla, P.J. (2007). Outcomes of resection for rectal cancer in India: the impact of the double stapling technique. *World Journal of Surgical Oncology*, Vol.21, No.5, pp. 35
- Smith, L.E. (1981). Anastomosis with EEA stapler after anterior colonic resection. *Diseases of the Colon and Rectum*, Vol.24, No.4, pp. 236-242
- Thrsen, G. & Rosseland, A.R. (1983). Endoscopic incision of postoperative stenoses in the upper gastrointestinal tract. *Gastrointestinal Endoscopy*, Vol.29, No.1, pp. 26-29
- Urayama, H., Ohtake, H., Ohmura, K. & Watanabe, Y. (1997). Pharyngoesophageal reconstruction with the use of vascular anastomoses: operative modifications and long-term prognosis. *The Journal of Thoracic and Cardiovascular Surgery*, Vol.113, No.6, pp. 975-981
- Verma, J.S., Chan, A.C., Li, M.K. & Li, A.K. (1990). Low anterior resection of the rectum using a double stapling technique. *The British Journal of Surgery*, Vol.77, No.8, pp. 888-890
- Vezeridis, M., Evans, J.T., Mittelman, A. & Ledesma, E.J. (1982). EEA stapler in low anterior anastomosis. *Diseases of the Colon and Rectum*, Vol.25, No.4, pp. 364-367
- Vignali, A., Fazio, V.W., Lavery, I.C., Milsom, J.W., Church, J.M., Hull, T.L., Strong, S.A. & Oakley, J.R. (1997). Factors associated with the occurrence of leaks in stapled rectal anastomoses: a review of 1,014 patients. *Journal of the American College of Surgeons*, Vol.185, No.2, pp. 105-113
- Waxman, B.P. (1983). Large bowel anastomoses. II. The circular staplers. *The British Journal of Surgery*, Vol.70, No.2, pp. 64-67
- Werre, A., Mulder, C., van Heteren, C. & Bilgen, E.S. (2000). Dilation of benign strictures following low anterior resection using Savary-Gilliard bougies. *Endoscopy*, Vol.32, No.5, pp. 385-388
- Whitworth, P.W., Richardson, R.L. & Larson, G.M. (1988). Balloon dilation of anastomotic strictures. *Archives of Surgery*, Vol.123, No.6, pp. 759-762



Current Concepts in Colonic Disorders

Edited by Dr. Godfrey Lule

ISBN 978-953-307-957-8

Hard cover, 276 pages

Publisher InTech

Published online 05, January, 2012

Published in print edition January, 2012

The 21st Century has seen a resurgence of research of the gastrointestinal tract, especially since it was established that it plays a central role as an immune system organ and consequentially has a huge impact on causation, impact and transmission of most human ailments. New diseases such as the Acquired Immunodeficiency Syndrome, hepatitis and tumours of the gastrointestinal tract have emerged and they are currently subjects of intensive research and topics of scientific papers published worldwide. Old diseases like diarrhea have become extremely complex to diagnose with new and old pathogens, drugs, tumours and malabsorptive disorders accounting for the confusion. This book has set out algorithms on how to approach such conditions in a systematic way both to reach a diagnosis and to make patient management cheaper and more efficient. "Current Concepts in Colonic Disorders" attempts to put all the new information into proper perspective with emphasis on aetiopathogenesis and providing rational approach to management of various old and new diseases. As the book editor, I have found this first edition extremely interesting and easy to understand. Comments on how to improve the content and manner of presentation for future editions are extremely welcome.

How to reference

In order to correctly reference this scholarly work, feel free to copy and paste the following:

S. Shimada, M. Kuramoto, A. Matsuo, S. Ikeshima, H. Kuhara, K. Eto and H. Baba (2012). Treatment of Colorectal Stricture After Circular Stapling Anastomoses, Current Concepts in Colonic Disorders, Dr. Godfrey Lule (Ed.), ISBN: 978-953-307-957-8, InTech, Available from: <http://www.intechopen.com/books/current-concepts-in-colonic-disorders/treatment-of-colorectal-stricture-after-circular-stapling-anastomoses>

INTECH
open science | open minds

InTech Europe

University Campus STeP Ri
Slavka Krautzeka 83/A
51000 Rijeka, Croatia
Phone: +385 (51) 770 447
Fax: +385 (51) 686 166
www.intechopen.com

InTech China

Unit 405, Office Block, Hotel Equatorial Shanghai
No.65, Yan An Road (West), Shanghai, 200040, China
中国上海市延安西路65号上海国际贵都大饭店办公楼405单元
Phone: +86-21-62489820
Fax: +86-21-62489821

© 2012 The Author(s). Licensee IntechOpen. This is an open access article distributed under the terms of the [Creative Commons Attribution 3.0 License](#), which permits unrestricted use, distribution, and reproduction in any medium, provided the original work is properly cited.

IntechOpen

IntechOpen