

We are IntechOpen, the world's leading publisher of Open Access books Built by scientists, for scientists

4,800

Open access books available

122,000

International authors and editors

135M

Downloads

Our authors are among the

154

Countries delivered to

TOP 1%

most cited scientists

12.2%

Contributors from top 500 universities



WEB OF SCIENCE™

Selection of our books indexed in the Book Citation Index
in Web of Science™ Core Collection (BKCI)

Interested in publishing with us?
Contact book.department@intechopen.com

Numbers displayed above are based on latest data collected.

For more information visit www.intechopen.com



Appendiceal Intussusception

Nikolaos Varsamis, Konstantinos Pougouras, Nikolaos Salveridis,
Aekaterini Theodosiou, Eftychios Lostoridis, Georgios Karageorgiou,
Athanasios Mekakas and Konstantinos Christodoulidis
*1st Department of Surgery, General Hospital of Kavala
Greece*

1. Introduction

Diseases of the appendix constitute a problem of daily practice in the routine of the general surgeon. One should be well aware and familiar with all the spectrum of its pathology and, of course, he should be able to deal with it successfully and uneventfully. It is not a coincidence that appendectomy is the first operation a general surgeon is trained to perform. Moreover, statistics claim that appendectomy is the most common emergent general surgery procedure performed in the United States. Finally, with 250,000 appendectomies performed there every year, Addiss et al estimated in 1990 the lifetime risk of appendectomy to be 8.6% for men and 6.7% for women (Chaar et al, 2009).

Despite being such a common matter of daily medical practice, diseases of the appendix may comprise lesions that are not so usually encountered by a general surgeon. Therefore it is important and worthy to try to illuminate them and bring some useful information concerning them to the foreground.

Intussusception of the appendix is such an infrequent appendiceal lesion with an incidence of 0.01% among patients receiving an appendectomy. Although it may clinically mimic more common acute and chronic abdominal conditions, it is an important entity to recognize, since it could be discovered as a caecal mass or mistaken for a gastrointestinal neoplasm. However, diagnosis is rarely made preoperatively due to its variable and non-specific symptoms.

All the information mentioned above point out the importance of the thorough presentation concerning the clinical entity of the intussusception of the vermiform appendix that is going to be given in the following pages of this essay.

2. Appendiceal intussusception: A challenge for the general surgeon

2.1 Materials and methods

Appendiceal intussusception, despite being a rare entity, is a distinctive and by means of diagnosis challenging condition. The literature referring to appendiceal intussusception mainly consists of case report articles. Our objective is to present a thorough review of the existing literature, based on articles published in journals accessible via Medline (Pub Med database source).

A research in Pub Med/Medline was performed by our team using the key words "Appendiceal Intussusception" and MeSH ("Appendix"[Majr]) AND "Intussusception"

[Majr]. In the first instance our research resulted in 160 titles of articles, whereas in the second we found 183 ones. All of them having an abstract or full text available were reviewed and taken into consideration as a source of data for our essay. During our research we found out that in 2009 Chaar et al made a comprehensive review of the English literature concerning appendiceal intussusception and presented a series of 191 cases published, including one who was their patient. We decided to use those 191 cases as our initial material and add all the cases of appendiceal intussusception published after Chaar's review up until 2011, while we also added some articles from previous years that weren't included in his review. Finally, we gathered a total of 28 articles describing 29 new cases of appendiceal intussusception plus some cases where the appendiceal stump acted as the leading point for intussusception. Thus our material comprises 220 cases of appendiceal intussusception described in English literature from which all data that are presented below have emerged.

2.2 Definition and classification of intussusception

Intussusception represents a rare form of bowel obstruction, which is defined as the telescoping of a proximal segment of the gastrointestinal tract, called intussusceptum, into the lumen of the adjacent distal segment of the gastrointestinal tract, called intussusciens. Lesions within the lumen of the bowel have a higher likelihood to cause invagination, because peristalsis drags them forward. These lesions act as "leading points" for intussusception (Kim et al, 2006).

This entity was first reported in 1674 by Barbette of Amsterdam and further presented in a detailed report in 1789 by John Hunter as "introssusception". Historically, Sir Jonathan Hutchinson was the first to operate on a child with intussusception in 1871 (Marinis et al, 2009).

The most common locations in the gastrointestinal tract where an intussusception can take place are the junctions between freely moving intestinal segments, and retroperitoneally or adhesively fixed bowel segments. The types of intussusception have been classified according to their location into four categories :

- entero-enteric intussusception , confined to the small bowel
- colo-colic intussusception, involving only the large bowel
- ileo-colic intussusception, defined as the prolapse of the terminal ileum within the ascending colon
- ileo-caecal intussusception, where the ileo-cecal valve is the leading point of the intussusception and that is distinguished with some difficulty from the ileo-colic variant

(Marinis et al, 2009).

2.3 Basic anatomy and physiology of the appendix

The appendix is located in the right iliac fossa and usually its base is situated in a line joining the right superior iliac spine to the umbilicus in relation to the anterior abdominal wall (one third of the way from the right superior iliac spine). The vermiform appendix is a narrow, muscular diverticulum containing numerous lymphoid follicles. Its length varies from 8 to 13 cm (3 to 5 in.) and its base arises from the posteromedial surface of the caecum approximately 2,5 cm (1 in.) below the ileocolic valve. It usually has a complete peritoneal covering and it attaches to the mesentery of the small intestine by the mesoappendix. The

latter contains the appendicular vessels and nerves. The teniae coli of the caecum converge to the base of the appendix and form a muscle coat. It is divided in three parts: base, body and tip of the appendix. The tip of the appendix is moving freely and may be found inside (85%) or outside the peritoneum (15%) (Anson & McVay, 1971). In the first case, the most common position of the appendix is coiled up behind the caecum (65%). In 20% of cases, it hangs down into the pelvis against the right pelvic wall. Less common sites are in front or behind the terminal part of the ileum. In the second case, it projects upward along the lateral site of the caecum or the ascending colon. In cases of intestinal malrotation or situs inversus, it may be located in the right upper quadrant or in the left iliac fossa, respectively (Snell, 2008).

The appendicular artery is a branch of the ileocolic artery, which originates from the superior mesenteric artery. In 30% of the cases, a second branch from the posterior caecal artery exists. The appendicular vein drains into the ileocolic vein and finally to the portal vein (through upper mesenteric vein). The lymph vessels drain into one or two nodes lying in the mesoappendix, into the ileocaecal nodes and eventually into the superior mesenteric nodes (Snell, 2008).

The nerve supply derives from the superior mesenteric plexus, which gives the sympathetic and parasympathetic (vagus) nerves. The visceral pain of the appendix is conducted by afferent nerve fibers that enter the spinal cord at the level of the 10th thoracic segment (Snell, 2008).

The role of the appendix as a part of the immune system remains unknown. Its physiologic function is related to the presence of lymphoid follicles in the submucosal layer of the appendix. The lymphoid follicles appear two weeks after birth and number about 200 or more between the ages of 15 and 25 years. They progressively decline and become atrophic in the elderly with fibrosis of the wall and total or partial obliteration of the lumen of the appendix (Schumpelick et al, 2000). Mucous is secreted into the lumen of appendix with a rate of 2-3 ml per day (Sbarounis, 1991).

2.4 Intussusception of the vermiform appendix

2.4.1 Historical background

In 1858 McKidd was the first who described a case of complete invagination of the appendix into the caecum of a 7 year-old boy as a post mortem finding (Gilpin, 1989; McKidd, 1858). In 1890, the first operation for appendiceal intussusception in a 13-months-old child was reported. Wright, Renshaws, Pitts and McGraw performed successful operations for appendiceal intussusception. In 1964, Collins concluded a 40-year study on 71,000 appendices obtained from surgical and autopsy material and reported prevalence of 0.01% for intussusception of the appendix; the prevalence of endometriosis and adenocarcinoma of the appendix were 0.05% and 0.08%, respectively (Collins, 1963; Ryu et al, 2005).

Since the first report, the literature on appendiceal intussusception has been limited to case reports and small case series. Forshall in 1953 and Bachman and Clement in 1971 wrote the largest case series, presenting 7 patients each. Some investigators attempted limited reviews of the literature. Fink et al reviewed the literature in 1964 and found that less than 118 cases had been previously reported. Finally, Chaar et al made a comprehensive review in 2009 and presented 191 cases of appendiceal intussusception described in the English literature since then (Chaar et al, 2009).

From all the above it is clear that appendiceal intussusception is an extremely rare lesion of the appendix. Despite its rarity, it is a disease encountered and described one and a half century ago, and it still remains in the centre of medical interest, since case reports and reviews continue to be published nowadays.

2.4.2 Demographics

There is an objective difficulty in presenting accurate data referring to demographics and incidence of appendiceal intussusception due to the infrequency of this condition. Most articles in the literature are limited in case reports or small case series. Moreover, results presented in these articles are often variant and controversial.

Fink et al reviewed the literature and found that less than 118 cases were reported. Their paper was published in 1964 and stated that appendiceal intussusception is predominantly a pediatric condition, with most cases observed in the first decade of life, with the average age of occurrence being 16 years old. Men seemed to be affected 4 to 5 times more frequently than women (Fink et al, 1964). Jevon et al reviewed the cases reported between 1984 and 1991 and found 12 reports of appendiceal intussusception. He concluded that this lesion occurs mostly in adults and has an equal sex distribution (Jevon et al, 1992). Finally, Chaar et al in 2009 concluded that appendiceal intussusception is more often encountered in adult women, with a predominance of occurrence in the 4th decade of life. He presented demographic data from 189 out of 191 patients mentioned. (Chaar et al, 2009).

Our team worked out with a total of 218 patients' demographic data. 189 patients came from Chaar's review and 29 patients from our research in the literature. Male patients were 82 out of 218 in total (37.6%), whereas female patients were 136 out of 218 (62.4%). Consequently, male/female ratio of patients suffering from appendiceal intussusception was approximately 1/3. Moreover, pediatric patients affected by this lesion were 52 out of 218 (23.8%), while adult patients were 166 out of 218 (76.2%). Thus, appendiceal intussusception is more commonly encountered in the age group of adults, with a frequency which is more than 2 times higher than that of the pediatric age group.

Interestingly, intussusception of the vermiform appendix happens more often in male population in the pediatric age group, while female patients are more in the age group of adults. In particular, 32 out of 52 patients (61.5%) in the pediatric age group were male, whereas 116 out of 166 patients (69.9%) in the age group of adults were female. It is clear that there is an inversion in the frequency and rate of appearance (1/3) among the two sexes in the two different age groups of pediatric and adult population. This phenomenon can be explained by the fact that appendiceal intussusception in adults is predominantly secondary to appendiceal endometriosis or mucocele, as we will more thoroughly explain in a following chapter of this essay. However, endometriosis happens only to women and mucocele of the appendix is also more often in women. Moreover, appendiceal intussusception in pediatric age group is almost always primary with elements of inflammation, thus female dominance stops to exist. Therefore, there seems to be a rational explanation for the observed inversion in the frequencies among the two sexes.

Patients' terminal ages varied from 17 days after gestation to 85 years of life, and the total average age of occurrence lied between 35 and 36 years (35.6 years). In the pediatric age group average age of presentation was 6.8 years. Finally, in the age group of adults appendiceal intussusception emerged in the average age of 45.5 years.

2.4.3 Classification

Appendiceal intussusception was first classified by Moschowitz in 1910 and later modified by McSwain in 1941. The classification is anatomically based on which part of the appendix is the intussusceptum and where the intussusciens is located. McSwain described 5 types as follows (Fig. 1):

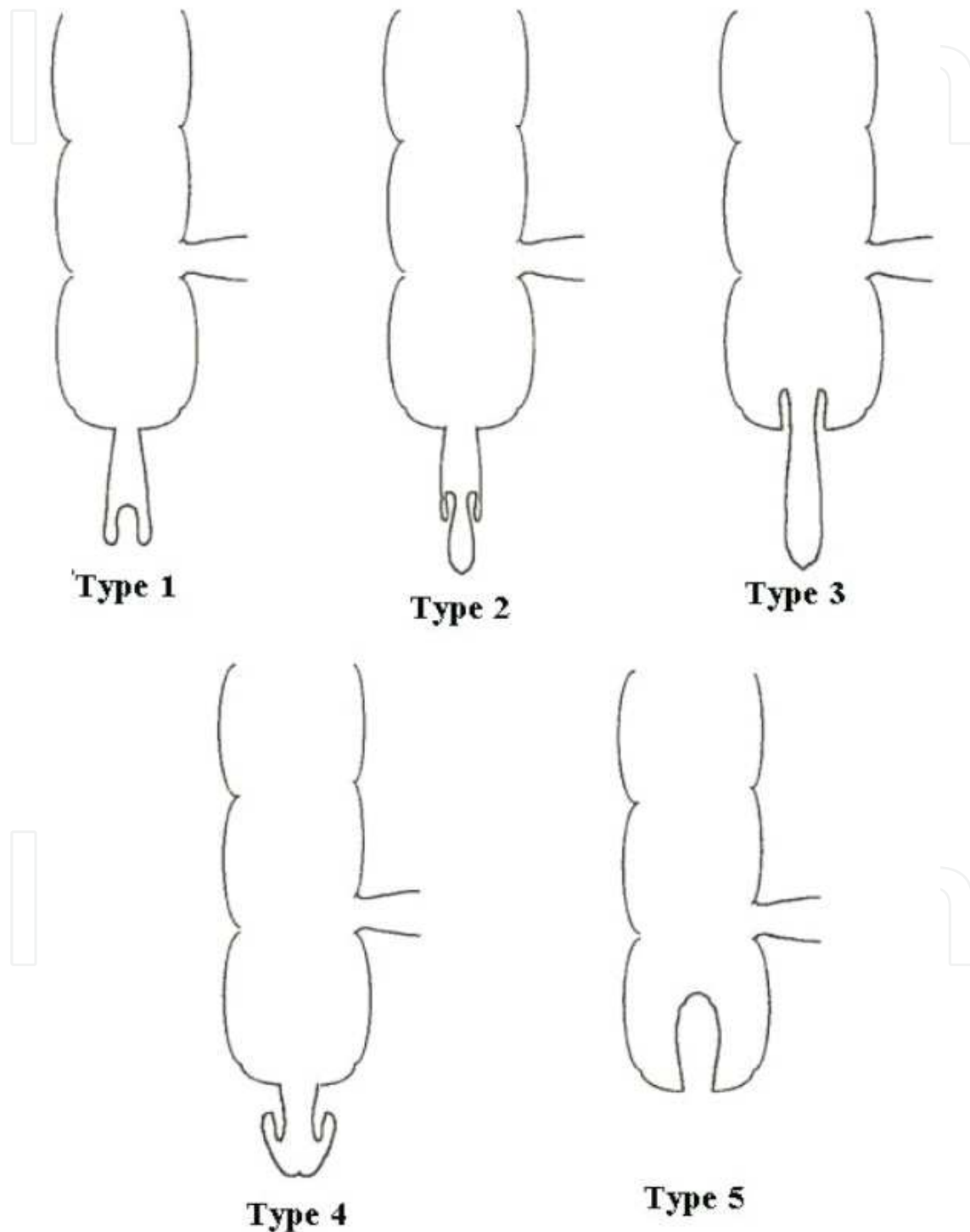


Fig. 1. Classification of appendiceal intussusception as proposed by McSwain in 1941 (Taban et al, 2006).

Type I: The tip of the appendix forms the intussusceptum and is invaginated into the proximal appendix, which is the intussusciens.

Type II: The invagination starts at some point along the length of the appendix. The intussusciens is the adjacent tissue.

Type III: The invagination starts at the junction of the appendix and caecum. The caecum is the intussusciens.

Type IV: This is retrograde intussusception, where the proximal appendix is invaginated into the distal appendix.

Type V: Complete invagination of the appendix into the caecum from progression of types I and II or type III. (Chaar et al, 2009).

All types of the previously described primary appendiceal intussusceptions, possibly with the exception of type IV, can initiate a secondary intussusception. The question of whether the intussuscepted appendix initiates a secondary intussusception presumably depends upon both the degree of irritation by its presence inside the caecum and the anatomy of the caecum. A fixed caecum is unlikely to intussuscept, whereas a mobile caecum with rotational anomaly may be more likely to produce intussusception (Atkinson et al, 1976). Characteristically, Dunavant and Wilson reported in 1952 the case of an intussuscepted appendix leading to complete colonic intussusception and protrusion of the inverted appendix from the anus as a mass (Dunavant & Wilson, 1952).

Langsam proposed in 1958 a simpler classification for appendiceal intussusception:

Type I begins at the tip of the appendix (the intussusceptum) which intussuscepts into its more proximal portion (the intussusciens).

Type II begins in the base of the appendix (intussusceptum) and the caecum is the intussusciens.

In **type III**, the base of the appendix is the intussusceptum received by the appendiceal tip.

Type IV refers to complete inversion of the appendix with accompanying ileocaecal intussusception, whereby the appendix remains the leading point of the intussusceptum.

This can result from types I and II of appendiceal intussusception (Salehzadeh et al, 2010).

Finally, Jacobs in 1963 argued that the term "intussusception of the appendix" should be reserved only for the condition in which the appendix intussuscepts into itself, in the same way that ileum intussuscepts into ileum in the ileo-ileal type of intussusception. This condition is equivalent to retrograde appendiceal intussusception, described as type IV by McSwain, and its rarity is pointed out by the fact that Collins in 1963 in a review of 71,000 human specimens after appendectomy found that particular lesion only in one case (Collins, 1963; Jacobs, 1963).

2.4.4 Etiology and predisposing conditions

The etiology of most cases of appendiceal intussusception remains unknown; however certain predisposing conditions are thought to make intussusception more likely to happen. Pathophysiological features that determine the invagination of the appendix can be divided in two large groups: anatomical and pathological.

Anatomical conditions are represented by:

- a fetal type of caecum, with the appendix originating from its tip
- a wide appendicular lumen with the proximal lumen having a greater diameter than its distal part
- a mesoappendix that is thin, free from fat and with a narrow base

- a mobile appendicular wall capable of active peristalsis
- an appendix that is free, unfixed by peritoneal folds or adhesions.

Most workers theorize that abnormal appendiceal peristalsis secondary to local irritation is the chief pathologic predisposing factor. The most commonly accepted view, which has been suggested by Rolleston in 1898, proposes that either an intramural or an intraluminal lesion produces irritation of the normal appendiceal peristaltic activity, which leads to an attempt by the appendix to extrude the offending lesion. The appendix itself undergoes strong peristaltic contractions which may become more vigorous if the appendiceal wall is irritated. This may lead to part of its wall being pushed in, or out, acting as the leading point for an intussusception. Spasm of the muscular sphincter at the base of the appendix might also form the apex of an intussusception. It seems likely as mentioned before that a combination of anatomical, physiological and minor pathological changes interact to produce this rare condition.

Local pathological irritants such as parasites, fecaliths, foreign bodies, neoplasms (polyps, mucocoeles, adenocarcinomas, carcinoid tumors), hypertrophic lymphoid follicles, mucocoeles, endometrial implants and postinflammatory scars have been implicated as predisposing lesions for the development of appendiceal intussusception (Atkinson et al, 1976; Gilipin, 1989; Komine et al, 2004; Taban et al, 2006).

In our clinic we have encountered the case of a calcified appendiceal mucocoele acting as the leading point for caecocolic intussusception (Varsamis et al, 2010). An intraoperative photo of the mucocoele after manual reduction of the caecocolic intussusception can be seen in **Fig. 2**.

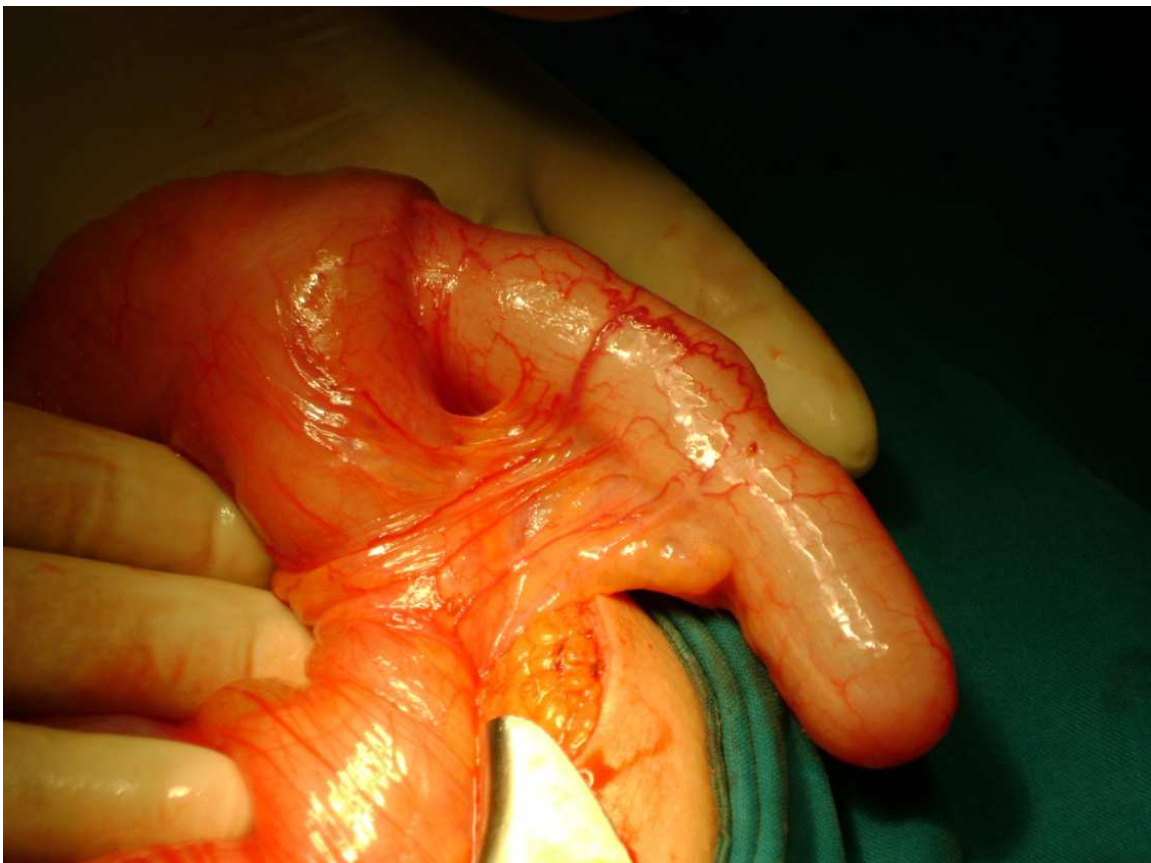

Fig. 2. Intraoperative photo of a large mucocoele with its base intussuscepted into the lumen of the caecum. **Type III** of appendiceal intussusception according to McSwain's classification. (From our clinic's photo archive).

Finally, cases where the inverted appendiceal stump after appendectomy acted as the leading point for a secondary ileo-colic intussusception have been described in the literature. Those cases comprise mainly pediatric and young adult male patients, with the intussusception taking place commonly during the first few post-operative days. When the appendiceal stump is inverted into the caecum after appendectomy, conceivably a leading point for intussusception could be created. Yeager in 1947 studied methods of appendiceal stump closure and showed that an inverted stump was more intramural than intraluminal. However, swelling and inflammatory reaction caused by a foreign body at the site of an intramural stump could encroach on the caecal lumen sufficiently to be caught in normal peristalsis and lead to intussusception (Arora et al, 2008; Bridger, 1956; Hanson et al, 1967; Lipskar et al, 2008; Yeager, 1947).

2.4.5 Histopathological findings

Histopathological examination of the intussuscepted appendix and results were reported in 153 cases used by Chaar in his review. We added the histopathological findings of our 29 new cases to those previously mentioned and gathered a total of 182 results concerning cases of appendiceal intussusception.

Inflammatory lesions consistent with acute appendicitis were reported in 51 patients suffering from appendiceal intussusception. Inflammation was the most frequent histopathological finding with a percentage of occurrence estimated in 28%. The second commonest diagnosis was endometrial implants in the intussuscepted appendix, which was found in 43 female patients (23.6%). Simple mucoceles (Fig.3) acted as the leading points for intussusception in 29 cases (15.9%) and mucinous cystadenomas in 8 cases (4.4%). Adenomas of the intussuscepted appendix were diagnosed in 14 patients (7.7%), adenocarcinomas in 8 patients (4.4%), carcinoid tumors in 9 patients (4.9%) and histopathological findings of neuroendocrine carcinoma with a metastatic lymph node were reported in 1 patient (0.55%). Other tumors of the intussuscepted appendix comprised 1 case of papilloma (0.55%), 1 case of hamartoma (0.55%) and 1 case of juvenile polyp (0.55%).

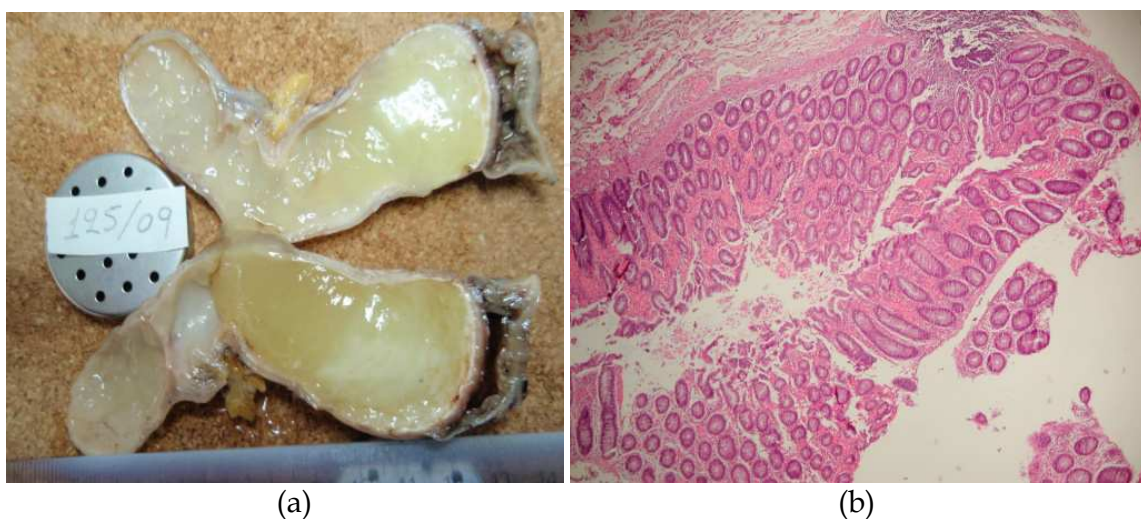


Fig. 3. **(a)** Gross section of the simple mucocele shown in Figure 2, with its lumen full of yellow, gelatinous mucus. **(b)** Histopathological image of the same mucocele showing mucus producing glands in its wall, with no elements of cellular atypia (H&E Stain x 100. From our clinic's photo archive).

Moreover, 1 patient with Mucosa Associated Lymphoid Tissue (MALT) Lymphoma (0.55%) and also 1 patient (0.55%) with ileo-caecal Non-Hodgkin Lymphoma (NHL) were encountered in the literature. In total, 74 patients (40.6%) suffered from a primary benign or malignant neoplasia of the vermiform appendix which took place in the development of a secondary appendiceal intussusception.

Other less common lesions found at histopathological examination were 3 cases of appendiceal distention due to Cystic Fibrosis (1.65%), 2 cases of an inverted appendiceal stump with no elements of inflammation (1.1%), 2 cases of colonoscopically taken biopsies which revealed normal appendiceal mucosa (1.1%), 2 cases of fecalith material (1.1%), 1 case of a granuloma due to Crohn's Disease (0.55%), 1 case of microscopic melanosis coli (0.55%), 1 case with angiodysplastic foci in the appendix causing anemia (0.55%), 1 case of Schistosomiasis with occupation of the appendiceal base and several lymph nodes by Schistosome's eggs (0.55%) and 1 final case with simple lymphoid hyperplasia of the appendix (0.55%).

In the pediatric age group, 23 out of 36 patients having an histopathological examination came with the final diagnosis of appendiceal inflammation (63.9%). Inflammation was the commonest diagnosis in children because other lesions causing appendiceal intussusception like tumors normally emerge in adolescence. In the adult group of patients endometriosis of the appendix was the commonest diagnosis, with 43 reported women out of 146 patients (29.5%). Finally, simple mucocele and inflammation, both encountered in 26 out of 146 patients (17.8%), were the second commonest lesions causing appendiceal intussusception in adults.

2.4.6 Clinical presentation

Symptoms of appendiceal intussusception have classically been divided into four groups. In the first group, onset of symptoms is abrupt similarly to acute appendicitis and these cases are frequently taken to surgery with the diagnosis of acute appendicitis. At operation partial or complete intussusception of the appendix is found.

In the second group, the symptoms are consistent with intestinal intussusception. Abdominal pain and vomiting usually occur for several days. Bowel movements may be normal. Less commonly, there may be constipation, diarrhea or melena. Examination frequently reveals an abdominal mass which is recognized as an underlying intussusception. These cases have a compound intussusception and the appendiceal invagination is discovered only after the main intussusception has been reduced either by surgery or by barium enema examination.

A third group includes cases with a prolonged history of repeated intermittent severe attacks of right lower quadrant abdominal pain. Vomiting and melena may be present. The interval between the attacks is quite variable. Physical examination between attacks is unrevealing. The acute pain can be due to intermittent secondary intussusception which follows intussusception of the appendix. A patient with a history of multiple attacks of intermittent abdominal pain deserves a thorough clinical and radiological examination with the possibility of appendiceal intussusception considered in the differential diagnosis.

There is a fourth group of patients in which primary appendiceal intussusception is asymptomatic. In these cases, appendiceal intussusception is described as an incidental finding in screening colonoscopic or radiological investigation of the patient. Brewer and Wangenstein suggested in 1974 a fifth group, in which intermittent bleeding from rectum is found in otherwise asymptomatic patients (Atkinson et al, 1976).

In our material of 220 patients suffering from appendiceal intussusception the observed symptoms and signs had a variable frequency of presentation. Abdominal pain, reported in 161 out of 220 cases, turned out to be the commonest symptom with a percentage of 73.2%. It was mainly located in the right lower quadrant or periumbilically and its character was colicoid. Nausea and emesis were present in 56 out of 220 patients and followed in frequency with 25.5%. Blood per rectum or melena occurred in 47 patients and was the third commonest symptom (21.4 %). A mass could be palpated on physical examination of the abdominal wall in 38 patients (17.3%). Other symptoms or signs reported according to their frequency of existence were diarrhea in 28 cases (12.7%), constipation in 21 cases (9.5%), weight loss in 12 cases (5.5%), anorexia in 10 cases (4.5%), abdominal tenderness in 10 cases (4.5%) and bowel distention in 5 cases (2.3%). Finally, 3 patients were totally asymptomatic, representing 1.4% of cases.

2.4.7 Laboratory, radiological and colonoscopic investigation

Elaborate investigation of patients suffering from appendiceal intussusception is a very important parameter in the effort to reach a precise diagnosis. As mentioned before, in most cases patients referred with atypical and non-specific symptoms, like abdominal pain, nausea and constipation. Therefore, complete laboratory, radiological and colonoscopic examination should be performed to all the patients with obscure clinical presentation, in order to achieve a correct preoperative diagnosis.

Laboratory findings were not certain or specific according to the literature. In most cases, laboratory values and temperature were within normal limits. Leukocytosis with a polymorphonuclear white blood cell type were the commonest observed pathological findings. An elevated value of C-reactive protein (CRP) or mild pyrexia could be present in the event of co-existing inflammation. Moreover, anemia was reported in some cases where blood per rectum or melena were also observed. Finally, in two asymptomatic patients, screening blood tests revealed an increased serum γ -glutamyltranspeptidase (γ GTP) in the first and an elevated serum carcinoembryonic antigen (CEA) in the second one. Both patients suffered from appendiceal intussusception due to preexisting mucocoeles (Lu et al, 2009; Okuda et al, 2008).

In most cases of appendiceal intussusception, radiographical findings were normal, unless a small-bowel obstruction co-existed. "Air-fluid" levels of the small intestine could then be present in plain abdominal X-Ray films (Koumanidou et al, 2001; Varsamis et al, 2010).

Cases of appendiceal invagination were diagnosed during double-contrast barium enema examination, sometimes at asymptomatic patients. Levin *et al.* described in 1985 11 cases with characteristic radiological signs, like a "coiled-spring" sign in the caecum or nonfilling of the appendix. Radiological abnormalities included:

- no abnormality seen in the caecal region, with absence of the appendix
- oval or round bosselated intraluminal filling defects, usually in the medial wall of the caecum, with no visualization of the appendix (partial appendiceal invagination)
- intraluminal, "finger-like" filling defects within the caecum, usually arising from its medial wall (complete appendiceal invagination)
- reduction of the filling defect out of the caecum during fluoroscopy (Bachman & Clemett, 1971; Levine et al, 1985; Taban et al, 2006).

Ultrasonography has played a role in the diagnosis of appendiceal intussusception, especially in children. A "donut" sign or a "target" lesion is virtually diagnostic of

intussusception (Holt & Samuel, 1978). Appendiceal intussusception may appear as the “multiconcentric ring” sign on transverse scans, while longitudinal sonograms may show the inverted appendix protruding into the caecal lumen (Pumberger et al, 2000). Koumanidou et al in 2001 argued that the sonographic appearance of multiple concentric hypoechoic and hyperechoic rings is not characteristic of appendiceal intussusception but intussusception in general. She also claimed that visualization of the appendix within the head of the intussusception may be considered characteristic only when a small cyst or a “target-like” mass is demonstrated, having an outer diameter which should not exceed 6mm (Koumanidou et al, 2001). Tseng et al in 2006 reported a case of preoperative appendiceal intussusception diagnosis with endoscopic sonography, which revealed a multiconcentric ring structure in the region of the caecal base (Tseng et al, 2006). Appendiceal intussusception has been described as having a target, layered, sausage-shaped, or reniform appearance on CT; when present, this appearance is virtually pathognomonic (Luzier et al, 2006). Moreover, CT scans may reveal a mass lesion within the caecum, a thickened “sausage shaped” caecum and the pathognomonic bowel-within-bowel configuration (Fernandez-Rey et al, 2010). The limitations of CT primarily relate to its use of ionizing radiation and the risk of allergy to contrast material. However, CT can provide excellent anatomic detail in addition to assessing the presence of complications of intussusception. Last but not least, with modern CT scanners, isotropic voxel reconstructions in nonaxial planes provide additional diagnostic certainty by allowing direct visualization and differentiation of the distal ileum and ileocecal valve from the caecal tip and appendix (Luzier et al, 2006).

Sonographic and CT scanning images from a case of an intussuscepted appendiceal mucocele encountered by our clinic are shown in **Figure 4** below.

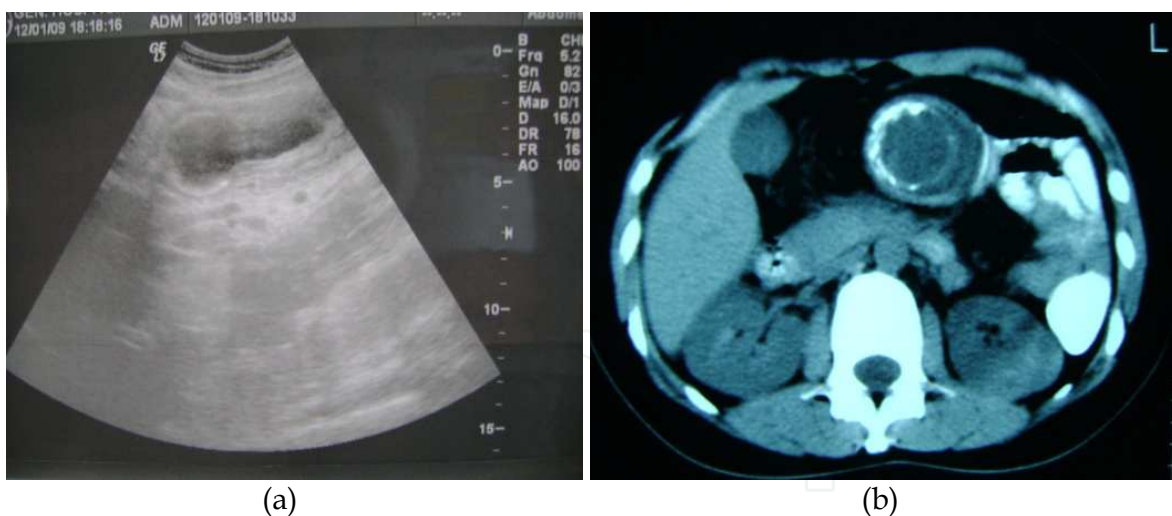


Fig. 4. **(a)** Abdominal ultrasound image, showing the intussuscepted appendiceal mucocele mentioned in previous figures, in a longitudinal cross section. **(b)** Abdominal CT scanning image, showing the calcified base of the same appendiceal mucocele intussuscepted into the lumen of the transverse colon. Pathognomonic “bowel-within-bowel” configuration. (From our clinic’s photo archive).

Finally, colonoscopy can play a very important role in the correct preoperative diagnosis of appendiceal intussusception. Most characteristic colonoscopic findings include a “mushroom-like”, polypoid lesion within the caecal lumen, which appears erythematous

and surrounds a central dimple corresponding to the appendiceal orifice. When air is insufflated, the dimple and mass may change appearance, becoming smaller or larger with peristalsis, or may even occur a total reduction of the appendiceal intussusception. If the intussusception has reduced on its own at the time of endoscopy, a central depression at the base of the caecum corresponding to the appendiceal lumen surrounded by an area of a halo type erythema can be seen (Ozuner et al, 2000). Therefore, careful endoscopic examination, with identification of the appendiceal orifice, should be required in all cases that recognition of a caecal polyp happens. Endoscopic removal of this lesion is associated with a high risk of subsequent peritonitis (Khawaja, 2002). Visualization of an appendiceal intussusception as a caecal polyp could also be achieved by means of CT colonogram scanning (Salehzadeh et al, 2010)

2.4.8 Differential diagnosis

Differential diagnosis of appendiceal intussusception includes the case of an appendiceal abscess, a duplication cyst or the presence of an asymptomatic inverted appendiceal stump. Of the appendiceal or other regional malignant tumors, lymphomas are the most common in the pediatric age group. Other primary malignancies most commonly found in adults include adenocarcinomas and carcinoid tumors. Benign tumors comprising lipomas, leiomyomas, fibromas and hemangiomas are scarcely encountered. Mucoceles of the appendix are more frequent in female patients and occur in adults (Atkinson et al, 1976, Christianakis et al, 2008; Wang et al, 2010).

In a case of caecocolic intussusception involving a calcified mucocele participating in the intussusception that was encountered by our surgical clinic, differential diagnosis included an inflamed Meckel's diverticulum and a mesenteric cyst. Final diagnosis was achieved intraoperatively after the reduction of the intussuscepted mucocele (Varsamis et al, 2010).

2.4.9 Methods of treatment

The treatment of the intussuscepted appendix can be conservative, minimally invasive or surgical. The choice must be done according to the patient's age, co morbidities, recurrence and risk of a neoplasm.

The intussuscepted appendix may be reduced with a barium enema if the diagnosis is certain, especially in children. However, there is a high recurrence rate (Kleiman, 1980). No more than 90 cm of hydrostatic pressure should be applied to avoid complications. Alternatively, air may be introduced via a rectal tube to produce caecal distention. If the attempt is successful and the appendix is completely filled, a close follow-up is indicated to early diagnose recurrence. Unlike children, reduction by barium enema or air is not suggested for adults, especially for patients over 60 years old. The reason is that adults have leading points which are frequently neoplastic (Patton & Ferrera, 2000).

Minimally invasive treatment includes colonoscopy, which should be done when the diagnosis of appendiceal intussusception is suspected. During colonoscopy, the intussusception may be reduced by performing several insufflations of air. This would result in a halo-like erythematous region surrounding the appendiceal lumen (Tavakkoli et al, 2007). It is crucial to avoid endoscopic removal because perforation and subsequent peritonitis are common and serious complications (Fazio et al, 1982). Resection with looping and snare retrieval should be performed by experienced gastroenterologists and when the

diagnosis is certain. If partial intussusception exists, colonoscopic appendectomy should be avoided (de Hoyos et al, 2006; Tavakkoli et al, 2007).

The treatment of choice for the appendiceal intussusception is surgical removal of the appendix either with laparotomy or laparoscopically. Appendectomy is the most common treatment in adults. If it is possible, an attempt to reduce the appendix should be made. The surgeon should try to milk out the intussuscepted appendix in a distal to proximal direction (Wolff & Boller, 2008). If the intussusception is not reducible, caecotomy (along a taenia band) should be performed to reduce it manually. Simple appendectomy should follow in every case (Nycum et al, 1999).

In pediatric patients the treatment of choice is the laparoscopic approach. In these cases, laparoscopic reduction is successful in 50% to 65% (Poddoubnyi et al, 1998; Schier, 1997). Inversion appendectomy is an option due to its aseptic benefit (Arora et al, 2008). However, the complication of intussusception after inversion appendectomy has been reported in 0,08% to 8% in children (Kidd et al, 2000).

Exploratory laparotomy is the management of choice if there is any suspicion of appendiceal mass, caecal neoplasm or compound ileocaecal-appendiceal intussusception. Right hemicolectomy with lymph node resection is the treatment of choice when the tumor is larger than 2 cm in diameter or when malignancy is suspected. Otherwise, simple appendectomy may be sufficient (Chen & Chiang, 2000). Special care must be taken in cases of mucoceles. Benign mucinous tumors are cured with appendectomy (simple excision); malignant lesions require right hemicolectomy if they are resectable (Connor et al, 1998; Rutledge & Alexander, 1992). The surgeon must avoid tumor rupture because mucinous cystadenocarcinoma can cause pseudomyxoma peritonei (Holder et al, 1989). In case of pseudomyxoma peritonei, treatment should include appendectomy, omentectomy and in females bilateral oophorectomy. Intraperitoneal chemotherapy may be useful (Hinson & Ambrose, 1998).

Other procedures include ileocaecal resection and partial caecectomy. In the latter case, a caecal cuff or a bigger part of the caecum should be resected. These procedures have the advantage of eliminating the appendiceal stump and resecting any appendiceal lesion in a safe margin (Chaar et al, 2009). In cases of mobile caecum or ascending colon, these structures could be attached to the lateral abdominal wall by sutures (Bridger, 1956).

Finally, some authors suggest that surgical intervention may be unnecessary in patients with long-standing asymptomatic appendiceal intussusception. A close follow up is indicated in these cases (Salehzaden et al, 2010).

2.4.10 Complications

The majority of patients suffering from appendiceal intussusception that received a surgical procedure had an uneventful postoperative course according to the literature. Only few cases had vague abdominal pain or discomfort. The symptoms subsided with conservative treatment.

Serious complications emerged after colonoscopic intervention in some cases of appendiceal intussusception. These included symptoms of pain and tenderness in the right lower abdominal quadrant or even bowel perforation and peritonitis after endoscopic removal of the intussuscepted appendix. Treatment of these patients varied from simple antibiotic medication to emergent surgical exploration (Fazio et al, 1982; Wirtschafter & Kaufman, 1976). In addition, systemic bacterial infection with fever and shivering has also been described in the literature, after simple endoscopic biopsies taken from an

intussuscepted appendix. Symptoms retreated with broad spectrum antibiotherapy (Seddik & Rabhi, 2011).

Special care should be taken in cases of simple appendectomy after reduction of the appendiceal intussusception, when the appendiceal stump is inverted with a purse-string suture into the caecal wall. It could act as the leading point for a new intussusception, as mentioned in a previous chapter of this essay.

Otherwise, potential complications are the same as those encountered after performing appendectomy or right hemicolectomy. Complications after appendectomy include injury to the bowel or to other adjacent structures, intra-abdominal abscess, surgical site infection and colonic fistula.

Complications after right hemicolectomy could be divided in three categories: intraoperative and technical, early and late postoperative complications. Intraoperative and technical complications include injury to the right ureter, to the duodenum, to the other bowel (such as deserosalizations), inadequate blood supply to the anastomosis, anastomosis under tension, stool and tumor cell spillage. Early postoperative complications include surgical site infection, anastomotic leak, intra-abdominal abscess and colcutaneous fistula. Late postoperative complications include anastomotic stricture, incisional and internal hernia, ureteral stricture and adhesions (Minter & Doherty, 2010).

3. Conclusions

Early recognition of appendiceal intussusception is important in avoiding misdiagnosis and misguided attempts at endoscopic removal or inappropriate surgery. An appendiceal intussusception may be mistaken for a polyp or carcinoma, and failure to accurately diagnose this condition has resulted in patients undergoing colonoscopic polypectomy with resultant perforation and peritonitis. Alternatively, patients have also undergone unnecessary hemicolectomy when the intussuscepted appendix is regarded as a malignancy.

Although reduction of the intussuscepted appendix may occur via increased caecal luminal pressure from barium enema or colonoscopy, the definitive treatment requires surgical resection. Finally, in those cases involved by a concurrent malignant tumor, reduction at laparotomy or laparoscopy with subsequent appendectomy and right hemicolectomy is the surgical treatment of choice (Duncan et al, 2005).

Complete invagination of the appendix is a condition with rare occurrence. If the appendix on laparotomy or laparoscopy cannot be found, this diagnosis should be considered and actively ruled out. Negative laparoscopy for acute appendicitis can only be negative if a normal appendix is seen (Vogelaar et al, 2004).

Finally, many surgeons continue to perform inversion appendectomy due to its aseptic benefit. This benefit, though potentially important, has never been strongly proven in the literature. With the advent of new stapling devices and the increased experience with laparoscopic appendectomies, the need for inversion appendectomy should be readdressed, since the inverted appendiceal stump has been described in literature as the leading point for ileo-colic intussusception (Arora et al, 2008).

4. References

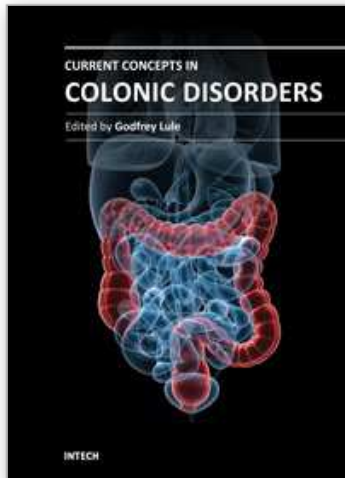
Anson B.J, Mc Vay C.B (1971). *Surgical anatomy*, (5th ed.) W. B. Saunder Company, pp. 745-834, ISBN 0721612954, Philadelphia-USA.

- Arora A, Caniano AD, Hammond S, Besner GE (2008). Inversion appendectomy acting as a lead point for intussusceptions. *Pediatric Surgery International*, Vol. 24, No. 11, (November 2008), pp. 1261-1264, ISSN 1437-9813.
- Atkinson GO, Gay BB, Naffis D (1976). Intussusception of the appendix in children. *American Journal of Roentgenology*, Vol. 126, No. 6, (June 1976), pp. 1164-1168, ISSN 0361-803X.
- Bachman AL., Clemett AR (1971). Roentgen aspects of primary appendiceal intussusception. *Radiology*, Vol. 101, No. 3, (December 1971), pp. 531-538, ISSN 1527-1315.
- Bridger JE (1956). Ileo-colic intussusception after appendicectomy. *British Medical Journal*, Vol. 2, No. 4995, (September 1956), pp. 755, ISSN 0959-8138.
- Chaar CI, Waxelman B, Zuckerman K, Longo W (2009). Intussusception of the appendix: a comprehensive review of the literature. *The American Journal of Surgery*, Vol. 198, No.1, (July 2009), pp. 122-128, ISSN 0002-9610.
- Chen YC, Chiang JM (2000). Appendiceal intussusception with adenocarcinoma mimicking a cecal polyp. *Gastrointestinal Endoscopy*, Vol. 52, No. 1, (July 2000), pp. 130-131, ISSN 1097-6779.
- Christianakis E, Sakelaropoulos A, Papantzimas C, Pitiakoudis M, Filippou G, Filippou D, Rizos S, Pascalidis N (2008). Pelvic plastron secondary to acute appendicitis in a child presented as appendiceal intussusceptions. A case report. *Cases Journal*, Vol. 1, No. 1, (September 2008), pp. 135-138, ISSN 1757-1626.
- Collins DC (1963). 71,000 human appendix specimens. A final report, summarizing forty years' study. *American journal of Proctology*, Vol. 14, (December 1963), pp. 265-281, ISSN 0002-9521.
- Connor SJ, Hanna GB, Frizelle FA (1998). Appendiceal tumors: retrospective clinicopathologic analysis of appendiceal tumors from 7,970 appendectomies. *Diseases of the Colon and Rectum*, Vol. 41, No. 1, (January 1998), pp. 75-80, ISSN 1530-0358.
- de Hoyos A, Monroy MA, Gallegos C, Checa G (2006). Intussusception of the appendix resected at colonoscopy. *Endoscopy*, Vol. 38, No. 7, (March 2006), pp. 763, ISSN 0013726X.
- Dunavant D, Wilson H (1952). Intussusception of the appendix, with complete inversion of the appendix and protrusion from the anus. *Annals of Surgery*, Vol. 135, No. 2, (February 1952), pp.287-288, ISSN 1528-1140.
- Duncan JE, DeNobile JW, Sweeney WB (2005). Colonoscopic Diagnosis of Appendiceal Intussusception: Case Report and Review of the Literature. *Journal of the Society of Laparoendoscopic Surgeons*, Vol. 9, No. 4, (October-December 2005), pp. 488-490, ISSN 1086-8089.
- Fazio RA, Wickremesinghe PC, Arsura EL, Rando J (1982). Endoscopic removal of an intussuscepted appendix mimicking a polyp-an endoscopic hazard. *American Journal of Gastroenterology*, Vol. 77, No. 8, (August 1982), pp. 556-558, ISSN 1572-0241.
- Fernandez-Rey CL, Garcia C, Alvarez Blanco AM (2010). Appendicular mucocele as cause of intestinal intussusception: diagnostic by computer tomography. *Revista Espanola De Enfermedades Digestivas*, Vol. 102, No. 10, (October 2010), pp. 604-605, ISSN 1130-0108.

- Fink VH, Al S, Goldberg SL (1964). Intussusception of the appendix. Case reports and reviews of the literature. *American Journal of Gastroenterology*, Vol. 42, (October 1964), pp. 431-441, ISSN 0002-9270.
- Gilpin D (1989). Intussusception of the appendix. *The Ulster Medical Journal*, Vol. 58, No. 52, (October 1989), pp 193-195, ISSN 0041-6193.
- Hanson EL, Goodkin L, Pfeffer RB (1967). Ileocolic intussusception in an adult caused by a granuloma of the appendiceal stump: report of a case. *Annals of Surgery*, Vol. 66, No. 1, (July 1967), pp. 150-152, ISSN 1528-1140.
- Hinson FL, Ambrose NS (1998). Pseudomyxoma peritonei. *The British Journal of Surgery*, Vol. 85, No. 10, (October 1998), pp. 1332-1339, ISSN 1365-2168.
- Holder PD, Fehir KM, Schwartz MR, Smigocki G, Madewell JE (1989). Primary mucinous cystadenocarcinoma of the appendix with pseudomyxoma peritonei manifested as a splenic mass. *Southern Medical Journal*, Vol.82, No. 8, (August 1989), pp. 1029-1031, ISSN 1541-8243.
- Holt S, Samuel E (1978). Multiple concentric ring sign in the ultrasonographic diagnosis of intussusceptions. *Gastrointestinal Radiology*, Vol. 3, No. 3, (August 1978), pp. 307-309, ISSN 0364-2356.
- Jacobs R (1963). Intussusception of the appendix. *Canadian Medical Association Journal*, Vol. 89, (September 1963), pp. 620-621, ISSN 1488-2329.
- Jevon GP, Daya D, Qizilbash AH (1992). Intussusception of the appendix: a report of four cases and review of the literature. *Archives of Pathology & Laboratory Medicine*, Vol. 116, No. 9, (September 1992), pp. 960-964, ISSN 1543-2165.
- Khawaja FI (2002). Diseases of the appendix recognized during colonoscopy. *Saudi Journal of Gastroenterology*, Vol. 8, No. 2, (May 2002), pp. 43-52, ISSN 1319-3767.
- Kidd J, Jackson R, Wagner CW, Smith SD (2000) Intussusception following the Ladd procedure. *Archives of Surgery*, Vol. 135, No. 6, (June 2000), pp. 713-715, ISSN 0096-6908.
- Kim YH, Blake MA, Harisinghani MG et al (2006). Adult intestinal intussusceptions: CT appearances and identification of a causative lead point. *Radiographics*, Vol. 26, No. 3, (June 2006), pp. 733-744, ISSN 1527-1323.
- Kleinman PK (1980). Intussusception of the appendix: hydrostatic reduction. *American Journal of Roentgenology*, Vol. 134, No. 6, (June 1980), pp. 1268-1270, ISSN 1546-3141.
- Komine N, Yasunaga C, Nakamoto M, Shima I, Iso Y, Takeda Y, Nakamata T (2004). Intussusception of the appendix that reduced spontaneously during follow-up in a patient on hemodialysis therapy. *Internal Medicine*, Vol. 43, No. 6, (June 2004), pp. 479-483, ISSN 1349-7235.
- Koumanidou C, Vakaki M, Theofanopoulou M, Nikas J, Pitsoulakis G, Kakavakis K (2001). Appendiceal and appendiceal-ileocolic intussusception: sonographic and radiographic evaluation. *Pediatric Radiology*, Vol. 31, No. 3, (March 2001), pp. 180-183, ISSN 1432-1998.
- Levine MS, Trenkner SW, Herlinger H, et al (1985). Coiled-spring sign of appendiceal intussusception. *Radiology*, Vol. 155, No. 1, (April 1985), pp. 41-44, ISSN 1527-1315.
- Lipskar A, Telem D, Masseur J, Midullab P, Dolgina S (2008). Failure of appendectomy to resolve appendiceal intussusception. *Journal of Pediatric Surgery*, Vol. 43, No. 8, (August 2008), pp. 1554-1556, ISSN 1531-5037.

- Lu IT, Ko CW, Chang CS, Hou TC (2009). Asymptomatic intussusceptions secondary to a giant appendiceal mucocele treated via a laparoscopic approach. *Gastrointestinal Endoscopy*, Vol. 70, No. 5 (November 2009), pp. 1026-1027, ISSN 1097-6779.
- Luzier J, Verhey P, Dobos N (2006). Preoperative CT diagnosis of appendiceal intussusception. *American Journal of Roentgenology*, Vol. 187, No. 3, (September 2006), pp. 325-326, ISSN 1546-3141.
- Marinis A, Yiallourou A, Samanides L, Dafnios N, Anastasopoulos G, Vassiliou I, Theodosopoulos T (2009). Intussusception of the bowel in adults: A review. *World Journal of Gastroenterology*, Vol.15, No.4, (January 2009), pp. 407-411, ISSN 1007-9327.
- McKidd J (1858). Case of invagination of caecum and appendix. *Edinburgh Medical Journal*, Vol. 4, pp.793-797, ISSN 0367-1038.
- Minter R, Doherty G (2010). Appendectomy, Colectomy. In: *Current procedures: Surgery*, (1st ed), Mc Graw Hill, pp. 156-160 & 180-191, ISBN 978-0-07-145316-5, USA.
- Nycum LR, Moss H, Adams JQ, Macri CI (1999). Asymptomatic intussusceptions of the appendix due to endometriosis. *Southern Medical Journal*, Vol. 92, No. 5, (May 1999), pp. 524-525, ISSN 1541-8243.
- Okuda I, Matsuda M, Noguchi H, Kokubo T, (2008). Massive mucinous cystadenoma of the appendix with intussusception in an adult: usefulness of reconstructed computed tomography images. *Radiation Medicine*, Vol. 26, No. 2, (February 2008), pp. 88-91, ISSN 0288-2043.
- Ozuner C, Davidson P, Church J (2000). Intussusception of the vermiform appendix: preoperative colonoscopic diagnosis of two cases and review of the literature. *International Journal of Colorectal Disease*, Vol. 15, No. 3 , (June 2000), pp. 185-187, ISSN 1432-1262.
- Patton KR, Ferrera PC (2000). Intussusception of a normal appendix. *American Journal of Emergency Medicine*, Vol. 18, No. 1, (January 2000), pp. 115-117, ISSN 0735-6757.
- Poddoubnyi IV, Dronov AF, Blinnikov OI, Smirnov AN, Darenkov IA, Dedov KA(1998). Laparoscopy in the treatment of intussusceptions in children. *Journal of Pediatric Surgery*, Vol. 33, No. 8, (August 1998), pp. 1194-1197, ISSN 1531-5037.
- Pumberger W, Hormann M, Pomberger G, Hallwirth U (2000). Sonographic diagnosis of intussusception of the appendix vermiformis. *Journal of Clinical Ultrasound*, Vol. 28, No. 9, (November-December 2000), pp. 492- , ISSN 1097-0096.
- Rutledge RH, Alexander JW (1992). Primary appendiceal malignancies: rare but important. *Surgery*, Vol. 111, No. 3, (March 1992), pp. 244-250, ISSN 1816-3211.
- Ryu BY, Kim TH, Jeon JY, Kim HK, Choi YH, Baik GH (2005). Colonoscopic Diagnosis of Appendiceal Intussusception: A Case Report. *Journal of Korean Medical Science*, Vol. 20, No.4, (August 2005),pp.680-682, ISSN 1011-8934.
- Salehzadeh A, Scala A, Simson JNL (2010).Appendiceal intussusceptions mistaken for a polyp at colonoscopy: case report and review of the literature. *Annals of Royal College of Surgeons England*, Vol.92, No.6 , (September 2010), pp. 46-48, ISSN 1478-7083.
- Sbarounis C (1991). Diseases of the vermiform appendix. In: *General Surgery*, (1st ed.), University studio press, pp. 874-885, ISBN: 960-12-0303-6, Thessaloniki-Greece.
- Schier F (1997). Experience with laparoscopy in the treatment of intussusceptions. *Journal of Pediatric Surgery*, Vol. 32, No. 12, (December 1997), pp. 1713-1714 , ISSN 1531-5037.

- Schumpelick V, Dreuw B, Ophoff K, Prescher A (2000). Appendix and cecum. Embryology, anatomy and surgical applications. *The Surgical Clinics of North America*, Vol. 80, No. 1, (February 2000), pp. 295-318, ISSN 0039-6109.
- Seddik H, Rabhi M (2011). Two cases of appendiceal intussusception : a rare diagnostic pitfall in colonoscopy. *Diagnostic and Therapeutic Endoscopy*; 2011:198984. Epub 2011 Apr 12, ISSN 1070-3608.
- Snell S.R (2008). The Abdomen: Part II-The Abdominal Cavity In: *Clinical anatomy by regions*, (8th ed.), Lippincott Williams & Wilkins, pp. 230-232, ISBN-13: 978-0-7817-6404-9, ISBN-10: 0-7817-6404-1, Philadelphia/Baltimore-USA.
- Taban S, Dema A, Lazar D, Sporea I, Lazar E, Cornianu M (2006). An unusual "tumor" of the cecum: the inverted appendiceal stump. *Romanian Journal of Morphology and Embryology*, Vol. 47, No. 2, (September 2006), pp. 193-196, ISSN 1220-0522.
- Tavakkoli H, Sadrkabir SM, Mahzouni P (2007). Colonoscopic diagnosis of appendiceal intussusceptions in a patient with intermittent abdominal pain: a case report. *World Journal of Gastroenterology*, Vol. 13, No. 31, (August 2007), pp. 4274-4277, ISSN 1007-9327.
- Tseng PH, Lee YC, Chiu HM, Wu MS, Lin JT, Wang HP (2006). Appendiceal intussusception diagnosed with endoscopic sonography. *Journal of Clinical Ultrasound*, Vol. 34, No. 7, (September 2006), pp. 348-351, ISSN 1097-0096.
- Varsamis N, Theodosiou A, Voulalas G, Papadopoulou H, Pakataridis A, Manafis K, Christodoulidis K(2010). Caecocolic Intussusception Involving Calcified Mucocele of the Appendix. *Hellenic Journal of Surgery*, Vol. 82, No. 2, (July - August 2010), pp. 252-256, ISSN 0018 - 0092.
- Vogelaar FJ, Molenaar IQ, Adhin S, Steenvoorde P (2004). Invagination of the appendix: Diagnostic laparoscopy? *Digestive Diseases and Sciences*, Vol. 49, No. 2, (February 2004), pp. 351-352, ISSN 1573-2568.
- Wang SM, Huang FC, Wu CH, Ko SF, Lee SY, Hsiao CC (2010). Ileocecal Burkitt's Lymphoma presenting as ileocolic intussusceptions with appendiceal invagination and acute appendicitis. *Journal of the Formosan Medical Association*, Vol. 109, No. 6, (June 2010), pp. 476-479, ISSN 0929-6646.
- Wirtschafter SK, Kaufman H (1976). Endoscopic appendectomy. *Gastrointestinal Endoscopy*, Vol. 22, No. 3, (February 1976), pp. 173-174, ISSN 1097-6779.
- Wolff BC, Boller AM (2008). Large bowel obstruction. In: *Current surgical therapy*, (9th ed.), Cameron JL, Mosby Elsevier, pp. 189-192, ISBN 978-1-4160-3497-1, Philadelphia-USA.
- Yeager GH (1947). The appendiceal stump. *Annals of Surgery*, Vol.126, No. 5, (November 1947), pp. 814-819, ISSN 1528-1140.



Current Concepts in Colonic Disorders

Edited by Dr. Godfrey Lule

ISBN 978-953-307-957-8

Hard cover, 276 pages

Publisher InTech

Published online 05, January, 2012

Published in print edition January, 2012

The 21st Century has seen a resurgence of research of the gastrointestinal tract, especially since it was established that it plays a central role as an immune system organ and consequentially has a huge impact on causation, impact and transmission of most human ailments. New diseases such as the Acquired Immunodeficiency Syndrome, hepatitis and tumours of the gastrointestinal tract have emerged and they are currently subjects of intensive research and topics of scientific papers published worldwide. Old diseases like diarrhea have become extremely complex to diagnose with new and old pathogens, drugs, tumours and malabsorptive disorders accounting for the confusion. This book has set out algorithms on how to approach such conditions in a systematic way both to reach a diagnosis and to make patient management cheaper and more efficient. "Current Concepts in Colonic Disorders" attempts to put all the new information into proper perspective with emphasis on aetiopathogenesis and providing rational approach to management of various old and new diseases. As the book editor, I have found this first edition extremely interesting and easy to understand. Comments on how to improve the content and manner of presentation for future editions are extremely welcome.

How to reference

In order to correctly reference this scholarly work, feel free to copy and paste the following:

Nikolaos Varsamis, Konstantinos Pougouras, Nikolaos Salveridis, Aekaterini Theodosiou, Eftychios Lostoridis, Georgios Karageorgiou, Athanasios Mekakas and Konstantinos Christodoulidis (2012). Appendiceal Intussusception, Current Concepts in Colonic Disorders, Dr. Godfrey Lule (Ed.), ISBN: 978-953-307-957-8, InTech, Available from: <http://www.intechopen.com/books/current-concepts-in-colonic-disorders/appendiceal-intussusception>

INTECH
open science | open minds

InTech Europe

University Campus STeP Ri
Slavka Krautzeka 83/A
51000 Rijeka, Croatia
Phone: +385 (51) 770 447
Fax: +385 (51) 686 166
www.intechopen.com

InTech China

Unit 405, Office Block, Hotel Equatorial Shanghai
No.65, Yan An Road (West), Shanghai, 200040, China
中国上海市延安西路65号上海国际贵都大饭店办公楼405单元
Phone: +86-21-62489820
Fax: +86-21-62489821

© 2012 The Author(s). Licensee IntechOpen. This is an open access article distributed under the terms of the [Creative Commons Attribution 3.0 License](#), which permits unrestricted use, distribution, and reproduction in any medium, provided the original work is properly cited.

IntechOpen

IntechOpen