

# We are IntechOpen, the world's leading publisher of Open Access books Built by scientists, for scientists

**4,800**

Open access books available

**122,000**

International authors and editors

**135M**

Downloads

Our authors are among the

**154**

Countries delivered to

**TOP 1%**

most cited scientists

**12.2%**

Contributors from top 500 universities



**WEB OF SCIENCE™**

Selection of our books indexed in the Book Citation Index  
in Web of Science™ Core Collection (BKCI)

Interested in publishing with us?  
Contact [book.department@intechopen.com](mailto:book.department@intechopen.com)

Numbers displayed above are based on latest data collected.

For more information visit [www.intechopen.com](http://www.intechopen.com)



## An Expansible Aortic Ring for a Standardized and Physiological Approach of Aortic Valve Repair

Emmanuel Lansac<sup>1</sup>, Isabelle Di Centa<sup>2</sup>, Rémi Escande<sup>3</sup>, Maguette Ba<sup>3,4</sup>, Nizar Kellil<sup>3</sup>, Eric Arnaud Crozat<sup>5</sup>, Eric Portocarrero<sup>6</sup>, Aicha Abed<sup>3,4</sup>, Anthony Paolitto<sup>7</sup>, Mathieu Debauchez<sup>1</sup> and Anne Meddahi- Pellé<sup>3,4</sup>

<sup>1</sup>*Institut Mutualiste Montsouris, Cardiovascular Surgery Department, Paris*

<sup>2</sup>*Vascular Surgery Department, Foch Hospital, Suresnes*

<sup>3</sup>*Inserm U698, Bioengineering for Cardiovascular Imaging and Therapy Team CHU Xavier Bichat, Paris*

<sup>4</sup>*IUT Saint Denis, Paris 13 University*

<sup>5</sup>*Cardiac Surgery Department, La Tronche Hospital,*

<sup>6</sup>*Cardiac Surgery Nancy Hospital, Nancy,*

<sup>7</sup>*CoroNéo Inc, Montreal*

<sup>1,2,3,4,5,6</sup>*France*

<sup>7</sup>*Canada*

### 1. Introduction

Dystrophy of the ascending aorta is the main etiology of thoracic aortic aneurysms and/or pure aortic insufficiency (tricuspid or bicuspid valves) operated in western countries (Iung et al., 2003; Roberts et al., 2006). It includes two phenotypes depending on whether the sinuses of Valsalva and/or supracoronary aorta are dilated: 1) isolated AI and/or supracoronary aneurysm (sinuses of Valsalva < 40 mm); 2) aortic root aneurysms (sinuses of Valsalva > 45 mm) (Lansac et al., 2008). Until recently, prosthetic valve replacement was the only surgical option for AI, performing either isolated valve replacement, composite valve and graft replacement or supracoronary graft and/or valve replacement. However, none of the current valve substitutes are ideal options, since mechanical valves require life-long anticoagulation and bioprosthetic valves present the risk of reoperation (Houel et al., 2002). Inspired by mitral experience, reconstructive methods have been developed to treat AI, based on sparing or repairing the native aortic valve, while replacing or stabilizing the other components of the aortic root. The two original valve sparing procedures - remodeling of the aortic root and reimplantation of the aortic valve - focused on root reconstruction to reduce the dilated root diameters in order to restore proper valve function. "Remodeling" technique provides the most physiological reconstruction of the root, but it does not address the dilated annular base (Yacoub et al., 1983). Alternatively, the Reimplantation, as an inclusion technique, provides a subvalvular annuloplasty to the detriment of valve dynamics (David & Feindel, 1992). Numerous technical variations aimed to associate

preservation of aortic root dynamics with the treatment of dilated native annulus (Aicher et al., 2010; Hopkins, 2003). This results in a lack of standardization and limits their widespread application.

Furthermore, most failures with valve sparing techniques are due to residual cusp prolapse, either as a primary unrecognized lesion or secondary to an induced prolapse after root reconstruction. Despite its more frequent detection intra operatively, cusp prolapse remains challenging to evaluate and treat.

As restorations of both root geometry and cusp coaptation are the prerequisite for a successful valve sparing procedure, we propose a standardized aortic valve repair approach addressing both the aorta and the valve, associating a physiological reconstruction of the aortic root, with cusp resuspension and subvalvular external aortic ring annuloplasty (Lansac et al., 2005a, 2006, 2009, 2010a, 2010b, 2010c, 2011a, 2011b). Depending on the phenotype of the ascending aorta, physiological reconstruction of the root will be achieved through to the Remodeling technique (root aneurysm, sinuses of Valsalva  $\geq 45$  mm), or a supracoronary graft (supracoronary aneurysm, sinuses of Valsalva  $< 40$  mm). Subvalvular aortic annuloplasty is achieved through external implantation of a calibrated expansible aortic ring that reduces dilated diameters in diastole in order to increase valvular coaptation height, while maintaining root systolic expansibility (Lansac et al., 2009).

## 2. Anatomical landmarks for aortic valve repair

### 2.1 The ascending aorta: Descriptive anatomy

The ascending aorta may be defined as the ensemble of two distinct entities, separated by the sinotubular junction (STJ): (1) the aortic root, initial portion of the aorta that includes the aortic valve with its crown-shaped annulus, interleaflet triangles, coronary arteries ostia and sinuses of Valsalva and (2) the supracoronary aorta extending above the STJ up to the brachiocephalic trunk (Fig. 1) (Anderson et al., 1991; Lansac & Di Cesta, 2010c; Reid, 1970; Robicksek, 1991; Sutton et al., 1995). Coronary arterial ostia are more frequently located below the sinotubular junction, arising within the left and right sinuses of Valsalva and are named accordingly (Muriago et al., 1997; Tops et al., 2008; Turner & Navartnam, 1996). A recent study examining 169 patients using multislice computed tomography, showed that the mean distance from the basal attachment of the cusps to the left and right coronary ostia was  $14.4 \pm 2.9$  mm and  $17.2 \pm 3.3$  mm respectively (Tops et al., 2008).

The aortic annulus is not planar since it is formed by the semilunar insertion of the cusps that extend from their basal attachments within the left ventricle (aortic annular base) to their distal attachments at the STJ, forming the commissures (Anderson et al., 1991). This three-dimensional structure of the aortic annulus may be rationalized into two functional diameters of the aortic root, ensuring proper valve function, namely the aortic annular base and the STJ (Anderson et al., 1991; Lansac & Di Cesta, 2010c; De Waroux et al., 2007) (Fig. 1). Echographic measurement of the aortic annulus corresponds to the aortic annular base diameter (Fig. 2) (Roman et al., 1987).

Cut-off point of "normal" diameters of the aortic root ensuring valve coaptation can be defined from analysis of main series as an aortic annular base diameter ranging from 21 to 24.5 mm (mean 22.9 mm) and a sinotubular junction diameter ranging from 27.5 to 28.1 mm (mean 27.5 mm) with a normal root ratio STJ/annular base of 1.2. Although difficult to assess precisely, the aortic annular base seems to present a systolic expansion of 6.2% (2.5-9.6%). Systolic expansion at the sinotubular junction level is reported to be 5.7% (2.8-9.8%) (Lansac & Di Cesta, 2010c; Tamas & Nylander, 2007).

Out of main series describing dystrophic aortic roots, aortic annular base diameter superior to 25 mm and sinotubular junction diameter superior to 35 mm are reported and should be considered as dilated (Gallo et al., 1995; Lansac & Di Centa, 2010c).

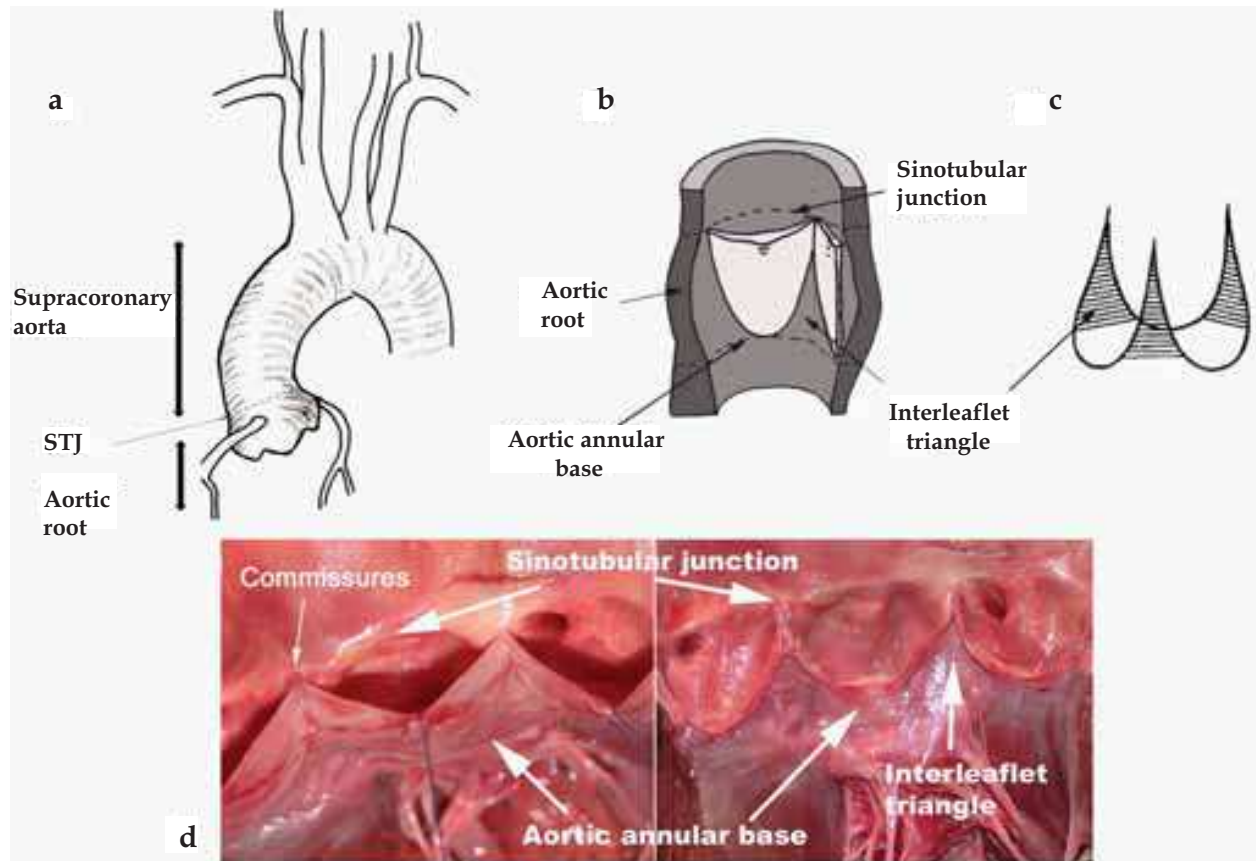


Fig. 1. Anatomy of the ascending aorta and detailed anatomy of the aortic root

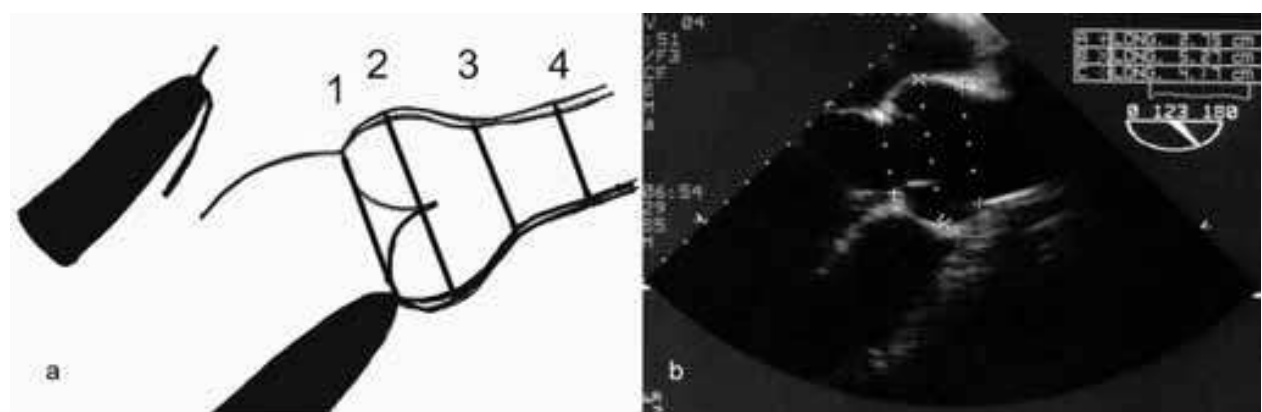


Fig. 2. Echocardiographic measurements of aortic root diameters, in long-axis. 1) Aortic annular base diameter (internal diameter), 2) Sinuses of Valsalva (external diameter, from leading edge to leading edge), 3) Sino-tubular junction (external diameter, from leading edge to leading edge), 4) Ascending aorta (external diameter, from leading edge to leading edge)

Aortic cusps dimensions vary from one patient to another, as well as from one cusp to another, in height, width, and surface area. In a study of 200 normal hearts, only five hearts

were found to have cusps of equal size (Roberts, 1970; Silver & Roberts, 1985; Vollebergh & Becker, 1977). Cusp geometry determines cusp coaptation that depends on length of free margin and aortic insertion, intercommissural distance, and cusp height. These values are difficult or impossible to measure by echocardiography or intra-operative measurements. Bierbach et al. have proposed to use the relative height difference between insertion and free margin of the cusp (effective height) as a surrogate parameter of cusp coaptation. In their study effective height has a constant relationship to root dimensions and body size (Bierbach et al., 2010). Authors suggest to measure this parameter as the indicator of configuration and geometric height of a cusp and designed a specific calliper to measure it intra-operatively (Schäfers et al., 2006). Effective height revealed values in healthy adult individuals measured by transthoracic echocardiography in the range of 7 to 12 mm. The three interleaflet triangles are an extension of the left ventricular outflow tract and are composed of aorta's fibrous walls between the expanded sinuses of Valsalva. The two interleaflets triangles placed on both sides of the noncoronary cusp are in fibrous continuity with the membranous septum, the fibrous trigones and the mitral valve (Sutton et al., 1995). The membranous interventricular septum extends downward and upward corresponding to the interleaflet triangles between the right and non coronary sinuses. It is in close relationship with the atrioventricular node. The bundle of His crosses the right fibrous trigone and passes along the lower edge of the membranous septum. This anatomical landmark is important when performing aortic valve surgery in order to avoid inducing intraventricular conduction abnormalities or heart block (Kunzelman et al., 1994).

## 2.2 The ascending aorta: A dynamic structure

Better understanding of aortic valve dynamics recently became a concern because of the increase use of stentless bioprostheses and aortic valve repair and sparing procedures. Although the relationship between the sinuses of Valsalva and the aortic valve had been intuitively shown by Leonardo da Vinci (Robicksek, 1991), the aortic valve has been for a long time regarded as a passive, tri-leaflet structure that moves back and forth according to pressure differences between the left ventricle (LV) and aorta. This concept has led to the development of all mechanical and stented bioprostheses. Several authors have questioned this simplistic view by showing that expansion of the aortic root actively participates in aortic valve opening, reducing shear stress on the cusps (Brewer et al., 1976; Pang et al., 2000; Thubrikar et al., 1977). In 1976, Brewer et al. described the interdependence of aortic valve opening and root expansion in an isolated aortic root model (Brewer et al., 1976). They showed that valve opening was related to the 16% radial displacement of the commissures, which was interpreted as a mechanism to reduce shear stress on the cusps. Using radio-opaque markers in dogs, Thubrikar et al. (Thubrikar et al, 1977, 1979) confirmed *in vivo* that aortic valve opening was related to commissural expansion prior to ejection. They suggested that the mechanism of aortic valve opening was related to the release of the inward pull of the commissures that occurs during isovolumic contraction. Although they did not measure it, they also suggested that the constraining effect of the annular base was part of the mechanism. Limited by their data-sampling rate (60 Hz), all calculations were made on abnormal cardiac cycles under the assumption that a non-ejecting extra systole was equivalent to the isovolumic contraction (IVC). Similarly, Vesely et al. interpreted aortic root dilation prior to valve opening as secondary to passive hemodynamic recoil of the aortic root (Hansen et al., 1995).

Three-dimensional (3D) digital sonomicrometry, characterized by a high rate of data acquisition (200 to 800 Hz), offers opportunity for a precise time-related study of the aortic

root and valve dynamics within each phase of the normal cardiac cycle (Gorman et al., 1996; Hansen et al., 1995; Pang et al., 2000). Using this technique we intended to precise the mechanism of aortic root expansion and the shape of the aortic valve orifice at maximum opening on an ovine model.

A significant aortic root expansion occurs during isovolumic contraction and initiates the aortic leaflet separation prior to ejection ( $2.1 \pm 0.5\%$ ). This opening is primarily due to commissural expansion, but it is also due to the expansion of the annular base. Both expansions are strongly related to the left ventricular pressure increase ( $r = 0.95$ ) during IVC. The aortic root volume increases by  $33.7 \pm 2.7\%$  with a maximal deformation happening during the systole at the commissural level, maximizing left ventricular ejection. These findings also confirm the study of Sutton et al. (Sutton et al., 1995), who described the interleaflet muscular triangles - located under the semilunar attachment of the cusps - as an essential component of the aortic annulus and part of the left ventricular outflow tract.

Indeed the aortic root is a junction between the left ventricular and the systemic circulation. Thin cusps separate these two compartments with different hemodynamic systems. The first, left ventricular compartment is situated below the cusps and includes the sigmoid-shaped cusp attachments (traditionally described as the annulus), the interleaflet triangles, and the commissures. These structures are related to the left ventricular hemodynamics. The second, aortic compartment, is situated above the cusps, includes the sinuses of Valsalva, the sinotubular junction and ascending aorta, and is related to aortic and coronary flow dynamics. During IVC, aortic root expansion starts at the left ventricular compartment due to volume redistribution in the left ventricular outflow tract. The aortic compartment expansion is delayed at the end of IVC due to a redistribution of volume above the cusps. Confirmation of these bi-compartmental volume dynamics is provided during end-diastole, by the observed re-expansion of the aortic root related to left ventricular compartment expansion during left ventricular filling.

The initiation of cusp separation (i.e., valve opening) is a dynamic process that occurs in the presence of a negative left ventricular -aorta pressure gradient ( $-8.5 \pm 2.6$  mmHg).

The shape of the aortic valve orifice remains speculative. Thubrikar et al. (Thubrikar et al., 1977, 1979, 1993), followed by Higashidate et al. (Higashidate et al., 1995), described it as initially stellate, then triangular and circular at maximal opening. These studies were limited by their low data sampling rate (60 Hz), which did not allow for continuous recording of the changes in valve orifice within each phase of the cardiac cycle. Sonometrics analysis at 200 to 800 Hz showed that the shape of the aortic valve orifice progressed from initially stellate to triangular then circular and finally clover shaped at maximum opening following the shape of the three sinuses of Valsalva (Figure 3). At that time, the cusp's free edge area exceeded the commissural area by  $+16.3 \pm 2.0\%$ . This behavior of the valve cusps might explain cases of early cusp deterioration following re-implantation of the aortic valve within a tubular conduit without sinuses of Valsalva (Gallo et al., 1995; Grande-Allen et al., 2000; Leyh et al., 1999) because cusp expansion beyond the commissural level would result in cusp impact against the wall of the cylindrical conduit.

Furthermore, as previously published, aortic root expansion is also asymmetric, and it induces a tilting dynamic of the aortic valve throughout the cardiac cycle (Dagum et al., 1999; Lansac et al., 2005b). In an ovine model, the aortic root tilt angle between the basal and commissural plane decreases in systole, aligning the left ventricular outflow tract with the ascending aorta in order to maximize ejection. As soon as the valve starts closing and during diastole, the angle tilts back (as a shock absorber), reducing stress on the cusps.

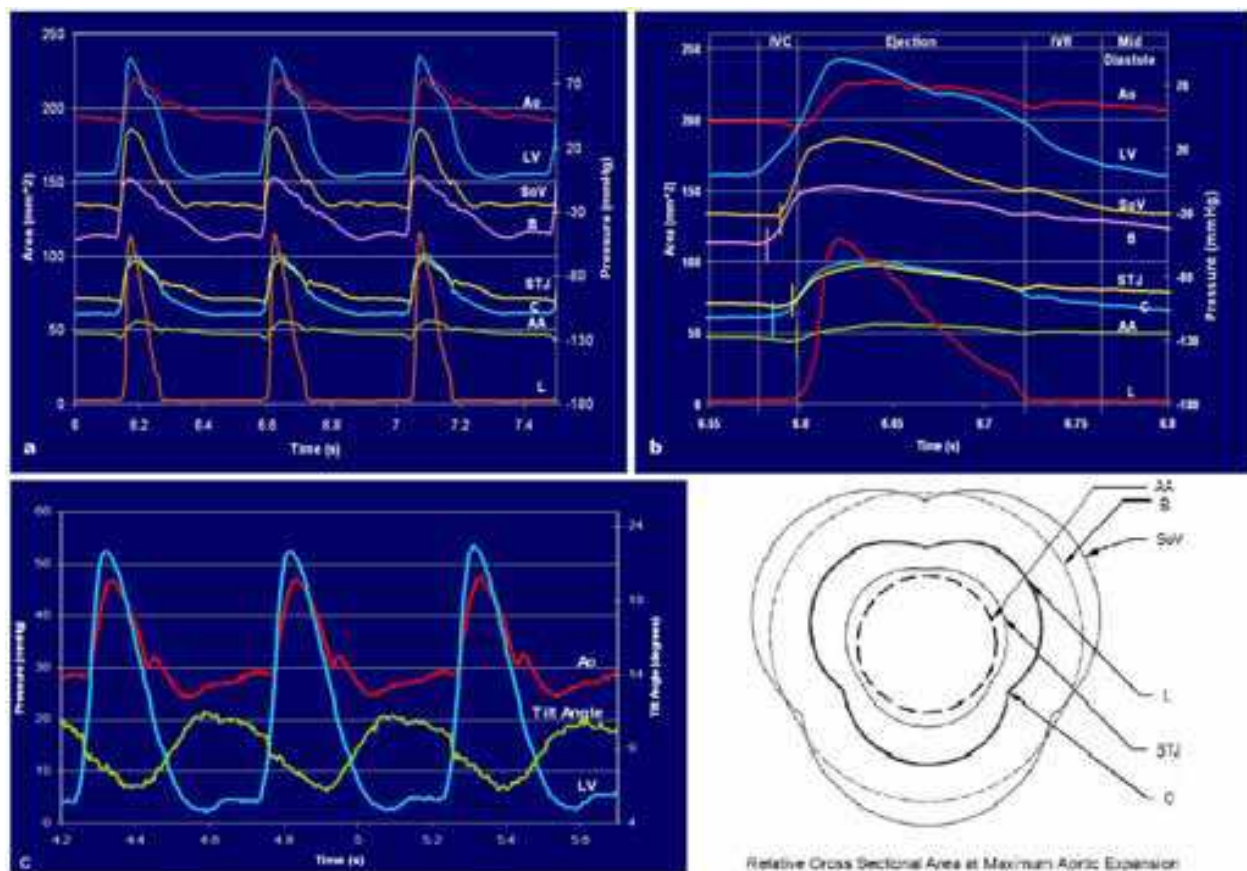


Fig. 3. Changes at each level of the aortic root time related to left ventricular and ascending aorta pressures in one sheep, a) during three cardiac cycles and b) detail of one cardiac cycle. c) Dynamic changes of tilt angle of the aortic root time related to left ventricular and aortic pressures. d) cross-sectional area diagram of the aortic root at maximum expansion during ejection (sonomicrometry) showing the clover-shaped orifice of the aortic valve. *Ao* aortic pressure, *LV* left ventricular pressure, *SoV* sinuses of Valsalva, *B* annular base, *STJ* sinotubular, *C* commissures, *AA* ascending aorta, *L* leaflet

Therefore, the durability of native aortic valve seems to rely on a dynamic triad associating 1) systolic expansion of the aortic root, 2) a clover-shaped aortic orifice that embraces the bulging sinuses of Valsalva, and 3) tilting dynamics of the aortic valve (Lansac et al., 2002). Aortic valve surgery should try to preserve these baseline dynamics as much as possible using more physiologically based surgical approaches.

### 3. Dystrophic aortic roots

#### 3.1 Dystrophic aortic roots: A diameter disease

Dystrophic aortic roots are characterized by dilation of both functional diameters of the aortic root: the aortic annular base and sino-tubular junction (STJ) diameters (>25mm and >35 mm respectively), preventing coaptation of otherwise thin and pliable valves (De Waroux et al., 2007; La Canna et al., 2009; Lansac et al., 2008, 2010c). Cusp prolapse is often associated with root aneurysms and is the most common cause of isolated dystrophic aortic insufficiency (AI). On an echocardiographic study of patients with aortic root aneurysms (n=700) or isolated aortic insufficiency (n=595), average aortic annular base diameter was

respectively 26.4mm (25-27.5mm) and 27.3mm (27-28mm), and average sinotubular junction was respectively 45.3mm (39.5-52.4mm) and 31mm (28-35mm). Ratio between the sinotubular junction and aortic annular base diameters was 1.7 in case of root aneurysms, whereas for isolated aortic insufficiency it was 1.1 (Lansac et al., 2008, 2010c).

### 3.2 Surgical indications

Surgical emergency operation is indicated in the setting of acute ascending aortic dissection or rupture into the pericardium (acute cardiac tamponade). Operative mortality remains significant and death is almost certain in the case of rupture or acute dissection if not surgically addressed.

Based on natural history of ascending aortic aneurysms, prophylactic surgery seems appropriate at 5 to 5.5 cm diameter depending on the etiology. Intervention criteria are summarized in Figure 4 (Hiratzka et al., 2010; Vahanian et al., 2007). Actually, elective surgery of the ascending aorta is much safer than emergency intervention (mortality 4.3%).

For patients with Marfan’s syndrome and bicuspid valves size criterion is somewhat lower. In those patients, prophylactic repair is warranted for an intervention criterion of 4.5 to 5.0 cm diameter for most authors (Bentall & De Bono, 1968; Yacoub et al., 1998). Dissection or rupture have been stated at sizes less than 5.0 cm in several cases, and an increase rate of aneurysm dilatation greater than 5mm/y is known to lead to an 4.1-fold risk of complications.

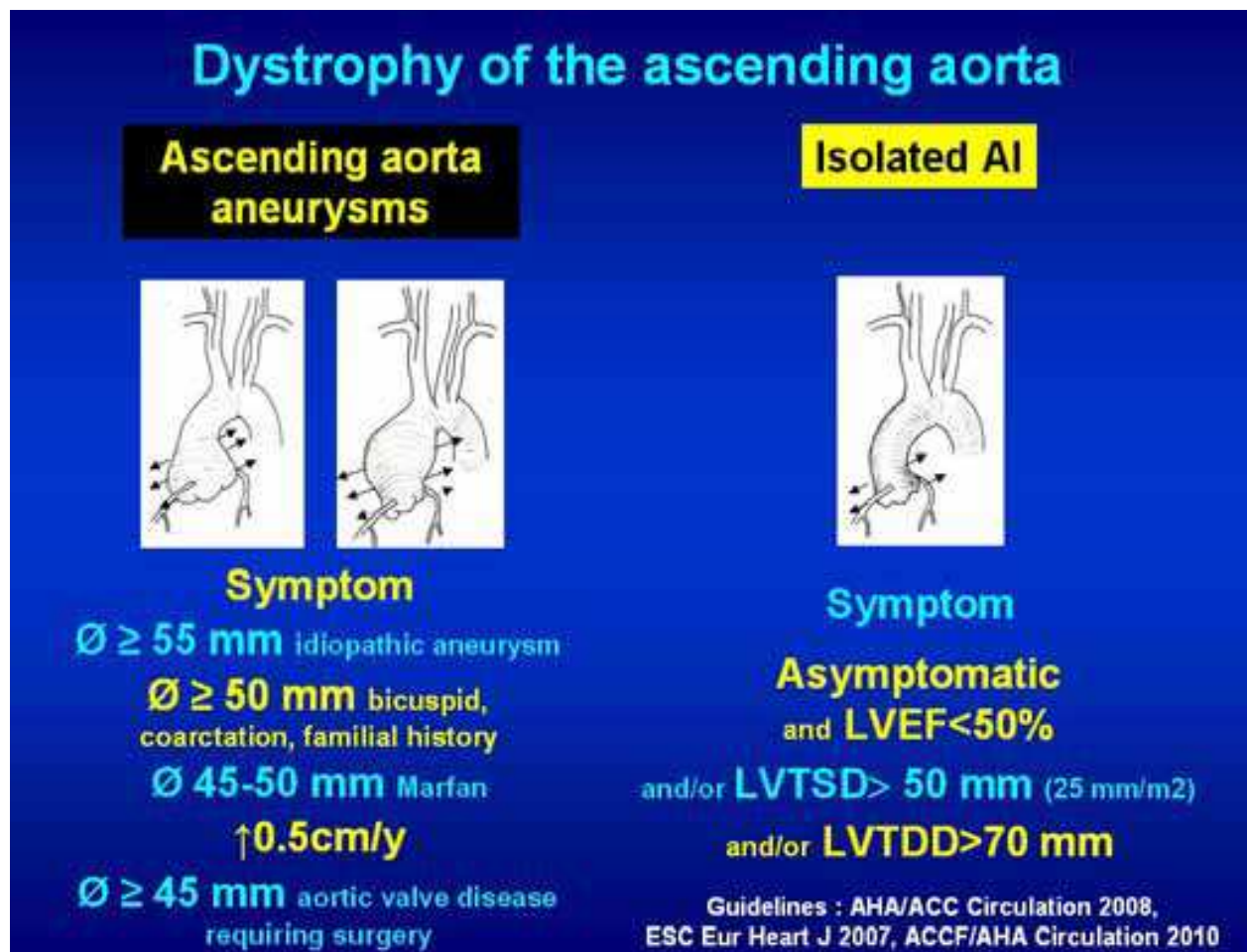


Fig. 4. Surgical indications for ascending aorta aneurysms and/or aortic insufficiency



Other risk factors for aortic dissection in patients with Marfan syndrome include familial history of aortic dissection and a ratio between observed diameter and predicted diameter above 1.3. Women with Turner's syndrome showing an ascending aortic diameter  $>25\text{mm}/\text{m}^2$  should be operated on (David et al., 2006).

### 3.3 Preoperative imaging

Transthoracic and transesophageal echocardiography are performed to define the anatomy of the valve and the phenotype of the ascending aorta (Roman et al., 1987). It remains critical in order to analyze the lesional mechanism of aortic insufficiency both pre- and postrepair in case of aortic valve repair procedures. It measures the 4 characteristics aortic diameters at end diastole, in the parasternal long-axis view, at 4 levels: aortic annular base, sinuses of Valsalva, sino-tubular junction and supra-coronary aorta. Measurements are made perpendicular to the long axis of the aorta using the leading edge technique in views showing the largest aortic diameters. (Fig. 2) (Roman et al., 1987). Analysis of the valve evaluates the number of cusps and direction of regurgitant jet. An eccentric jet towards the anterior mitral leaflet identifies a right coronary cusp prolapse whereas a jet directed towards the septum corresponds to a non or left coronary cusp prolapse (De Waroux et al., 2007).

Most patients are initially evaluated and followed with helical CT (computed tomography) scans, completed with a 3-dimensional reconstruction of the data to increase the accuracy of aneurysm measurements, determination of its proximal and distal extent, and differentiation between dissection, penetrating ulcers or intramural hematoma. Moreover, it allows preoperative coronary arteries assessment.

As a routine, it is recommended to perform both an echocardiography and a helical computed tomography in order to evaluate and confirm the size of the aneurysm.

### 3.4 Surgical techniques for dystrophic aortic roots

Treatment for dystrophic aortic root aneurysms can be either replacement of the aortic valve and root, or repair of the aortic valve, while replacing the dilated aortic root in case of aneurysms.

#### 3.4.1 Aortic valve and root replacement procedure

Depending on root phenotype, it consists either of isolated valve replacement (isolated aortic insufficiency), composite valve and graft replacement (Bentall procedure, for aortic root aneurysms (Bentall & De Bono, 1968)) or supracoronary graft and/or valve replacement (supra-coronary aneurysm).

#### 3.4.2 Aortic valve-sparing procedures

Owing to the improved understanding of aortic valve dynamics, reconstructive methods have been developed to treat aortic insufficiency, based on sparing or repairing the native aortic valve, while replacing or stabilizing the other components of the aortic root, in order to avoid complications of prosthetic valves.

## 4. Remodeling of the aortic root and reimplantation of the aortic valve

### 4.1 Description of the original valve sparing procedures

The two original valve sparing procedure - remodeling of the aortic root and reimplantation of the aortic valve - focused on root reconstruction to reduce the dilated root diameters in

order to restore proper valve function (David & Feindel, 1992; Yacoub et al., 1983). The reimplantation technique offers aortic annulus support but withdraws the sinuses of Valsalva and includes the interleaflet triangles within a graft tube, thus impairing root dynamics (David et al., 1992, 2006, 2007). In contrast, the remodeling technique provides more physiologic movements of the cusps within three reconstructed neo-sinuses, thus preserving root expansibility through the interleaflet triangles, but without addressing annular base dilation (Yacoub et al., 1983, 1998).

These techniques spare the patient from anticoagulation and prosthetic valve morbidity with a 10-year survival rate ranging from 80.4 to 92% (mean 88.2%) (Aicher et al., 2010; Lansac & Di Centa, 2010c). In both techniques with proper patient selection, the results up to 10 years are equally excellent. However, in earlier series of the remodeling technique, the reoperation rate was higher after type A aortic dissection and in patients with Marfan syndrome (Lansac et al., 2006; Leyh et al., 2002; Luciani et al., 1999; Yacoub et al., 1998). In the unselected population of the original remodeling series, up to 30 % of patients presented recurrence of AI grade II or III (Erasmi et al., 2005; Furukawa et al., 1999; Lansac et al., 2006; Luciani et al., 1999). The only risk factor for failure was a dilated native aortic annulus (diameter  $\geq$  25 mm) (Hanke et al., 2009; Lansac et al., 2006; Leyh et al., 2002; Luciani et al., 1999; Yacoub et al., 1998).

## **4.2 Aortic root and valve dynamics after remodeling or reimplantation**

### **4.2.1 In vitro studies**

All studies show that the remodeling technique exhibits valve dynamics closest to those of the native aortic root. The recreation of the sinuses of Valsalva preserves vortex formation, as well as cusp opening and closing dynamics, thus, reducing cusp stress which theoretically improves their durability. The valve shows asymmetric motion after reimplantation. The cusp bending deformation index is increased with the reimplantation techniques and sinus prosthesis compared with the control and remodeling groups (Erasmi et al., 2005; Furukawa et al., 1999; Grande-Allen et al., 2000).

### **4.2.2 In vivo studies**

Leyh and colleagues clearly demonstrated that distensibility of the aortic root and a proper valve motion were better preserved after the remodeling than after the reimplantation technique (Leyh et al., 1999). They showed that reimplantation with a straight tube abolished root distensibility at all levels; the cusps took longer for closing, and systolic contact of at least one cusp against the tube graft was constantly found. Reconstruction of the sinuses may assure a sufficient gap to avoid any such contact between the open cusp and the Dacron wall, which is known to be responsible for cusp thickening and accelerated degeneration (Aybek et al., 2005; De Paulis et al., 2002). The presence of vortices inside the neosinuses of Valsalva preserves the slow closing displacement of the cusps and is associated with a valve motion similar to that of normal subjects (De Paulis et al., 2002; Maselli et al., 2005). Although not significant, valve velocities after the remodeling procedure using the Valsalva graft (Gelweave Valsalva™, Vascutek, Inc.) are closer to normal than after reimplantation using the same graft (De Paulis et al., 2002).

Therefore, all dynamic studies suggest that cusp motion and flow patterns across the reconstructed aortic root are more physiologic (1) after remodeling of the aortic root than after reimplantation of the aortic valve and (2) after procedures using a prosthetic conduit fashioned with neosinuses of Valsalva than without.

#### 4.3 Modification of original remodeling and reimplantation techniques

Numerous technical variations aimed to associate preservation of aortic root dynamics with vortices (neosinuses of Valsalva) and expansibility (interleaflet triangles) with the treatment of dilated native annulus ( $\pm$  cusp lesion) (Hopkins, 2003; Lansac & Di Cerna, 2010c).

David et al. added an external Teflon strip on the aortomitral junction to the remodeling technique (David III) or oversized (+4 mm) the tube graft for the reimplantation technique (David IV) (David, 1999, 2005). The David V technique used an even larger graft size (+ 6-8 mm), which is "necked down" at both the bottom and the top ends to create graft pseudosinuses (Miller, 2007). Many authors suggested different methods to customize the tube graft for the reimplantation or remodeling in order to provide better neosinuses of Valsalva. More recently De Paulis et al. designed the Valsalva graft (Gelweave Valsalva™, Vascutek, Inc.) with vertical pleats in the proximal section for reconstruction of the aortic root and with the standard horizontal pleats for ascending aorta replacement (Cochran & Kunzelman, 2000; Gleason, 2005; Hess et al., 2005; Hetzer et al., 2008; Kollar, 2007; Miller, 2007; Morishita et al., 2002; Ruvolo & Fattouch, 2009; Scensson, 2003; Takamoto et al., 2006; Urbanski et al., 2009; Zehr et al., 2000).

We suggest combining advantages of both original valve sparing techniques by associating the Remodeling reconstruction of the aortic root with an expansible sub-valvular annuloplasty (Figure 5).

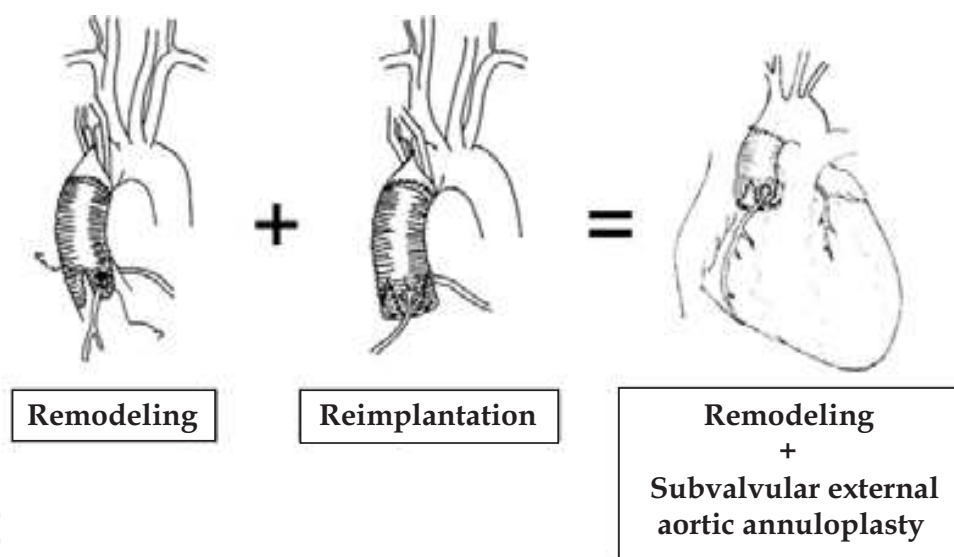


Fig. 5. Combination of Remodeling and Reimplantation procedures by placing an external subvalvular ring annuloplasty associated to the Remodeling procedure

#### 5. From original valve sparing procedures to a physiological approach of aortic valve repair

Although restoration of root geometry is an important prerequisite for a successful valve sparing, preventing recurrence of aortic insufficiency remains a challenge. Most failures with valve sparing techniques are due to residual cusp prolapse, either as a primary unrecognized lesion or secondary to an induced prolapse after root reconstruction. Despite its more frequent detection intra operatively, cusp prolapse remains challenging to evaluate and treat. Schafers et al proposed to use a cusp caliper to obtain symmetrical cusp

resuspension with an effective height  $\geq 8$  to 10 mm in order to restore cusp coaptation (Bierbach et al., 2010; Schäfers et al., 2006). In their report, an effective height  $\geq 9$  mm is an excellent predictor for a good haemodynamic outcome after valve repair. This technique allows correction of any residual or induced symmetrical prolapse after reduction of the STJ provided by the remodeling procedure. Indeed, Soncini et al., using finite element analysis showed that noduli of Arantius were lowered towards the valve orifice during valve closure after reimplantation (3.8 mm) and remodeling (3.3 mm) (Soncini et al., 2009). Subvalvular annuloplasty through an aortic ring or proximal suture of a reimplantation tube graft partially compensates the induced symmetric prolapse by increasing the coaptation height. However, in the absence of cusp resuspension, coaptation level may remain too low (at the level of the aortic annular plane or below). This can induce a billowing aspect of the cusps with progressive drop of the coaptation level and height ( $< 4$ mm) which have been described as a risk factor for reoperation (De Waroux et al., 2007). Normalisation of effective height leads to a high probability of normal or near-normal aortic valve function (Bierbach et al., 2010; Schäfers et al., 2006).

As restorations of both root geometry and cusp coaptation are the prerequisite for a successful valve sparing procedure, we designed a standardized surgical management of dystrophic aortic roots towards a more systematic and physiological repair approach (Fig. 6). This approach is proposed based on the principles of reduction of dilated root diameters

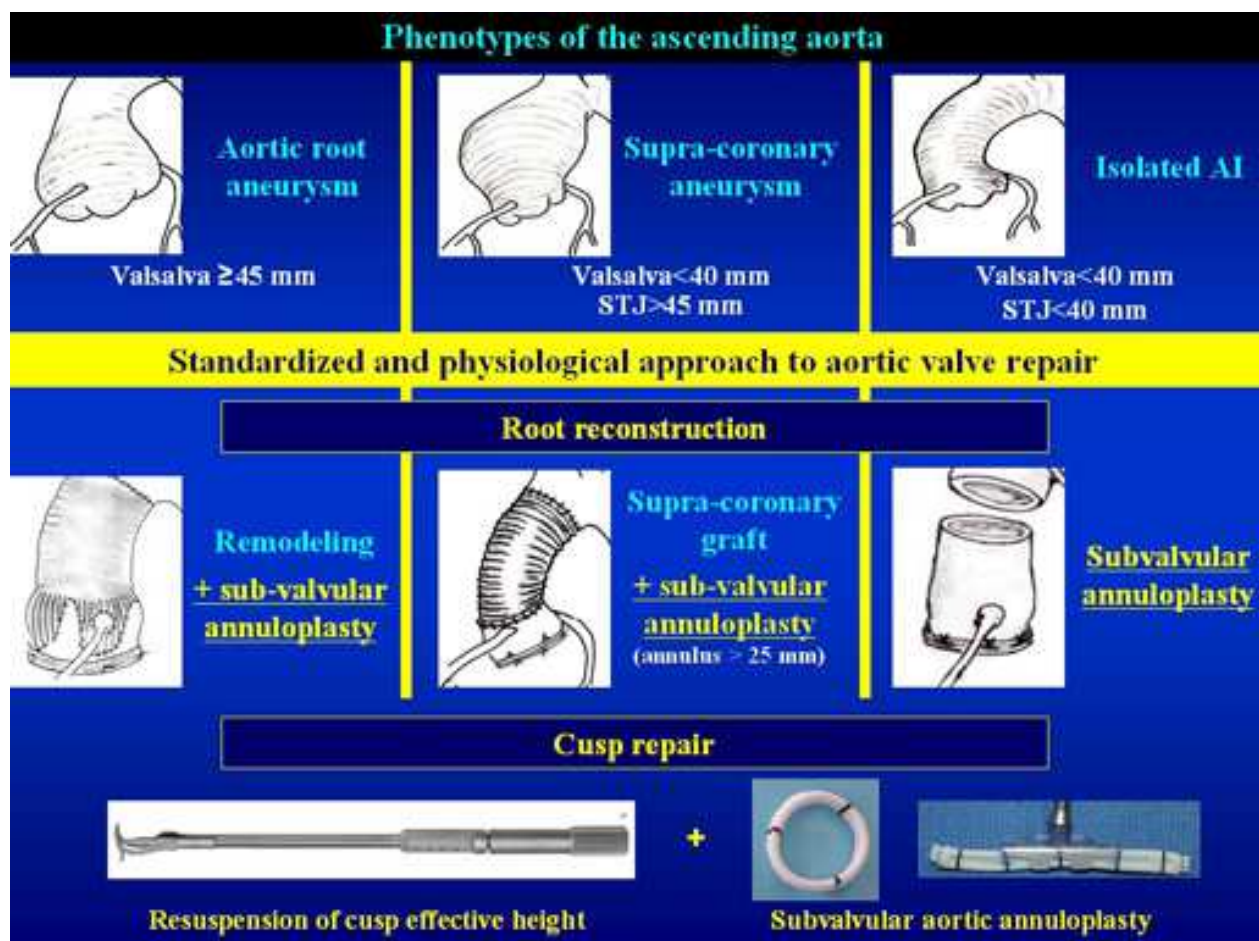


Fig. 6. Standardized and physiological approach to aortic valve repair according each phenotype of the ascending aorta

(aortic annular base and STJ); respect of root dynamics (expansibility through the interleaflet triangles and restoration of sinuses of Valsalva) and retraction of cusp coaptation height (measurement of the effective height). Depending on the phenotype of the ascending aorta, reduction of the sinotubular junction diameter will be achieved through a physiological reconstruction of the root according to the Remodeling technique (root aneurysm, sinuses of Valsalva  $\geq 45$  mm), a supracoronary graft (supracoronary aneurysm, sinuses of Valsalva  $< 40$  mm). Valve repair is achieved in two steps: 1) before root reconstruction by aligning adjacent cusp free edges, excess of length is corrected using plicating central stitches or limited resection; 2) after root reconstruction, resuspending residual or induced cusp prolapse in order to obtain an effective height of 8 mm (distance between the free edge of the cusp to the aortic annular base). Expansible subvalvular annuloplasty is systematically added using an external expansible aortic ring in order to increase cusp coaptation height, while maintaining systolic expansibility. Ring is "open" in case of isolated aortic insufficiency or supra-coronary aneurysm, in order that it may be positioned below the coronary arteries without detaching them from the aortic root (Lansac et al., 2005a, 2006, 2009, 2010a, 2010b, 2010c, 2011a, 2011b).

## 6. An expansible aortic ring for a calibrated subvalvular aortic annuloplasty

To standardize this physiologically based approach to conservative aortic valve surgery, we designed a calibrated expansible aortic ring that reduces dilated diameters in diastole in order to increase cusp coaptation height, while maintaining root systolic expansibility (Figure 7) (Lansac et al., 2009).

The aortic rings (Extra-Aortic, CORONEO Inc., Montreal, Canada) are composed of two silicone elastomer cores covered by a polyester textile. Black indicator marks on the ring and suture windows in the ring-holder are incorporated to facilitate optimal suture placement between the two cores. Design prerequisites for the ring were: 1) target *in vivo* device expansion between 5% and 15% over the cardiac cycle, 2) minimized radial thickness of the ring while preserving the desired dynamic behaviour, 3) ring durability, 4) stable and predictable bioreaction with surrounding tissues.

Characteristics of this new device were established *in vitro* on the bench-top. Biocompatibility of the ring and the impact of its implantation on root dynamics were studied *in vivo* in the ovine model.

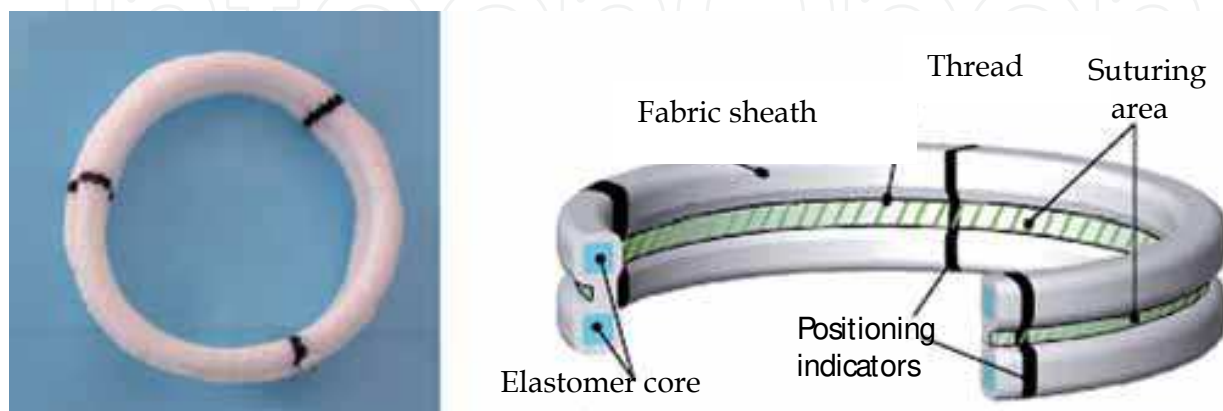


Fig. 7. Expansible aortic ring (left hand side) and its detailed constitution (right hand side)

Root dynamics were assessed using intracardiac echography before surgery, and at 6 months. Histological, scanning electron microscopy and mechanical studies were then performed on explanted samples. Prosthetic rings created a significant reduction of the aortic annular base diameter without significant transvalvular gradient (mean  $3.4 \pm 2.1$  mmHg). Coaptation height was increased from  $2.5 \pm 0.7$  mm to  $6.2 \pm 1.1$  mm ( $p < 0.001$ ). Dynamics of the root were well preserved. The device was clearly visible in explanted sheep hearts at 6 months. There was no erosion of the external ring into the aorta or adjacent structures, neither at the level of the aortic annular base nor at the STJ level. Coronary arteries were patent in all cases. Mechanical testing on 6 month explanted samples revealed no significant differences in elastic modulus. Histomorphological studies showed incorporation of the material without degradation. Aortic cusps remained thin and pliable. Macroscopic examination of the hearts did not show calcification as confirmed by Alizarin red staining. Polyester fabric was fully integrated in the tissue and colonized by a dense extracellular matrix. Low and high magnifications of the samples showed the encapsulation of the elastomer core in a fibrous zone. No inflammatory reaction was noted around the device and no apparent degradation of the elastomer core was observed by SEM observation (Lansac et al., 2009).

## 7. Remodeling of the aortic root with cusp resuspension and subvalvular external aortic ring annuloplasty for aortic aneurysms

We describe a standardized procedure for aortic aneurysms with tricuspid valves (Lansac et al., 2011b). In all cases, intra-operative transesophageal echocardiography (TEE) remains critical in order to analyze the lesional mechanism of AI both pre- and post-repair (Lansac et al., 2011a).

### 7.1 Dissection of the subvalvular plane

After aortic cross-clamping, the aneurysm is opened and the aortic root and valve are carefully inspected (particularly the geometry of the aortic valve and leaflet morphology). Pliable non retracted cusps are suitable for valve repair. The presence of an intact fenestration, a bicuspid valve or limited calcification is not a contraindication. External dissection of the aortic root is performed down to the base of the aortic annulus which is liberated from the pulmonary artery and infundibulum and from the roof of the left atrium, in order to reach the subvalvular plane. The wall of the aortic sinus is totally removed leaving a fringe of aortic wall of approximately 2 mm. The internal aortic annular base diameter is measured with Hegar dilators. Measurement of the native aortic annular base diameter with Hegar dilators is the sole criterion to determine size of the expandable aortic ring which is undersized from one size in order to increase coaptation height while protecting cusp repair (Table 1).

	Aortic annular base Ø (Hegar dilators, mm)			
	25-27	28-30	31-33	≥34
<b>Tube graft Ø (mm)</b>	28	30	32	34
<b>Subvalvular aortic ring Ø (mm)</b>	25	27	29	31

Table 1. Criteria for choice of the aortic ring and tube graft diameters

### 7.2 Placement of 5 subvalvular anchoring stitches (fig. 8)

Five threads of 2.0 coated polyester fiber pledgeted (3/8 needle 25, Ethibond, Ethicon Inc., Somerville NJ, USA), are placed from the inside out as “U” stitches (width of 3 mm) circumferentially in the subvalvular plane, clock-wise beginning from the non-coronary sinus. Three stitches are placed 2 mm below the nadir of insertion of each cusp, and two stitches are placed below two of the three commissures at the base of the interleaflet triangles (no suture is placed at the base of the interleaflet triangle situated between the right and noncoronary sinuses to avoid potential injury to the bundle of His and membranous septum\*)

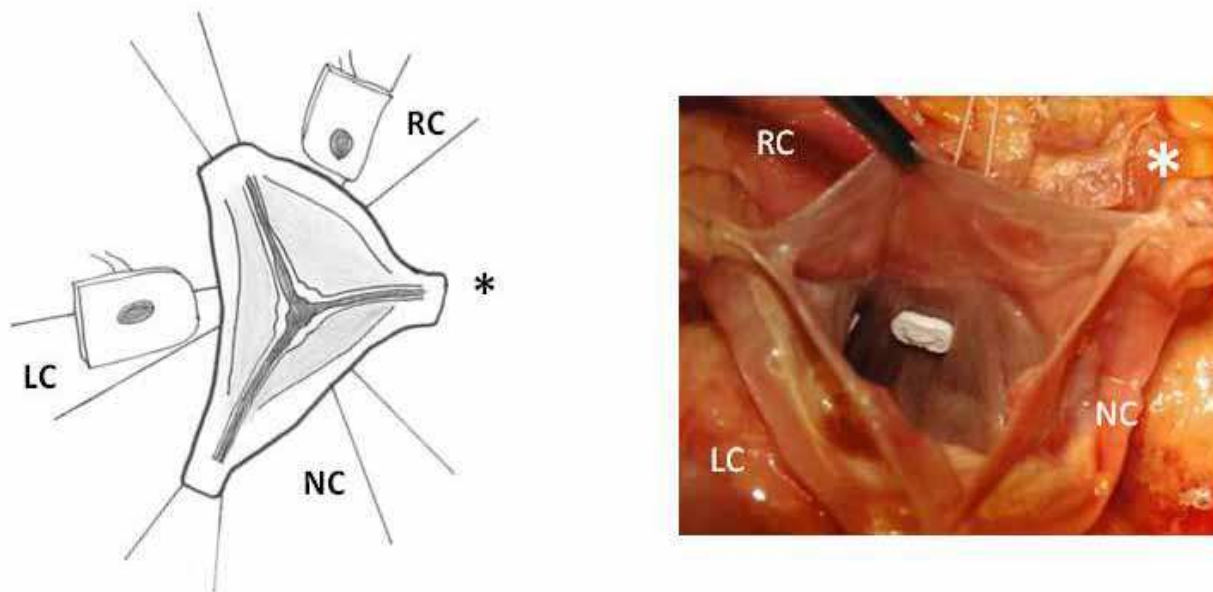


Fig. 8. Positioning of the stitches. RC: right coronary, LC: left coronary, NC: non-coronary, \*: membranous septum

### 7.3 First step of valve repair: Alignment of adjacent cusp free edges (fig. 9)

A polypropylene 6/0 stay suture is passed through each noduli of Arantius. A grasper pulls outwards on the corresponding commissure while the two stitches at the level of the noduli of Arantia are retracted in the opposite direction. The excess length of free edge is then determined. Same step is performed for each hemi-cusp. Distance between the two stitches determines the area for the central plicating stitches to equalize each hemi-cusp (polypropylene 5 or 6/0-13).

### 7.4 Remodeling of the aortic root (fig. 10)

The Remodeling technique is performed using a Gelweave Valsalva™ graft. Remodeling of the aortic root is standardized by scalloping the Valsalva graft into three symmetrical neosinuses using the linear demarcations on the bulging part of the graft. The heights of the scallops to suture the commissures are cut up to the transition point between circumferential and axial folds in the graft. Suturing of the graft starts on the left coronary sinus at the nadir of the sinus (1) towards half sinus (2). Another running suture is begun at the tip of the commissure (3) towards corresponding hemi-sinus (4). (polypropylene 5.0). Right and non coronary sinuses are then sutured.

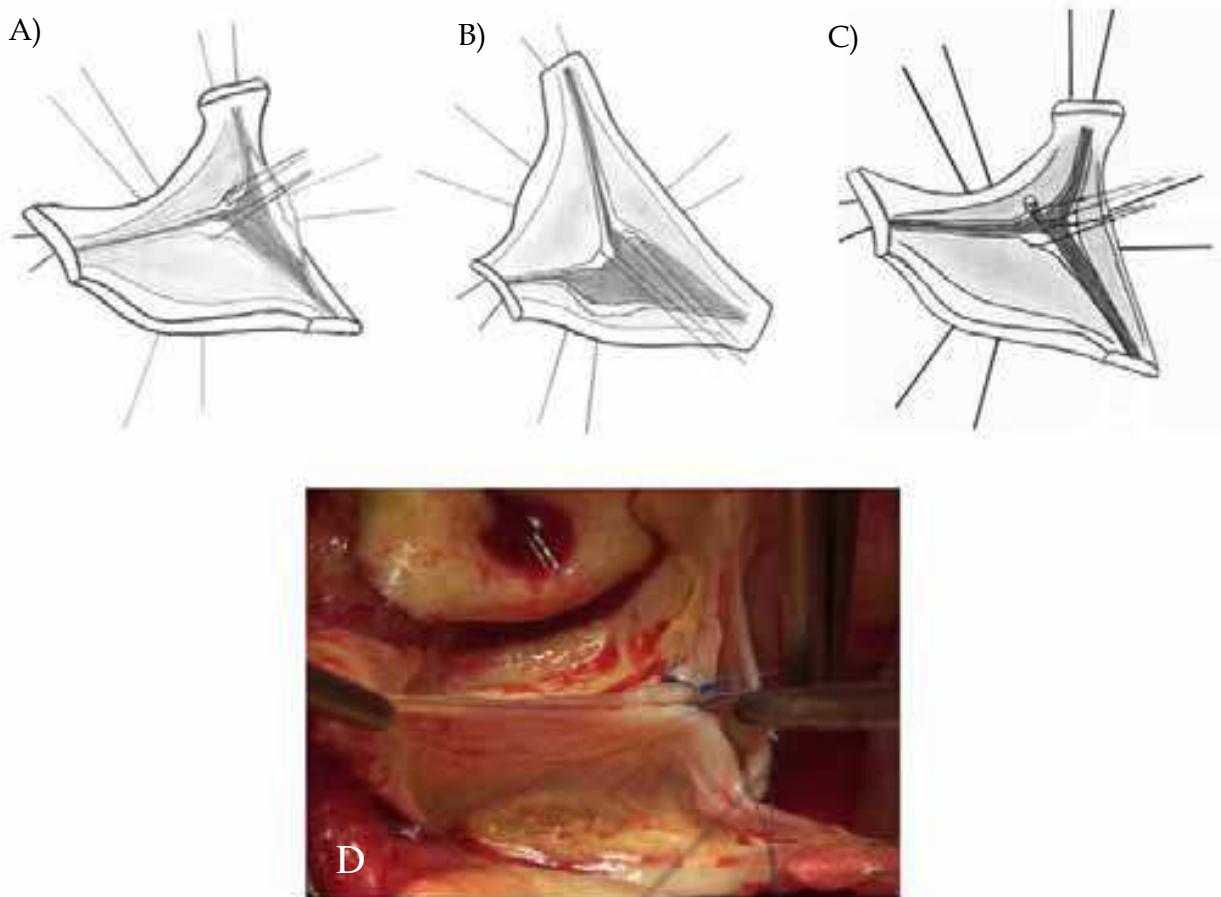


Fig. 9. First step of cusp repair. Alignment of cusp free edges to determine excess of length (A-B) and plicating of stitches to equalize each hemi-cusp (C-D)

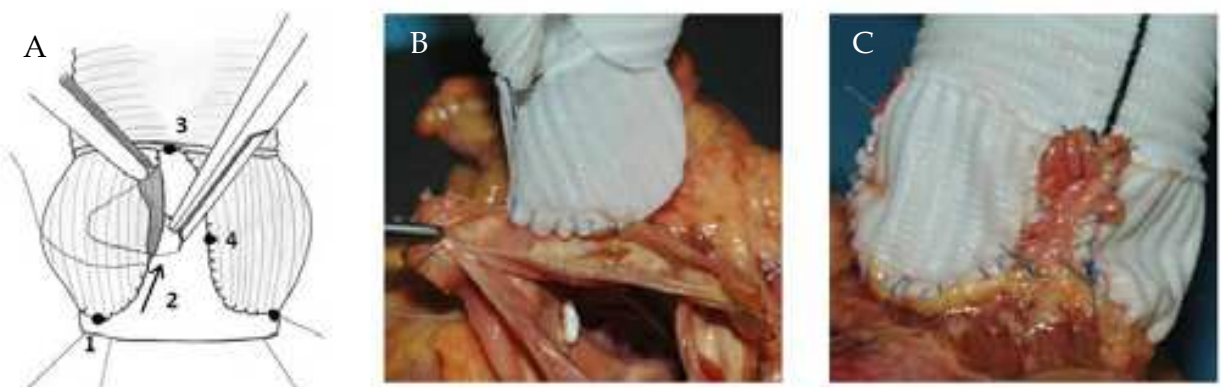


Fig. 10. Step by step suturing of the tube graft for Remodeling (A), from beginning (B) to the end (C)

**7.5 Second step for cusp repair: Resuspension of cusp effective height (fig. 11)**

Once suturing of the tube graft performed,, commissural traction sutures are placed to mimic a pressurized aortic root in order to measure the effective height of each cusp. A dedicated cusp caliper is used to evaluate any residual or induced cusp prolapse (Fehling



Instruments, Karlstein, Germany) (Schäfers et al., 2006). Plicating stitches are added on the free edge of the culprit leaflet until an effective height of 8 to 10 mm is obtained.



Fig. 11. Commissural traction and cusps measurement using a calliper (A-B) and cusps height correction (C)

#### 7.6 Placement of the prosthetic aortic ring in the subvalvular position (fig. 12)

The five anchoring “U” stitches are passed through the inner aspect of the prosthetic expandible aortic ring (Extra aortic, CORONEO Inc., Montreal, QC, Canada). The attachment point between the handle and the ring-holder is aligned with the commissure between the non- and right coronary sinuses (atrioventricular node) where there is no anchoring stitch. The ring is then descended around the remodelled aortic root (a). The holder is released and knots are tied to secure the ring in subvalvular position (b).

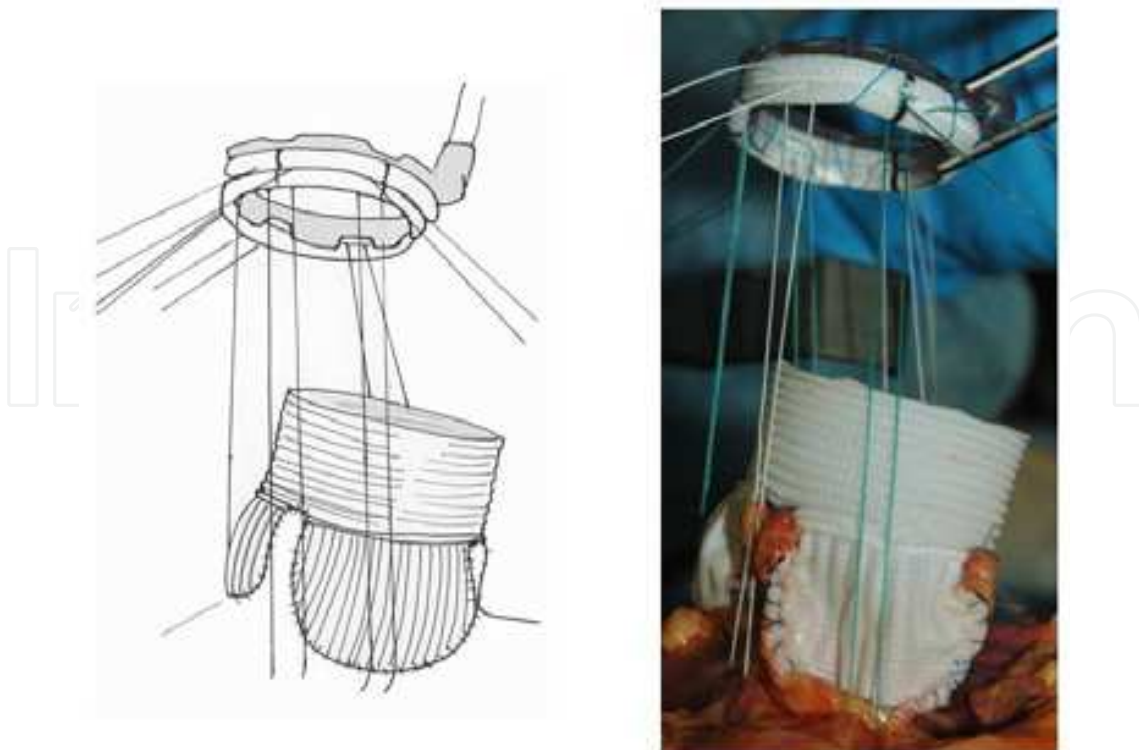


Fig. 12. Suture and descent of the prosthetic aortic ring

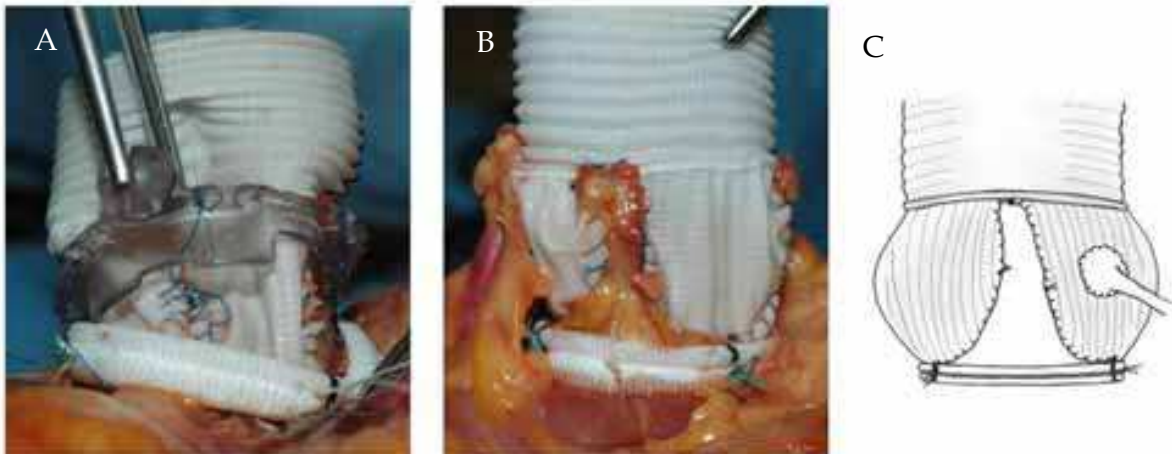


Fig. 13. Final steps of the procedure: the holder is removed (A) and final aspect of the neo-aortic root after anastomosis of the coronary ostia (B-C)

Reimplantation of the coronary ostia buttons into the corresponding ‘neo-sinuses’ of Valsalva is obtained using 5.0 Prolene (fig. 13). The thicker part of the Gelweave graft can be cut to suture the coronaries ostia if they are ascensionned which is often the case for the right coronary button. Distal anastomosis is performed using a 4-5/0 Prolene running suture in a standard fashion.

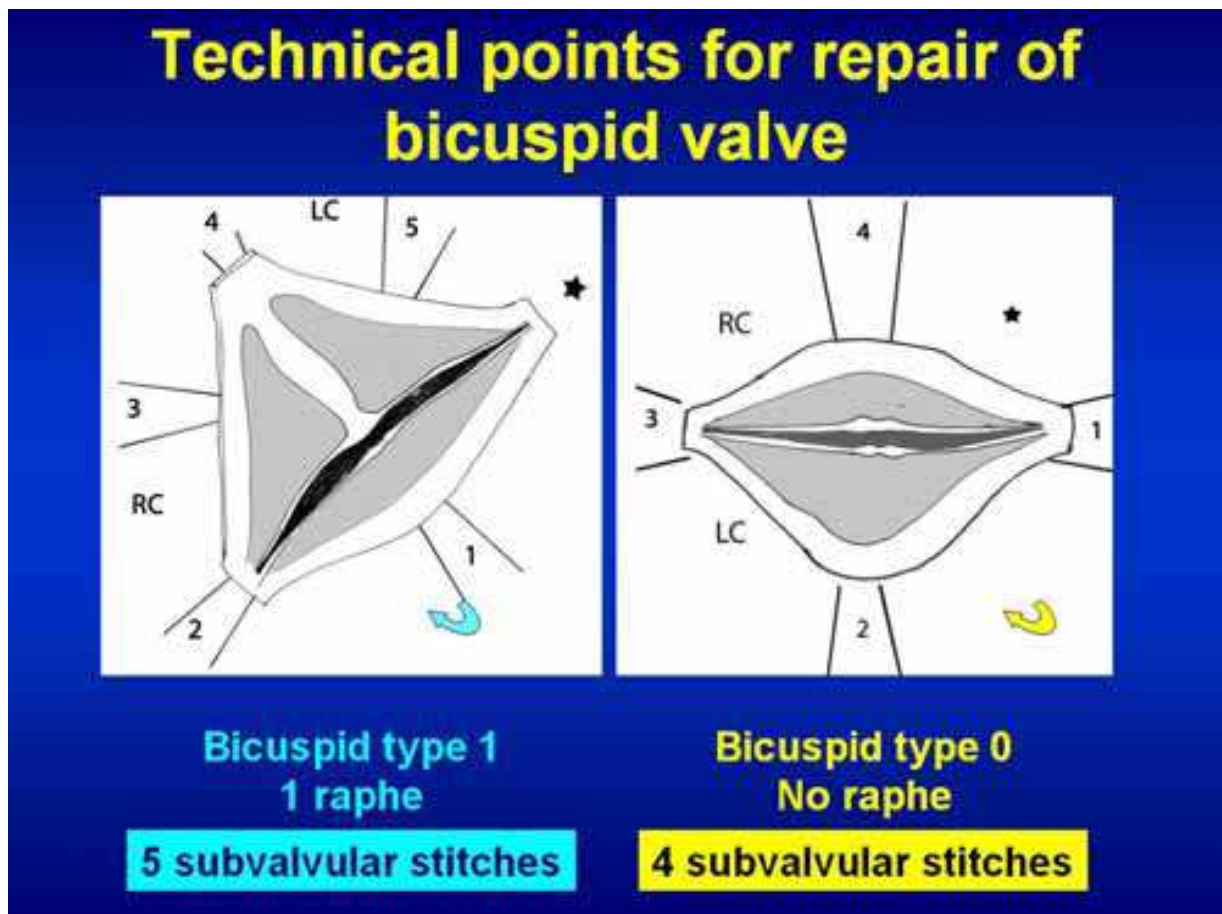


Fig. 14. Bicuspid valves: Placement of the 5 subvalvular “U” stitches

### 7.7 Specific aspect of repair for aortic root aneurysms with bicuspid aortic valves

Dissection of the subvalvular plane as well as sizing of the ring and graft are similar to tricuspid valves (Lansac et al., 2011b). Principle for repair, applicable to all types of bicuspid valves, consists of aligning the free edges of the two cusps, and placing the commissures in the neo-aortic root at 180° according to Schafers et al. Therefore, the Remodeling technique is performed by tailoring the Gelweave Valsalva™ graft into two symmetrical sinuses of Valsalva (Schäfers et al., 2010) (fig. 14-15).

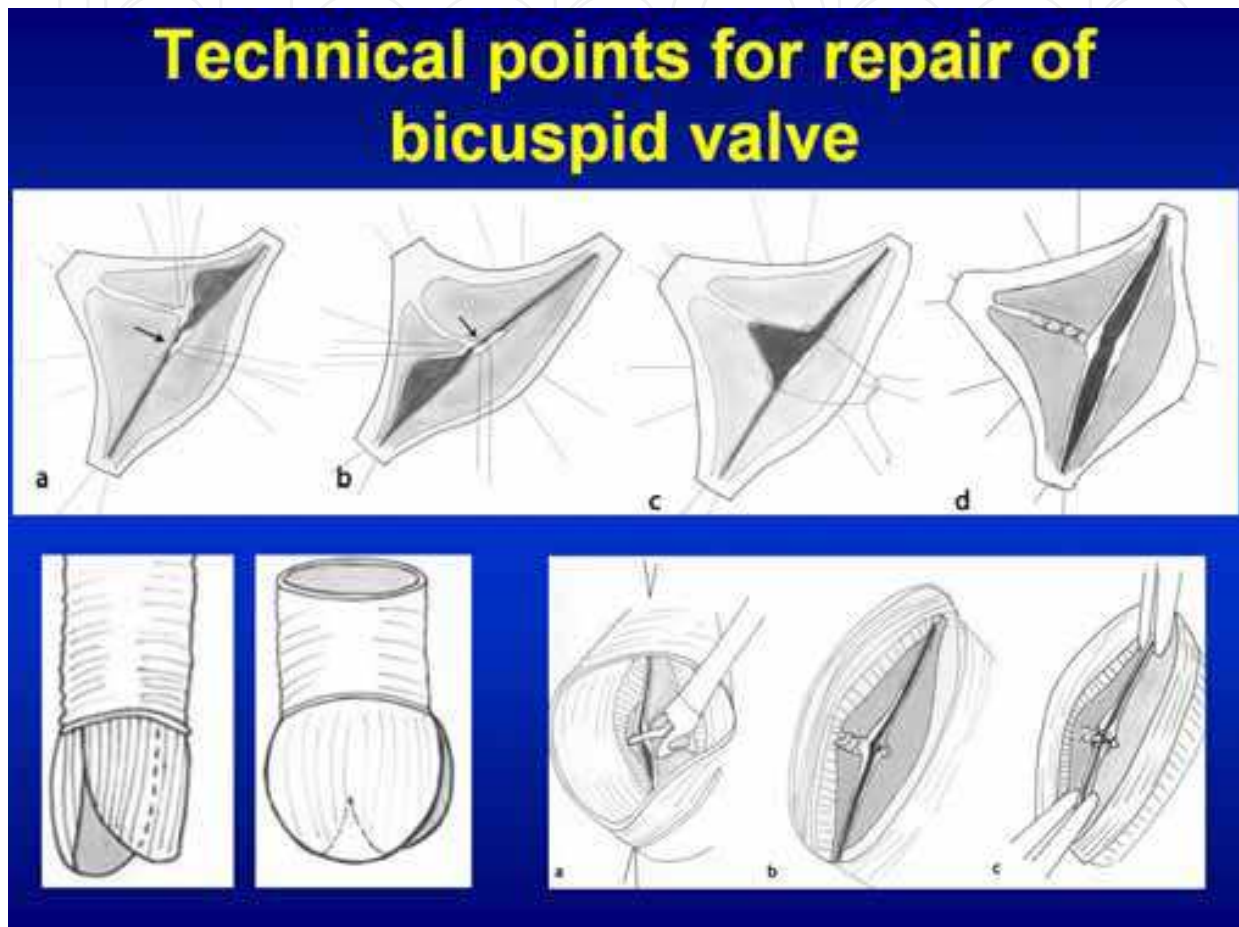


Fig. 15. Bicuspid valves: Valve repair and suture of the remodeling

## 8. Subvalvular aortic annuloplasty for isolated aortic insufficiencies

Principle of isolated aortic valve repair associates cusp repair (alignment of cusp free edge + effective height resuspension) with subvalvular aortic annuloplasty. The expansible aortic ring is of an open configuration in order to allow placement below the coronary arteries without detaching them from the aortic wall (Lansac et al., 2011a, 2011b).

### 8.1 Transection of the aorta and dissection of the aortic root down to the subvalvular plane

The aorta is completely transected 1 cm above the sino-tubular junction. External dissection of the aortic root down to the aortic annular base is performed, passing under the coronary arteries, without detaching them from the aortic wall. The external aspect of the aortic wall

is dissected free from the pulmonary artery and infundibulum and from the roof of the left atrium, in order to reach the subvalvular plane. The internal aortic annular base diameter is measured with Hegar dilators. It is the sole criterion to determine the size of the expandible external subvalvular aortic ring, which is downsized by one size (CORONEO, Inc.).

### 8.2 Placement of the five anchoring subvalvular “U” stitches

Five “U” stitches (2.0 coated polyester fiber, 3/8 needle 25) are circumferentially placed from inside out in the subvalvular plane, below the nadirs of each cusp and at the base of each interleaflet triangles except the one situated between the right and noncoronary sinuses to avoid potential injury to the bundle of His and membranous septum.

### 8.3 Valve repair: Alignment of adjacent cusp free edges followed by resuspension of the cusp effective height

Commissural traction stitches are placed. Alignment of adjacent cusp free edges is performed. Excess cusp length is corrected by plicating central stitches if <5mm and limited cusp resection if >5 mm. Effective height cusp resuspension is then re-evaluated on the unfused cusp using a cusp caliper (Fehling Instruments, Karlstein, Germany). Plicating central stitches are added on the free edge of this cusp until an effective height of 10 mm is obtained. Re-alignment of the two cusps free edges is then performed by adding plicating stitches on the fused cusp (fig. 16).

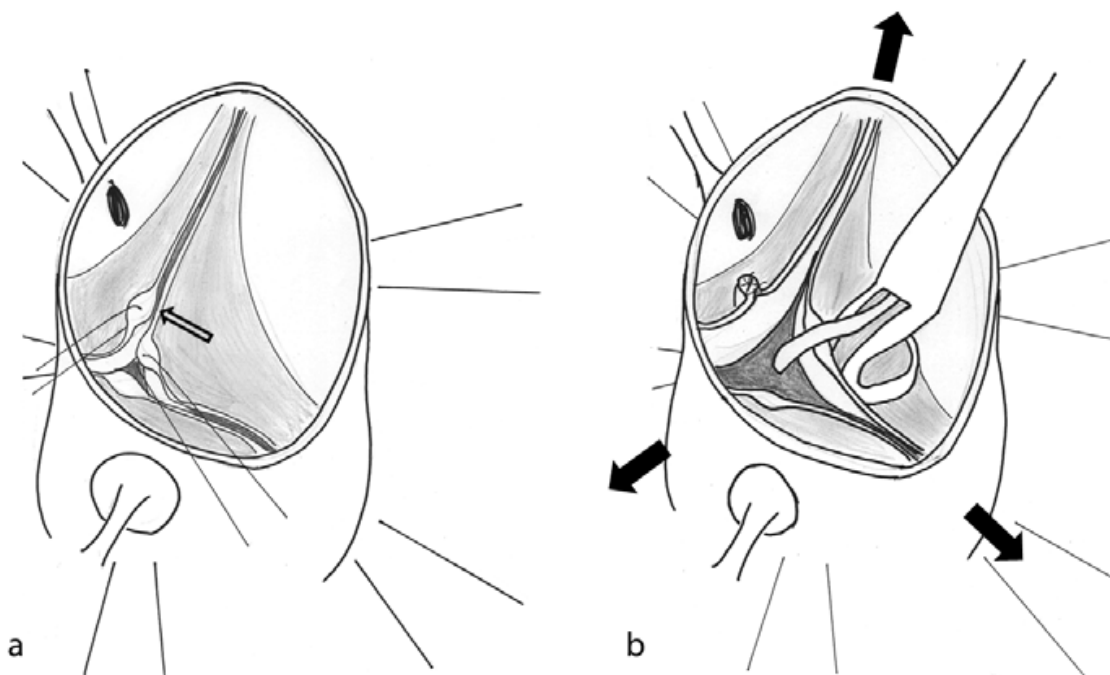


Fig. 16. Aortic valve resuspension for repair of isolated aortic insufficiency

### 8.4 Placement of the aortic prosthetic ring in subvalvular position and TEE control

The subvalvular stitches are passed through the inner aspect of the ‘open’ subvalvular prosthetic ring, in order that it may be positioned below the coronary arteries. The ring is closed with a series of “U” stitches. Transsection of the aorta is closed in standard fashion with running suture (fig. 17).

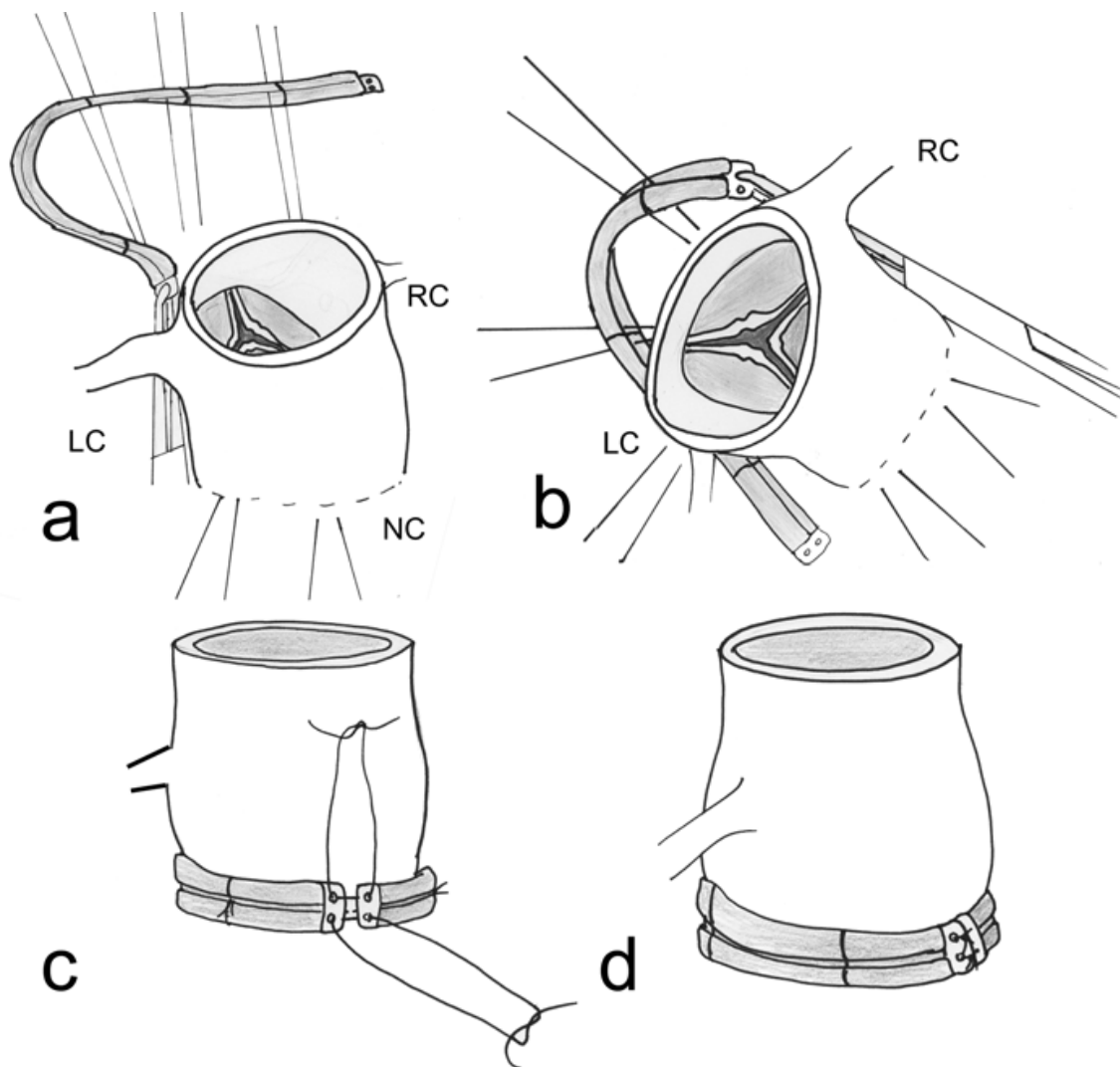


Fig. 17. Placement of the aortic prosthetic ring in subvalvular position

### 9. Preliminary results

From 2003 to 2009, 187 patients underwent Remodeling with subvalvular ring annuloplasty in 14 centers (24 surgeons). Preoperative AI  $\geq$  grade 2 was present in 67.9% (127), and bicuspid valve in 20.8% (39). Need for cusp repair was assessed according to 3 strategies: Group 1: gross visual estimation (74 patients), Group 2: alignment of cusp free edges (62 patients), Group 3: two-steps approach associating alignment of cusp free edges with effective height resuspension (51 patients). A composite outcome was defined as recurrence of aortic insufficiency  $\geq$  grade 2 and/or reoperation.

Valve sparing was successful in all but 2 cases. Operative mortality was 3.2% (6). Ring produced a significant annular base reduction from  $27.3 \pm 0.6$  to  $20.5 \pm 1.7$  mm ( $p < 0.01$ ) without significant mean transvalvular gradient ( $7.2 \pm 2.9$  mmHg). Treatment of cusp lesion was most frequently performed in Group 3 (70.6%, versus 20.3% Group 1 and 30.6% Group 2,  $p < 0.001$ ). Nine patients required reoperation during follow-up ( $31.4 \pm 4.5$  months (1-80)). At one year, no patients in Group 3 presented with composite outcome events (versus 28.1% Group 1, 15% Group 2,  $p < 0.001$ ). Residual aortic insufficiency and tricuspid anatomy were

independent risk factors for composite outcome in Group 1 and 2. Annulus diameter, Marfan syndrome and cusp repair had no effect on aortic insufficiency recurrence or reoperation. Repair of bicuspid valves showed better results than tricuspid valves anatomy. This might be partly explained by higher rate of cusp repair in bicuspid patients (72% of patients versus 28% of patients for tricuspid valves). Apart from high rate of cusp repair, better results in Group 3 also could reflect a learning curve or other confounding factors, since these patients were operated later (Lansac et al., 2010a, 2010b).

## **10. Evaluation of the standardized approach to aortic valve repair: CAVIAAR trial and registry (Conservative Aortic Valve surgery for aortic Insufficiency and Aneurysm of the Aortic Root)**

Few series have compared valve repair with composite valve and graft replacement (Bassano et al., 2001; De Oliveira et al., 2003; Karck et al., 2004; Patel et al., 2008; Volguina et al., 2009; Zehr et al., 2004). Conclusions remain controversial since they were often retrospective, based on selected patients (Marfan), and compare different operating time periods, techniques and learning curve periods. Overall, rates of thromboembolism, bleeding, and endocarditis after valve repair seem lower than those reported for prosthetic valves. A current prospective international registry just provided 30-day morbidity and mortality data and shows equivalent results after a composite valve replacement or a valve-sparing procedure (despite various type of reimplantation) in a selected population of Marfan patients (National Marfans Foundation prospective aortic root replacement registry) (Volguina et al., 2009).

In order to evaluate the standardized approach of valve repair using the expansible aortic ring versus mechanical valve replacement, unselected population of patients with aortic root aneurysms (bicuspid and tricuspid valves) are currently enrolled in France in the ongoing prospective multicenter CAVIAAR trial (Conservative Aortic Valve surgery for aortic Insufficiency and Aneurysm of the Aortic Root), over the next 5 years. Aside from the trial, all patients operated according to the CAVIAAR technique outside France are enrolled in the prospective CAVIAAR registry.

## **11. Conclusion**

Avoidance of anticoagulation and prosthetic related complications makes aortic valve repair an appealing procedure. Considering the increasing rate of cusp repair reported in the literature, conservative aortic valve surgery seems to be evolving from aortic valve sparing to aortic valve repair. However, the need remains for reliable long-term data comparing valve replacement and valve-repair procedures. A standardized management of dystrophic aortic roots towards a physiological approach to valve repair might improve long term durability of the results, and encourage more widespread adoption of these procedures.

## **12. Acknowledgements**

We wish to thank the surgeons who operated the patients in the CAVIAAR trial: Pr C. Acar, Pr B. Albat, Dr E. Arnaud Crozat, Dr F. Baud, Pr D. Blin, Dr N. Bonnet, Dr O. Bouchot, Dr D. Chatel, Dr F. Doguet, Dr G. Fernandez, Dr JP Fleury, Dr T. Folliguet, Pr I. Gandjbakhch, Dr R. Hacini, Pr P. Leprince, Dr S. Lopez, Pr P. Menu, Pr P. Nataf, Pr A. Pavie, Dr A. Rama.

Authors thank the Ecole de Chirurgie de l'Assistance Publique Hôpitaux de Paris (Paris, France) for the use of its anatomical laboratory and organization of the yearly workshops on aortic valve repair.

### 13. References

- Aicher D, Fries R, Rodionychewa S, Schmidt K, Langer F, Schäfers HJ. (2010). Aortic valve repair leads to a low incidence of valve-related complications. *Eur J Cardiothorac Surg*, Vol. 37, No. 1, pp. (127-132).
- Anderson RH, Devine WA, Ho SY, Smith A, Mc Kay R. (1991). The myth of the aortic annulus: the anatomy of the subaortic outflow tract. *Ann Thorac Surg*, Vol. 52, No. 3, pp. (640-646).
- Aybek T, Sotiriou M, Wohleke T, Miskovic A, Simon A, Doss M, Dogan S, Wimmer-Greinecker G, Moritz A. (2005). Valve opening and closing dynamics after different aortic valve-sparing operations. *JHeart Valve Dis*, Vol. 14, No. 1, pp. (114-120).
- Bassano C, De Matteis GM, Nardi P, Buratta MM, Zeitani J, De Paulis R, Chiariello L. (2001). Mid-term follow-up of aortic root remodelling compared to Bentall operation. *Eur J Cardiothorac Surg*, Vol. 19, No. 5, pp. (601-605).
- Bentall HH, De Bono A. (1968). A technique for complete replacement of the ascending aorta. *Thorax*, Vol. 23, No. 4, pp. (338-339).
- Bierbach BO, Aicher D, Issa OA, Bomberg H, Gräber S, Glombitza P, Schäfers HJ. (2010). Aortic root and cusp configuration determine aortic valve function. *Eur J Cardiothorac Surg*, Vol. 38, No. 4, pp. (400-406).
- Brewer RJ, Deck JD, Capati B, Nolan SP. (1976). The dynamic aortic root: its role in aortic valve function. *JThorac Cardiovasc Surg*, Vol. 72, No. 3, pp. (413-417).
- Cabanes L, Chalas C, Christin-Maitre S, Donadille B, Felten ML, Gaxotte V, Jondeau G, Lansac E, Lansac J, Letur H, N'Diaye T, Ohl J, Pariente-Khayat A, Roulot D, Thepot F, Zénaty D. (2010). Turner syndrome and pregnancy: clinical practice. Recommendations for the management of patients with Turner syndrome before and during pregnancy. *Eur J Obstet Gynecol Reprod Biol*, Vol. 152, No. 1, pp. (18-24).
- Cochran RP, Kunzelman KS. (2000). Methods of pseudosinus creation in an aortic valve-sparing operation for aneurysmal disease. *JCard Surg*, Vol. 15, No. 6, pp. (428-433).
- Dagum P, Green GR, Nistal FJ, Daughters GT, Timek TA, Foppiano LE, Bolger AF, Ingels NB Jr, Miller DC. (1999). Deformational dynamics of the aortic root: modes and physiologic determinants. *Circulation*, Vol. 100, No. 19 Suppl, pp. (II54-II62).
- David T, Feindel CM, Webb GD, Colman JM, Armstrong S, Maganti M. (2006). Long term results of aortic valve sparing operations for aortic root aneurysm. *J Thorac Cardiovasc Surg*, Vol. 132, No. 2, pp. (347-354).
- David TE, Feindel CM, Webb GD, Colman JM, Armstrong S, Maganti M. (2007). Aortic valve preservation in patients with aortic root aneurysm: results of the reimplantation technique. *Ann Thorac Surg*, Vol. 83, No. 2, pp. (S732-S735), discussion S785-S790.
- David TE, Feindel CM. (1992). An Aortic Valve-sparing operation for patients with aortic incompetence and aneurysm of the ascending aorta. *JThorac Cardiovasc Surg*, Vol. 103, No. 4, pp. (617-622).

- David TE. (1999). Aortic valve repair for management of aortic insufficiency. *Adv Card Surg*, Vol. 11, pp. (129-159).
- David TE. (2005). Sizing and tailoring the Dacron graft for reimplantation of the aortic valve. *JThorac Cardiovasc Surg*, Vol. 130, No. 2, pp. (243-244).
- De Oliveira NC, David TE, Ivanov J, Armstrong S, Eriksson MJ, Rakowski H, Webb G. (2003). Results of surgery for aortic root aneurysm in patients with Marfan syndrome. *JThorac Cardiovasc Surg*, Vol. 125, No. 4, pp. (789-796).
- De Paulis R, De Matteis GM, Nardi P, Scaffa R, Bassano C, Chiariello L. (2002). Analysis of valve motion after the reimplantation type of valve-sparing procedure (David I) with a new aortic root conduit. *Ann Thorac Surg*, Vol. 74, No. 1, pp. (53-57).
- De Waroux JB, Pouleur AC, Goffinet C, Vancraeynest D, Van Dyck M, Robert A, Gerber BL, Pasquet A, El Khoury G, Vanoverschelde JL. (2007). Functional anatomy of aortic regurgitation: accuracy, prediction of surgical reparability, and outcome implications of transesophageal echocardiography. *Circulation*, Vol. 116, No. 11 Suppl, pp. (I264-I269).
- Erasmí A, Sievers HH, Scharfschwerdt M, Eckel T, Misfeld M. (2005). In vitro hydrodynamics, cusp-bending deformation, and root distensibility for different types of aortic valve-sparing operations: remodeling, sinus prosthesis, and reimplantation. *JThorac Cardiovasc Surg*, Vol. 130, No. 4, pp. (1044-1049).
- Furukawa K, Ohteki H, Cao Z, Doi K, Narita Y, Minato N, Itoh T. (1999). Does dilatation of the sinotubular junction cause aortic regurgitation? *Ann Thorac Surg*, Vol. 68, No. 3, pp. (949-954).
- Gallo R, Kumar N, Al Halees Z, Duran C. (1995). Early failure of aortic valve conservation in aortic root aneurysm. *JThorac Cardiovasc Surg*, Vol. 109, No. 5, pp. (1011-1012).
- Gleason TG. (2005). New graft formulation and modification of the David reimplantation technique. *JThorac Cardiovasc Surg*, Vol. 130, No. 2, pp. (601-603).
- Gorman JH 3rd, Gupta KB, Streicher JT, Gorman RC, Jackson BM, Ratcliffe MB, Bogen DK, Edmunds LH Jr. (1996). Dynamic three-dimensional imaging of the mitral valve and the left ventricle by rapid sonomicrometry array localization. *J Thorac Cardiovasc Surg*, Vol. 112, No. 3, pp. (712-726).
- Grande-Allen KJ, Cohran RP, Reinhall PG, Kunzelman KS. (2000). Re-creation of sinuses is important for sparing the aortic valve: a finite element model. *JThorac Cardiovasc Surg*, Vol. 119, No. 4 Pt 1, pp. (753-763).
- Hanke T, Charitos EI, Stierle U, Robinson D, Gorski A, Sievers HH, Misfeld M. (2009). Factors associated with the development of aortic valve regurgitation over time after two different techniques of valve-sparing aortic root surgery. *J Thorac Cardiovasc Surg.*, Vol. 137, No. 2, pp. (314-319).
- Hansen B, Menkis AH, Vesely I. (1995). Longitudinal and radial distensibility of the porcine aortic root. *Ann Thorac Surg*, Vol. 60, No. 2 Suppl, pp. (S384-S390).
- Hess PJ Jr, Klodell CT, Beaver TM, Martin TD. (2005). The Florida sleeve: a new technique for aortic root remodeling with preservation of the aortic valve and sinuses. *Ann Thorac Surg*, Vol. 80, No. 2, pp. (748-750).



- Hetzer R, Komoda S, Komoda T. (2008). Remodeling of aortic root by annular reconstruction and plication of sinuses of valsalva left ventricular a. *J Card Surg*, Vol. 23, No. 1, pp. (49-51).
- Higashidate M, Tamiya K, Toshiyuki B, Yasaharu I. (1995). Regulation of the aortic valve opening: in vivo dynamic of aortic valve orifice area. *J Thorac Cardiovasc Surg*, Vol. 110, No. 2, pp. (496-503).
- Hiratzka LF, Bakris GL, Beckman JA, Bersin RM, Carr VF, Casey DE Jr, et al. (2010). ACCF/AHA/AATS/ACR/ASA/SCA/SCAI/SIR/STS/SVM guidelines for the diagnosis and management of patients with Thoracic Aortic Disease: a report of the American College of Cardiology Foundation/American Heart Association Task Force on Practice Guidelines, American Association for Thoracic Surgery, American College of Radiology, American Stroke Association, Society of Cardiovascular Anesthesiologists, Society for Cardiovascular Angiography and Interventions, Society of Interventional Radiology, Society of Thoracic Surgeons, and Society for Vascular Medicine. *Circulation*, Vol. 121, No. 13, pp. (e266-369).
- Hopkins RA. (2003). Aortic valve leaflet sparing and aortic valve replacement: evolution of techniques for aortic root reconstruction. *Eur J Cardiothorac Surg*, Vol. 24, No. 6, pp. (886-897).
- Houel R, Soustelle C, Kirsch M, Hillion ML, Renaut C, Loisançe DY. (2002). Long-term results of the Bentall operation versus separate replacement of the ascending aorta and aortic valve. *J Heart Valve Dis.*, Vol. 11, No. 4, pp. (485-491).
- Iung B, Baron G, Butchart EG, Delahaye F, Gohlke-Barwolf C, Levang OW, Tornos P, Vanoverschelde JL, Vermeer F, Boersma E, Ravaut P, Vahanian A. (2003). A prospective survey of patients with valvular heart disease in Europe: The Euro Heart Survey on Valvular Heart Disease. *Eur Heart J*, Vol. 24, No. 13, pp. (1231-1243).
- Karck M, Kallenbach K, Hagl C, Rhein C, Leyh R, Haverich A. (2004). Aortic root surgery in Marfan syndrome: Comparison of aortic valve-sparing reimplantation versus composite grafting. *J Thorac Cardiovasc Surg*, Vol. 127, No. 2, pp. (391-398).
- Kollar A. (2007). Valve-sparing reconstruction within the native aortic root: integrating the Yacoub and the David methods. *Ann Thorac Surg*, Vol. 83, No. 6, pp. (2241-2243).
- Kunzelman KS, Grande KJ, David TE, Cochran RP, Verrier ED. (1994). Aortic root and valve relationships: impact on surgical repair. *J Thorac Cardiovasc Surg*, Vol. 107, No. 1, pp. (162-170).
- La Canna G, Maisano F, De Michele L, Grimaldi A, Grassi F, Capritti E, De Bonis M, Alfieri O. (2009). Determinants of the Degree of Functional Aortic Regurgitation in Patients With Anatomically Normal Aortic Valve and Ascending Thoracic Aorta Aneurysm Transesophageal Doppler Echocardiography Study. *Heart*, Vol. 95, No. 2, pp. (130-136).
- Lansac E, Di Cetta I, Arnaud Crozat E, Bouchot O, Doguet F, Daroca T, Nijs J. An external open ring for isolated aortic valve repair. (2011a). *MMCTS* (February 14, 2011). doi:10.1510/mmcts.2009.004119 (<http://mmcts.ctsnetjournals.org/cgi/content/abstract/2011/0214/mmcts.2009.004119>).

- Lansac E, Di Centa I, Arnaud Crozat E, Bouchot O, Doguet F, Hacini R, Demaria R, Chatel D, Sleilaty G, Debauchez M. (2011b). Remodeling of the aortic root combined to an expandible aortic ring annuloplasty. *MMCTS* (April 1, 2011). doi: 10.1510/mmcts.2006.001958  
<http://mmcts.ctsnetjournals.org/cgi/content/full/2011/0401/mmcts.2006.001958>.
- Lansac E, Di Centa I, Bonnet N, Leprince P, Jault F, Rama A, Acar C, Pavie P, Gandjbakhch I. (2006). Aortic prosthetic ring annuloplasty: a useful adjunct to a standardized aortic valve-sparing procedure? *Eur J Cardiothorac Surg*, Vol. 29, No. 4, pp. (537-544).
- Lansac E, Di Centa I, Raoux F, Al Attar N, Acar C, Joudinaud T, Raffoul R. (2008). A lesional classification to standardize surgical management of aortic insufficiency towards valve repair. *Eur J Cardio Thorac Surg*, Vol. 33, No. 5, pp. (872-880).
- Lansac E, Di Centa I, Raoux F, Bulman-Fleming N, Ranga A, Abed A, Ba M, Paolitto A, Letourneur D, Meddahi-Pelle A. (2009). An expandible aortic ring for a physiological approach to conservative aortic valve surgery. *J Thorac Cardiovasc Surg*, Vol. 138, No. 3, pp. (718-724).
- Lansac E, Di Centa I, Sleilaty G, Arnaud Crozat E, Bouchot O; Hacini R; Blin D, Doguet F; Bessou JP, Albat B, De Maria R, Villemot JP, Portocarrero E, Acar C, Chatel D, Lopez S, Folliguet T, Debauchez M. (2010a). An aortic ring: from a physiological reconstruction of the root to a standardized approach of aortic valve repair. *J Thorac Cardiovasc Surg*, Vol. 140, No. 6 Suppl, pp. (S28-S35).
- Lansac E, Di Centa I, Sleilaty G, Bouchot O, Arnaud Crozat E, Blin D, Acar C, Debauchez M. (2010b). An aortic ring to standardize aortic valve repair: a preliminary results of a prospective multicentric cohort of 144 patients. *Eur J CardioThorac Surg*, Vol. 38, No. 2, pp. (147-154).
- Lansac E, Di Centa I, Varnous S, Rama A, Jault F, Duran CMG, Acar C, Pavie A, Gandjbakhch I. (2005a). External aortic annuloplasty ring for valve-sparing procedures. *Ann Thorac Surg*, Vol. 79, No. 1, pp. (356-358).
- Lansac E, Lim HS, Shomura Y, Lim KH, Rice Nt, Goetz W, Duran C. (2002). A four-dimensional study of the aortic root dynamics. *Eur J Cardiothorac Surg*, Vol. 22, No. 4, pp. (497-503).
- Lansac E, Lim HS, Shomura Y, Lim KH, Rice NT, Goetz WA, Duran CM. (2005b). Aortic root dynamics are asymmetric. *J Heart Valve Dis*, Vol. 14, No. 3, pp. (400-407).
- Lansac, E. Di Centa, I. (2010c). From dynamic anatomy to conservative aortic valve surgery: the tale of the ring, In: *Aortic root surgery*, Yankah, CA. Weng, Y., Hetzer, R., pp. (102-132), Springer, ISBN 978-3-7985-1868-1, Germany.
- Leyh RG, Fischer S, Kallenbach K, Kofidis T, Pethig K, Harringer W, Haverich A. (2002). High failure rate after valve-sparing aortic root replacement using the "remodelling technique" in acute type A aortic dissection. *Circulation*, Vol. 106, No. 12 Suppl 1, pp. (I229-I233).
- Leyh RG, Schmidtke C, Sievers HH, Yacoub MH. (1999). Opening and closing characteristics of the aortic valve after different types of valve-preserving surgery. *Circulation*, Vol. 100, No. 21, pp. (2153-2160).

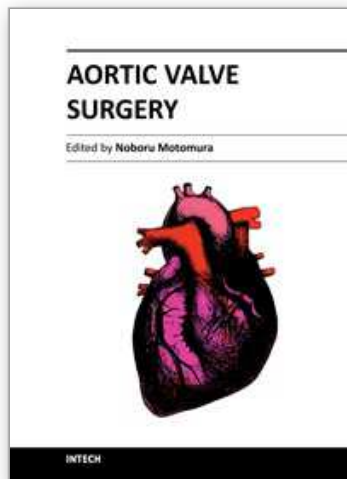
- Luciani GB, Casali G, Tomezzoli A, Mazzucco A. (1999). Recurrence of aortic insufficiency after aortic root remodeling with valve preservation. *Ann Thorac Surg*, Vol 67, No. 6, pp. (1849-1852).
- Maselli D, Montalto A, Santise G, Minardi G, Manzara C, Musumeci F. (2005). A normogram to anticipate dimension of neo-sinuses of valsalva in valve-sparing aortic operations. *Eur J Cardiothorac Surg*, Vol. 27, No. 5, pp. (831-835).
- Miller DC. (2007). Valve-sparing aortic root replacement: current state of the art and where are we headed? *Ann Thorac Surg*, Vol. 83, No. 2, pp. (S736-S739).
- Morishita K, Murakami G, Koshino T, Fukada J, Fujisawa Y, Mawatari T, Abe T. (2002). Aortic root remodeling operation: how do we tailor a tube graft? *Ann Thorac Surg*, Vol. 73, No. 4, pp. (1117-1721).
- Muriago M, Sheppard MN, Ho SY, Anderson RH. (1997). Location of the coronary arterial orifices in the normal heart. *Clin Anat*, Vol. 10, No. 5, pp. (297-302).
- Nataf P, Lansac E. (2006). Dilation of the Thoracic aorta: medical or surgical management. *Heart*, Vol. 92, No. 9, pp. (1345-1352).
- Pang DC, Choo SJ, Luo HH, Shomura Y, Daniel S, Nikolic SJ, Cheung DT, Oury JH, Duran CMG. (2000). Significant increase of aortic root volume and commissural area occurs prior to aortic valve opening. *J Heart Valve Dis*, Vol. 9, No. 1, pp. (9-15).
- Patel ND, Weiss ES, Alejo DE, Nwakanma LU, Williams JA, Dietz HC, Spevak PJ, Gott VL, Vricella LA, Cameron DE. (2008). Aortic root operations for Marfan syndrome: a comparison of the Bentall and valve-sparing procedures. *Ann Thorac Surg*, Vol. 85, No 6, pp. (2003-2010).
- Reid K. (1970). The anatomy of the sinus of Valsalva. *Thorax*, Vol. 25, No. 1, pp. (79-85).
- Roberts WC, Ko JM, Moore TR, Jones WH 3<sup>rd</sup>. (2006). Causes of pure aortic regurgitation in patients having isolated aortic valve replacement at a single US tertiary hospital (1993 to 2005). *Circulation*, Vol. 114, No. 5, pp. (422-429).
- Roberts WC. (1970). The structure of the aortic valve in clinically isolated aortic stenosis: an autopsy study of 162 patients over 15 years of age. *Circulation*, Vol. 42, No. 1, pp. (91-97).
- Robicksek F. (1991). Leonardo da Vinci and the sinuses of Valsalva. *Ann Thorac Surg*, Vol. 52, No 2, pp. (328-335).
- Roman MJ, Devereux RB, Niles NW, Hochreiter C, Kligfield P, Sato N, Spitzer MC, Borer JS. (1987). Aortic root dilatation as a cause of isolated, severe aortic regurgitation. Prevalence, clinical and echocardiographic patterns, and relation to left ventricular hypertrophy and function. *Ann Intern Med*, Vol. 106, No. 6, pp. (800-807).
- Ruvolo G, Fattouch K. (2009). Aortic valve-sparing root replacement from inside the aorta using three Dacron skirts preserving the native Valsalvasinuses geometry and stabilizing the annulus. *Interact Cardiovasc Thorac Surg*, Vol. 8, No. 2, pp. (179-181).
- Schäfers HJ, Bierbach B, Aicher D. (2006). A new approach to the assessment of aortic cusp geometry. *J Thorac Cardiovasc Surg*, Vol. 132, No. 2, pp. (436-438).
- Schäfers HJ, Kuniyama T, Fries P, Brittner B, Aicher D. (2010). Valve-preserving root replacement in bicuspid aortic valves. *J Thorac Cardiovasc Surg*, Vol. 140, No. 6 Suppl, pp. (S36-S40).

- Silver MA, Roberts WC. (1985). Detailed anatomy of the normally functioning aortic valve in hearts of normal and increased weight. *Am J Cardiol*, Vol. 55, No. 4, pp. (454-461).
- Soncini M, Votta E, Zinicchino S, Burrone V, Mangini A, Lemma M, Antona C, Redaelli A. (2009). Aortic root performance after valve sparing procedure: a comparative finite element analysis. *Med Eng Phys*, Vol. 31, No. 2, pp. (234-243).
- Sutton JP III, Ho SY, Anderson RH. (1995). The forgotten interleaflet triangles: a review of the surgical anatomy of the aortic valve. *Ann Thorac Surg*, Vol. 59, No. 2, pp. (419-427).
- Svensson LG. (2003). Sizing for modified David's reimplantation procedure. *Ann Thorac Surg*, Vol. 76, No. 5, pp. (1751-1753).
- Takamoto S, Nawata K, Morota T. (2006). A simple modification of "David-V" aortic root reimplantation. *Eur J Cardiothorac Surg*, Vol. 30, No. 3, pp. (560-562).
- Tamás E, Nylander E. (2007). Echocardiographic description of the anatomic relations within the normal aortic root. *J Heart Valve Dis*, Vol. 16, No. 3, pp. (240-246).
- Thubrikar M, Bosher LP, Nolan SP. (1979). The mechanism of opening of the aortic valve. *J Thorac Cardiovasc Surg*, Vol. 77, No. 6, pp. (863-870).
- Thubrikar M, Harry L, Nolan SP. (1977). Normal aortic valve function in dogs. *Am J Cardiol*, Vol. 40, No. 4, pp. (563-568).
- Thubrikar M, Heckman JL, Nolan SP. (1993). High speed cine-radiographic study of the aortic valve leaflet motion. *J Heart Valve Dis*, Vol. 2, No. 6, pp. (653-661).
- Tops LF, Wood DA, Delgado V, Schuijf JD, Mayo JR, Pasupati S, Lamers FPL, van der Wall EE, Schalij MJ, Webb JG, Bax JJ. (2008). Noninvasive evaluation of the aortic root with multi-slice computed tomography: implications for transcatheter aortic valve replacement. *J Am Coll Cardiol Img*, Vol. 1, No. 3, pp. (321-330).
- Turner K, Navartnam V. (1996). The positions of coronary arterial ostia. *Clin Anat*, Vol. 9, No. 6, pp. (376-380).
- Urbanski PP, Zhan X, Frank S, Diegeler A. (2009) Aortic root reconstruction using new vascular graft. *Interact Cardiovasc Thorac Surg*, Vol. 8, No. 2, pp.(187-190).
- Vahanian A, Baumgartner H, Bax J, Butchart E, Dion R, Filippatos G, Flachskampf F, Hall R, Jung B, Kasprzak J, Nataf P, et al. (2007). Guidelines on the management of valvular heart disease: The Task Force on the Management of Valvular Heart Disease of the European Society of Cardiology. *Eur Heart J*, Vol. 28, No. 2, pp. (230-268).
- Volguina IV, Miller DC, LeMaire SA, Palmero LC, Wang XL, Connolly HM, Sundt TM 3rd, Bavaria JE, Dietz HC, Milewicz DM, et al. (2009) Valve-sparing and valve-replacing techniques for aortic root replacement in patients with Marfan syndrome: Analysis of early outcome. *J Thorac Cardiovasc Surg*, Vol. 137, No. 5, pp. (1124-1132).
- Vollebergh FE, Becker AE. (1977). Minor congenital variations of cusp size in tricuspid aortic valves: possible link with isolated aortic stenosis. *Br Heart J*, Vol. 39, No. 9, pp. (1006-1011).
- Yacoub M, Fagan A, Stassano P, Radley-Smith R. (1983). Result of valve conserving operations for aortic regurgitation [abstract]. *Circulation*, Vol. 68(suppl):III321.
- Yacoub MH, Gehle P, Chandrasekaran V, Birks EJ, Child A, Radley-Smith R. (1998). Late results of a valve sparing operation in patients with aneurysms of the ascending aorta and root. *J Thorac Cardiovasc Surg*, Vol. 115, No. 5, pp. (1080-1090).

- Zehr KJ, Orszulak TA, Mullany CJ, Matloobi A, Daly RC, Dearani JA, Sundt TM 3rd, Puga FJ, Danielson GK, Schaff HV. (2004). Surgery for aneurysms of the aortic root: a 30-year experience. *Circulation*, Vol. 110, No 11, pp. (1364-1371).
- Zehr KJ, Thubrikar MJ, Gong GG, Headrick JR, Robicsek F. (2000). Clinical introduction of a novel prosthesis for valve-preserving aortic root reconstruction for annuloaortic ectasia. *JThorac Cardiovasc Surg*, Vol. 120, No. 6, pp. (692-698).

IntechOpen

IntechOpen



## **Aortic Valve Surgery**

Edited by Prof. Noboru Motomura

ISBN 978-953-307-600-3

Hard cover, 246 pages

**Publisher** InTech

**Published online** 22, December, 2011

**Published in print edition** December, 2011

The aortic valve is located at the center of the heart. It is the core of cardiac anatomy and aortic valve surgery has led the field of cardiac surgery. This book describes all aspects of aortic valve surgery and it will help clarify daily questions regarding the clinical practice in aortic valve surgery, as well as induce inspiration and new insights into this field.

### **How to reference**

In order to correctly reference this scholarly work, feel free to copy and paste the following:

Emmanuel Lansac, Isabelle Di Centa, Rémi Escande, Maguette Ba, Nizar Kellil, Eric Arnaud Crozat, Eric Portocarrero, Aicha Abed, Anthony Paolitto, Mathieu Debauchez and Anne Meddahi- Pelle (2011). An Expansible Aortic Ring for a Standardized and Physiological Approach of Aortic Valve Repair, *Aortic Valve Surgery*, Prof. Noboru Motomura (Ed.), ISBN: 978-953-307-600-3, InTech, Available from: <http://www.intechopen.com/books/aortic-valve-surgery/an-expansible-aortic-ring-for-a-standardized-and-physiological-approach-of-aortic-valve-repair>

**INTECH**  
open science | open minds

### **InTech Europe**

University Campus STeP Ri  
Slavka Krautzeka 83/A  
51000 Rijeka, Croatia  
Phone: +385 (51) 770 447  
Fax: +385 (51) 686 166  
[www.intechopen.com](http://www.intechopen.com)

### **InTech China**

Unit 405, Office Block, Hotel Equatorial Shanghai  
No.65, Yan An Road (West), Shanghai, 200040, China  
中国上海市延安西路65号上海国际贵都大饭店办公楼405单元  
Phone: +86-21-62489820  
Fax: +86-21-62489821

© 2011 The Author(s). Licensee IntechOpen. This is an open access article distributed under the terms of the [Creative Commons Attribution 3.0 License](#), which permits unrestricted use, distribution, and reproduction in any medium, provided the original work is properly cited.

IntechOpen

IntechOpen