

We are IntechOpen, the world's leading publisher of Open Access books Built by scientists, for scientists

4,800

Open access books available

122,000

International authors and editors

135M

Downloads

Our authors are among the

154

Countries delivered to

TOP 1%

most cited scientists

12.2%

Contributors from top 500 universities



WEB OF SCIENCE™

Selection of our books indexed in the Book Citation Index
in Web of Science™ Core Collection (BKCI)

Interested in publishing with us?
Contact book.department@intechopen.com

Numbers displayed above are based on latest data collected.
For more information visit www.intechopen.com



Pediatric Natural Killer Cell Malignancy

Yoshiko Hashii

*Department of Developmental Medicine, Osaka University Graduate School of Medicine
Japan*

1. Introduction

Natural killer (NK) cell malignancy is a heterogeneous disorder and rare, representing <1% of non-Hodgkin lymphomas for most of the world, except in Asia and Latin America. In Asia, especially, the incidence of NK-cell lymphomas is approximately 7%-10% of lymphomas [Au et al., 2005].

The pathogenesis of NK-cell malignancies has not yet been fully elucidated. In the 2008 World Health Organization (WHO) classification of tumors of hematopoietic and lymphoid tissues, there are two entities associated with NK cells: mature T-cell and NK-cell neoplasms (including chronic lymphoproliferative disorder of NK cells, aggressive NK-cell leukemia, and extranodal NK/T-cell lymphoma, nasal type) and NK-cell lymphoblastic leukemia/lymphoma, which is included provisionally in the category of acute leukemias of ambiguous lineage (Table 1) [Swedlow et al., 2008]. What was previously described as blastic NK-cell leukemia is defined as blastic plasmacytoid dendritic cell neoplasm in the WHO 2008 classification [Swedlow et al., 2008]. In pediatric patients, the four NK cell neoplasms are rare, with blastic NK-cell lymphoma being the most prevalent.

-
- Acute leukemias of ambiguous lineage
 - NK-cell lymphoblastic leukemia/lymphoma
 - Mature T-cell and NK-cell neoplasms
 - Chronic lymphoproliferative disorder of NK cells
 - Aggressive NK-cell leukemia
 - Extranodal NK/T-cell lymphoma, nasal type
-

Table 1. WHO classification of hematopoietic and lymphoid neoplasms associated with NK cells [Swedlow et al., 2008]

A rigorous review of the literature to date is required to adequately understand and manage the various pediatric NK-cell malignant entities. The clinical characteristics of pediatric cases with these NK-cell malignant entities defined according to the 2008 WHO classification are discussed in this paper and compared to adult cases.

2. Pathology of NK-cell neoplasms in pediatric patients

The 2008 WHO classification of tumors of hematopoietic and lymphoid tissue recognizes four categories of NK-cell neoplasms: NK-cell lymphoblastic leukemia/lymphoma, chronic

lymphoproliferative disorder of NK cells, aggressive NK-cell leukemia (ANKL), and extranodal NK/T-cell lymphoma, nasal type (ENKL) (Table 1). NK-cell lymphoblastic leukemia involves immature NK cells, while chronic lymphoblastic leukemia/lymphoma, chronic lymphoproliferative disorder of NK cells, and aggressive NK-cell leukemia are mainly neoplasms of mature NK cells. ENKL is the main neoplasm of mature NK cells. Among the four entities, ANKL and ENKL are associated with Epstein-Barr virus (EBV).

2.1 NK-cell lymphoblastic leukemia/lymphoma

NK-cell lymphoblastic leukemia/lymphoma is a very rare disease in both adults and children. Because of limitations in NK-cell-specific markers, it is included as acute leukemia of ambiguous lineage according to the WHO 2008 classification [Swerdlow et al., 2008]. This neoplasm has been difficult to define. CD56 is the most important and sensitive NK-cell marker, but CD56 is not specific for NK cells. Previously, many cases were reported as NK-cell leukemia because of the expression of CD57 but are plasmacytoid dendritic cell leukemia in the WHO 2008 classification. This issue is discussed below.

2.2 Chronic lymphoproliferative disorder of NK cells

Chronic lymphoproliferative disorder of NK cells is rare, especially in pediatric patients. It occurs in adults at a median age of 60 years. This provisional entity in the WHO 2008 classification is characterized by a persistent (>6 months) increase in peripheral blood NK cells (usually $2 \times 10^9/L$) without a clearly identified cause. It is very difficult to distinguish between neoplastic and reactive NK cells. Cells have an NK-cell phenotype: CD16⁺, CD56⁺, CD2⁻, CD7⁻, surface CD3 (sCD3)⁻, and cytoplasmic CD3 (CD3 ϵ)⁺. Cytotoxic markers including T-cell-restricted intracellular antigen-1 (TIA-1), granzyme B, and granzyme M are positive. EBV is negative. One pediatric case has been reported from China [Kwong et al., 1995]. CD2 was positive and CD3 was weakly positive. EBV status was not described. The case was a 3-year-old female who presented hepatosplenomegaly. She died 11 days after diagnosis because of uncontrolled disease and did not receive chemotherapy. The clinical course of the majority of cases with chronic lymphoproliferative disorder of NK cells shows a good prognosis and transformation to aggressive disease has been rarely reported [Ohno et al., 1998].

2.3 Aggressive NK-cell leukemia

ANKL is a systemic proliferation of NK cells with primary involvement of peripheral blood and bone marrow, and shows a fulminant clinical course. The age distribution of ANKL patients has been reported to show two peaks, one at 20 years and the other at 40 years of age [Suzuki et al., 2004b]. The disease typically affects patients at a younger age compared to other NK-cell malignancies. The clinical features, and cytological and immunohistochemical findings of this rare pediatric NK-cell malignancy are summarized in Tables 2 and 3. EBV is closely associated with the pathogenesis of this disease. Latent EBV shows monoclonality and causes EBV-infected NK-cell lymphoproliferative disease.

2.3.1 Diagnosis

Patients are diagnosed with ANKL when a proliferation of large granular lymphoblasts of an NK-cell phenotype is found in peripheral blood and/or bone marrow exceeding 30% of the total nucleated cells [Suzuki et al., 2004b]. The immunophenotype of ANKL is typically

defined by CD2⁺, sCD3⁻, CD3ε⁺, and CD56⁺. Loss of CD7 is occasionally observed. This immunophenotype is almost identical to that for extranodal NK/T-cell lymphoma, except for CD16⁺. T-cell receptor (TCR) genes are in germline configuration. Some cases are CD11b⁺ and CD57⁻. These neoplastic cells express FAS ligand and high levels of FAS ligand can be found in the serum of affected patients [Kato et al., 1998].

2.3.2 Clinical features and immunohistochemical findings in pediatric and adolescent patients

To date, 19 pediatric and adolescent cases (<19 years of age) have been reported in the literature from 1986 to 2010. Most patients have been reported from Japan and Korea. Table 2 summarizes the clinical findings of these 19 pediatric cases. Median age at diagnosis was 14 years (range, 2–19 years). Gender distribution was equal (9 females and 10 males), which is the same in adult patients. Acute lymphoblastic leukemia typically affects children at 2–6 years of age, while the median age of ANKL patients is generally higher.

Pediatric ANKL patients presented acute and rapidly progressive symptomatology. The most common presenting symptom is fever (12/13, 92%). Hepatomegaly (10/13, 77%), splenomegaly (12/16, 75%), and lymphadenopathy (6/16, 37%) are also frequently observed. The incidence of these symptoms is almost the same as that of adult patients [Yoo et al., 2009]. Two patients (cases 3 and 5) presented a chronic course and spontaneous regression was seen and transformation to ANKL. In adult patients, transformation from chronic lymphoproliferative disorder of NK cells to ANKL has been rarely reported. Pediatric patients manifest features of chronic active EBV infection, leading to overlap with EBV-positive T-cell lymphoproliferative disorders [Suzuki et al., 2004a]. The clinical presentation of ANKL has a resemblance to EBV-associated hemophagocytic lymphohistiocytosis. Chronic active EBV infection occurs predominantly in children and young adults and the incidence of hemophagocytosis as a clinical feature is frequently observed in cases of pediatric ANKL. Hypersensitivity to mosquito bites is sometimes seen as a preceding feature of ANKL in pediatric and adolescent patients.

This disease is typically resistant to chemotherapy and successful treatment has been infrequently reported. The complete response rate is below 20% and 2-year overall survival rate is 5% in adult patients [Suzuki, 2010; Suzuki et al., 2010]. There is insufficient data to interpret complete remission and overall survival rates in pediatric ANKL patients. Results have been unsatisfactory using combination chemotherapy regimens that are typically used for acute lymphoblastic leukemia or non-Hodgkin lymphoma. In adults, chemotherapy with L-asparaginase-containing regimens has been reported to be effective in some cases [Ichikawa et al., 2010]. Among pediatric ANKL cases, only two patients were reported as being alive and one patient died with complete remission, while 13 cases died and one (case 15) died of graft-versus-host disease (GVHD) and infection without relapse. The median survival time for patients who died is 4 months. Two cases received allogeneic stem cell transplantation: one died due to GVHD without disease and one was alive. Chemotherapy with L-asparaginase-containing regimens and subsequent allogeneic stem cell transplantation led to prolonged survival in a few young adult patients, even when the stem cell transplantation was performed in patients who did not have a complete response [Ito et al., 2008]. Better outcome is suggested among patients who received allogeneic stem cell transplantation.

Case	Age/ gender	Fever	Hepato- megaly	Spleno- megaly	Lymph- adenopathy	Other sites	Treatment	Prognosis	Reference
1	6 y/M	+	+	+	+		NHL-BFM 90/Allo-SCT	Alive	Ohnuma et al., 1997
2	14 y/F	+	+	+	+	Skin	VCR/Dox/Cy /CA	Aggressive, died 4 mo	Koizumi et al., 1986
3	13 y/M	ND	ND	+	ND		ND	ND	Kawa-Ha et al., 1989
4	15 y/M	ND	ND	+	ND		ND	ND	Kawa-Ha et al., 1989
5	16 y/F	ND	ND	+	ND		ND	ND	Kawa-Ha et al., 1989
6	16 y/F	+	+	+	-		ND	Aggressive, died 32 mo	Imamura et al., 1990
7	13 y/F	+	+	+	+		ND	Aggressive, died 26 mo	Imamura et al., 1990
8	18 y/M	+	+	+	+	Lung	VDS/THP- ADR/Cy/PSL	Aggressive, died 4 mo	Furuno et al., 1994
9	13 y/M	+	+	+	-		PSL	Aggressive, died 47 d	Kaizu et al., 2004
10	19 y/F	+	+	-	-	HPS	DHAP	Aggressive, died 14 d	Kohrt & Advani, 2004
11	17 y/F	+	+	+	-		COP/BLM	Aggressive, died 1 mo	Suzuki et al., 2004b
12	12 y/M	+	-	-	+	Lung	DNR/Cy/VCR /L-Asp/PSL	Aggressive, died 5 mo	Suzuki et al., 2004b
13	16 y/F	+	+	+	-	Kidney	PSL	Aggressive, died 1 d	Suzuki et al., 2004b
14	18 y/F	+	-	-	+	Tonsil	CHOP/Allo- SCT	Died due to GVHD 39 mo	Suzuki et al., 2004b
15	13 y/M	-	-	+	-		AIEOP-95	Alive, CCR 1447 d	Patel et al., 2010
16	14 y/F	ND	ND	ND	ND		ND	Aggressive, died 1 mo	Yoo et al., 2009
17	2 y/M	ND	ND	ND	ND		ND	Aggressive, died 5 d	Yoo et al., 2009
18	16 y/M	ND	ND	ND	ND		ND	Aggressive, died 11 mo	Yoo et al., 2009
19	5 y/M	+	+	-	-	HPS	HLH2004	Aggressive, died 4 mo	Petterson et al., 2008

Abbreviations: ADR, adriamycin; AIEOP-95, Associazione Italiana Ematologia Oncologia Pediatrica 95 protocol; Allo-SCT, allogeneic stem cell transplantation; BLM, bleomycin; CA, cytarabine; CCR, clinical complete response; CHOP, cyclophosphamide, doxorubicin, vincristine, prednisolone; COP, cyclophosphamide, vincristine, prednisolone; Cy, cyclophosphamide; d, days; DHAP, dexamethasone, high-dose cytarabine, cisplatin; Dox, doxorubicin; F, female; GVHD, graft-versus-host disease; HLH2004, hemophagocytic lymphohistiocytosis 2004 protocol; HPS, hemophagocytosis; L-Asp, L-asparaginase; M, male; mo, months; ND, not determined; NHL-BFM 90, non-Hodgkin lymphoma-Berlin-Frankfurt-Munster 90 protocol; mo, month; PSL, prednisolone; THP-ADR, pirarubicin; VCR, vincristine; VDS, vindesine; y, year.

Table 2. Clinical characteristics of pediatric patients with aggressive NK leukemia

Yoo et al. have reported that CD7 antigen loss is frequently observed among adult ANKL patients and the absence of CD7 may serve as a reliable marker for the diagnosis of ANKL in adults [Yoo et al., 2009]. However, CD7⁺ is shown in 13 of 16 pediatric ANKL patients (Table 3). Immunophenotypic analysis of CD7 expression is therefore not useful in the diagnosis of ANKL in pediatric patients. EBV DNA is detected in almost all pediatric patients.

Case	CD2	CD3 ϵ	sCD3	CD4	CD7	CD8	CD16	CD56	CD57	EBV DNA	Reference
1	+	ND	-	-	+	-	-	+	-	+	Ohnuma et al., 1997
2	+	ND	-	-	ND	-	+	-	-	+	Koizumi et al., 1986
3	+	ND	-	-	ND	-	+	ND	ND	+	Kawa-Ha et al., 1989
4	+	+	-	-	+	-	-	+	ND	+	Kawa-Ha et al., 1989
5	+	ND	-	-	+	-	+	+	ND	+	Kawa-Ha et al., 1989
6	+	ND	-	-	+	-	+	ND	-	ND	Imamura et al., 1990
7	+	ND	-	-	+	-	ND	+	ND	ND	Imamura et al., 1990
8	+	ND	-	-	+	-	+	ND	ND	+	Furuno et al., 1994
9	+	ND	-	ND	+	ND	-	+	-	+	Kaizu et al., 2004
10	ND	+	-	ND	ND	ND	ND	+	ND	ND	Kohrt & Advani, 2004
11	+	ND	-	-	+	+	ND	+	ND	+	Suzuki et al., 2004b
12	+	ND	-	-	-	-	+	+	ND	+	Suzuki et al., 2004b
13	+	ND	-	-	+	-	+	+	ND	+	Suzuki et al., 2004b
14	+	-	-	-	+	-	ND	+	-	ND	Suzuki et al., 2004b
15	-	+	-	-	-	-	-	+	ND	ND	Patel et al., 2010
16	+	+	-	-	+	-	+	+	ND	ND	Yoo et al., 2009
17	+	+	-	ND	+	ND	+	+	ND	ND	Yoo et al., 2009
18	+	+	-	-	+	-	+	+	ND	-	Yoo et al., 2009
19	+	+	-	-	-	+	ND	+	ND	+	Petterson et al., 2008

Abbreviations: EBV, Epstein-Barr virus; ND, not determined.

Table 3. Phenotypic characteristics of pediatric patients with aggressive NK leukemia. Case numbers correspond with those in Table 2

2.4 Nasal and extranodal NK-cell lymphoma

ENKL is characterized by vascular damage and destruction, prominent necrosis, a cytotoxic phenotype, and an association with EBV. ENKL typically presents in the nasal cavity or nasopharynx, with most cases having tumors localized in the upper aerodigestive tract (UAT) including nasal cavity, nasopharynx, oral cavity, oropharynx, and hypopharynx. Primary tumors that present outside the UAT, but share identical histologic features with the UAT disease, have also been categorized as non-nasal-type NK/T-cell lymphoma (NUAT-ENKL). There is clinical heterogeneity between nasal and extranasal UAT-ENKL or between UAT-ENKL and NUAT-ENKL [Kohrt et al., 2009; Kim et al., 2008]. Kim et al. reported that NUAT-ENKL had significantly higher proportions of disseminated disease, aggressive biologic features, and worse prognosis than UAT-ENKL [Kim et al., 2008]. In the UAT-ENKL group, there are differences in clinical prognostic factors between nasal UAT and extranasal UAT. Patients with extranasal UAT showed a higher proportion of advanced disease (stages III and IV on the Ann Arbor system) and regional lymphadenopathy. However, there did not seem to be any difference between extranasal UAT-ENKL and nasal UAT-ENKL with respect to survival rate. Compared to patients with UAT-ENKL (including both nasal and extranasal UAT ENKL), patients with NUAT-ENKL showed significantly higher proportions of advanced-stage disease, two or more extranodal sites, positive regional lymphadenopathy, presence of B symptoms, and poor Eastern Cooperative Oncology Group performance status. As a result of the aggressive features of NUAT-ENKL, survival rates were lower than those of UAT-ENKL (5-year overall survival rate: 22% versus 41%, $P < 0.001$) [Kim et al., 2008].

ENKL is rare in Western countries, but is more frequent in East Asia, and Central and South America [Oshimi, 1996]. It represents 3.3% of all non-Hodgkin lymphoma in Japan, 6% in Hong Kong, 8% in Korea, and 5% in Taiwan [Lymphoma Study Group of Japanese Pathologists, 2000]. ENKL is the most common lymphoma type among primary nasal-type lymphomas in Asian patients. The male:female ratio is approximately 3:1 and the median age of presentation is middle age [Ishida & Kwong, 2010]. ENKL shows onset at an older age than ANKL.

2.4.1 Diagnosis

The immunophenotype of ENKL is typically CD2⁺, CD56⁺, CD3ε⁺, sCD3⁻, CD4⁻, CD20⁻, and CD30⁻. CD56, a highly useful marker for NK cells, is not specific for ENKL and can be expressed in peripheral T-cell lymphomas. Occasional cases are CD7⁺ or CD30⁺. ENKL shares many features with ANKL, such as the presence of azurophilic granules in the cytoplasm of the neoplastic cells and identical immunophenotype except for CD16 expression. CD16 is negative in ENKL cases, but is positive in most ANKL cases [Nava & Jaffe, 2005]. As with ANKL, ENKL tumor cells are usually EBV positive. Cytotoxic molecules are positive (granzyme B, TIA-1, and perforin). Lymphomas that demonstrate a CD3ε⁺ and CD56⁻ immunophenotype are also classified ENKL if both cytotoxic molecules and EBV are positive. TCR rearrangement is in the germline configuration. CD56 is a highly useful marker of NK cells but is not specific for ENKL. CD56 is expressed in peripheral T-cell lymphomas, particularly those that show the gamma delta TCR configuration.

2.4.2 Clinical features and Immunohistochemical findings in pediatric and adolescent patients

In this literature review, all journals were searched from 1996 to date for ENKL cases (Tables 4 and 5). Twenty-one pediatric cases with ENKL were reported: seven from Asia, 11 from

Case	Age/ gender	Stage (Ann Arbor)	Fever	Subtype (primary site)	Sites involved	Other signs	Treatment	Prognosis	Reference
1	17 y/M	IV	+	NUAT	L/S/LN	HPS	mBACOD, 2-CdA	Aggressive, died 2 mo	Kwong et al., 1997
2	17 y/F	I	-	UAT (nasal)			CHOP	Alive 27 mo	Kwong et al., 1997
3	18 y/F	I	-	UAT (nasal)			CHOP	Alive 107 mo	Kwong et al., 1997
4	16 y/F	II	+	NUAT	Cecum		CHOP	Aggressive, died 7 mo	Lei et al., 1997
5	15 y/F	IV	+	NUAT	L/S/Mes o/BM		-	Aggressive, died 59 d	Catlin et al., 1999
6	1 mo/M	IV	+	NUAT	L/S/BM		IFN- α	Aggressive, died 6 d	Catlin et al., 1999
7	9 y/M	II	-	NUAT	Sk/LN		POG9219/ CCG1883/ HDC	Alive, 41 mo	Shaw et al., 2001
8	12 y/M	II	-	NUAT	M/LN		POG9219/I CE/HDC	Alive, 15 mo	Shaw et al., 2001
9	17 y/M	IV	ND	NUAT	Sk	HPS	ND	Died 33 mo	Ko et al., 2004
10	17 y/M	IV	-	NUAT	L/Sk/L N		GEM/IRI	Aggressive, died 67 d	Pol-Rodriguez et al., 2006
11	17 y/F	IV	+	NUAT	LN/Sk/S /K/P/O	HPS/H MB	CHOP	Aggressive, died 3 mo	Aydin et al., 2007
12	0.7 y/F	I	ND	UAT (mastoid)			POG9219	Alive	Hutchinson et al., 2008
13	16.3 y/M	I	ND	UAT (nasal)			POG9219	Died	Hutchinson et al., 2008
14	16.3 y/F	II	ND	UAT (nasal)	Sk		POG9219	Alive	Hutchinson et al., 2008
15	16.6 y/M	II	ND	UAT (nasal)			POG9219	Died	Hutchinson et al., 2008
16	16 y/M	I	-	UAT (nasal)			CHOP	Alive, CCR >24 mo	Chang et al., 2008
17	12 y/F	I	-	UAT (nasal)			CHOP/IR	Alive, CCR 8 mo	Lee et al., 2008
18	11 y/M	IV	+	UAT (nasal)	BM	HPS	-	Aggressive, died 5 mo	Brodkin et al., 2008
19	9 y/F	I	+	UAT (nasophary nx)		HMB	CHOP	ND	Zhang et al., 2009
20	15 y/F	IV	+	UAT (tonsil)		HPS/L i/S	CHOP	Died 1 mo	Pellier et al., 2009
21	4 y/M	I	+	UAT (nasal)			CHOP	Aggressive, died 18 d	Miles et al., 2010

Abbreviations: BM, bone marrow; CCG1883, Childhood Cancer Group 1883 protocol; CCR, clinical complete response; CHOP, cyclophosphamide, doxorubicin, vincristine, prednisolone; d, days; F, female; GEM, gemcitabine; HDC, high-dose chemotherapy; HMB, hypersensitivity to mosquito bites; HPS, hemophagocytosis; ICE, ifosfamide, carboplatin, etoposide; IFN- α , interferon alpha; IR, irinotecan; K, kidney; L, lung; Li, liver; LN, lymph node; M, mastoid; mo, months; P, pancreas; POG9219, Pediatric Oncology Group 9219 protocol; M, male; mBACOD; bleomycin, adriamycin, cyclophosphamide,

vincristine, dexamethasone, methotrexate; meso, mesosalpinx; ND, not determined; NUAT; non-upper aerodigestive tract; O, oral; S, spleen; Sk, skin; UAT; upper aerodigestive tract; y, years; 2-CdA, 2-chlorodeoxyadenosine.

Table 4. Clinical characteristics of pediatric patients with extranodal NK leukemia

Case	CD2	CD3 _ε	CD3	CD4	CD7	CD8	CD16	CD56	Cytotoxic markers	TCR re-arrangement	EBV DNA	Reference
1	+	ND	-	-	-	-	-	+	ND	ND	ND	Kwong et al., 1997
2	+	ND	-	-	-	-	-	+	ND	ND	ND	Kwong et al., 1997
3	+	ND	-	-	-	-	-	+	ND	ND	ND	Kwong et al., 1997
4	+	-	-	-	+	-	-	+	ND	-	ND	Lei et al., 1997
5	-	-	-	-	NT	-	-	+	ND	NT	+	Catlin et al., 1999
6	-	-	-	+	+	+	+	+	ND	NT	+	Catlin et al., 1999
7	+	-	-	-	-	-	-	+	ND	-	-	Shaw et al., 2001
8	-	-	-	-	-	-	-	+	ND	ND	+	Shaw et al., 2001
9	ND	ND	ND	ND	ND	ND	ND	ND	ND	-	+	Ko et al., 2004
10	+	+	+	+	+	+	+	+	TIA-1+	NT	+	Pol-Rodriguez et al., 2006
11	+	+	ND	-	ND	-	ND	-	Granzyme B+	-	-	Aydin et al., 2007
12	ND	ND	ND	ND	ND	ND	ND	ND	ND	ND	ND	Hutchinson et al., 2008
13	ND	ND	ND	ND	ND	ND	ND	ND	ND	ND	ND	Hutchinson et al., 2008
14	ND	ND	ND	ND	ND	ND	ND	ND	ND	ND	ND	Hutchinson et al., 2008
15	ND	ND	ND	ND	ND	ND	ND	ND	ND	ND	ND	Hutchinson et al., 2008
16	+	+	NT	+	+	-	NT	-	TIA-1, granzyme B+	+	+	Chang et al., 2008
17	NT	+	+	NT	NT	NT	+	+	NT	NT	-	Lee et al., 2008
18	+	+	+	NT	NT	-	NT	+	NT	NT	+	Brodkin et al., 2008
19	+	NT	+	NT	+	+	NT	-	TIA-1+	-	+	Zhang et al., 2009
20	+	+	+	+	+	+	-	+	ND	+	+	Pellier et al., 2009
21	+	+	NT	-	+	+	NT	-	TIA-1+	+	+	Miles et al., 2010

Abbreviations: EBV, Epstein Barr virus; ND, not determined; NT, not tested; TCR, T-cell antigen receptor; TIA-1, T-cell-restricted intracellular antigen-1.

Table 5. Phenotypic characteristics of pediatric patients with extranodal NK leukemia. Case numbers correspond with those in Table 4

US (including one with acquired disease), and one each from Turkey, South America, and France. In adult patients, the International Peripheral T-cell Lymphoma Project reported a four-fold higher relative frequency of ENKL among lymphoma in Asian countries compared to Western countries [Au et al., 2009]. For peripheral T-cell lymphoma, ENKL was the most common histology in Asian countries (range 34%–56%) except for Japan (11%) [Au et al., 2009]. In children and adolescents, the frequency of Asian cases is the same as in adults. Median age is 16 years (range, 0.7–18 years excluding the infant with acquired disease) and the mean age is 13 years. ENKL presents at a higher age than other forms of pediatric leukemia/lymphoma in a similar manner to other NK-lineage leukemias/lymphomas. There were 11 males and 9 females (male to female ratio, 1.22:1) and male predominance has been reported in adults.

Of the 21 pediatric patients, 14 patients had local disease (stage I and II) and seven had disseminated disease (stage III and IV) on the Ann Arbor staging system. The ratio of patients with UAT-ENKL as compared to those with NUAT-ENKL is 7:2 in adults and 2:1 in pediatric patients (Table 4). In pediatric patients, the frequency of NUAT-ENKL patients is higher than in adults [Oshimi et al., 2005]. In pediatric ENKL patients, about half of them presented UAT-ENKL: nine patients had a nasal site and three patients had an extranasal site, including mastoid, tonsil, and skin. UAT patients have been regarded as having no dissemination to other sites [Kim & Heo, 2009]. Cases 18 and 21 are therefore exceptional cases. They had significant hepatomegaly and lymphadenopathy. Their condition deteriorated progressively and lymph node biopsy and bone marrow aspiration presented the invasion of ENKL cells. Case 18 died after 4 days and case 20 died after 30 days from onset [Brodkin et al., 2008]. In adult patients, only 16% of UAT-ENKL patients are reported to have involvement of an extranodal site [Kim et al., 2008].

The proportion of pediatric NUAT-ENKL with a primary tumor outside the UAT is higher than that in adults. In adults, Kim et al. reported three patients with local disease (stage II) and six with disseminated disease (stage IV) [Kim et al., 2008]. Patients with NUAT-ENKL showed higher proportions of advanced-stage disease than adult patients with NUAT-ENKL. In pediatric patients tumor tended to disseminate. The sites involved were lymph node (5 cases), spleen (5 cases), lung (4 cases), bone marrow (2 cases), and skin (2 cases). The predominant site of adult NUAT-ENKL group is skin (37%), liver or spleen (31%), and the GI tract (24%).

Hemophagocytosis (HPS) can be a complication in ENKL (2%–8% of patients) [Kim et al., 2008]. In pediatric patients, four (1 UAT and 3 NUAT) of 20 cases were reported with HPS (Table 4). The frequency of HPS in pediatric patients may be higher than that of adults.

2.4.3 Hypersensitivity to Mosquito Bite syndrome and ENKL

Hypersensitivity to mosquito bite (HMB) syndrome is characterized by an intense skin reaction and systemic symptomatology such as high fever, lymphadenopathy, and hepatosplenomegaly. This condition has been mostly reported in Japanese children. HMB syndrome occurs in association with NK-cell lymphocytosis-related chronic EBV infection. CD4⁺ T cells from patients respond markedly to mosquito salivary gland extracts, and CD4⁺ T cells stimulated by mosquito bites may play a key role in the development of HMB syndrome and NK-cell oncogenesis. It is unclear how stimulated CD4⁺ T cells are involved in viral reactivation of viral oncogene expression in NK cells (Fig. 1) [Asada, 2007]. In the 20 pediatric ENKL cases in this review, two cases may have exhibited HMB syndrome before ENKL; one from China and the other from Turkey.

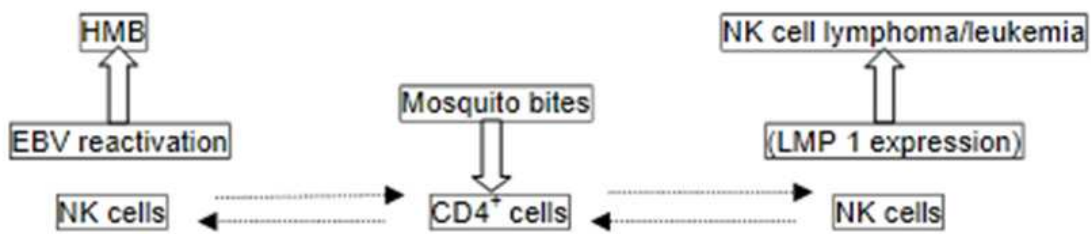


Fig. 1. CD4⁺ T cells stimulated by mosquito bites may play a key role in the development of hypersensitivity to mosquito bites (HMB) and NK-cell oncogenesis via the induction of Epstein-Barr virus (EBV) reactivation and EBV-oncogene latent membrane protein 1 (LMP1) expression, respectively [Asada 2007]

2.4.4 Treatment and outcome

There remains a lack of consensus on the treatment of ENKL and there is no standard therapy in adults or pediatric patients. ENKL shows an aggressive clinical course with various clinicopathologic characteristics. Due to this clinical heterogeneity of ENKL, optimal treatment and prognostic factors have been difficult to determine with the conventional Ann Arbor staging system. NUAT-ENKL has a pathologic similarity to UAT-ENKL but is a clinically distinct subtype.

2.4.4.1 Radiotherapy

For early-stage ENKL, both UAT and NUAT, experience with radiation therapy, chemotherapy, and combined therapy has been reported. The largest study with radiotherapy or radiotherapy plus chemotherapy was reported by Kim et al. [2001]. In this report of 143 patients, 104 received upfront radiotherapy alone with a median dose of 50.4 Gy (range, 20–70 Gy). Of those who received radiotherapy alone, 69% of patients achieved a complete response (CR), while only 8% of those who received chemotherapy prior to radiotherapy achieved CR [Kim et al., 2001; Korht & Advani 2009]. Huang et al. reported CR and 5-year overall survival (OS) rates of 100% in patients who received radiotherapy alone, while those who received chemotherapy (CHOP) alone had rates of 25% and 90%, respectively [Huang et al., 2008]. Li et al. reported overall response in 85 of 87 (97.7%) patients with stage I UAT-ENKL who received radiotherapy with 50–56 Gy (standard is 50 Gy). The 5-year OS, 5-year progression-free survival (PFS), and local control rates for all patients were 80%, 69%, and 93%, respectively [Li et al., 2011b].

The dose and field of radiation in stage I or II ENKL is an important factor with respect to outcome. A radiation dose of at least 54 Gy is seen as being associated with better outcome. Comparing those who received ≥ 54 Gy versus < 54 Gy, 5-year OS and disease-free survival (DFS) rates were higher with the former: 75% vs 46% and 60% vs 46%, respectively [Huang et al., 2008]. Systemic failure is shown in 25% to 30% of patients with stage II and II disease treated with radiotherapy alone. This shows the role of chemotherapy in control of clinically occult disease.

2.4.4.2 Chemotherapy

There are few studies that included patients treated with chemotherapy alone. Studies of chemotherapy regimens including cyclophosphamide, doxorubicin, vincristine, and prednisone (CHOP) are disappointing because of high rates of refractory disease or early relapse: the CR rate with chemotherapy alone was $< 33\%$ and 2-year DFS and OS were 23%

and 44%, respectively [Kim et al., 2003]. This poor prognosis with chemotherapy alone appears related to high P-glycoprotein (P-gp) expression in this NK-cell neoplasm. P-gp is associated drug efflux and treatment resistance.

2.4.4.3 Combined modality therapy

For the control of clinically occult early-stage disease, a combined modality therapy is anticipated to reduce distant failure and overall risk of relapse. In a series of 108 patients with early-stage ENKL receiving radiotherapy followed by chemotherapy consisting with cyclophosphamide, epirubicin, vincristine, prednisolone, and bleomycin [Avilés et al., 2003], combined therapy demonstrated high efficacy with a 92% overall response rate and 8-year OS of 86%. In early-stage ENKL, Guo et al. reported that patients who received CHOP followed by radiotherapy (45 Gy) had a CR rate of only 49% as compared to 100% for those who received radiotherapy prior to CHOP [Guo et al., 2008]. Li et al. reported that patients with early-stage UAT-ENKL (stages I and II) treated with radiotherapy or radiotherapy plus chemotherapy had 5-year OS and PFS rates of 72% and 65%, respectively, overall. The cumulative rates of 5-year systemic failure and OS, respectively, were 24% and 74% for combined modality therapy as compared to 28% and 70% for radiotherapy alone. There was no significant difference between radiotherapy alone and combined modality therapy. A very low incidence of cervical lymph node or CNS relapse was observed. As a result, the addition of chemotherapy did not significantly decrease the systemic failure rate or improve survival [Li et al., 2011a]. In the Japanese JCOG 0211 study [Yamaguchi et al. 2008], 27 patients received radiotherapy (50 Gy) and reduced-dose chemotherapy (carboplatin etoposide, ifosfamide, and dexamethasone). The CR rate was 77% and overall response rate was 81%. Of the ten patients with disease recurrence, nine failed at a distant site. These studies demonstrate that local control using radiotherapy should precede systemic chemotherapy. Prospective studies are needed to clarify the role of chemotherapy.

2.4.4.4 Advanced-stage disease

Combined chemotherapy and radiotherapy is the most commonly used approach for advanced-stage disease. Due to the limited number and size of series, the efficacy of intensive therapy has not been demonstrated. For CHOP or m-BACOD (bleomycin, vincristine, dexamethasone, and methotrexate) followed by radiotherapy, the CR rate in patients with advanced-stage disease was 25% and median OS was 2 months as compared to 75% and 12 months, respectively, in those with early-stage disease [Kwong et al., 1997].

L-asparaginase has been reported as a novel approach for the treatment of advanced-stage ENKL. NK-cell tumors appear highly sensitive to L-asparaginase *in vitro*, as NK cells express low levels of asparaginase synthase. In a series of 15 patients with relapsed or refractory ENKL treated with L-asparaginase monotherapy, seven achieved a CR with an overall response rate of 87% [Jaccard et al., 2009]. Yamaguchi et al. have reported the efficacy of the SMILE regimen consisting with steroids, methotrexate, ifosfamide, L-asparaginase, and etoposide. These agents are independent of the multidrug resistant mechanism (mediated by P-gp) in tumor cells. This phase I study included six patients with advanced-stage disease. The overall response rate after 2 cycles of SMILE therapy was 67%, with 50% achieving CR [Yamaguchi et al., 2008].

2.4.4.5 Stem cell transplantation

Autologous and allogeneic stem cell transplantation (SCT) have been evaluated for consolidation and for relapsed or refractory disease. Suzuki et al. reported 25 CR patients

who received SCT and 4-year OS was 68% [Suzuki et al., 2006]. This demonstrated a significant benefit compared to 188 historical controls who had 4-year OS of 21%. As there have been few reports of SCT, the ability to define its role as therapy for relapsed or refractory disease remains limited. For refractory and relapsed ENKL patients, Yokoyama et al. reported a retrospective analysis of five cases treated with allogeneic SCT [Yokoyama et al., 2010]. All five patients received a myeloablative conditioning regimen (total body irradiation/cyclophosphamide with or without cytarabine) and survived without disease (median follow-up period of 1,911 days). This small case series suggests that allogeneic SCT might improve the outcome of advanced-stage ENKL.

2.4.4.6 Pediatric study

In the pediatric ENKL patients (excluding case 19 whose prognosis was not reported), eight of 12 patients with early-stage (stage I and II) disease including UAT and NUAT were alive (Table 4). Two cases were not described in detail and another two cases died within 1 year. The CR rate is 61%. Case 21 had nasal and right cervical lymphadenopathy and his tumor was not controlled; he died despite CHOP and more intensive chemotherapy. The outcome of pediatric early-stage patients was worse than in adults. The reason is that most cases did not receive radiotherapy and received chemotherapy alone, generally CHOP.

In advanced-stage disease (stage IV), all cases died and average survival was 181 days (6 days to 33 months). Both UAT and NUAT cases show very progressive disease and poor prognosis. Two cases with NUAT received high-dose chemotherapy, had complete remission, and were alive. Case 9 received cord blood SCT after a conditioning regimen consisting of total body irradiation (12 Gy), thiotepea, and cyclophosphamide, while case 10 received autologous SCT after thiotepea and cyclophosphamide.

There have been no large studies in pediatric patients. The largest is a report from China. Wang et al. reported the outcome of 37 pediatric and adolescent UAT-ENKL patients. Among the patients with stage I and II disease, 19 patients received primary radiotherapy with or without chemotherapy, and 14 patients received chemotherapy followed by radiotherapy. The CR rate after initial radiotherapy was 74%, which was significantly higher than the response rate after initial chemotherapy (17%). The median radiation dose for the primary tumor was 50 Gy (range, 15–60 Gy), with dose fractions of 1.8–2 Gy. They reported no late side effects, e.g. secondary malignancy [Wang et al., 2009].

2.5 Blastic plasmacytoid dendritic cell neoplasm and blastic NK-cell lymphoma

Blastic plasmacytoid dendritic cell neoplasm (pDCL) defines leukemia/lymphoma with expression of CD4 and CD56 without any other lineage-specific markers. pDCL is rare and presents a <1% of acute leukemias and 0.7% of cutaneous lymphomas [Garnache-Ottou et al., 2007]. It primarily affects the elderly (median age 69 years) [Feuillard et al., 2002]. The clinical course is very aggressive and rapidly fatal [Reimer et al., 2003]. Histologically, this malignancy is classified as blastic NK-cell lymphoma/leukemia. The 2000 WHO classification considers this malignancy as blastic NK-cell lymphoma [Harris et al., 2000].

The ontogenic origin of this malignancy has not been clearly identified. Chaperot et al. have demonstrated the origin of these tumor cells as dendritic cells [Chaperot et al., 2001]. These malignant cells express interleukin-3 (IL-3) receptor maturation with IL-3 and produce interferon alpha (IFN- α) in response to influenza virus. These cells become a powerful inducer of naïve CD4⁺ T-cell proliferation and promote T-helper 2 polarization. Finally, these authors concluded the origin of this neoplasm is a plasmacytoid dendritic cell subset. Feuillard et al. reported 23 cases with CD4⁺, CD56⁺ leukemia. The majority of patients were

elderly adults, but three children were included in their report. At diagnosis, most patients had cutaneous involvement, with disseminated purple lesions on the dermis. Lymphadenopathy and/or splenomegaly were frequent [Chaperot et al., 2001]. Morphologic and cytochemical analysis revealed a high frequency of vacuolization with pseudopodia-like cytoplasmic expansions. Myeloperoxidase and monocytic esterase activity were never detected.

However, all cases of pDCL do not produce IFN- α and secretion levels of IFN- α have been lower than their normal counterparts. pDCL cells proved incapable of differentiating into NK cells, B cells, myeloid cells, or monocytes, and differentiation into mature pDC was only possible. Furthermore, a subset of pDCL demonstrated the expression of blood dendritic cell antigen 2 (BDCA-2), a specific dendritic cell marker. This fact supports that the origin of pDCL as dendritic cells [Jaye et al., 2006]. However, some other reports remain undetermined concerning the possible origin of pDCL. More investigation is required to establish the definitive nature of these CD4⁺/CD56⁺ tumor cells.

2.5.1 Differential diagnosis

Table 6 shows the differential diagnosis. ENKL is associated with EBV infection, while this has not been reported for pDCL. Although expression of CD56⁺, CD2⁺, CD7⁺, and intraplasmic granzyme B can be in common between ENKL and pDCL, ENKL never expresses CD4⁺ [Harris et al., 1997]. In about 10% to 20% of acute myelogenous leukemia patients, tumor cells express CD33⁺, CD4⁺, and CD56⁺. Very undifferentiated acute myelogenous leukemia weakly shows myelocytic or monoblastic markers. In these cases, identification of pDC-specific markers (e.g. BDCA-2) is useful [Garnache-Outtu et al., 2007]. Mixed myeloblastic/NK-cell leukemia are defined as types of myeloid leukemia in the WHO 2008 classification [Swerdlow et al., 2008]. These leukemias express CD7⁺, CD33⁺, and CD56⁺. They correspond to proliferation of an immature precursor with myeloid and NK potential [Suzuki et al., 1997]. The leukemia phenotype is different from pDCL as they do not express CD4 and CD36 in reported cases [Suzuki et al., 1997]. Furthermore, in pDCL, there is no expression of CD34, while its expression has always shown in mixed myeloblastic/NK-cell leukemia cells.

Marker	pDCL	ENKL	AML	Mixed myeloblastic/NK-cell leukemia
CD2	-	+	-	
CD7	-	+	±	+
CD56	+	+	+	+
CD4	+	-	+	-
Granzyme B	-	+		
CD33	-	-	+	+
CD117	-	-	+	
CD34	-	-	±	+
CD36	+	-	-	-
BDCA-2	+	-	-	-

Abbreviations: AML, acute myelogenous leukemia; BDCA-2, blood dendritic cell antigen 2; ENKL, extranodal NK-cell leukemia; pDCL, blastic plasmacytoid dendritic cell neoplasm.

Table 6. Differential diagnosis of blastic plasmacytoid dendritic cell neoplasms

2.5.2 Pediatric cases

Pediatric pDCL is very rare and limited to a few case reports and small case series. Jegalian et al. reported 25 pediatric cases (20 in the literature, 9 at their institution) with pDCL [Jegalian et al., 2010]. They demonstrated the clinical features and prognosis of pediatric patients. In pediatric patients, 24% of patients lacked cutaneous involvement, which is slightly higher rate than adults. In adult patients, pDCL clinical presentation at the time of diagnosis usually consists of a cutaneous involvement and the patients without cutaneous involvement are very rare. In adult patients, especially the elderly, prognosis is very poor. Median OS was only 13 months for all patients. Allogeneic SCT is a useful treatment in younger adult patients. They reported a regimen suited to acute lymphoblastic leukemia followed by SCT is more effective than using an acute myelogenous leukemia or non-Hodgkin lymphoma regimen. While the OS of pediatric patients receiving SCT was 67% (4 of 6 patients), that for patients without SCT was 74%. In pediatric patients, treatment with a high-risk regimen appears effective without SCT. SCT was useful for only relapsed or secondary remission disease. Outcome of pediatric patients was more favorable than that of adults [Jegalian et al., 2010].

3. Conclusion

NK-cell malignancy is difficult to define and there is confusion in diagnosis. One of the reasons for the confusion is that CD56 is not only expressed in NK-cell malignancy but in various other hematopoietic malignancies, e.g. acute myelogenous leukemia non-Hodgkin lymphoma, pDCL. It is hoped that more specific markers for NK-cell malignancy will assist in defining these malignancies. NK-cell precursor tumors with lymphomatous presentation that expressed NK-specific CD94A1 transcripts have been described [Lin et al., 2005]. I used this method and clarified the origin of one case [Hashii et al., 2010]. Antibodies against killer immunoglobulin-like receptors (KIRs) will hopefully provide a useful tool for clarification of the diagnosis of the NK-cell malignancies. Currently, these antibodies are not commonly used. Although, BDCA-2 is useful for clarifying the difference between NK-cell malignancy and pDCL, it is not commonly used. The diagnosis of precursor NK-cell lymphoblastic leukemia/lymphoma may be considered in cases that express CD56⁺ along with immature T-cell markers (CD2⁺, CD7⁺, and CD3e⁺) without B-cell or myeloid markers.

4. References

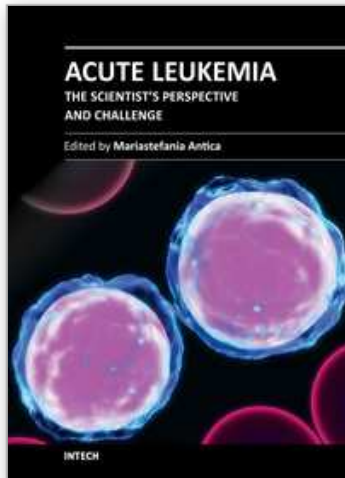
- Asada, H. (2007). Hypersensitivity to mosquito bites: a unique pathogenic mechanism linking Epstein-Barr virus infection, allergy and oncogenesis, *Journal of Dermatological Science* 45(3): 153–160.
- Au, W.Y., Ma, S.Y., Chim, C.S., et al. (2005). Clinicopathologic features and treatment outcome of mature T-cell and natural killer-cell lymphomas diagnosed according to the World Health Organization classification scheme: a single center experience of 10 years, *Annals of Oncology* 16(2): 206–214.
- Au, W.Y. & Weisenburger, D.D., Intragumtornchai, T., et al. (2009). Clinical differences between nasal and extranasal natural killer/T-cell lymphoma: a study of 136 cases from the International Peripheral T-Cell Lymphoma Project, *Blood* 113(17): 3931–3937.

- Avilés, A., Neri, N., Fernández, R., et al. (2003). Nasal NK/T-cell lymphoma with disseminated disease treated with aggressive combined therapy, *Medical Oncology* 20(1): 13–17.
- Aydin, G.B., Akyuz, C., Talim, B., et al. (2007). Extranodal type T/NK-cell lymphoma with an atypical clinical presentation, *Pediatric Hematology-Oncology* 24(4): 291–299.
- Brodkin, D.E., Hobohm, D.W., Nigam, R. (2008). Nasal-type NK/T-cell lymphoma presenting as hemophagocytic syndrome in an 11-year-old Mexican boy, *Journal of Pediatric Hematology and Oncology* 30(12): 938–940.
- Catlin, E.A., Roberts, J.D. Jr., Erana, R., et al. (1999). Transplacental transmission of natural-killer-cell lymphoma, *New England Journal of Medicine* 341(2): 85–91.
- Chang, B.H., Stork, L. & Fan, G. (2008). A unique case of adolescent CD56-negative extranodal NK/T-cell lymphoma, nasal type, *Pediatric and Developmental Pathology* 11(1): 50–54.
- Chaperot, L., Bendriss, N., Manches, O., et al. (2001). Identification of a leukemic counterpart of the plasmacytoid dendritic cells, *Blood* 97(10): 3210–3217.
- Feuillard, J., Jacob, M.C., Valensi, F., et al. (2002). Clinical and biologic features of CD4(+)CD56(+) malignancies, *Blood* 99(5): 1556–1563.
- Furuno, T., Hara, N., Hagimoto, N., et al. (1994). Multiple pulmonary nodules manifested in a patient with NK cell granular lymphocyte proliferative disorder, *Chest* 105(6): 1893–1895.
- Garnache-Ottou, F., Feuillard, J. & Saas, P. (2007). Plasmacytoid dendritic cell leukaemia/lymphoma: towards a well defined entity? *British Journal of Haematology* 136(4): 539–548.
- Guo, Y., Lu, J.J., Ma, X., et al. (2008). Combined chemoradiation for the management of nasal natural killer (NK)/T-cell lymphoma: elucidating the significance of systemic chemotherapy, *Oral Oncology* 44(1):23–30.
- Harris, N.L., Jaffe, E.S., Diebold, J., et al. (2000). The World Health Organization classification of neoplasms of the hematopoietic and lymphoid tissues: report of the Clinical Advisory Committee meeting–Airlie House, Virginia, November, 1997, *The Hematology Journal* 1(1): 53–66.
- Hashii, Y., Okuda, T., Ohta, H., et al. (2010). Pediatric myeloid/NK cell precursor lymphoma/leukemia expressing T/NK immunophenotype markers, *International Journal of Hematology* 91(3): 525–529.
- Huang, M.J., Jiang, Y., Liu, W.P., et al. (2008). Early or up-front radiotherapy improved survival of localized extranodal NK/T-cell lymphoma, nasal-type in the upper aerodigestive tract, *International Journal of Radiation Oncology Biology Physics* 70(1): 166–174.
- Hutchison, R.E., Laver, J.H., Chang, M., et al. (2008). Non-anaplastic peripheral t-cell lymphoma in childhood and adolescence: a Children's Oncology Group study, *Pediatric Blood Cancer* 51(1): 29–33.
- Ichikawa, S., Fukuhara, N., Yamamoto, J., et al. (2010). Successful allogeneic hematopoietic stem cell transplantation for aggressive NK cell leukemia, *Internal Medicine* 49(17): 1907–1910.
- Imamura, N., Kusunoki, Y., Kawa-Ha, K., et al. (1990). Aggressive natural killer cell leukaemia/lymphoma: report of four cases and review of the literature. Possible

- existence of a new clinical entity originating from the third lineage of lymphoid cells, *British Journal of Haematology* 75(1): 49–59.
- Ishida, F. & Kwong, Y.L. (2010). Diagnosis and management of natural killer-cell malignancies, *Expert Review of Hematology* 3(5): 593–602.
- Ito, T., Makishima H., Nakazawa, H., et al. (2008). Promising approach for aggressive NK cell leukaemia with allogeneic haematopoietic cell transplantation, *European Journal of Haematology* 81(2): 107–111.
- Jaccard, A., Petit, B., Girault, S., et al. (2009). L-asparaginase-based treatment of 15 western patients with extranodal NK/T-cell lymphoma and leukemia and a review of the literature, *Annals of Oncology* 20(1): 110–116.
- Jaye, D.L., Geigerman, C.M., Herling, M., et al. (2006). Expression of the plasmacytoid dendritic cell marker BDCA-2 supports a spectrum of maturation among CD4+ CD56+ hematodermic neoplasms, *Modern Pathology* 19(12): 1555–1562.
- Jegalian, A.G., Buxbaum, N.P., Facchetti, F., et al. (2010). Blastic plasmacytoid dendritic cell neoplasm in children: diagnostic features and clinical implications, *Haematologica* 95(11): 1873–1879.
- Kaizu, K., Maeda, M., Ohkawa, T., et al. (2004). Marked elevation of soluble fas ligand and cytokine secretion after splenectomy in aggressive natural killer cell leukemia/lymphoma, *Leukemia and Lymphoma* 45(11): 2291–2294.
- Kato K., Ohshima K., Ishihara S., et al. (1998). Elevated serum soluble Fas ligand in natural killer cell proliferative disorders, *British Journal of Haematology* 103(4):1164–1166.
- Kawa-Ha, K., Ishihara, S., Ninomiya, T., et al. (1989). CD3-negative lymphoproliferative disease of granular lymphocytes containing Epstein-Barr viral DNA, *Journal of Clinical Investigation* 84(1): 51–55.
- Kim, B.S., Kim, T.Y., Kim, C.W., et al. (2003). Therapeutic outcome of extranodal NK/T-cell lymphoma initially treated with chemotherapy—result of chemotherapy in NK/T-cell lymphoma, *Acta Oncologica* 42(7): 779–783.
- Kim, G.E., Lee, S.W., Chang, S.K., et al. (2001). Combined chemotherapy and radiation versus radiation alone in the management of localized angiocentric lymphoma of the head and neck, *Radiotherapy and Oncology* 61(3): 261–269.
- Kim, T.M. & Heo, D.S. (2009). Extranodal NK/T-cell lymphoma, nasal type: new staging system and treatment strategies, *Cancer Science* 100(12): 2242–2248.
- Kim, T.M., Lee, S.Y., Jeon, Y.K., et al. (2008). Clinical heterogeneity of extranodal NK/T-cell lymphoma, nasal type: a national survey of the Korean Cancer Study Group, *Annals of Oncology* 19(8): 1477–1484.
- Ko, Y.H., Cho, E.Y., Kim, J.E., et al. (2004). NK and NK-like T-cell lymphoma in extranasal sites: a comparative clinicopathological study according to site and EBV status, *Histopathology* 44(5): 480–489.
- Kohrt, H. & Advani, R. (2009). Extranodal natural killer/T-cell lymphoma: current concepts in biology and treatment, *Leukemia and Lymphoma* 50(11): 1773–1784.
- Koizumi, S., Seki, H., Tachinami, T., et al. (1986). Malignant clonal expansion of large granular lymphocytes with a Leu-11+, Leu-7- surface phenotype: in vitro responsiveness of malignant cells to recombinant human interleukin 2, *Blood* 68(5): 1065–1073.
- Kwong, Y.L., Chan, A.C., Liang, R., et al. (1997). CD56+ NK lymphomas: clinicopathological features and prognosis, *British Journal of Haematology* 97(4): 821–829.

- Kwong, Y.L., Wong, K.F., Chan, L.C., et al. (1995). Large granular lymphocyte leukemia. A study of nine cases in a Chinese population, *American Journal of Clinical Pathology* 103(1): 76–81.
- Lee, J.Y., Jang, Y.D. & Kim, H.K. (2008). The primary role of the otolaryngologist in managing pediatric sinonasal malignancies: an extranodal NK/T-cell lymphoma originating from the inferior turbinate mucosa of the nasal cavity, *Journal of Pediatric Hematology and Oncology* 30(5): 401–404.
- Lei, K.I., Chow, J.H. & Johnson P.J. (1997). Aggressive primary natural killer cell lymphoma of the caecum: a case report and literature review, *Clinical Oncology (Royal College of Radiology)* 9(3): 191–194.
- Li, Y.X., Liu, Q.F., Wang, W.H., et al. (2011a). Failure patterns and clinical implications in early stage nasal natural killer/T-cell lymphoma treated with primary radiotherapy, *Cancer* doi: 10.1002/cncr.26167 [Epub ahead of print].
- Li, Y.X., Wang, H., Jin, J., et al. (2011b). Radiotherapy Alone With Curative Intent in Patients With Stage I Extranodal Nasal-type NK/T-cell Lymphoma, *International Journal of Radiation Oncology Biology Physics* [Epub ahead of print].
- Lin, C.W., Liu, T.Y., Chen, S.U., et al. (2005). CD94 1A transcripts characterize lymphoblastic lymphoma/leukemia of immature natural killer cell origin with distinct clinical features, *Blood* 106: 3567–3574.
- Miles, R.R., Afify Z., Yaish, H., et al. (2010). CD56-negative extranodal nasal type NK/T-cell lymphoma, *Pediatric Blood Cancer* 55: 186–189.
- Nava, V.E. & Jaffe, E.S. (2005). The pathology of NK-cell lymphomas and leukemias, *Advances in Anatomic Pathology* 12: 27–34.
- Ohno, Y., Amakawa, R., Fukuhara, S., et al. (1989). Acute transformation of chronic large granular lymphocyte leukemia associated with additional chromosome abnormality, *Cancer* 64: 63–67.
- Ohnuma, K., Toyoda, Y., Nishihira, H., et al. (1997). Aggressive natural killer (NK) cell lymphoma: report of a pediatric case and review of the literature, *Leukemia and Lymphoma* 25: 387–392.
- Oshimi, K., Kawa, K., Nakamura, S., et al. (2005). NK-cell neoplasms in Japan, *Hematology* 10(3): 237–245.
- Oshimi, K. (1996). Lymphoproliferative disorders of natural killer cells, *International Journal of Hematology* 63(4): 279–290.
- Patel, A.P., Ghatak, S.B. & Patel, J.A. (2010). Long term survival in aggressive NK cell leukemia. *Indian Pediatrics* 47(9): 807–808.
- Lymphoma Study Group of Japanese Pathologists. (2000). The World Health Organization classification of malignant lymphomas in Japan: incidence of recently recognized entities, *Pathology International* 50(9): 696–702.
- Pellier, I., N'Golet, L., Rachieru, P., et al. (2009). Disseminated nasal-type natural killer/T-cell lymphoma in a child: a case report, *Journal of Pediatric Hematology and Oncology* 31(5): 362–366.
- Petterson, T.E., Bosco, A.A. & Cohn, R.J. (2008). Aggressive natural killer cell leukemia presenting with hemophagocytic lymphohistiocytosis, *Pediatric Blood Cancer* 50(3): 654–657.

- Pol-Rodriguez, M.M., Fox, L.P., Sulis, M.L., et al. (2006). Extranodal nasal-type natural killer T-cell lymphoma in an adolescent from Bangladesh, *Journal of the American Academy of Dermatology* 54(5 Suppl): S192-S197.
- Reimer, P., Rüdiger, T., Kraemer, D., et al. (2003). What is CD4+CD56+ malignancy and how should it be treated? *Bone Marrow Transplantation* 32(7): 637-646.
- Shaw, P.H., Cohn, S.L., Morgan, E.R., et al. (2001). Natural killer cell lymphoma: report of two pediatric cases, therapeutic options, and review of the literature, *Cancer* 91(4): 642-646.
- Suzuki, K., Ohshima, K., Karube, K., et al. (2004a). Clinicopathological states of Epstein-Barr virus-associated T/NK-cell lymphoproliferative disorders (severe chronic active EBV infection) of children and young adults, *International Journal of Oncology* 24(5): 1165-1174.
- Suzuki, R., Suzumiya, J., Nakamura, S., et al. (2004b). Aggressive natural killer-cell leukemia revisited: large granular lymphocyte leukemia of cytotoxic NK cells, *Leukemia* 18(4): 763-770.
- Suzuki, R., Suzumiya, J., Nakamura, S., et al. (2006). Hematopoietic stem cell transplantation for natural killer-cell lineage neoplasms, *Bone Marrow Transplant* 37(4): 425-431.
- Suzuki, R., Suzumiya, J., Yamaguchi, M., et al. (2010). Prognostic factors for mature natural killer (NK) cell neoplasms: aggressive NK cell leukemia and extranodal NK cell lymphoma, nasal type, *Annals of Oncology* 21(5): 1032-1040.
- Suzuki, R., Yamamoto, K., Seto, M., et al. (1997). CD7+ and CD56+ myeloid/natural killer cell precursor acute leukemia: a distinct hematolymphoid disease entity, *Blood* 90(6): 2417-2428.
- Suzuki, R. (2010). Treatment of advanced extranodal NK/T cell lymphoma, nasal-type and aggressive NK-cell leukemia, *International Journal of Hematology* 92(5): 697-701.
- Swerdlow, S.H., Campo, E. & Harris, N.L. (2008). WHO Classification of Tumours of Haematopoietic and Lymphoid Tissues. IARC, Lyon.
- Wang, Z.Y., Li, Y.X., Wang, W.H., et al. (2009). Primary radiotherapy showed favorable outcome in treating extranodal nasal-type NK/T-cell lymphoma in children and adolescents, *Blood* 114(23): 4771-4776.
- Yamaguchi, M., Suzuki, R., Kwong, Y.L., et al. (2008). Phase I study of dexamethasone, methotrexate, ifosfamide, L-asparaginase, and etoposide (SMILE) chemotherapy for advanced-stage, relapsed or refractory extranodal natural killer (NK)/T-cell lymphoma and leukemia, *Cancer Science* 99(5): 1016-1020.
- Yokoyama, H., Yamamoto, J., Tohmiya, Y., et al. (2010). Allogeneic hematopoietic stem cell transplant following chemotherapy containing l-asparaginase as a promising treatment for patients with relapsed or refractory extranodal natural killer/T cell lymphoma, nasal type, *Leukemia and Lymphoma* 51(8): 1509-1512.
- Yoo, E.H., Kim, H.J., Lee, S.T., et al. (2009). Frequent CD7 antigen loss in aggressive natural killer-cell leukemia: a useful diagnostic marker, *The Korean Journal of Laboratory Medicine* 29(6): 491-496.
- Zhang, Z., Shi, Q., An, X., et al. (2009). NK/T-cell lymphoma in a child with hypersensitivity to mosquito bites, *Journal of Pediatric Hematology/Oncology* 31(11): 855-857.



Acute Leukemia - The Scientist's Perspective and Challenge

Edited by Prof. Mariastefania Antica

ISBN 978-953-307-553-2

Hard cover, 428 pages

Publisher InTech

Published online 22, December, 2011

Published in print edition December, 2011

This book provides a comprehensive overview of the basic mechanisms underlying areas of acute leukemia, current advances, and future directions in management of this disease. The first section discusses the classification of acute leukemia, taking into account diagnoses dependent on techniques that are essential, and thankfully readily available, in the laboratory. The second section concerns recent advances in molecular biology, markers, receptors, and signaling molecules responsible for disease progression, diagnostics based on biochips and other molecular genetic analysis. These advances provide clinicians with important understanding and improved decision making towards the most suitable therapy for acute leukemia. Biochemical, structural, and genetic studies may bring a new era of epigenetic based drugs along with additional molecular targets that will form the basis for novel treatment strategies. Later in the book, pediatric acute leukemia is covered, emphasizing that children are not small adults when it comes to drug development. The last section is a collection of chapters about treatment, as chemotherapy-induced toxicity is still a significant clinical concern. The present challenge lies in reducing the frequency and seriousness of adverse effects while maintaining efficacy and avoiding over-treatment of patients.

How to reference

In order to correctly reference this scholarly work, feel free to copy and paste the following:

Yoshiko Hashii (2011). Pediatric Natural Killer Cell Malignancy, *Acute Leukemia - The Scientist's Perspective and Challenge*, Prof. Mariastefania Antica (Ed.), ISBN: 978-953-307-553-2, InTech, Available from: <http://www.intechopen.com/books/acute-leukemia-the-scientist-s-perspective-and-challenge/pediatric-natural-killer-cell-malignancy>

INTECH
open science | open minds

InTech Europe

University Campus STeP Ri
Slavka Krautzeka 83/A
51000 Rijeka, Croatia
Phone: +385 (51) 770 447
Fax: +385 (51) 686 166
www.intechopen.com

InTech China

Unit 405, Office Block, Hotel Equatorial Shanghai
No.65, Yan An Road (West), Shanghai, 200040, China
中国上海市延安西路65号上海国际贵都大饭店办公楼405单元
Phone: +86-21-62489820
Fax: +86-21-62489821

© 2011 The Author(s). Licensee IntechOpen. This is an open access article distributed under the terms of the [Creative Commons Attribution 3.0 License](#), which permits unrestricted use, distribution, and reproduction in any medium, provided the original work is properly cited.

IntechOpen

IntechOpen