

We are IntechOpen, the world's leading publisher of Open Access books Built by scientists, for scientists

4,800

Open access books available

122,000

International authors and editors

135M

Downloads

Our authors are among the

154

Countries delivered to

TOP 1%

most cited scientists

12.2%

Contributors from top 500 universities



WEB OF SCIENCE™

Selection of our books indexed in the Book Citation Index
in Web of Science™ Core Collection (BKCI)

Interested in publishing with us?
Contact book.department@intechopen.com

Numbers displayed above are based on latest data collected.

For more information visit www.intechopen.com



Contemporary Anterior Cruciate Ligament Reconstruction

P. Christel¹ and W. Boueri²

¹Habib Medical Center, Riyadh

²Bellevue University Medical Center, Mansourieh - El metn

¹Saudi Arabia

²Lebanon

1. Introduction

The modern era of anterior cruciate ligament (ACL) reconstruction started in the early 1990's with the development of arthroscopic knee reconstruction procedures. Early on, graft fixation issues and, graft choice have been extensively debated. Then, the transtibial technique appeared (Rosenberg & Deffner, 1997; Chen et al., 2003). This was an easy and quick way to reconstruct the ACL which became soon adopted by most surgeons. However, the outcome was not always as good as expected (Freedman et al., 2003, Lewis et al., 2008) and with the re-discovery of the ACL anatomy and biomechanics, deep changes have been introduced in the way to reconstruct the ACL. This chapter reviews the main features related to ACL reconstruction and focus on the current state of the art in this field

2. ACL anatomy

The reader will find all the necessary details in the numerous articles which have been recently published in this field (Colombet et al., 2006; Edwards et al., 2006; Giron et al. 2006; Harner et al., 1999; Mochizuki et al., 2007; Petersen & Zantop, 2007; Purnell et al., 2008; Takahashi et al., 2006; Zantop et al., 2006). We will summarize the main relevant points for surgical reconstruction of the ACL.

The ACL consists of at least two functional bundles, anteromedial (AMB) and posterolateral (PLB). The AMB is about twice long and big as compared to the PLB. The AM bundle is more sagittally oriented, limiting the anterior tibial translation while the more oblique PLB (Fig 1), limits the internal rotation of the tibia (Zantop et al., 2007).

Both bundles are parallel in full knee extension and, due to the location of their attachments, they cross each other when the knee bends. During knee flexion, the PLB shortens by more than 30%, while the AMB elongates by 15%. The PLB is tight when the knee is close to extension whereas the AMB is tensed when the knee bends. The range of length variation for the AMB varies between 1-3mm while the PLB exhibits a much wider range, 4-7mm. In order to reproduce the ACL anatomy several studies have assessed and quantify the footprints.

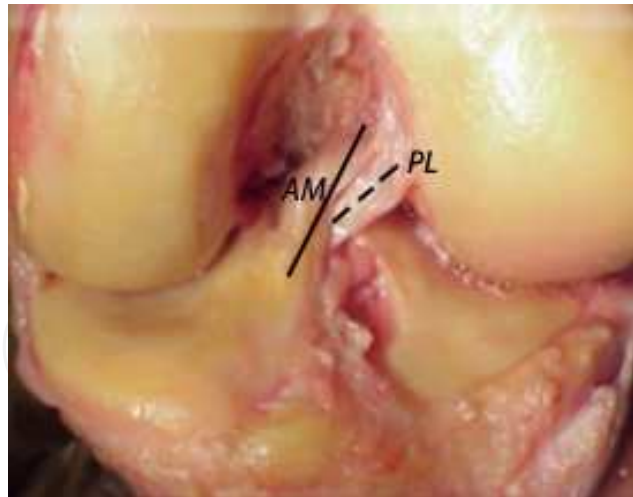

Fig. 1. ACL bundles. Solid line: anteromedial bundle (AM), dotted line; posterolateral bundle (PL)

2.1 ACL femoral foot print

In Western subjects, the length of the foot print is $18.3\text{mm} \pm 2.3\text{mm}$, the width $10.3\text{mm} \pm 2.7\text{mm}$ (Colombet et al., 2006). The distance between the bundle centers is $8.2\text{mm} \pm 1.2\text{mm}$. In anatomic position, the most anterior fibers of the foot print are located behind the lateral intercondylar ridge (Fu & Jordan, 2007). There are no ACL fibers located in front of the lateral intercondylar ridge (Fig. 2). The most posterior fibers are located at 2-3mm from the lateral femoral condyle articular cartilage limit, following its curvature. The bifurcate ridge, perpendicular to the lateral intercondylar ridge separates the AMB from the PLB attachment.

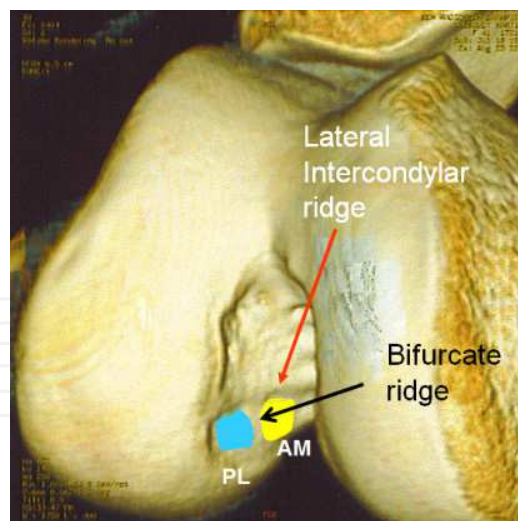


Fig. 2. Three-dimensional CT view of the intercondylar notch in “endoscopic” position (femoral shaft horizontal). The ACL bundle attachment sites are shown in relation with the lateral intercondylar- and the bifurcate ridges.

On a lateral X-ray it is possible to locate the lateral intercondylar ridge (Farrow et al, 2008). When the femur is in the endoscopic position, i.e. horizontal, the ridge originates at the posterior part of the Blumensaat’s line (80% from anterior) and the mean Blumensaat’s-ridge angle is 75.5° . In this position, the whole ACL femoral footprint becomes posterior to the

ridge. The center of the femoral bundles can be also located using the quadrants method described by Bernard et al (Bernard et al, 1997). The position of the centers is illustrated on Fig. 3.

2.2 Tibial footprint

It is larger than on the femoral side with a $17.6\text{mm} \pm 2.1\text{mm}$ length and $12.7\text{mm} \pm 2.8\text{mm}$ width. The distance between the bundle centers is $8.4\text{mm} \pm 0.4\text{mm}$ (Colombet et al., 2006). The most anterior point of the tibial footprint is located right behind the posterior edge of the anterior inter-meniscal ligament. The most posterior fibers of the footprint are located at $10.3\text{mm} \pm 1.9\text{mm}$ in front of the retro eminence ridge which corresponds to the ridge limiting the anterior attachment of the posterior cruciate ligament on the tibia. The center of the ACL tibial footprint is thus located 20-22mm in front of the PCL attachment. The distribution and the surface area of the bundle attachments is variable (Colombet et al., 2006; Edwards et al., 2007) and there is no visible ridge separating the bundles as on the femoral side.

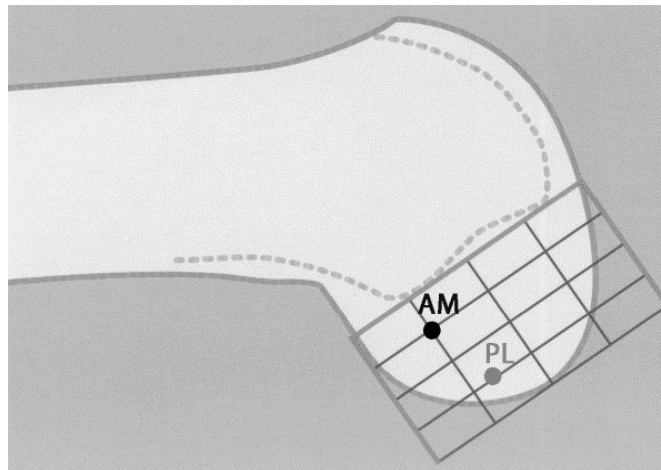


Fig. 3. Location of the femoral bundle centers according to the quadrant's method of Bernard.

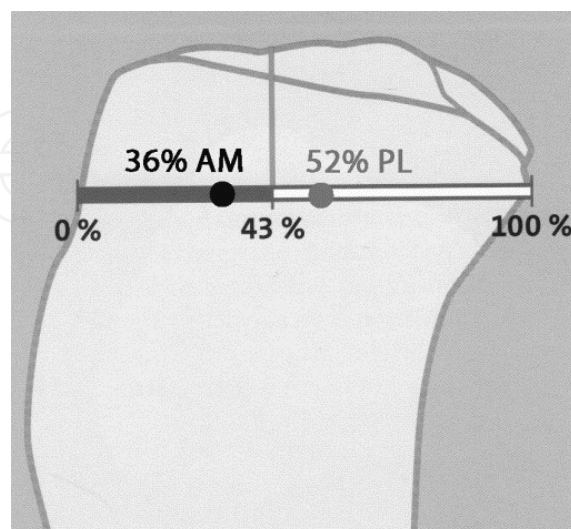


Fig. 4. Position of the tibial bundle centers projected on the Staubli & Rauschnig line. The center of the ACL is located at 43% of the AP diameter

On lateral X rays it is possible to locate the various centers of the tibial ACL foot print. Using the Stäubli and Rauschning technique (Fig. 4), the footprint center is located at 43 % of the antero-posterior diameter of the tibia (Stäubli & Rauschning, 1994) while the center of the AMB is located at 36% and the center of the PLB at 52% (Colombet et al., 2006).

3. Graft selection

3.1 Autografts

Contrary to a common belief, the bone-patellar-tendon-bone (BPTB) remains the most frequently used autograft (Shelton and Fagan, 2011), but hamstring and quadriceps tendon grafts are common alternative.

Graft type	Anterior knee pain	Anterior knee Numbness	Failure rate	Knee Tightness	Residual Weakness	Extension deficit	Patient Satisfaction
BPTB	High	High	Low	High	Quadriceps muscle	High	High
Hamstring	Low	Low	Slightly Higher	Slightly lower	Hamstrings	Low	High
Quadriceps	Low	Low	Low	High	Quadriceps muscle	Low	High

Table 1. This table summarizes the factors to be considered in ACL autograft selection (from Shelton and Fagan, 2011).

All three graft types exhibit strength values above 2,000 N.

3.1.1 BPTB autograft, which has two bone plugs at each of its extremities, affords the most secure fixation, a low failure rate and high rate of patient satisfaction. This is the graft of choice among team physicians dealing with high level professional athletes (Pandarinath et al., 2011). However, it is associated with increased anterior knee pain and numbness with a greater incidence of extension loss and long term osteoarthritis of the knee. Residual anterior knee pain can be decreased by filling the bony defects of the harvesting sites, and numbness can be prevented by saving the infrapatellar branch of the saphenous nerve during harvesting.

3.1.2 Hamstring grafts are associated with less harvesting morbidity than BPTB, however, they exhibit a slighter degree of laxity, especially in females. Their harvesting weakens flexion strength of the knee and may account in the reported incidence of graft failure. They are usually fashioned in a quadrupled stranded graft using both gracilis and semitendinosus tendons.

3.1.3 Quadriceps tendon has a low incidence of anterior knee pain and almost no residual numbness. It can be fashioned with or without bone plug. After harvesting, quadriceps deficit is temporary. Clinical outcome is excellent with residual laxity similar to BTB both in males and females, without extension deficit. For many, this is the graft of choice for ACL revision or posterior cruciate ligament reconstruction.

Most studies which have reported results of ACL reconstruction show no significant difference in residual anterior laxity, functional results and International Knee Documentation Committee (IKDC) scores regardless the autograft which is used (Aune et al., 2001; Beynon et al., 2002; Freedman et al., 2003; Maletis et al., 2007; Yunes et al., 2001)

3.2 Allografts

Allografts avoid harvesting tendons with their drawbacks, i.e anterior knee pain or numbness. In countries where legal issues are important, especially the United States (USA), allografts became the graft of choice for ACL reconstruction.

3.2.1 Currently, three kinds of allografts are available: chemically treated, irradiated and/or fresh frozen. Due to their poor mechanical properties, chemically treated or irradiated allografts are gradually abandoned (Krych et al., 2008). Currently, fresh frozen allografts are the most widely used. Tissue banks insure the proper donor selection as well as bacterial and viral screening. With the current infection control protocols, the incidence of viral or bacterial contamination is null. Graft quality is an issue and donor age must be known. Thus the choice of the tissue bank is critical.

3.2.2 Fresh frozen tibialis anterior or posterior tendons, Achilles' tendon with bone plug and BPTB are the most widely used. The outcome is similar to autografts (Foster et al., 2010) however, allografts have significantly lower normal stability rates than autografts (Bach et al., 2005; Prodromos et al., 2007).

Most of the US authors do not recommend the use of allografts in young and high demanding athletes. Also the use of allografts add a significant cost to the procedure (c.a. \$ 3,000 in the USA). Thus, for the authors, the use of allografts which lead to inferior results compared to autografts at an increased cost remains questionable

4. Graft fixation issues

4.1 Composite grafts with bone plugs are commonly fixed in the tunnels either with absorbable or metal interference screws.. This method provides the highest strength and rigidity. However there is concern that a too rigid construct may alter the full range of knee motion and some surgeons prefer suspensory fixation with sutures tied on post or buttons or buttons with build in tissue loops. Soft tissue grafts fixation relies on numerous different methods: interference screws, suspensory devices, cross pins. On the femoral side suspensory devices with build in tissue loop, like the Endobutton® Continuous Loop provides the strongest and stiffest fixation. With hamstring grafts, graft slippage at the tibial fixation site may occur explaining the slight increase in laxity compared to BTB.

4.2 Tunnel enlargement

Following ACL reconstruction, tunnel enlargement occurs regardless the graft choice and the fixation system (L'Insalata et al., 1997). This is an early phenomenon which occurs during the first-three post operative months. Biomechanical (bungee cord and wiper windshield effects) as well as biological factors (local cytokine release) may account for this enlargement (Wilson et al., 2004). Until now, one important factor might have been underestimated: the graft positioning. With anatomic placement of the ACL grafts tunnel enlargement is less (Chhabra et al., 2006).

5. The evolution of ACL reconstruction

Before the early 1990's most of the ACL reconstruction were performed through medial arthrotomy which became with time mini arthrotomy. However, arthroscopic reconstruction (Paulos et al., 1991) undergone rapid development. Although achievement of stability has been well-documented in open ACL reconstructive procedures, it quickly appeared arthroscopically assisted ACL reconstruction offered significantly diminished morbidity, and more predictable rehabilitation after surgery. Improvements in instrumentation allowed refining the precision of the technique.

5.1 The transtibial technique

Rosenberg is the surgeon who introduced the transtibial technique for ACL reconstruction (Rosenberg & Deffner, 1997; Rosenberg & Brown, 1997; Chen et al., 2003). We will briefly summarize the technique. In a first step, regardless the nature of the graft, a specific tibial drill guide is used to insert a 2.4mm guide wire in the foot of the ACL tibial footprint. In the sagittal plane, a 55° angle orientation with regard to the plane of the tibial plateau is recommended (Fig. 5A). In the coronal plane the guide wire is inserted 1.5cm medial to the tibial tubercle (Fig. 5B), above the pes anserinus tendons, and oriented at 25° with regard to the tibial axis (75° with regard to the tibial plateau surface). The guide wire is then used to guide a cannulated drill bit which diameter corresponds to the graft diameter (Fig.5C).

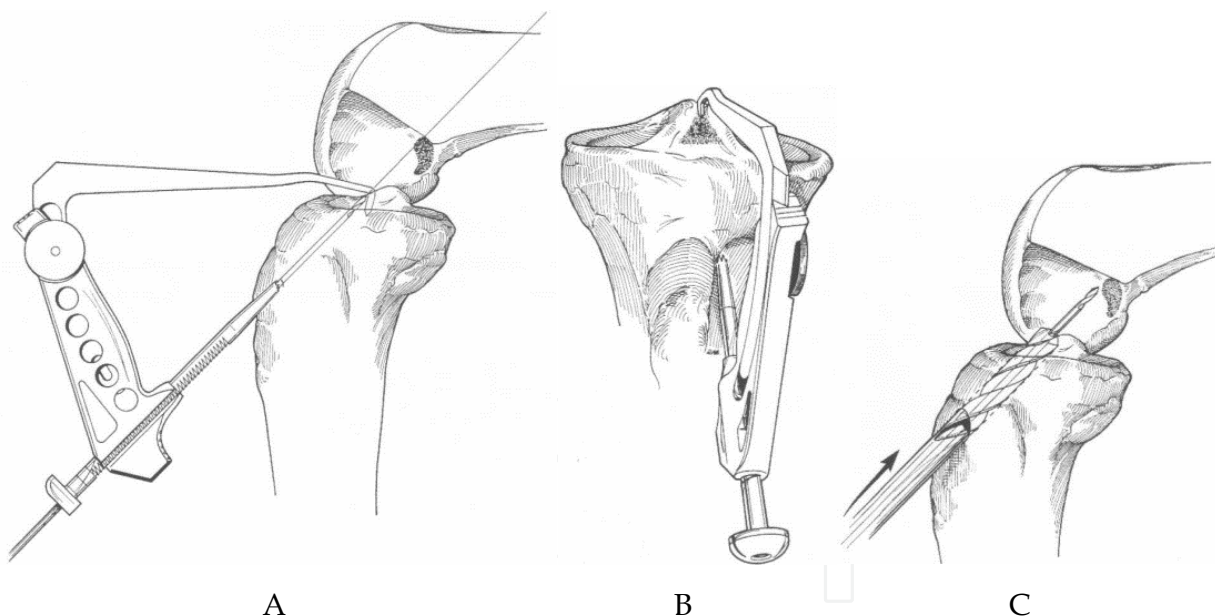


Fig. 5. Transtibial technique, tibial steps. A: insertion of the tibial guide wire at 55 degree inclination with regard to the tibial plateau plane. B: the starting point of the guide wire is just medial to the tibial tubercle. C: a cannulated drill, which size corresponds to the graft diameter is passed on the guide wire. The knee is maintained at 90 degree of flexion.

In a second step, with the knee bent at 90° of flexion, a femoral guide is introduced through the tibial tunnel inside the intercondylar notch region. The femoral guide has a hook at its intra articular tip which offset (3-9mm) is chosen according to the size of the knee and where the surgeon decides to drill the femoral tunnel in relation with the ACL femoral footprint

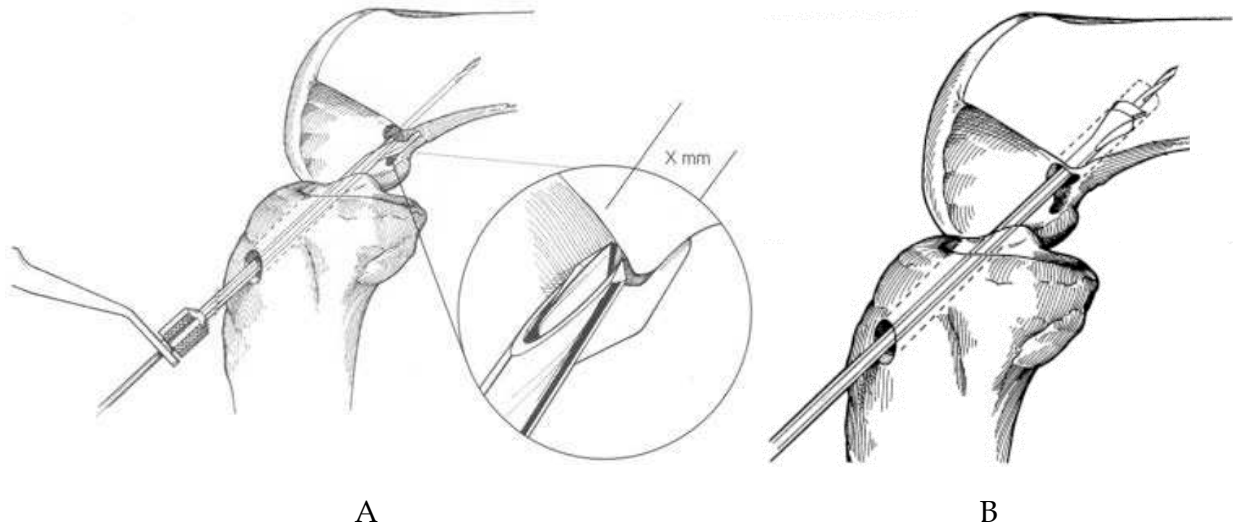


Fig. 6. Transtibial technique, femoral steps. A: An endofemoral guide wire is introduced through the tibial tunnel. The knee remains bent at 90 degree. The hook located at the proximal tip has variable offset with regard to the shaft of the aimer (X mm). An eyelet needle is drilled through the lateral femoral condyle. This drawing perfectly illustrates the fact one can't reach the center of the ACL femoral footprint with the transtibial technique. B: An endoscopic cannulated drill is passed on the on the guide wire drilling a femoral socket at the desired depth. During drilling, the tibial tunnel is widened by the drill.

(Fig. 6). A long guide wire with an eyelet is inserted with the help of the femoral guide, through the lateral femoral condyle, breaching the lateral cortex until it passes through the skin of the lateral side of the thigh. The femoral guide is removed keeping the guide wire in the condyle. Then, maintaining the knee at 90° of flexion, a cannulated endoscopic drill, which head is the cutting part and the shaft smaller, is threaded on the guide wire through the tibial tunnel, the intercondylar notch, the lateral femoral condyle at a depth which depends on graft type and fixation type. The diameter of the endoscopic drill is chosen according to the graft diameter. The eyelet of the guide wire is used to pull a loop suture through the tibial tunnel, the intercondylar notch and the tibial tunnel exiting on the lateral side of the thigh. The loop stitch is use do pull the graft until it settles in the femoral tunnel and fixed appropriately either with an interference screw, an Endobutton or with cross pins. Then the graft is put under Manual tension; the knee is cycled from full extension to full flexion at least 20 times. The length variation of the graft at the exit of the tibial tunnel is measured and the graft fixed in the tibia either with an interference screw or using extra cortical fixation: button or screw post and washer. The knee flexion at fixation depends on the graft length variation: the larger is the length variation, closer to extension the fixation must be done in order to avoid extension deficit.

As the reader will notice the "clock-face" reference do determine the tunnel position is not used in this chapter. Although this reference has been widely accepted in the literature to describe femoral tunnel positioning it has generated more confusion than clarification (Fu, 2008; Van Eck et al., 2010). The "clock-face" system is based on radiographs of the knee in extension while ACL reconstruction is performed at 90 degree of flexion or more. Therefore

the orientation of the clock face is no longer valid as the ACL femoral insertion site moves from vertical to horizontal when the knee bends. Furthermore the intercondylar notch is a 3-dimensional structure while the clock-face refers to a 2-dimensional structure which is neglectful of the depth of the notch.

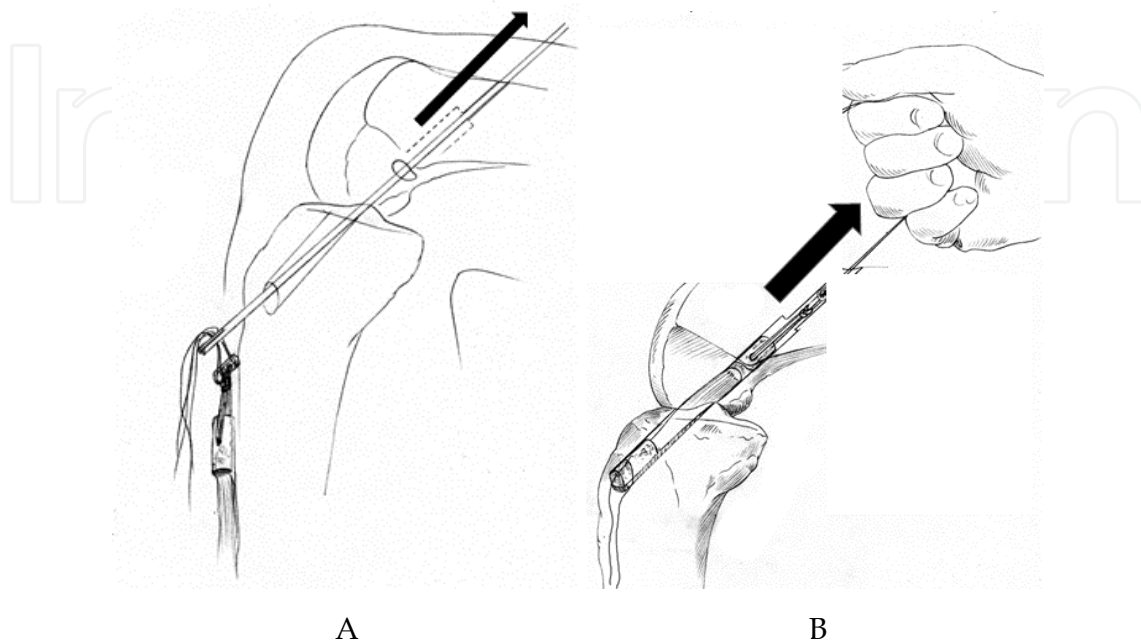


Fig. 7. Passing the graft. A: the leading stitches of the graft are first pulled through the tibial and femoral tunnel with the help of the eyelet guide wire. B: the graft is then pulled through the tunnels until it fills the femoral tunnel.

As the whole reconstruction procedure is performed through a small tibial incision which is used for harvesting and drilling, the transtibial technique is also called "one-incision" technique. Alternatively, "two-incision" technique has been developed. With this technique a lateral thigh incision is performed in order to settle, behind the lateral femoral condyle, a rear entry femoral guide, which position is arthroscopically controlled. The guide wire and the tunnel drilling are then performed from outside in. With the "two-incision" technique, the position of the femoral guide wire is independent from the tibial tunnel. However, due to the lateral thigh incision and its associated morbidity, the "two-incision" technique has never known a large development. On the contrary, the one-incision technique has quickly spread worldwide. With appropriate instruments "one-incision" ACL reconstruction with quadrupled hamstring tendons can be performed in less than 30 minutes in skilful hands.

5.2 Outcome of transtibial ACL reconstruction

5.2.1 Systematic review

There are many articles which address the outcome of single bundle transtibial reconstruction. We will summarize one of the most recent systematic review of single-bundle ACL reconstruction outcomes by Lewis et al. (Lewis et al.,2008). The authors reported a systematic review of 11 randomized, controlled trials comparing patellar tendon and hamstring tendon grafting. The respective outcomes of each group were combined to

assist the orthopaedic surgeon in assessing the current success of single-bundle reconstruction. The primary factors assessed were tibial subluxation and side-to-side differences in laxity. Secondary outcomes included concomitant injuries and treatments, complications, graft failure, range of motion, and radiographic evidence of degenerative changes. In this review of 1024 single-bundle anterior cruciate ligament reconstructions, including HS and BTPB autografts, 495 concomitant meniscal tears, 95 chondral injuries, and 2 posterior cruciate ligament tears were noted. The complication rate was 6%, and graft failure 4%. Reported pivot-shift test results were negative in 81% of cases; reported Lachman tests were negative in 59% cases; and KT-1000 arthrometer side-to-side differences were ≤ 5 mm in 86% of cases. Flexion and extension deficits were reported in 9 of 11 studies through mean range of motion or deficit ranges. Radiographic changes of articular surface were observed in 7% of the knees at follow-up. The authors concluded this systematic review of a significant body of unbiased outcome data on single-bundle ACL reconstruction demonstrates it to be a safe, consistent surgical procedure affording reliable results. On the other hand, there was still 19% persisting positive pivot shift tests (5-32%), 41% positive Lachman tests (14-76%), and 29% KT1000 side-to-side difference ≥ 3 mm (10- 54%). It appears the range of the values is quite variable from one publication to another. This is related to subjective bias when evaluating the patients. If one considers the persistence of a positive pivot shift test as a criterion for anatomic failure, single bundle transtibial ACL reconstruction has failed to restore a normal knee kinematic in 5 to 32% of the cases. The KT1000 arthrometer, which is certainly the most objective test method, showed almost 30% of anatomical failures. Accordingly one may question the validity of single bundle transtibial ACL reconstruction which lead to 30% of anatomic failures.

5.2.2 Factors influencing the outcome

Regardless the graft types (allograft vs autograft), graft source (bone patellar tendon bone, hamstring or Achilles tendon), some significant factors influence the outcome (Kowalchuk et al., 2009) of single bundle reconstruction: lower patient-reported outcome is strongly associated with obesity (BMI>30), smoking, meniscectomy and severe chondrosis at time of surgery. Also, a more vertical orientation of the graft influences the occurrence of a residual pivot shift test (Pinczewski et al., 2008).

In the long term range, following BPTB, good results are maintained at 15 years after surgery with respect to ligamentous stability, subjective outcomes, and range of motion while kneeling pain remains a significant problem. Concern remains regarding the incidence of further anterior cruciate ligament injury (24% sustained contralateral ACL ruptures, and 8% ruptured the graft). Graft rupture was associated with a graft inclination angle $<17^\circ$. Contralateral anterior cruciate ligament rupture was associated with age <18 years at time of primary injury. There is increasing number of patients (51%) with radiographic and clinical signs of osteoarthritis despite surgical stabilization (Hui et al., 2011). The joint degeneration seems to be more frequently met after BPTB graft than after HS grafts.

6. The move toward anatomy

Several surgeons, who early recognized the need to further improve the outcome of ACL reconstruction, moved towards a more anatomic way to reconstruct the ACL. This was mostly based on the drawbacks of the transtibial technique

- When the tibial tunnel was drilled through the tibial ACL footprint, the resulting femoral tunnel is too high in the notch (Fig. 8) inducing an impingement with the anterior part of the intercondylar notch leading to the necessity to widen the notch during surgery to avoid the impingement (notch plasty).
- It became obvious the femoral tunnel could not be drilled through the ACL footprint using the transtibial technique (Arnold et al., 2001; Gougoulas et al., 2008; Heming et al., 2007; Kaseta et al., 2008). In order to overcome this issue Howell proposed to shift the tibial tunnel posteriorly in order to reach, at least partially, the ACL femoral footprint and also avoid impingement with the roof of the intercondylar notch (Howell & Clark, 1992; Howell, 1998; Howell et al. 2001). However, this resulted in a vertical graft placement (posterior on the tibia and high in the notch) which was able to control the anterior tibial translation but not the tibial rotation. This explains the high rate of residual positive pivot shift. Many clinical and experimental studies have supported this issue (Boden et al., 1996; Herbort et al., 2010; Jepsen et al., 2007; Khalfayan et al., 1996; Lee et al., 2007; Markolf et al., 2002; Muneta et al., 1995; Mushal et al., 2005; Ristanis et al., 2003; Rue et al., 2008; Sommer et al., 2000; Scopp et al., 2004).
- However, contrary to all the studies which have demonstrated the influence of the femoral tunnel aperture location and orientation on the knee stability, tibial tunnel position has fewer influence on knee laxity (Morgan et al., 1995; Romano et al., 1993).

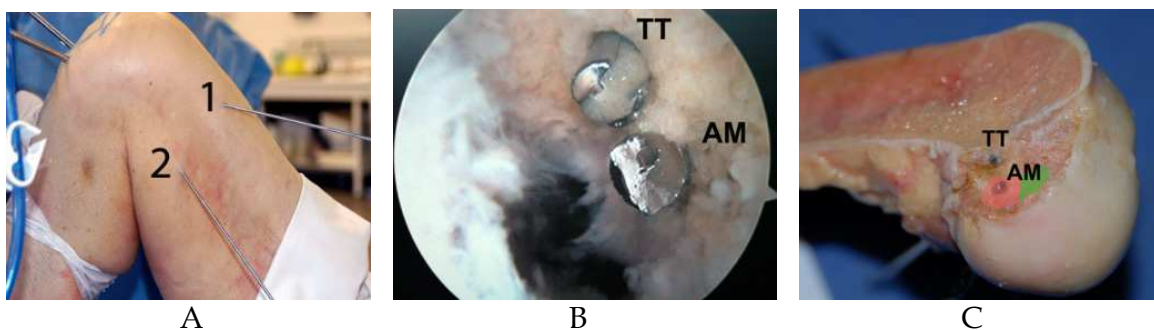


Fig. 8. Position of the femoral guide wire inserted either transtibial or transportal in cadaver. All the three illustrations are from the same right knee. A: 1 transtibial guide wire inserted at 90 degree of flexion, 2 transportal guide wire inserted at 110 degree of knee flexion. B: intra-articular visualization of the guide wires from the medial side (TT transtibial, AM transportal). C: The medial femoral condyle has been removed. The TT guide wire is located in the roof of the intercondylar notch out of the ACL footprint. The AM guide wire is right in the center of the AMB attachment site (pink). The PL footprint is colored in green.

7. Transportal technique

Drilling the femoral tunnel through an anteromedial (AM) portal has been described early on (Clancy, 1985; Cain & Clancy, 2002; Deehan & Pinczewski, 2002). These authors recognized the best and easiest way to reach the femoral ACL footprint was to drill through an AM portal. Transportal technique allows positioning the femoral tunnel lower in the notch, where the ACL is attached, with a more horizontal tunnel, offering in addition to the tibial translation control a better rotational control compared to the transtibial technique (Alentorn-Geli et al., 2009; Bedi et al., 2010; Bedi et al., 2011; Bottoni, 2008; Dargel et al., 2009; Gavriilidis et al., 2008; Loh et al., 2003; Rue et al., 2008; Sohn & Garrett, 2009; Zantop et al., 2008). Also, drilling the

femoral tunnel through an AM portal allows obtaining tunnel aperture which overlaps with the native ACL footprint, while drilling through the tibial tunnel hardly covers part of the AM footprint (Abebe et al., 2009). Modifying the tibial tunnel orientation to overcome this issue has been proposed (Chhabra et al., 2004; Heming et al., 2007; Kopf et al., 2010; Miller et al., 2010). When drilling a more horizontal tunnel, and starting more medial it becomes possible to target the native ACL footprint. However, the resulting tunnel becomes very short, with a quite oval intra-articular tunnel aperture, putting the medial tibial plateau at risk for fracture, rising concerns for tibial graft fixation, and compromising graft stability at the tunnel aperture. Nevertheless, transportal drilling technique has pearls and pitfalls which have been described in the literature (Basdekis et al., 2008; Harner et al., 2008; Lubowitz, 2009; Zantop et al., 2008).

7.1 Portals

The location of the instrumental anteromedial (AM) portal, also called accessory AM- or far medial portal is critical (Fig. 9). The best way to locate it is to use a spinal needle, keeping the scope through the anterolateral (AL) portal in order to optimize its placement under direct vision. The needle must sit above the anterior segment of the medial meniscus, far enough from the medial femoral condyle not to damage the cartilage when using endoscopic drills. Single fluted endoscopic drills reduce the risk for cartilage damages. If the portal is close to the patellar tendon the drill will be oriented at sharp angle with regard to the lateral wall of the intercondylar notch resulting in an oval femoral tunnel aperture. If the portal is more medial, the orientation of the drill will result in a more circular aperture.

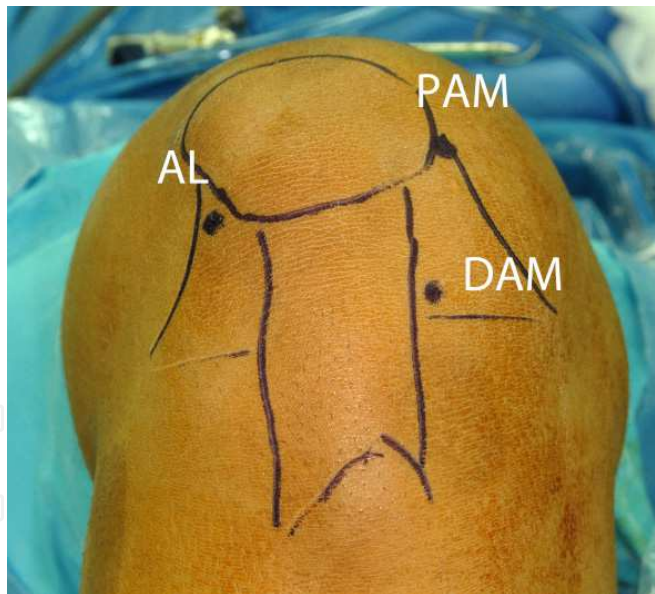


Fig. 9. Portal location for transportal drilling technique. Anterolateral portal (AL) is high in the soft spot above the fat pad. Proximal anteromedial portal (PAM) is located at the junction between the patella and the medial femoral condyle. Distal anteromedial (DAM) portal is located above the anterior segment of the medial meniscus

7.2 Drilling

During drilling, the knee must be bent at least at 110 degree of flexion in order to avoid blowing up the posterior wall of the lateral femoral condyle (Fig. 10). The more the knee is

bent the longer is the femoral tunnel (Basdekis et al., 2008). It might be necessary to resect part of the fat pad in order to obtain an appropriate vision of the lateral wall of the notch. Keeping the scope through the AL portal provides a tangential view of the lateral wall of the notch and the ACL footprint. So, in order to insure a good visualization of the footprint it is better to view the notch from the medial side of the knee. Placing the scope through a proximal AM portal and the instruments through an accessory AM portal is also called three-portal technique (Cohen & Fu, 2007) as it combines one AL portal with 2 AM portals. Watching the lateral wall of the intercondylar notch from medial provides a full view of the ACL foot print from the anterior cartilage margin to the posterolateral outlet and allows precise visualization of the lateral intercondylar ridge.

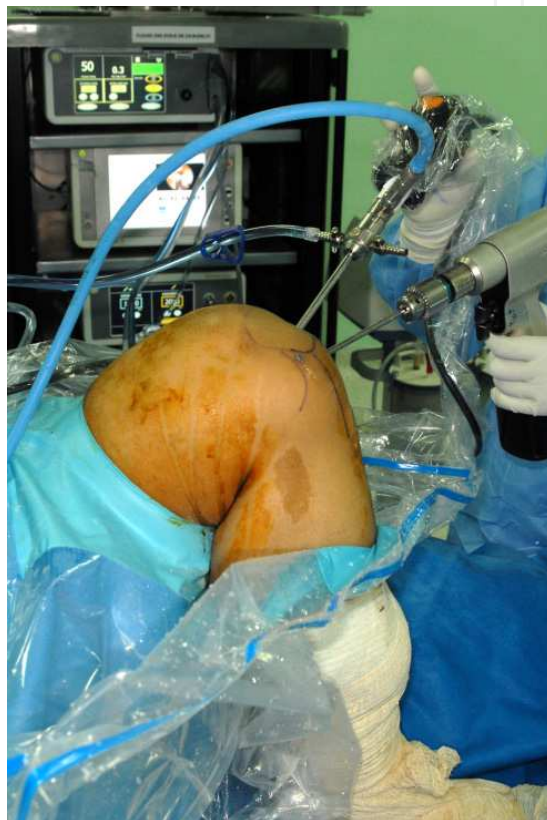

Fig. 10. Drilling the femoral tunnel transportal. The knee is bent at least at 110 degree of flexion. The scope is through the PAM portal and the drill through the DAM portal (Right knee).

7.3 Transportal drilling limitations

- intra-articular visualization of the notch may be restricted so that the surgeon must be confident with the arthroscope and eventually needs to remove soft tissues around the notch
- cross-pin graft fixation techniques require guide instruments that are designed for transtibial insertion only
- As the femoral tunnel is more horizontal when drilled through an AM portal, the graft – tunnel angulation may increase resulting in higher contact pressures at the anterior aspect of the graft with full extension and might cause bone tunnel enlargement.

However, Chhabra et al (Chhabra et al., 2006) comparing transtibial femoral tunnel expansion vs AM drilling found significantly less enlargement with the transportal technique

8. Development of anatomic double-bundle ACL reconstruction

Anatomic ACL reconstruction is defined as the functional restoration of the ACL to its native dimensions, collagen orientation, and insertion sites (Van Eck et al., 2010). The concept and development of double-bundle ACL reconstruction comes from the rediscovery of the ACL bundles anatomy and biomechanics of ACL reconstruction. Several studies have shown that rotational control of the tibia as well as anterior tibial translation were much improved when the PLB was reconstructed in addition to the AMB (Colombet et al., 2007; Kanaya et al., 2009; Markolf et al., 2009; Sbihi et al., 2004; Yagi et al., 2002; Zaffagnini et al., 2008; Zantop et al., 2007).

Already in his original transtibial technique, T Rosenberg was mentioning the possibility to reconstruct 2 bundles, if the femoral footprint size was big enough, by drilling 2 sockets in the femur and one tunnel in the tibia. This idea was further developed in Japan (Hara et al., 2000; Hamada et al., 2001; Mae et al., 2001; Munetta et al., 1999), then in France (Franceschi et al., 2002; Bellier et al., 2004) and finally in the USA. While few authors persisted in the use of transtibial technique (Yasuda et al., 2004), it appeared rapidly to most surgeons that double bundle ACL reconstruction which necessitates drilling 2 femoral sockets and 2 tibial tunnels could be only performed either with transportal technique or two-incision technique.

8.1 Following is a brief summary of the principles of anatomic double-bundle ACL reconstruction technique. We will describe transportal technique with four tunnels, which is the most widely used. Few surgeons are using alternative techniques like two-incision- (Aglietti et al., 2005) or modified transtibial technique (Yasuda et al., 2004). Most of the authors use autogenous hamstring tendons. Usually the AMB is reconstructed with a double-stranded semitendinosus tendon, while the gracilis is used for the PLB. According to their size or length, tendons can be doubled, tripled or even quadruple-stranded. Allografts are used mostly in the USA. In Western patients, with autogenous hamstrings, the average AMB diameter is 7mm (6-9mm) and PLB 6mm (5-7mm). Most of the authors use Endobutton® CL for the femoral fixation. Others are using interference screws. On the tibial side, various fixation methods have been described: interference screws, plate and screw, screw post and washer. As femoral tunnels are drilled independently one may start either by drilling tibial- or femoral tunnels.

8.1.1 Femoral tunnels

The femoral footprint is visualized through an AM portal and carefully identified according to the landmarks previously described (Cha et al., 2005). Identifying the intercondylar ridge is a key issue and fluoroscopy may help. Through an accessory AM portal two sockets are drilled through the center of each bundle attachment with the knee bent at least at 110° of flexion (Basdekis et al., 2008; Basdekis et al., 2009; Hoshino et al., 2009). Specific instruments allow proper positioning of the tunnels, keeping a 2-3 mm bone bridge (Fig. 11) between them in order to insure independent fixation of each bundle (Bellier et al., 2004; Christel et

al., 2005; Christel et al., 2008 a-c). Three-dimensional CT studies (Fig 12 A) have validated the accuracy of the instruments (Basdekis et al., 2009a). The resulting cortical bone bridge separating the tunnel apertures remains stable with time (Hantes et al., 2010). When the knee is at 90° of flexion, PLB tunnel is located in front and lower compared to AMB tunnel. The axis going through the center of both tunnels should make a 30° angle with the long axis of the femur.

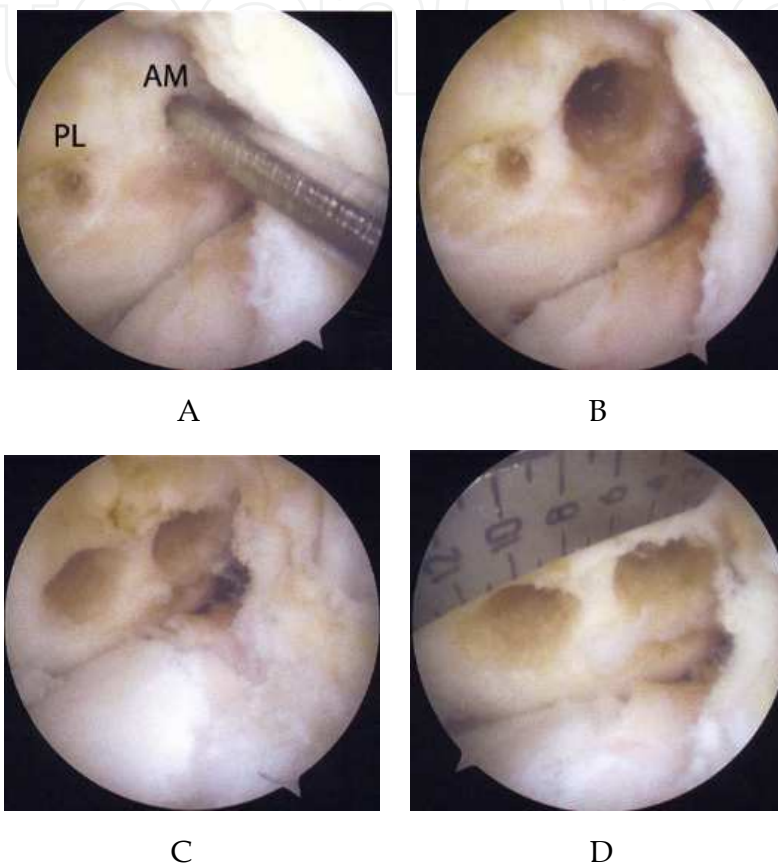


Fig. 11. Double bundle ACL reconstruction, left knee, drilling of the femoral sockets. The lateral wall of the intercondylar notch is viewed from medial. A: the centers of both bundles are marked. A guide wire is inserted through the center of the AMB, knee bent at 110 degree. B: the AM socket is drilled at a diameter equal to the bundle graft. C: both sockets are drilled, knee views from medial at 90 degree of flexion. D: there is a 2mm bone bridge between the 2 sockets.

8.1.2 On the tibial side, the AMB tunnel starts along the medial side of the tibial tubercle and opens in the center of the AMB footprint. The PLB tunnel starts more medially, in front of the anterior edge of the medial collateral ligament. Specific instrumentation allows drilling the PLB tunnel through the center of the PLB footprint, 8-9mm behind and slightly lateral to the AMB aperture, saving a 2-3mm bone bridge between the two tunnels (Christel et al., 2005; Christel et al., 2008 a-c). Three-dimensional CT studies (Fig.12B) have validated the accuracy of the instruments (Saharsrabudhe et al., 2010). The diameters of the tunnels correspond to the graft diameters.

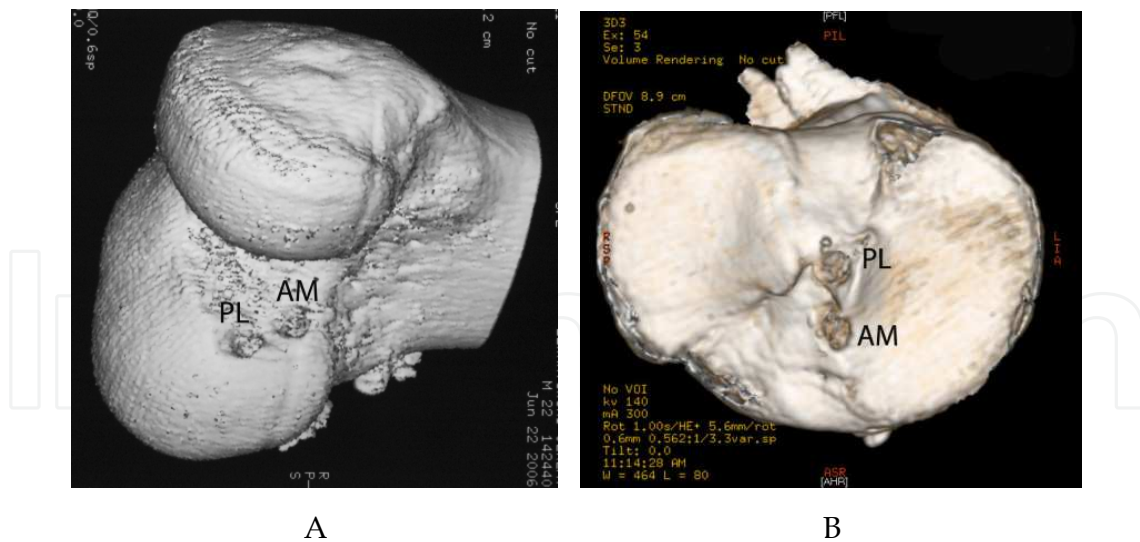


Fig. 12. Three-dimensional CT scan views of the tunnels after double-bundle ACL reconstruction. A: femoral sockets, B: intra-articular aperture of the tibial tunnels.

As for single-bundle ACL, several authors have shown tunnel position is highly critical for proper tension and bundles efficacy (Forsythe et al., 2010; Giron et al., 2007, Nishimoto et al., 2009; Silva et al., 2010). Unfortunately most of the publications related to double-bundle ACL reconstruction outcome do not document the position of the tunnels. In order to document tunnel position after surgery, 3-dimensional CT scan is the method of choice (Basdekis et al., 2009a; Forsythe B et al., 2010; Saharsrabudhe et al., 2010). Accordingly, if many publications relate to double-bundle ACL reconstruction, it is hard to distinguish between those which perform anatomical reconstruction, i.e. with tunnels drilled within the ACL footprints, and those with non-anatomical reconstructions where tunnels are drilled outside the ACL footprints.

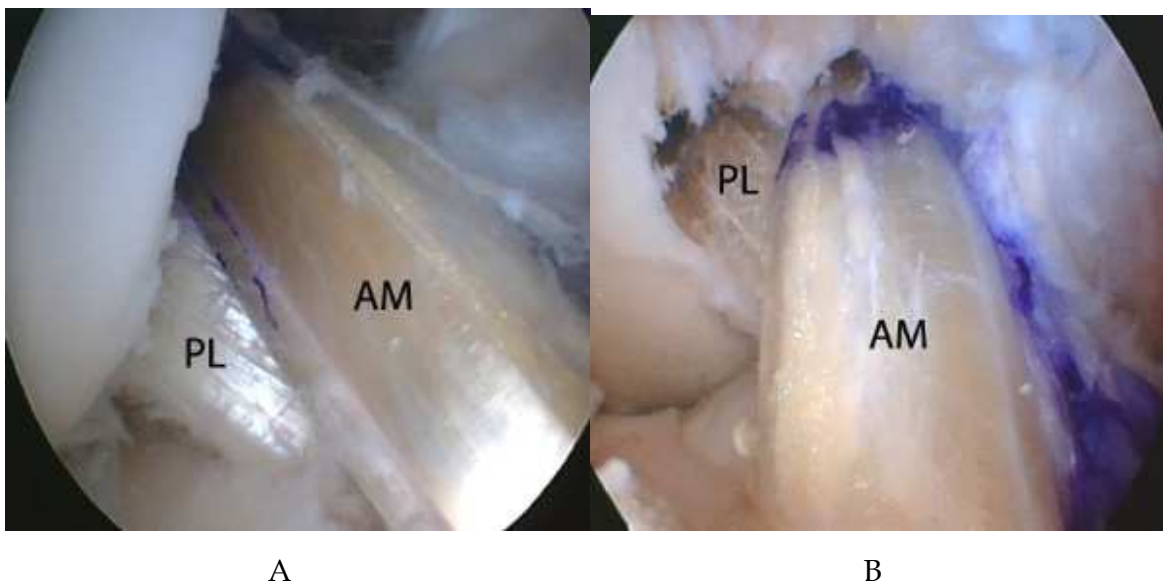


Fig. 13. Intra-articular view of a double bundle ACL graft. The AMB is reconstructed with a double-stranded semitendinosus while the PLB is reconstructed with a double stranded gracilis. A: grafts viewed through the AL portal, B: grafts viewed through an AM portal

8.2 Outcome of anatomic double-bundle ACL reconstruction

8.2.1 Review study

Authors Year of publication	Level of evidence	Technique	N	KT 134 N(mm)	Pivot shift %> glide
Yagi et al, 2007	2	SB AM	20	1.9	35
		SB PL	20	1.7	20
		A2B	20	1.9	15
Aglietti et al, 2007	2	SB	25	2.4	42
		2B transtibial	25	1.6	24
		2B 2-incision	25	1.4	16
Yasuda et al, 2006	2	SB	24	2.8	50
		A 2B	24	1.1	12.5
Jarvela, 2007	1	SB	52	1.8	36
		A2B	25	1.4	3.3
Muneta et al, 2007	1	SB	34	2.4	41.2
		A2B	105	1.4	14.7
Asagumo et al, 2007	3	SB	52	1.9	19.2
		A2B	71	1.7	12.7
Kondo et al, 2008	2	SB	157	2.5	49
		A2B	171	1.2	19
Siebold et al, 2008	1	SB	35	1.6	31.4
		A2B	35	1.0	0.04
Streich et al, 2008	1	SB	25	0.94	25
		A2B	24	1.1	24
Kim et al, 2009	3	SB	28	2.6	11
		A2B	31	1.8	0
Aglietti et al, 2010	1	SB	35	2.1	26
		A2B	35	1.2	14

Table 2. Summary of the main studies comparing the outcome of single-bundle (SB) with anatomic double-bundle (A2B) ACL reconstruction. N is the number of patients in the study groups. Mean KT 1000 arthrometer results are given for a 134N load. Positive pivot shift test corresponds to pivot shift glide or more. All studies have at least a 2-year minimum follow up.

The above table summarizes 15 comparative studies, 6 level 1, 7 level 2, 2 level 3, all with follow up > 2 years and effective follow up, single-bundle 96.2 %, anatomic double-bundle 93.4 %. There is total number of 455 single-bundle patients and, 520 anatomic double-bundle. There is no statistical difference regarding the KT 1000 outcome. However, there is clearly less residual pivot shift after anatomic double-bundle reconstruction (12% vs 33%).

8.2.2 Meta-analysis

Meredick et al. (Meredick et al., 2008) have conducted a meta-analysis where they systematically identified randomized controlled trials (RCTs) comparing single-bundle versus doublebundle ACL reconstruction.

Two outcome measures were reported (in a manner permitting meta-analysis) in at least 3 of 4 trials: KT-1000 arthrometer and pivot-shift testing. On average, KT-1000 arthrometer side-to-side difference was 0.52 mm closer to normal in patients treated with double-bundle reconstruction. This difference is demonstrated to be clinically insignificant. The odds of a normal or nearly normal pivot shift is higher in the patients treated with double-bundle ACL reconstruction than in those treated with single bundle. However, this finding is not statistically significant because the 95% confidence intervals include 0. The authors concluded double-bundle reconstruction does not result in clinically significant differences in KT-1000 arthrometer or pivot shift testing. One may argue the authors grouped together normal and nearly normal knees, while the goal of ACL surgery is to restore a normal knee. When considering the figures of this study and separating normal- from nearly normal knees it appears that following single-bundle (293 patients) 63.5 % of them had no pivot shift while following double bundle (318 patients), 87.7% had no pivot shift ($p < 0.001$). In fact all the single-bundle versus double-bundle studies have compared anatomic with non-anatomic reconstructions. Single bundle technique was based on a transtibial approach (with a femoral tunnel almost entirely located outside the ACL footprint) while, double-bundle tunnels were located within the ACL footprints.

9. Anatomic double bundle reconstruction limitations

If one wish to maintain a sufficient graft size (7mm for AMB and 6mm for PLB), small ACL footprints (less than 14mm long) do not allow drilling independent tunnels with a sufficient bone bridge in between. In this case single bundle reconstruction must be used. Also narrow intercondylar notch is a severe limitation as it does not leave enough space for the graft.

The concept of anatomic double bundle ACL reconstruction was further applied to partial tears of the ACL when one bundle only has been ruptured. In these particular cases it has been proposed to reconstruct only the damaged bundle, performing an ACL augmentation (Borbon CA et al., 2011; Serrano-Fernandez JM et al., 2010).

10. The anatomic single bundle ACL reconstruction

Taking into account technical difficulties for drilling 4 independent tunnels with consistent bone bridges and the renewed knowledge of ACL anatomy, anatomic single bundle ACL reconstruction was a logic development. The basis for this technique is to drill the femoral tunnel in the center of the femoral foot print, between the centers of both bundles, behind the intercondylar ridge, in such way that it includes part of both AMB and PLB fibers (Ho et al., 2009; Rue et al., 2008; Shino et al., 2008, Steiner, 2009; van Eck et al., 2011; Yamamoto et al., 2004).

10.1 Technical principles

In order to perform an optimal anatomic single-bundle ACL reconstruction the transportal technique must be used. As stated before, with the lens from the medial side it is easy to identify the femoral ACL stump, the intercondylar ridge and the centers of the AMB and PLB. The center of the anatomic femoral tunnel is located in at mid distance from the bundle centers. It can be drilled right in the middle of the footprint and will contain 50% of AMB fibers and 50% of PLB fibers. I can also be drilled more proximally to contain more AMB fibers or more distally, containing more PLB fibers. However a single tunnel in the middle of the foot print will contain less fiber than 2 tunnels drilled in the center of each bundle

attachment. On the tibial side the tunnel is drilled in the center of the ACL foot print, slightly medial. As the femoral tunnel is much lower than with the transtibial technique, the resulting graft has a more oblique orientation and is able to resist anterior tibial translation and tibial internal rotation (Fig. 14).

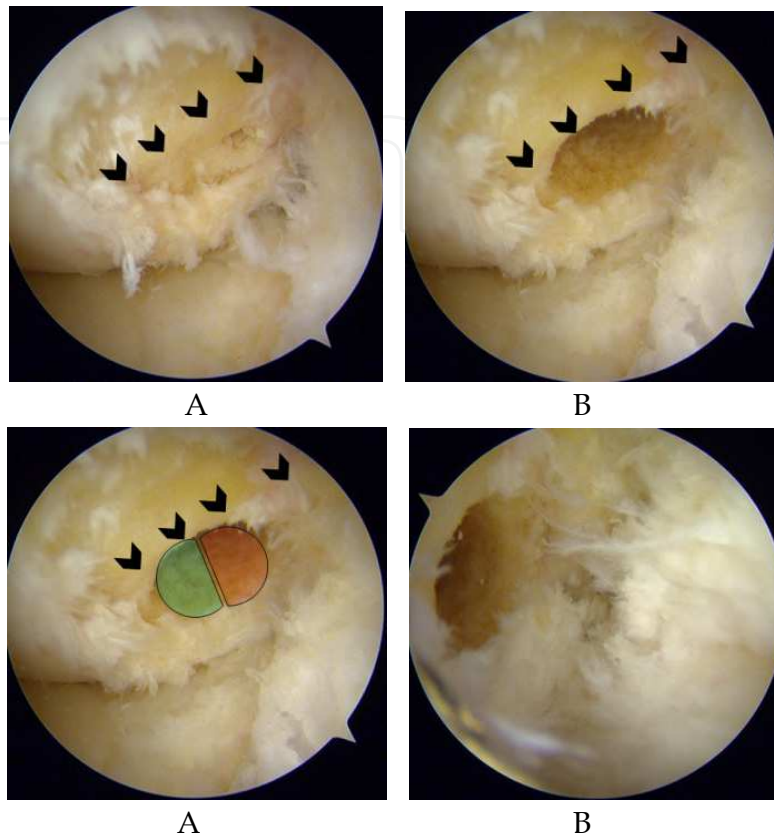


Fig. 13. Femoral socket for single bundle anatomic reconstruction. A: the lateral wall of the intercondylar notch has been gently cleaned with a curette to locate the lateral intercondylar ridge (arrows). B: position of a 9mm socket, right behind the intercondylar ridge. C: the socket aperture is positioned in such a way that it overlaps 50% of the PLB- and 50% of the AMB attachment sites. A,B, and C views are taken from the medial side. D: view of the socket from the AL portal.

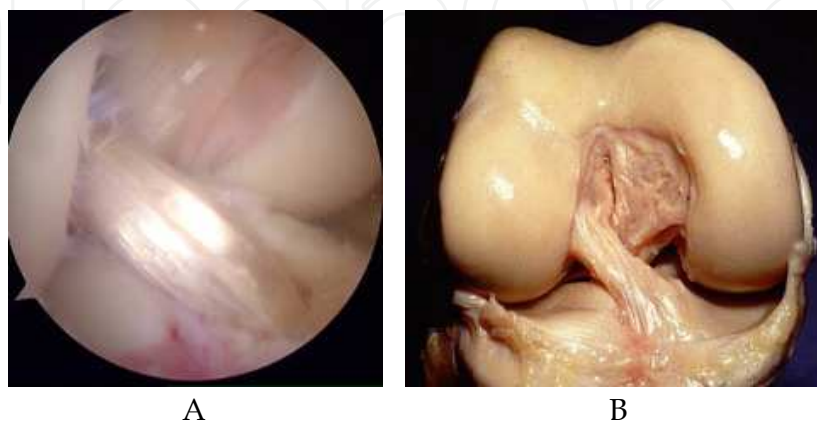


Fig. 14. Comparison of the obliquity of an anatomic single bundle ACL (A) with a native ACL (B). Note the similarity in orientation of both reconstructed and native ACL.

10.2 Outcome of anatomic single-bundle ACL

Currently, only few published papers deal with comparison of the outcome of anatomic single- with anatomic double-bundle (Gobbi et al., 2011; Park et al., 2010; Song et al., 2009). On the clinical stand point these studies show no statistical differences between the objective and subjective outcomes of the two techniques. Thus it seems that reconstructing the ACL with anatomic single-bundle technique is a valid option with improved results compared to single-bundle transtibial. Further publications and longer follow-up should confirm these preliminary results.

11. Conclusion

There is still much to learn about ACL reconstruction. The old transtibial technique which does not reconstruct the ACL where it is attached has progressively evolved toward anatomical ACL reconstruction. Currently anatomic single- and double-bundle ACL reconstruction are well established and well described. However, if the outcome of these techniques has considerably improved with regard to the transtibial technique, the results are still far to be perfect. There are still small percentages of fair results for which improvements have to be made. Only long term results will tell if the restoration of ACL anatomy is going to decrease knee joint degeneration which remains the major issue of long term outcome of ACL reconstruction

12. References

- Abebe ES, Moorman III CT, Dziedzic TS, Spritzer CE, Cothran RL, Taylor DC, William E. Garrett WE Jr, DeFrate LE. (2009) Femoral Tunnel Placement During Anterior Cruciate Ligament Reconstruction : An In Vivo Imaging Analysis Comparing Transtibial and 2-Incision Tibial Tunnel -Independent Techniques. *Am J Sports Med*, 37, No.10 (October), pp 1904-1911
- Aglietti P, Cuomo P, Giron F, Boerger TO. (2005). Double-bundle anterior cruciate ligament reconstruction: surgical technique. *Operative Techniques in Orthopaedics*, F Fu (Ed), WB Saunders Pub, Philadelphia. Vol 15, No.2 (April), pp 111-115
- Aglietti P, Giron F, Cuomo P, Losco M, Mondanelli N. (2007). Single- and doubleincision double-bundle ACL reconstruction. *Clin Orthop Relat Res*. 454, pp 108-113.
- Aglietti P, Giron F, Losco M, Cuomo P, Ciardullo A, Mondanelli N. (2010). Comparison between single-and double-bundle anterior cruciate ligament reconstruction: a prospective, randomized, single-blinded clinical trial. *Am J Sports Med*, 38, No.1 (January), pp 25-34.
- Alentorn-Geli E, Lajara F, Samitier G, Cugat R (2010) The transtibial versus the anteromedial portal technique in the arthroscopic bone-patellar tendon-bone anterior cruciate ligament reconstruction. *Knee Surg Sports Traumatol Arthrosc*. 18, No. 8 (August), pp 1013-1037.
- Arnold MP, Kooloos J, van Kampen A (2001) Single-incision technique misses the anatomical femoral anterior cruciate ligament insertion: a cadaver study. *Knee Surg Sports Traumatol Arthrosc*, 9, pp 194-199
- Asagumo H, Kimura M, Kobayashi Y, Taki M, Takagishi K. (2007) Anatomic reconstruction of the anterior cruciate ligament using double-bundle hamstring tendons: surgical techniques, clinical outcomes, and complications. *Arthroscopy* 23:602-609

- Aune AK, Holm I, Risberg MA, Jensen HK, Steen H (2001) Four-strand hamstring tendon autograft compared with patellar tendon-bone autograft for anterior cruciate ligament reconstruction. A randomized study with two-year follow-up. *Am J Sports Med*, 29, pp722-728
- Bach BR Jr, Aadalén KJ, Dennis MG, et al. (2005). Primary anterior cruciate ligament reconstruction using fresh-frozen, nonirradiated patellar tendon allograft: Minimum 2-year follow-up. *Am J Sports Med*, 33, pp284-292.
- Basdekis G, Abisafi C, Christel P. (2008). Influence of knee flexion angle on femoral tunnel characteristics when drilled through the anteromedial portal during anterior cruciate ligament reconstruction. *Arthroscopy*, 24, pp 459-464.
- Basdekis G, Christel P, Anne F. (2009a). Validation of the position of the femoral tunnels in anatomic double-bundle ACL reconstruction with 3-D CT scan. *Knee Surg Sports Traumatol Arthrosc*, 17, pp 1089-1094
- Basdekis G, Abisafi C, Christel P. (2009b). The effect of knee flexion angle on the length and orientation of posterolateral femoral tunnel drilled through the anteromedial portal during anatomic double-bundle ACL reconstruction. *Arthroscopy*, 25, pp 1108-1111.
- Bedi A, Raphael B, Maderazo A, Pavlov H, Williams RJ III. (2010). Transtibial versus anteromedial portal drilling for anterior cruciate ligament reconstruction: A cadaveric study of femoral tunnel length and obliquity. *Arthroscopy*, 26, No 3 (March), pp 342-350.
- Bedi A, Musahl V, Steuber V, Kendoff D, Choi D, Allen AA, Pearle AD, Altchek DW. (2011). Transtibial versus anteromedial portal reaming in anterior cruciate ligament reconstruction: An anatomic and biomechanical evaluation of surgical technique. *Arthroscopy*, 27, No 3 (March), pp 380-390
- Bellier G, Christel P, Colombet P, Djian P, Franceschi JP, Sbihi A. (2004). Double Stranded Hamstring Graft For Anterior Cruciate Ligament Reconstruction. *Arthroscopy*, 20, pp 890-894
- Bernard M, Hertel P, Hornung H, Cierpinski T. (1997). Femoral insertion of the ACL: radiographic quadrant method. *Am J Knee Surg*, 10, pp 14-21
- Beynon BD, Johnson RJ, Fleming BC, Kannus P, Kaplan M, Samani J, Renstrom P (2002) Anterior cruciate ligament replacement: comparison of bone-patellar tendon-bone grafts with two-strand hamstring grafts. A prospective, randomized study. *J Bone Joint Surg Am*, 84A, pp 1503-1513
- Boden B, Migaud H, Gougeon F, Debroucker MJ, Duquenois A. (1996). Effect of graft position on laxity after anterior cruciate ligament reconstruction. Stress radiography in 90 knees 2 to 5 years after autograft. *Acta Orthopaedica Belgica*, 62, pp 2-7
- Borbon CA, Mouzopoulos G, Siebold R. (2011). Why perform an ACL augmentation? *Knee Surg Sports Traumatol Arthrosc*. 17, Jun 9. [Epub ahead of print]
- Bottoni CR. (2008). Anterior cruciate ligament femoral tunnel creation by use of anteromedial portal. *Arthroscopy* 24, No. 11 (November), pp 1319 (letter to the editor).
- Cain EL Jr, Clancy WG Jr. (2002). Anatomic endoscopic anterior cruciate ligament reconstruction with patella tendon autograft. *Orthop Clin North Am*, 33, No.4, pp 717-725.

- Cha PS, Brucker PU, West RV, et al. (2005). Arthroscopic double bundle anterior cruciate ligament reconstruction: An anatomic approach. *Arthroscopy*, 21, pp1275.e1-1275.e8.
- Chen L, Cooley V, Rosenberg T. (2003). ACL reconstruction with hamstring tendon. *Orthop Clin North Am*, 34, No. 1 (January), pp 9-18.
- Chhabra A, Diduch DR, Blessey PB, Miller MD. (2004). Recreating an acceptable angle of the tibial tunnel in the coronal plane in anterior cruciate ligament reconstruction using external landmarks. *Arthroscopy*, 20, pp 328-330.
- Chhabra A, Kline AJ, Nilles KM, Harner CD. (2006). Tunnel expansion after anterior cruciate ligament reconstruction with autogenous hamstrings: A comparison of the medial portal and transtibial techniques. *Arthroscopy*, 22, pp 1107-1112.
- Christel P, Franceschi JP, Sbihi A, Colombet P, Djian P, Bellier G. (2005). Anatomic ACL Reconstruction: the French Experience. *Operative Techniques in Orthopaedics*, F Fu (Ed), WB Saunders Pub, Philadelphia. Vol 15, No.2 (April), pp 103-110.
- Christel P, Basdekis G, Abisafi C. (2008a). Double-bundle ACL reconstruction technique: France. In: *Current concepts in ACL reconstruction*, Fu FH, Cohen SB, eds. Thorofare, NJ: Slack, pp 275-286.
- Christel P, Sahasrabudhe A, Basdekis G. (2008b). Anatomic double-bundle anterior cruciate ligament reconstruction with anatomic aimers. *Arthroscopy*, 24, No. 10 (October), pp 1146-1151
- Christel P, Sahasrabudhe A, Basdekis G. (2008c). Double-bundle ACL reconstruction with the Anatomic Director set. *Operative Tech in Sports Med*, 16, pp 131-137
- Clancy WG Jr. Intra-articular reconstruction of the anteriorcruciate ligament. *Orthop Clin North Am*. 1985; 16:181 -189.
- Cohen SB, Fu FH. (2007). Three-portal technique for anterior cruciate ligament reconstruction: Use of a central medial portal. *Arthroscopy*, 23, No 3 (March), pp 325.e1-325.e4
- Colombet P, Robinson J, Christel P, et al. (2006).Morphology of anterior cruciate ligament attachments for anatomic reconstruction: A cadaveric dissection and radiographic study. *Arthroscopy*, 22, pp984-992.
- Colombet P, Robinson J, Christel P, Franceschi JP, Djian P. (2007).Using navigation to measure rotation kinematics during ACL reconstruction. *Clin Orthop Relat Res*, 454, (Januray), pp59-65.
- Dargel J, Schmidt-Wiethoff R, Fischer S, Mader K, Koebke J, Schneider T. (2009). Femoral bone tunnel placement using the transtibial tunnel or the anteromedial portal in ACL reconstruction: A radiographic evaluation. *Knee Surg Sports Traumatol Arthrosc*, 17, pp 220-227.
- Deehan DJ, Pinczewski LA. (2002). Endoscopic anterior cruciate ligament reconstruction using a four strand hamstring tendon construct. *J R Coll Surg Edinb*. 2002 Feb;47(1):428-36
- Edwards A, Bull AM, Amis AA. (2007). The attachments of the anteromedial and posterolateral fibre bundles of the anterior cruciate ligament: Part 1: tibial attachment. *Knee Surg Sports Traumatol Arthrosc*. Dec;15, No.12 (Dec), pp 1414-1421.
- Edwards A, Bull AM, Amis AA. (2008).The attachments of the anteromedial and posterolateral fibre bundles of the anterior cruciate ligament. Part 2: Femoral attachment. *Knee Surg Sports Traumatol Arthrosc*, 16, pp 29-36

- Farrow LD, Gillespie RJ, Victoroff BN, Cooperman DR. (2008). Radiographic location of the lateral intercondylar ridge its relationship to Blumensaat's line. *Am J Sports Med*, 36, No. 10 (October), pp 2002-2006
- Forsythe B, Kopf S, Wong AK, Martins CAQ, Anderst W, Tashman S, Fu FH. (2010). The Location of Femoral and Tibial Tunnels in Anatomic Double-Bundle Anterior Cruciate Ligament Reconstruction Analyzed by Three-Dimensional Computed Tomography Models. *J Bone Joint Surg Am*, 92, pp 1418-1426.
- Foster TE, Wolfe BL, Ryan S, Silvestri L, Krall Kaye E. (2010). Does the graft source really matter in the outcome of patients undergoing anterior cruciate ligament reconstruction? : An evaluation of autograft versus allograft reconstruction results: A systematic review *Am J Sports Med*, 38, No.1 (January), pp 189-199.
- Franceschi JP, Sbihi A, Champsaur P. (2002). Dual arthroscopic reconstruction of the anterior cruciate ligament using anteromedial and posterolateral bundles. *Rev Chir Orthop*, 88, pp 691-697
- Freedman KB, D'Amato MJ, Nedeff DD, Kaz A, Bach BR Jr (2003) Arthroscopic anterior cruciate ligament reconstruction: a metaanalysis comparing patellar tendon and hamstring tendon autografts. *Am J Sports Med*, 31, pp 2-11.
- Fu FH, Jordan SS. (2007). The lateral intercondylar ridge- a key to anatomic anterior cruciate ligament reconstruction. *J Bone Joint Surg Am*, 89, pp 2103-2104.
- Fu FH. (2008). The clock-face reference: Simple but nonanatomic. *Arthroscopy*, 24, 1433, author reply 1434.
- Gavriilidis I, Motsis EK, Pakos EE, Georgoulis AD, Mitsionis G, Xenakis TA. (2008). Transtibial versus anteromedial portal of the femoral tunnel in ACL reconstruction: a cadaveric study. *Knee* 15, pp 364-367.
- Giron F, Cuomo P, Aglietti P, Bull RJ AM, Amis AA (2006) Femoral attachment of the anterior cruciate ligament. *Knee Surg Sports Traumatol Arthrosc* 1, pp 250-256.
- Giron F, Cuomo P, Edwards A, Bull AM, AmisAA, Aglietti P. (2007). Double-bundle "anatomic" anterior cruciate ligament reconstruction: A cadaveric study of tunnel positioning with a transtibial technique. *Arthroscopy*, 23, pp 7-13.
- Gobbi A, Mahajan V, Karnatzikos G, Nakamura N. (2011). Single- versus Double-bundle ACL Reconstruction: Is There Any Difference in Stability and Function at 3-year Followup? *Clin Orthop Relat Res*. 469, No.6, On line June 11. [Epub ahead of print]
- Gougoulis N, Khanna A, Griffiths D, Maffulli N. (2008). ACL reconstruction: can the transtibial technique achieve optimal tunnel positioning? A radiographic study. *Knee*, 15, pp 486-490.
- Hamada M, Shino K, Horibe S, et al. (2001). Single- versus bi-socket anterior cruciate ligament reconstruction using autogenous multiple-stranded hamstring tendons with Endobutton femoral fixation: A prospective study. *Arthroscopy*, 17, pp 801-807
- Hantes ME, Liantsis AK, Basdekis GK, Karantanas AH, Christel P, Malizos KN. (2010) Evaluation of the bone bridge between the bone tunnels after anatomic double-bundle anterior cruciate ligament reconstruction: a multidetector computed tomography study. *Am J Sports Med*, 38, No.8 (August), pp1618-1625.
- Hara K, Kubo T, Suginosita T, et al. (2000). Reconstruction of the anterior cruciate ligament using a double-bundle. *Arthroscopy*, 16, pp 860-864

- Harner CD, Baek GH, Vogrin TM, Carlin GJ, Kashiwaguchi S, Woo SL. (1999). Quantitative analysis of human cruciate ligament insertions. *Arthroscopy*, 15, pp741-749
- Harner CD, Honkamp NJ, Ranawat AS. (2008). Anteromedial portal technique for creating the anterior cruciate ligament femoral tunnel. *Arthroscopy*, 24, No. 1 (January), pp 113-115.
- Heming JF, Rand J, Steiner ME. (2007). Anatomical limitations of transtibial drilling in anterior cruciate ligament reconstruction. *Am J Sports Med*, 35, pp 1708-1715.
- Herbort M, Lenschow S, Fu FH, Petersen W, Zantop T. (2010). ACL mismatch reconstructions: influence of different tunnel placement strategies in single-bundle ACL reconstructions on the knee kinematics. *Knee Surg Sports Traumatol Arthrosc*, 18, pp1551-1558
- Ho JY, Gardiner A, Shah V, Steiner ME (2010) Equal kinematics between central anatomic single-bundle and double-bundle *Knee Surg Sports Traumatol Arthrosc*, 18, No. 12 (December), pp 1551-1558
- Hoshino Y, Nagamune K, Yagi M, Araki D, Nishimoto K, Kubo S, Minoru D, Kurosaka M, Kuroda R. (2009). The effect of intraoperative knee flexion angle on determination of graft location in the anatomic double-bundle anterior cruciate ligament reconstruction. *Knee Surg Sports Traumatol Arthrosc*, 17, No.9 (September), pp 1052-1060
- Howell SM. Clark JA. (1992). Tibial tunnel placement in anterior cruciate ligament reconstructions and graft impingement. *Clin Orthop*, 283, pp 187-195.
- Howell SM.(1998). Principles for placing the tibial tunnel and avoiding roof impingement during reconstruction of a tom anterior cruciate ligament. *Knee Surg Sports Traumatol Arthrosc*, 6(suppl I), pp S49-S55.
- Howell SM. Gittins ME. Gottlieb JE, Traina SM. ZoellnerTM. (2001). The relationship between the angle of the tibial tunnel in the coronal plane and loss of flexion and anterior laxity after anterior cruciate ligament reconsu-uction. *AmJ Sports Med*,29, pp 567-574.
- Hui C, Salmon LJ, Kokb A, Maeno S, Linklater J, Pinczewski LA. (2011). Fifteen-Year Outcome of Endoscopic Anterior Cruciate Ligament Reconstruction With Patellar Tendon Autograft for "Isolated" Anterior Cruciate Ligament Tear. *Am J Sports Med*, 39, No. 1(January), pp 89-97
- Jarvela T. (2007). Double-bundle versus single-bundle anterior cruciate ligament reconstruction: a prospective, randomized clinical study. *Knee Surg Sports Traumatol Arthrosc*. 15, pp 500-507.
- Jepsen CF, Lundberg-Jensen AK, Faunoe P. (2007). Does the position of the femoral tunnel affect the laxity or clinical outcome of the anterior cruciate ligament reconstructed knee.' A clinical, prospective, randomized, double-blind study. *Arthroscopy*, 23, pp 1326-1333.
- Kanaya A, Ochi M, Deie M, Adachi N, Nishimori M, Nakamae A (2009) Intraoperative evaluation of anteroposterior and rotational stabilities in anterior cruciate ligament reconstruction: lower femoral tunnel placed single-bundle versus double-bundle reconstruction. *Knee Surg Sports Traumatol Arthrosc* 17:907-913
- Kaseta MK. DeFrate LE. Charnock BL. Sullivan RT. Garrett WE Jr. (2008). Reconstruction technique affects femoral tunnel placement in ACL reconstruction. *Clin Orthop*, 466, pp 1467-1474.

- Khalfayan EE, Sharkey PF, Alexander AH, Bruckner JD, Bynum EB. (1996). The relationship between tunnel placement and clinical results after anterior cruciate ligament reconstruction. *Am J Sports Med*, 24, pp 335-341.
- Kim SJ, Jo SB, Kumar P, Oh KS. (2009). Comparison of single- and double-bundle anterior cruciate ligament reconstruction using quadriceps tendon-bone autografts. *Arthroscopy*, 25, No. 1 (January), pp:70-77
- Kondo E, Yasuda K, Azuma H, Tanabe Y, Yagi T. (2008). Prospective clinical comparisons of anatomic double-bundle versus single-bundle anterior cruciate ligament reconstruction procedures in 328 consecutive patients. *Am J Sports Med*, Sep;36, No.9 (September), pp1675-1687.
- Kopf S, Martin DE, Tashman S, Fu FH. (2010). Effect of tibial drill angles on bone tunnel aperture during anterior cruciate ligament reconstruction. *J Bone Joint Surg Am*, 92,pp 871-881.
- Kowalchuk DA, Harner CD, Fu FH, Irrgang JJ.(2009). Prediction of patient-reported outcome after single-bundle ACL reconstruction. *Arthroscopy*, 25, No.5 (May), pp 457-463.
- Krych AJ, Jackson JD, Hoskin TL, Dahm DL. (2008). A meta-analysis of patellar tendon autograft versus patellar tendon allograft in anterior cruciate ligament reconstruction. *Arthroscopy*, 24, No. 3 (March), pp 292-298
- Lee MC, Seong SC, Lee S, Chang CB, Park YK, Kim CH. (2007). Vertical femoral tunnel placement results in rotational knee laxity after anterior cruciate ligament reconstruction. *Arthroscopy*, 23, pp 771-778.
- Lewis PB, Parameswaran AD, Rue JPH, Bach BR Jr. (2008). Systematic review of single-bundle anterior cruciate ligament reconstruction outcomes: a baseline assessment for consideration of double-bundle techniques. *Am J Sports Med*, 36, No.10 (October), pp 2028-2036
- L'Insalata JC, Klatt B, Fu FH, Harner CD. (1997). Tunnel expansion following anterior cruciate ligament reconstruction: a comparison of hamstring and patellar tendon autografts. *Knee Surg Sports Traumatol Arthrosc.*, 5, No.4, pp234-238.
- Loh JC. Fukuda Y, Tsuda E. Steadman RJ. Fu FH. Woo SL-Y. Knee stability and graft function following anterior cruciate ligament reconstruction: Comparison between 11 o'clock and 10 o'clock femoral tunnel placement: 2002 Richard O'Connor Award paper. *Arthroscopy*. 2003;19:297-304.
- Lubowitz JH (2009) Anteromedial portal technique for the anterior cruciate ligament femoral socket: pitfalls and solutions. *Arthroscopy* 25:95-101
- Maletis GB, Cameron SL, Tengan JJ, Burchette RJ. (2007). A prospective randomized study of anterior cruciate ligament reconstruction: A comparison of patellar tendon and quadruple-strand semitendinosus/gracilis tendons fixed with bioabsorbable interference screws. *Am J Sports Med*, 35, pp 384-394.
- Markolf KL, Hame S, Hunter DM. et al. (2002). Effects of femoral tunnel placement on knee laxity and forces in an anterior cruciate ligament graft. *J Orthop Res*, 20, pp 1016-1024.
- Markolf KL, Park S, Jackson SR, McAllister DR. (2009). Anteriorposterior and rotatory stability of single and double-bundle anterior cruciate ligament reconstructions. *J Bone Joint Surg Am*, 91, pp 107-118.


- Meredick RB, Vance KJ, Appleby D, Lubowitz JH. (2008). Outcome of single-bundle versus double-bundle reconstruction of the anterior cruciate ligament: A meta-analysis. *Am J Sports Med*, 36; 1414-1421
- Miller MD, Gerdeman AC, Miller CD, Hart JM, Gaskin CM, Golish SR, Clancy WG Jr.(2010). The effects of extra-articular starting point and transtibial femoral drilling on the intra-articular aperture of the tibial tunnel in ACL reconstruction. *Am J Sports Med*, 38, No. 4, pp 707-712
- Mochizuki T, Muneta T, Nagase T, Shirasawa S, Akita KI, Sekiya I. Cadaveric knee observation study for describing anatomic femoral tunnel placement for two-bundle anterior cruciate ligament reconstruction. *Arthroscopy*. 2006;22:356-361,
- Morgan CD, Kaiman VR, Graw DM.(1995). Definitive landmarks for reproducible tibial tunnel placement in anterior cruciate ligament reconstruction. *Arthroscopy*, 11, pp 275-288.
- Muneta T, Yamamoto H, Ishibashi T, Asahina S, Murakami S, Furuya K. (1995). The effects of tibial tunnel placement and roofplasty on reconstructed anterior cruciate ligament. *Arthroscopy*, 1, pp 57-62.
- Muneta T, Sekiya I, Yagishita K, et al. (1999). Two-bundle reconstruction of the anterior cruciate ligament using semitendinosus tendon with Endobuttons: Operative technique and preliminary results. *Arthroscopy*, 15, pp 618-624.
- Muneta T, Koga H, Mochizuki T, et al. (2007). A prospective randomized study of 4-strand semitendinosus tendon anterior cruciate ligament reconstruction comparing single-bundle and double-bundle techniques. *Arthroscopy*, 23, pp 618-628.
- Musahl V, Plakseychuk A, VanScyoc A, et al. (2005). Varying femoral tunnels between the anatomical footprint and isometric positions: Effect on kinematics of the anterior cruciate ligament-reconstructed knee. *Am J Sports Med*, 33, pp 712-718.
- Nishimoto K, Kuroda R, Mizuno K, Hoshino Y, Nagamune K, Kubo S, Yagi M, Yamaguchi M, Yoshiya S, Kurosaka M (2009) Analysis of the graft bending angle at the femoral tunnel aperture in anatomic double bundle anterior cruciate ligament reconstruction: a comparison of the transtibial and the far anteromedial portal technique. *Knee Surg Sports Traumatol Arthrosc*, 17, pp270-276
- Pandarath R, Ciccotti M, DeLuca PF, Frederick RW. (2011). Current trends in ACL reconstruction among professional team physicians. *Proceedings of the AAOS 2011 Annual Meeting*, 12, paper 324
- Park SJ, Jung YB, Jung HJ, Jung HJ, Shin HK, Kim E, Song KS, Kim GS, Cheon HY, Kim S. (2010). Outcome of arthroscopic single-bundle versus double-bundle reconstruction of the anterior cruciate ligament: a preliminary 2-year prospective study. *Arthroscopy*. 26, No.5 (May), pp 630-636.
- Paulos LE, Cherf J, Rosenberg TD, Beck CL. (1991). Anterior cruciate ligament reconstruction with autografts. *Clin Sports Med*, 10, No. 3 (July), pp 469-85.
- Petersen W, Zantop T.(2007) Anatomy of the anterior cruciate ligament with regard to its two bundles. *Clin Orthop Relat Res*, 454, pp 35-47.
- Pinczewski LA, Salmon LJ, Jackson WF, von Bormann RB, Haslam PG, Tashiro S. (2008). Radiological landmarks for placement of the tunnels in single-bundle reconstruction of the anterior cruciate ligament. *J Bone Joint Surg Br.*, 90, No.2 (February), pp :172-179.

- Prodromos C, Joyce B, Shi K. (2007). A meta-analysis of stability of autografts compared to allografts after anterior cruciate ligament reconstruction. *Knee Surg Sports Traumatol Arthrosc*, 15, pp 851-856
- Purnell ML, Larson AI, Clancy W. (2008). Anterior cruciate ligament insertions on the tibia and femur and their relationships to critical bony landmarks using high-resolution volume-rendering computed tomography. *Am J Sports Med*, 36, pp 2083-2090.
- Ristanis S, Giakas G, Papageorgiou CD, Moraiti T, Stergiou N, Georgoulis AD. (2003). The effects of anterior cruciate ligament reconstruction on tibial rotation during pivoting after descending stairs. *Knee Surg Sports Traumatol Arthrosc*, 11, pp 360-365.
- Romano VM, Graf BK, Keenc JS, Lange RH. (1993). Anterior cruciate ligament reconstruction: The effect of tibial tunnel placement on range of motion. *Am J Sports Med*, 21, pp 415-418.
- Rosenberg TD, Deffner KT. (1997). ACL reconstruction: semitendinosus tendon is the graft of choice. *Orthopedics*. 29, No.5 (May); pp396, 398.
- Rosenberg T, Brown G. (1997). Anterior cruciate liagement reconstruction with a quadrupled semitendinosus autograft. *Sports Med Arthrosc Rev*, 1, pp243-258
- Rue JP, Ghodadra N, Bach BR Jr. (2008). Femoral tunnel placement in single-bundle anterior cruciate ligament reconstruction: A cadaveric study relating transtibial lateralized femoral tunnel position to the anteromedial and posterolateral femoral origins of the anterior cruciate ligament. *Am J Sports Med*, 36 pp 73-79.
- Rue JP, Ghodadra N, Lewis PB, Bach BR Jr. (2008). Femoral and tibial tunnel position using a transtibial drilled anterior cruciate ligament reconstruction technique. *J Knee Surg*, 21, pp 246-249.
- Rue JPH, Ghodadra N, Bach, BR Jr. (2008). Femoral tunnel placement in single-bundle anterior cruciate ligament reconstruction: A cadaveric study relating transtibial femoral tunnel position to the anteromedial and posterolateral bundle femoral origins of the anterior cruciate ligament. *Am J Sports Med* 36, No.1 (January), pp 73-79.
- Saharsrabudhe A, Christel P, Anne F, Appleby D, Basdekis G. (2010) Postoperative evaluation of tibial footprint and tunnels characteristics after anatomic double-bundle anterior cruciate ligament reconstruction with anatomic aimers. *Knee Surg Sports Traumatol Arthrosc*. 18, No.11 (November), pp 1599-1606.
- Sbihi A, Franceschi JP, Christel P, Colombet P, Djian P, Bellier G. (2004). Comparaison biomécanique de la reconstruction du ligament croisé antérieur par greffe de tendons de la patte d'oie à un ou deux faisceaux. Une étude cadavérique. *Rev Chir Orthop*, 90, pp 643-650.
- Serrano-Fernandez JM, Espejo-Baena A, Martin-Castilla B, De La Torre-Solis F, Mariscal-Lara J, Merino-Ruiz ML. (2010). Augmentation technique for partial ACL ruptures using semitendinosus tendon in the over-the-top position. *Knee Surg Sports Traumatol Arthrosc*, 18, No.9 (September), pp1214-1218
- Shelton WR, Fagan BC. (2011). Autografts commonly used on anterior cruciate ligament reconstruction. *J Am Acad Othop Surg*, 19, No.5 (May), pp 259-264.
- Siebold R, Dehler C, Ellert T. (2008). Prospective randomized comparison of double-bundle versus single-bundle anterior cruciate ligament reconstruction. *Arthroscopy*, 24, No.2 (February), pp 137-45

- Sommer C, Friederich NF, Muller W. (2000). Improperly placed anterior cruciate ligament grafts: correlation between radiological parameters and clinical results. *Knee Surg Sports Traumatol Arthrosc*, 8, pp 207-213
- Stäubli HU, Rauschnig W. (1994). Tibial attachment area of the anterior cruciate ligament in the extended knee position. Anatomy and cryosections in vivo complemented by magnetic resonance arthrography. *Knee Surg Sports Traumatol Arthrosc*, 2, pp 138-146.
- Scopp JM, Jasper LE, Belkoff SM, Moorman CT III. (2004). The effect of oblique femoral tunnel placement on rotational constraint of the knee reconstructed using patellar tendon autografts. *Arthroscopy*, 20, pp 294-299.
- Shino K, Nakata K, Nakamura N, Toritsuka Y, Horibe S, Nakagawa S, Suzuki T. (2008). Rectangular tunnel double-bundle anterior cruciate ligament reconstruction with bone-patellar tendon-bone graft to mimic natural fiber arrangement. *Arthroscopy*, 24, No.10 (October), pp 1178-1183.
- Silva A, Sampaio R, Pinto E. (2010). Placement of femoral tunnel between the AM and PL bundles using a transtibial technique in single-bundle ACL reconstruction. *Knee Surg Sports Traumatol Arthrosc*, 18, No.12 (December), pp 1245-1251.
- Sohn DH, Garrett WE Jr. (2009). Transitioning to anatomic anterior cruciate ligament graft placement. *J Knee Surg*, 22, No.2 (April), pp155-160
- Steiner M. (2009). Anatomic single-bundle ACL reconstruction. *Sports Med Arthrosc*, 17, No.4 (December), pp:247-251.
- Streich NA, Friedrich K, Gotterbarm T, Schmitt H. (2008). Reconstruction of the ACL with a semitendinosus tendon graft: a prospective randomized single-blinded comparison of double-bundle versus single-bundle technique in male athletes. *Knee Surg Sports Traumatol Arthrosc*, 16, No.3 (March), pp 232-238
- Song EK, Oh LS, Gill TJ, Li G, Gadikota HR, Seon JK. (2009). Prospective comparative study of anterior cruciate ligament reconstruction using the double-bundle and single-bundle techniques. *Am J Sports Med*, 37, pp 1705-1711.
- Takahashi M, Doi M, Abe M, Suzuki D, Nagano A (2006) Anatomical study of the femoral and tibial insertions of the anteromedial and posterolateral bundles of human anterior cruciate ligament. *Am J Sports Med*, 34, pp787-792
- van Eck C, Lesniak bP, Schreiber VM, Fu F. (2010). Anatomic single- and double-bundle anterior cruciate ligament reconstruction flowchart. *Arthroscopy*, 26, No.2 (February), pp 258-268.
- van Eck C, Working Z, Fu F. (2011). Current concepts in anatomic single- and double-bundle anterior cruciate ligament reconstruction. *Phys Sportsmed*. 39, No.2 (May), pp 140-148.
- Wilson TC, Kantaras A, Atay A, Johnson DL. (2004). Tunnel enlargement after anterior cruciate Ligament surgery. *Am J Sports Med*, 32, No.2, pp 543-549.
- Yagi M, Wong EK, Kanamori A, Debski RE, Fu FH, Woo SL. (2002). Biomechanical analysis of an anatomic anterior cruciate ligament reconstruction. *Am J Sports Med*, 30, pp 660-666.
- Yagi M, Kuroda R, Nagamune K, Yoshiya S, Kurosaka M. (2007). Double bundle ACL reconstruction can improve rotational stability. *Clin Orthop Relat Res*, 454, pp100-107.

- Yamamoto Y, Hsu WH, Woo SL, Van Scyoc AH, Takakura Y, Debski RE. (2004). Knee stability and graft function after anterior cruciate ligament reconstruction: A comparison of a lateral and an anatomical femoral tunnel placement. *Am J Sports Med*, 32, pp 1825-1832.
- Yasuda K, Kondo E, Ichiyama H, et al. (2004). Anatomic reconstruction of the anteromedial and posterolateral bundles of the anterior cruciate ligament using hamstring tendon grafts. *Arthroscopy*, 20, pp 1015-1025.
- Yasuda K, Kondo E, Ichiyama H, Tanabe Y, Tohyama H. (2006). Clinical evaluation of anatomic double-bundle anterior cruciate ligament reconstruction procedure using hamstring tendon grafts: comparisons among 3 different procedures. *Arthroscopy*, 22, pp 240-251.
- Yunes M, Richmond JC, Engels EA, Pinczewski LA (2001) Patellar versus hamstring tendons in anterior cruciate ligament reconstruction: a meta-analysis. *Arthroscopy*, 17, pp248-257.
- Zaffagnini S, Bruni D, Martelli S, Imakiire N, Marcacci M, Russo A (2008) Double-bundle ACL reconstruction: influence of femoral tunnel orientation in knee laxity analysed with a navigationssystem—an in vitro biomechanical study. *BMC Musculoskeletal Disord*, 9, pp 25-
- Zantop T, Petersen W, Sekiya JK, Musahl V, Fu FH (2006) Anterior cruciate ligament anatomy and function relating to anatomical reconstruction. *Knee Surg Sports Traumatol Arthrosc*, 14, pp982-992
- Zantop T, Herbort M, Raschke MJ, Fu FH, Petersen W (2007) The role of the anteromedial and posterolateral bundles of the anterior cruciate ligament in anterior tibial translation and internal rotation. *Am J Sports Med*, 35, pp 223-227.
- Zantop T, Haase AK, Fu FH, Petersen W. (2008). Potential risk of cartilage damage in double bundle ACL reconstruction: impact of knee flexion angle and portal location on the femoral PL bundle tunnel. *Arch Orthop Trauma Surg*, 128, pp 509-513.
- Zantop T, Diermann N, Schumacher T, Schanz S, Fu FH, Petersen W. (2008). Anatomical and nonanatomical double-bundle anterior cruciate ligament reconstruction: importance of femoral tunnel location on knee kinematics. *Am J Sports Med*, 36, pp 678-685.

IntechOpen



Modern Arthroscopy

Edited by Dr Jason L. Dragoo

ISBN 978-953-307-771-0

Hard cover, 302 pages

Publisher InTech

Published online 09, December, 2011

Published in print edition December, 2011

Modern Arthroscopy will assist practitioners to stay current in the rapidly changing field of arthroscopic surgery. The chapters in this book were written by a panel of international experts in the various disciplines of arthroscopy. The goals of this text are to present the classical techniques and teachings in the fields of Orthopaedics and Dentistry, but also to include new, cutting-edge applications of arthroscopy, such as temporomandibular arthroscopy and extra-articular arthroscopy of the knee, just to name a few. We hope Modern Arthroscopy becomes a core reference for your arthroscopic surgery practice.

How to reference

In order to correctly reference this scholarly work, feel free to copy and paste the following:

P. Christel and W. Boueri (2011). Contemporary Anterior Cruciate Ligament Reconstruction, Modern Arthroscopy, Dr Jason L. Dragoo (Ed.), ISBN: 978-953-307-771-0, InTech, Available from: <http://www.intechopen.com/books/modern-arthroscopy/contemporary-anterior-cruciate-ligament-reconstruction>

INTECH
open science | open minds

InTech Europe

University Campus STeP Ri
Slavka Krautzeka 83/A
51000 Rijeka, Croatia
Phone: +385 (51) 770 447
Fax: +385 (51) 686 166
www.intechopen.com

InTech China

Unit 405, Office Block, Hotel Equatorial Shanghai
No.65, Yan An Road (West), Shanghai, 200040, China
中国上海市延安西路65号上海国际贵都大饭店办公楼405单元
Phone: +86-21-62489820
Fax: +86-21-62489821

© 2011 The Author(s). Licensee IntechOpen. This is an open access article distributed under the terms of the [Creative Commons Attribution 3.0 License](#), which permits unrestricted use, distribution, and reproduction in any medium, provided the original work is properly cited.

IntechOpen

IntechOpen