

# We are IntechOpen, the world's leading publisher of Open Access books Built by scientists, for scientists

## 4,800

Open access books available

## 122,000

International authors and editors

## 135M

Downloads

Our authors are among the

## 154

Countries delivered to

## TOP 1%

most cited scientists

## 12.2%

Contributors from top 500 universities

**WEB OF SCIENCE™**Selection of our books indexed in the Book Citation Index  
in Web of Science™ Core Collection (BKCI)

Interested in publishing with us?  
Contact [book.department@intechopen.com](mailto:book.department@intechopen.com)

Numbers displayed above are based on latest data collected.  
For more information visit [www.intechopen.com](http://www.intechopen.com)



# Abnormal Brain Density in Victims of Rape with PTSD in Mainland China: A Voxel-Based Analysis of Magnetic Resonance Imaging Study

Shuang Ge Sui<sup>1</sup>, Ling Jiang Li<sup>1</sup>, Yan Zhang<sup>1</sup>,  
Ming Xiang Wu<sup>2</sup> and Mark E. King<sup>3</sup>

<sup>1</sup>*Mental Health Institute, Second Xiangya Hospital, Central-South University*

<sup>2</sup>*ShenZhen People's Hospital*

<sup>3</sup>*Faculty of Education, The University of Hong Kong, HKSAR  
P. R. China*

## 1. Introduction

Posttraumatic stress disorder (PTSD) is a relatively common and predictable psychological syndrome (Miller, 1999). PTSD occurs in a proportion of individuals exposed to severe psychological trauma (Kasai et al., 2006) and in which the individual responds with fear, helplessness, or horror (Danckwerts & Leathem, 2003). Individuals with PTSD suffer from intrusive memories about the traumatic event, persistent avoidance of stimuli associated with the trauma, and persistent symptoms of increased arousal. These symptoms become uncontrollable and disabling (Bremner & Charney, 1994) that seriously threaten human health and social function. Due to its debilitating nature, PTSD has emerged as an important public health problem in the general population (Sareen et al., 2007).

In recent years, a great deal of research has been directed towards understanding the etiology, phenomenology, neurobiology, clinical characteristics and treatment of PTSD (Nemeroff et al., 2006). However, a number of core psychological processes underlying PTSD have yet to be elucidated (Shin et al., 2006; Liberzon & Sripada, 2008). Over the past decade, findings from neuroimaging studies have allowed for tremendous advances in our understanding of the experience of emotions in healthy individuals and the dysregulation of these processes associated with PTSD. These studies have been useful in both generating hypotheses on the neurobiology of normative human responses to trauma and complementing our understanding of the wide-ranging alterations in trauma survivors who develop PTSD.

Structural neuroimaging studies have focused primarily on hippocampal volumetry (Geuze et al., 2005) as well as the prefrontal cortex (Geuze et al., 2008a) and other brain structures. Hippocampal morphology has been correlated with severity of PTSD symptomatology (Gilbertson et al., 2002; Villarreal & King, 2004). However, the results have been inconsistent, with studies reporting significant reductions or increases, as well as unchanged volumes. For example, studies have shown that patients with PTSD are associated with bilateral lower hippocampal volume (Bossini & Castrogiovanni, 2007; Bremner et al., 2003; Emdad et al., 2006; Lindauer et al., 2004a; Vythilingam et al., 2005; Li et al., 2006), which are

considered to be either due to atrophy of the hippocampus as a consequence of suffering from PTSD due to excessive stress (Bremner et al., 1995; Gurvits et al., 1996) or that hippocampal volume to be a risk factor for developing PTSD (Gilbertson et al., 2002). Other studies report unchanged hippocampal volumes in female patients with chronic PTSD traumatized by intimate partner violence (Fennema-Notestine et al., 2002), those traumatized by witnessing a plane crash at the same air show (Jatzko et al., 2006a), elderly PTSD patients (Golier et al., 2006), and adult burn patients (Winter & Irle, 2004). Opposite trends in abused juveniles were found in other studies. (Tupler & De Bellis, 2006). A recent meta-analysis, however, confirmed the presence of significantly smaller hippocampal and left amygdala volumes in patients with PTSD compared to controls with and without trauma exposure (Karl et al., 2006). The findings of previous studies suggest that abnormal hippocampal volume was not a necessary and sufficient condition of PTSD.

Several studies have shown that the medial prefrontal cortex, which includes the anterior cingulate cortex and medial frontal cortex, are involved in the process of extinction of fear conditioning and the retention of extinction (Milad et al., 2006). Research on abnormalities in the prefrontal cortex in PTSD patients suggested decreased volume (Fennema-Notestine et al., 2002; Carrion et al., 2001; Richert et al., 2006; Hakamata et al., 2007), while some findings suggested increased volume of the middle-inferior and ventral regions of the prefrontal cortex (Richert et al., 2006).

The cerebellum has been considered only as a classical subcortical center for motor control (Botez, 1993). Botez et al. found that the patients with bilateral cerebellar damage showed deficits in the non-motor and behavioural functions including execution, attention, learning, and cognition (Botez, 1993; Ciesielski & Knight, 1994; Gao et al., 1996). Gao et al. found that the lateral cerebellar output (dentate) nucleus is not activated by the control of movement per se, but is strongly engaged during passive and active sensory tasks (Gao et al., 1996). Recent research of the cerebellum's contribution to cognitive processing and emotional processing have increased enormously, showing that the cerebellum is responsible for sensory perception, learning, memory, attention, linguistic, emotional control and conflict resolution processing (Mandolesi et al., 2001; Bischoff-Grethe et al., 2002; Vokaer et al., 2002; Claeys et al., 2003; Guenther et al., 2005; Allen et al., 2005; Konarski et al., 2005; Schmahmann & Caplan, 2006; Gianaros et al., 2007; Schweizer et al., 2007).

Anatomical studies revealed that via the thalamus, the cerebellum interacts with multiple areas of the prefrontal cortex and subcortex limbic lobe (Middleton & Strick, 2001; Zhu et al., 2006). The cerebellum influences several areas of the prefrontal cortex via the thalamus (Middleton & Strick, 2001). Gold and Buckner found a region in the right lateral cerebellum which exhibited a pattern similar to the left inferior frontal gyrus during semantic decisions on words and phonological decisions on pseudowords (Gold & Buckner, 2002). Patients with degenerative cerebellar diseases show high rates of cognitive impairment or psychiatric symptoms (Leroi et al., 2002; Liszewski et al., 2004), and neuroimaging studies have found that mood disorders were activated in the cerebellum (Liotti et al., 2000; Phan et al., 2002). The study by Gianaros et al. found that healthy individuals show heightened stressor-induced neural activation in the cingulate cortex, bilateral prefrontal cortex, and cerebellum while performing a standardized Stroop color-word interference task (Gianaros et al., 2007); however, studies of the cerebellum in PTSD patients have been very limited. In two positron emission tomography (PET) studies, abnormal activities in the cerebellum of PTSD subjects were found, including higher regional cerebral blood flow (Bonne et al., 2003) and augmented glucose absorption activity (Molina et al., 2010). Bellis et al. found that the

left, right, and total cerebellum were smaller in maltreated children and adolescents with PTSD. They also found that cerebellar volume was positively correlated with the age of onset of the trauma that led to PTSD and negatively correlated with the duration of the trauma (Bellis & Kuchibhatla, 2006). Even with these findings, no precise results were found in cerebellum sub-areas.

In addition to findings related to the hippocampus and medial prefrontal cortex, many current functional neuroimaging studies have identified that other brain areas such as the prefrontal cortex, temporal lobe, parietal lobe, limbic lobe and cerebellum may also be implicated in PTSD (Bonne et al., 2003; Lanius et al., 2005; Molina et al., 2010; Bremner, 2006, Bremner et al., 2008; Geuze et al., 2008b). Brain functional imaging studies from patients with PTSD showing increased amygdala function and decreased medial prefrontal/anterior cingulate function during fear acquisition are hypothesized to represent a neural correlate of the failure of extinction seen in PTSD (Bremner, 2006, Bremner et al., 2008). A functional magnetic resonance imaging study comparing veterans with and without PTSD reveals that those with PTSD had overactivation of the temporal gyrus during the encoding phase, and underactivation of the bilateral middle temporal gyrus in the retrieval phase (Geuze et al., 2008b). Another functional magnetic resonance imaging study comparing PTSD patients and control subjects' connectivity maps in the left ventrolateral thalamus reveals that PTSD subjects had higher covariations between activations in the left ventrolateral thalamus and in the right insula, left parietal lobe, right middle frontal gyrus, and superior temporal gyrus (Lanius et al., 2005). Fluorodeoxyglucose positron emission tomography (FDG-PET) researches also indicate relatively diminished activity in the limbic, frontal and prefrontal cortex; relatively augmented activity in the fusiform cortex and in the cerebellum in patients with PTSD (Bonne et al., 2003; Molina et al., 2010). The findings of functional neuroimaging studies suggest that there are more brain areas that may be affected in PTSD, but only a few studies have found corresponding structural abnormalities in these brain areas. In contrast to the considerable research on subcortical structure volumetry, few studies to date have been directed to gray matter reductions in the cortex. It is evident that structural neuroimaging studies will allow for the testing of hypotheses of an association between PTSD and abnormal gray matter. Although volumetry findings reveal changes in the volume of specific brain regions, most of these studies defined particular regions-of-interests (ROIs) and measured their size and hemispheric asymmetry using traditional morphometric techniques with high-resolution magnetic resonance images (MRI). The disadvantage of this method is that some important brain areas may be neglected, and the process of drawing ROIs may introduce additional errors. Furthermore, the measurement of volume may not accurately reflect changes in the internal structure of the brain. In recent years, a fully automated voxel-based morphometry (VBM) technique has allowed for the examination of cerebral asymmetries across the entire brain directly (Corbo et al., 2005; Kasai et al., 2008; Luders et al., 2004), which can compensate for the subjectivity of ROI approaches. The VBM technique has been used for assessing regional gray matter density (GMD) (per unit volume in native space) in PTSD patients and revealed abnormal GMD in the hippocampus, anterior cingulate cortex, and insula (Emdad et al., 2006; Jatzko et al., 2006a; Richert et al., 2006; Kasai et al., 2008; Luders et al., 2004).

Most previous PTSD studies in the West focused on the disorder caused by various traumatic events, such as war (Vythilingam et al., 2005; Bremner et al., 1995; Pavic et al., 2007), disaster (Jatzko et al., 2006a, b; Abe et al., 2006; Li et al., 2006; Yamasue et al., 2003), and sexual abuse (Bremner et al., 2003; Tupler&De Bellis, 2006). Although considerable research has focused on rape-related PTSD, limited studies have been carried out in the

context of Mainland China. In this study, rape was defined as an event that occurred without the victim's consent that involved the use or threat of force to penetrate the victim's vagina or anus by penis, tongue, fingers, or object, or the victim's mouth by penis (Tjaden & Thoennes, 2000). Interestingly, evidence indicates that the incidence rate of PTSD induced by rape is the highest among all kinds of trauma (Rothbaum et al., 1992).

In the current study, we employed VBM to explore differences in GMD between victims of rape (VoR) with and without PTSD, as well as in healthy comparison (HC) subjects. Based on findings from previous neuroimaging studies (Milad et al., 2006; Carrion et al., 2001; Richert et al., 2006; Hakamata et al., 2007; Bonne et al., 2003; Lanius et al., 2005; Molina et al., 2010; Bremner et al., 2006, 2008; Geuze et al., 2008b), we hypothesized that VoR with PTSD would show structural changes in extensive brain areas, including the prefrontal, temporal, parietal and limbic regions, compared to VOR without PTSD and to HC.

## 2. Material and methods

### 2.1 Subjects

We conducted a cross-sectional study on VoR and HC in Guangdong Province, People's Republic of China. Subjects living and working in Guangdong who met the criteria of being female, at least 18 years old, right-handed, with an educational attainment above secondary school level were included. Exclusion criteria for VoR and HC were a history of neurological or brain trauma and alcohol or drug use/abuse. Additional exclusion criteria for VoR included a previous or current psychiatric diagnosis other than PTSD, and for HC included any previous or current DSM-IV psychiatric disorder. The Ethics Committee of the Second Xiangya Hospital, Central South University, the People's Republic of China approved the study protocol. Written informed consent was obtained from all subjects in the study. The sample size for this study was projected based on previous research (Lindauer et al., 2004a; Fennema-Notestine et al., 2002; Jatzko et al., 2006a; Abe et al., 2006) where sample sizes ranging from eight to twenty were reported.

**VoR subjects:** VoR subjects were recruited in two stages. In the first stage, 53 potential subjects were recruited from (a) four public psychological consulting clinics; (b) referred to the clinics by a non-government organization (NGO) specializing in assisting victims of sexual assault; and (c) through advertisements in local newspapers requesting VoR for brain imaging studies. As an incentive for participation, six months free psychological counseling and medical therapy were offered. In the second stage, psychiatrists in the four consulting clinics explained the study to the 53 potential subjects and requested consent to participate in this study. As a result, 23 VoR met the inclusion/exclusion criteria and gave written informed consent.

**Healthy Comparison (HC) Subjects:** The HC subjects for this study were also recruited through a two-stage process. First, after obtaining the major demographic characteristics (i.e. gender, race, age, height, weight, and educational years) of VoR, we published notices across the province to recruit female health workers with similar demographic characteristics. A total of 65 volunteers agreed to participate and were screened according to inclusion/exclusion criteria. The health status of the HC was determined based on health check reports, as well as an illness history interview conducted by a doctor and a psychiatrist. In the second stage, the exact number of HC was recruited to best match the major demographic characteristics of each case of VoR with PTSD.

In this study, all subjects were measured with the Trauma History Questionnaire (THQ) (Green et al., 1996) and the Posttraumatic Stress Disorder Checklist Civilian Version (PCL-C)

(Ruggiero et al., 2003). In addition, two independent, clinically experienced psychiatrists interviewed VoR subjects using the Clinician-Administered PTSD Scale (CAPS) (Blake et al., 1995). The PCL-C was used to predict PTSD diagnoses, and the CAPS was used to differentiate PTSD and non-PTSD VoR subgroups. A senior psychiatrist confirmed the final diagnosis of PTSD.

## 2.2 MRI data acquisition

Images were obtained from using a research-dedicated Siemens Avanto 1.5 Tesla MRI scanner. The T1-weighted anatomical images were acquired using a three-dimensional gradient-echo sequence, with TR=11 msec, TE=4.94 msec, number of averages=1, matrix=256×224 pixels, field of view=256mm×224mm, with a flip angle of 15°. 176 sagittal slices with a 1 mm slice thickness were acquired with no interslice gap. There was a voxel resolution of 1×1×1mm<sup>3</sup>. The total acquisition time was 5 minutes and 34 seconds.

## 2.3 MRI data analysis

Voxel-based morphometry was implemented by using the Statistical Parametric Mapping software (SPM2) (Wellcome Department of Imaging Neuroscience, London, England; www.fil.ion.ucl.ac.uk) (Friston et al., 1995). First, images were spatially normalized to the Montreal Neurological Institute (MNI) space with the standard T<sub>1</sub>-MRI template (Mazziotta et al., 1995) implemented in the SPM2 program, and re-sliced into a final voxel size of 1×1×1mm<sup>3</sup> using tri-linear interpolation. The spatially normalized images were then segmented into three compartments: gray matter, white matter and cerebrospinal fluid. Furthermore, a Jacobian determinant was not introduced to modulate the resulting gray matter images so the voxel's values indicate the absolute density of the local gray matter. Finally, the segmented gray matter images from VoR with PTSD, VoR without PTSD, and HC were smoothed with a 12-mm full-width at half-maximum isotropic Gaussian kernel (Ashburner & Friston, 2000). The result of between-groups comparisons of gray matter images were performed in the general linear model.

Because we are particularly interested in exploring increases/decreases in GMD in VoR with PTSD compared to VoR without PTSD and HC, two-sample t-tests were performed in the VBM analysis in a voxel-by-voxel manner. Consistent with previous studies (Liberzon et al., 2007; Hou et al., 2007), the significance threshold was set to  $p < 0.005$  corrected for multiple comparisons with a minimal cluster size of >50 voxels. The significant regions were superimposed onto SPM2's standard T<sub>1</sub>-weighted brain images. Based on previous research (Milad et al., 2006; Carrion et al., 2001; Richert et al., 2006; Hakamata et al., 2007; Bonne et al., 2003; Lanius et al., 2005; Molina et al., 2010; Bremner et al., 2006, 2008; Geuze et al., 2008b), we hypothesized that compared with HC, VoR with PTSD would show gray matter abnormalities in the prefrontal, temporal, parietal and limbic regions. We used the small volume correction (SVC) tool in the SPM2 package with the specific purpose of restricting comparisons to specific voxels located in these regions. This approach permits the implementation of hypothesis-driven analyses with corrections for the pre-specified ROIs rather than corrections for the whole brain.

## 3. Results

Following the initial interview, among the 23 VoR subjects, 13 met the DSM-IV diagnostic criteria for current PTSD and 10 VoR did not meet the criteria for PTSD. Based on the study

protocol, 13 HC were recruited to match VoR with PTSD. All subjects were scanned with an MRI, however, due to too many head movements during MRI scanning, a total of five subjects (2 PTSD, 2 non-PTSD, and 1 HC) were removed. As a result, the final sample consisted of 11 VoR with PTSD (ages 18-31), 8 VoR without PTSD (ages 23-33), and 12 HC (ages 22-33).

The three groups did not differ significantly on major demographics (i.e., age, height, weight, and educational years). In addition, the average interval between rape trauma and data acquisition did not differ significantly between VoR with and VoR without PTSD. Even so, VoR with PTSD scored significantly higher on PTSD symptomatology ( $P < 0.001$ ) compared to VoR without PTSD and HC. None of the participants in this study received medication prior to neuroimaging acquisition. The results are summarized in Table 1.

	VoR (n=19)		Healthy Comparison (n=12)	F	t	p
	PTSD(n=11)	Non-PTSD(n=8)				
<b>Age (years)</b>						
Mean	25.55	27.50	26.42	.614	-	.55
SD	4.01	4.00	3.45			
<b>Education (years)</b>						
Mean	14.73	15.63	14.83	.91	-	.41
SD	1.62	1.92	1.12			
<b>Hight (CM)</b>						
Mean	157.82	159.25	160.67	.83	-	.45
SD	5.44	5.81	4.77			
<b>Weight (KG)</b>						
Mean	49.00	51.13	50.88	0.41	-	.67
SD	4.13	6.19	6.81			
<b>Trauma event</b>	raped	raped	none	-	-	-
<b>Interval (months)</b>						
Mean	45.45	53.50	-	-	-.31	.76
SD	55.68	55.54	-			
<b>PCL-C score</b>						
Mean	60.36	34.63	22.58	60.32	-	.000
SD	8.39	8.96	7.89			
<b>CAPS score</b>						
Mean	74.45	15.88	-	-	14.70	.000
SD	8.30	8.95	-			

VoR, Victims of Rape; PTSD, post-traumatic stress disorder; SD, standard deviation; CM, centimeter; KG, kilogram; Interval, time between raped trauma occurrence and scan; PCL-C, Post-traumatic Stress Disorder Checklist Civilian Version; CAPS, Clinician-Administered PTSD Scale.

Table 1. Demographic and clinical characteristics of VoR with and without PTSD and Healthy Comparison

### 3.1 Differences in GMD between VoR with PTSD and HC

The areas found to have abnormal GMD in VoR with PTSD compared to HC are shown in Figure 1. The cortical areas with decreased GMD in VoR with PTSD compared to HC are listed in Part A of Figure 1. These areas include the left medial frontal cortex (A-1), right medial frontal cortex (A-2), the left middle frontal cortex (A-3), the left middle temporal gyrus (A-4), and the left fusiform cortex (A-5). The areas with increased GMD are listed in Part B of Figure 1, and include the right posterior cingulate cortex (B-1), the left pre-central cortex (B-2), right pre-central cortex (B-3), the left inferior parietal lobule (B-4), right inferior parietal lobule (B-5), and the right post-central cortex (B-6). The MNI coordinates, voxel t values, k values (cluster size > 50), and corresponding Brodmann Areas (BA) are detailed in Table 2. Regions displayed are for  $p < .005$ .

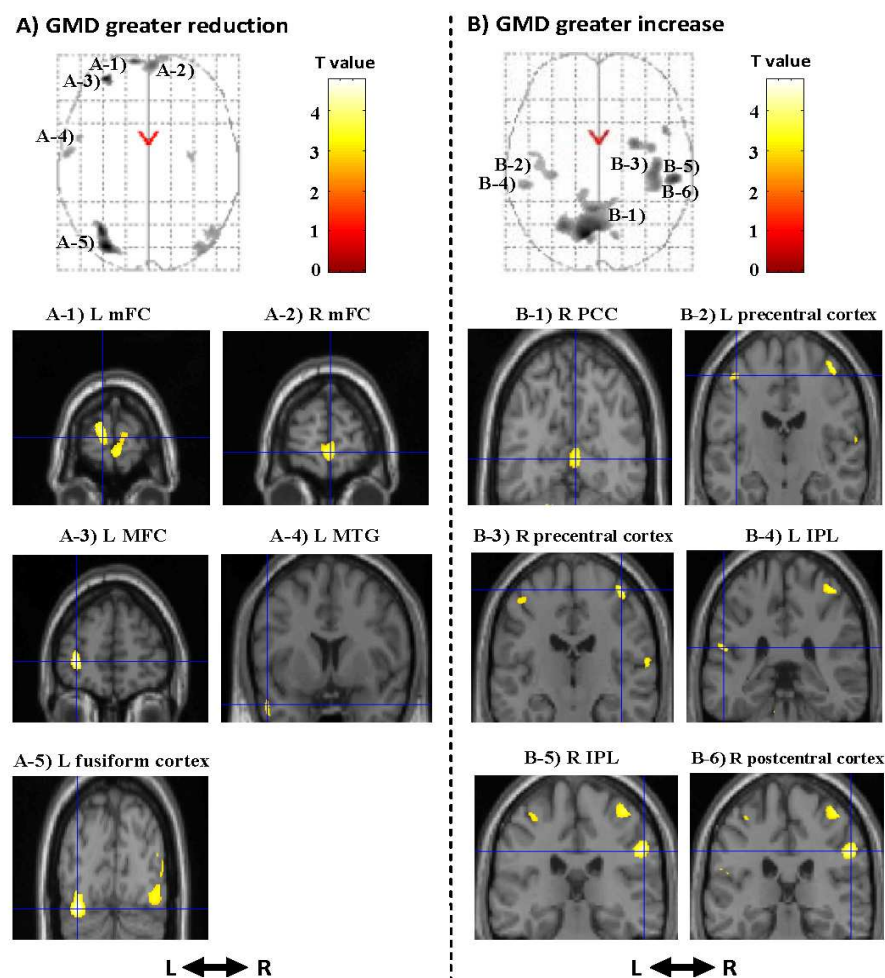


Fig. 1. Brain regions showing abnormalities in GMD in VoR with PTSD versus Healthy Comparison

Part A shows the cortical areas with decreased gray-matter density (GMD) in Victims of Rape with post-traumatic stress disorder compared to Healthy Comparison. Part B shows the areas with increased GMD.

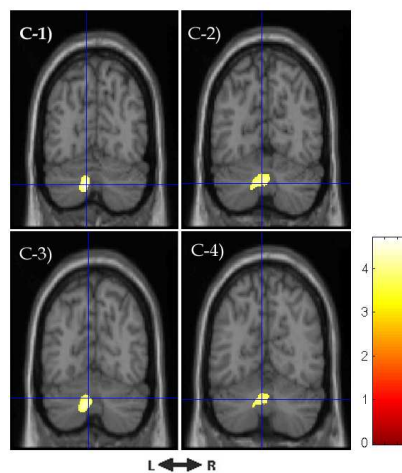
L: left; R: right; mFC: medial prefrontal cortex; MFC: middle frontal cortex; MTG: middle temporal gyrus; PCC: posterior cingulate cortex; IPL: inferior parietal lobule.



k	Voxel t value	MNI coordinates (x, y, z)	Region	Brodmann Area	p
Greater reduction					
143	3.85	-968 11	Left medial frontal cortex	10	0.001
318	3.73	4 64 -4	Right medial frontal cortex	10	0.001
398	4.67	-31 54 2	Left middle frontal cortex	10	0.000
51	3.11	-51 7 -26	Left middle temporal gyrus	21	0.003
718	4.75	-31 -82 -18	Left fusiform cortex	19,20	0.000
Greater increase					
449	3.57	4 -64 7	Right posterior cingulate	30,23	0.001
240	3.02	-41 -16 55	Left pre-central cortex	4	0.003
343	3.77	42 -18 62	Right pre-central cortex	4,6	0.001
64	3.34	-53 -34 21	Left inferior parietal lobule	40	0.002
211	3.77	57 -27 33	Right inferior parietal lobule	40	0.001
412	4.17	55 -28 35	Right post-central cortex	2,3	0.000

PTSD, Post-traumatic Stress Disorder; k, cluster size; Regions displayed are for  $p < .005$ ,  $k > 50$ .

Table 2. Gray-matter density in Victims of Rape with PTSD versus Healthy Comparison



L: left; R: right; (C-1) Pyramis ( $x = -9$ ,  $y = -72$ ,  $z = -36$ ;  $k = 519$ ,  $t = 4.70$ ); (C-2) uvula ( $x = -4$ ,  $y = -66$ ,  $z = -35$ ;  $k = 256$ ,  $t = 4.02$ ); (C-3) declive ( $x = -6$ ,  $y = -69$ ,  $z = -30$ ;  $k = 213$ ,  $t = 3.84$ ); and (C-4) nodule ( $x = -4$ ,  $y = -63$ ,  $z = -31$ ;  $k = 147$ ,  $t = 3.93$ ); Coordinates presented are in Montreal Neurological Institute space.

Fig. 2. Significantly increased cerebellum density in VoR with PTSD versus Healthy Comparison

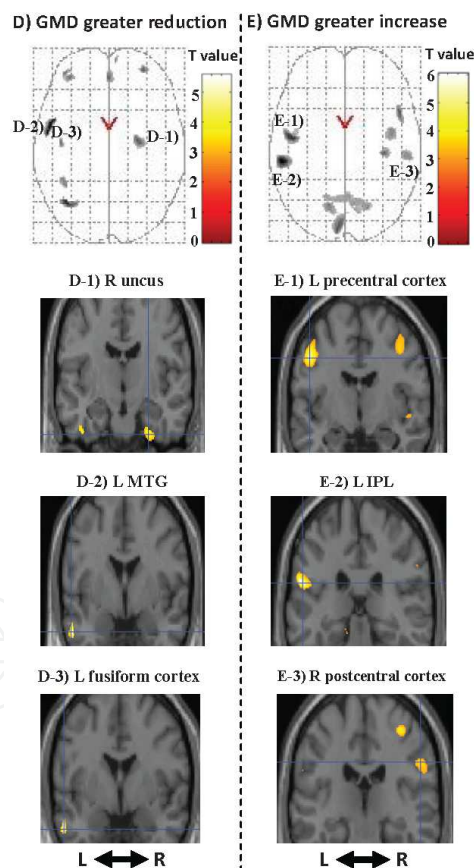
The PTSD Group showed increased cerebellum density compared with controls in the left side, specifically in the pyramis, uvula, declive, and nodule (see Figure 2).

### 3.2 Differences in GMD between VoR with and without PTSD

The areas found to have abnormal GMD in VoR with PTSD compared to the VoR without PTSD are shown in Figure 3. The cortical areas with decreased GMD are listed in Part C of Figure 3. These areas include the right uncus (D-1), the left middle temporal gyrus (D-2), and the left fusiform cortex (D-3). The areas with increased GMD are listed in Part D of

k	Voxel t value	MNI coordinates (x, y, z)	Region	Brodmann Area	p
Greater reduction					
173	4.23	27 -10 -35	Right uncus	20,28	0.000
314	5.56	-55 -1 -26	Left middle temporal gyrus	21	0.000
53	5.23	-54 -1 -27	Left fusiform cortex		20 0.000
Greater increase					
993	5.31	-48 -8 39	Left pre-central cortex		6,4 0.000
607	6.03	-55 -29 21	Left inferior parietal lobule	40	0.001
270	3.79	54 -23 33	Right post-central cortex		2 0.000

Table 3. Gray-matter density in VoR with PTSD versus VoR without PTSDVoR, Victims of Rape; PTSD, post-traumatic stress disorder; *k*, cluster size; Regions displayed are for  $p < .005, k > 50$ .



Part C shows the cortical areas with decreased gray-matter density (GMD) in Victims of Rape (VoR) with post-traumatic stress disorder (PTSD) compared to VoR without PTSD. Part D shows the areas with increased GMD.

L: left; R: right; MTG: middle temporal gyrus; IPL: inferior parietal lobule.

Fig. 3. Brain regions showing abnormalities in GMD in VoR with PTSD versus VoR without PTSD

Figure 2, and include the left pre-central cortex (E-1), the left inferior parietal lobule (E-2), and the right post-central cortex (E-3). The MNI coordinates, voxel *t* values, *k* values (cluster size > 50), and corresponding BA are detailed in Table 3. Regions displayed are for  $p < .005$ .

## 4. Discussion

This cross-sectional study employed VBM to examine brain density abnormalities among VoR with PTSD compared to VoR without PTSD and HC in mainland China. The findings of this study support the hypothesis that changes in brain density are associated with the pathophysiology of rape-induced PTSD.

### 4.1 The frontal cortex

The structural abnormalities in the medial and middle frontal cortex found in VoR with PTSD are supported by previous studies (Shin et al., 2006; Fennema-Notestine et al., 2002; Richert et al., 2006; Hakamata et al., 2007). In addition to such structural findings, functional neuroimaging studies have also shown dysfunction in these cortical areas (Bremner et al., 1999a, 2003; Lanius et al., 2004, 2006; Lindauer et al., 2004b, 2008; Morey et al., 2008). It is therefore possible that altered GMD in the medial and middle frontal cortex may contribute to their hypofunction. However, in the current study, VoR with PTSD had GMD reductions in the left middle frontal cortex and the bilateral medial frontal cortex relative to the HC, but no significant differences relative to VoR without PTSD. This result suggests that severe psychological trauma may change brain gray matter of the medial and middle frontal cortex, but that such plastic changes to these cortical brain structures may not underlie the pathophysiology of PTSD.

Compared to VoR without PTSD and HC, VoR with PTSD had significant bilateral increases in GMD of the pre-central gyrus, which mainly consists of the premotor cortex and the supplementary motor area. Studies indicate the importance of the supplementary motor area in motor tasks that demand retrieval of motor memory (Tanji, 1994). The premotor cortex, located in the pre-central cortex (BA6), seems to play a major role in language (Duffau et al., 2003). Functional neuroimaging studies on PTSD suggest abnormal functional activities in this cortical area. Empirical studies have shown that PTSD groups are characterized by relatively more activation in the pre-central cortex than non-PTSD and healthy comparisons (Bonne et al., 2003; Bremner et al., 1999a; Lanius et al., 2006; Shaw et al., 2002; Jatzko et al., 2006b). These findings suggest that increases in GMD of the pre-central cortex may be involved in the neural basis of motor and linguistic PTSD symptomatology.

### 4.2 The parietal lobule

The parietal lobule, including the superior and inferior parietal lobule (BA7, BA40) is implicated in memory, recognition, and deductive reasoning (Xie et al., 2004; Knauff et al., 2002). In this study, compared to VoR without PTSD and HC, VoR with PTSD had significant increases in GMD of the inferior parietal lobule. This indicates that the inferior parietal lobule might play an important role in the pathophysiology of PTSD. Additionally, one PET study showed that chronic PTSD patients presented relatively diminished activity in the post-central regions (Molina et al., 2010), which mainly consist of the primary somatic sensory cortex and secondary somatic sensory cortex (Geng et al., 2006). Increases in GMD in the post-central cortex may be associated with the dysfunction related with PTSD.

### 4.3 The temporal gyrus

Our study showed significant GMD decreases in the left middle temporal gyrus in VoR with PTSD compared to HC. Studies comparing veterans with and without PTSD reveals that those with PTSD had overactivation of the temporal gyrus during the resting state (Molina et al., 2010) and the encoding phase (Geuze et al., 2008b), and underactivation of the bilateral middle temporal gyrus in the retrieval phase (Geuze et al., 2008b). Functional neuroimaging studies reveals significant activation in left middle temporal gyrus in response to empathy judgments in post-therapy PTSD (Farrow et al., 2005) and higher levels of activation in the middle temporal gyrus in dissociative PTSD (Lanius et al., 2006). Empirical evidence suggests that the fusiform cortex is specialized for face processing (Rossion et al., 2000; Rhodes et al., 2004). Research also indicates relatively augmented activity in the fusiform cortex in patients with PTSD (Bonne et al., 2003; Molina et al., 2010). The reduced GMD of the middle temporal gyrus and fusiform cortex found in this study implicates these regions in the dysfunction of memory and dissociative symptoms in PTSD.

### 4.4 The limbic lobe

In the present study, VoR with PTSD had significant increases in GMD in the right posterior cingulate cortex compared to HC. Meta-analyses have revealed that the prominent themes in the posterior cingulate cortex are episodic memory retrieval and pain (Nielsen et al., 2005), visuospatial processing and assessment of threat (Nemeroff et al., 2006), as well as fear conditioning (Doronbekov et al., 2005). Comparison of connectivity maps by functional connectivity analyses (Lanius et al., 2004) reveals that subjects with PTSD showed greater correlations in interregional brain activity than subjects without PTSD in the right posterior cingulate cortex (BA 29). Functional neuroimaging studies have found increased activation in the posterior cingulate cortex in victims with PTSD compared to victims without PTSD and to healthy controls (Bremner et al., 1999a, b, 2003; Doronbekov et al., 2005; Sachinvala et al., 2000). These indicate that dysfunction in the posterior cingulate cortex may underlie pathological symptoms provoked by traumatic reminders of sexual assault among VoR with PTSD.

### 4.5 The cerebellum

We found that the density of cerebellum, which plays an important role in motor and cognition (Mandolesi et al., 2001; Bischoff-Grethe et al., 2002; Vokaer et al., 2002; Claeys et al., 2003; Guenther et al., 2005; Allen et al., 2005; Konarski et al., 2005; Schmahmann & Caplan, 2006; Gianaros et al., 2007; Schweizer et al., 2007), was increased in patients with PTSD. Combination of early studies about structural abnormal (Leroi et al., 2002; Liszewski et al., 2004; Bellis & Kuchibhatla, 2006) and functional abnormal (Bonne et al., 2003; Molina et al., 2010; Gianaros et al., 2007; Liotti et al., 2000; Phan et al., 2002) in the cerebellum in PTSD patients, the finding is consistent with our hypothesis that the cerebellum was involved in the neuropathology of cognitive processing and emotional processing in PTSD patients. Furthermore, the density increased in the cerebellum while decreased in the prefrontal cortex. According to the anatomical studies that the cerebellum interacts with the prefrontal cortex via the thalamus (Middleton & Strick, 2001; Zhu et al., 2006), and the functional studies that the cerebellum influences several areas of the prefrontal cortex via the thalamus (Middleton & Strick, 2001) and exhibits a pattern similar to the frontal cortex during semantic decisions (Gold & Buckner, 2002), the findings suggest that the cerebellum

may be involved in the functional compensation for the pathological changes in the neuro-circuitry of PTSD.

Earlier studies in the cerebellum of PTSD patients found correlations with abnormal blood flow and glucose absorption (Bonne et al., 2003; Molina et al., 2010) and abnormal volume (Bellis & Kuchibhatla, 2006) in the cerebellum also. This study extends the literature on cerebellum structure involvement in PTSD. This finding, if replicated in larger patient samples, may serve as a marker of brain dysfunction in PTSD, and thus allows for the study of cerebellum pathophysiology before and throughout the course and treatment of PTSD. It should be noted that whilst the sample size (11 VoR with PTSD) of this study meets the threshold of research reported in the literature (Jatzko et al., 2006a; Hou et al., 2007), it was nevertheless limited in terms of its statistical power. A further limitation is the potential for selection bias in both the VoR Group and HC. Given the social stigma attached to VoR in the Chinese cultural context that often results in sexual shame, fear and anxiety over disclosure of the rape, guilt over derogating family honor, self-scrutiny and self-blame after the fact, and even blame of the victim, contribute to the potential selection bias in the VoR Group. Regarding the selection bias in HC, it was not our intention for this group (12 HC) to be representative of the general population, nor were the 65-pooled controls. This group was particularly designed to match the VoR with PTSD regarding the major demographic characteristics. However, given the fact that HC were recruited from healthy workers, selection bias from the healthy-worker effect should be borne in mind.

The use of a cross-sectional design is another significant limitation of this study. The shared variance estimated between variables in a cross-sectional design does not allow for a critical examination of causal relationships among them. Consequently, we cannot state categorically whether changes in brain density were the cause or the effect of trauma exposure/PTSD.

## 5. Conclusion

The abnormal density of cerebral regions in VoR with PTSD supports the hypothesis that PTSD is associated with structural plastic changes to brain. The results suggest that the medial frontal cortex, pre-central cortex, posterior cingulate cortex, post-central cortex, inferior parietal lobule, and cerebellum are likely to contribute to the neural mechanisms underlying PTSD. These findings suggest that the pre-central cortex of PTSD may be involved in the neural basis of motor and linguistic PTSD symptomatology; the middle temporal gyrus and fusiform cortex may be implicated in the dysfunction of memory and dissociative symptoms in PTSD; the posterior cingulate cortex may underlie pathological symptoms provoked by traumatic reminders of PTSD; the inferior parietal lobule of PTSD might play an important role in the dysfunction of memory, recognition, and deductive reasoning; and the cerebellum may contribute to the functional compensation for the pathological changes in the neuro-circuitry of PTSD. These findings may lead to a better understanding of the basis of brain structure for clinical symptoms with VoR of PTSD. Also, they can be benefit to the researches of PTSD treatment.

Future studies call for exploring experiences of rape and associated PTSD symptomatology by using case-control or longitudinal designs, investigating the effect of the specific social and cultural meanings of rape, examining the impact on individuals' posttraumatic response and coping ability, and looking into the relation between brain GMD and PTSD

symptoms. In addition, the findings of this study need to be confirmed in the future and in different subgroups of PTSD patients.

## 6. Acknowledgments

We acknowledge support from grant from the National Natural Science Foundation of China (30830046 to Lingjiang Li and Shuangge Sui), the National Science and Technology Program of China (2007BAI17B02 to Lingjiang Li), and the National 973 Program of China (2009CB918303, 2006CB5000800 to Lingjiang Li).

## 7. References

- Abe, O., Yamasue, H., Kasai, K., Yamada, H., Aoki, S., Iwanami, A., Ohtani, T., Masutani, Y., Kato, N., & Ohtomo, K. (2006). Voxel-based diffusion tensor analysis reveals aberrant anterior cingulum integrity in posttraumatic stress disorder due to terrorism. *Psychiatry Research-Neuroimaging*, Vol. 146, No. 3, pp. 231-242
- Allen, G., McColl, R., Barnard, H., Ringe, WK., Fleckenstein, J., & Cullum, CM. (2005). Magnetic resonance imaging of cerebellar-prefrontal and cerebellar-parietal functional connectivity. *Neuroimage*, Vol. 28, No. 1, pp. 39-48
- Ashburner, J. & Friston, KJ. (2000). Voxel-based morphometry - The methods. *Neuroimage*, Vol. 11, pp. 805-821
- Bellis, MD. & Kuchibhatla, M. (2006). Cerebellar volumes in pediatric maltreatment-related posttraumatic stress disorder. *Biological Psychiatry*, Vol. 60, No. 7, pp. 697-703
- Bischoff-Grethe, A., Ivry, RB., & Grafton, ST. (2002). Cerebellar involvement in response reassignment rather than attention. *The Journal of Neuroscience*, 22, No. 2, pp. 546-553
- Blake, DD., Weathers, FW., Nagy, LM., Kaloupek, DG., Gusman, FD., Charney, DS., & Keane, TM. (1995). The Development of a Clinician-Administered PTSD Scale. *Journal of Traumatic Stress*, Vol. 8, No. 1, pp. 75-90
- Bonne, O., Gilboa, A., Louzoun, Y., Brandes, D., Yona, I., Lester, H., Barkai, G., Freedman, N., Chisin, R., & Shalev, AY. (2003). Resting regional cerebral perfusion in recent posttraumatic stress disorder. *Biological Psychiatry*, Vol. 54, No. 10, pp. 1077-1086
- Bossini, L. & Castrogiovanni, P. (2007). Pre- and posttreatment neuroimaging of PTSD: Focus on hippocampal volume. *Journal of Psychosomatic Research*, No. 63, pp. 310-310
- Botez, MI. (1993). Cerebellum and non-motor behaviour. *Romanian journal of neurology and psychiatry*, Vol. 31, No. 3-4, pp. 189-193
- Bremner, JD. & Charney, DS. (1994). Neurobiology of Posttraumatic Stress Disorder - Implications for Treatment. In: *Current Therapeutic Approaches to Panic and Other Anxiety Disorders*, Darcourt, G., Mendlewicz, J., Racagni, G., Brunello, N. (Eds.), Vol. 8, pp. 171-186
- Bremner, JD., Randall, P., Scott, TM., Bronen, RA., Seibyl, JP., Southwick, SM., Delaney, RC., McCarthy, G., Charney, DS., & Innis, RB. (1995). MRI-Based Measurement of Hippocampal Volume in Patients with Combat-Related Posttraumatic-Stress-Disorder. *The American Journal of Psychiatry*, Vol. 152, pp. 973-981

- Bremner, JD., Staib, LH., Kaloupek, D., Southwick, SM., Soufer, R., & Charney, DS. (1999a). Neural correlates of exposure to traumatic pictures and sound in Vietnam combat veterans with and without posttraumatic stress disorder: A positron emission tomography study. *Biological Psychiatry*, Vol. 45, pp. 806-816
- Bremner, JD., Narayan, M., Staib, LH., Southwick, SM., McGlashan, T., & Charney, DS. (1999b). Neural correlates of memories of childhood sexual abuse in women with and without posttraumatic stress disorder. *The American Journal of Psychiatry*, Vol. 156, pp. 1787-1795
- Bremner, JD., Vythilingam, M., Vermetten, E., Southwick, SM., McGlashan, T., Staib, LH., Soufer, R., & Charney, DS. (2003). Neural correlates of declarative memory for emotionally valenced words in women with posttraumatic stress disorder related to early childhood sexual abuse. *Biological Psychiatry*, Vol. 53, No. 10, pp. 879-889
- Bremner, JD. (2006). Traumatic stress: effects on the brain. *Dialogues Clinical Neuroscience*, Vol. 8, No. 4, pp. 445-461
- Bremner, JD., Elzinga, B., Schmahl, C., & Vermetten, E. (2008). Structural and functional plasticity of the human brain in posttraumatic stress disorder. In: *Progress in Brain Research*, de Kloet, ER., Oitzl, MS. & Vermetten E. (Eds.), Vol. 167, pp. 171-186
- Carrion, VG., Weems, CF., Eliez, S., Patwardhan, A., Brown, W., Ray, RD., & Reiss, AL. (2001). Attenuation of frontal asymmetry in pediatric posttraumatic stress disorder. *Biological Psychiatry*, Vol. 50, No. 12, pp. 943-951
- Ciesielski, KT. & Knight, JE. (1994). Cerebellar abnormality in autism: a nonspecific effect of early brain damage? *Acta Neurobiologiae Experimentalis*, Vol. 54, No. 2, pp. 151-154
- Claeys, KG., Orban, GA., Dupont, P., Sunaert, S., Hecke, PV., & Schutter, ED. (2003). Involvement of multiple functionally distinct cerebellar regions in visual discrimination: a human functional imaging study. *Neuroimage*, Vol. 20, No. 2, pp. 840-854
- Corbo, V., Clement, MH., Armony, JL., Pruessner, JC., & Brunet, A. (2005). Size versus shape differences: Contrasting voxel-based and volumetric analyses of the anterior cingulate cortex in individuals with acute posttraumatic stress disorder. *Biological Psychiatry*, Vol. 58, No. 2, pp. 119-124
- Danckwerts, A. & Leatham, J. (2003). Questioning the Link Between PTSD and Cognitive Dysfunction. *Neuropsychology Review*, Vol. 13, pp. 221-235
- Doronbekov, TK., Tokunaga, H., Ikejiri, Y., Kazui, H., Hatta, N., Masaki, Y., Ogino, A., Miyoshi, N., Oku, N., Nishikawa, T., & Takeda, M. (2005). Neural basis of fear conditioning induced by video clip: Positron emission tomography study. *Psychiatry and Clinical Neurosciences*, Vol. 59, No. 2, pp. 155-162
- Duffau, H., Capelle, L., Denvil, D., Gatignol, P., Sichez, N., Lopes, M., Sichez, JP., & Van Effenterre, R. (2003). The role of dominant premotor cortex in language: a study using intraoperative functional mapping in awake patients. *Neuroimage*, Vol. 20, No. 4, pp. 1903-1914
- Emdad, R., Bonekamp, D., Sondergaard, HP., Bjorklund, TB., Agartz, I., Ingvar, M., & Theorell, TR. (2006). Morphometric and psychometric comparisons between non-substance-abusing patients with posttraumatic stress disorder and normal controls. *Psychotherapy and Psychosomatics*, Vol. 75, pp. 122-132

- Farrow, TFD., Hunter, MD., Wilkinson, ID., Gouneea, C., Fawbert, D., Smith, R., Lee, KH., Mason, S., Spence, SA., & Woodruff, PWR. (2005). Quantifiable change in functional brain response to empathic and forgivability judgments with resolution of posttraumatic stress disorder. *Psychiatry Research-Neuroimaging*, Vol. 140, No. 1, pp. 45-53
- Fennema-Notestine, C., Stein, MB., Kennedy, CM., Archibald, SL., & Jernigan, TL. (2002). Brain morphometry in female victims of intimate partner violence with and without posttraumatic stress disorder. *Biological Psychiatry*, Vol. 52, No. 11, pp. 1089-1101
- Friston, KJ., Holmes, AP., Worsley, KJ., Poline, JB., Frith, CD., & Frackowiak, RSJ. (1995). Statistical parametric maps in functional imaging: A general linear approach. *Human Brain Mapping*, Vol. 2, pp. 189-210
- Gao, JH., Parsons, LM., Bower, JM., Xiong, JH., & Fox, PT. (1996). Cerebellum implicated in sensory acquisition and discrimination rather than motor control. *Science*, Vol. 272, No. 5261, pp. 545-547
- Geng, JJ., Eger, E., Ruff, CC., Kristjansson, A., Rotshtein, P., & Driver, J. (2006). On-line attentional selection from competing stimuli in opposite visual fields: Effects on human visual cortex and control processes. *Journal of Neurophysiology*, Vol. 96, No. 5, pp. 2601-2612
- Geuze, E., Vermetten, E., & Bremner, JD. (2005). MR-based in vivo hippocampal volumetrics: 2. Findings in neuropsychiatric disorders. *Molecular Psychiatry*, Vol. 10, pp. 160-184
- Geuze, E., Vermetten, E., Goebel, R., & Westenberg, H. (2008a). Thinner prefrontal cortex in veterans with posttraumatic stress disorder. *Biological Psychiatry*, Vol. 41, No. 3, pp. 675-681
- Geuze, E., Vermetten, E., Ruf, M., de Kloet, CS., & Westenberg, HGM. (2008b). Neural correlates of associative learning and memory in veterans with posttraumatic stress disorder. *Journal of Psychiatric Research*, Vol. 42, No. 8, pp. 659-669
- Gianaros, PJ., Jennings, JR., Sheu, LK., Derbyshire, SW., & Matthews KA. (2007). Heightened Functional Neural Activation to Psychological Stress Covaries With Exaggerated Blood Pressure Reactivity. *Hypertension*, Vol. 49, pp. 134-140
- Gilbertson, M., Shenton, M., Ciszewski, A., Kasai, K., Lasko, N., Orr, S., & Pitman, R. (2002). Smaller hippocampal volume predicts pathologic vulnerability to psychological trauma. *Nature Neuroscience*, Vol. 5, No. 11, pp. 1242-1247
- Gold, BT. & Buckner, RL. (2002). Common prefrontal regions coactivate with dissociable posterior regions during controlled semantic and phonological tasks. *Neuron*, Vol. 35, No. 4, pp. 803-812
- Golier, JA., Harvey, PD., Legge, J., & Yehuda, R. (2006). Memory performance in older trauma survivors - Implications for the longitudinal course of PTSD. *Psychobiology of Posttraumatic Stress Disorder: A Decade of Progress*, Vol. 1071, pp. 54-66
- Green, BL. (1996). Trauma History Questionnaire. In: *Measurement of stress, trauma, and adaptation*, Stamm, BH, (Ed.), pp. 366-369, Sidran Press, Lutherville, MD



- Guenther, FH., Ghosh, SS., & Tourville, JA. (2005). Neural modeling and imaging of the cortical interactions underlying syllable production. *Brain and Language*, Vol. 96, No. 3, pp. 280-301
- Gurvits, TV., Shenton, ME., Hokama, H., Ohta, H., Lasko, NB., Gilbertson, MW., Orr, SP., Kikinis, R., Jolesz, FA., McCarley, RW., & Pitman, RK. (1996). Magnetic resonance imaging study of hippocampal volume in chronic, combat-related posttraumatic stress disorder. *Biological Psychiatry*, Vol. 40, No. 11, pp. 1091-1099
- Hakamata, Y., Matsuoka, Y., Inagaki, M., Nagamine, M., Hara, E., Imoto, S., Murakami, K., Kim, Y., & Uchitomi, Y. (2007). Structure of orbitofrontal cortex and its longitudinal course in cancer-related post-traumatic stress disorder. *Neuroscience Research*, Vol. 59, No. 4, pp. 383-388
- Hou, CL., Liu, J., Wang, K., Li, LJ., Liang, M., He, Z., Liu, Y., Zhang, Y., Li, WH., & Jiang, TZ. (2007). Brain responses to symptom provocation and trauma-related short-term memory recall in coal mining accident survivors with acute severe PTSD. *Brain Research*, Vol. 1144, pp. 165-174
- Jatzko, A., Rothenhofer, S., Schmitt, A., Gaser, C., Demirakca, T., Weber-Fahr, W., Wessa, M., Magnotta, V., & Braus, DF. (2006a). Hippocampal volume in chronic posttraumatic stress disorder (PTSD): MRI study using two different evaluation methods. *Journal of Affective Disorders*, Vol. 94, No. 1-3, pp. 121-126
- Jatzko, A., Schmitt, A., Demirakca, T., Weimer, E., & Braus, D. (2006b). Disturbance in the neural circuitry underlying positive emotional processing in post-traumatic stress disorder (PTSD) - An fMRI study. *European Archives of Psychiatry and Clinical Neuroscience*, Vol. 256, No. 2, pp. 112-114
- Karl, A., Schaefer, M., Malta, LS., Dorfel, D., Rohleder, N., & Werner, A. (2006). A meta-analysis of structural brain abnormalities in PTSD. *Neuroscience and Biobehavioral Reviews*, Vol. 30, No. 7, pp. 1004-1031
- Kasai, K., Yamasue, H., Araki, T., Sakamoto, H., & Kato, N. (2006). Structural and Functional Neuroimaging in Posttraumatic Stress Disorder. In: *PTSD: Brain Mechanisms and Clinical Implications*. Kato, N., Kawata, M., & Pitman, RK. (Eds.), pp. 203-209, Springer, Tokyo, Japan.
- Kasai, K., Yamasue, H., Gilbertson, MW., Shenton, ME., Rauch, SL., & Pitman, RK. (2008). Evidence for Acquired Pregenuel Anterior Cingulate Gray Matter Loss from a Twin Study of Combat-Related Posttraumatic Stress Disorder. *Biological Psychiatry*, Vol. 63, No. 6, pp. 550-556
- Knauff, M., Mulack, T., Kassubek, J., Salih, HR., & Greenlee, MW. (2002). Spatial imagery in deductive reasoning: a functional MRI study. *Cognitive Brain Research*, Vol. 13, No. 2, pp. 203-212
- Konarski, JZ., McIntyre, RS., Grupp, LA., & Kennedy, SH. (2005). Is the cerebellum relevant in the circuitry of neuropsychiatric disorders? *Journal of Psychiatry & Neuroscience*, Vol. 30, No. 3, pp. 178-186
- Lanius, RA., Williamson, PC., Densmore, M., Boksman, K., Neufeld, RW., Gati, JS., & Menon, RS. (2004). The nature of traumatic memories: A 4-T fMRI functional connectivity analysis. *The American Journal of Psychiatry*, Vol. 161, pp. 36-44


- Lanius, RA., Williamson, PC., Bluhm, RL., Densmore, M., Boksman, K., Neufeld, RWJ., Gati, JS., & Menon, RS. (2005). Functional connectivity of dissociative responses in posttraumatic stress disorder: A functional magnetic resonance imaging investigation. *Biological Psychiatry*, Vol. 57, No. 8, pp. 873-884
- Lanius, RA., Bluhm, R., Lanius, U., & Pain, C. (2006). A review of neuroimaging studies in PTSD: Heterogeneity of response to symptom provocation. *Journal of Psychiatric Research*, Vol. 40, No. 8, pp. 709-729
- Leroi, I., O'Hearn, E., Marsh, L., Lyketsos, CG., Rosenblatt, A., Ross, CA., Brandt, J., & Margolis, RL. (2002). Psychopathology in patients with degenerative cerebellar diseases: a comparison to Huntington's disease. *The American Journal of Psychiatry*, Vol. 159, pp. 1306-1314
- Li, L., Chen, S., Liu, J. Zhang, J., He, Z., & Lin, X. (2006). Magnetic resonance imaging and magnetic resonance spectroscopy study of deficits in hippocampal structure in fire victims with recent-onset posttraumatic stress disorder. *The Canadian Journal of Psychiatry*, Vol. 51, No. 7, pp. 431-437
- Liberzon, I., King, AP., Britton, JC., Phan, KL., Abelson, JL., & Taylor, SF. (2007). Paralimbic and medial prefrontal cortical involvement in neuroendocrine responses to traumatic stimuli. *The American Journal of Psychiatry*, Vol. 164, pp. 1250-1258
- Liberzon, I. & Sripada, CS. (2008). The functional neuroanatomy of PTSD: A critical review. *Stress Hormones and Post Traumatic Stress Disorder: Basic Studies and Clinical Perspectives, Progress in Brain Research*, Vol. 167, pp. 151-169, ISSN 0079-6123
- Lindauer, RJL., Vlieger, EJ., Jalink, M., Olf, M., Carlier, IVE., Majoie, CBLM., den Heeten, GJ., & Gersons, BPR. (2004a). Smaller hippocampal volume in dutch police officers with posttraumatic stress disorder. *Biological Psychiatry*, Vol. 56, No. 5, pp. 356-363
- Lindauer, RJL., Booij, J., Habraken, JBA., Uylings, HBM., Olf, M., Carlier, IVE., den Heeten, GJ., van Eck-Smit, BLF., & Gersons, BPR. (2004b). Cerebral blood flow changes during script-driven imagery in police officers with posttraumatic stress disorder. *Biological Psychiatry*, Vol. 56, No. 11, pp. 853-861
- Lindauer, RJL., Booij, J., Habraken, JBA., van Meijel EPM., Uylings, HBM., Olf, M., Carlier, IVE., den Heeten, GJ., van Eck-Smit, BLF., & Gersons, BPR. (2008). Effects of psychotherapy on regional cerebral blood flow during trauma imagery in patients with post-traumatic stress disorder: a randomized clinical trial. *Psychological Medicine*, Vol. 38, No. 4, pp. 543-554
- Liotti, M., Mayberg, HS., Brannan, SK., McGinnis, S., Jerabek, P., & Fox, PT. (2000). Differential limbic-cortical correlates of sadness and anxiety in healthy subjects: implication for affective disorders. *Biological Psychiatry*, Vol. 48, No. 1, pp. 30-42
- Liszewski, CM., O'Hearn, E., Leroi, I., Gourley, L., Ross, CA., & Margolis, RL. (2004). Cognitive Impairment and Psychiatric Symptoms in 133 Patients With Diseases Associated With Cerebellar Degeneration. *The Journal of Neuropsychiatry and Clinical Neurosciences*, Vol. 16, No. 1, pp. 109-112
- Luders, E., Gaser, C., Jancke, L., & Schlaug, G. (2004). A voxel-based approach to gray matter asymmetries. *Neuroimage*, Vol. 22, No. 2, pp. 656-664

- Mandolesi, L., Leggio, MG., Graziano, A., Neri, P. & Petrosini, L. (2001). Cerebellar contribution to spatial event processing: involvement in procedural and working memory components. *European Journal of Neuroscience*, Vol. 4, No. 12, pp. 2011-2022
- Mazziotta, JC., Toga, AW., Evans, A., Fox, P., & Lancaster, J. (1995). A probabilistic atlas of the human brain: theory and rationale for its development. The International Consortium for Brain Mapping (ICBM). *NeuroImage*, Vol. 2, No. 2, pp. 89-101
- Middleton, FA. & Strick, PL. (2001). Cerebellar projections to the prefrontal cortex of the primate. *The Journal of Neuroscience*, Vol. 21, No. 2, pp. 700-712
- Milad, MR., Rauch, SL., Pitman, RK., & Quirk, GJ. (2006) Fear extinction in rats: Implications for human brain imaging and anxiety disorders. *Biological Psychology*, Vol. 73, No. 1, pp. 61-71
- Miller, L. (1999). Atypical psychological responses to traumatic brain injury: PTSD and beyond. *Neurorehabilitation*, Vol. 13, No. 2, pp. 79-90
- Molina, ME., Isoardi, R., Prado, MN., & Bentolila, S. (2010). Basal cerebral glucose distribution in long-term post-traumatic stress disorder. *World Journal of Biological Psychiatry*, Vol. 11, No. 2, pp. 493-501
- Morey, RA., Petty, CM., Cooper, DA., Labar, KS., & McCarthy, G. (2008). Neural systems for executive and emotional processing are modulated by symptoms of posttraumatic stress disorder in Iraq War veterans. *Psychiatry Research-Neuroimaging*, Vol. 162, No. 1, pp. 59-72
- Nemeroff, CB., Bremner, JD., Foa, EB., Mayberg, HS., North, CS., & Stein, MB. (2006). Posttraumatic stress disorder: A state-of-the-science review. *Journal of Psychiatric Research*, Vol. 40, No. 1, pp. 1-21
- Nielsen, FA., Balslev, D., & Hansen, LK. (2005). Mining the posterior cingulate: Segregation between memory and pain components. *Neuroimage*, Vol. 27, No. 3, pp. 520-532
- Pavic, L., Gregurek, R., Rados, M., Brkljacic, B., Brajkovic, L., Simetin-Pavic, I., Ivanac, G., Pavlisa, G., & Kalousek, V. (2007). Smaller right hippocampus in war veterans with posttraumatic stress disorder. *Psychiatry Research-Neuroimaging*, 154, No. 2, pp. Vol. 191-198
- Phan, KL., Wager, T., Taylor, SF., & Liberzon, I. (2002). Functional neuroanatomy of emotion: a meta-analysis of emotion activation studies in PET and fMRI. *Neuroimage*, Vol. 16, No. 2, pp. 331-348
- Rhodes, G., Byatt, G., Michie, PT., & Puce, A. (2004). Is the fusiform face area specialized for faces, individuation, or expert individuation? *Journal of Cognitive Neuroscience*, Vol. 16, No. 2, pp. 189-203
- Richert, KA., Carrion, VG., Karchemskiy, A., & Reiss, AL. (2006). Regional differences of the prefrontal cortex in pediatric PTSD: an MRI study. *Depression and Anxiety*, Vol. 23, No. 1, pp. 17-25
- Rossion, B., Dricot, L., Devolder, A., Bodart, JM., Crommelinck, M., de Gelder, B., & Zoontjes, R. (2000). Hemispheric asymmetries for whole-based and part-based face processing in the human fusiform gyrus. *Journal of Cognitive Neuroscience*, Vol. 12, No. 5, pp. 793-802

- Rothbaum, BO., Foa, EB., Riggs, D.S, Murdock, T., & Walsh, W. (1992). A Prospective Examination of Posttraumatic-Stress-Disorder in Rape Victims. *Journal of Traumatic Stress*, Vol. 5, No. 3, pp. 455-475
- Ruggiero, K.J, Ben, KD., Scotti, JR., & Rabalais, AE. (2003). Psychometric Properties of the PTSD Checklist – Civilian Version. *Journal of Traumatic Stress*, Vol. 16, No. 5, pp. 495-502
- Sachinvala, N., Kling, A., Suffin, S., Lake, R., & Cohen, M. (2000). Increased regional cerebral perfusion by <sup>99m</sup>Tc hexamethyl propylene amine oxime single photon emission computed tomography in post-traumatic stress disorder. *Military Medicine*, Vol. 165, No. 6, pp. 473-479
- Sareen, J., Cox, BJ., Stein, MB., Afifi, TO., Fleet, C., & Asmundson, GJG. (2007). Physical and mental comorbidity, disability, and suicidal behavior associated with posttraumatic stress disorder in a large community sample. *Psychosomatic Medicine*, Vol. 69, No. 3, pp. 242-248
- Schmahmann, JD. & Caplan, D. (2006). Cognition, emotion and the cerebellum. *Brain*, 129, No. 2, pp. 290-292
- Schweizer, TA., Oriet, C., Meiran, N., Alexander, MP., Cusimano, M., & Stuss, DT. (2007). The Cerebellum Mediates Conflict Resolution. *Journal of Cognitive Neuroscience*, Vol. 19, No. 12, pp.1974-1982
- Shaw, ME., Strother, SC., McFarlane, AC., Morris, P., Anderson, J., Clark, CR., & Egan, GF. (2002). Abnormal functional connectivity in posttraumatic stress disorder. *NeuroImage*, Vol. 15, No. 3, pp.661-674
- Shin, LM., Rauch, SL., & Pitman, RK. (2006). Amygdala, Medial Prefrontal Cortex, and Hippocampal Function in PTSD. *Annals of the New York Academy of Sciences*, Vol. 1071, pp. 67-79
- Tanji, J. (1994). The Supplementary Motor Area in the Cerebral-Cortex. *Neuroscience Research*, Vol. 19, No. 3, pp. 251-268
- Tjaden, P. & Thoennes, N. (2000). Full Report of the Prevalence, Incidence, and Consequences of Violence Against Women: Findings From the National Violence Against Women Survey, In: *National Criminal Justice Reference Service*, 11/2000, Available from <http://www.ncjrs.gov/app/Publications/abstract.aspx?ID=183781>
- Tupler, LA. & De Bellis, MD. (2006). Segmented hippocampal volume in children and adolescents with posttraumatic stress disorder. *Biological Psychiatry*, Vol. 59, No. 6, pp.523-529
- Villarreal, G. & King, CY. (2004). Neuroimaging studies reveal brain change in posttraumatic stress disorder. *Psychiatric Annals*, Vol. 34, No. 11, pp.845-856
- Vokaer, M., Bier, JC., & Elincx, S., Claes, T., Paquier, P., Goldman, S., Bartholome, EJ., & Pandolfo, M. (2002). The cerebellum may be directly involved in cognitive functions. *Neurology*, Vol. 58, No. 6, pp. 967-970
- Vythilingam, M., Luckenbaugh, DA., Lam, T., Morgan, CA., Lipschitz, D., Charney, DS., Bremner, JD., & Southwick, SM. (2005). Smaller head of the hippocampus in Gulf War-related posttraumatic stress disorder. *Psychiatry Research-Neuroimaging*, Vol. 139, pp. 89-99

- Winter, H. & Irle, E. (2004). Hippocampal volume in adult burn patients with and without posttraumatic stress disorder. *The American Journal of Psychiatry*, Vol. 161, No. 12, pp.2194-2200
- Xie, S., Xiao J., Bai J., & Jiang, X. (2004). Memory tasks in normal aged volunteers: an fMRI study. *China Journal of Medical Imaging Technology*, Vol. 20, pp. 571-574
- Yamasue, H., Kasai, K., Iwanami, A., Ohtani, T., Yamada, H., Abe, O., Kuroki, N., Fukuda, R., Tochigi, M., Furukawa, S., Sadamatsu, M., Sasaki, T., Aoki, S., Ohtomo, K., Asukai, N., & Kato, N. (2003). Voxel-based analysis of MRI reveals anterior cingulate gray-matter volume reduction in posttraumatic stress disorder due to terrorism. *Proceedings of the National Academy of Sciences of the United States of America*, Vol. 100, No. 15, pp. 9039-9043
- Zhu, J., Yung, W., Chow, BK., Chan, Y., & Wang, J. (2006). The cerebellar-hypothalamic circuits: Potential pathways underlying cerebellar involvement in somatic-visceral integration. *Brain Research Reviews*, Vol. 52, No. 1, pp. 93-106

IntechOpen



## **Neuroimaging for Clinicians - Combining Research and Practice**

Edited by Dr. Julio F. P. Peres

ISBN 978-953-307-450-4

Hard cover, 424 pages

**Publisher** InTech

**Published online** 09, December, 2011

**Published in print edition** December, 2011

Neuroimaging for clinicians sourced 19 chapters from some of the world's top brain-imaging researchers and clinicians to provide a timely review of the state of the art in neuroimaging, covering radiology, neurology, psychiatry, psychology, and geriatrics. Contributors from China, Brazil, France, Germany, Italy, Japan, Macedonia, Poland, Spain, South Africa, and the United States of America have collaborated enthusiastically and efficiently to create this reader-friendly but comprehensive work covering the diagnosis, pathophysiology, and effective treatment of several common health conditions, with many explanatory figures, tables and boxes to enhance legibility and make the book clinically useful. Countless hours have gone into writing these chapters, and our profound appreciation is in order for their consistent advice on the use of neuroimaging in diagnostic work-ups for conditions such as acute stroke, cell biology, ciliopathies, cognitive integration, dementia and other amnesic disorders, Post-Traumatic Stress Disorder, and many more

### **How to reference**

In order to correctly reference this scholarly work, feel free to copy and paste the following:

Shuang Ge Sui, Ling Jiang Li, Yan Zhang, Ming Xiang Wu and Mark E. King (2011). Abnormal Brain Density in Victims of Rape with PTSD in Mainland China: A Voxel-Based Analysis of Magnetic Resonance Imaging Study, Neuroimaging for Clinicians - Combining Research and Practice, Dr. Julio F. P. Peres (Ed.), ISBN: 978-953-307-450-4, InTech, Available from: <http://www.intechopen.com/books/neuroimaging-for-clinicians-combining-research-and-practice/abnormal-brain-density-in-victims-of-rape-with-ptsd-in-mainland-china-a-voxel-based-analysis-of-magn>

**INTECH**  
open science | open minds

### **InTech Europe**

University Campus STeP Ri  
Slavka Krautzeka 83/A  
51000 Rijeka, Croatia  
Phone: +385 (51) 770 447  
Fax: +385 (51) 686 166  
[www.intechopen.com](http://www.intechopen.com)

### **InTech China**

Unit 405, Office Block, Hotel Equatorial Shanghai  
No.65, Yan An Road (West), Shanghai, 200040, China  
中国上海市延安西路65号上海国际贵都大饭店办公楼405单元  
Phone: +86-21-62489820  
Fax: +86-21-62489821

© 2011 The Author(s). Licensee IntechOpen. This is an open access article distributed under the terms of the [Creative Commons Attribution 3.0 License](#), which permits unrestricted use, distribution, and reproduction in any medium, provided the original work is properly cited.

IntechOpen

IntechOpen